

2

Pathology of Teeth

Environmental Defects of Enamel, 42	Natal Teeth, 58
Turner Hypoplasia, 42	Microdontia and Macrodontia, 58
Dental Disturbances due to	Double Teeth, 60
Antineoplastic Therapy, 44	Talon Cusp, 62
Dental Fluorosis, 44	Dens Evaginatus and Shovel-Shaped
Tooth Wear, 46	Incisors, 62
Attrition, 46	Dens Invaginatus, 64
Abrasion, 46	Enamel Pearls, 64
Erosion, 48	Cervical Enamel Extension, 66
Abfraction, 48	Taurodontism, 66
Internal Resorption, 50	Hypercementosis, 66
External Resorption, 50	Dilaceration, 68
Discolorations of Teeth, 52	Supernumerary Roots, 68
Extrinsic Tooth Staining, 52	Syndrome-Associated Enamel
Intrinsic Tooth Staining, 52	Defects, 68
Ankylosis, 54	Amelogenesis Imperfecta, 70
Transposition, 54	DSPP-Associated Dentin Disorders, 72
Hypodontia, 54	Dentin Dysplasia, Type 1, 74
Hyperdontia, 56	Regional Odontodysplasia, 74

Environmental Defects of Enamel

Figs. 2.1 and 2.2

Tooth enamel develops in three major stages: matrix deposition, initial mineralization, and final maturation. Ameloblasts are extremely sensitive to external influences, with more than 90 different factors known to be associated with disturbance in enamel formation. Although the causes are diverse, the most commonly reported factors include serious disease during the first 3 years of life, hypocalcemia, renal disorders, nutritional deficiencies, and viral infections associated with high fever.

Unlike bone, dental enamel cannot be remodeled. With knowledge of the timing of tooth formation, the site of defective enamel can be used to pinpoint the time of damage. The formation of the deciduous tooth crowns begins around the 14th week of pregnancy and continues until 12 months of age. The formation of the permanent tooth crowns is initiated at 6 months and continues to age 15.

The associated enamel disturbance may be quantitative, qualitative, or both. **Enamel hypoplasia** arises from failure of appropriate matrix deposition and presents as pits, grooves, or larger areas of missing enamel. In contrast, **enamel opacities** are areas of enamel hypomaturization in which the tooth presents with a normal size and shape but demonstrates an area of white, cream, yellow, or brown opacity.

The pattern of enamel disturbance tends to be bilaterally symmetric and involves only the portion of enamel that was developing at the time of the insult. Early environmental influences affect the anterior dentition and first molars, whereas damage later in tooth development alters the bicuspid and second molars. The enamel damage usually is associated with aesthetic rather than functional difficulties. Significantly altered anterior teeth may be repaired with composite resin restorations, labial veneers, or full crowns.

Turner Hypoplasia

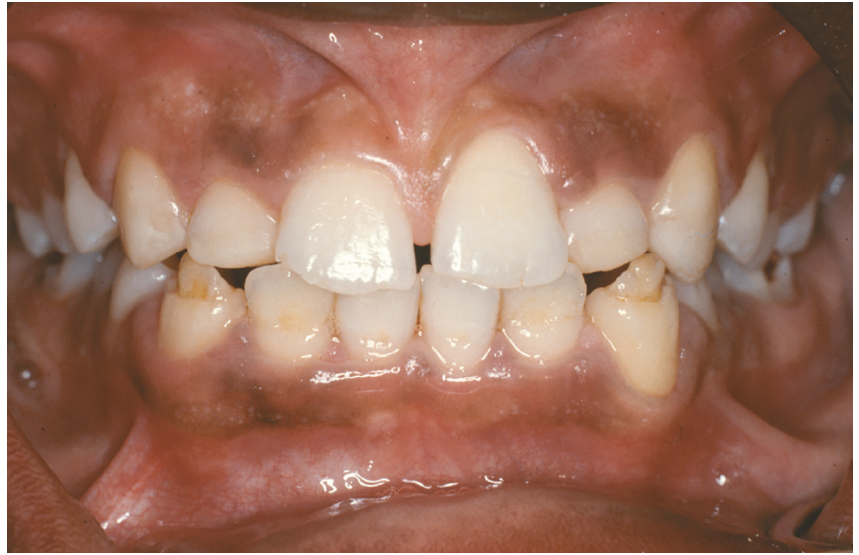Fig. 2.3

Environmental enamel defects also may be isolated to a single permanent tooth when associated with a local rather than systemic influence. When seen in an incisor, the ameloblasts typically were damaged by a traumatic event that forced a deciduous incisor into the underlying developing permanent tooth. Much more frequently, localized developmental defects arise in bicuspid secondary to infection of an overlying deciduous molar. The enamel defects vary from focal areas of white or yellow hypomaturization to extensive hypoplasia that can involve the entire crown.

■ **Figure 2.1**

Environmental Enamel Hypoplasia

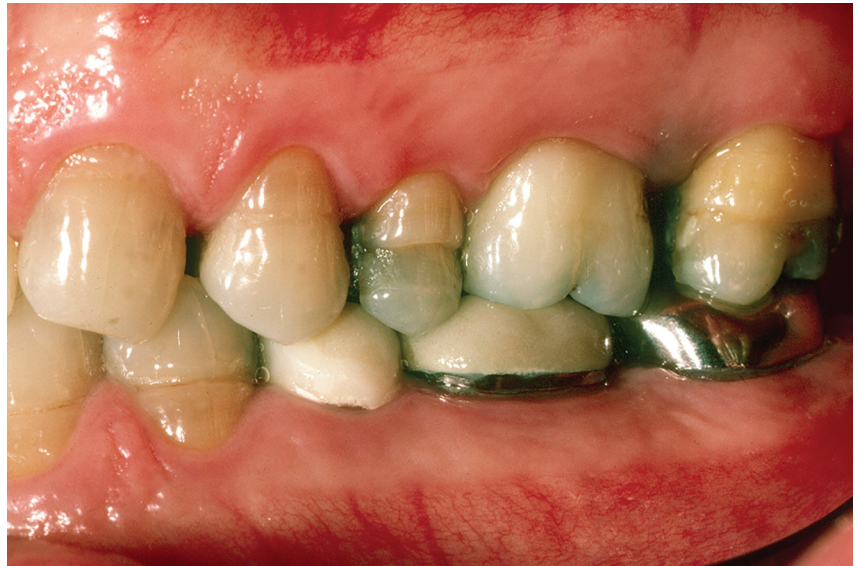Dentition demonstrating bilaterally symmetric enamel grooves affecting the anterior teeth.



■ **Figure 2.2**

Environmental Enamel Hypoplasia

Dentition demonstrating enamel grooves affecting both premolars and second molars in both arches.



■ **Figure 2.3**

Turner Hypoplasia

Maxillary central incisors demonstrating localized area of yellowish hypomaturation.

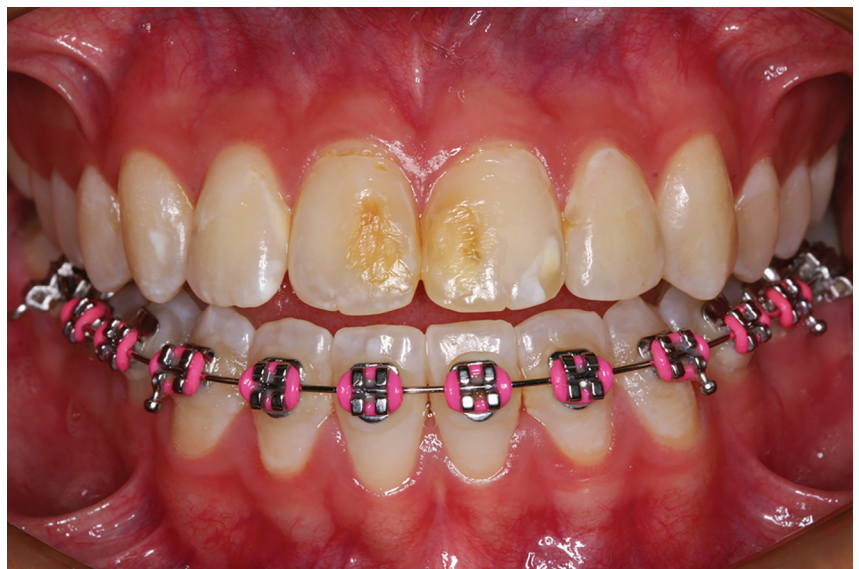

Fig. 2.4

Antineoplastic therapy administered during childhood has been associated with alterations in tooth formation. The developing teeth are most sensitive to local radiation therapy, but less significant effects also can be seen in association with systemic chemotherapy. Radiation induces both quantitative and qualitative defects, whereas chemotherapy predominantly produces qualitative changes. The severity varies with the patient's age at treatment, the type of therapy, and the dose and field of radiation.

The alterations are seen primarily in children treated prior to the age of 12, with the most severe effects noted in children younger than 5 years. If exposure occurs prior to crown formation, then microdontia or hypodontia may occur. If exposure occurs during later stages of tooth development, then enamel hypomaturation, short pointed roots, and taurodontism may be seen.

Dental Fluorosis

Figs. 2.5 and 2.6

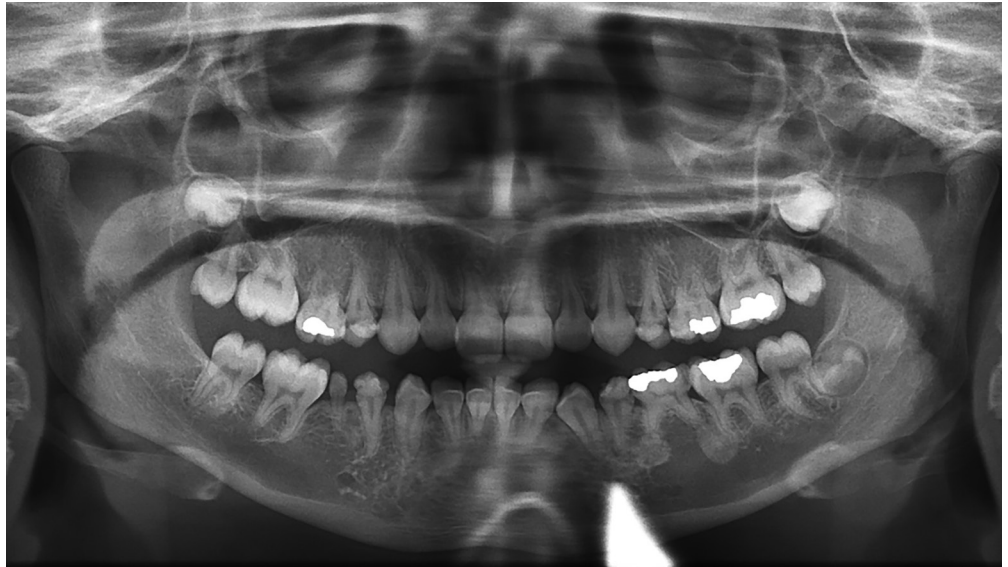Exposure to fluoride has been shown to be an effective agent for reduction in dental caries, but it also can be associated with enamel defects known as dental fluorosis. Healthcare advocates strive to determine the most appropriate level of fluoride exposure that will result in maximal caries reduction and minimal dental fluorosis.

In 1962 the US Public Health Service recommended fluoridation of the water supply nationwide, with concentrations varying by climate. Because of increased water consumption in warmer regions of the United States, the recommended concentration of fluoride in the nation's water supply varied from 0.7 to 1.2 mg/L. A recent increased prevalence of dental fluorosis has led to a reexamination of the recommended fluoride levels in the nation's water supply. Secondary to increased availability of fluoride from other sources, the US Public Health Service in 2015 recommended a single nationwide standard of 0.7 mg/L of fluoride in all community water supplies. Even in communities with fluoride levels maintained at 0.7 ppm, a Cochrane review revealed the prevalence of aesthetically obvious fluorosis to be approximately 12%.

Teeth with clinically evident fluorosis are caries resistant and demonstrate areas of white opaque enamel that may exhibit intermixed areas of yellow or brown discoloration. In severe fluorosis, irregular brownish depressed areas of defective surface enamel may be seen, which has been termed **mottled enamel**. Surface microabrasion of zones of yellow or brown discoloration often results in a permanent improvement of the enamel coloration. Elimination of the white lusterless enamel usually requires labial veneers or full crowns.

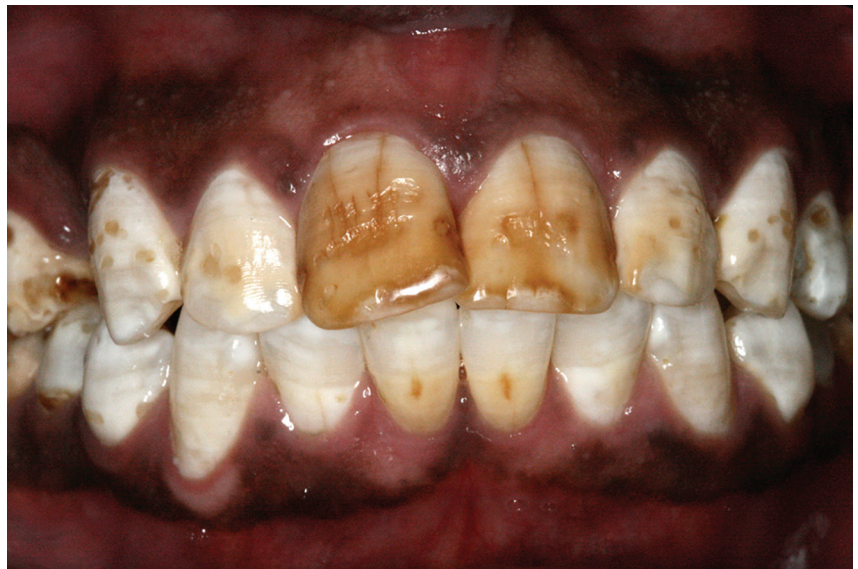■ **Figure 2.4**
Dental Disturbances due to Antineoplastic Therapy

Dentition demonstrating short pointed roots, hypodontia, microdontia, and areas of enamel hypoplasia in a patient who received radiation for a hematologic malignancy. (Courtesy Dr. Matthew D'Addario.)



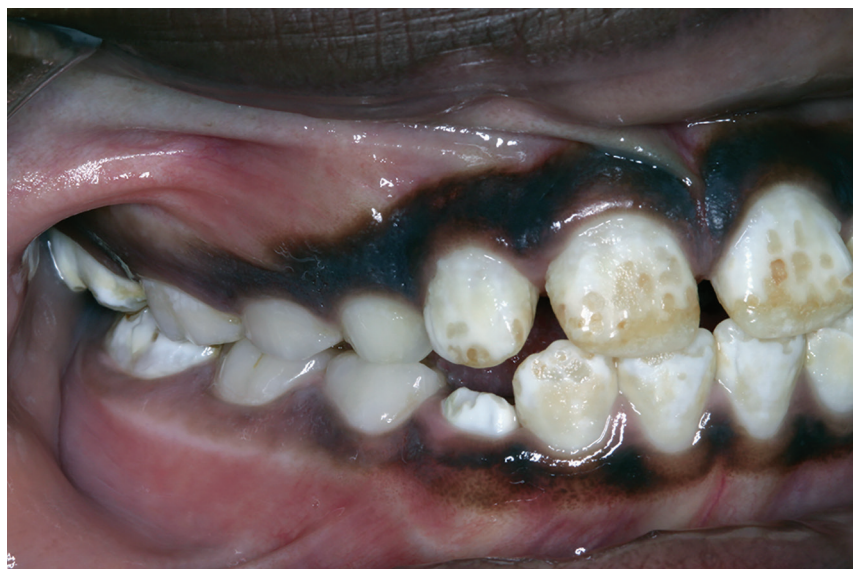■ **Figure 2.5**
Dental Fluorosis

Dentition demonstrating diffuse white hypomaturation with areas of brown staining and mottling.



■ **Figure 2.6**
Dental Fluorosis

Patient in mixed dentition demonstrating white hypomaturation of the permanent teeth and clinically normal deciduous teeth.



Tooth Wear

Tooth wear is a normal physiologic process that occurs with aging. When the extent of lost tooth structure results in symptoms, functional problems, or aesthetic concerns, the changes must be considered pathologic. Tooth surface loss occurs from attrition, abrasion, erosion, and possibly abfraction. Although these processes are discussed separately, the vast majority of pathologic tooth wear occurs from a combination of these influences.

Attrition

Fig. 2.7

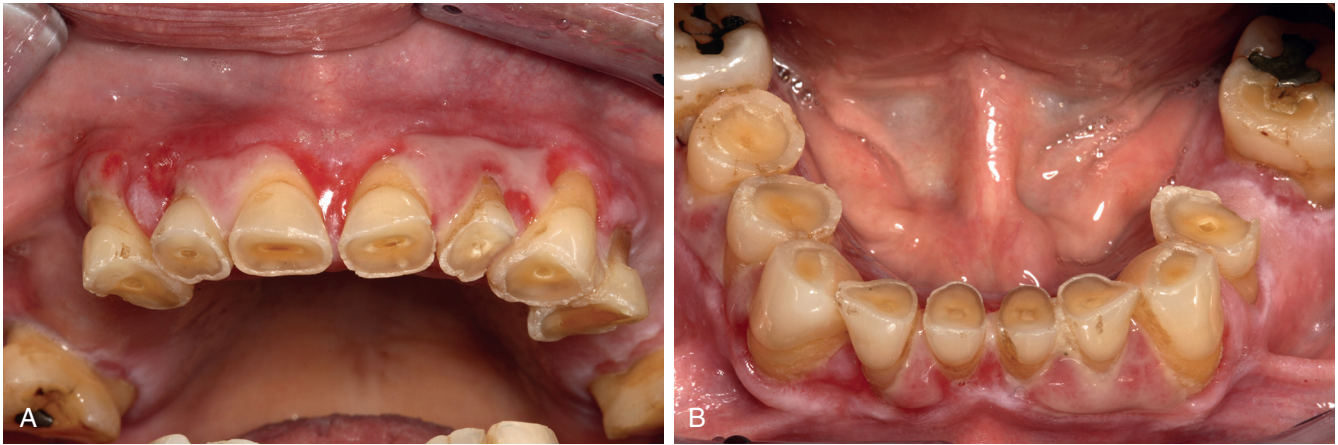
Attrition is tooth wear caused by tooth-to-tooth contact. Occlusal and incisal attrition presents as flattened wear facets on opposing teeth and arises from local forces of mastication often combined with abrasion related to the coarseness of the diet. Interproximal attrition also can be seen but is reduced in the modern population, most likely secondary to dietary changes since the agricultural revolution. Attrition affects both the deciduous and permanent dentitions, resulting in both a decreased height and length of both arches. The loss of tooth structure is slow and rarely results in dentin sensitivity or pulp exposure. Bruxism, premature contacts, and developmental abnormalities of tooth structure, such as amelogenesis imperfecta and dentinogenesis imperfecta, may accelerate the process.

Abrasion

Figs. 2.8 and 2.9

Abrasion is the pathologic loss of tooth structure secondary to an external mechanical action. The most common pattern occurs on the facial surfaces of the teeth at the cemento-enamel junction secondary to toothbrushing. This pattern of tooth wear increases with age, the degree of force applied, the frequency of brushing, and in association with an inappropriate toothbrushing technique (horizontal vs. vertical). Chewing abrasive materials such as smokeless tobacco can accelerate tooth wear, and inappropriate biting of items such as thread or fingernails also can be damaging. Habits such as chewing pencils, inappropriate use of floss or toothpicks, constant holding of pipe stems, opening bobby pins, or cracking nuts also can produce significant abrasion.

Toothbrush abrasion typically creates horizontal cervical notches that may be more advanced on prominent teeth. Damage associated with pipe smoking or chronic bobby pin use often creates V-shaped notches, whereas inappropriate use of floss or toothpicks results in loss of interdental tooth structure. Pulp exposure is not expected because of the slow progression of the process. Often, tertiary dentin can be seen filling the space previously occupied by the pulp.

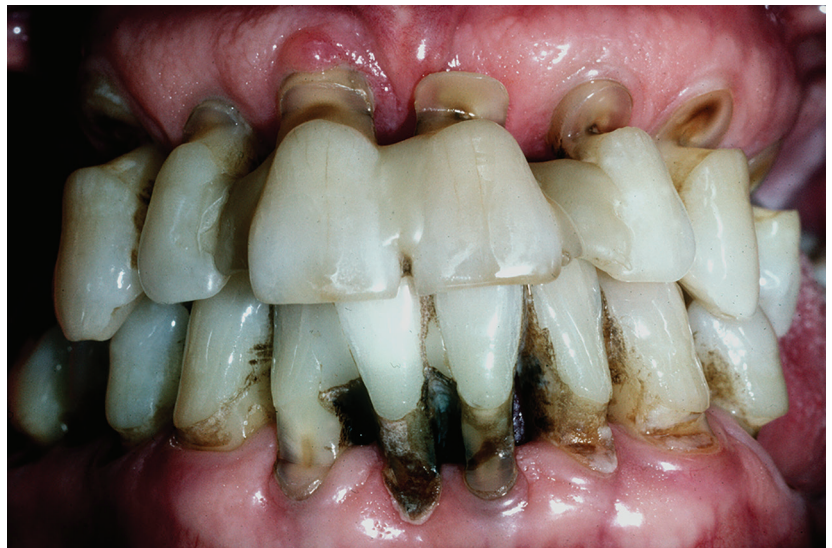

■ **Figure 2.7**
Dental Attrition

(A) Patient demonstrating extensive loss of maxillary tooth height secondary to tooth wear. Note the tertiary dentin filling the canal secondary to pulpal recession. (B) Mandibular arch in the same patient.

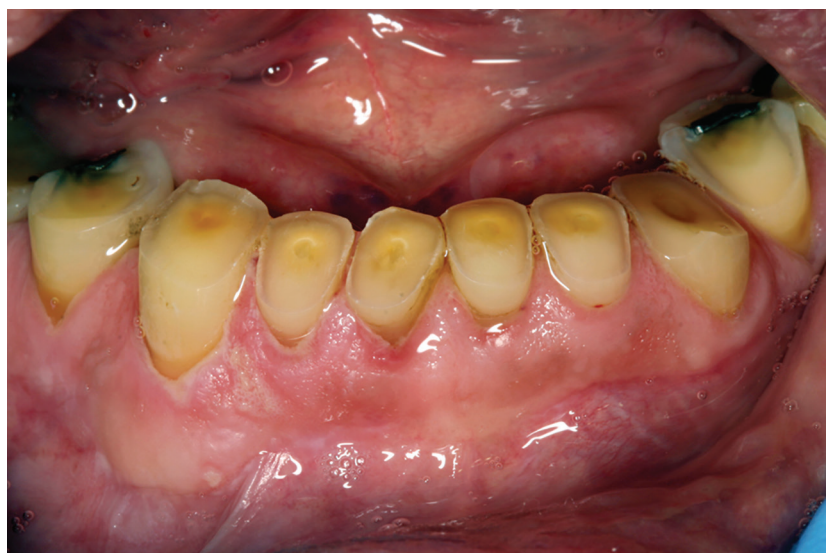■ **Figure 2.8**
Dental Abrasion

Patient demonstrating extensive cervical notching secondary to inappropriate and overzealous toothbrushing. The anterior teeth are splinted with resin because of coronal instability.



■ **Figure 2.9**
Dental Abrasion

Dentition demonstrating extensive loss of vertical tooth height due to a combination of attrition and abrasion in a patient who chronically chewed tobacco. Note tertiary dentin filling the pulp canals.



Figs. 2.10 and 2.11

Erosion is tooth wear caused by chemical action other than a bacterial process. Although saliva has significant buffering ability, this protection can be overwhelmed by poor salivary flow or excess acid. The source of the acid can be intrinsic secondary to prolonged or repeated exposure to stomach acid, or it can be extrinsic from exposure to food, drink, or environmental factors.

Because saliva has the ability to remineralize enamel following acid exposure, the loss of tooth structure also is thought to involve abrasion or attrition that removes enamel previously softened by an acid. Low salivary flow appears associated with an increased prevalence of erosion and may be secondary to medication-induced xerostomia, systemic diseases such as Sjögren syndrome, or dehydration from factors such as high levels of exercise or simply insufficient hydration. Consumption of carbonated soft drinks, natural fruit juices, and acidic snacks is associated with an increased prevalence of dental erosion, whereas drinking milk or eating yogurt appears to exert a protective effect.

Affected occlusal surfaces demonstrate cupping of cusp tips and flattening of the occlusal anatomy. In advanced cases the entire anatomy may be lost and replaced by a hollowed out occlusal surface. Erosion of smooth surfaces creates a flattened appearance that may evolve into concavities that usually are more wide than deep. Previously placed dental restorations may appear raised above the tooth surface because of loss of adjacent enamel and dentin, a presentation known as *perimolysis*. As seen in the other forms of tooth wear, pulpal exposure is not expected despite extensive loss of tooth structure.

Abfraction

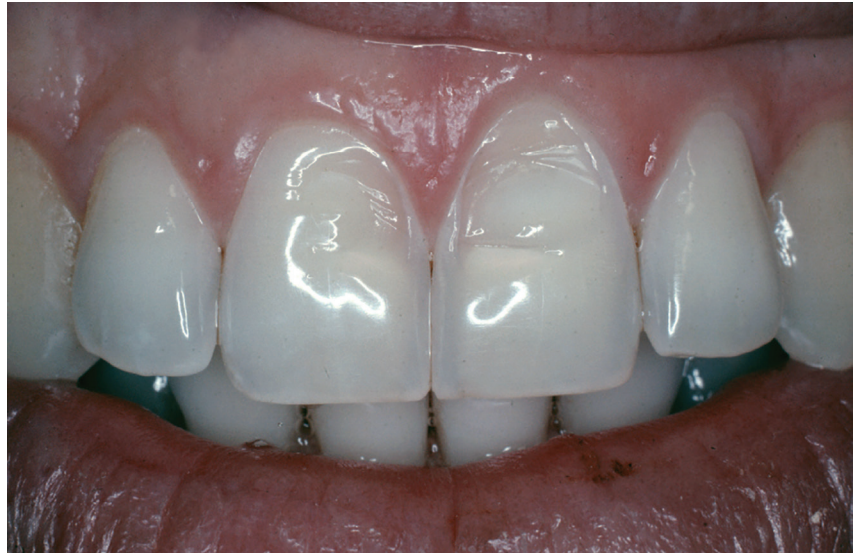Fig. 2.12

Abfraction is a theory that suggests tooth damage may develop secondary to occlusal stresses and repeated tooth flexure, creating disruption of the enamel in the cervical region. Once damaged, these areas would be more susceptible to the effects of abrasion and erosion, resulting in wedge-shaped, noncarious cervical lesions. The existence of this condition is controversial. Some investigators have reported no convincing clinical evidence for this theory, with some clinical findings seemingly in conflict with the basic hypothesis.

Damage created by abfraction is confined to the facial surfaces in the cervical region. Although the cervical damage resembles that secondary to abrasion and erosion, the defects often are deeper and more narrow with sharper side walls. The process may affect a single tooth with adjacent teeth being unaffected, or it may be noted in a subgingival location, both of which would be unusual in teeth affected by abrasion or erosion.

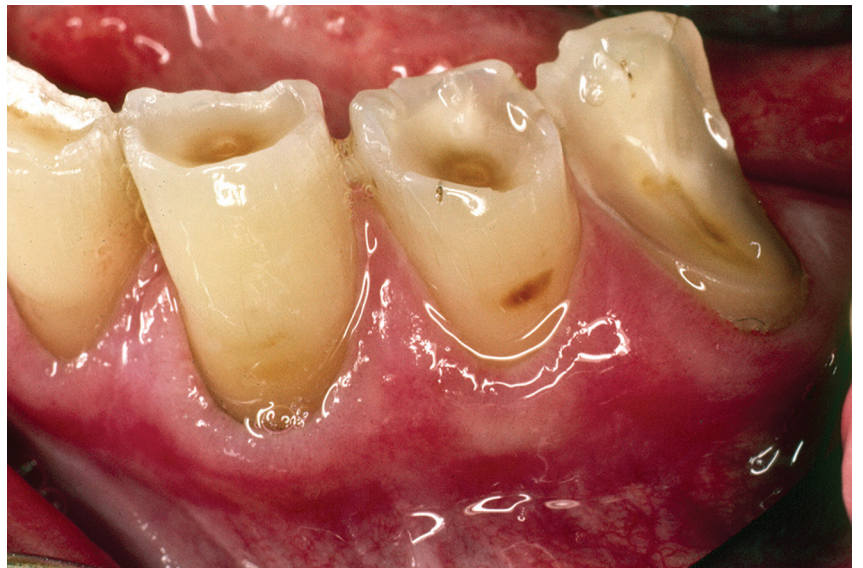■ **Figure 2.10**
Dental Erosion

Maxillary central incisors demonstrating localized enamel defects secondary to chronic lemon sucking.



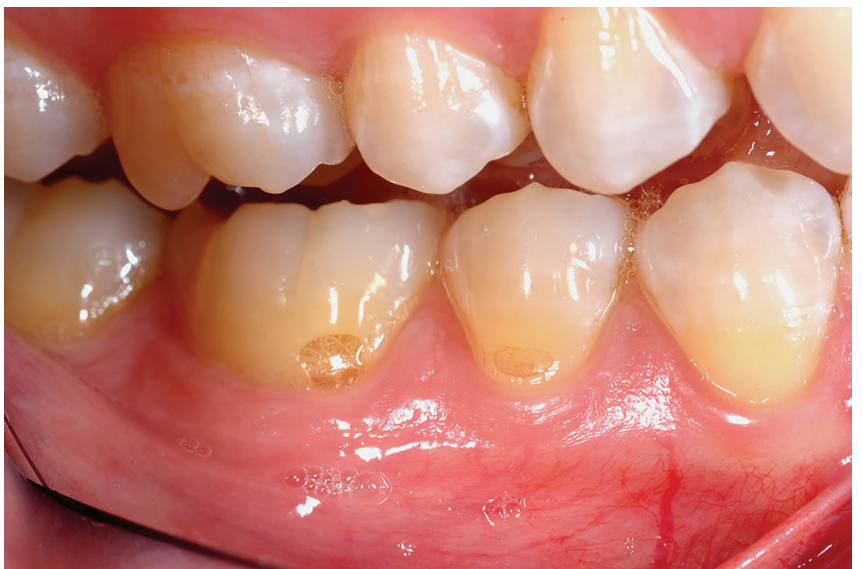■ **Figure 2.11**
Dental Erosion

Dentition demonstrating diffuse loss of coronal enamel and dentin. Note elevated rims of enamel surround central dentin concavities. This destruction resulted in complete loss of the buccal cusp in the depicted premolar tooth.



■ **Figure 2.12**
Dental Abfraction

Mandibular premolar and molar demonstrating isolated area of cervical enamel loss.



Internal Resorption

Fig. 2.13

Internal resorption refers to loss of tooth structure on the dentinal walls of the pulp. This process is relatively uncommon and occurs when the predentin and odontoblastic layers are lost, with exposure of the mineralized dentin to dentinoclastic cells within the pulp. The resorption most commonly arises secondary to an inflammatory reaction triggered by trauma or bacterial invasion of the pulp. Once initiated, the process often continues until the pulp tissue is removed endodontically or becomes necrotic.

Radiographically, the area of resorption typically presents as a symmetric, oval to round radiolucent enlargement of the pulp canal. If diagnosed prior to perforation of the root, endodontic therapy usually is successful in eliminating the soft tissue responsible for the resorption. In some cases, periapical radiographs are insufficient to delineate the full extent of the process, with computed tomography proven to be superior in accurately outlining the area of destruction.

External Resorption

Figs. 2.14 and 2.15

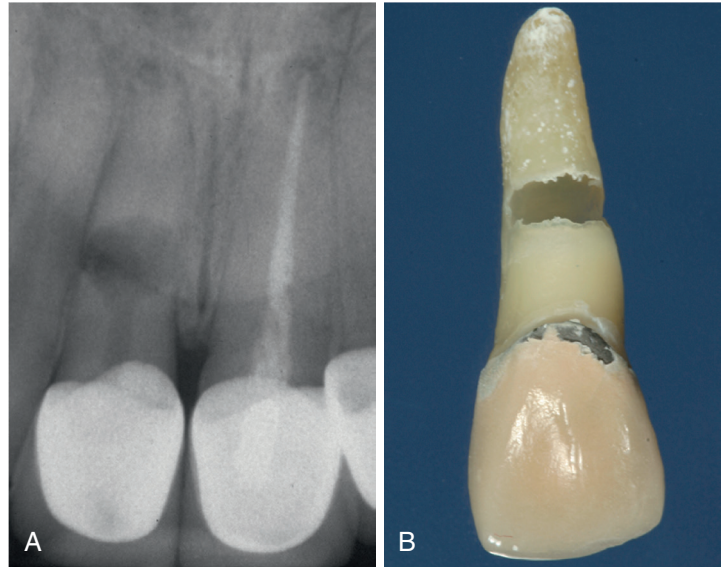
External resorption refers to a loss of tooth structure along the external surface of the root, secondary to destruction of the precementum and exposure of the adjacent mineralized cementum to cementoclasts within the periodontal ligament. In contrast to internal resorption, this process is very common, although it often is insignificant clinically. Localized pressure is a common cause, which may arise from orthodontic therapy, excessive occlusal forces, or adjacent impacted teeth, cysts, or tumors. Periodontal and periapical inflammatory disease also frequently are associated with external resorption. Avulsed teeth replaced after degeneration of the periodontal ligament may demonstrate progressive external resorption and subsequent ankylosis.

When compared with internal resorption, the area of tooth loss often creates a more irregular radiolucency. When resorptive defect is superimposed over the pulp, the original outline of the canal remains visible without the radiolucent pulpal expansion noted in internal resorption.

Although the resorption often stops after removal of an obvious trigger, many examples do not demonstrate an obvious cause, making successful intervention difficult. Resorption secondary to periodontitis or periapical inflammatory disease often ceases with elimination of any associated infection. Removal of the granulation tissue and restoration of the defect in areas of surgically accessible resorption have been successful in arresting the process.

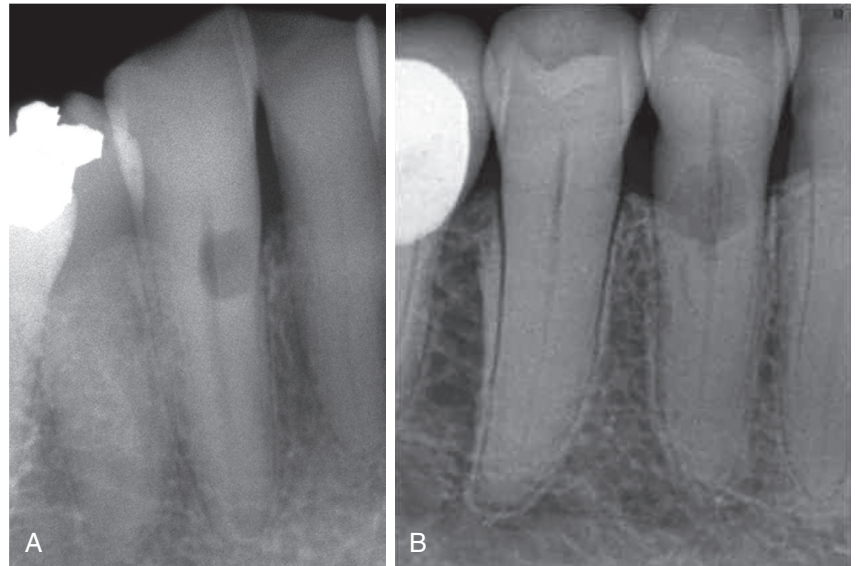
■ **Figure 2.13**
Internal Resorption

(A) Tooth demonstrating oval radiolucent expansion of the pulp canal. (B) Gross photograph of the same tooth exhibiting a radicular defect that perforated the lateral aspect of the root.



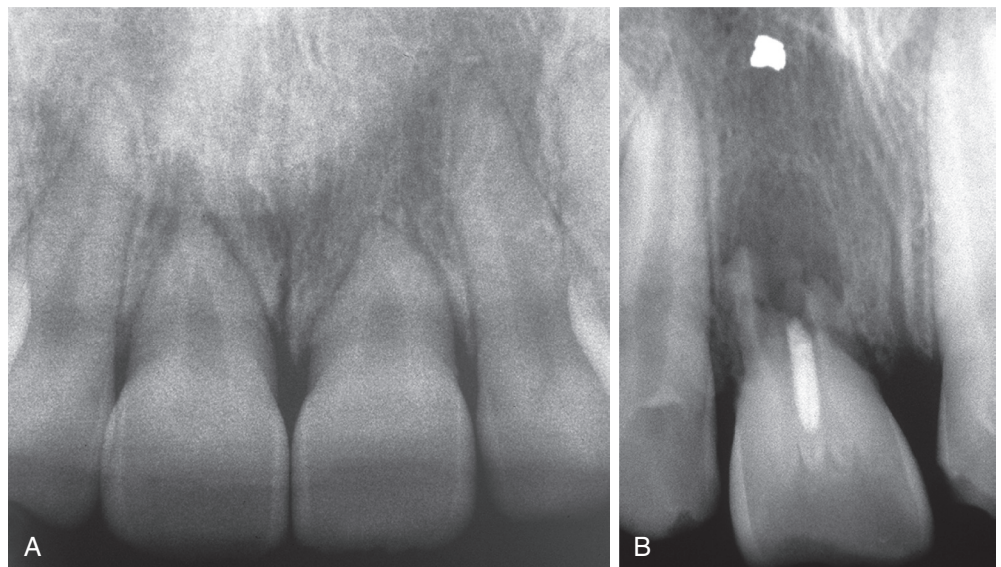
■ **Figure 2.14**
External Resorption

(A) Mandibular cuspid demonstrating radiolucency of the root. Note the original outline of the pulp canal is retained. (B) Mandibular first premolar exhibiting oval radiolucency superimposed over the pulp canal (Courtesy Dr. Todd Barrett.)



■ **Figure 2.15**
External Resorption

(A) Anterior maxillary dentition demonstrating blunt, short roots. These alterations arose following orthodontic therapy. (B) Maxillary central incisor exhibiting extensive loss of root structure. This tooth was avulsed during a traumatic event, treated endodontically, and reimplanted.



Discolorations of Teeth

The normal color of deciduous teeth is bluish white, whereas permanent teeth appear grayish white. Upon aging, the enamel often thins and the teeth become more yellow. More stark discolorations also can occur and may be extrinsic or intrinsic in origin.

Extrinsic Tooth Staining

Fig. 2.16

Extrinsic discolorations of teeth arise from deposition of a surface stain that typically can be removed by professional cleaning with prophy paste. Common causes include stains from bacteria, tobacco products, foods, beverages (especially coffee and tea), systemic medications, and certain mouthwashes or toothpastes.

Plaque containing chromogenic bacteria may create green to orange areas of discoloration. Black to brown areas also may be seen secondary to formation of ferric sulfide when bacterial hydrogen sulfide combines with iron in the crevicular fluid. Stains from tobacco and beverages tend to demonstrate discoloration most frequently on the lingual and palatal surfaces. Stannous fluoride is used in many current toothpastes, and the stannous ion (tin) may combine with bacterial sulfides to create a black stain. Chronic use of chlorhexidine mouth rinse can result in a yellow-brown discoloration that is seen with an increased frequency in patients who also frequently consume tannin-containing beverages, such as tea and wine.

Intrinsic Tooth Staining

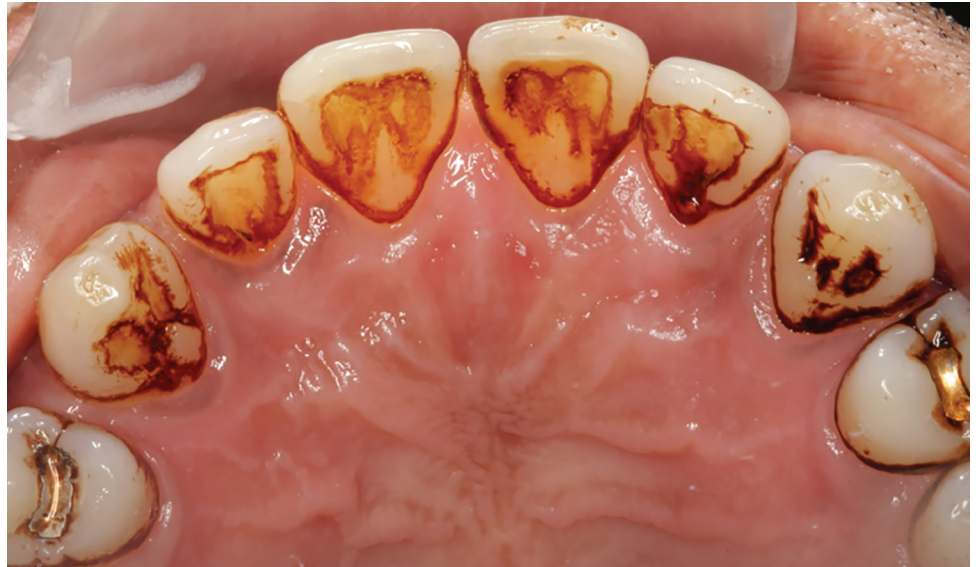Figs. 2.17 and 2.18

Intrinsic tooth discolorations may arise from developmental tooth abnormalities or an endogenous material that is incorporated into tooth structure during development. Because these do not represent surface stains, removal is not possible. Developmental discolorations include variants of amelogenesis imperfecta, dentinogenesis imperfecta, and dental fluorosis.

The development of deciduous tooth crowns extends from the 4th month of gestation to approximately the 12th month of life, whereas the crowns of the permanent teeth begin formation around birth with completion at approximately 8 years of age. During this time, stains can be permanently incorporated into the developing teeth from a variety of conditions (such as erythropoietic porphyria, alkaptonuria, hyperbilirubinemia) and medications (especially tetracycline and minocycline). In the majority of these situations, the discoloration affects only the portion of the tooth developing at the time the condition or medication was present. One exception is minocycline. This agent has the ability to stain dental pulp, which can result in a diffuse discoloration of teeth long after formation has been completed.

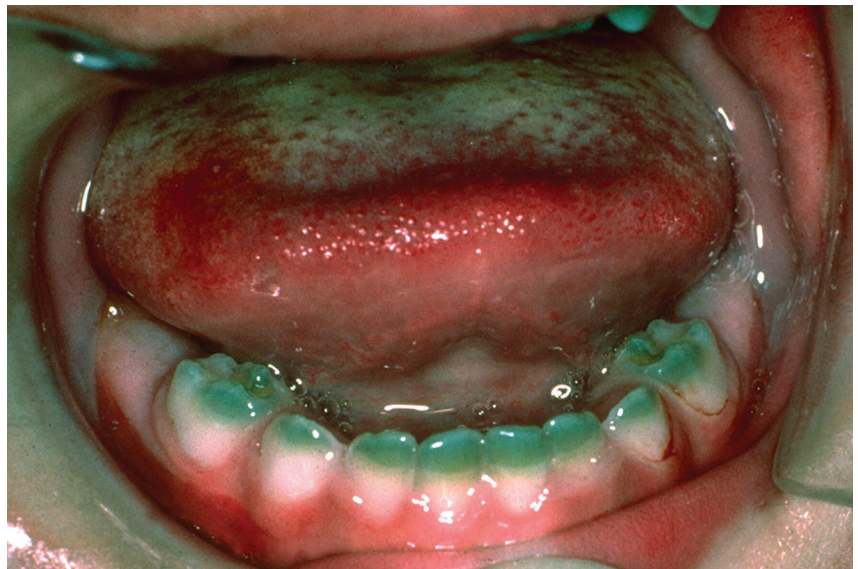■ **Figure 2.16**
Extrinsic Tooth Staining

Patient from Palau who chronically used betel quid and developed diffuse red-dish-brown discoloration of the palatal surfaces of the teeth (Courtesy Dr. Lynn Wallace.)



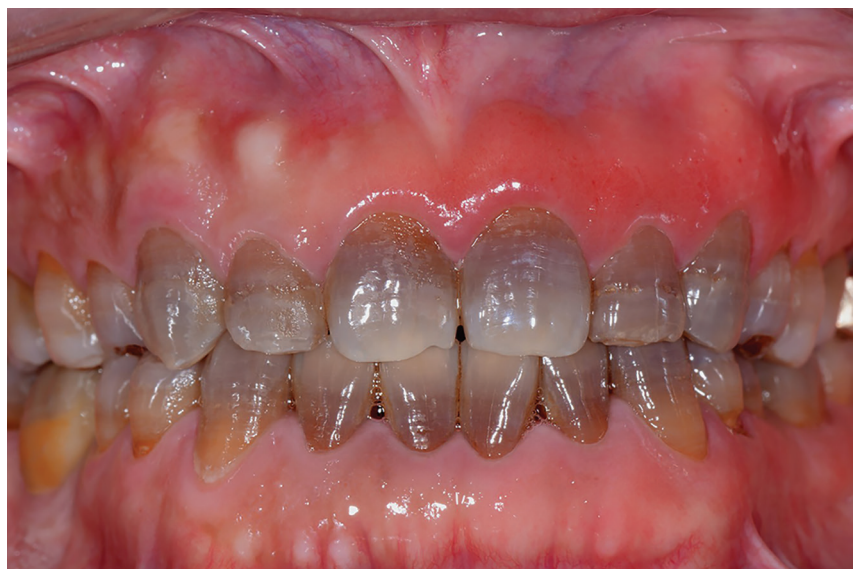■ **Figure 2.17**
Intrinsic Tooth Staining

Greenish discoloration of the incisal third of the deciduous dentition in a patient who had liver disease and hyperbilirubinemia as an infant. (Courtesy Dr. Ronnie Carr.)



■ **Figure 2.18**
Intrinsic Tooth Staining

Diffuse grayish dentition in a patient who used systemic tetracycline as a child.



Ankylosis

Fig. 2.19

Emergence of teeth is a continuous process that compensates for tooth wear and does not cease after full eruption. **Ankylosis** refers to cessation of emergence that occurs secondary to fusion of the tooth with the alveolar bone. Many believe the periodontal ligament represents an anatomic barrier that separates the tooth from adjacent bone and helps prevent ankylosis. Although the cause of ankylosis is unknown, trauma or a genetically decreased periodontal ligament space may predispose to fusion between teeth and the alveolar ridge.

Although permanent teeth may be affected, the deciduous molars are associated most commonly with clinically significant ankylosis. In most cases the fusion is detected by infraocclusion of the affected tooth in which its occlusal plane is below that of adjacent teeth. Occasionally, percussion will demonstrate a sharp solid or metallic sound. Although the fusion often does not create obvious radiographic alterations, occasionally loss of the typical periodontal ligament space is noted.

In the vast majority of cases, ankylosis of deciduous molars resolves spontaneously as the underlying permanent bicuspid erupts. In cases with significantly delayed eruption, extraction of the ankylosed deciduous molar is indicated. In teeth without an underlying successor, a prosthetic buildup can be placed to equalize the occlusal height with adjacent teeth. Luxation also has been used in an attempt to break the osseous fusion and encourage redevelopment of an intact periodontal ligament.

Transposition

Fig. 2.20

Dental transposition is a type of ectopic eruption in which two adjacent teeth interchange positions. The vast majority are unilateral and involve the maxillary cuspid. The most common pattern involves the cuspid and first premolar, with the cuspid and lateral incisor being the second most frequent interchange. Although an association with dental trauma during childhood has been suggested in some cases, significant evidence suggests involvement of genetic factors.

If caught during the early stages of eruption, surgical and orthodontic procedures can be performed to guide the teeth into their appropriate positions. If the transposition is well established, alignment of the teeth with subsequent restorative treatment to camouflage the altered positions is appropriate. Another option is removal of one or both affected teeth, with implant placement.

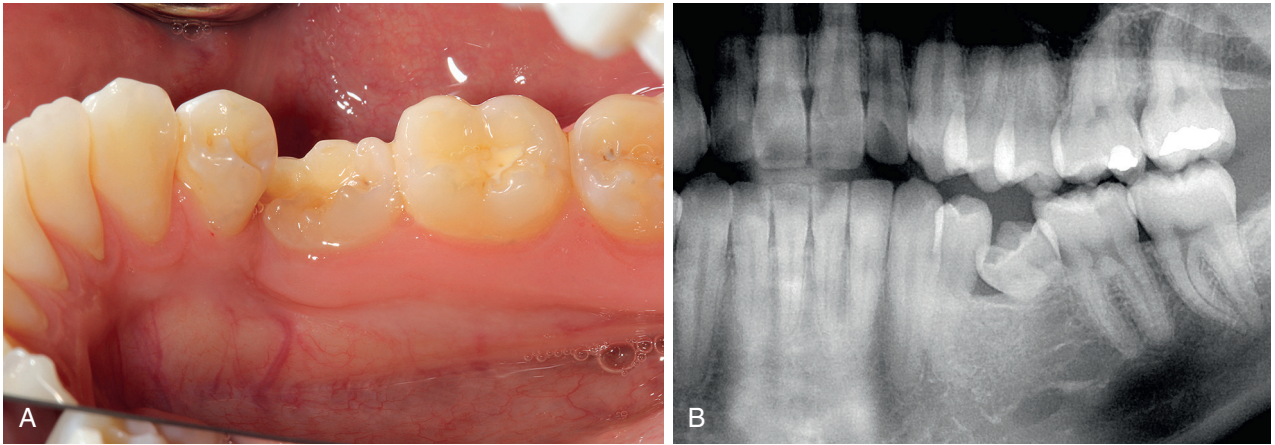
Hypodontia

Fig. 2.21

Hypodontia refers to one or more missing teeth, whereas the term **oligodontia** is used when more than six teeth are missing. A total absence of teeth is known as **anodontia** and is seen primarily in association with ectodermal dysplasia. The dental lamina is extremely sensitive to external influences, and damage prior to tooth formation possibly can result in hypodontia. Local trauma, infection, radiation therapy, chemotherapy, medications, endocrine abnormalities, and severe intrauterine disturbances have been associated with missing teeth.

With more than 200 genes known to be involved in odontogenesis, genetics exert a strong influence on tooth numbers. Hypodontia may be an isolated finding, or it may be a component of various genetic syndromes that are inherited as autosomal dominant, autosomal recessive, or X-linked traits. At least 111 syndromes are known to be associated with hypodontia, with another 80 associated with oligodontia. Mutations in five genes (*AXIN2*, *MSX1*, *PAX9*, *EDA*, *WNT10A*) have been confirmed to be associated with isolated hypodontia, and another 79 gene mutations have been found in association with a wide variety of syndromes that may include hypodontia as a feature. Of significant interest is *AXIN2* because of its association with both hypodontia and carcinoma of the colon. Other investigators also have suggested an association between hypodontia and other forms of human cancer, but these correlations are less strong. It must be stressed that in the majority of the cases of hypodontia, the involved genes have yet to be discovered.

Hypodontia is uncommon in the deciduous dentition. The most commonly missing teeth are the third molars, mandibular second molars, maxillary permanent lateral incisors, and maxillary second premolars. In contrast, the least commonly missing permanent teeth are the maxillary central incisors, the maxillary and mandibular first molars, and the mandibular canines. Hypodontia demonstrates a female predominance, with affected individuals demonstrating teeth that generally are smaller than normal and often have a more simplified shape.



■ Figure 2.19

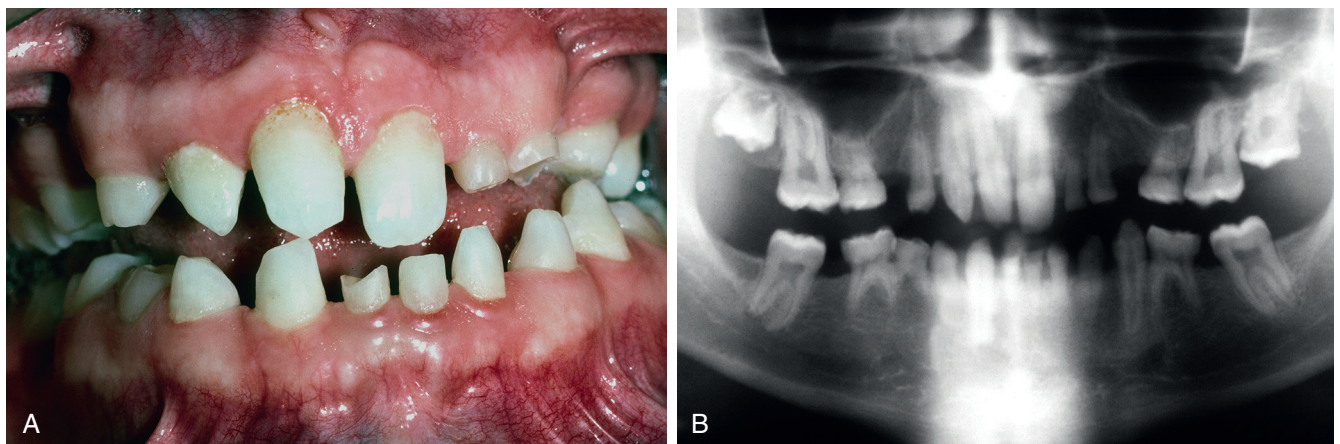
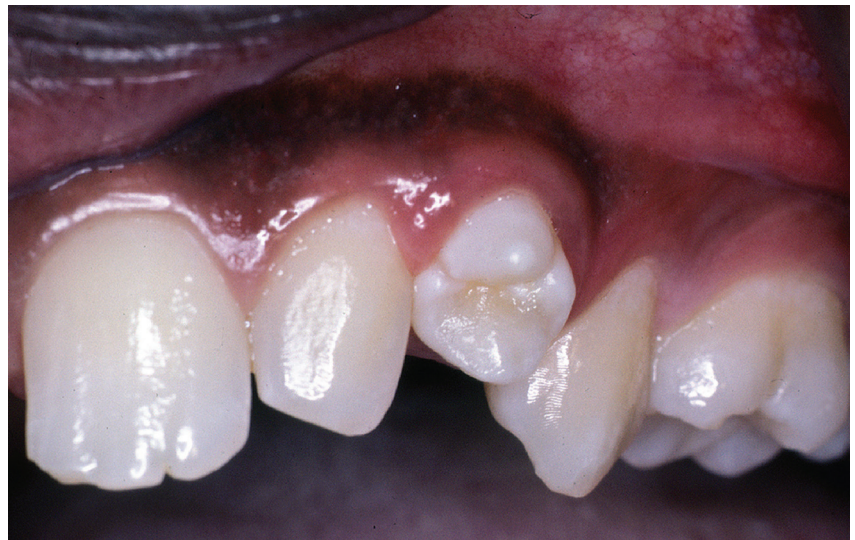Ankylosis

(A) Mandibular second deciduous molar with occlusal plane below the adjacent teeth. (B) Radiograph of the same patient reveals significant radicular resorption and no underlying second premolar. (With appreciation to Dr. Jordan Brown.)

■ Figure 2.20

Dental Transposition

Rotated maxillary first premolar demonstrating eruption between the lateral and cuspid.



■ Figure 2.21

Oligodontia

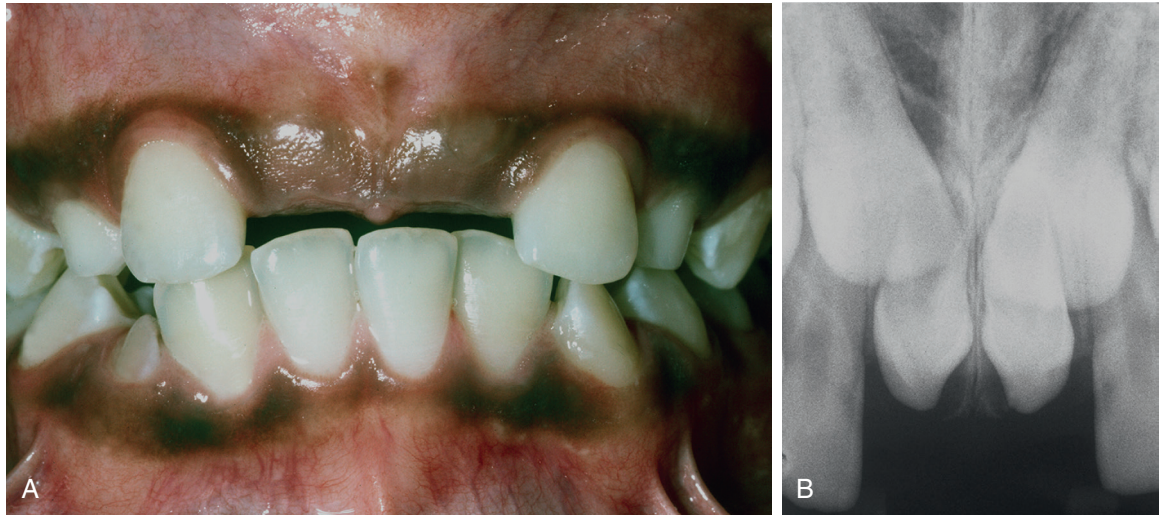(A) Patient demonstrating numerous missing teeth and retained deciduous teeth. (B) Panoramic radiograph of the same patient.

Figs. 2.22–2.24

Hyperdontia refers to an excess number of teeth beyond the expected 20 deciduous and 32 permanent teeth. The additional teeth are termed **supernumerary** and demonstrate a male and maxillary predominance. Supernumerary teeth are five times more common in the permanent dentition than in the deciduous dentition. Affected patients often demonstrate teeth that are larger in size with a more complex anatomy.

The additional teeth may be single or multiple; unilateral or bilateral; and in one or both jaws. The most common supernumerary tooth arises in the midline of the anterior maxilla and is known as a **mesiodens**. Following the mesiodens in order of decreasing frequency are maxillary fourth molars, maxillary lateral incisors, mandibular fourth molars, and mandibular premolars. In contrast to single-tooth hyperdontia, the most common site for multiple supernumerary teeth is the mandibular premolar region. A supernumerary tooth lingual or buccal to a molar is termed a **paramolar**, whereas one located distal to a third molar is known as a **distodens** or **distomolar**. Although the vast majority of supernumerary teeth are nonsyndromic, at least 20 syndromes demonstrate an association with hyperdontia, with cleidocranial dysplasia and Gardner syndrome being the most frequently mentioned.

Many supernumerary teeth are asymptomatic and discovered incidentally during imaging obtained for other indications. However, complications are not rare and include delayed or ectopic eruption of adjacent teeth, root resorption of adjacent teeth, crowding, malocclusion, objectionable diastema, and development of a significant pericoronal cyst or tumor. Although disagreement exists related to early or late removal of problematic supernumerary teeth, investigators have suggested the optimal time for removal of a mesiodens is approximately 6 to 7 years of age, after which the prevalence of complications appears to increase. Prior to surgical removal, cone beam computed tomography has been shown to be beneficial in precisely defining the location of the tooth and its proximity to vital anatomic structures such as the nasal floor and nasopalatine canal.

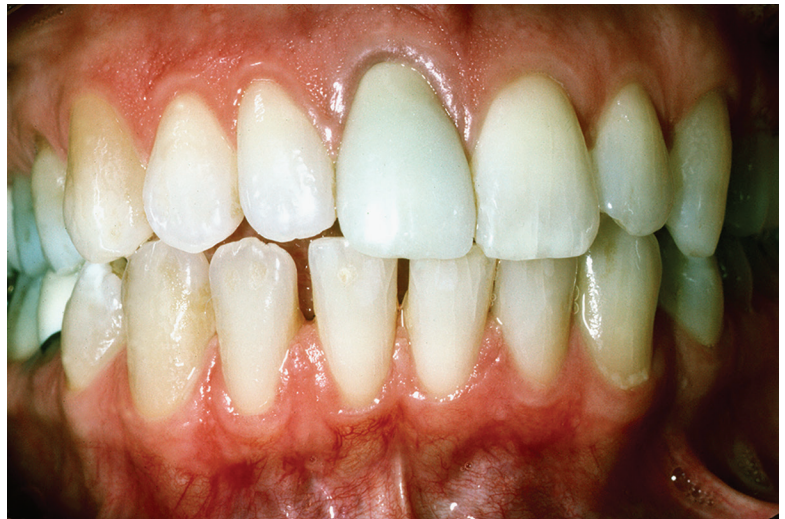

■ **Figure 2.22**
Hyperdontia (Mesiodens)

(A) Patient presenting with failure of eruption of the maxillary central incisors. (B) Radiograph of the same patient demonstrating bilateral supernumerary teeth superimposed on the central incisors.

■ **Figure 2.23**
Hyperdontia

Patient demonstrating two lateral incisors of the right maxillary quadrant.



■ **Figure 2.24**
Hyperdontia

Patient exhibiting multiple bilateral supernumerary mandibular premolars.

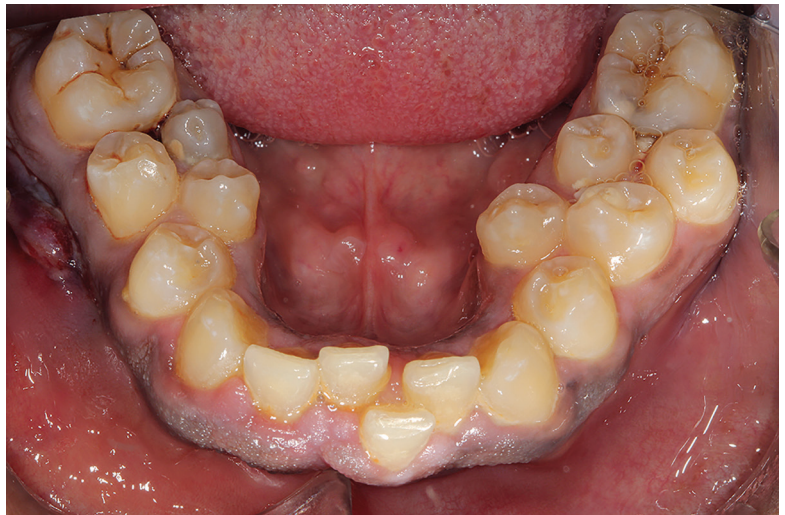

Fig. 2.25

Eruption of the deciduous dentition begins at approximately 6 months of age. Teeth evident at birth are known as **natal teeth**, whereas those erupting within the first 30 days of life have been termed **neonatal teeth**. The vast majority represent prematurely erupted deciduous teeth rather than supernumerary teeth, with the anterior mandibular incisors being affected most frequently.

During breast-feeding, natal mandibular incisors have been associated with traumatic ulcerations of the ventral tongue termed **Riga-Fede disease**. Management includes smoothing of the sharp incisal edges, covering the incisal edges with composite resin, or use of a protective mouthguard during feeding. Extraction of the tooth is recommended only if it is radiographically proven to be a supernumerary tooth or if extreme mobility is noted. Although aspiration of a mobile tooth is a concern, this complication has never been reported even though natal teeth are not rare. If possible, surgical removal should be delayed because early tooth mobility frequently resolves within a month, thereby eliminating the need for extraction. In addition, delaying extraction negates the need for administration of vitamin K to reduce surgery-related bleeding. Although occasionally performed by medical staff without significant oral health training, this procedure is performed best by a dental professional who should ensure that all radicular remnants are curetted thoroughly at the time of crown removal.

Microdontia and Macrodontia

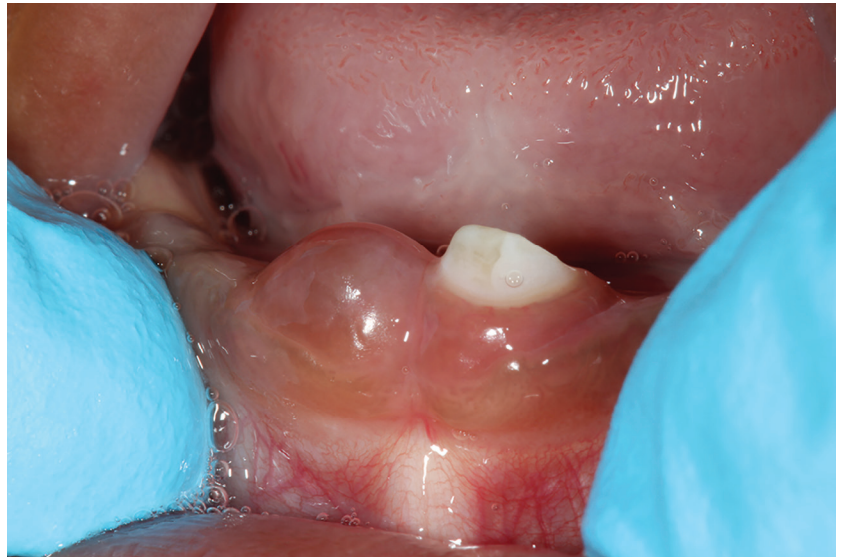Figs. 2.26 and 2.27

Microdontia refers to teeth that are smaller than normal, whereas **macrodontia (megadontia)** relates to teeth that are larger than normal. There is a direct correlation between microdontia and hypodontia, along with a similar association between macrodontia and hyperdontia. Missing teeth demonstrate a strong female predominance, with affected individuals exhibiting teeth that are incrementally smaller than normal and often with a more simplified shape. In contrast, supernumerary teeth exhibit a male predominance, with teeth that are larger than normal and often exhibit a more complex anatomy. In spite of these associations, the decreased/increased tooth size is subtle.

Generalized marked microdontia or macrodontia is rare and usually is noted in association with pituitary dysfunction. In contrast, isolated microdontia is not uncommon and most often involves the maxillary lateral incisors (so-called peg laterals) or third molars. Localized macrodontia is less common and can be difficult to separate from gemination or fusion. Hereditary and environmental influences appear active in hypodontia/microdontia and hyperdontia/macrodontia. In studies of monozygotic twins, strong concordance of hypodontia/microdontia is not present. In spite of this, if one twin demonstrates hypodontia/microdontia, the co-twin is at a significantly increased risk of showing this same trait (13-fold in one study).

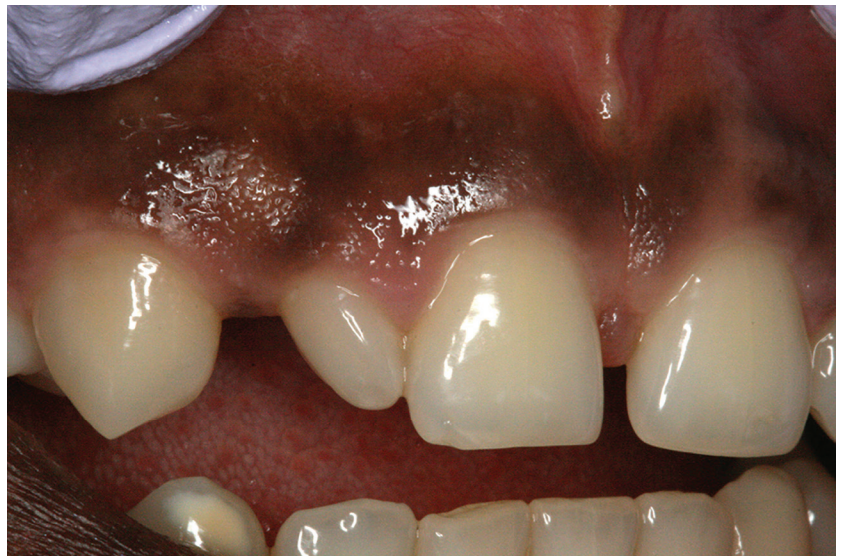■ **Figure 2.25**
Natal Tooth

Newborn demonstrating prematurely erupted mandibular left central incisor adjacent to eruption cyst associated with the right central incisor. (With appreciation to Dr. Matthew Tillman.)



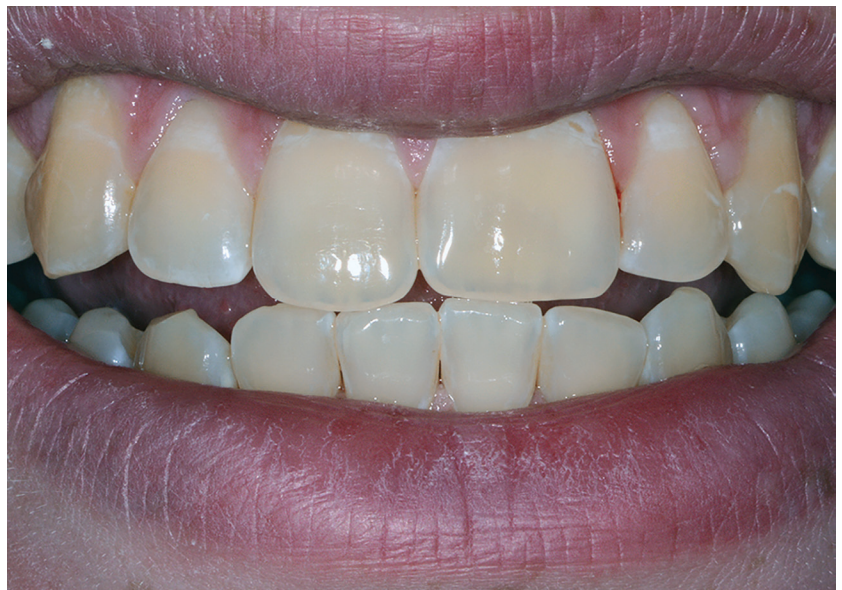■ **Figure 2.26**
Microdontia

Patient demonstrating small peg-shaped right maxillary lateral incisor.



■ **Figure 2.27**
Macrodontia

Patient demonstrating enlarged left maxillary central incisor. (Courtesy Dr. Peter Fam.)



Figs. 2.28–2.31

Double teeth are two teeth joined together or one enlarged tooth that shows an incomplete attempt to divide into two teeth. **Gemination** occurs when a single tooth bud attempts to divide, resulting in a bifid, grooved, or enlarged crown. The process begins at the incisal edge but ceases prior to complete division of the tooth. The affected tooth typically is associated with a common root and pulp canal. **Fusion** occurs when two normally separated teeth are joined by dentin. Fused teeth may share a root and pulp canal or demonstrate separated roots. **Concrescence** is noted when two fully formed teeth are united by cementum without confluence of the dentin. This union may develop during or after initial completion of root formation.

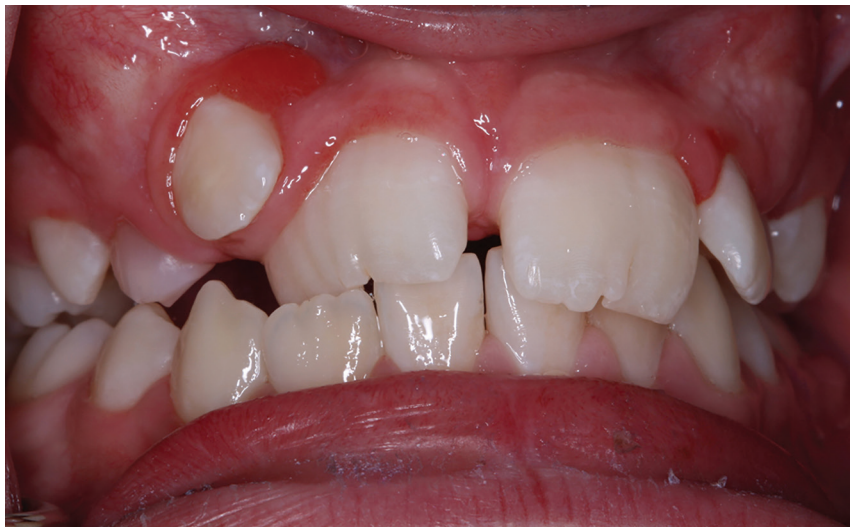Classically, gemination appears as a single enlarged or double tooth in which the tooth count is normal when the anomalous tooth is counted as one. In contrast, the tooth count in fusion reveals a missing tooth when the anomalous tooth is counted as one. Like most definitions, exceptions do occur. Fusion with a supernumerary tooth is suspected when a bifid crown is associated with two separated roots but the tooth count is normal when the anomalous tooth is counted as one.

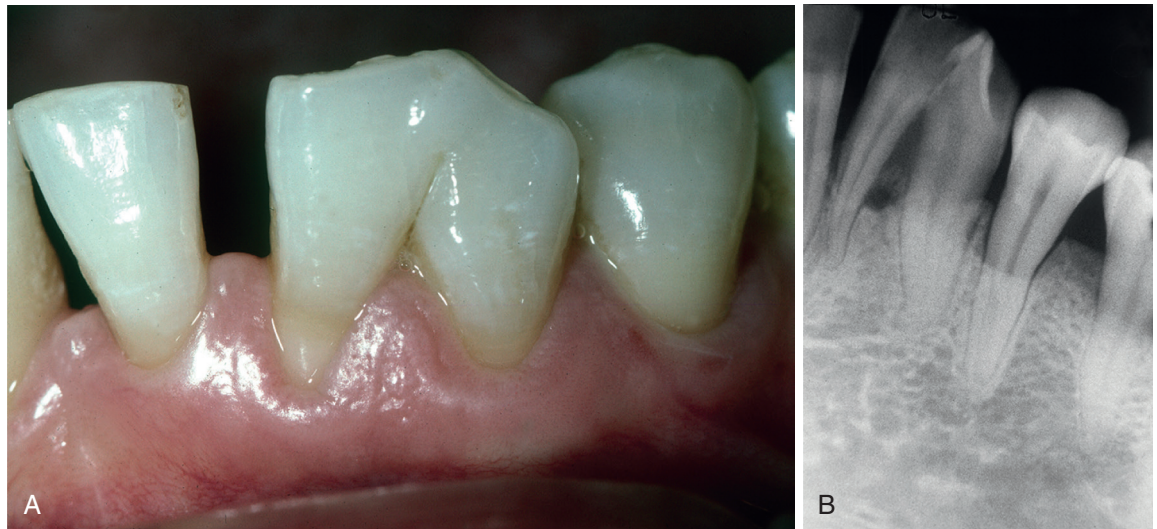
Gemination and fusion can involve either dentition, with the incisors and canines most commonly affected. When fusion is noted in the deciduous dentition, the majority of patients will demonstrate lack of formation of the associated succedaneous tooth. Gemination demonstrates a maxillary predominance, whereas fusion occurs more frequently in the mandible. Bilateral examples are uncommon. Concrescence is noted more frequently in the posterior maxilla because of the frequent approximation of the apices of the second and third molars.

Gemination and fusion can create aesthetic concerns, malocclusion, an enlarged diastema, and predisposition to caries and periodontal disease. The therapeutic options must be individualized to the patient's needs and include reshaping and restoration of the altered crown; hemisection into two separate teeth; or extraction with replacement by a partial denture, fixed bridge, or implant. Many cases of concrescence require no therapy, although some may be associated with delayed eruption or extraction difficulties.

■ Figure 2.28 Gemination

Bilaterally enlarged maxillary central incisors exhibiting a groove in the midline of each tooth. Unrelated spongiotic gingival hyperplasia also is noted in association with the partially erupted right maxillary lateral incisor.



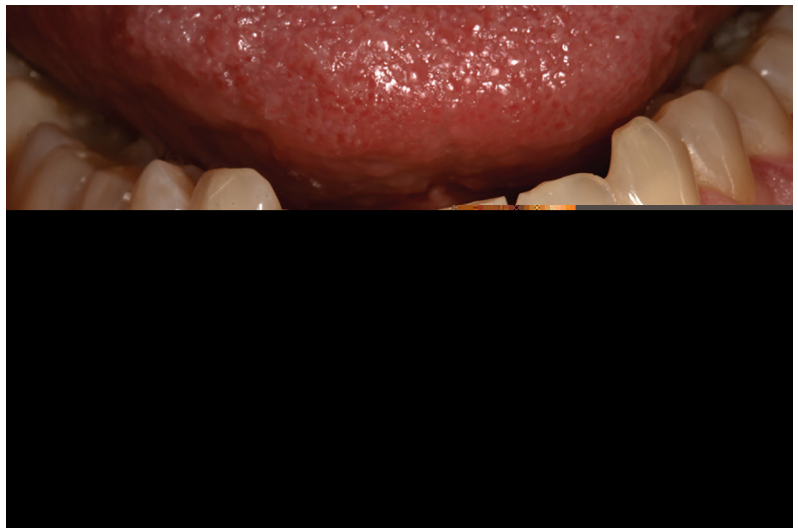


■ **Figure 2.29**
Fusion

(A) Facial view of mandibular right lateral incisor attached to the crown of the adjacent cuspid. (B) Radiograph of the same teeth.

■ **Figure 2.30**
Fusion

Enlarged mandibular right central incisor in a patient who also is missing the lateral incisor in that quadrant.



■ **Figure 2.31**
Concrescence

Maxillary second and third molar demonstrating radicular attachment. Upon histopathologic examination, the teeth shared cementum but not dentin.

Fig. 2.32

A **talon cusp** is an accessory cusp of an anterior tooth that is located most often on the palatal surface and extends at least half way from the cementoenamel junction to the incisal edge. There is a male predominance, with the vast majority occurring in the maxillary permanent teeth. The maxillary lateral is the most commonly affected permanent tooth, whereas the central incisor is the most frequently involved deciduous tooth. Facial talon cusps are uncommon. An increased prevalence has been seen in a number of syndromes including Rubinstein-Taybi, Ellis-van Creveld, Sturge-Weber, Mohr, incontinentia pigmenti achromians, and Berardinelli-Seip.

The cusp consists of enamel and dentin that may contain a central pulp horn. Developmental grooves that are prone to caries may be present where the cusp joins the palatal surface. In addition to caries along these grooves, the cusp also is associated with occlusal interferences, displacement of the affected tooth, irritation of the adjacent soft tissues, and an increased prevalence of periodontal and pulpal disease. Any evident developmental groove should be restored with a resin-modified glass ionomer. Cusps creating occlusal problems can be removed incrementally at 6- to 8-week intervals and coated with a fluoride varnish to allow for deposition of reparative dentin in an effort to maintain pulpal vitality.

Dens Evaginatus and Shovel-Shaped Incisors

Figs. 2.33 and 2.34

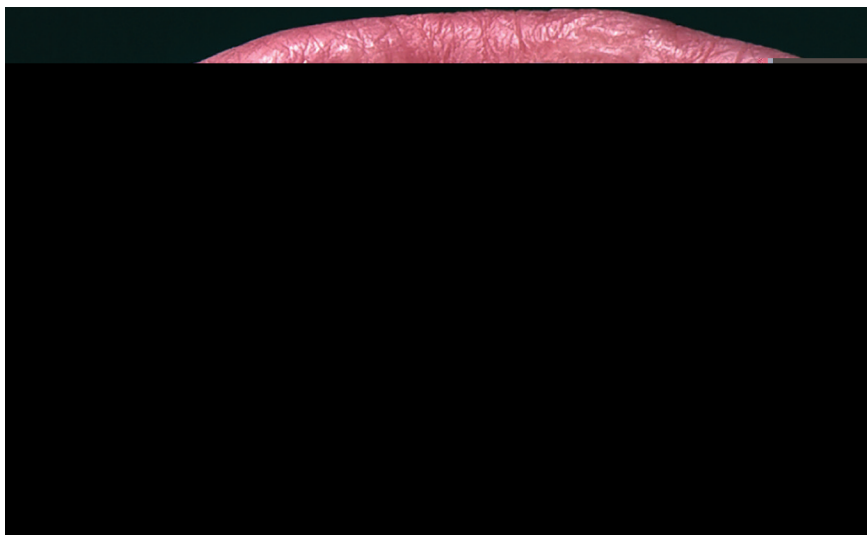
Dens evaginatus is an accessory cusp that originates from the central groove or lingual ridge of the buccal cusp of a premolar or molar tooth. The mandibular premolar is affected most frequently, and the condition usually is bilateral. The finding is rare in whites; it is discovered most often in Asians, the Inuit, and Native Americans. As would be expected, dens evaginatus has been associated with occlusal problems, cuspal fracture, and pulpal pathosis. Removal of the cusp while maintaining pulpal vitality is difficult but has been achieved by slow periodic grinding and removal of all opposing occlusal interferences. Another option is placement of resin reinforcement around the cusp until pulpal recession has occurred, thereby increasing the possibility of maintaining vitality during removal.

Dens evaginatus often is associated with **shovel-shaped incisors**. Once again, this variation in dental anatomy is unusual in whites but common in Asians, the Inuit, and Native Americans. Affected incisors demonstrate prominent lateral margins that create a hollowed lingual surface similar to the scoop of a shovel. Not uncommonly, the marginal ridges converge on a deep cingulum pit that is prone to caries and should be restored to prevent loss of vitality.

■ **Figure 2.32**

Talon Cusp

Right maxillary lateral incisor demonstrating a



Dens Invaginatus

Figs. 2.35 and 2.36

Dens invaginatus is a tooth with a surface invagination lined by enamel. According to the classic description of coronal dens invaginatus by Oehlers, the invagination may be confined to the crown (type I), extend past the cementoenamel junction (type II), or parallel the pulp and exit along the lateral or apical aspect of the root (type III). Type III can be confusing because of the potential for interradicular abscess formation in association with a vital tooth. In addition, an extremely rare radicular variant has been documented in which the enamel invagination arises from the cementum surface and extends into the underlying radicular dentin. Dens invaginatus exhibits a strong maxillary predominance, with the lateral incisor most commonly affected. Bilateral involvement is common. Involvement of mandibular teeth, premolars, and molars occurs infrequently.

Ideally, the invagination should be restored to prevent loss of pulpal vitality. Frequently, however, periapical inflammatory disease secondary to pulpal necrosis leads to discovery of the anomaly. Cone beam computed tomography is superior to periapical and panoramic radiographs for identifying the invaginations and demonstrating the complex pulpal anatomy of the distorted tooth. Although conventional endodontic therapy is successful in the majority of cases, some teeth are extremely distorted and may require extraction.

Enamel Pearls

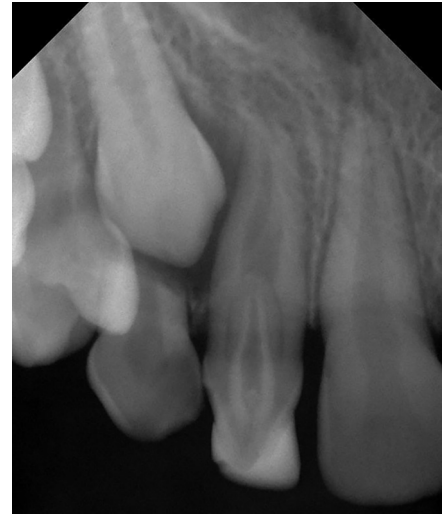Fig. 2.37

Enamel pearls (enamelomas) are ectopic exophytic globules of enamel located on the root surface. Most commonly, the lesion is composed of a ball of enamel with a dentin core, but it may consist entirely of enamel or also contain dental pulp. The majority are discovered on the mesial or distal surfaces of molars, with a predilection for the furcation or the groove between incompletely separated roots. There may be multiple affected teeth or multiple pearls on a single tooth, and the finding demonstrates a strong maxillary predominance. Involvement of premolars, canines, and incisors is uncommon. Rare examples may be encased in the radicular dentin or found separate from the teeth within the alveolar bone.

The enamel pearl prevents connective tissue attachment of the root with the adjacent periodontium, provides a niche for bacterial colonization, and complicates cleansing of the site once exposed to the oral cavity. An association with progressive localized periodontitis can occur, necessitating extraction in many cases. Surgical therapy with removal of the enamel pearl, scaling, root planning, and osteoplasty have been successful in resolving the localized periodontitis and preventing loss of the affected tooth.

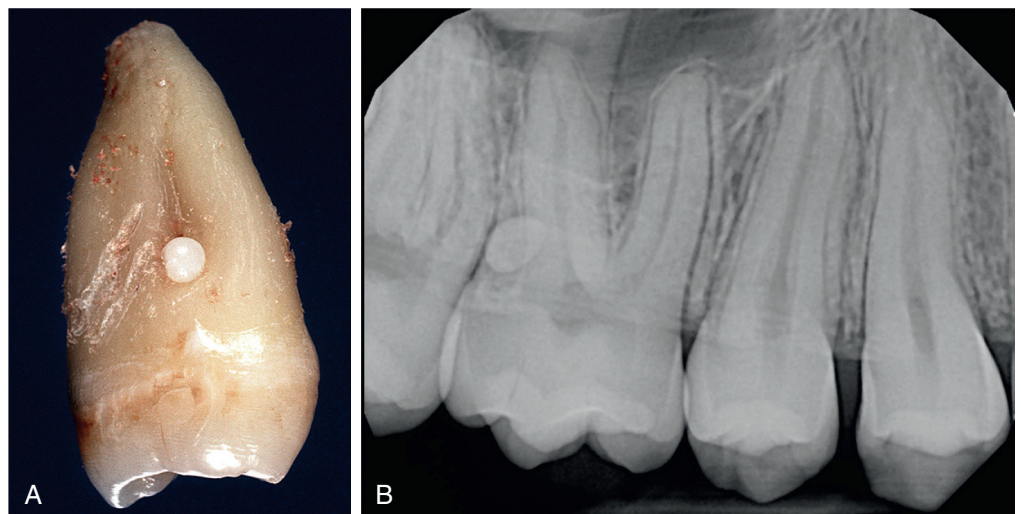
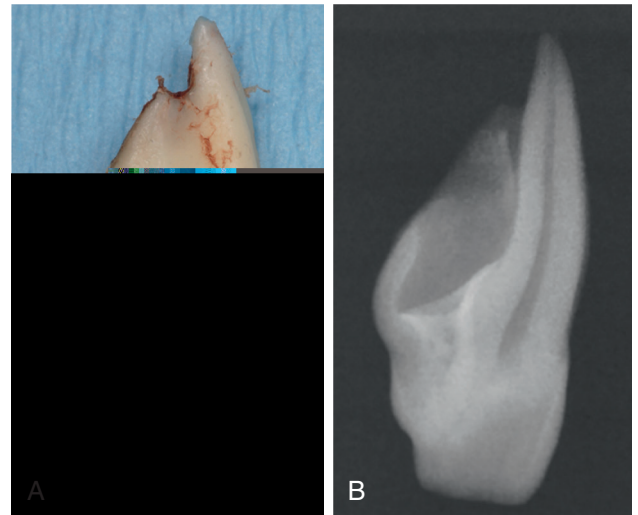
■ **Figure 2.35**
Dens Invaginatus

Periapical radiograph of right maxillary lateral incisor demonstrating incisal invagination lined by radiopaque enamel.



■ **Figure 2.36**
Dens Invaginatus

(A) Deformed right maxillary lateral incisor. (B) Radiograph of the same tooth exhibiting a channel lined by radiopaque enamel. The channel parallels the pulp and extends from the incisal edge to an exit along the lateral aspect of the root.



■ **Figure 2.37**
Enamel Pearl

(A) Maxillary molar exhibiting exophytic mass of enamel located at the bifurcation of fused roots. (B) Radiograph of a different maxillary molar exhibiting a radiopaque mass of ectopic enamel attached to the distal root of the first molar. (Courtesy Drs. James Lemon and Mary Ellis.)

Cervical Enamel Extension

Fig. 2.38

Cervical enamel extensions are not exophytic globules but represent sessile fingerlike tracts of enamel from the cemento-enamel junction toward the bifurcation of a molar. This creates an isosceles triangle-like extension of enamel with the base toward the coronal enamel and the leading point directed at the bifurcation. Cervical enamel extensions are not rare and demonstrate a slight mandibular predominance. Although any molar may be affected, the third molars are affected much less frequently.

Because the enamel prevents normal connective tissue attachment, the process can be associated with localized loss of periodontal attachment with furcation involvement. In addition, these enamel extensions have been associated with a clinically and radiographically distinctive inflammatory odontogenic cyst known as the **buccal bifurcation cyst**, although the association remains controversial. Flattening or removing the enamel with an excisional new attachment procedure and furcationplasty has been successful in preventing further loss of periodontal attachment.

Taurodontism

Fig. 2.39

Taurodontism is an apical extension of the pulp chamber that increases its apico-occlusal height and displaces the radicular bifurcation closer to the apex of a molar tooth. Taurodontism may be unilateral or bilateral and predominantly involves the permanent dentition. This dental anomaly may occur as an isolated finding or in association with greater than 20 syndromes. Patients with hypodontia or cleft lip and/or cleft palate demonstrate an increased prevalence of taurodontism. Although the alteration can complicate endodontic therapy, taurodonts require no specific therapy.

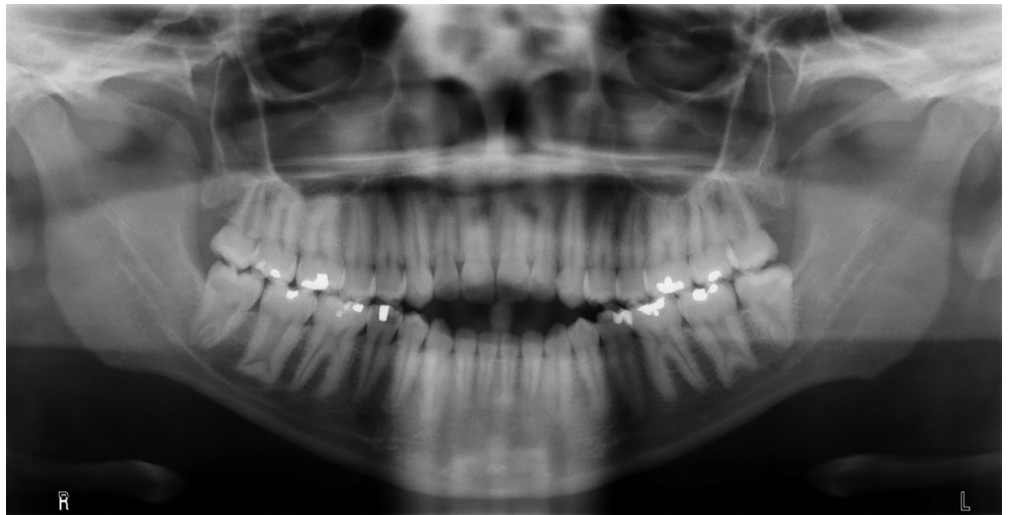
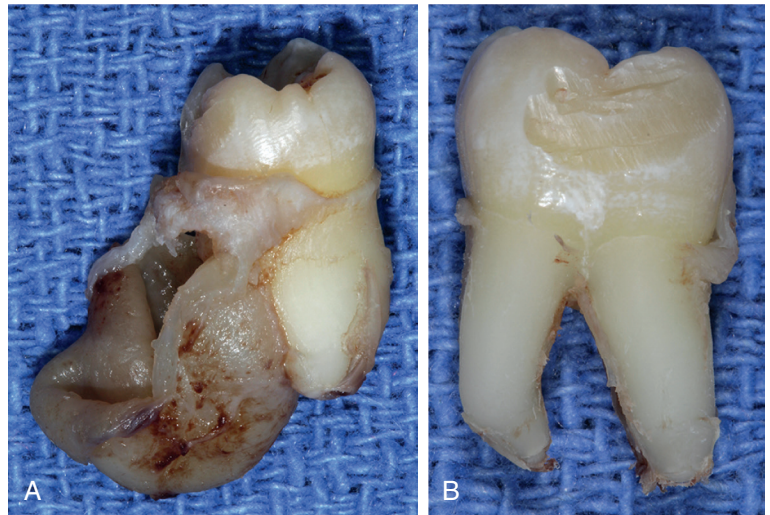
Hypercementosis

Fig. 2.40

Hypercementosis is a nonneoplastic deposition of excessive cementum. Most frequently, there is a uniform deposition with a drumstick-like thickening of the apical third of the root. Less commonly and less well known are small focal knots or projections of excess cementum on the lateral or interradicular root surfaces. Diffuse hypercementosis may be associated with various syndromes and systemic diseases, such as Paget disease of bone, acromegaly, thyroid goiter, calcinosis, arthritis, and rheumatic fever. Isolated hypercementosis may be related to local factors such as periradicular inflammation, occlusal trauma, impaction, loss of antagonistic teeth, and dilaceration. Although teeth demonstrating hypercementosis require no specific therapy, the thickened root occasionally may create problems during extraction and may require sectioning to aid in removal.

■ **Figure 2.38**
Cervical Enamel Extension

(A) Extracted mandibular molar with associated buccal bifurcation cyst. (B) Facial view of the same tooth demonstrating a white, opaque line of enamel extending into the bifurcation.

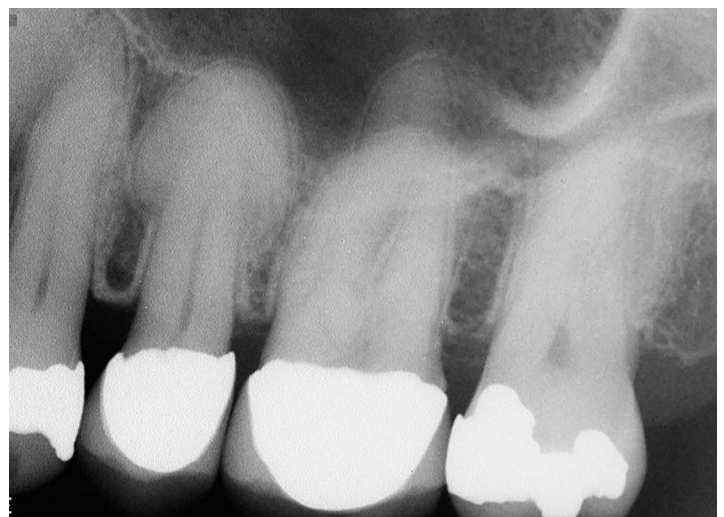

■ **Figure 2.39**
Taurodontism

Panoramic radiograph demonstrating alteration of multiple molars in all four quadrants. These molars exhibit enlarged pulp chambers and root bifurcations that approximate the apex. (Courtesy Dr. Sarah Marks Leach.)

■ **Figure 2.40**
Hypercementosis

Left maxillary premolar demonstrating radiopaque clublike thickening of the radicular portion of the tooth (Courtesy Dr. Eddie White.)



Dilaceration

Fig. 2.41

Dilaceration is an abnormal bend in the root or crown of a tooth. Although the root is affected most frequently, the bend may occur anywhere along the length of the tooth and has been noted in various teeth throughout the dentition. Although many examples appear idiopathic, others arise in association with significant trauma during tooth development, such as avulsion or intrusion of an overlying deciduous tooth. An adjacent anatomic structure, cyst, or tumor also may induce an abnormal angulation in a developing tooth. Dilaceration usually is diagnosed radiographically, but the change often is subtle when the bend occurs in a facial or lingual direction.

Minor dilaceration requires no therapy. Dilaceration of a deciduous tooth can alter its resorption and delay eruption of the underlying permanent tooth, occasionally mandating extraction of the bent tooth. Severe dilacerations also can prevent eruption of the affected tooth and create endodontic or extraction difficulties.

Supernumerary Roots

Fig. 2.42

Supernumerary roots refer to teeth with a greater than normal number of roots. Although any tooth in either dentition may be affected, the permanent molars of both arches followed by the mandibular canines and premolars are involved most frequently.

As would be expected, supernumerary roots can create problems during endodontic therapy and exodontia. Although some examples are obvious on periapical radiographs, many are subtle and difficult to identify. All extracted teeth should be examined closely to ensure small supernumerary roots did not separate during removal. In addition, a thorough search for all accessory canals during endodontic therapy increases the chance of success. When questions arise, cone beam computed tomography has been shown to be superior for demonstrating the number of roots and the complex anatomy of their pulp canals.

Syndrome-Associated Enamel Defects

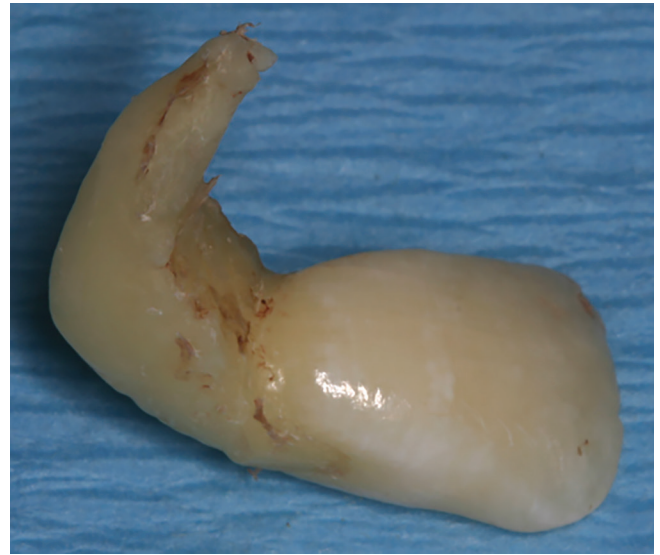Fig. 2.43

Development of enamel involves thousands of genes and their associated protein products. It is not surprising that certain molecular alterations result in enamel disturbances along with other systemic manifestations. More than 80 syndromes are known to demonstrate associated enamel defects.

One excellent and well-known example is **tricho-dento-osseous syndrome**, an autosomal dominant disorder that arises secondary to alteration of the *DLX3* gene. Affected patients present with osteosclerosis (most often in the base of the skull and the mastoid), infantile kinky hair, and brittle nails. The dental phenotype includes enamel hypomaturational/hypoplasia (diffuse creamy enamel with pits) or enamel hypoplasia/hypomaturational (generalized thin enamel that also is creamy and opaque) combined with taurodontism.

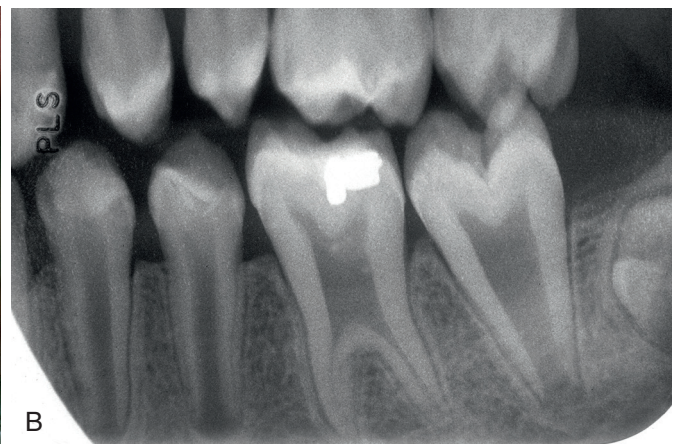
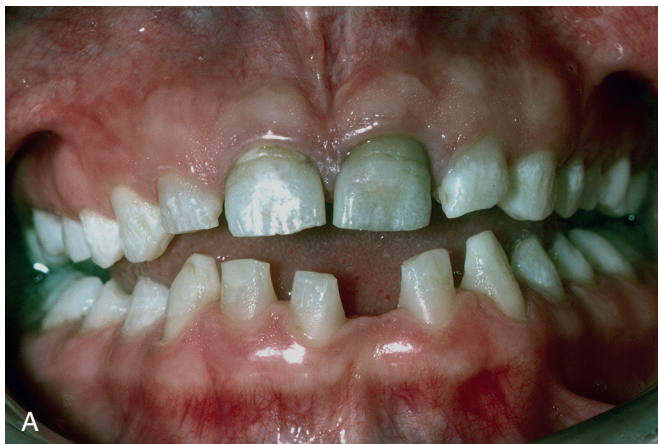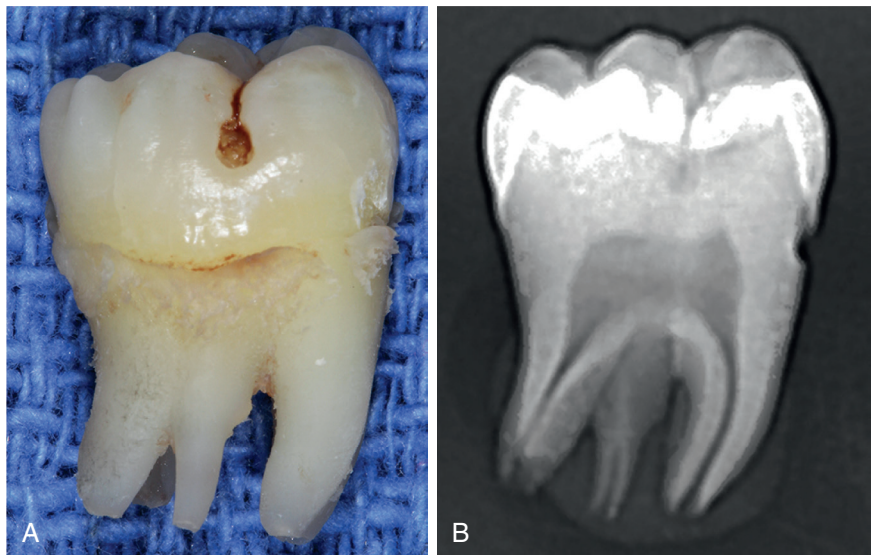
■ **Figure 2.41**
Dilaceration

Maxillary central incisor demonstrating abnormal curvature of its root.



■ **Figure 2.42**
Supernumerary Roots

(A) Gross photograph of mandibular molar exhibiting third accessory root. (B) Radiograph of same tooth exhibiting the accessory root.



■ **Figure 2.43**
Tricho-Dento-Osseous Syndrome

(A) Dentition demonstrating small, widely spaced teeth with white hypomature enamel (hypoplasia-hypomaturation). (B) Radiograph of same patient demonstrating thin enamel and taurodontism.

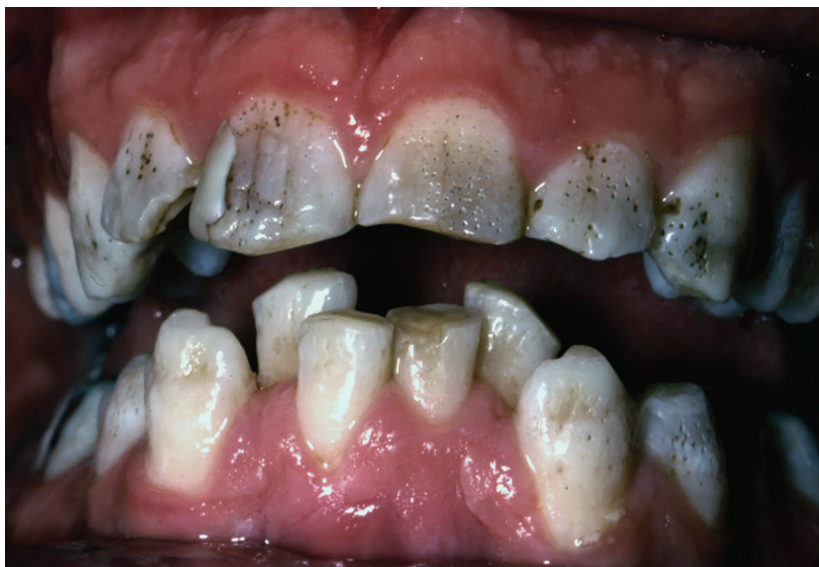Figs. 2.44–2.47

Amelogenesis imperfecta refers to genetic alterations in enamel formation unrelated to a systemic disorder or syndrome. The inheritance patterns include autosomal dominant, autosomal recessive, and X-linked. Phenotypic classification remains popular and includes hypoplastic (localized pitted, generalized pitted, generalized thin), hypomaturational (diffuse creamy, diffuse pigmented, snow capped), hypocalcification, and hypomaturational combined with hypoplasia and taurodontism. Numerous weaknesses in this system have become evident as the associated genetic alterations have been defined. Although all of the involved loci are not known, 10 genes have been associated definitively with amelogenesis imperfecta and allow for molecular diagnosis in the majority of the cases. In spite of this, molecular diagnosis also demonstrates numerous weaknesses, and many believe the most appropriate system must include the mode of inheritance, phenotype, and gene mutation with its associated protein function.

Amelogenesis imperfecta can be associated with significant aesthetic concerns, dental sensitivity, loss of vertical dimension with an increased frequency of caries, anterior open bite, delayed eruption, tooth impaction, and associated gingivitis/periodontitis. Mild variants often can be approached satisfactorily with facial veneers, whereas more severe cases require full coverage as soon as practical. Although many clinicians avoid crown placement in young individuals, studies have demonstrated positive results when following a multisession pattern that allows for the full eruption of the teeth (incisors first followed by premolars and cuspids). Although sensitivity often is a problem associated with conventional crown placement in younger patients, those with amelogenesis imperfecta usually report diminished sensitivity after crown placement, not more. Another option includes using milled acetal resin overlays until eruption is complete.

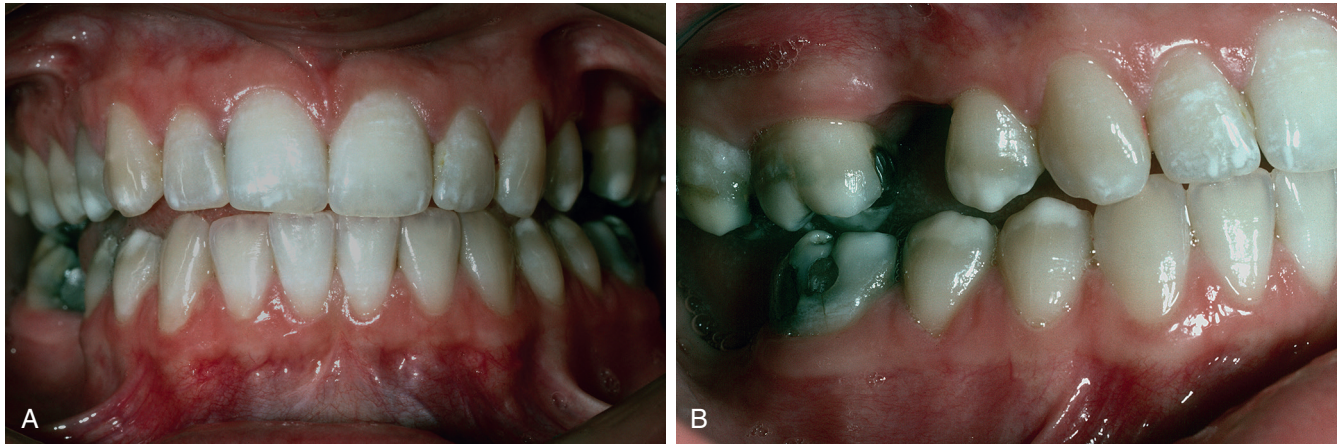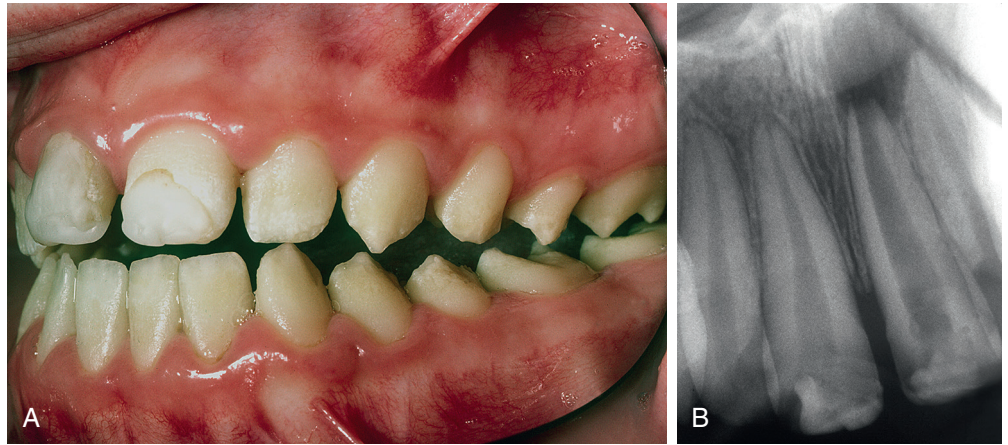
■ **Figure 2.44**
Amelogenesis Imperfecta, Generalized Pitted Hypoplastic Variant

Dentition demonstrating diffuse pitting of coronal enamel.



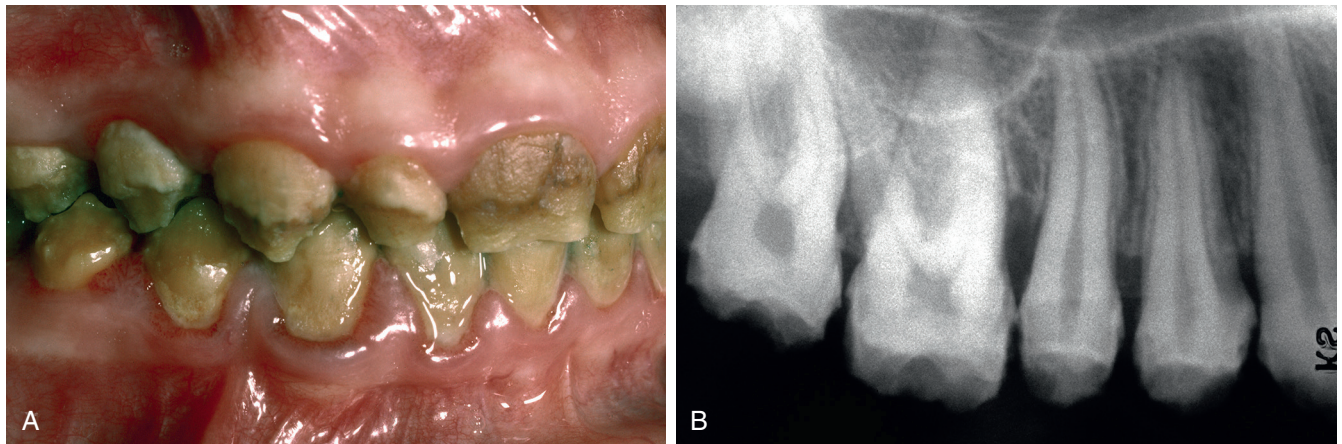
■ **Figure 2.45**
Amelogenesis Imperfecta, Generalized Thin Hypoplastic Variant

(A) Dentition demonstrating small, yellowish teeth with open contacts in a patient with anterior open bite. (B) Periapical radiograph of same patient demonstrating absence of enamel and areas of composite restoration.



■ **Figure 2.46**
Amelogenesis Imperfecta, Snow-Capped Hypomaturation Variant

(A) Facial view of dentition demonstrating white, opaque enamel restricted to the incisal and apical third of the teeth. (B) Buccal view of the posterior dentition in the same patient.



■ **Figure 2.47**
Amelogenesis Imperfecta, Hypocalcification Variant

(A) Dentition demonstrating brown-to-orange, crumbly enamel. (B) Periapical radiograph demonstrating enamel with decreased opacity and irregular loss due to rigors of mastication.

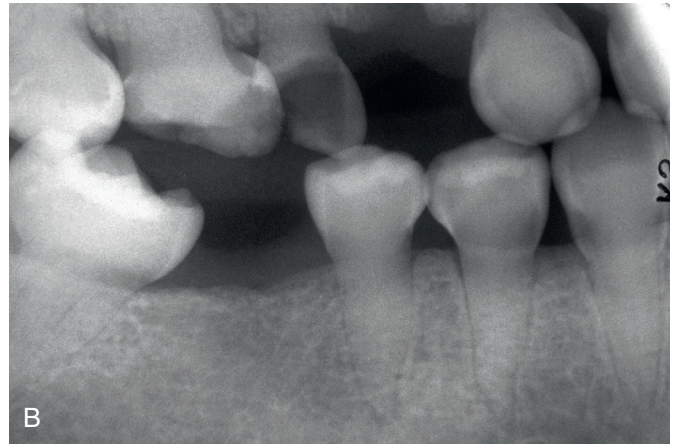
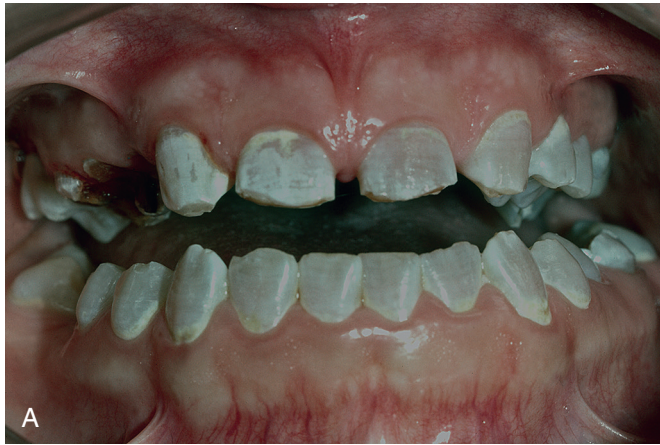Figs. 2.48–2.50

Dentinogenesis imperfecta (DGI) is an autosomal dominant abnormality of dentin in the absence of a systemic disease and associated with alteration of the dentin sialophosphoprotein (*DSPP*) gene. Dentin matrix is 90% collagen and 10% noncollagenous proteins. The majority of the noncollagenous proteins are produced under control of the *DSPP* gene. Disruption of either collagen or noncollagenous protein formation can result in a clinically obvious dentin disorder.

The widely used Shields classification includes two forms of dentin dysplasia (DD I and DD II) and three patterns of dentinogenesis imperfecta (DGI I, DGI II, DGI III). However, with advances in the genetics of tooth formation, the Shields classification is becoming obsolete. DD I (discussed later) does not appear to be associated with *DSPP* or a gene that controls collagen formation. DGI I is associated with the systemic disease, osteogenesis imperfecta, and is caused by genetic mutations that affect formation of collagen, not dentin protein. This disorder should be termed *osteogenesis imperfecta with opalescent teeth* and is an entity distinct from DGI. The remaining disorders in the Shields classification, DD II, DGI II, and DGI III, appear related to variations of the *DSPP* gene and are proposed to represent varying degrees of severity of the same disease, dentinogenesis imperfecta.

Classically, DGI presents with blue-to-brown translucent teeth that radiographically present with bulbous crowns, cervical constrictions, thin roots, and early obliteration of pulp chambers and canals. Although the enamel is normal, it often is lost prematurely because of an altered enamel-dentin junction.

In the moderate (old Shields DGI II) and severe (old Shields DGI III) variants of DGI, both dentitions demonstrate the features described previously, with the primary difference being the presence of shell teeth in those patients with severe disease. **Shell teeth** demonstrate enamel with normal thickness and roots with thin dentinal walls surrounding enlarged pulps. In the mild pattern (Shields DD II), the deciduous teeth resemble the other two variants, but the permanent teeth are normal, clinically. Radiographically, the permanent teeth are distinctive and demonstrate dramatically enlarged thistle tube-shaped pulp chambers that develop pulp stones over time.

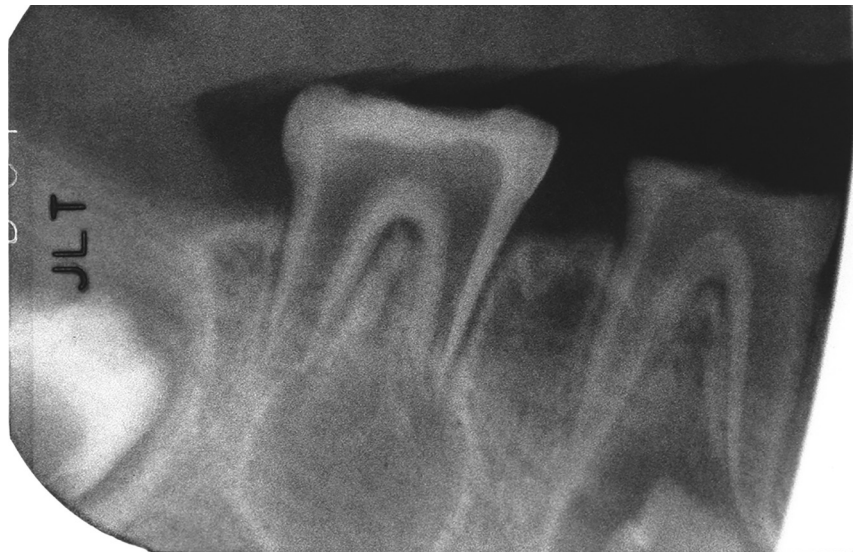

■ **Figure 2.48**
Dentinogenesis Imperfecta, Moderate Form

(A) Permanent dentition demonstrating diffuse grayish translucence. (B) Radiograph of same patient demonstrating bulbous crowns, cervical constrictions, and thin roots.

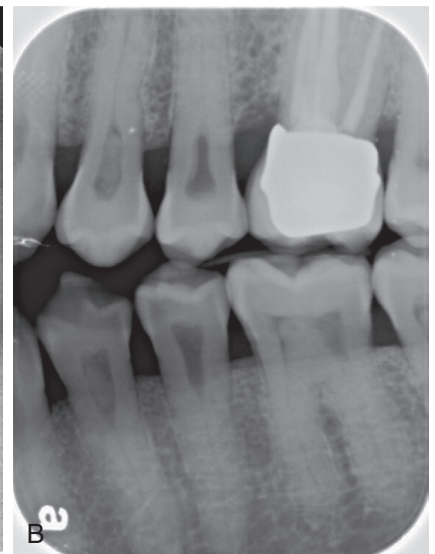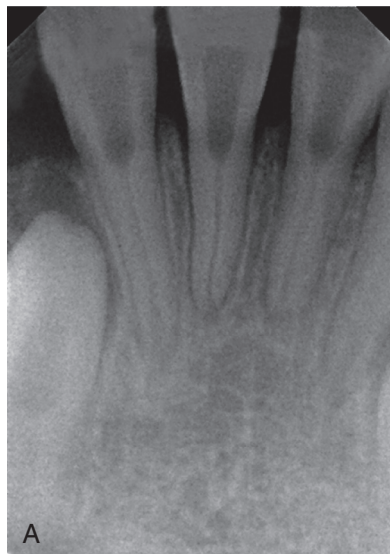■ **Figure 2.49**
Dentinogenesis Imperfecta, Severe Form

Periapical radiograph demonstrating shell teeth with enlarged pulp canals and thin radicular dentin. Prior to eruption these teeth demonstrated normal thickness of enamel, but the enamel was lost prior to the radiograph. (Courtesy Dr. Robin Wilson.)



■ **Figure 2.50**
Dentinogenesis Imperfecta, Mild Form (Dentin Dysplasia, Type II)

(A) Periapical radiograph demonstrating mandibular incisors exhibiting thistle tube-shaped pulp chambers. (B) Periapical radiograph of different patient with posterior dentition demonstrating thistle tube-shaped pulp chambers with pulp stones. These permanent teeth were normal clinically. (Courtesy Dr. James Zettler.)



Dentin Dysplasia, Type 1

Figs. 2.51 and 2.52

Dentin dysplasia, type I is a rare autosomal dominant disorder of dentin not associated with a systemic disease. Affected patients demonstrate teeth with normal-appearing crowns associated with failure of root formation or dramatically shortened roots. When root formation is noted, root canals typically are absent with only a thin crescent of pulp noted at the junction between the crown and the root. Typically in molar teeth, the bifurcation close to the apex. An unusual variation exhibiting root canals with midroot bulges associated with large pulp stones has been described, but there is concern this pattern often is due to a systemic disease such as hyperphosphatemic familial tumoral calcinosis.

Dentin dysplasia, type I diffusely involves both dentitions, with the deciduous teeth often revealing more severe manifestations. Because of dentinal clefts that extend to the dentinoenamel junction, loss of pulpal vitality with associated periapical inflammatory disease often is noted without significant caries or trauma. Tooth mobility and premature exfoliation are common.

Regional Odontodysplasia

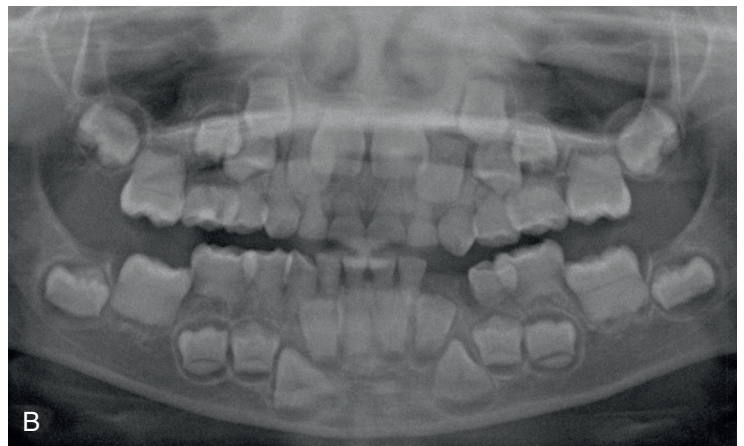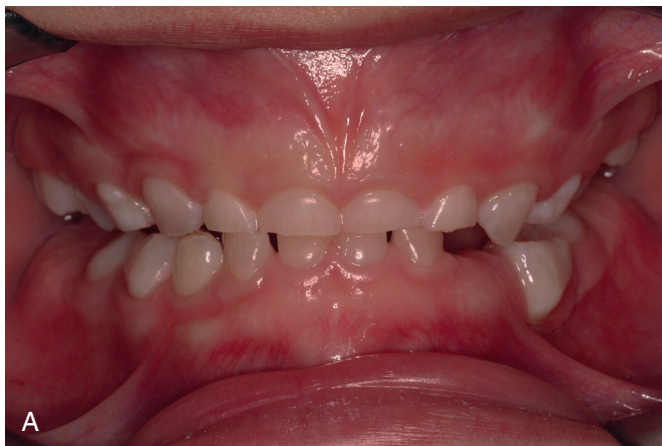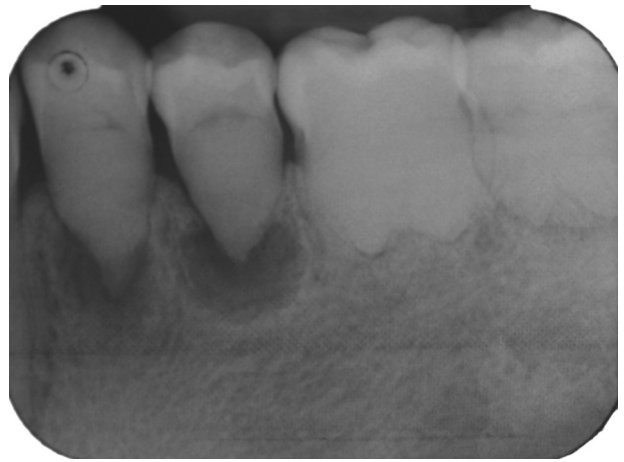
Fig. 2.53

Regional odontodysplasia is a nonhereditary and localized dental malformation that typically affects several contiguous teeth. Although a number of causative factors have been proposed, the pathogenesis has yet to be determined. The process demonstrates a strong maxillary predominance and typically affects both dentitions or only the permanent teeth. Although the malformation usually is limited to a single quadrant, bilateral involvement or ipsilateral alterations in both arches may be seen. Diffuse involvement is extremely rare, as is an unaffected tooth intermixed within a quadrant of altered teeth.

Although many affected teeth demonstrate delayed eruption, once exposed, the teeth are yellow to brown with a rough surface. Radiographically, the affected dentition has been coined **ghost teeth** because of the wispy image created by their large pulps surrounded by extremely thin layers of enamel and dentin. Short roots and open apices are common. Frequent signs and symptoms include failure of eruption, early exfoliation, and associated abscess formation.

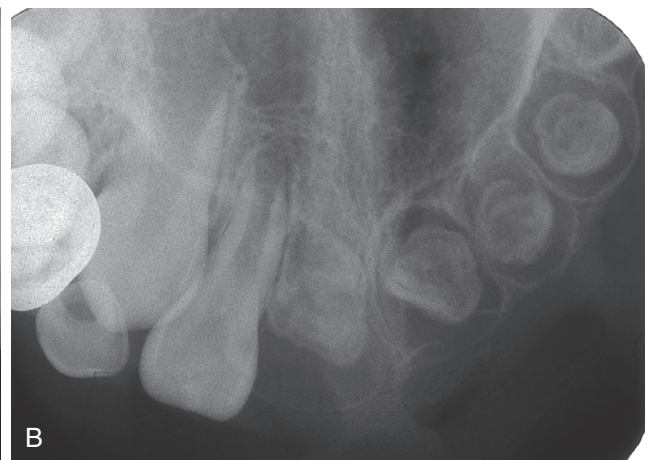
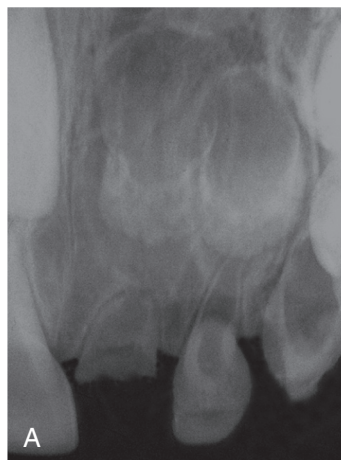■ **Figure 2.51**
Dentin Dysplasia, Type I

Periapical radiograph of posterior dentition demonstrating short roots, absence of root canals, and a small crescent-shaped pulp chamber. Note the bifurcation adjacent to the apex in the molar teeth. (Courtesy Dr. Michael Quinn.)



■ **Figure 2.52**
Dentin Dysplasia, Type I

(A) Patient with clinically normal appearing deciduous dentition. (B) Panoramic radiograph of the same patient. Note short roots, no pulp canals, and crescent-shaped pulp chambers. (Courtesy Dr. Thomas Ison.)



■ **Figure 2.53**
Regional Odontodysplasia

(A) Periapical radiograph of the left maxillary anterior teeth. Both the deciduous and permanent dentition demonstrate enlarged pulps associated with paper-thin enamel and dentin. All other teeth in both arches are not affected. (Courtesy Dr. Gregory Dimmich.) (B) Occlusal radiograph of different patient demonstrating similar alterations, also involving the maxilla on the left side. (Courtesy Dr. Román Carlos.)

Environmental Defects of Enamel

- Brook AH, Smith JM. Environmental causes of enamel defects. *Ciba Found Symp*. 1997;205:212–225.
- Suckling GW. Developmental defects of enamel – historical and present day perspective of their pathogenesis. *Adv Dent Res*. 1989;3:87–94.
- Wong HM, Peng S-M, Wen YF, et al. Risk factors of developmental defects of enamel – A prospective cohort study. *PLoS ONE*. 2014;9:e109351.

Turner Hypoplasia

- Andreasen JO, Sundström B, Ravn JJ. The effect of traumatic injuries to primary teeth on their permanent successors. 1. A clinical and histologic study of 117 injured permanent teeth. *Scand J Dent Res*. 1971;79:219–283.
- Turner JG. Injury to the teeth of succession by abscess of the temporary teeth. *Brit Dent J*. 1909;30:1233–1237.
- Von Arx T. Developmental disturbances of permanent teeth following trauma to the primary dentition. *Aust Dent J*. 1993;38:1–10.

Dental Disturbances due to Antineoplastic Therapy

- Gawade PL, Hudson MM, Kaste SC, et al. A systematic review of dental late effects in survivors of childhood cancer. *Pediatr Blood Cancer*. 2014;61:407–416.
- Holttä L, Levy SM, Warren JJ, et al. Long-term adverse effects on dentition in children with poor-risk and autologous stem cell transplantation with or without total body radiation. *Bone Marrow Transplant*. 2002;29:121–127.
- Näsman M, Björk O, Söderhäll S, et al. Disturbances in the oral cavity in pediatric long-term survivors after different forms of antineoplastic therapy. *Pediatr Dent*. 1994;16:217–223.

Dental Fluorosis

- Iheozor-Ejiofor Z, Worthington HV, Walsh T, et al. Water fluoridation for the prevention of dental caries. *Cochrane Database Syst Rev*. 2015;(6):CD010856, doi:10.1002/14651858.CD010856.pub2.
- O'Mullane DM, Baez RJ, Jones S, et al. Fluoride and oral health. *Community Dent Health*. 2016;33:69–99.
- U.S. Department of Health and Human Services Federal Panel on Community Water Fluoridation. U.S. Public Health Service recommendations for fluoride concentration in drinking water for the prevention of dental caries. *Public Health Rep*. 2015;130:318–331.

Tooth Wear

- Bartlett DW, Shah P. A critical review of non-carious cervical (wear) lesions and the role of abfraction, erosion, and abrasion. *J Dent Res*. 2006;85:306–312.
- Carvalho TS, Colon P, Ganss C, et al. Erosive tooth wear – diagnosis and management. *Swiss Dent J*. 2016;126:342–346.
- Grippio JO, Simring M, Coleman TA. Abfraction, abrasion, biocorrosion, and the enigma of noncariou cervical lesions: a 20-year perspective. *J Esthet Restor Dent*. 2012;24:10–25.
- Kontaxopoulou I, Alam S. Risk assessment for tooth wear. *Prim Dent J*. 2015;4:25–29.
- Litonjua LA, Andreana S, Patra AK, et al. An assessment of stress analyses in the theory of abfraction. *Biomed Mater Eng*. 2004;14:311–321.
- Salas MMS, Nascimento GG, Vargas-Ferreira F, et al. Diet influenced tooth erosion prevalence in children and adolescents: results of a meta-analysis and meta-regression. *J Dent*. 2015;43:865–875.
- Sarig R, Hershkovitz I, Shvalb N, et al. Proximal attrition facets: morphometric, demographic, and aging characteristics. *Eur J Oral Sci*. 2014;122:271–278.
- Shellis RP, Addy M. The interactions between attrition, abrasion and erosion in tooth wear. *Monogr Oral Sci*. 2014;25:32–45.
- Young WG, Khan F. Sites of dental erosion are saliva-dependent. *J Oral Rehabil*. 2002;29:35–43.
- Young WG. Tooth wear: diet analysis and advice. *Int Dent J*. 2005;55:68–72.
- Yule PL, Barclay SC. Worn down by toothwear? Aetiology, diagnosis and management revisited. *Dent Update*. 2015;42:525–532.

Tooth Resorption

- Aziz K, Hoover T, Sidhu G. Understanding root resorption with diagnostic imaging. *CDA J*. 2014;42:159–164.
- Bakland LK. Root resorption. *Dent Clin North Am*. 1992;36:491–507.
- Gartner AH, Mack T, Somerlott RG, et al. Differential diagnosis of internal and external resorption. *J Endod*. 1976;2:329–334.
- Germain L. Tooth resorption: the “black hole” of dentistry. *Dent Today*. 2015;34:78–83.
- Tronstad L. Root resorption – etiology, terminology and clinical manifestations. *Endod Dent Traumatol*. 1988;4:241–252.

Discolorations of Teeth

- Dayan D, Heifferman A, Gorski M, et al. Tooth discoloration – extrinsic and intrinsic factors. *Quintessence Int*. 1983;14:195–199.
- Eisenberg E, Bernick SM. Anomalies of the teeth with stains and discolorations. *J Prev Dent*. 1975;2:7–20.
- Giunta JL, Tsamtsouris A. Stains and discolorations of teeth: review and case reports. *J Pedod*. 1978;2:175–182.

Ankylosis

- de Moura MS, Pontes AS, Brito MHSE, et al. Restorative management of severely ankylosed primary molars. *J Dent Child*. 2015;82:41–46.
- Douglass J, Tinanoff N. The etiology, prevalence, and sequelae of infraocclusion of primary molars. *J Dent Child*. 1991;58:481–483.
- Ekim SL, Hatibovic-Kofman S. A treatment decision-making model for infraoccluded primary molars. *Int J Paediatr Dent*. 2001;11:340–346.

Dental Transposition

- Danielsen JC, Karimian K, Ciarlantini R, et al. Unilateral and bilateral dental transposition in the maxilla – dental and skeletal findings in 63 individuals. *Eur Arch Paediatr Dent*. 2015;16:467–476.
- Lorente T, Lorente C, Murry PG, et al. Surgical and orthodontic management of maxillary canine-lateral incisor transpositions. *Am J Orthod Dentofacial Orthop*. 2016;150:876–885.
- Peck L, Peck S, Attia Y. Maxillary canine-first premolar transpositions, associated dental anomalies and genetic basis. *Angle Orthod*. 1993;63:99–109.
- Peck S, Peck L. Classification of maxillary tooth transpositions. *Am J Orthod Dentofacial Orthop*. 1995;107:505–517.

Hypodontia

- Khalaf K, Miskelly J, Voge E, et al. Prevalence of hypodontia and associated factors: a systemic review and meta-analysis. *J Orthod*. 2014;41:299–316.
- Lammi L, Arte S, Somer M, et al. Mutations in AXIN2 cause familial tooth agenesis and predispose to colorectal cancer. *Am J Hum Genet*. 2004;74:1043–1050.
- Longtin R. Chew on this: mutation may be responsible for tooth loss, colon cancer. *J Natl Cancer Inst*. 2004;96:987–989.
- Nieminen P. Genetic basis of tooth agenesis. *J Exp Zool B Mol Dev Evol*. 2009;312B:320–342.
- Pani SC. The genetic basis of tooth agenesis: basic concepts and genes involved. *J Indian Soc Pedod Prev Dent*. 2011;29:84–89.
- Yin W, Bian Z. The gene network underlying hypodontia. *J Dent Res*. 2015;94:878–885.

Hyperdontia

- Bereket C, Çakir-Özkan N, Sener I, et al. Analyses of 100 supernumerary teeth in a nonsyndromic Turkish population: a retrospective multicenter study. *Niger J Clin Pract*. 2015;18:731–738.
- Bodin I, Julin P, Thomsson M. Hyperdontia. I. Frequency and distribution of supernumerary teeth among 21,609 patients. *Dentomaxillofac Radiol*. 1978;7:15–17.
- Brook AH, Jernvall J, Smith RN, et al. The dentition: the outcomes of morphogenesis leading to variations in tooth number, size, and shape. *Aust Dent J*. 2014;59(suppl 1):131–142.
- Cassetta M, Altieri F, Giansanti M, et al. Morphological and topographical characteristics of posterior supernumerary molar teeth: an epidemiological study on 25, 186 subjects. *Med Oral Patol Oral Cir Bucal*. 2014;19:e545–e549.

- Mossaz J, Kloukos D, Pandis N, et al. Morphologic characteristics, location, and associated complications of maxillary and mandibular supernumerary teeth as evaluated using cone beam computed tomography. *Eur J Orthod*. 2014;36:708–718.
- Omer RS, Anthonappa RP, King NM. Determination of the optimum time for surgical removal of unerupted anterior supernumerary teeth. *Pediatr Dent*. 2010;32:14–20.
- Rajab LD, Hamdan MAM. Supernumerary teeth: review of the literature and a survey of 152 cases. *Int J Pediatr Dent*. 2002;12:244–254.

Natal Teeth

- Baldiwal M, Nayak R. Conservative management of Riga-Fede disease. *J Dent Child*. 2014;81:103–106.
- Kana A, Markou I, Arhakis A, et al. Natal and neonatal teeth: a systemic review of prevalence and management. *Eur J Paediatr Dent*. 2013;14:27–32.
- Khandelwal V, Nayak UA, Nayak PA, et al. Management of an infant having natal teeth. *BMJ Case Rep*. 2013;doi:10.1136/bcr-2013-010049.
- Moura LEAD, Moura MS, Lima MDM, et al. Natal and neonatal teeth: a review of 23 cases. *J Dent Child*. 2014;81:107–111.

Microdontia and Macrodontia

- Brook AH, Jernvall J, Smith RN, et al. The dentition: the outcomes of morphogenesis leading to variations in tooth number, size, and shape. *Aust Dent J*. 2014;59(suppl 1):131–142.
- Jeong KH, Kim D, Song Y-M, et al. Epidemiology and genetics of hypodontia and microdontia: a study of twin families. *Angle Orthod*. 2015;85:980–985.
- Kyriazidou A, Haider D, Mason C, et al. Case report: macrodont mandibular second premolars a hereditary dental anomaly. *Eur Arch Paediatr Dent*. 2013;14:411–416.
- Pereira L, Assunção PA, Salazar SLA, et al. Uncommon true isolated macrodontia of a maxillary tooth. *J Contemp Dent Pract*. 2014;15:116–118.

Double Teeth

- Brook AH, Winter GB. Double teeth: a retrospective study of “geminated” and “fused” teeth in children. *Br Dent J*. 1970;129:123–130.
- Finkelstein T, Shapira Y, Bechor N, et al. Fused and geminated permanent maxillary central incisors: prevalence, treatment options, and outcome in orthodontic patients. *J Dent Child*. 2015;82:147–152.
- Neves FS, Rovaris K, Oliveira ML, et al. Concrescence. Assessment of case by periapical radiography, cone beam computed tomography, and micro-computed tomography. *N Y State Dent J*. 2014;80:21–23.
- Prabhu RV, Chatra L, Shenai P, et al. Bilateral fusion in primary mandibular teeth. *Indian J Dent Res*. 2013;24:277–278.
- Ruprecht A, Batniji S, El-Newehi E. Double teeth: the incidence of germination and fusion. *J Pedod*. 1985;9:332–337.
- Smail-Ferguson V, Terradot J, Bolla MM, et al. Management of non-syndromic double tooth affecting permanent maxillary central incisors: a systematic review. *BMJ Case Rep*. 2016;doi:10.1136/bcr-2016-215482.

Talon Cusp

- Dankner E, Harari D, Rotstein I. Dens evaginatus of anterior teeth. Literature review and radiographic survey of 15,000 teeth. *Oral Surg Oral Med Oral Pathol Oral Radiol Endod*. 1996;81:472–476.
- Davis PJ, Brook AH. The presentation of talon cusp: diagnosis, clinical features, associations and possible aetiology. *Br Dent J*. 1986;160:84–88.
- Manuja N, Chaudhary S, Nagpal R, et al. Bilateral dens evaginatus (talon cusp) in permanent maxillary lateral incisors: a rare developmental dental anomaly with great clinical significance. *BMJ Case Rep*. 2013;doi:10.1136/bcr-2013-009184.
- Mellor JK, Ripa LW. Talon cups: a clinically significant anomaly. *Oral Surg Oral Med Oral Pathol*. 1970;29:225–228.

Dens Evaginatus and Shovel-Shaped Incisors

- Gaynor WN. Dens evaginatus – how does it present and how should it be managed? *N Z Dent J*. 2002;98:104–107.
- Levitan ME, Himel VT. Dens evaginatus: literature review, pathophysiology, and comprehensive treatment regimen. *J Endod*. 2006;32:1–9.

- Saini TS, Kharat DU, Mokeem S. Prevalence of shovel-shaped incisors in Saudi Arabian dental patients. *Oral Surg Oral Med Oral Pathol*. 1990;70:540–544.

Dens Invaginatus

- Capar ID, Ertas H, Arslan H, et al. A retrospective comparative study of cone-beam computed tomography versus rendered panoramic images in identifying the presence, types, and characteristics of dens invaginatus in a Turkish population. *J Endod*. 2015;41:473–478.
- Macho AZ, Ferreiroa A, Rico-Romano C, et al. Diagnosis and endodontic treatment of type II dens invaginatus by using cone-beam computed tomography and splint guides for cavity access. *J Am Dent Assoc*. 2015;146:266–270.
- Oehlers FAC. Dens invaginatus (dilated composite odontome). I. Variations of the invagination process and associated anterior crown forms. *Oral Surg Oral Med Oral Pathol*. 1957;10:1204–1218.
- Oehlers FAC. Dens invaginatus (dilated composite odontome). II. Associated posterior crown forms and pathogenesis. *Oral Surg Oral Med Oral Pathol*. 1957;10:1302–13116.
- Oehlers FAC. The radicular variant of dens invaginatus. *Oral Surg Oral Med Oral Pathol*. 1958;11:1251–1260.

Enamel Pearls

- Cavanha AO. Enamel pearls. *Oral Surg Oral Med Oral Pathol*. 1965;19:373–382.
- López SP, Warren RN, Bromage TG, et al. Treatment of an unusual non-tooth related enamel pearl (EP) and 3 teeth-related EPs with localized periodontal disease without teeth extractions: a case report. *Compend Contin Educ Dent*. 2015;36:592–599.
- Risnes S, Segura JJ, Casado A, et al. Enamel pearls and cervical enamel projections in 2 maxillary molars with localized periodontal disease. Case report and histologic study. *Oral Surg Oral Med Oral Pathol Oral Radiol Endod*. 2000;89:493–497.
- Romeo U, Palaia G, Botti R, et al. Enamel pearls as a predisposing factor to localized periodontitis. *Quintessence Int*. 2011;42:69–71.

Cervical Enamel Extension

- Fowler CB, Brannon RB. The paradental cyst: a clinicopathologic study of six new cases and review of the literature. *J Oral Maxillofac Surg*. 1989;47:243–248.
- Hou G-L, Tsai C-C. Cervical enamel projection and intermediate bifurcational ridge correlated with molar furcation involvement. *J Periodontol*. 1997;68:687–693.
- Pompura JR, Sándor GKB, Stoneman DW. The buccal bifurcation cyst: a prospective study of treatment outcomes in 44 sites. *Oral Surg Oral Med Oral Pathol Oral Radiol Endod*. 1997;83:215–221.

Taurodontism

- Hashova JE, Gill DS, Figueiredo JAP, et al. Taurodontism – a review. *Dent Update*. 2009;36:235–243.
- Jafarzadeh H, Azarpazhooh A, Mayhall JT. Taurodontism: a review of the condition and endodontic treatment challenges. *Int Endod J*. 2008;41:375–388.
- Melo Filho MR, dos Santos LAN, Barbosa Martelli DR, et al. Taurodontism in patients with nonsyndromic cleft lip and palate in a Brazilian population: a case control evaluation with panoramic radiographs. *Oral Surg Oral Med Oral Pathol Oral Radiol Endod*. 2015;120:744–750.

Hypercementosis

- Abbot F. Hyperostosis of roots of teeth. *Dent Cosmos*. 1886;28:665–683.
- d’Incau E, Couture C, Crépeau N, et al. Determination and validation of criteria to define hypercementosis in two medieval samples from France (Sains-en-Gohelle, AD 7th-17th century; Jau-Dignac-et-Loirac, AD 7th-8th century). *Arch Oral Biol*. 2015;60:293–303.
- Gardner BS, Goldstein H. The significance of hypercementosis. *Dent Cosmos*. 1931;73:1065–1069.
- Leider AS, Garbarino VE. Generalized hypercementosis. *Oral Surg Oral Med Oral Pathol*. 1987;63:375–380.

Dilaceration

- Jafarzadeh H, Abbott PV. Dilaceration: review of an endodontic challenge. *J Endod*. 2007;33:1025–1030.

Ligh RQ. Coronal dilacerations. *Oral Surg Oral Med Oral Pathol.* 1981;51:567.

Topouzelis N, Tsaousoglou P, Pisoka V, et al. Dilaceration of maxillary central incisor: a literature review. *Dent Traumatol.* 2010;26:427–433.

Supernumerary Roots

Kannan SK, Suganya, Santharam H. Supernumerary roots. *Indian J Dent Res.* 2002;13:116–119.

Chauhan R, Singh S. Endodontic treatment of mandibular molars with atypical root canal anatomy: report of 4 cases. *Gen Dent.* 2015;63:67–70.

Syndromic Enamel Defects and Amelogenesis Imperfecta

Aldred MJ, Savarirayan R, Crawford PJM. Amelogenesis imperfecta: a classification and catalogue for the 21st century. *Oral Dis.* 2003;9:19–23.

Lundgren GP, Vestlund GIM, Trulsson M, et al. A randomized controlled trial of crown therapy in young individuals with amelogenesis imperfecta. *J Dent Res.* 2015;94:1041–1047.

Wilson OL, Bradshaw JP, Marks MK. Amelogenesis imperfecta, facial esthetics and Snap-on Smile®. *J Tenn Dent Assoc.* 2015;95:18–21.

Witkop CJ Jr. Amelogenesis imperfecta, dentinogenesis imperfecta and dentin dysplasia revisited: problems in classification. *J Oral Pathol.* 1988;17:547–553.

Wright JT, Carrion IA, Morris C. The molecular basis of hereditary enamel defects in humans. *J Dent Res.* 2015;94:52–61.

DSPP-Associated Dentin Disorders

Barron MJ, McDonnell ST, MacKie I, et al. Hereditary dentine disorders: dentinogenesis imperfecta and dentine dysplasia. *Orphanet J Rare Dis.* 2008;3:31.

Dean JA, Hartsfield JK Jr, Wright JT, et al. Dentin dysplasia, type II linkage to chromosome 4q. *J Craniofac Genet Dev Biol.* 1997;17:172–177.

de Dure-Molla M, Fournier BP, Berdal A. Isolated dentinogenesis imperfecta and dentin dysplasia: revision of the classification. *Eur J Hum Genet.* 2015;23:445–451.

MacDougall M. Refined mapping of the human dentin sialophosphoprotein (DSPP) gene within the critical dentinogenesis imperfecta type II and dentin dysplasia type II loci. *Eur J Oral Sci.* 1998;106(suppl 1):227–233.

McKnight DA, Simmer JP, Hart PS, et al. Overlapping DSPP mutations cause DD and DGI. *J Dent Res.* 2008;87:1108–1111.

Shields ED, Bixler D, El-Kafrawy AM. A proposed classification for heritable human dentine defects with a description of a new entity. *Arch Oral Biol.* 1973;18:543–553.

Dentin Dysplasia, Type I

O'Carroll MK, Duncan WK, Perkins TM. Dentin dysplasia: review of the literature and a proposed subclassification based on radiographic findings. *Oral Surg Oral Med Oral Pathol.* 1991;72:119–125.

Ranta H, Lukinmaa P-L, Waltimo J. Heritable dentin defects: nosology, pathology, and treatment. *Am J Med Genet.* 1993;45:193–200.

Vieira AR, Lee M, Vairo F, et al. Root anomalies and dentin dysplasia in autosomal recessive hyperphosphatemic familial tumoral calcinosis. *Oral Surg Oral Med Oral Pathol Oral Radiol.* 2015;120:e235–e239.

Regional Odontodysplasia

Al-Tuwirqi A, Lambie D, Seow WK. Regional odontodysplasia: literature review and report of unusual case located in the mandible. *Pediatr Dent.* 2014;36:62–67.

Crawford PJM, Aldred MJ. Regional odontodysplasia: a bibliography. *J Oral Pathol Med.* 1989;18:251–263.

Kahn MA, Hinson RL. Regional odontodysplasia. Case report with etiologic and treatment considerations. *Oral Surg Oral Med Oral Pathol Oral Radiol Endod.* 1991;72:462–467.

Tervonon SA, Stratmann U, Mokrys K, et al. Regional odontodysplasia: a review of the literature and report of four cases. *Clin Oral Invest.* 2004;8:45–51.