

Treatment of congenital maxillomandibular interalveolar fusion is a surgical priority because of the high risk of aspiration pneumonia and feeding handicaps. In addition, early treatment is necessary if the teeth are to grow and align correctly. However, successful delayed surgical corrections have been reported.<sup>7</sup> The rarity of this condition makes standardization of treatment difficult. In this case, a 4-year-old boy was referred to our emergency unit with asphyxia after vomiting. We found the child could not open his mouth, and his upper and lower jaws were fused solid, leaving only a 2- to 3-mm gap in the anterior part. After performing an urgent tracheotomy, we performed an osteotomy to relieve the fusion between the bilateral ramus mandible, maxilla and zygoma, and we also performed a temporomandibular joint reconstruction using a silicon block. Then, 2 years later, a mandibular lengthening was performed using an external distracter.

A lot of cases of mandible hypoplasia have been reported in the literature, but the treatment of mandible hypoplasia generally was not mentioned in the literature because only early period treatment methods have been mentioned. Recurrence of fusion between the alveolar arches after separation of the maxilla and mandible have been reported.<sup>8</sup> In the literature, a silicon block was used to keep the maxillary and mandibular alveolar arches separated.<sup>1</sup> In this case, we used a silicon block in the temporomandibular joint.

## REFERENCES

1. Rao S, Oak M, Kulkarni B. Congenital midline palatomandibular bony fusion with a mandibular cleft and a bifid tongue. *Br J Plast Surg* 1997;50:139-143
2. Burket LW. Congenital bony temporomandibular ankylosis and facial hemiatrophy. *JAMA* 1936;106:719-721
3. Verdi GD, O'Neal B. Cleft palate and congenital alveolar synechia syndrome. *Plast Reconstr Surg* 1984;74:684-687
4. Haramis HT, Apesos J. Cleft palate and congenital lateral alveolar synechia syndrome: case presentation and literature review. *Ann Plast Surg* 1995;34:424-427
5. Goodacre TEE, Wallace AF. Congenital alveolar fusion. *Br J Plast Surg* 1990;43:203-205
6. Kamata S, Satoh K, Uemura T, Onizuka T. Congenital bilateral zygomaticomandibular fusion with mandibular hypoplasia. *Br J Plast Surg* 1996;49:251-254
7. Agarwal K, Chandra SS, Sreekumar NS. Congenital bilateral intermaxillary bony fusion. *Ann Plast Surg* 1993;30:163-165
8. Ugurlu K, Turan T, Urganci N, et al. Fusion of maxillary and mandibular alveolar process together with a median mandibular cleft: a rare congenital anomaly. *J Craniomaxillofacial Surg* 1999;27:105-108

## Congenital Mandibular Hypoplasia: Analysis And Classification

Davinder J. Singh, MD, Scott P. Bartlett, MD

Philadelphia, Pennsylvania, USA

**Abstract:** Mandibular hypoplasia is a frequently encountered craniofacial difference and can be classified into three groups: congenital, developmental, and acquired. The focus of this article is on the congenital group, the majority of which is associated with syndromes. There have been numerous publications on patients with syndromic congenital mandibular hypoplasia; however, there has been no investigation and differentiation of the "nonsyndromic" patients. The purpose of this study was to analyze this subgroup of patients with nonsyndromic congenital mandibular hypoplasia to determine incidence, clinical presentation, and treatment.

A retrospective analysis of all children treated for congenital mandibular hypoplasia at the Children's Hospital of Philadelphia between 1975 and 2003 was performed. Two hundred sixty-six patients were identified during this 27-year period. Of these 266 patients, 148 presented with oculo-auriculo-vertebral (OAV) spectrum, 52 with mandibulofacial dysostosis, 31 with Pierre Robin sequence, and 17 with miscellaneous syndromes. The remaining 18 patients were identified as having congenital mandibular hypoplasia without any known syndrome.

Of the 18 patients with nonsyndromic congenital mandibular hypoplasia, 17 had primary bilateral growth anomalies and 1 had a primary unilateral growth disturbance resulting in bilateral deformity. Seven patients were products of a complicated pregnancy, 10 patients required tracheotomy or prolonged intubations, and 7 required gastric tube feedings. Associated anomalies included temporomandibular joint ankylosis in five patients, aglossia/microglossia in three patients, and rare craniofacial clefts in three patients. The average number of procedures required to treat the mandibular deformity for each patient was six.

Although mandibular hypoplasia is a common craniofacial anomaly, patients manifesting nonsyndromic congenital mandibular hypoplasia are a rare subgroup. Case reports illustrating the range of mandibular deformities are presented.

**Key Words:** Congenital, mandibular hypoplasia, nonsyndromic

**M**andibular hypoplasia is a common craniofacial anomaly and is highly variable in its clinical presentation and its etiology. The etiology can be

From the Division of Plastic Surgery, University of Pennsylvania School of Medicine, and Children's Hospital of Philadelphia, Philadelphia, Pennsylvania.

Presented at the 18th Annual Meeting of the Northeastern Society of Plastic Surgeons, Bermuda, October 5, 2002, and the American Cleft Palate Association Meeting, Asheville, NC, April 15, 2003.

Address correspondence and reprint requests to Dr. Singh, Division of Plastic Surgery, 3400 Spruce Street, 10 Penn Tower, Philadelphia, PA 19104; e-mail: davinder.singh@uphs.upenn.edu.

congenital, developmental, or acquired. Congenital hypoplasia most frequently results from maldevelopment of the first and second branchial arches, either unilateral or bilateral. Developmental hypoplasia presents with a class II malocclusion and underdevelopment of the mandible for unknown reasons. Acquired hypoplasia includes oncologic defects, radiation damage, trauma, and hemifacial atrophy.<sup>1</sup>

The focus of this study is on the congenital mandibular hypoplasia group. The embryology of the mandible is key in understanding the pathology of this deformity. Mandibular development begins early in the 4th week of gestation, as neural crest cells migrate into the future head and neck region to initiate branchial arch formation. The first branchial arch, often called the mandibular arch, develops two elevations, the mandibular and maxillary prominences. The mandibular prominence forms the lower jaw or mandible, and the maxillary prominence forms the maxilla, zygoma, and squamous portion of the temporal bone. Mandibular hypoplasia is believed to result from insufficient migration of cranial neural crest cells into the first branchial arch during the 4th week.<sup>2</sup>

Congenital mandibular hypoplasia most often results in a bilateral deformity, even though the primary abnormality may be unilateral. Compensatory growth changes on the unaffected side are the cause of this bilateralism. The degree of hypoplasia is quite variable and, when severe, can lead to significant functional issues at birth. With severe mandibular hypoplasia, obstruction at the hypopharynx occurs because of the retroposition of the base of the tongue into the posterior pharyngeal airway. Some of these patients can have the condition managed by prone positioning, with the anticipation of mandibular growth. However, for some the condition is not treatable with positioning; these patients experience persistent airway obstruction with frequent hypoxic episodes and resultant poor feeding. They patients require endotracheal intubation or tracheotomy.<sup>3</sup> In addition to respiratory concerns, these patients have failure to thrive because of their inability to feed. They often require gastric tube feedings. As the patient grows and develops dentition, occlusal discrepancies result in dietary limitations and create obstacles to good dental hygiene.<sup>4</sup> Speech development, specifically articulation, may be affected secondary to mandibular size and occlusal discrepancies.<sup>5</sup>

Most patients with congenital mandibular hypoplasia have associated syndromes. More than 60 syndromes having mandibular hypoplasia as a compo-

nent have been described. The most common is oculo-auriculo-vertebral (OAV) spectrum, which includes hemifacial and bifacial microsomia. The next most common is the mandibulofacial dysostosis group or Treacher Collins' syndrome.<sup>6-9</sup> Patients with hemifacial microsomia and those with Treacher Collins' syndrome have been well studied, with numerous publications addressing the presentation and treatment of these patients.<sup>10-13</sup> Distinct from this group are the patients with nonsyndromic malformations of the mandible. There have been no publications defining these patients, so the purpose of this study is to analyze and classify this subgroup and to determine incidence, clinical presentation, and treatment.

## METHODS

A retrospective analysis of all patients with planned surgical treatment of congenital mandibular hypoplasia at the Children's Hospital of Philadelphia between 1975 and 2003 was performed. Charts were reviewed for birth history, clinical presentation, etiology, and genetic diagnosis. From this group, the data of patients with nonsyndromic mandibular hypoplasia were extracted. For this subgroup, the following additional information was obtained from clinic notes and radiographic studies: respiratory and feeding problems at birth, duration of tracheotomy and tube feedings, severity and symmetry of hypoplasia, and operative management.

## RESULTS

The investigation revealed 266 patients with congenital mandibular hypoplasia. One hundred forty-eight presented with OAV spectrum, 52 with Treacher Collins' syndrome, 31 with Pierre Robin sequence, 17 with miscellaneous syndromes, and 18 were identified as having congenital mandibular hypoplasia without any known syndrome. This accounts for 6.8% of all patients with congenital mandibular hypoplasia.

The age range at presentation for these 18 patients was 1 week to 12 years, some having presented late because of prior treatment elsewhere. Seven patients were products of a complicated pregnancy, such as preterm labor, polyhydramnios, and spontaneous rupture of membranes. There was no known family history of craniofacial or other anomalies. Six patients underwent tracheotomy at birth or shortly thereafter for respiratory difficulties. Two patients underwent tracheotomy intraoperatively during mandibular procedures because of the inability to

intubate. Two patients were born premature and required prolonged intubation of 4 to 6 weeks. Seven patients were fed with gastric tube, with the feedings continuing until after the first mandibular lengthening procedure.

Associated anomalies included temporomandibular joint (TMJ) ankylosis in five patients, aglossia/microglossia in three patients, and rare craniofacial clefts in three patients. The remaining eight patients had isolated mandibular hypoplasia. All patients had bilateral involvement, which was symmetrical in 18 of the 19 patients. One had unilateral TMJ ankylosis and a more severe hypoplasia on that side.

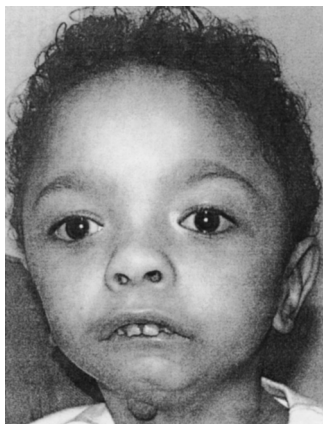
All patients have had or will require mandibular lengthening. The average number of procedures for each patient treated to date was six, with a range of 1 to 13. Four patients are planned for surgical intervention. Patients with TMJ ankylosis had the highest average number of procedures at 7.6. Surgical procedures included: distraction  $\pm$  bone grafting; osteotomies, advancements, and bone grafting; costochondral reconstruction of the mandible; TMJ arthroplasties; and coronoidectomies.

The following case reports illustrate the variable nature and progression of the deformity requiring multiple procedures through the period of growth.

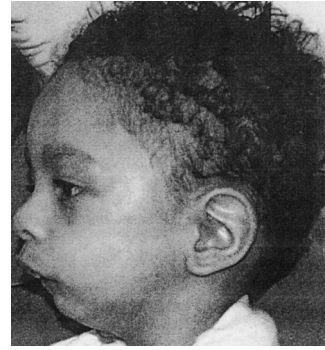
### Case Reports of Patients With Nonsyndromic Congenital Mandibular Hypoplasia

#### *Case 1: Isolated Mandibular Hypoplasia*

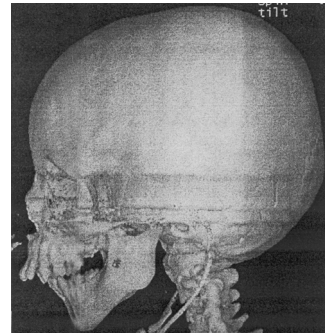
JS is a 2-year-old boy who was born with severe micrognathia requiring gastric tube feeding since birth (Figs 1–11). Photographs and computed tomog-



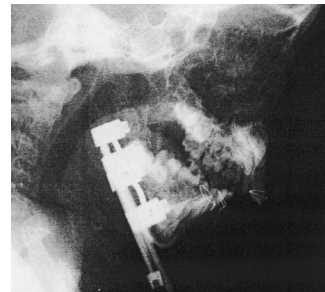
**Fig 1** Two-year-old boy with isolated mandibular hypoplasia.



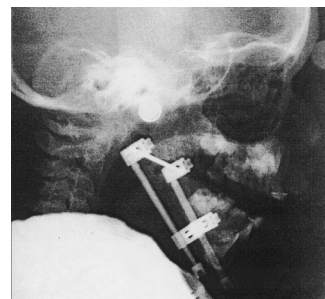
**Fig 2** Two-year-old boy with isolated mandibular hypoplasia.



**Fig 3** Three-dimensional CT scan demonstrating the normal, but diminutive, mandible.

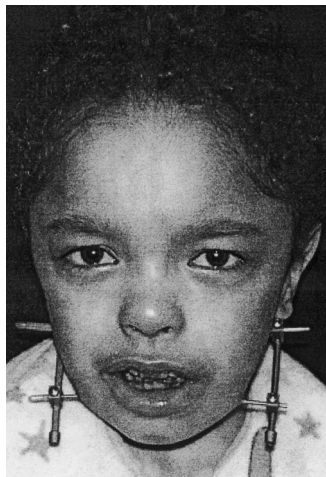


**Fig 4** Immediate postoperative cephalogram of bilateral external distractor placement.

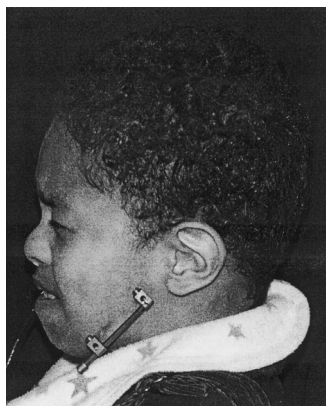


**Fig 5** Cephalogram after completion of distraction, during the consolidation phase, illustrating the degree of advancement.

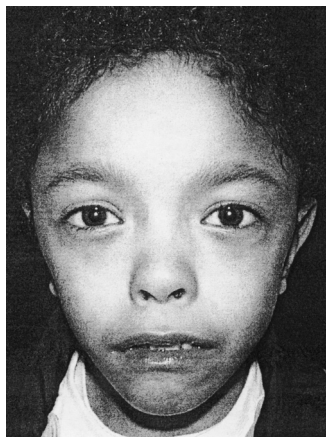




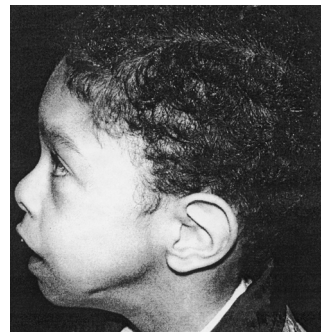**Fig 6** AP photo during the consolidation phase.



**Fig 7** Lateral photo during the consolidation phase.



**Fig 8** AP photo after distraction.

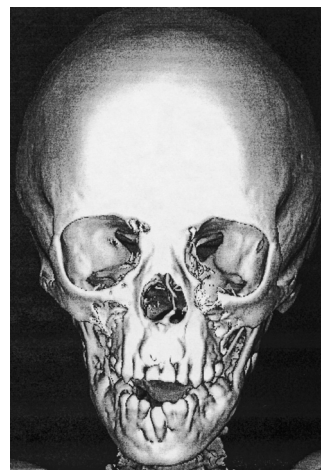


**Fig 9** Lateral photo after distraction.

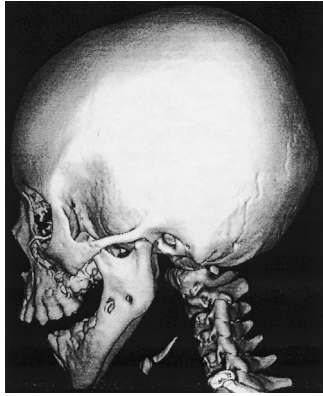
raphy (CT) scans illustrate the severe micrognathia, demonstrating a normal, but diminutive, mandible. The patient underwent bilateral external mandibular distraction at age 3 years. Cephalograms demonstrate immediate postoperative distractor placement and during consolidation. Postoperative correction of the deformity is seen in photographs and CT scans. Oral intake has been resumed.

#### Case 2: TMJ Ankylosis

LW is a 2-year-old girl who presented with facial asymmetry noted at age 5 months (Figs 12–15). Photographs at age 2 years and then 4 years show the progression of the deformity. X-rays (not shown) at 4 years of age revealed a left TMJ ankylosis. The patient was lost to follow-up and presented again at age 12 years without any surgical or orthodontic intervention, demonstrating significant retrognathia and asymmetry.



**Fig 10** Postoperative AP and lateral three-dimensional CT illustrating mandibular advancement.



**Fig 11** Postoperative lateral three-dimensional CT illustrating mandibular advancement.

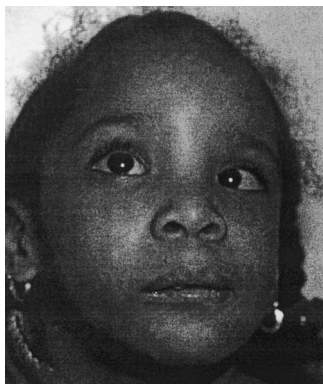
### Case 3: Aglossia/Microglossia

RK is a boy with mandibular hypoplasia and aglossia who required tracheotomy at birth (Figs 16–28). Photos and lateral cephalograms at age 2.5 years demonstrate severe micrognathia. He underwent 17-mm advancement with iliac bone grafting at 3 years of age.


Three years later, at age 5 years, he had progressive micrognathia. He then underwent external distraction. After distraction at age 7 years, he had good lower facial proportions. Just 1 year later, he had significant, recurrent micrognathia, illustrating the progressive nature of this deformity. He underwent distraction at age 12 years, completing three lengthening procedures in 10 years, again demonstrating the need for repeat procedures.

### Case 4: Rare Craniofacial Clefts

GC is a 3-year-old boy with bilateral Tessier 7 clefts, cleft palate, and mandibular hypoplasia (Figs 29–30).



**Fig 12** A 2-year-old girl with mild lower facial asymmetry.



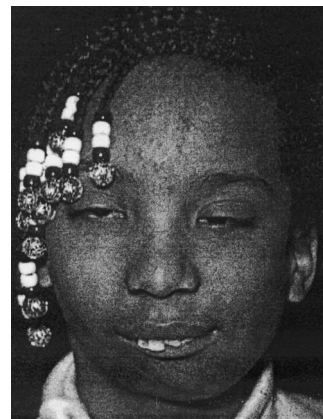
**Fig 13** Patient at age 4 years, illustrating progressive lower facial asymmetry secondary to a left congenital TMJ ankylosis (demonstrated on x-ray not shown).

Preoperative photographs illustrate the pronounced micrognathia.


### DISCUSSION

In reviewing the patients with mandibular hypoplasia, an algorithm evolved by which to classify these patients. This algorithm assists in understanding the pathology and treatment of congenital mandibular hypoplasia (Fig 31). Mandibular hypoplasia can be first categorized as congenital, developmental, or acquired. The focus of this study, the patients with congenital mandibular hypoplasia, can be viewed as having either deformational or malformational hypoplasia.

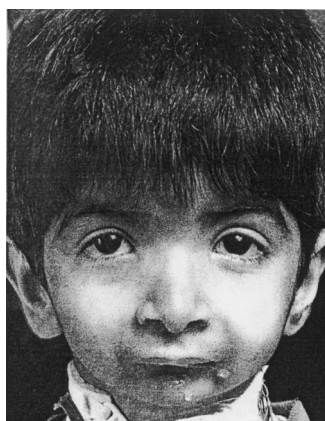
Deformational hypoplasia is one in which extrinsic forces cause the resultant difference. These patients can have syndromic or nonsyndromic man-



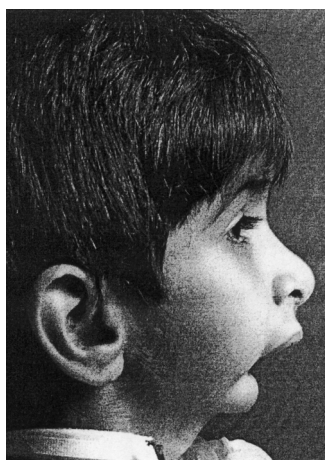
**Fig 14** Patient at age 12 years, having received no orthodontic or surgical intervention. This demonstrates the natural course of this deformity.



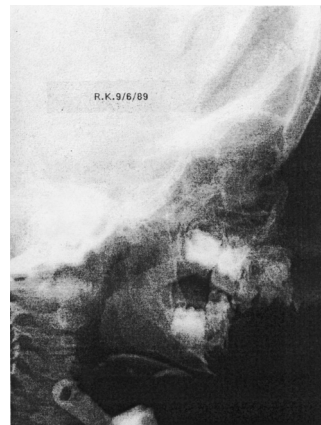
**Fig 15** Lateral photo of patient at age 12 years.



**Fig 16** A 2.5-year-old boy with aglossia and micrognathia, who underwent tracheostomy at birth for airway compromise.



**Fig 17** A 2.5-year-old boy with aglossia and micrognathia, who underwent tracheostomy at birth for airway compromise.



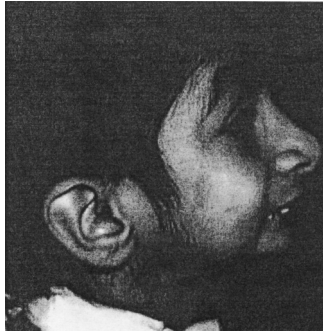**Fig 18** Lateral cephalogram of 2.5-year-old boy, showing the severe micrognathia. The patient underwent a 17-mm advancement with iliac bone grafts bilaterally.

dibular hypoplasia and include, but are not limited to, those with torticollis, intrauterine constraint, and Pierre Robin sequence, which is the most commonly seen form. Pierre Robin (PR) sequence includes micrognathia, glossoptosis, and airway obstruction with or without cleft palate.<sup>14</sup> Patients with deformational hypoplasia have mandibular growth potential once the deforming forces have been removed; however, controversy remains as to whether the most patients with PR achieve mandibular growth to normal facial proportions.<sup>15-17</sup>

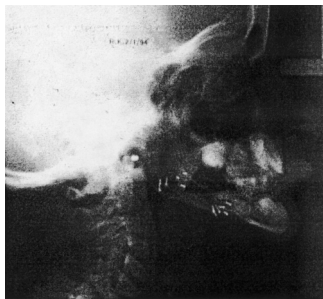
The other category, malformational hypoplasia, is one in which an intrinsic growth disturbance or anomaly exists, whether it is genetically identifiable or not. These patients can also be classified having syndromic or nonsyndromic mandibular hypoplasia. Most patients with malformational mandibular hypoplasia have syndromes such as OAV spectrum and mandibulofacial dysostosis. Gorlin has identified more than 60 syndromes with mandibular hypoplasia as a component. After exclusion of all the malformational mandibular hypoplasia syndromes, a subset of patients emerged, who are by definition patients with nonsyndromic, malformational mandibular hypoplasia.

We have excluded patients with PR, although some authors have proposed that PR sequence occasionally may be malformational in origin.<sup>15,17</sup> When we reviewed the pathology and growth of the patients with nonsyndromic, malformational mandibular hypoplasia, four subgroups were evident based on associated anomalies: patients with TMJ ankylosis, those with aglossia/microglossia, those with rare craniofacial clefting, and those with isolated mandibular hypoplasia. Of these subgroups, the patients

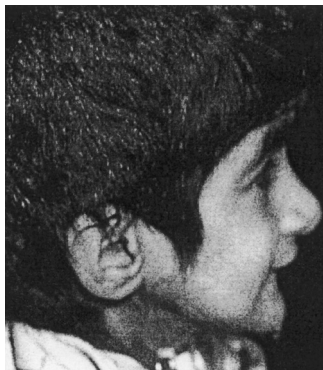



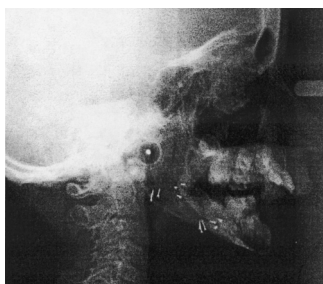
**Fig 19** Lateral photograph at age 5 years, showing progressive micrognathia. The patient underwent bilateral external mandibular distraction.



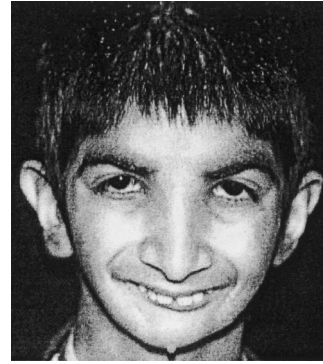
**Fig 20** Lateral cephalogram after distraction.



**Fig 21** Lateral photo after distraction.



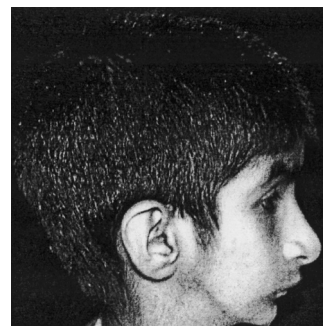
**Fig 22** Lateral cephalogram 1 year after distraction, demonstrating the progressive nature of this patient's micrognathia.



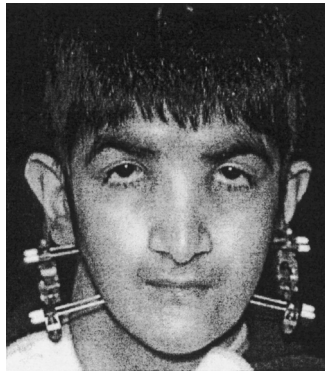
**Fig 23** AP photo at age 12 years, showing the need for repeat distraction.

with TMJ ankylosis, aglossia/microglossia, and rare craniofacial cleft had a more severe and progressive micrognathia. This may be understood by examining the postnatal growth of the mandible. The mandible grows by appositional bone growth and by the development of the alveolar process, which accompanies teeth development. The condyle is central in initiating growth of the mandible by endochondral ossification of the epiphysis. Bone deposition occurs at the condyle and along the posterior border of the ramus as bone resorption takes place along the anterior surface of the mandible. The forward and downward pressure of the tongue also contributes to the growth of the mandible.<sup>18</sup>

Although the most common cause of TMJ ankylosis is trauma, congenital TMJ ankylosis is also a known entity and is thought to originate from maldevelopment of the condyle in utero during the 4th to 5th week of gestation. Congenital TMJ ankylosis has not been associated with any syndrome.<sup>19</sup> The five patients with TMJ ankylosis who were included in the nonsyndromic congenital mandibular hypoplasia group had careful review of their birth



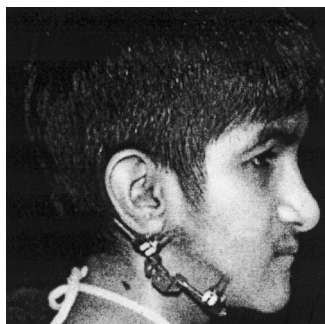
**Fig 24** Lateral photo at age 12 years, showing the need for repeat distraction.



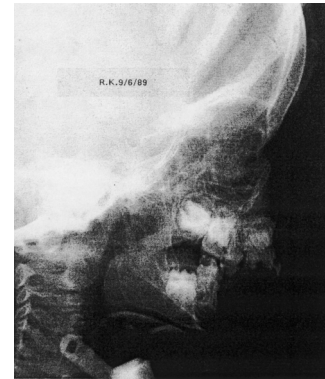
**Fig 25** AP photo with bilateral external distractors in place during the consolidation phase.

and trauma histories to exclude trauma as a cause of ankylosis. These five patients had more significant problems with feeding and dentition because of limited oral opening and required the greatest number of corrective procedures in the entire group. Early treatment is advocated in these patients to avoid consequent impairment of midface growth.<sup>20,21</sup>

Aglossia/microglossia characterizes another subgroup of patients with nonsyndromic, malformational mandibular hypoplasia. Of the 18 patients, 3 had associated aglossia/microglossia. One patient also had TMJ ankylosis. All three patients required tracheotomy at birth and gastric tube feedings through infancy and had more severe mandibular hypoplasia compared with the other subgroups. Some authors have included such patients with aglossia/microglossia within the oromandibular limb hypogenesis syndromes; however, controversy remains as to whether these patients should be included because there are no associated limb anomalies.<sup>8,9</sup> We have chosen to classify them as having nonsyndromic mandibular hypoplasia.



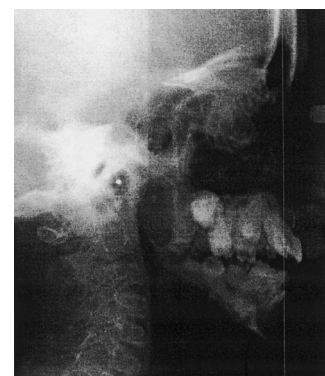**Fig 26** Lateral photo with bilateral external distractors in place during the consolidation phase.



**Fig 27** Initial lateral cephalogram at age 2.5 years.

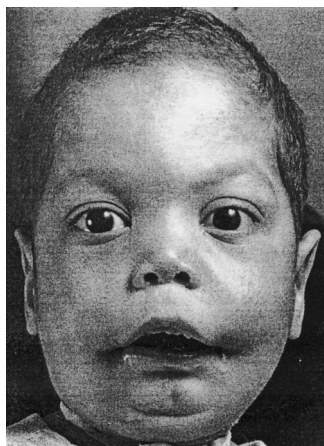
The third subgroup includes the patients with nonsyndromic rare craniofacial clefts (RCFC), in which the clefting process affects the mandible. Although in most patients with RCFC the mandible is not affected, the lateral and midline clefts may result in mandibular hypoplasia. The following types of clefts were encountered in the three patients: Tessier 3-11, bilateral 7, and bilateral 6. The clefting process affected soft tissue as well as mandibular growth to a severity requiring lengthening procedures.

The last subgroup, the patients with isolated mandibular hypoplasia, was the least severely affected. Two of the eight patients had prolonged intubations secondary to premature birth. Only two required tracheotomy, one at 13 months because of the inability to intubate for a procedure. The second patient who underwent tracheotomy had a tentative diagnosis of Pierre Robin sequence at birth because of the airway obstruction. However, this patient had

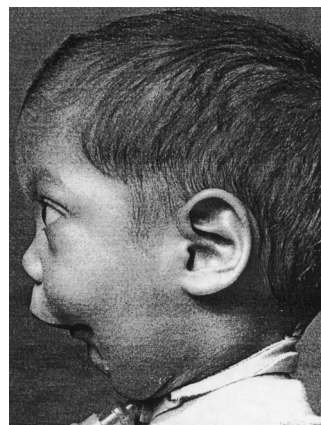


**Fig 28** Most recent cephalogram at age 13 years, after three mandibular lengthening procedures.





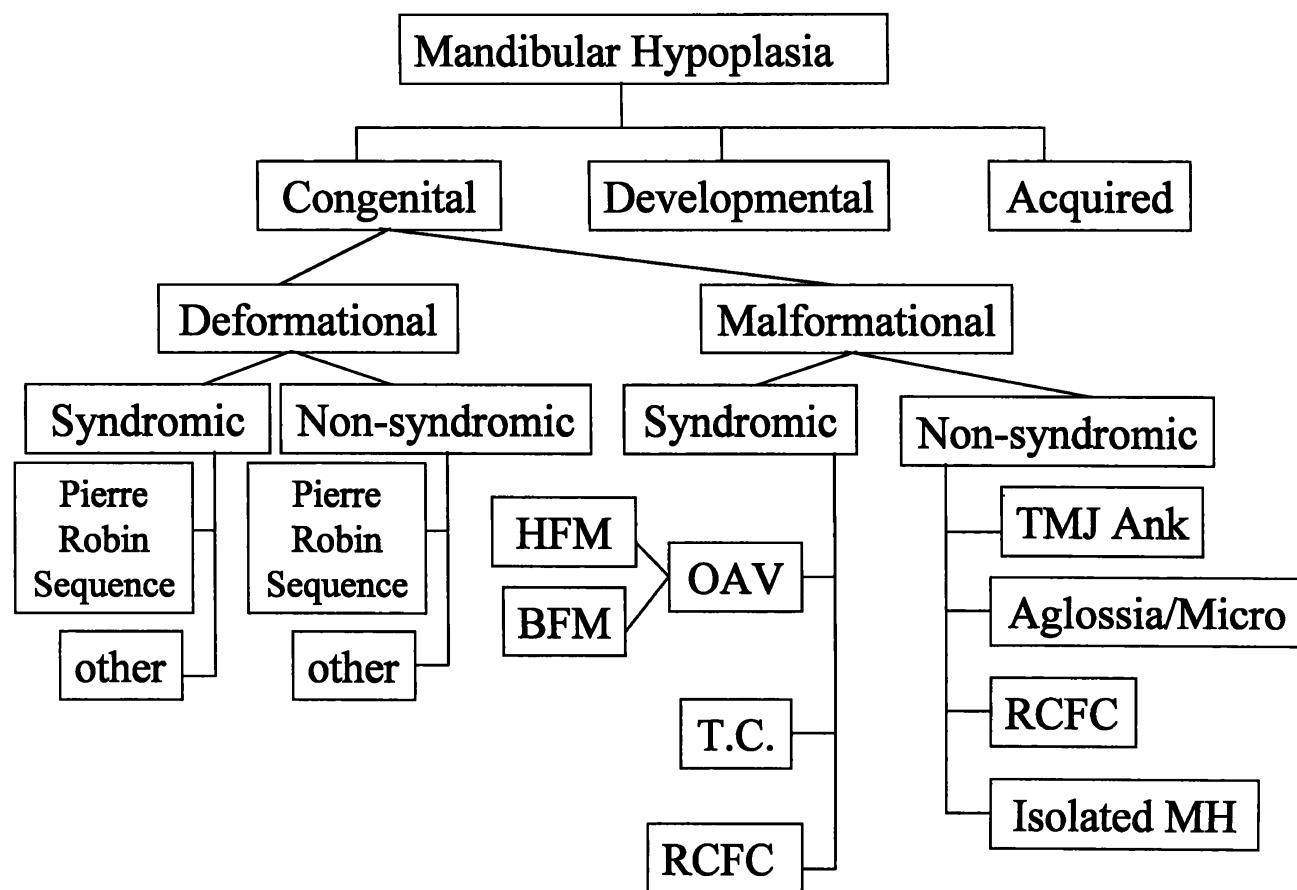
**Fig 29** A 3-year-old boy with bilateral Tessier 7 clefts, cleft palate, and mandibular hypoplasia.



**Fig 30** A 3-year-old boy with bilateral Tessier 7 clefts, cleft palate, and mandibular hypoplasia.

almost no mandibular growth and presented late at the age of 10 years with tracheotomy in place, having had no intervention. Because of this lack of mandibular growth, the diagnosis of Pierre Robin sequence

was incorrect. Patients with isolated mandibular hypoplasia often receive inaccurate diagnoses of Pierre Robin sequence at birth when the clinician notes the hypoplastic jaw.



**Fig 31** Algorithm illustrating a classification technique for mandibular hypoplasia.

The patients with nonsyndromic mandibular hypoplasia appear to have a progressive micrognathia/retrognathia requiring multiple procedures as they grow. This is in contrast to the patients with hemifacial/bifacial microsomia and Treacher Collins' syndrome, who appear to have a stable deformity, and those with Pierre Robin sequence, whose deformity tends to self-correct without intervention. This clinical observation is not quantifiable because of maxillary growth and the consequent inability to superimpose cephalograms.

## CONCLUSIONS

In conclusion, patients with congenital, malformational, nonsyndromic mandibular hypoplasia are a rare subgroup of all patients born with mandibular hypoplasia. As a whole, they tend to have an increased severity of mandibular deficiencies compared with those with syndromic disease, as evidenced by a higher incidence of significant airway compromise and feeding difficulties secondary to the hypoplastic mandible. In addition, they have a progressive retrognathia requiring repeat procedures. Within our nonsyndromic group, the patients with TMJ ankylosis, aglossia/microglossia, and rare craniofacial cleft were more severely affected than were those with isolated hypoplasia. Early recognition and treatment of these patients with nonsyndromic congenital mandibular hypoplasia can lessen the magnitude and number of procedures required for addressing respiratory, feeding, and growth complications.

## REFERENCES

1. McCarthy JG, Kawamoto H, Grayson BH, et al. Surgery of the Jaws. In McCarthy (ed). Plastic Surgery. Philadelphia: WB Saunders, Harcourt Brace Jovanovich, Inc, 1990:1188-1474
2. Moore KL. The Branchi Apparati and the Head and Neck. In The Developing Human. Philadelphia: WB Saunders, Harcourt Brace Jovanovich, Inc, 1988
3. Morovic CG, Monasterio L. Distraction osteogenesis for obstructive apneas in patients with congenital craniofacial malformations. *Plast Reconstr Surg* 2000;105:2324
4. Posnick JC, Goldstein JA. Surgical management of temporomandibular joint ankylosis in the pediatric population. *Plast Reconstr Surg* 1993;91:791
5. Ruscillo DM, Tekieli ME, Van Sickels JE. Speech production before and after orthognathic surgery: a review. *Oral Surg Oral Med Oral Pathol* 1985;59(1):10-14
6. Gorlin RJ. Syndromes associated with jaw deformity. Symposium on reconstruction of jaw deformity. Volume 16. Educational Foundation of the American Society of Plastic and Reconstructive Surgeons
7. Abramson DL, Cohen M, Mulliken JB. Mobius syndrome: classification and grading system. *Plast Reconstr Surg* 1998;102:961
8. Yamada A, Konno N, Imai Y, et al. Treatment of hypoglossia-hypodactyly syndrome without extremity anomalies. *Plast Reconstr Surg* 2000;106:274
9. Chicarilli Z, Polayes I. Oromandibular limb hypogenesis syndromes. *Plast Reconstr Surg* 1985;76:13
10. Stelnicki EJ, Lin W, Lee C, et al. Long-term outcome study of bilateral mandibular distraction: a comparison of Treacher Collins and Nager syndromes to other types of micrognathia. *Plast Reconstr Surg* 2002;109:1819
11. Kamata S, Satoh K, Uemura T, Onizuka T. Congenital bilateral zygomatico-mandibular fusion with mandibular hypoplasia. *Br J Plast Surg* 1996;49:251
12. Pruzansky S. Not all dwarfed mandibles are alike. *Birth Defects* 1969;5:120
13. Cousley RR, Calvert ML. Current concepts in the understanding and management of hemifacial microsomia. *Br J Plast Surg* 1997;50(7):536-551
14. Shprintzen RJ. The implications of the diagnosis of Robin sequence. *Cleft Palate Craniofac J* 1992;29:205
15. Daskalogiannakis J, Ross RB, Thompson BD. The mandibular catch-up growth controversy in Pierre Robin sequence. *Am J Orthod Dentofacial Orthop* 2001;120:280
16. Laitinen SH, Ranta RE. Cephalometric measurements in patients with Pierre Robin syndrome and isolated cleft palate. *Scand J Plast Reconstr Hand Surg* 1992;26:177
17. Figueroa AA, Glupker TJ, Fitz MG, BeGole EA. Mandible, tongue, and airway in Pierre Robin sequence: a longitudinal cephalometric study. *Cleft Palate Craniofac J* 1991;28:425
18. Sperber GH. Craniofacial Development. London: BC Decker Inc., 2001
19. Bowerman J. Reconstruction of the temporomandibular joint for acquired deformity and congenital malformation. *Br J Oral Maxillofac Surg* 1987;25(2):149-160
20. Pensler JM, Christopher RD, Bewyer DC. Correction of micrognathia with ankylosis of the temporomandibular joint in childhood. *Plast Reconstr Surg* 1993;91:799
21. Dean A, Alamillos F. Mandibular distraction in temporomandibular joint ankylosis. *Plast Reconstr Surg* 1999;104:2021

## Heminasal Proboscis With Associated Microphthalmos and Encephalocele

Derek Kofi O. Boahene, MD,\* George B. Bartley, MD,†  
Ricky P. Clay, MD,‡ Dana M. Thompson, MD\*

Rochester, Minnesota

**Abstract:** Heminasal proboscis is a rare congenital malformation that presents complex management issues when associated with other craniofacial abnormalities. A newborn male, known to have a facial mass on prenatal ultrasonography, was delivered by planned induction at 37 weeks' gestation. He was intubated im-

From the \*Department of Otorhinolaryngology, the †Division of Plastic and Reconstructive Surgery, Mayo Clinic, Rochester, Minnesota, and the ‡Department of Ophthalmology, Mayo Clinic, Jacksonville, Florida.

Address reprint requests to Dana M. Thompson, MD, Department of Otorhinolaryngology, Mayo Clinic, 200 First Street SW, Rochester, MN 55905.

© 2004 Mayo Foundation for Medical Education and Research