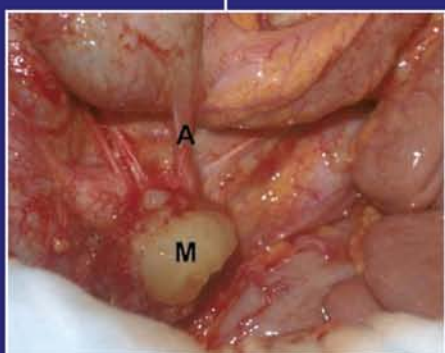
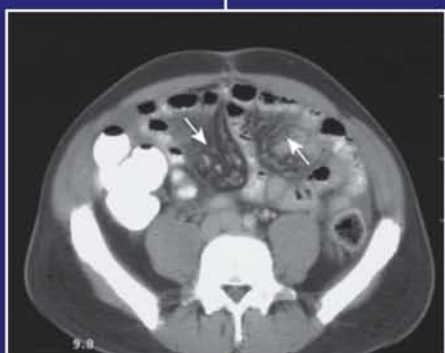
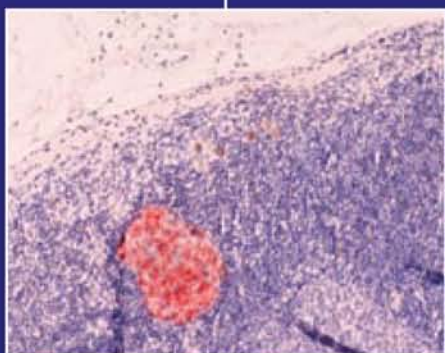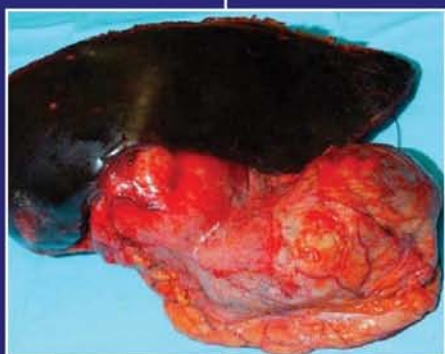# Textbook of Surgical Oncology

Edited by  
Graeme J Poston  
R Daniel Beauchamp  
Theo JM Ruers

# TEXTBOOK OF SURGICAL ONCOLOGY

Edited by

**Graeme J Poston** MB BS MS FRCS (Eng) FRCS (Ed)

Head of Division of Surgery  
University Hospital Aintree  
Liverpool  
UK

**R Daniel Beauchamp** MD

Section of Surgical Sciences  
Vanderbilt University Hospital  
Vanderbilt University Medical Center  
Nashville, TN  
USA

**Theo J M Ruers** MD PhD

Surgeon  
Department of Surgery  
The Netherlands Cancer Institute  
Antoni van Leeuwenhoek Hospital  
Amsterdam  
The Netherlands

**informa**  
healthcare

© 2007 Informa UK Ltd

First published in the United Kingdom in 2007 by Informa Healthcare, Telephone House, 69-77 Paul Street, London EC2A 4LQ. Informa Healthcare is a trading division of Informa UK Ltd. Registered Office: 37/41 Mortimer Street, London W1T 3JH. Registered in England and Wales number 1072954.

Tel: +44 (0)20 7017 5000

Fax: +44 (0)20 7017 6699

Website: [www.informahealthcare.com](http://www.informahealthcare.com)

All rights reserved. No part of this publication may be reproduced, stored in a retrieval system, or transmitted, in any form or by any means, electronic, mechanical, photocopying, recording, or otherwise, without the prior permission of the publisher or in accordance with the provisions of the Copyright, Designs and Patents Act 1988 or under the terms of any licence permitting limited copying issued by the Copyright Licensing Agency, 90 Tottenham Court Road, London W1P 0LP.

Although every effort has been made to ensure that all owners of copyright material have been acknowledged in this publication, we would be glad to acknowledge in subsequent reprints or editions any omissions brought to our attention.

Although every effort has been made to ensure that drug doses and other information are presented accurately in this publication, the ultimate responsibility rests with the prescribing physician. Neither the publishers nor the authors can be held responsible for errors or for any consequences arising from the use of information contained herein. For detailed prescribing information or instructions on the use of any product or procedure discussed herein, please consult the prescribing information or instructional material issued by the manufacturer.

A CIP record for this book is available from the British Library.

Library of Congress Cataloging-in-Publication Data

Data available on application

ISBN-10: 1 84184 625 2

ISBN-13: 978 1 84184 507 4

Distributed in North and South America by  
Taylor & Francis  
6000 Broken Sound Parkway, NW, (Suite 300)  
Boca Raton, FL 33487, USA

*Within Continental USA*

Tel: 1 (800) 272 7737; Fax: 1 (800) 374 3401

*Outside Continental USA*

Tel: (561) 994 0555; Fax: (561) 361 6018

Email: [orders@crcpress.com](mailto:orders@crcpress.com)

Distributed in the rest of the world by

Thomson Publishing Services

Cheriton House

North Way

Andover, Hampshire SP10 5BE, UK

Tel: +44 (0)1264 332424

Email: [tps.tandfsalesorder@thomson.com](mailto:tps.tandfsalesorder@thomson.com)

Composition by Exeter Premedia Services Private Ltd., Chennai, India

Printed and bound by Replica Press Pvt Ltd.

# Contents

---

List of contributors	vii
Preface	xiii
Acknowledgments	xv
Color plate	xvii

## SECTION I GENERAL PRINCIPLES

1. Is there a surgical oncology? <i>Graeme J Poston</i>	1
2. Principles of quality control in surgical oncology <i>Theo Wiggers</i>	5
3. Principles of adjuvant radiotherapy <i>Pooja Jain, Azeem Saleem and Pat Price</i>	11
4. Principles of chemotherapy <i>Emily Chan and Jordan D Berlin</i>	21
5. Designing clinical trials in surgical oncology: the importance of quality assurance <i>Marcel den Dulk, Elma Meershoek-Klein Kranenbarg and Cornelis J H van de Velde</i>	33
6. Palliative care in surgical oncology <i>Iain Lawrie and Mari Lloyd-Williams</i>	41
7. Communication and psychological needs of the cancer surgery patient <i>Clare Byrne and Graeme J Poston</i>	49

## SECTION II HEAD AND NECK

8. Oropharynx <i>J Matthew Conoyer and James L Netterville</i>	61
---	----



### SECTION III THORACIC

9. Lung and bronchus 77  
*Joe B Putnam*
10. Esophagus 93  
*Joseph B Zwischenberger, Daina W Parker, Casey M Smólarz, Kristin Kucera, and Brent C Parker*

### SECTION IV BREAST

11. Screen-detected breast cancer 105  
*Emiel J T Rutgers*
12. Symptomatic breast cancer 113  
*Megan Baker Ruppel and David J Cole*
13. Oncoplastic surgery for breast cancer 127  
*Judy C Boughey, Kelly K Hunt and Elisabeth K Beahm*

### SECTION V GASTROENTEROLOGY

14. Gastric cancer 147  
*David J Joyce and Peter McCulloch*
15. Small bowel and appendiceal tumors 157  
*Sarah T O'Dwyer*
16. Cancer of the colon, rectum and anus 165  
*Nipun B Merchant, Alexander A Parikh, Carl R Schmidt and R Daniel Beauchamp*
17. Pancreatic cancer and ampullary carcinoma 189  
*Dirk J Gouma, W L Vervenne and O R C Busch*
18. Hepatocellular carcinoma 205  
*Dario Ribero, Eddie K Abdalla and Jean-Nicolas Vauthey*
19. Carcinoma of the biliary tree and gallbladder 217  
*George Miller and William R Jarnagin*
20. Liver metastases 239  
*Theo JM Ruers*

### SECTION VI UROLOGY

21. Kidney renal cell carcinoma 249  
*Melissa R Kaufman, Michael S Cookson and Sam S Chang*
22. Urothelial carcinoma of the bladder and upper tracts 259  
*William T Lowrance, Sam S Chang and Michael S Cookson*
23. Prostate cancer 271  
*Philip A Cornford and Daniel M Burke*
24. Testicular tumors 287  
*Mark Fordham and Peter Clark*

---

**SECTION VII GYNECOLOGY**

25. General principles of gynecological oncology for the general surgeon 295  
*Robert E Kingston*

**SECTION VIII SKIN**

26. Squamous cell carcinoma and basal cell carcinoma of the skin 303  
*JJ Bonenkamp*
27. Melanoma 311  
*Charles R Scoggins and Kelly M McMasters*

**SECTION IX ENDOCRINE**

28. Adrenal tumors 327  
*Barney Harrison and Sabapathy P Balasubramanian*
29. Thyroid cancer 339  
*Douglas Fraker*
30. Parathyroid carcinoma/malignancy 353  
*Alison Waghorn*
31. Neuroendocrine tumors of the gastrointestinal tract 363  
*Menno R Vriens and Inne H M Borel Rinkes*

**SECTION X SARCOMA**

32. Soft tissue sarcoma 369  
*Andrew J Hayes and Isaac M Cranshaw*
33. Skeletal malignancies 379  
*Ginger E Holt and Herbert S Schwartz*

**SECTION XI BRAIN TUMORS**

34. Neurosurgical oncology: neoplasms of the brain and meninges 393  
*Charles B Stevenson and Reid C Thompson*

- Index 411



# Contributors

---

**Eddie K Abdalla**

Division of Hepatobiliary Surgery  
M D Anderson Cancer Center  
Houston, TX  
USA

**Megan Baker Ruppel MD**

Department of Surgery  
Medical University of South Carolina  
Charleston, SC  
USA

**Sabapathy P Balasubramanian MBBS MS FRCSEd**

Academic Unit of Surgical Oncology  
University of Sheffield  
Sheffield  
UK

**Elisabeth K Beahm MD FACS**

Professor, Departments of Surgical Oncology and  
Plastic and Reconstructive Surgery  
The University of Texas  
MD Anderson Center  
Houston, TX  
USA

**R Daniel Beauchamp MD**

Section of Surgical Sciences  
Vanderbilt University Hospital  
Vanderbilt University Medical Center  
Nashville, TN  
USA

**Jordan D Berlin MD**

Vanderbilt-Ingram Cancer Center  
Nashville, TN  
USA

**J J Bonenkamp MD PhD**

Radboud University Medical Centre  
Department of Surgery  
Nijmegen  
The Netherlands

**Inne H M Borel Rinkes MD PhD**

Department of Surgery  
University Medical Center  
Utrecht  
The Netherlands

**Judy C Boughey MD**

Department of Surgery  
The Mayo Clinic  
Rochester, MN  
USA

**Daniel M Burke MB BS FRCS (Urol)**

Royal Liverpool and Broadgreen University Hospital  
Liverpool  
UK

**O R C Busch**

Department of Surgery  
Department of Medical Oncology  
Academic Medical Centre from the  
University of Amsterdam  
Amsterdam  
The Netherlands.

**Clare Byrne MSc RN**

Liverpool Supra-Regional Hepatobiliary Unit  
University Hospital Aintree  
Liverpool  
UK

**Emily Chan MD PhD**  
Vanderbilt-Ingram Cancer Center  
Nashville, TN  
USA

**Sam S Chang MD**  
Vanderbilt University Medical Center  
Nashville, TN  
USA

**Peter Clark MA MD FRCP**  
Clatterbridge Centre for Oncology  
Liverpool  
UK

**David J Cole MD**  
Department of Surgery  
Medical University of South Carolina  
Charleston SC  
USA

**J Matthew Conoyer MD PhD**  
Department of Otolaryngology  
Vanderbilt University Medical Center  
Nashville, TN  
USA

**Michael S Cookson MD**  
Department of Urologic Surgery  
Vanderbilt University Medical Center  
Nashville, TN  
USA

**Philip A Cornford BSc(hons) MB BS(hons)**  
FRCS (Urol) MD FEBU  
Department of Urology  
Royal Liverpool University Hospital  
Prescot Street  
Liverpool  
UK

**Isaac M Cranshaw MBChB FRACS**  
Surgical Oncology  
Royal Marsden Hospital  
London  
UK

**Marcel den Dulk MD**  
Department of Surgery  
Leiden University Medical Center  
Leiden  
The Netherlands

**Mark Fordham FRCS**  
Royal Liverpool University Hospital  
Liverpool  
UK

**Douglas Fraker MD**  
Department of Surgery  
Hospital of the University of Pennsylvania  
Philadelphia  
Pennsylvania  
USA

**Dirk J Gouma MD**  
Professor and Chairman of the Department of Surgery  
Academic Medical Center, University of Amsterdam  
Amsterdam  
The Netherlands

**Andrew J Hayes PhD FRCS**  
Melanoma and Sarcoma Unit  
Royal Marsden NHS Foundation Trust  
London  
UK

**Barney Harrison MS FRCS**  
Royal Hallamshire Hospital  
Sheffield  
UK

**Ginger E Holt MD**  
Vanderbilt Orthopaedic Institute  
Nashville, TN  
USA

**Kelly K Hunt MD FACS**  
Department of Surgical Oncology  
University of Texas  
M D Anderson Cancer Center  
Houston, TX  
USA

**Pooja Jain MRCP FRCR**  
Academic Department of Radiation Oncology  
Christie Hospital NHS Trust  
Withington  
Manchester  
UK

**William R Jarnagin MD FACS**  
Department of Surgery  
Memorial Sloan-Kettering Cancer Center  
New York, NY  
USA

**David J Joyce MD**  
Resident in Surgery  
Baltimore, MD  
USA

**Melissa R Kaufman MD PhD**  
Department of Urologic Surgery  
Vanderbilt University  
Nashville, TN  
USA

**Robert E Kingston BSc MBChB FRCS(Eng) FRCOG**  
Department of Gynecological Oncology  
Liverpool Women's Hospital  
Liverpool  
UK

**Kristin Kucera BS**  
University of Texas Medical Branch  
Galveston, TX  
USA

**Elma Meershoek-Klein Kranenbarg MSc**  
Department of Surgery  
Leiden University Medical Center  
Leiden  
The Netherlands

**Iain Lawrie MB ChB DipMedEd MRCGP**  
Palliative Medicine  
The Leeds Teaching Hospitals NHS Trust  
Leeds  
UK

**Mari Lloyd-Williams MD FRCP FRCGP M Med Sci ILTM**  
Palliative Medicine  
Academic Palliative and Supportive Care  
Studies Group (APSCSG)  
School of Population, Community and  
Behavioural Sciences  
University of Liverpool  
Liverpool  
UK

**William T Lowrance MD**  
Department of Urologic Surgery  
Vanderbilt University Medical Center  
Nashville, TN  
USA

**Peter McCulloch MD FRCSEd**  
Nuffield Department of Surgery  
University of Oxford  
The John Radcliffe Hospital  
Oxford  
UK

**Kelly M McMasters MD PhD**  
Department of Surgery  
University of Louisville  
Louisville, KY  
USA

**Nipun B Merchant MD**  
Division of Surgical Oncology  
Vanderbilt University Medical Center  
Nashville, TN  
USA

**George Miller MD**  
Department of Surgery  
Memorial Sloan-Kettering Cancer Center  
New York NY  
USA

**James L Netterville MD**  
Department of Otolaryngology  
Vanderbilt University Medical Center  
Nashville, TN  
USA

**Sarah T O'Dwyer**  
Christie Hospital NHS Trust  
Manchester  
UK

**Alexander A Parikh MD**  
Department of Surgery  
Division of Surgical Oncology  
Vanderbilt University Medical Center  
Nashville, TN  
USA

**Brent C Parker PhD**  
Radiation Oncology  
University of Texas Medical Branch  
Galveston, TX  
USA

**Daina W Parker BS**  
University of Texas Medical Branch  
Galveston, TX  
USA

**Graeme J Poston MB BS MS FRCS(Eng) FRCS(Ed)**  
Head of Division of Surgery  
University Hospital Aintree  
Liverpool  
UK

**Pat Price** MA MD FRCP FRCR  
Department of Radiation Oncology  
Christie Hospital NHS Trust  
Manchester  
UK

**Joe B Putnam Jr** MD  
Department of Thoracic Surgery  
The Vanderbilt clinic  
Nashville, TN  
USA

**Dario Ribero** MD  
Department of Surgical Oncology  
University of Texas  
M D Anderson Cancer Center  
Houston, TX  
USA

**Theo J M Ruers** MD PhD  
Surgeon  
Department of Surgery  
The Netherlands Cancer Institute  
Antoni van Leeuwenhoek Hospital  
Amsterdam  
The Netherlands

**Emiel J T Rutgers** MD PhD FRCS (Eng) FRCS Glasgow)  
Department of Surgical Oncology  
Netherlands Cancer Institute  
Amsterdam  
The Netherlands

**Azeem Saleem** MB BS DMRT PhD FRCR  
University of Manchester Wolfson Molecular  
Imaging Centre  
Manchester And Clinical Oncology  
Christie Hospital NHS Trust  
Manchester  
UK

**Carl R Schmidt** MD  
General Surgery  
Vanderbilt University Medical Center  
Nashville, TN  
USA

**Herbert S Schwartz** MD  
Vanderbilt Orthopaedic Institute  
Nashville, TN  
USA

**Charles R Scoggins** MD  
Division of Surgical Oncology  
University of Louisville  
Louisville, KY  
USA

**Casey M Smolarz** BA  
University of Texas Medical Branch  
Galveston, TX  
USA

**Charles B Stevenson** MD  
Department of Neurological Surgery  
Vanderbilt University Medical Center  
Nashville, TN  
USA

**Reid C Thompson** MD  
Department of Neurological Surgery  
Vanderbilt University Medical Center  
Nashville  
USA

**Cornelis J H van de Velde** MD PhD  
FRCS (London) FRCPs (Glasgow)  
Department of Surgery  
Leiden University Medical Center  
Leiden  
The Netherlands

**Jean-Nicholas Vauthey** MD  
Department of Surgical Oncology  
University of Texas  
M D Anderson Cancer Center  
Houston, TX  
USA

**W L Vervenne\***  
Department of Surgery  
Department of Medical Oncology\*  
Academic Medical Centre  
University of Amsterdam  
Amsterdam  
The Netherlands

**Menno R Vriens** MD PhD  
Department of Surgery  
University Medical Center Utrecht  
Utrecht  
The Netherlands

**Alison Waghorn** MB ChB FRCS MD  
Breast Assessment Unit  
Royal Liverpool University Hospital  
Liverpool  
UK

---

**Theo Wiggers MD PhD FRCS**  
Department of Surgery  
University Medical Center Groningen  
Groningen  
The Netherlands

**Joseph Zwischenberger MD**  
Division of CT Surgery  
University of Texas Medical Branch at Galveston  
Galveston, TX  
USA





# Preface

---

Cancer is increasingly the major cause of premature death worldwide, while surgery remains the principal therapeutic modality with the highest drate of cure (a position it has occupied since the dawn of modern medicine). Furthermore, surgeons are most frequently the gatekeepers of care for the majority of patients who develop solid malignant tumors. Surgeons play pivotal roles in diagnosis: in the clinic; at the bedside; performing endoscopies; and undertaking diagnostic surgical procedures. It is impossible to overestimate the role of radical surgical resection of the oncologic field in offering these patients the best hope of long-term survival and cure. As a result, even today, 60 per cent of those who are cured of cancer are cured by surgery alone. And surgery remains integral to the treatment of the vast majority of the remainder who require multi-modal therapy to achieve cure.

However, the modern surgical management of solid tumors is now multi-modal, yet residency training remains discipline based, often following historical anatomic-based crafts. Surgical oncology is not recognised in many countries as a distinct discipline in both training and practice (as say vascular or transplant surgery), nor are residents in the other oncologic disciplines (medical and radiation oncology) exposed to the principles of cancer surgery during the course of their training.

Therefore the purpose of this book is two fold. Firstly, to overview the field of surgical oncology for surgeons in training; covering the principles of surgical, radiation and medical oncology; the holistic approach to the surgical cancer patient; and the diagnostic, staging and treatment algorithms necessary to successfully manage these patients. Secondly, to provide a comprehensive source of reference to medical and radiation oncologists both in practice and in training, and other healthcare professionals intimately involved in the care of cancer patients (palliative care, primary care, cancer nursing and other therapists, as well as carers), for the role of surgery in both the curative and palliative management of their patients.

Lastly, we should never forget our patients. Those, facing the most awful of challenges, confronted by the enormity of their diagnosis, who then literally place their lives in the hands of the surgical oncologist. Their courage and hope is an everyday reminder to those of us who take on the enormous responsibility of managing their care. This book is dedicated to those, our patients.

Graeme J Poston  
R Daniel Beauchamp  
Theo JM Ruers



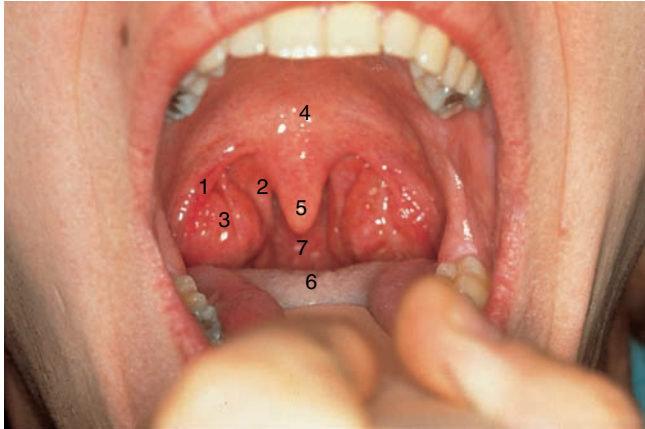
# Acknowledgments

---

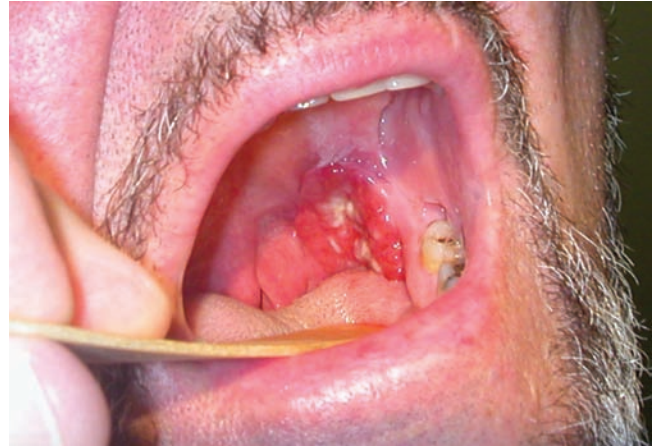The editors would like to thank the many members of the Informa Healthcare group who helped them to put this volume together. Philip Greenwood, who initiated the project, and Andrea Seils and Sherri Niozolek, who supervised the crucial final stages, deserve special mention. Our dedicated and hardworking PAs, Sue Boyt and Pat Pugliani, more than deserve equal billing for their

forebearance and organizational skills alone. Most of all we would like to thank the authors who willingly and (mostly) promptly produced high quality chapters for no material reward, despite the unfamiliarity to many of them of the constraints of the evidence-based approach we requested.

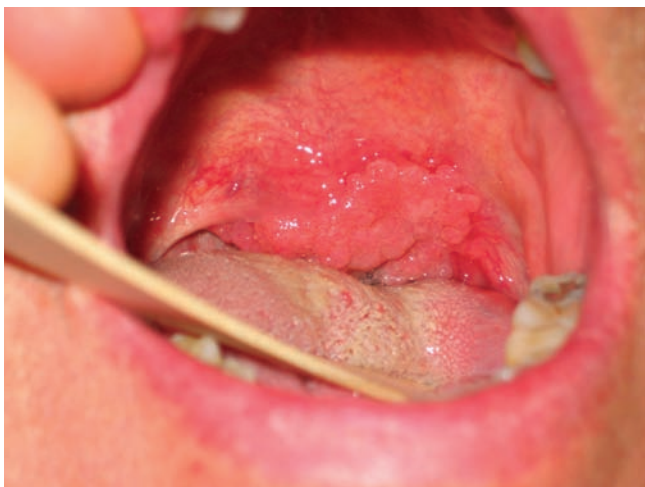



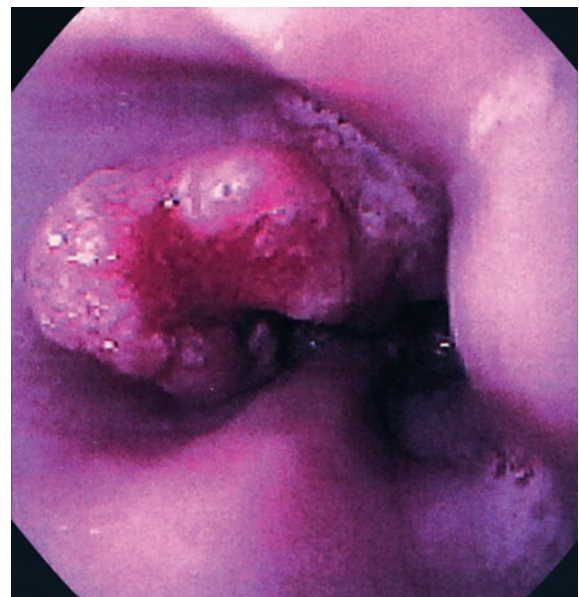**Figure 8.1** Transoral examination of the oropharynx: (1) anterior tonsillar pillar (palatoglossus), (2) posterior tonsillar pillar (palatopharyngeus), (3) palatine (faucial) tonsil within tonsillar fossa, (4) soft palate, (5) uvula, (6) dorsal surface of tongue, and (7) posterior pharyngeal wall. Reproduced from reference 16, with permission.



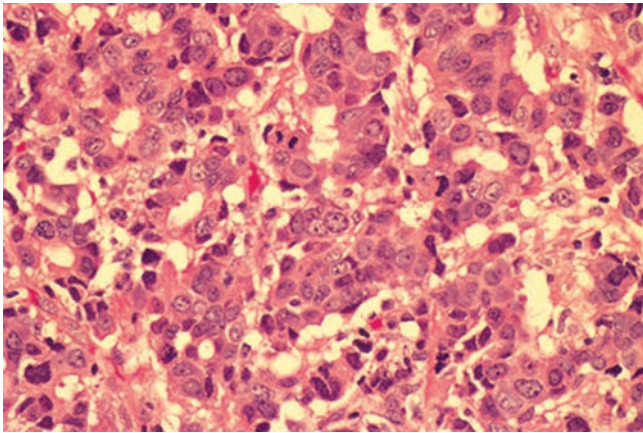
**Figure 8.3** Squamous cell carcinoma of the left tonsillar fossa. Courtesy of James L Netterville.



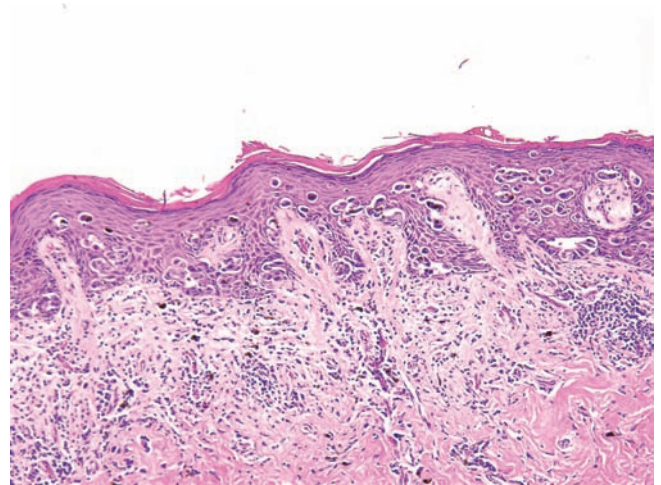
**Figure 8.4** Lymph node regions of the neck. Reproduced from reference 19, with permission.



**Figure 10.3** Adenocarcinoma of the esophagogastric junction. From reference 11, with permission.



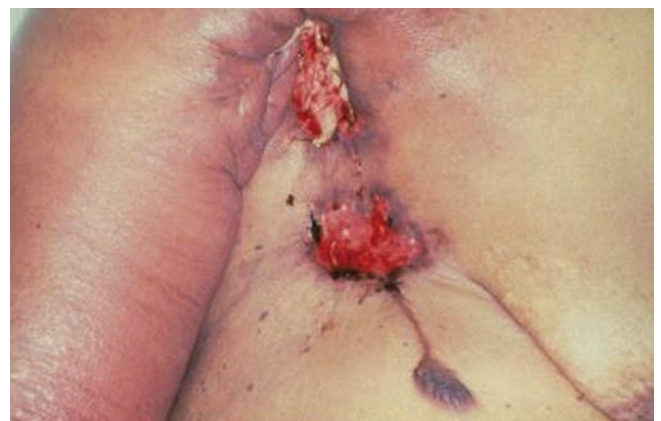**Figure 12.1** Invasive ductal carcinoma. Hematoxylin and eosin staining of breast biopsy sample demonstrating features consistent with invasive ductal breast cancer, Nottingham grade III. Histologically, breast cancer cells are larger than normal epithelium, and can assume a variety of patterns usually within a dense stroma with glandular formation, cords of cells, broad sheets of cells, or a mixture of all of these. Well differentiated tumors demonstrate glandular formation, whereas poorly differentiated tumors contain solid sheets of pleomorphic neoplastic cells. Courtesy of William Gillanders.



**Figure 12.2** Inflammatory breast cancer. Hematoxylin and eosin staining of an incisional breast biopsy specimen demonstrating typical dermal invasion seen in inflammatory breast cancer. Additional common pathological findings include infiltration of the subepidermal lymphatics and vessels by tumor cells. Courtesy of John Metcalf.

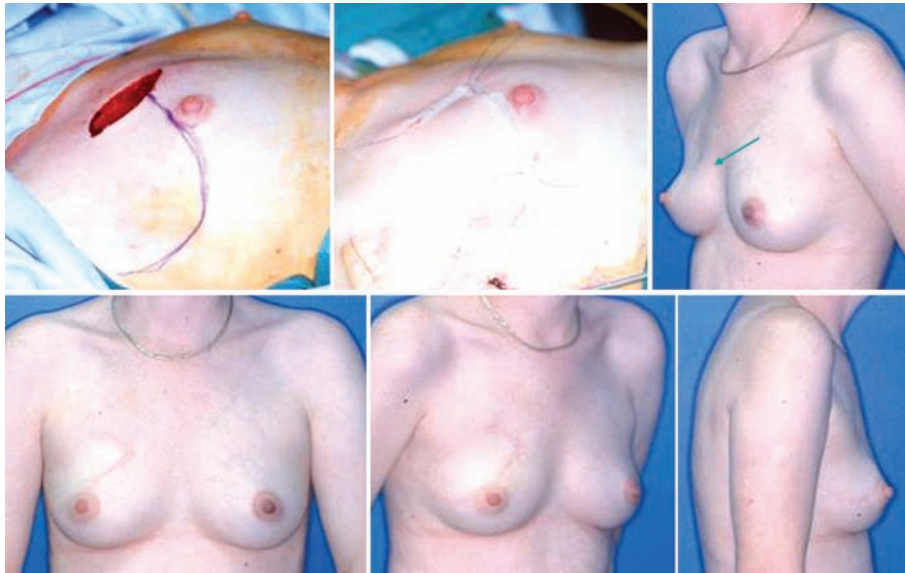


**Figure 12.5** Peau d' orange. Common presentation of dermal edema with evidence of skin pitting in patient with inflammatory breast cancer. Courtesy of Virginia Herrmann.

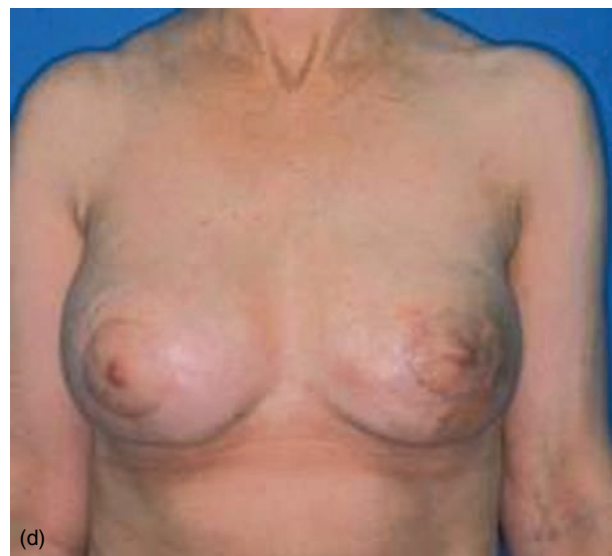
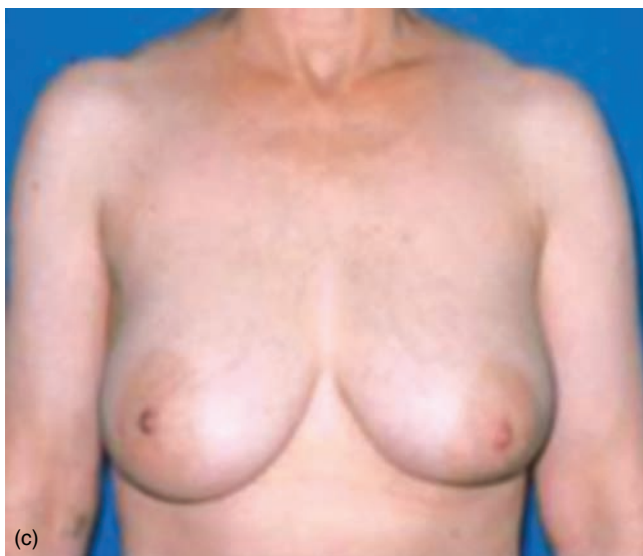
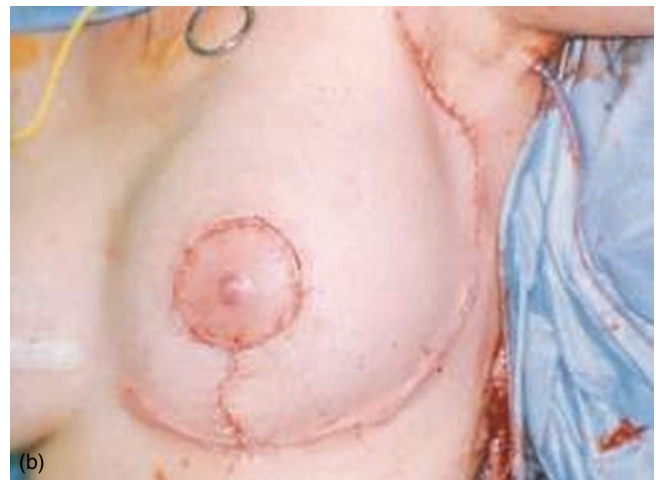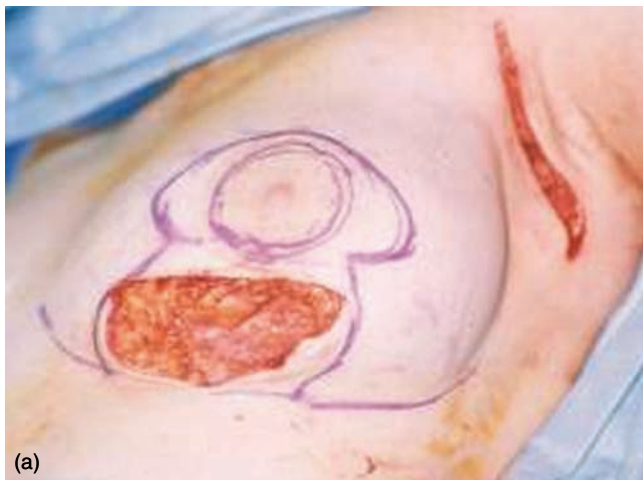**Figure 12.6** Local recurrence of breast cancer postmastectomy. Patient with evidence of disease recurrence within mastectomy scar.



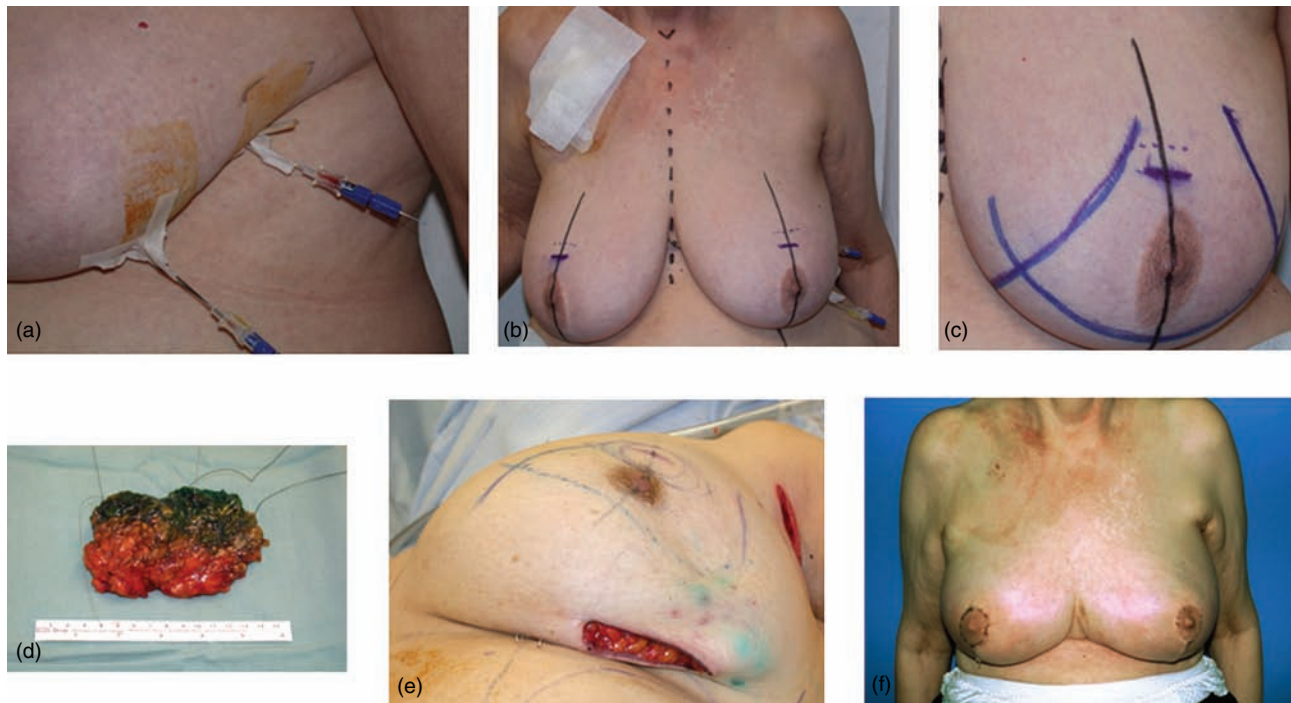


**Figure 13.6** Local tissue rearrangement. A 33-year-old woman 15 months after superior composite rotation flap. This technique should generally be limited to small volume defects. Note contour deformity overlying pectoralis muscle (arrow). Replacement of a skin resection in this location would result in a poorly color matched and highly visible 'patch'. Reproduced in part from reference 26, with permission.

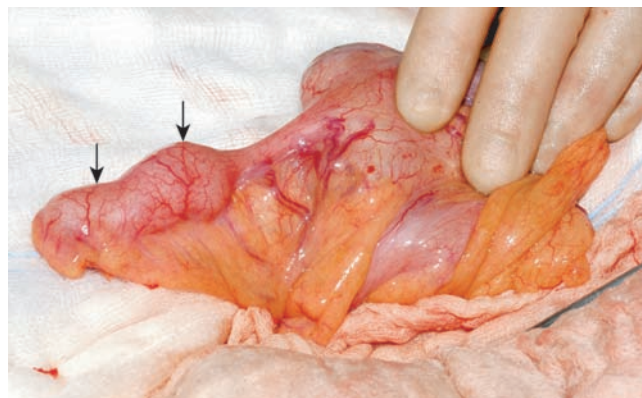


**Figure 13.9** Immediate reduction mammoplasty for reconstruction after partial mastectomy. (a) The patient had a small inferior defect after partial mastectomy, ideally suited to a reduction mammoplasty approach. (b) The defect was corrected with medial and lateral advancement of breast flaps on the index breast and a contralateral mastopexy. There was minimal volume change in the breasts and excellent symmetry of the breasts. (c) and (d) The patient's result is demonstrated 3 months postoperatively. Case figures reproduced from reference 26, with permission.

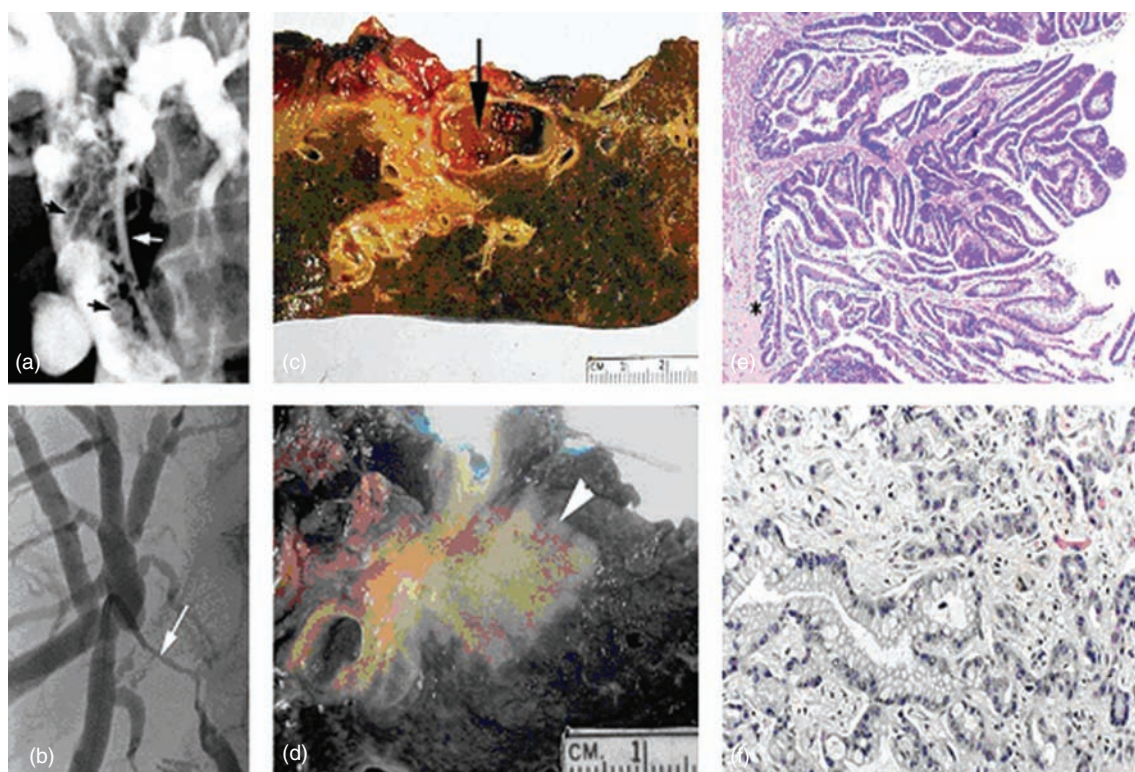




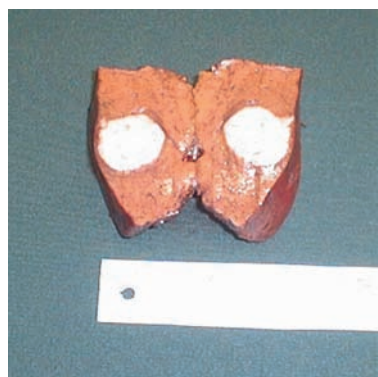**Figure 13.10** Immediate reduction mammoplasty for partial mastectomy. This patient underwent partial mastectomy for a lower outer quadrant tumor. A medially based breast flap and contralateral reduction mammoplasty for symmetry were employed for immediate reconstruction. This technique is well suited to patients with baseline macromastia who desire smaller breasts. (a) Preoperative needle localization bracketing the area to be resected. (b) and (c) Preoperative markings of critical breast landmarks, including the proposed new nipple point and paramedian line of the breast (where the inframammary fold intersects the nipple line) will help with ultimate symmetry of the two sides. (d) Extensive intraoperative processing of surgical margins is critical to the success of this approach, and the reconstructive 'reassembly' the breast is best deferred until all margins are confirmed. (e) A total of 256g of breast tissue was removed, resulting in a central and lateral deficit. (f) The patient had an uneventful postoperative course, with preservation of the nipple sensibility bilaterally. Early postoperative result 6 weeks after reduction mammoplasty utilizing a modified vertical reduction mammoplasty approach.



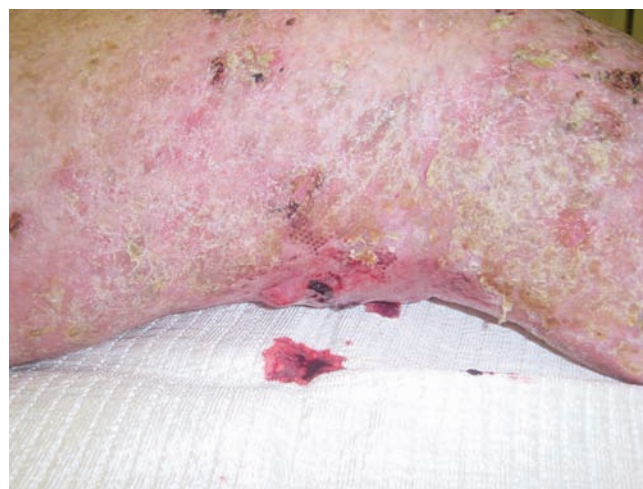**Figure 15.3** Macroscopic appearance of a distended swollen appendix containing tumor confined to the lumen.



**Figure 19.2** Cholangiographic, gross and microscopic appearance of a papillary cholangiocarcinoma (a) (c) and (e), and a nodular-sclerosing tumor (b) (d) and (f), respectively. Transhepatic cholangiogram of a papillary hilar cholangiocarcinoma (a) showing multiple filling defects that expand the bile duct (black arrows; the biliary drainage catheter is indicated by the white arrow). This is in contrast to the cholangiographic features of nodular-sclerosing tumors characterized by an irregular stricture that constricts the bile duct lumen (b) (arrow); a transhepatic catheter is seen traversing the stricture. On examination of the cut gross specimens, note the papillary tumor within the bile duct lumen (c) (arrow) and the nodular-sclerosing tumor invading the hepatic parenchyma (d) (arrowhead). A histological section of a papillary cholangiocarcinoma is shown with no invasive component (e) (asterisk) and an invasive nodular-sclerosing tumor associated with a desmoplastic stroma (f). From reference <sup>12</sup>, with permission.

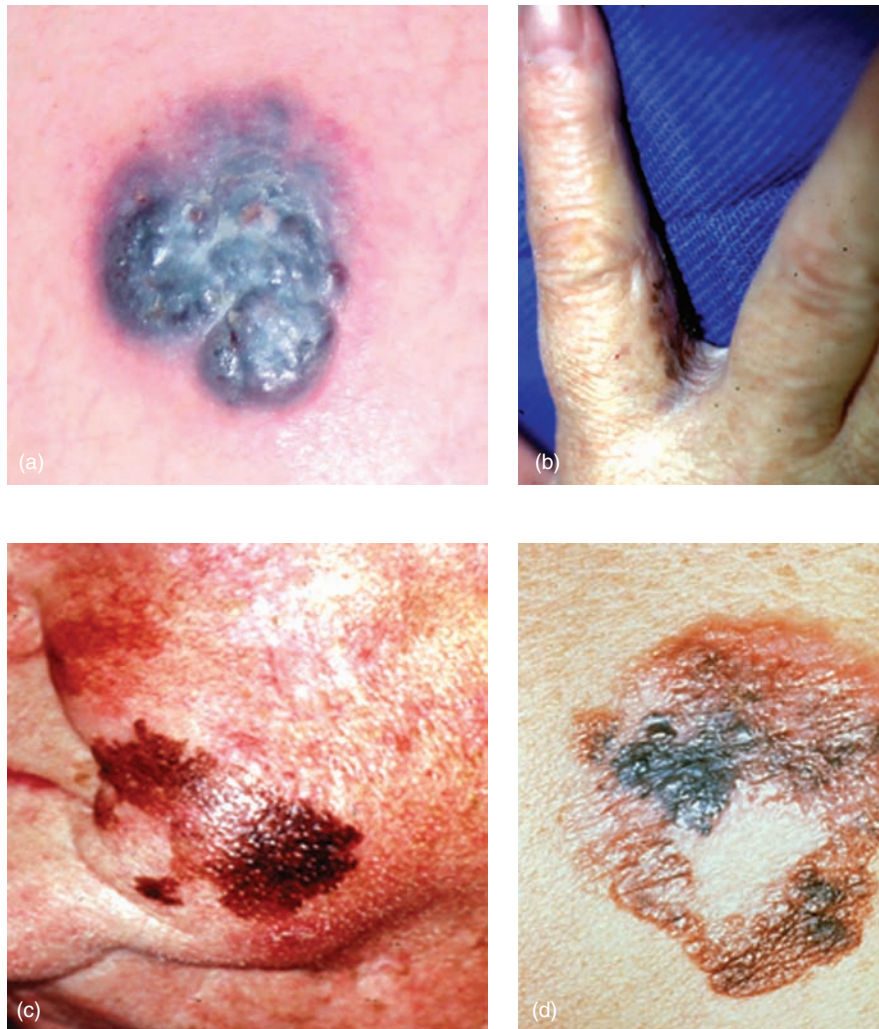

**Figure 20.2** Resection specimen after local wedge resection of solitary colorectal liver metastasis.

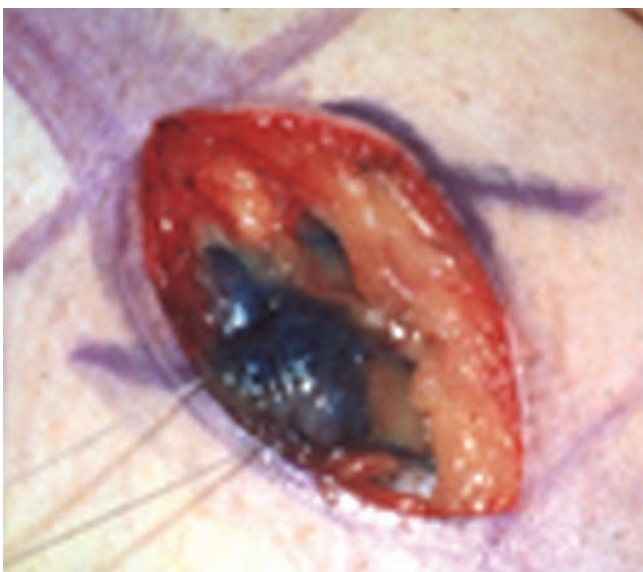


**Figure 26.1** Multiple skin lesions and nodal metastases (arrow) in the popliteal area of a squamous cell carcinoma on the leg of a patient who was treated with psoralen (P) UVA 20 years before.

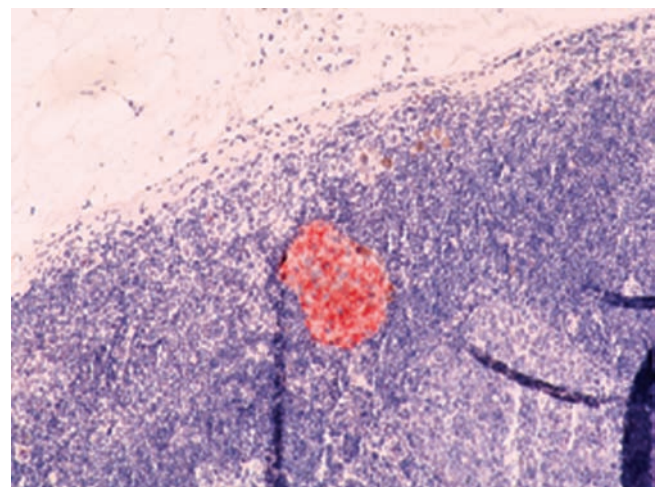




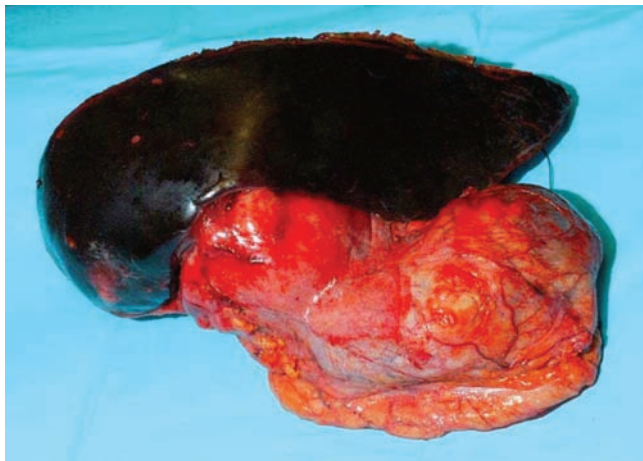
**Figure 27.1** (a) Nodular melanoma arising from a pre-existing nevus. Note focal ulceration. (b) Acral lentiginous melanoma arising between fingers. (c) Lentigo maligna melanoma. (d) Superficial spreading melanoma with irregular borders and variegated pigmentation.



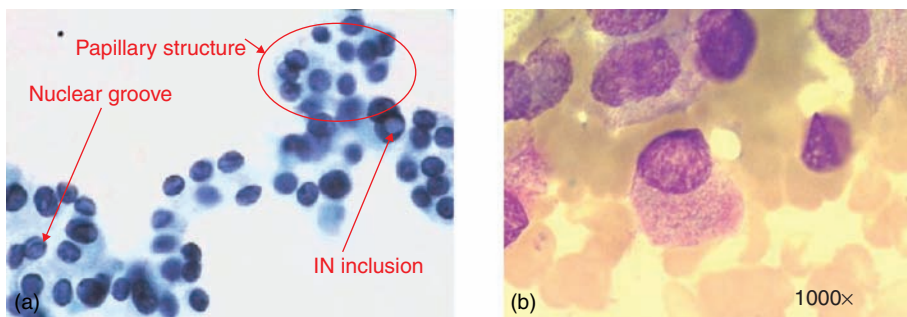
**Figure 27.4** Blue, radioactive inguinal lymph node mapped as the sentinel lymph node.



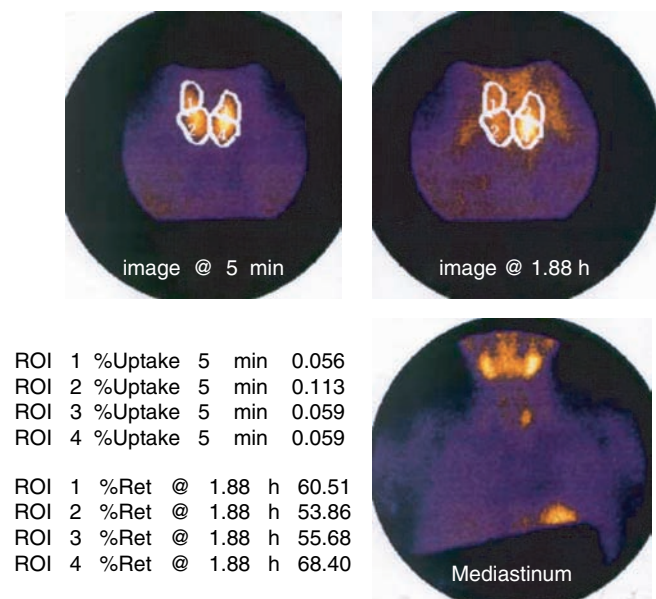
**Figure 27.5** Sentinel lymph node micrometastasis identified by immunohistochemistry.



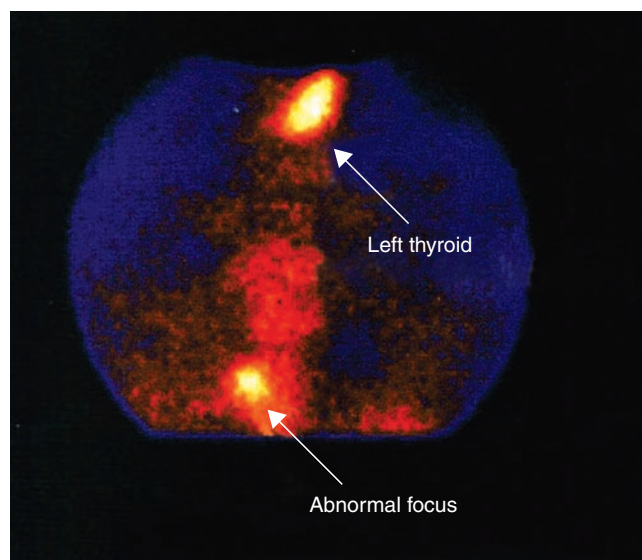
**Figure 28.4** En bloc resection of the adrenal gland, kidney and segments 5, 6 and 7 of the liver for locally advanced adrenocortical cancer on the right side.



**Figure 29.4** (a) Fine needle aspiration of papillary thyroid cancer demonstrating nuclei and central lymph node clearing. (b) Fine needle aspiration of medullary thyroid cancer.

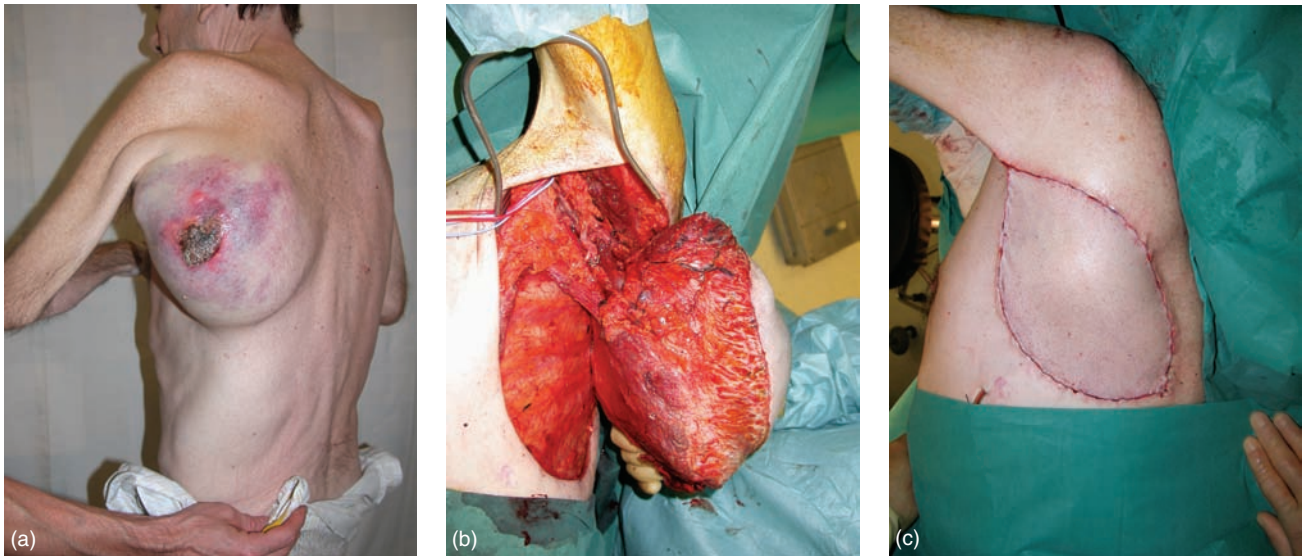


**Figure 30.1** Sesta MIBI scanning of a left lower parathyroid adenoma. ROI, region of interest.

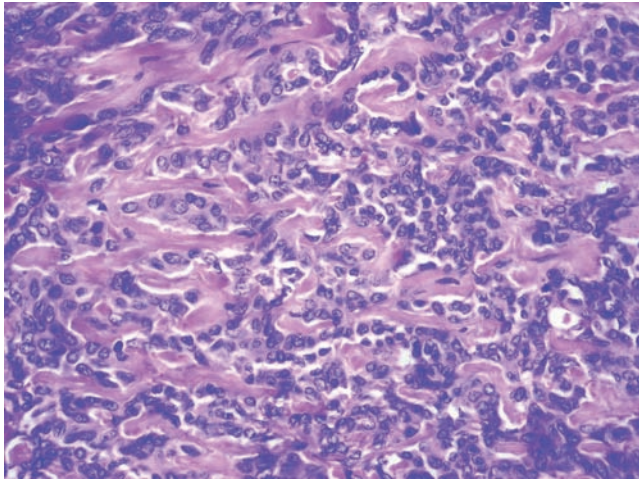


**Figure 30.5** Ectopic parathyroid gland in anterior mediastinum. Note the parathyroid pathology can be found anywhere from submandibular gland to the mediastinum.

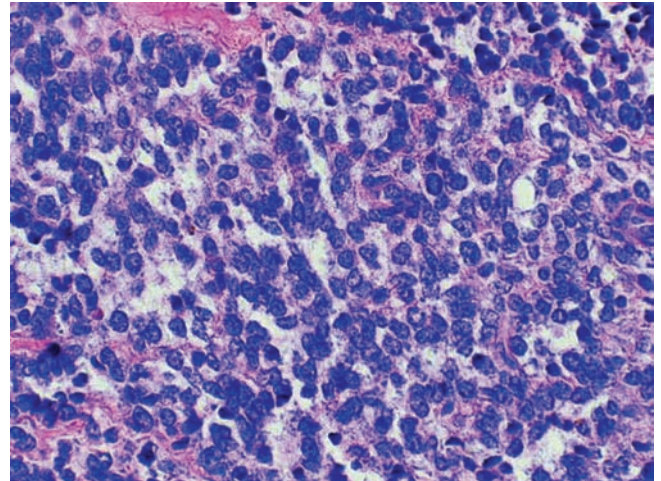




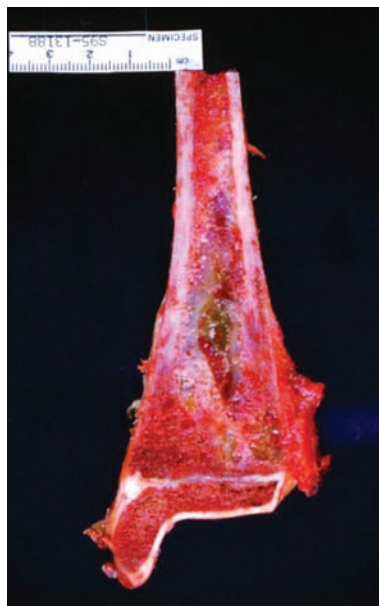
**Figure 32.4** Reconstruction of a large defect in the chest wall with a latissimus dorsi myocutaneous flap.



**Figure 33.3** Osteosarcoma photomicrograph demonstrating abundant tumor osteoid (200 × H&E).



**Figure 33.4** Photomicrograph of Ewing's sarcoma (400 × H&E).



**Figure 33.6** Macroscopic specimen from Figure 33.5.

# Is there a surgical oncology?

1

Graeme J Poston

---

## INTRODUCTION

Is there a surgical oncology? Considering the statistic that 60% of patients who are presently cured from cancer are cured by surgical resection alone then at face value the answer must be yes. However, there are a number of major hurdles (both practical and philosophical) that must be overcome, if we wish to maintain the role of the surgeon in the management of the cancer patient.

First, surgical oncology is not recognized universally as a distinct discipline within surgery. Second, those surgeons who regard themselves as surgical oncologists fall into two broad but distinct groups: those who regard themselves as general surgical oncologists, able to operate on most solid tumors, with a minimal practice in benign pathology; and those surgeons who are anatomical site specific, and retain the remit to treat patients with complex benign disorders relating to their organ of interest. Although the perceived trend is towards the latter group, general surgical oncology will remain for the foreseeable future because of the nature and needs of health-care delivery worldwide (particularly in countries with developing economies).

On the other hand, standing still is not, never was, and never will be, an option. The major advances in radiation and medical oncology of the past few decades have changed the face of cancer treatment forever. Tumors previously thought unresectable with curative intent, can now be brought to potentially curable surgical resection using neoadjuvant strategies. Similarly, long-term outcomes following apparently curative surgery can be significantly improved for patients with most common solid tumors using appropriate adjuvant strategies.

Surgeons need to be aware of continuing advances in these related disciplines. Already radiotherapy is considered an alternative to surgical excision for basal cell carcinoma of the skin (the commonest, but least lethal invasive tumor worldwide) and squamous carcinoma of the esophagus. The use of appropriate chemotherapy has completely changed the outlook in stage III and IV malignant teratoma of the testis, and similar chemotherapy

driven advances are now being witnessed in the management of advanced colorectal cancer, metastatic to the liver.

## HISTORY

The history of surgery is paved with oncological landmarks. The first curative excision of an ovarian tumor was achieved by Ephraim McDowell in 1809<sup>1</sup>. Modern surgical oncology has its roots in the last decades of the 19th century. With the advent of general anesthesia, following the work of Simpson, and antisepsis, from the work of Lister, Semmelweis and Pasteur, surgeons were able to operate within the abdomen and on large structures such as the breast. Pioneers such as Billroth in Vienna and Langenbeck in Berlin described potentially curative operations for stomach and biliary tumors. Although Billroth is frequently credited with performing the first gastrectomy for cancer (which he performed in Vienna on 29 January 1881), the honor must go to Pean who performed a partial gastrectomy in 1879 in Paris, and Rydiger who performed a similar procedure in Chelmino, Poland in 1880<sup>1</sup>. In Billroth's first case, the operation took only 90 minutes to complete, yet the tumor was already spreading and his 43-year-old female patient was dead less than 4 months later. When Billroth attempted to publish this case, he was only allowed to do so by the editor if he could add the rider that this was the first and hopefully the last time that this operation would be described!

The concept of breast cancer was known to the ancient Egyptians, as shown by the papyri of Ebers and Smith. Operations for breast cancer were described in the 7th century by Aetius of Amida, who emphasized that the knife should cut around the tumor, remaining in the healthy tissue, thereby being the first surgeon to appreciate the significance of the resection margin<sup>1</sup>. Barthelemy Cabrol, a student of Pare in the late 16th century, was the first to advocate the additional resection of the underlying pectoral muscles. The modern

concept of breast conservation surgery for breast cancer was first proposed by the Florentine surgeon Nannoni in 1746! He advocated lumpectomy with a wide margin, along with the adjacent underlying fascia and any palpable regional lymph nodes. Further enlightenment on the spread of breast cancer comes from the writings of Jean-Louis Petit, a surgeon at the Charite Hospital in Paris during the first half of the 18th century, who was the first to describe the spread of breast cancer to the regional axillary lymph nodes. These observations led to the arguments for more radical surgery being proposed by Charles Hewitt Moore of London's Middlesex Hospital in the 1850s and ultimately to Halsted's proposals for radical lymphadenectomy for improving outcomes in breast cancer.

Kocher became the first surgeon to win the Nobel Prize for medicine in recognition of his pioneering work in the field of thyroid surgery. It should also be remembered that the concept of hormone manipulation of malignant tumors was pioneered by surgeons. George Beatson, a Glasgow surgeon advocated oophorectomy for symptom control in advanced breast cancer in 1896<sup>2</sup>. In 1966, the Canadian-American surgeon Charles Huggins won the Nobel Prize for medicine in recognition of his 1945 work in the field of antiandrogen therapy in prostate cancer<sup>3</sup>.

Between 1900 and 1910 Hugh Young performed the first radical prostatectomy and Ernst Wertheim the first radical hysterectomy. In 1908, Ernest Miles described the first abdominoperineal resection for rectal cancer<sup>4</sup> and, the following decade, Torek performed the first esophagectomy in New York in 1913. The first attempted resection of a liver tumor was performed by Lius in November 1886, who ligated and then cut through a pedicle left lobe 'adenoma'. Attempts to suture the severed pedicle to the abdominal wall were unsuccessful, and the stump was returned to the abdominal cavity. Death due to ongoing hemorrhage from the uncontrolled stump inevitably occurred 6 hours later<sup>5</sup>! Undaunted, Carl von Langenbuch performed the first successful (insofar as the patient lived) hepatectomy in Berlin in 1888 (although he too had to re-operate for reactionary hemorrhage, although this time successfully)<sup>6</sup>. Following the first successful resection of a lung metastasis by Divis in 1927, Evarts Graham performed the first pneumonectomy for primary bronchogenic carcinoma in Washington in 1933. Other milestones in cancer surgery include the first nephrectomy by E B Wolcott of Milwaukee, Wisconsin in 1861 (although the patient died 2 weeks later from septicemia)<sup>1</sup>.

Such was the rate of achievement at the beginning of the 20th century that Sir John Erichsen, Professor of Surgery at University College Hospital, London was

quoted in the *Lancet* in 1873 as saying, 'The final limit to the development of manipulative surgery . . . has nearly, if not quite, been reached . . . if we reflect on the great achievements of modern operative surgery, very little remains for the boldest to devise or the most dextrous to perform'

With the advantage of retrospection, it is now clear that many of these pioneers explored blind alleys in their bids to conquer cancer. Halstedian radical mastectomy has clearly evolved from complete axillary clearance to today's techniques of sentinel node biopsy. The principles of wide excision of malignant tumors, to include a margin of surrounding healthy tissue, first proposed by Billroth, were taken to absurd extremes in the field of melanoma surgery by the work of Sampson Handley, in work that would be unpublishable today (his paper which underpinned the 5 cm wide resection margin, held sacrosanct for malignant melanoma surgery for nearly 80 years, was based on his work examining 27 separate and satellite lesions from the same, single patient)<sup>7</sup>.

Patient awareness of symptoms and modern screening programs now result in many more patients presenting at a far earlier stage in their disease process than those of 100 years ago. Nevertheless, the role of the surgeon remains as the diagnostic gatekeeper, and frequently the first port of call in the patient's journey through often complex and protracted treatments for malignant disease.

## UNDERSTANDING THE BIOLOGY OF CANCER

In this book, we systematically review the guiding principles that underpin the modern practice of surgical oncology, and then proceed to apply these principles to the individual anatomic sites that confront us in day to day practice. These principles begin with the need to understand the biology of cancer.

Cancer is increasing in prevalence worldwide. This statement is as true for developing nations as it is for the established economies in the West and Far East. Furthermore, those economies that are witnessing recent surging economic growth are seeing similar, commensurate increases in those cancers that were historically considered to be restricted to Western society. This 'Westernization of disease' is manifesting itself in the increasing prevalence of breast and colorectal cancer among the new middle classes, and carcinoma bronchus across society, in both India and China. Clearly behavioral change (smoking and diet) plays a major role, as does exposure to industrial carcinogens in often poorly regulated factories in the race for growth. Specific etiological factors are dealt with in each of the site-specific chapters.

Similarly, our understanding of the genetic and molecular factors that determine cancer etiology and development increases year on year. However, the long-awaited breakthroughs in treatments based on these findings have as yet to work their way into day to day practice for common solid tumors. Each site-specific chapter addresses these developments where they relate to contemporary oncological management.

However, some basic tenets remain constant with regard to the over-arching principles of surgical oncology. Although most benign tumors remain non-life threatening throughout their course, some will kill because of their location adjacent to or within vital organs (tumors around the heart or within the skull), and some may be lethal simply because of the size that they can attain without treatment. The distinction between benign and malignant tumors remains unchanged. Malignant tumors (cancers) deserve their notoriety due to their capacity to spread by direct invasion and metastasis by blood-borne, lymphatic and transcelomic spread. It is this understanding, apparent since the days of Hippocrates and Galen that continues to underpin the practice of modern-day surgical oncology.

It therefore remains imperative for the successful practice of surgical oncology, for the surgeon to command an understanding of the biology of the disease, so identifying those suffering at a time when successful surgical intervention offers the chance of cure. Similarly, this understanding dictates the nature and radicality of surgical intervention, in order to achieve the best chance of complete clearance of all disease.

The last factor in the understanding of tumor biology that impacts on surgical practice is the appreciation of tumor stage, and its relationship to both disease prognosis and the possible need for adjunctive therapies with surgical treatment.

## **INTEGRATION OF SURGERY WITH OTHER THERAPEUTIC INTERVENTIONS**

Surgery has formed the basis of successful modern cancer treatment for over a century. However, the only way that surgeons can directly improve the cure rate for the specific solid tumors falling within their own anatomic remit, is to detect disease at an earlier time in its course, when (hopefully) surgical intervention has a higher chance of successful outcome.

To be worthwhile, screening for solid tumors requires the assumption of a number of prerequisites. First, that the disease is of such prevalence in a given society for screening to confer sufficient health-economic benefit. Second, the method used to screen-detect tumors at an

earlier (and asymptomatic) stage in development is reliable, reproducible and cost-effective. Finally, that screening will lead to an increase in detection of disease at an earlier stage when timely surgical intervention can (hopefully) achieve a greater chance of long-term cure. For such screening programs to be successful (cervix, breast, colon, etc.), the input of surgeons into their design and execution is essential.

We are probably not going to again see major radical advances in surgical technology which render more cancer patients amenable to radical surgery with curative intent using surgery alone. Advances in minimal access surgery and enhanced postsurgical recovery may allow faster recovery and discharge after operation. Improvements in anesthesia and intensive care can allow us to operate with curative intent on patients who previously were deemed too old, infirm or unfit to undergo radical surgery. Similarly, we as surgeons are going to have to accept that certain solid tumors may in future, increasingly pass to our sister disciplines for both potentially curative (e.g. tumor ablation) and palliative (e.g. endoscopic stenting) interventions.

On the other hand, advances in both radiation and medical oncology now mean that many more patients with disease previously deemed inoperable because of tumor stage and burden, can now be downstaged to surgical resection with curative intent. In 1905, Sir Charles Ball, Professor of Surgery at Trinity College Dublin wrote, 'Then possibly the hypodermic needle may be enabled to claim a greater success than today can be achieved by the most extensive surgical procedures, conducted with scrupulous attention to elaborate technique'. Examples of such advances predicted by Ball over 100 years ago include the fields of esophageal cancer, rectal cancer and the management of colorectal liver metastases. Likewise, patients who previously needed large-scale disfiguring surgery for conditions such as locally advanced breast cancer, can if successfully responding to neoadjuvant therapy, now be subsequently considered for much less radical, but equally potentially life-saving surgery. Finally, advances in systemic chemotherapy and biological therapies may allow more cancer patients, previously deemed incurable, to benefit from techniques established within transplantation (e.g. liver transplantation for hepatocellular carcinoma).

## **CONCLUSION**

There has never been a greater need for competent surgeons skilled in the field of oncology. Over the past 2 decades we have witnessed major improvements in long-term survival for patients suffering from common



solid tumors. Long-term survival in breast and bowel cancer has more than doubled. Many of these achievements rest on advances in disease screening and radiation and medical oncology (both in the neoadjuvant/adjuvant

setting and long-term palliation). However, surgery continues to underpin these treatment strategies, both in diagnosis and therapy, and will continue to do so for the foreseeable future.

## REFERENCES

---

1. Haeger K. The Illustrated History of Surgery. London: Harold Starke, 1988: 223–45.
2. Beatson GT. On the treatment of inoperable cases of carcinoma of the mamma: suggestions for a new method of treatment with illustrative cases. *Lancet* 1896; 2: 104–7.
3. Nobel Lectures, Physiology or Medicine 1963–1970. Amsterdam: Elsevier Publishing Company, 1972.
4. Miles WE. A method of performing abdomino-perineal excision for carcinoma of the rectum and of the terminal portion of the pelvic colon. *Lancet* 1908; 2: 1812–5.
5. Luis A. Di una adenoma del fegato. *Centralblatt fur Chir* 1887; 5: 99. Abstr. From Ganzy, delle cliniche, 1886. Vol XXIII, No. 15.
6. Langenbuch C. Ein Fall von Resektion eines linksseitigen Schnurlappens der Leber. *Berl Klin Woch* 1888; 25: 37–8.
7. Handley WS. The pathology of melanotic growths in relation to their operative treatment. *Lancet* 1907; 2: 927–33.

# Principles of quality control in surgical oncology

2

Theo Wiggers

---

## INTRODUCTION

Cancer surgery puts the patient at risk twice for a poor outcome. The first time is during the initial (usually in hospital) period of diagnosis and treatment. Outcome is expressed as morbidity and even mortality. Both are directly related to the surgical procedure and are the threat for nearly every cancer patient. The second time for a risk of a poor, more cancer-specific outcome is due to improper staging and/or therapy. This outcome is traditionally expressed in disease-free survival and overall survival, but other outcome parameters such as good cosmetics, functional recovery and health-related quality of life<sup>1</sup> are also important parameters which can all vary widely because of the quality of the surgical procedure. In striving for the highest standard of quality in cancer care the cancer surgeon plays an essential role and is the most important prognostic factor twice in this whole process<sup>2</sup>.

The term quality has recently attracted a lot of attention but the principles have always been an important issue in surgical treatment. During residency we were brought up with the phrase: 'every detail counts'. Even the smallest mistake could still result in a catastrophe for the patient after an extensive and in all other aspects successful procedure. Initial complications during or after surgery, even seemingly mild ones, may radically alter the patient's risk for a good outcome. Initial complications often begin a cascade of complications that may even end in the patient's death<sup>3</sup>. Therefore, the result of a total mesorectal excision for rectal cancer can be destroyed by anastomotic leakage with subsequent sepsis and finally the death of the patient.

Nowadays we have a more systematic approach to the concept of quality. Nevertheless, the term total quality management is a relatively new concept in the field of surgery and needs further explanation. Quality can be defined as the totality of features and characteristics of a product or service that meet or exceed the customer requirements and expectations. Usually in medicine only the professional quality is mentioned. However, two other domains can be distinguished: logistic and relational quality.

The first reflects the quality of the organization of cancer care and the second the way of addressing the patient. The listed three dimensions are in a broad sense generic to all medical situations but all have specific relations to cancer surgery.

Quality control is the way to achieve optimal treatment results in all domains that meet a certain set standard. It is the operational process of techniques and activities to fulfill these requirements. This standard of outcome can be set by the community or by the professionals themselves. The result of a certain diagnostic or treatment procedure can be expressed in outcome or process indicators. In general, outcome parameters such as local recurrence rates after rectal cancer surgery or postoperative mortality after esophagectomy are set by the professionals, while process indicators (days on waiting lists, percentage 1 day diagnosis in breast clinics) have drawn more public attention. Although the concept of quality control is not specific for oncology or even cancer surgery it is explained in this chapter with examples relating to surgical oncology.

## CYCLIC MONITORING AND INDICATORS

Monitoring is an essential step in a quality system. To monitor the quality process in cancer surgery cyclic thinking is needed. This process is often described in four steps: plan, do, check; and act (Figure 2.1). After the initial phase of planning or redesigning a process or activity the procedure will be executed. After this phase it is essential that outcome should be measured and consequently action taken to improve the process. After this the cycle starts again.

Performance indicators can measure the quality of a hospital, a tumor working party, one discipline, or even an individual specialist. These indicators can be both outcome and process indicators. For example survival is an outcome parameter and the period that a patient is on the waiting list is a process indicator. Indicators need to fulfill several properties. An indicator must measure the

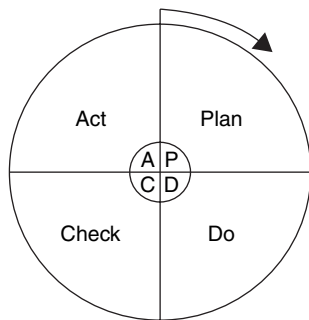


Figure 2.1 The quality cycle (PDCA).

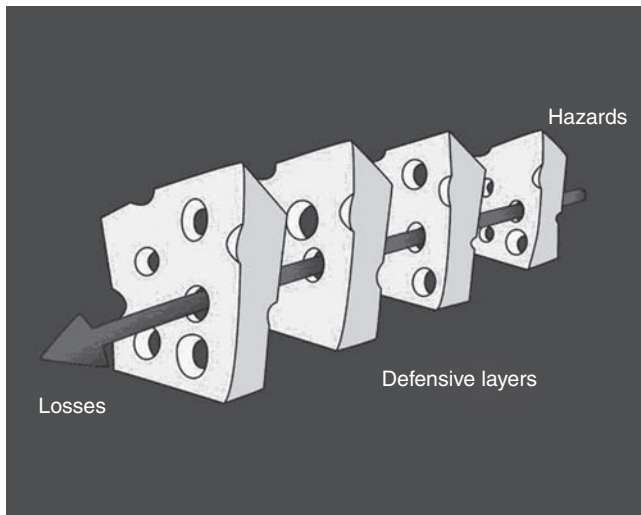
process in a correct and consistent way (reliability). If disease-free survival after breast cancer treatment is measured every time in a different way during follow-up (differences may occur in both frequency and type of examination) no comparable data can be obtained. Second it is important that the chosen indicator measures what it supposed to measure (validity). This means that for every indicator the following question should be raised: does the indicator capture an aspect of quality that is widely regarded as important and relevant? For pancreatic resection it is clear that postoperative mortality is a relevant outcome parameter since it reflects a strong association with the experience of the surgeon in combination with the infrastructure of the clinic. The final property of an indicator is that it should be responsive to changes in management (responsiveness). If after an initial survey a parameter scores over 90%, it is very unlikely that improvement of the process can be measured by this parameter. Postoperative mortality measurement with 10–15 cases a year will have such large confidence intervals that even a clinically relevant reduction of 5% cannot be measured<sup>4</sup>. The ‘gold standard’ of an outcome indicator such as disease-free survival is usually based on the results of randomized controlled trials. More specific local recurrence-free survival is a common endpoint for surgical trials but this endpoint may be far too late in time for a continuous improvement of the treatment process. Surrogate endpoints can be very useful for this, if used with caution<sup>5,6</sup>. Local recurrence rate of rectal cancer is caused by several factors but the most important is a free circumferential margin determined by the pathologist<sup>7</sup>. This indicator is available immediately after surgery and can be used as a reliable proxy parameter. After defining an output parameter it is important to choose the correct input parameters. Postoperative mortality as an example for an outcome parameter has to be adjusted for case mix input parameters such as age, comorbidity and stage before it can be used for benchmarking with other institutions.

Many hospitals and doctors fear that indicators will be used against them. However, internal indicators such as

the rate of postoperative wound infections have already been used for many years. Many of these measurements can in fact only been used for internal self-assessment and external parties should be convinced to use validated indicators only that are adjusted for case mix. Recently, in an audit, the percentage of preoperative irradiated rectal cancer patients was defined as an indicator of proper implementation of the national guideline. The relatively low performance state of a university hospital could be sufficiently explained by the fact that several patients had already been irradiated in the past for prostate or cervical cancer. A second explanation was that many locally advanced rectal cancers had already been irradiated elsewhere before referral. After these corrections the performance indicator met the preset standard. This example shows that in the future it will be necessary to adjust every indicator regularly.

## PROFESSIONAL QUALITY AND PATIENT SAFETY

Organ specialization and case load have been a big issue during recent years and for most cancers a direct relation between high volume and a better outcome has been demonstrated by reviewing the recent literature<sup>8</sup>. Concentration in clinics of high-risk procedures with a certain volume (procedures such as esophagectomy, pancreatotomy and hepatic resection) might prevent many postoperative deaths per year. Also, other procedures such as thyroidectomy and colon resections have shown the same tendency to a lesser extent. Reduction of postoperative mortality by 5% is in general as effective as toxic adjuvant treatment and should have high priority in achieving the highest quality in cancer surgery. Not only can a reduction in morbidity and mortality be achieved but also a better functional and even financial outcome is possible. Sometimes too much attention has been focused on numbers per year, since even smaller hospitals with dedicated teams can achieve good results. It is very likely that not only volume but also training and specialization result in a better outcome. The setting of an absolute number of cases is not very productive and diverts attention from organized multidisciplinary meetings, appropriate infrastructure and availability of modern techniques<sup>9</sup>. The focus of interest should be directed more towards analyzing and optimizing the whole process of diagnosis and treatment, since this whole process can put the patient at severe risk, especially during the in-patient period. Avoidance of mistakes has received a lot of attention during recent years. It has resulted in interest in patient safety as a concept. Since the publication of the report *To Err is Human* issued by the Institute of



**Figure 2.2** The 'Swiss cheese' model according to Reason<sup>11</sup>. Successive layers of defenses, barriers and safeguards may be penetrated due to active failures or latent conditions.

Medicine<sup>10</sup> the approach to errors has changed. Individuals can make mistakes but a system approach concentrates on the conditions under which individuals work and tries to build defenses to overt or mitigate the effects of mistakes. This is very well visualized by the Swiss cheese model<sup>11</sup>. Several layers of defense, each with its own holes, are put around a procedure (Figure 2.2). Both active failures and latent conditions cause holes in each layer. The usual way of thinking is to close the holes in the last layer of defense; however, redesigning the process and the closing of a hole in a much earlier layer will probably be more effective.

Root cause analysis is the way to go back in the process and try to identify weak points in the procedure. A good example is the incorrect position of a colostomy after an abdominoperineal resection. It is easy to blame the resident for not selecting the correct position during surgery or even marking the wrong spot the day before the operation. A better solution would be either proper training of the junior or having the right spot tattooed during the outpatient clinic by a stoma therapist. Marking of the correct part and site of the body has become a safety measure and the patient should be instructed to ask for this procedure for their own safety. It is important to get rid of the 'blame and shame' culture and introduce a more open environment in which it is possible to report on near misses and mistakes. The safety climate in a surgical department can be measured in a validated way and is an essential part of a culture in which patient safety can flourish<sup>12</sup>.

Reduction of complications in the direct postoperative period after a surgical procedure has many aspects not related to the cancer surgery itself, but to the invasive

nature of the intervention. Great attention to every detail during the preoperative work-up and clinical period may result in the reduction of adverse events. This is what is termed 'the first time at risk' above. There are also examples of actions in optimizing results that are more cancer specific. For instance the use of techniques stimulating wound healing after an abdominoperineal resection such as an omentoplasty or rectal abdominis flap may prevent a delay in adjuvant systemic treatment for rectal cancer. Careful attention towards wound healing in sarcoma will avoid postponement of the necessary adjuvant radiotherapy. Omitting a computer scan with iodine-containing contrast in the diagnostic work-up for a thyroid cancer makes postoperative radioactive treatment with iodine possible earlier resulting in a possible better outcome. Harvesting a sufficient number of lymph nodes in colon cancer may avoid discussions about the indication for adjuvant chemotherapy.

Most of the examples for patient safety in the clinical period are in relation to optimal use of multimodality treatment or to effects of surgery in general. Sometimes there has to be a balanced risk of the acceptance with a more extensive surgical procedure of a higher morbidity to achieve a better long-term cancer result. The reverse is also possible when a good short-term outcome of a local excision in rectal cancer has to be counterbalanced by a higher local recurrence rate. Quality assurance for all the participating disciplines (both diagnostic and therapeutic) is a key element in the set up of clinical prospective randomized trials<sup>13</sup>. This topic is discussed in the chapter of quality assurance in clinical trials.

## ORGANIZATIONAL QUALITY

In the past cancer surgery was performed after limited diagnostics within the frame of a monodisciplinary treatment. The enormous increase in diagnostic modalities (positron emission tomography scan, computer tomography, magnetic resonance imaging) and the order of adjuvant and neoadjuvant treatment have caused an enormous complexity in the handling of patients. Algorithms of breast cancer therapy can end up in over 250 possible treatment combinations. Waiting periods for every diagnostic or therapeutic procedure have caused the phenomenon of a cumulating waiting list in which after the end of one procedure the next discipline starts from scratch. In an environment of scarcity (waiting lists for every diagnostic examination or treatment) this cumulation may cause a delay of even months. This is not only stressful for the patient but also can put them at risk for more extensive tumor growth making a change in treatment plan necessary or for more complications after treatment.

An interval of more than 3 days between the end of short course radiotherapy and surgery resulted in excess of cardiac toxicity in elderly patients with a rectal cancer<sup>14</sup>. The ever increasing numbers of multidisciplinary meetings have reduced the time that can be spent on the treatment of an individual patient. There are a couple of solutions to manage this complex and time consuming process. Clinical pathways with defined slots for diagnostic and therapeutic procedures may reduce the cumulative waiting period. Redesigning the whole pathway allows for registration of abnormalities from this pathway. For these patients case management attempts to solve a problem that has occurred putting them back on track again. In other words, as long as the patient stays on track no special attention has to be paid but if an elderly patient develops delirium the case manager will develop an individual clinical path with extra support to keep the patient in the treatment plan. The enormous burden of multidisciplinary meetings can be reduced by skipping every moment in the well defined track in which the patient is only transferred to another discipline for further treatment. After a successful colon resection and lymph node metastases and the absence of (cardiac) comorbidity it is questionable whether multidisciplinary discussions will alter the standard treatment of adjuvant treatment. On the other hand, the preoperative multidisciplinary meeting with good imaging is essential in making the right treatment choice for rectal cancer.

## RELATIONAL QUALITY

For the patient not only are the professional and organizational quality important, but also the patient may expect that the way of communicating bad news is part of

the professional behavior of the surgeon. Analysis of the needs and expectations of patients attending a second opinion outpatient clinic showed that communication was a prominent factor<sup>15</sup>. This was even more important than the medical technical questions and only a minority, but significant, number of cases resulted in a relevant difference from the first opinion<sup>16</sup>. An open and direct approach based on the individual needs of the patient is the key element in good patient–doctor relations. Structural attention to the psychosocial sequelae of the diagnostic and therapeutic process may select a group of patients needing more extensive support by specialist psychologists. Referral to a specialized center can be helpful. Outcome aspects of enhanced social support, reduced psychosocial distress and emotional control should meet the same requirements of evidence-based medicine as other somatic interventions.

## CONCLUSIONS

Quality in surgical oncology is relevant for both the short-term outcome during the initial treatment period and the long-term outcome which reflects the more specific oncological aspects. It is essential to pay attention to all the three domains of quality (professional, organizational and relational). Measuring quality can be performed by using indicators. They provide information about short- and long-term outcome, and give important information regarding benchmarks. Avoidance of complications is characterized as patient safety with more attention to failures in the system than to mistakes of an individual person. All the combined efforts can be called total quality improvement by which an organization consistently meets or exceeds the customers' requirements.

## REFERENCES

1. Langenhoff BS, Krabbe PF, Wobbes T, Ruers TJ. Quality of life as an outcome measure in surgical oncology. *Br J Surg* 2001; 88: 643–52.
2. Lerut T. The surgeon as a prognostic factor. *Ann Surg* 2000; 232: 729–32.
3. Silber JH, Rosenbaum PR, Trudeau ME et al. Changes in prognosis after the first postoperative complication. *Med Care* 2005; 43: 122–31.
4. van Heek NT, Kuhlmann KF, Scholten RJ et al. Hospital volume and mortality after pancreatic resection: a systematic review and an evaluation of intervention in the Netherlands. *Ann Surg* 2005; 242: 781–8.
5. McGuire HH Jr, Horsley JS 3rd, Salter DR, Sobel M. Measuring and managing quality of surgery. Statistical vs incidental approaches. *Arch Surg* 1992; 127: 733–7.
6. Schatzkin A. Problems with using biomarkers as surrogate end points for cancer: a cautionary tale. *Recent Results Cancer Res* 2005; 166: 89–98.
7. Wiggers T, van de Velde CJ. The circumferential margin in rectal cancer. Recommendations based on the Dutch Total Mesorectal Excision Study. *Eur J Cancer* 2002; 38: 973–6.
8. Weitz J, Koch M, Friess H, Buchler MW. Impact of volume and specialization for cancer surgery. *Dig Surg* 2004; 21: 253–61.
9. Hillner BE, Smith TJ, Desch CE. Hospital and physician volume or specialization and outcomes in cancer treatment: importance in quality of cancer care. *J Clin Oncol* 2000; 18: 2327–40.
10. Kohn LT, Corrigan JM, Donaldson MS, eds. *To Err Is Human: Building a Safer Health System*. Washington, DC: National Academy Press, 1999.

11. Reason J. Human error: models and management. *BMJ* 2000; 320: 768–70.
12. Makary MA, Sexton JB, Freischlag JA et al. Patient safety in surgery. *Ann Surg* 2006; 243: 628–32.
13. Peeters KC, van de Velde CJ. Surgical quality assurance in breast, gastric and rectal cancer. *J Surg Oncol* 2003; 84: 107–12.
14. Marijnen A, Kapiteijn E, van de Velde CJ et al. Acute side effects and complications after short-term preoperative radiotherapy combined with total mesorectal excision in primary rectal cancer: report of a multicenter randomized trial. *J Clin Oncol* 2002; 20: 817–25.
15. Mellink WA, Dulmen AM, Wiggers T et al. Cancer patients seeking a second surgical opinion: results of a study on motives, needs, and expectations. *J Clin Oncol* 2003; 21: 1492–7.
16. Mellink WA, Henzen-Logmans SC, Bongaerts AH et al. Discrepancy between second and first opinion in surgical oncological patients. *Eur J Surg Oncol* 2006; 32: 108–12.

## RELEVANT WEBSITES

<http://www.acmq.org/>  
<http://www.psnet.ahrq.gov/>  
<http://www.qualityindicators.ahrq.gov/>



# Principles of adjuvant radiotherapy

3

Pooja Jain, Azeem Saleem and Pat Price

---

## INTRODUCTION

Radiation oncology is the clinical and scientific discipline dedicated to the management of cancer patients with ionizing radiation, either alone or in combination with other modalities such as surgery, chemotherapy or biological therapies. The aim of radiotherapy is to deliver a precise dose of radiation to a defined tumor volume with minimal damage to surrounding normal tissues. Normal tissue sensitivity limits the amount of radiation delivered at a time. Therefore, small doses of radiation, or fractions of the total dose, are delivered regularly over a specific period of time to attain either tumor eradication or control. Indications for radiotherapy in the management of cancer, defined prior to therapeutic intervention, are detailed further below.

- (1) A course of radical or curative radiotherapy is planned where the probability of long-term survival after adequate therapy is high, and some normal tissue side-effects of therapy, although undesirable, may be acceptable in this setting. Although single modality radical management with radiotherapy is used to treat a number of early stage laryngeal and skin cancers<sup>1</sup>, there is an increasing trend for the simultaneous (concurrent) use of chemotherapy in the radical management of cancer<sup>2-4</sup>. The concurrent use of primary chemoradiotherapy has, for example, increased local control in anal cancer<sup>2</sup> and both local and systemic control in cervical cancer<sup>5</sup>, over radiotherapy alone, reflecting the radiosensitizing and systemic cytotoxic effects of chemotherapy. The advantages of primary non-surgical management of cancer include organ preservation and the scope for subsequent surgical salvage in the event of local disease recurrence.
- (2) A course of radiotherapy delivered as an adjunct to the primary management modality to improve treatment efficacy is called adjuvant radiotherapy. Adjuvant radiotherapy is usually planned within a radical management setting and delivered after the primary

modality (usually surgery) has been completed. In early breast cancer for instance, adjuvant radiotherapy following breast-conserving surgery has replaced mastectomy, without compromising the overall survival rates<sup>6</sup>. When radiotherapy is administered prior to the primary modality, it is termed neoadjuvant treatment. Neoadjuvant radiotherapy is used to downsize the primary tumor, thereby making some inoperable tumors operable and to reduce local disease recurrences.

- (3) Palliative radiotherapy is given for control of symptoms such as pain, cough, or hemoptysis, for prevention of symptoms such as impending paralysis, or for temporary arrest of tumor growth. Palliative radiotherapy does not aim to improve survival. In contrast to radical or adjuvant radiotherapy, where treatment schedules usually last a few weeks in duration, palliative treatment schedules usually are of a short duration and primarily dictated by patient's life expectancy and the site and volume of tumor to be irradiated.

In this chapter, principles of adjuvant radiotherapy, i.e. radiotherapy administered sequentially as an adjunct to the primary treatment modality, are discussed.

## HISTORICAL PERSPECTIVE

Although radiation has been used as a primary treatment modality in oncology for about 100 years, the utility of radiotherapy as adjuvant therapy was only realized in the late 1960s. This conceptual evolution of the sequential use of multiple treatment modalities, especially surgery and radiotherapy, developed empirically, with a greater understanding of the natural history of cancer and as experience and evidence uncovered the advantages and limitations of individual treatment modalities<sup>7,8</sup>.

Solid tumors have a propensity to infiltrate adjacent normal tissues and to spread along fascial tissue planes, neurovascular bundles and periosteum. This tendency to



spread initially led to radical surgical techniques that attempted to remove both the primary tumor and tissue at high risk of disease recurrence, in order to gain maximal locoregional control. However, these extensive surgical procedures resulted in considerable physical deformity and were associated with considerable morbidity and psychological trauma<sup>8,9</sup>. Since radiation, like surgery, is a local treatment modality, it soon became apparent that extensive radical surgery could be avoided by complementing limited surgery with adjuvant radiotherapy, thus preserving functional anatomy, reducing morbidity and improving the patient's quality of life. Ever since, the complementary nature of radiotherapy in attaining this goal, especially its unique advantage in terms of organ and function preservation, has led to the increased use of adjuvant radiotherapy in a number of tumor sites<sup>7</sup>.

An example is the historical evolution of breast cancer surgery over the last century. Halsted's radical mastectomy<sup>9</sup> propounded in 1894, where the whole breast was removed together with underlying pectoral muscles and axillary contents was the favored treatment for the most of the 20th century for patients with breast cancer. However, a greater understanding of the biology of the disease, together with evidence from randomized clinical trials<sup>10–12</sup> resulted in the establishment of breast-conserving surgery with adjuvant radiotherapy as the preferred option for treating appropriate patients with early stage breast cancer.

## BIOLOGICAL PERSPECTIVE

### Radiation biology

Interaction of ionizing radiation with tissue leads to the formation of highly reactive free-radicals that interact with essential macromolecules. Although a range of reactions take place, it is the interaction with the cellular DNA that is important for cell kill. The high affinity of oxygen for free-radicals strengthens the effect of radiation by 'fixing' the free-radical damage. Despite a vast amount of DNA damage that is induced at clinically relevant doses, most of it is successfully repaired and it is believed that double-stranded DNA breaks are the critical lesions for radiation-induced cell kill<sup>13</sup>. Following irradiation, a number of cells are likely to remain metabolically functional and may proliferate for several postradiation generations before they eventually die. Radiation is considered to have achieved its goal, if the capacity to produce a continuously expanding progeny (or colony formation; clonogenicity) of cancer cells is abolished.

Radiotherapy is usually delivered as high energy X-rays or electrons produced by linear accelerators or

rarely as gamma rays produced from a radioisotope (usually cobalt-60). The dose is prescribed in units of gray (Gy; 1 Gy = 1 Joule per kg), which is the radiation dose absorbed by tissue.

The biological basis of fractionated radiotherapy results from a greater sparing of the normal tissues compared with tumors with one or more of the five recognized radiobiological processes (known as the '5 Rs'): redistribution, reoxygenation, repair, repopulation, and intrinsic cell radiosensitivity<sup>14</sup> playing a significant role in this process. The progression of cells that survive radiation as a result of being in a radioresistant phase of the cell cycle to radiation-sensitive (G2 and M) phases (redistribution or reassortment) a few hours after irradiation enhances the response of tumors to radiotherapy. Similarly, the improvement in oxygenation (reoxygenation) between fractions of hypoxic cancer cells that survive radiation also increases tumor sensitivity to radiotherapy, as oxygen is essential for the 'fixation' of radiation damage. The combination of hypoxia modifying agents with radiotherapy has resulted in an enhancement of the therapeutic index of radiotherapy in certain tumors and is an area of considerable interest and research<sup>15–17</sup>. In contrast to redistribution and reoxygenation, cellular repair of radiation damage and the repopulation by normal cells between radiation fractions tends to spare normal tissue from radiation damage.

Certain types of rapidly proliferating cancers also demonstrate a marked increase in growth rate (15–20 times faster) after the commencement of radiotherapy. This 'accelerated repopulation', which becomes apparent about 3–5 weeks after the start of treatment<sup>18,19</sup>, has been postulated to be a result of a decrease in tumor hypoxia and malnutrition, resulting in a reduced spontaneous cell loss and increased tumor growth rate<sup>20</sup>. Consequently, prolongation of a planned course of irradiation beyond a certain period may have a negative impact on local control of disease. For example, with squamous cell carcinoma of head and neck treated with primary radiotherapy, it has been estimated that an extra 0.6 Gy per day is required to counterbalance the effects of accelerated repopulation, when the overall treatment time exceeds 28 days<sup>19</sup>.

Finally, the inherent difference in radiation sensitivity differs markedly between cells from different tumors, which makes some tumors more radioresponsive than others. For example, seminomas and lymphomas, which have a higher inherent sensitivity to radiation, require smaller doses of radiation to achieve therapeutic benefit<sup>21,22</sup>. *In vitro* colony-forming assays of the surviving fraction of cells after a radiation dose of 2 Gy (SF2) have been used as the most common indicator of inherent radiosensitivity<sup>23,24</sup>.

## Radiobiological modelling

The currently favored and widely used model, that is used to describe the effect of irradiation on cell survival, is the linear-quadratic (LQ) model. The LQ model describes the radiation cell-survival curve by the following equation:

$$S = \exp(-\alpha D - \beta D^2)$$

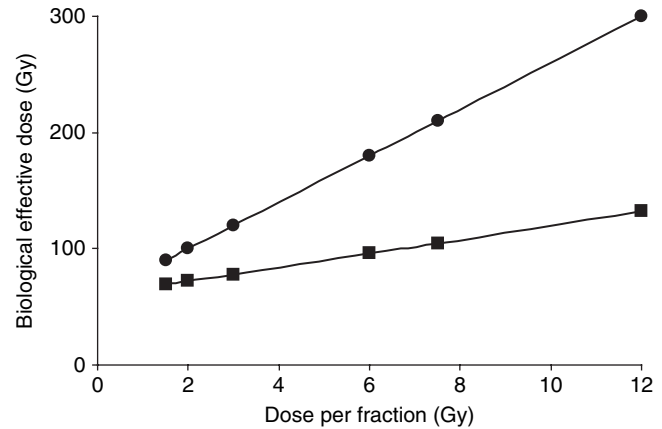
where  $S$  is the fraction of cells surviving a dose of  $D$ . The radiation cell-survival curve is continuously bending and the 'bendiness' of the curve is described by the  $\alpha/\beta$  ratio.  $\alpha/\beta$  ratios have been obtained experimentally for a number of normal tissues and tumors<sup>25</sup>, and tissues with a small  $\alpha/\beta$  have a 'bendier' curve compared with tissues with larger  $\alpha/\beta$  ratios. The LQ model has also been extended to account for tumor cell repopulation during the treatment period<sup>26</sup>. From the above LQ model equation, the biological effective dose (BED) or the quantity that is used to compare different fractionation regimens can be also be derived<sup>27</sup> and is expressed as:

$$\text{BED} = nd \times (1 + d/(\alpha/\beta))$$

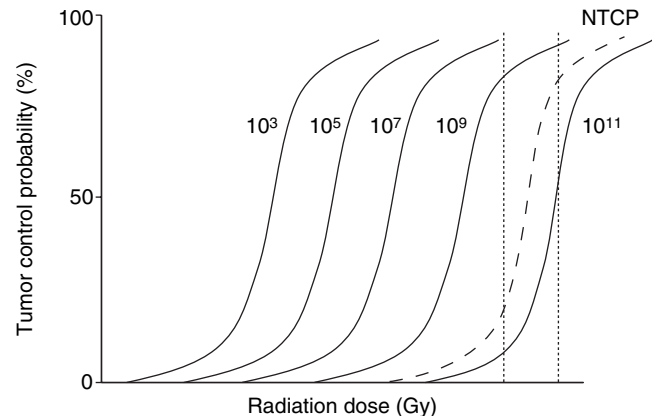
for 'n' well separated fractions of dose 'd'. It is apparent from the above equation that tissues with a lower  $\alpha/\beta$  such as late-responding tissues (e.g. neurological tissue) and some tumors such as prostate cancer<sup>28</sup> are more sensitive to changes in radiotherapy fraction size, compared with acutely responding tissues (e.g. mucosa) and most tumors. In other words, a rapid increase of total biological dose occurs with increasing dose per fraction in tissues which have a low  $\alpha/\beta$  (Figure 3.1).

Tumor control probability (TCP) curves are often used to relate the radiation dose with clinical outcome. Due to the random nature of cell killing by radiation, a Poisson model is used to calculate the TCP<sup>29</sup>. TCP curves approximate a sigmoid shape (Figure 3.2), with a steep relationship between dose and TCP between 10% and 90% for any one tumor or a population of identical tumors<sup>30</sup>. The shape and steepness of the TCP curve is affected by a number of factors, such as intrinsic radiosensitivity and heterogeneity in tumor cell kinetics<sup>30,31</sup>.

The relationship of both the TCP and the normal tissue complication probability (NTCP) with radiation dose are sigmoid in shaped. Therefore, for maximal therapeutic gain, the radiotherapy dose should result in maximal probability of tumor control with minimal (or reasonably acceptable) frequency of complications (Figure 3.2; therapeutic index). A leftward shift of the TCP curve, resulting in a larger separation between the TCP and NTCP curves and a therapeutic gain may result from factors such as smaller tumor burden or higher



**Figure 3.1** Theoretical illustration of the relationship between the biological effective dose (BED) and the dose per fraction. The top line (closed circles) is characteristic of late-responding tissues that typically have a small  $\alpha/\beta$ , where the BED increases considerably with increase in fraction size. For acutely responding tissues and most tumors, which have a large  $\alpha/\beta$ , the impact of changes in fraction size on BED are less pronounced (closed squares). For comparison, the overall treatment duration is the same for the different fractionation schemes in the above illustration.



**Figure 3.2** Schematic representation of tumor control probability (TCP) curves (unbroken lines) for different numbers of clonogenic cells and a theoretical normal tissue complication probability (NTCP) curve (dashed line) with radiation dose. TCP curves shift to the right with increase in clonogen numbers, with a worsening in therapeutic index. In this figure, the TCP curves for the largest clonogen number is unlikely to benefit from treatment with radiotherapy alone and these tumors are best managed with a combined modality treatment.

inherent tumor radiosensitivity. As illustrated in Figure 3.2, a worsening of the therapeutic index is seen with increase in tumor burden. In such situations, where the radiation dose needed to obtain tumor control is associated with a high probability of normal tissue toxicity, patients would be ideally managed with combination therapy, for example surgery followed by radiotherapy.

## Biological basis of adjuvant radiotherapy

Subclinical disease refers to disease that has no recognizable clinical signs or symptoms and hence is not evident on clinical or radiological examination. It most often refers to occult metastases distant from the primary site or clinically undetected extensions of the primary tumor.

The threshold for detection of disease in apparently normal tissue is dependent on factors such as technical limitation of the imaging modalities used, the anatomical site of disease and the density and distribution of clonogens in the tissue. For example, the size criteria that is often used to differentiate malignant from benign conditions radiologically, limits in imaging resolution and technical difficulties in obtaining pathological samples from very small and inaccessible lesions have generally limited the diagnosis of tumors to lesions above 1 cm in size. However, in order for a lesion to reach a size of 1 cm<sup>3</sup>, 10<sup>9</sup> tumor cells clustered together are required. Subclinical lesions may therefore contain anywhere from 1 (10<sup>0</sup>) to 10<sup>n</sup> clonogens, where 10<sup>n</sup> is the limit for detection of subclinical disease (e.g. 10<sup>9</sup> clonogens for a 1 cm lesion). Additionally, the absence of any cancer clonogens in a proportion of patients after primary therapy makes estimation of subclinical disease in individual instances extremely difficult. Treatment decisions are therefore based on several tumor and patient characteristics outlined later in this chapter.

The terms subclinical and microscopic disease are often used interchangeably, but subclinical disease is not always microscopic (especially, if the clonogens are not aggregated together for microscopic detection), although advances in imaging are bringing the two terms together. Improvements in imaging techniques, the use of functional imaging such as positron emission tomography (PET)<sup>32,33</sup> and molecular methods to detect subclinical disease<sup>34</sup> would allow for further refinement in adjuvant management.

## CURRENT PERSPECTIVE

### General principles of adjuvant radiotherapy

Since radiation, like surgery, is a local treatment modality, the primary aim of adjuvant radiotherapy is to improve disease control in the irradiated area by eradication of subclinical disease. There is strong evidence that such improvements in disease control achieved with radiotherapy may translate to enhanced overall survival rates as evidenced in tumors such as rectal cancer<sup>35,36</sup> and small cell lung cancer<sup>37</sup>. In breast cancer, the impact of local

control on overall survival<sup>6</sup> is however confounded by several factors such as the state of systemic micrometastatic burden at the time of locoregional adjuvant radiotherapy and the effect of radiation on normal tissue morbidity<sup>38,39</sup>.

### Side-effects of radiotherapy

The potential benefit of treatment has to be carefully balanced against radiotherapy-induced side-effects prior to administration of adjuvant radiotherapy. Radiotherapy-induced side-effects can be broadly classified as early (acute) or late, based on the time-frame of their manifestation. Early toxicities (Table 3.1) from radiation tend to arise during radiotherapy and can last from 6 weeks to 3 months after conclusion of radiotherapy. These are usually due to direct damage to the parenchymal tissue cells that are sensitive to irradiation. Late toxicities are usually apparent from 3 months after completion of radiotherapy (Table 3.2) and are attributed to damage to microvasculature and mesenchymal cells. However, the exact etiology is unknown and given the differences of the extent of toxicities observed between patients, inherent radiosensitivity of patients is also likely to contribute to the development of late effects<sup>24,40,41</sup>. Long-term morbidity such as cardiovascular mortality<sup>42</sup> and induction of new lung cancers<sup>43</sup> may occur several years after

**Table 3.1** Summary of early side-effects with radiotherapy

<i>Site</i>	<i>Early effects</i>
Skin	Erythema, pruritus, dry desquamation, moist desquamation
Oral mucosa	Mucositis
Esophagus	Esophagitis – dysphagia
Lung	Radiation pneumonitis – cough, shortness of breath
Liver	Radiation hepatitis – nausea, vomiting, raised hepatic transaminases
Stomach	Gastritis – indigestion, heartburn, excess wind
Small bowel	Enteritis – abdominal cramps, nausea, vomiting, diarrhea
Rectum	Proctitis – tenesmus, diarrhea
Bladder	Cystitis – frequency, urgency, dysuria
Systemic	Lethargy
Hemopoietic	Anemia, leucopenia, thrombocytopenia

**Table 3.2** Summary of late side-effects with radiotherapy

<i>Site</i>	<i>Late effects</i>
Skin	Fibrosis, pigmentation, telangiectasia, late ulceration
Mucosa	Fibrosis, stricture, fistula
Salivary glands	Xerostomia (permanent in 80% after 40–60 Gy (2Gy/fraction))
Kidney	Chronic radiation nephritis (inability to concentrate urine, nocturia), benign hypertension, proteinuria, malignant hypertension
Bone/cartilage	Growth retardation in young children (limb shortening, scoliosis), radionecrosis (mandible/femoral head), external ear cartilage necrosis
Lung	Radiation pneumonitis
Marrow	Myelofibrosis
Gonads	Sterility, genetic mutations
Tumorigenesis	Induction of second malignancies

completion of adjuvant radiotherapy in breast cancer patients. It is therefore imperative to take into account all treatment induced side-effects that may have an overall impact on patient morbidity and mortality, prior to planning of radiotherapy. As the severity of side-effects is dependent on the dose of radiotherapy and the extent of the organ irradiated (volume effect)<sup>44</sup>, it is possible to limit the side-effects by careful planning of treatment by reducing the amount of normal tissue being irradiated using modern techniques. Advances in imaging and their integration in radiotherapy planning, and radiation delivery techniques, e.g. computed tomography (CT) planning, integration of PET in planning, conformal radiotherapy, intensity-modulated radiotherapy, and image-guided radiotherapy may allow safe but appropriate reduction in the volume of normal tissue that is irradiated during treatment<sup>45–48</sup> and eventually help to minimize the toxicities associated with radiotherapy.

### Patient selection for adjuvant radiotherapy

The extent and need for adjuvant radiotherapy is based on the underlying patterns of potential disease spread<sup>49,50</sup> and tumor-specific factors<sup>51,52</sup>, respectively. The anatomical extent of adjuvant irradiation is primarily dictated by the natural history and patterns of disease spread. For instance, in breast tumors, increased survival is seen after locoregional postoperative adjuvant irradiation to the resected tumor bed and nodal drainage areas that are

contiguous with the primary tumor<sup>53,54</sup>. In contrast, a survival advantage is observed in patients with small cell lung cancer who achieve complete remission of the primary tumor with chemotherapy, followed by radiotherapy to an organ (brain) that is non-contiguous to the primary tumor (lung)<sup>37</sup>.

Tumor-specific factors such as tumor stage, grade and involvement of regional lymph nodes are associated with a higher risk of local recurrence<sup>51,52</sup> and primarily determine the need for treatment with adjuvant radiotherapy. The number and importance of tumor-specific factors vary between tumor types and risk factor stratification algorithms have been propounded for a number of tumor types that aid in the decision-making process<sup>55–57</sup>.

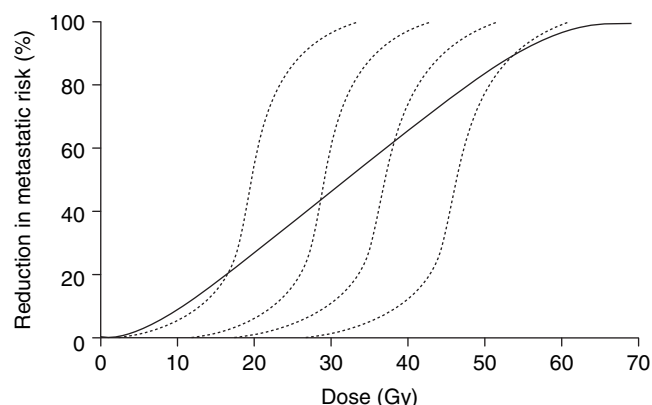
Finally, the decision to administer adjuvant radiotherapy is most importantly guided by an overall assessment of the individual clinical situation and a careful clinical risk and benefit analysis. The potential risk of disease recurrence has to be balanced against the risks associated with treatment (Tables 3.1 and 3.2), as a proportion of patients will not develop disease recurrence<sup>58</sup> after primary treatment alone. In summary, identification of patients for treatment with adjuvant radiotherapy will be dictated by the risk of local recurrence, the age of the patient, nature and severity of toxicity relative to the potential benefit, and the efficacy of systemic therapies (introduction of adjuvant chemotherapy has limited the role of adjuvant lung irradiation in patients with primary bone tumors<sup>59,60</sup>). Most importantly, competing causes of morbidity and mortality that may have an impact on overall patient survival need to be considered before embarking on a course of adjuvant radiotherapy.

### Dose considerations in adjuvant radiotherapy

Initially, it was generally believed that doses of 45–50 Gy (in 1.8–2 Gy fractions) were sufficient to eradicate about 90% of subclinical disease, whether delivered before or after surgery<sup>7,61</sup>. However, it soon became clinically evident that higher doses (approximately 60 Gy) were required to attain equivalent control in the postoperative setting<sup>62</sup>. Several reasons for this discrepancy have been suggested, including hypoxia in surgically disturbed tissue<sup>62</sup>, but the most plausible explanation is likely to be accelerated repopulation, as resection of tumor is associated with a gross decrease in total clonogenic number and improvement in hypoxia in the residual cancer cells<sup>63</sup>, resulting in accelerated repopulation.

In surgically undisturbed areas, a dose of 45–50 Gy (in 1.8–2 Gy fractions) or biologically equivalent doses are considered sufficient for subclinical disease. It has also been postulated, that in contrast to sigmoid-shape dose–response curves for macroscopic disease, the dose–response

curve of subclinical disease to radiation in surgically undisturbed areas, is linearly shaped, with no or a minimal threshold dose (Figure 3.3)<sup>64–67</sup>. This hypothesis, based on nearly exponential growth of subclinical disease and the uniform distribution of the logarithm of the cancer cell burden (i.e. a similar proportion of patients would have between 1 and 10 or 100 to 1000 or 1000 to 10000 metastatic clonogens, is supported by evidence from studies evaluating the reduction in the incidence of overt metastatic disease after elective irradiation<sup>64</sup>. It has therefore been suggested that worthwhile benefits in the control of subclinical disease can still be achieved by lower doses in surgically undisturbed areas, especially if necessitated by reduced tissue tolerance<sup>64</sup>.



**Figure 3.3** Modelling of dose–response curve for subclinical metastases based on the uniform distribution of the logarithm of numbers of metastatic cells ranging between 1 and  $10^9$  cells (dashed curves). The effective dose–response curve for the range of clonogens is linear shaped (unbroken curve). Adapted from reference 58.

## Preoperative versus postoperative radiotherapy

The decision to administer preoperative or postoperative radiotherapy tends to be site specific and is dictated by clinical experience and evidence. However, it is possible to provide a rationale for both preoperative and postoperative radiotherapy from general principles (Table 3.3). Very few trials have compared preoperative with postoperative radiotherapy and the interpretation of results is also complicated due the different dose-fractionation schedules used. An increased survival<sup>68</sup> with a decrease in locoregional recurrence<sup>69</sup> observed with postoperative radiotherapy compared with preoperative radiotherapy in head and neck cancer has resulted in postoperative radiotherapy becoming the standard in the treatment of head and neck cancer. In rectal cancer there is strong evidence that preoperative radiotherapy is more effective than postoperative radiotherapy and improves survival<sup>35</sup>, whereas in soft tissue sarcoma increased survival observed with preoperative radiotherapy is also associated with an increase in wound complications<sup>70</sup>.

## Time factors in adjuvant radiotherapy

The time interval between surgery and radiotherapy is an important factor in determining the outcome of adjuvant radiotherapy, as indirect evidence suggests that micrometastases grow at a faster rate compared with macroscopic disease<sup>58</sup>. Modelling studies based on clinical data have demonstrated that treatment delay in initiating adjuvant treatment after removal (or sterilization) of a primary tumor introduces a threshold into the dose–response curve of subclinical metastasis because existing subclinical cancer deposits continue to grow (Figure 3.4)<sup>58,65,71</sup>. Clinical studies in squamous cell carcinoma of the head and neck and adenocarcinoma of the rectum have

**Table 3.3** Comparison between preoperative and postoperative radiotherapy

<i>Preoperative radiotherapy</i>	<i>Postoperative radiotherapy</i>
Lower radiation dose (50 Gy in 1.8–2 Gy fractions)	Higher dose required (60 Gy in 1.8–2 Gy fractions)
Higher incidence of surgical complications <sup>77–79</sup>	Lower incidence of surgical complications Fixation of organs after surgery may result in a higher incidence of side-effects to radiotherapy
Volume of tissue requiring radiotherapy is generally smaller <sup>80</sup>	Volume of tissue requiring radiotherapy is usually larger to include whole surgical bed and drain sites
Patients cannot be selected for radiotherapy; a significant proportion not requiring radiotherapy may be treated	Patients not given unnecessary adjuvant radiotherapy
No delay in starting radiotherapy	Radiotherapy may be delayed because of surgical complications No delay in start of primary treatment
Inoperable or borderline tumor may be rendered operable <sup>81</sup>	Radiation can be specifically tailored to sites of concern. Targeting of boost radiation to positive disease margins and microscopic disease

demonstrated that prolonging the interval between surgery and radiotherapy has an adverse effect on local control<sup>58,72–76</sup>. More importantly, studies have also demonstrated that the overall treatment time of adjuvant radiotherapy is of greater importance than the gap between surgery and radiotherapy<sup>58</sup>. Since there is no lag-time for the onset of tumor repopulation during adjuvant pre- or postoperative radiotherapy, gaps in radiotherapy for subclinical disease may be detrimental from the first days of irradiation. One day of interruption

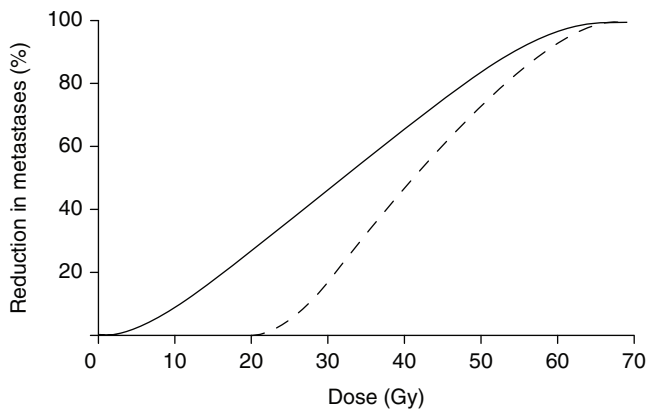
during adjuvant radiotherapy has, most likely, a larger negative impact on TCP than 1 day of extension of the interval between surgery and radiotherapy<sup>58</sup>. Therefore, it is imperative that adjuvant radiotherapy should be given as close as possible to the treatment of the primary, but more importantly that there is no prolongation of treatment, once it is initiated.

### Applications of adjuvant radiotherapy

The role of adjuvant radiotherapy in tumor sites such as breast, endometrium, seminomas, sarcomas, and rectum is well established and forms part of the initial management plan. The role of adjuvant radiotherapy in some tumor sites is summarized in Table 3.4.

### CONCLUSION

Adjuvant radiotherapy following a conservative surgical procedure allows the patient to be spared from the morbidities associated with radical surgery or radical radiotherapy, where higher doses of radiation are administered. It is likely that the use of adjuvant radiotherapy will increase in the future, together with an increase in usage of chemotherapy and/or novel biological agents, especially within the context of multi-modality management of cancer. In this scenario, the place of



**Figure 3.4** Effect of delay in starting treatment of subclinical disease (in surgically undisturbed areas) introduces a dose threshold (dashed curve) in the dose–response curve. Adapted from reference 71.

**Table 3.4** Summary of role of adjuvant in radiotherapy in different cancer sites

Site	Summary
Breast	Increases local control <sup>6,82</sup> ; some studies have also demonstrated an increase in overall survival <sup>53,54</sup>
Seminoma	Postorchidectomy radiotherapy to para-aortic lymph nodes reduces local recurrence <sup>83,84</sup>
Endometrium	Adjuvant radiotherapy to pelvis improves locoregional control <sup>85</sup> ; increases disease-free and overall survival <sup>86</sup> in early stage endometrial cancer
Small cell carcinoma of lung	Prophylactic cranial irradiation increases local control <sup>87</sup> ; improves survival in patients who achieve complete remission after chemotherapy <sup>37</sup>
Astrocytomas	Adjuvant radiotherapy increases survival in grade III and IV astrocytomas <sup>88,89</sup> increases progression-free but not overall survival in low-grade astrocytomas <sup>90</sup>
Rectal cancer	Pre- and postoperative radiotherapy decreases local recurrence <sup>35,36,91</sup> . Strong evidence that preoperative radiotherapy increases survival <sup>35</sup>
Vulvar cancer	Increases survival in node positive patients <sup>92</sup> . Organ preservation <sup>81,93</sup>
Esophageal cancer	Preoperative chemoradiotherapy reduces locoregional recurrence and increases overall survival, but is associated with increased treatment mortality <sup>94,95</sup>
Sarcomas	Adjuvant radiotherapy after limb-sparing surgery decreases local recurrence <sup>96,97</sup>
Head and neck	Adjuvant radiotherapy decreases local recurrence <sup>98</sup>
Urinary bladder	Organ preservation with conservative surgery and adjuvant chemoradiotherapy <sup>99,100</sup>

multi-disciplinary approach is especially important, with input from specialists such as oncologists (surgical and non-surgical), radiologists and pathologists at the outset, so that the optimal management decision is made before embarking on treatment.

## REFERENCES

- Mendenhall WM, Amdur RJ, Morris CG, Hinerman RW. T1-T2N0 squamous cell carcinoma of the glottic larynx treated with radiation therapy. *J Clin Oncol* 2001; 19: 4029.
- Epidermoid anal cancer: results from the UKCCCR randomised trial of radiotherapy alone versus radiotherapy, 5-fluorouracil, and mitomycin. UKCCCR Anal Cancer Trial Working Party. UK Co-ordinating Committee on Cancer Research. *Lancet* 1996; 348: 1049–54.
- Al-Sarraf M, LeBlanc M, Giri PG et al. Chemoradiotherapy versus radiotherapy in patients with advanced nasopharyngeal cancer: phase III randomized Intergroup study 0099. *J Clin Oncol* 1998; 16: 1310–7.
- Cooper JS, Guo MD, Herskovic A et al. Chemoradiotherapy of locally advanced esophageal cancer: long-term follow-up of a prospective randomized trial (RTOG 85-01). Radiation Therapy Oncology Group. *JAMA* 1999; 281: 1623–7.
- Green J, Kirwan J, Tierney J et al. Concomitant chemotherapy and radiation therapy for cancer of the uterine cervix. *Cochrane Database Syst Rev* 2005; (3): CD002225.
- Effects of radiotherapy and surgery in early breast cancer. An overview of the randomized trials. Early Breast Cancer Trialists' Collaborative Group. *N Engl J Med* 1995; 333: 1444–55.
- Fletcher GH. The evolution of the basic concepts underlying the practice of radiotherapy from 1949 to 1977. *Radiology* 1978; 127: 3–19.
- Fletcher GH, Evers WT. Radiotherapeutic management of surgical recurrences and postoperative residuals in tumors of the head and neck. *Radiology* 1970; 95: 185–8.
- Halsted WS. The results of operations for the cure of cancer of the breast performed at the Johns Hopkins Hospital from June, 1899, to January, 1894. *Johns Hopkins Hospital Reports* 1894–1895; 4: 297.
- Fisher B, Anderson S, Bryant J et al. Twenty-year follow-up of a randomized trial comparing total mastectomy, lumpectomy, and lumpectomy plus irradiation for the treatment of invasive breast cancer. *N Engl J Med* 2002; 347: 1233–41.
- Veronesi U, Banfi A, Del Vecchio M et al. Comparison of Halsted mastectomy with quadrantectomy, axillary dissection, and radiotherapy in early breast cancer: long-term results. *Eur J Cancer Clin Oncol* 1986; 22: 1085–9.
- Veronesi U, Cascinelli N, Mariani L et al. Twenty-year follow-up of a randomized study comparing breast-conserving surgery with radical mastectomy for early breast cancer. *N Engl J Med* 2002; 347: 1227–32.
- McMillan TJ, Steel GG. Molecular aspects of radiation biology. In: Steel GG, ed. *Basic Clinical Radiobiology*. London: Edward Arnold Publishers, 1993: 211–24.
- Steel GG, McMillan TJ, Peacock JH. The 5Rs of radiobiology. *Int J Radiat Biol* 1989; 56: 1045–8.
- Kaanders JH, Bussink J, van der Kogel AJ. ARCON: a novel biology-based approach in radiotherapy. *Lancet Oncol* 2002; 3: 728–37.
- Le QT, Taira A, Budenz S et al. Mature results from a randomized Phase II trial of cisplatin plus 5-fluorouracil and radiotherapy with or without tirapazamine in patients with resectable Stage IV head and neck squamous cell carcinomas. *Cancer* 2006; 106: 1940–9.
- Overgaard J, Hansen HS, Overgaard M et al. A randomized double-blind phase III study of nimorazole as a hypoxic radiosensitizer of primary radiotherapy in supraglottic larynx and pharynx carcinoma. Results of the Danish Head and Neck Cancer Study (DAHANCA) Protocol 5-85. *Radiother Oncol* 1998; 46: 135–46.
- Roberts SA, Hendry JH. Time factors in larynx tumor radiotherapy: lag times and intertumor heterogeneity in clinical datasets from four centers. *Int J Radiat Oncol Biol Phys* 1999; 45: 1247–57.
- Withers HR, Taylor JM, Maciejewski B. The hazard of accelerated tumor clonogen repopulation during radiotherapy. *Acta Oncol* 1988; 27: 131–46.
- Turesson I, Carlsson J, Brahme A et al. Biological response to radiation therapy. *Acta Oncol* 2003; 42: 92–106.
- Fertil B, Malaise EP. Intrinsic radiosensitivity of human cell lines is correlated with radioresponsiveness of human tumors: analysis of 101 published survival curves. *Int J Radiat Oncol Biol Phys* 1985; 11: 1699–707.
- West CM. Invited review: intrinsic radiosensitivity as a predictor of patient response to radiotherapy. *Br J Radiol* 1995; 68: 827–37.
- Bentzen SM. Potential clinical impact of normal-tissue intrinsic radiosensitivity testing. *Radiother Oncol* 1997; 43: 121–31.
- West CM, Davidson SE, Elyan SA et al. The intrinsic radiosensitivity of normal and tumour cells. *Int J Radiat Biol* 1998; 73: 409–13.
- Joiner MC. Molecular aspects of radiation biology. In: Steel GG, ed. *Basic Clinical Radiobiology*. London: Edward Arnold Publishers, 1993: 55–64.
- Dale RG, Hendry JH, Jones B et al. Practical methods for compensating for missed treatment days in radiotherapy, with particular reference to head and neck schedules. *Clin Oncol (R Coll Radiol)* 2002; 14: 382–93.
- Thames HD Jr, Withers HR, Peters LJ, Fletcher GH. Changes in early and late radiation responses with altered dose fractionation: implications for dose-survival relationships. *Int J Radiat Oncol Biol Phys* 1982; 8: 219–26.
- Bentzen SM, Ritter MA. The alpha/beta ratio for prostate cancer: what is it, really? *Radiother Oncol* 2005; 76: 1–3.
- Porter EH. The statistics of dose/cure relationships for irradiated tumors. Part I. *Br J Radiol* 1980; 53: 210–27.
- Zagars GK, Schultheiss TE, Peters LJ. Inter-tumor heterogeneity and radiation dose-control curves. *Radiother Oncol* 1987; 8: 353–61.
- Suwinski R, Taylor JM, Withers HR. The effect of heterogeneity in tumor cell kinetics on radiation dose-response.

## ACKNOWLEDGMENT

We would like to thank Dr C M L West for her valuable comments and Mr J Cullen for his help in the preparation of this book chapter.



- An exploratory investigation of a plateau effect. *Radiother Oncol* 1999; 50: 57–66.
32. Hollenbeak CS, Lowe VJ, Stack BC Jr. The cost-effectiveness of fluorodeoxyglucose 18-F positron emission tomography in the N0 neck. *Cancer* 2001; 92: 2341–8.
  33. Price P, Jones T. Can positron emission tomography (PET) be used to detect subclinical response to cancer therapy? The EC PET Oncology Concerted Action and the EORTC PET Study Group. *Eur J Cancer* 1995; 31A: 1924–7.
  34. Taback B, Morton DL, O'Day SJ et al. The clinical utility of multimarker radiotherapy-PCR in the detection of occult metastasis in patients with melanoma. *Recent Results Cancer Res* 2001; 158: 78–92.
  35. Glimelius B, Gronberg H, Jarhult J et al. A systematic overview of radiation therapy effects in rectal cancer. *Acta Oncol* 2003; 42: 476–92.
  36. Adjuvant radiotherapy for rectal cancer: a systematic overview of 8,507 patients from 22 randomised trials. *Lancet* 2001; 358: 1291–304.
  37. Cranial irradiation for preventing brain metastases of small cell lung cancer in patients in complete remission. *Cochrane Database Syst Rev* 2000; (4): CD002805.
  38. Kryj M, Maciejewski B, Withers HR et al. Incidence and kinetics of distant metastases in patients with operable breast cancer. *Neoplasma* 1997; 44: 3–11.
  39. Van de Steene J, Soete G, Storme G. Adjuvant radiotherapy for breast cancer significantly improves overall survival: the missing link. *Radiother Oncol* 2000; 55: 263–72.
  40. Fajardo LF. The pathology of ionizing radiation as defined by morphologic patterns. *Acta Oncol* 2005; 44: 13–22.
  41. Turesson I, Nyman J, Holmberg E, Oden A. Prognostic factors for acute and late skin reactions in radiotherapy patients. *Int J Radiat Oncol Biol Phys* 1996; 36: 1065–75.
  42. Cuzick J, Stewart H, Rutqvist L et al. Cause-specific mortality in long-term survivors of breast cancer who participated in trials of radiotherapy. *J Clin Oncol* 1994; 12: 447–53.
  43. Deutsch M, Land SR, Begovic M et al. The incidence of lung carcinoma after surgery for breast carcinoma with and without postoperative radiotherapy. Results of National Surgical Adjuvant Breast and Bowel Project (NSABP) clinical trials B-04 and B-06. *Cancer* 2003; 98: 1362–8.
  44. Emami B, Lyman J, Brown A et al. Tolerance of normal tissue to therapeutic irradiation. *Int J Radiat Oncol Biol Phys* 1991; 21: 109–22.
  45. Chen L, Price RA Jr, Nguyen TB et al. Dosimetric evaluation of MRI-based treatment planning for prostate cancer. *Phys Med Biol* 2004; 49: 5157–70.
  46. Grosu AL, Pierr M, Weber WA et al. Positron emission tomography for radiation treatment planning. *Strahlenther Onkol* 2005; 181: 483.
  47. Liu HH, Wang X, Dong L et al. Feasibility of sparing lung and other thoracic structures with intensity-modulated radiotherapy for non-small-cell lung cancer. *Int J Radiat Oncol Biol Phys* 2004; 58: 1268.
  48. Neal AJ, Oldham M, Dearnaley DP. Comparison of treatment techniques for conformal radiotherapy of the prostate using dose-volume histograms and normal tissue complication probabilities. *Radiother Oncol* 1995; 37: 29.
  49. Cox JD, Yesner RA. Causes of treatment failure and death in carcinoma of the lung. *Yale J Biol Med* 1981; 54: 201–7.
  50. Wood A, Robson N, Tung K et al. Patterns of supradiaphragmatic metastases in testicular germ cell tumors. *Clin Radiol* 1996; 51: 273–6.
  51. Elder EE, Kennedy CW, Gluch L et al. Patterns of breast cancer relapse. *Eur J Surg Oncol* 2006; 32: 922–7.
  52. Zlotecki RA, Katz TS, Morris CG et al. Adjuvant radiation therapy for resectable retroperitoneal soft tissue sarcoma: the University of Florida experience. *Am J Clin Oncol* 2005; 28: 310–6.
  53. Overgaard M, Jensen MB, Overgaard J et al. Postoperative radiotherapy in high-risk postmenopausal breast-cancer patients given adjuvant tamoxifen: Danish Breast Cancer Cooperative Group DBCG 82c randomised trial. *Lancet* 1999; 353: 1641–8.
  54. Ragaz J, Olivetto IA, Spinelli JJ et al. Locoregional radiation therapy in patients with high-risk breast cancer receiving adjuvant chemotherapy: 20-year results of the British Columbia randomized trial. *J Natl Cancer Inst* 2005; 97: 116–26.
  55. Goldhirsch A, Glick JH, Gelber RD et al. Meeting highlights: international expert consensus on the primary therapy of early breast cancer 2005. *Ann Oncol* 2005; 16: 1569–83.
  56. Goldhirsch A, Wood WC, Gelber RD et al. Meeting highlights: updated international expert consensus on the primary therapy of early breast cancer. *J Clin Oncol* 2003; 21: 3357–65.
  57. Leyvraz S, Jelic S. ESMO Minimum Clinical Recommendations for diagnosis, treatment and follow-up of soft tissue sarcomas. *Ann Oncol* 2005; 16(Suppl 1): i69–70.
  58. Suwinski R, Withers HR. Time factor and treatment strategies in subclinical disease. *Int J Radiat Biol* 2003; 79: 495–502.
  59. Mintz U, Keinan Z, Wainrach B. Prophylactic irradiation of the lung in Ewing's sarcoma. *Chest* 1976; 70: 393–5.
  60. Whelan JS, Burcombe RJ, Janinis J et al. A systematic review of the role of pulmonary irradiation in the management of primary bone tumors. *Ann Oncol* 2002; 13: 23.
  61. Fletcher GH. Clinical dose response curve of subclinical aggregates of epithelial cells and its practical applications in the management of human cancers. In: Friedman M, ed. *Biological and Clinical Basis of Radiosensitivity*. Springfield, IL: Charles C. Thomas, 1974: 485–501.
  62. Fletcher GH. *Textbook of Radiotherapy*, 2nd edn. Philadelphia: Lea & Febiger, 1973.
  63. Jones B, Dale RG. Cell loss factors and the linear-quadratic model. *Radiother Oncol* 1995; 37: 136–9.
  64. Withers HR, Peters LJ, Taylor JM. Dose-response relationship for radiation therapy of subclinical disease. *Int J Radiat Oncol Biol Phys* 1995; 31: 353–9.
  65. Suwinski R, Lee SP, Withers HR. Dose-response relationship for prophylactic cranial irradiation in small cell lung cancer. *Int J Radiat Oncol Biol Phys* 1998; 40: 797–806.
  66. Suwinski R, Maciejewski B, Withers HR. Dose-response relationship for elective neck irradiation of head and neck cancer – facts and controversies. *Neoplasma* 1998; 45: 107–12.
  67. Ben-Josef E. Letter to the editor: regarding Withers et al. *IJROBP* 31:353–9; 1995. *Int J Radiat Oncol Biol Phys* 1995; 32: 1267.
  68. Vandenbrouck C, Sancho H, Le Fur R et al. Results of a randomized clinical trial of preoperative irradiation versus postoperative in treatment of tumors of the hypopharynx. *Cancer* 1977; 39: 1445–9.
  69. Tupchong L, Scott CB, Blitzer PH et al. Randomized study of preoperative versus postoperative radiation therapy in advanced head and neck carcinoma: long-term follow-up of RTOG study 73-03. *Int J Radiat Oncol Biol Phys* 1991; 20: 21–8.
  70. O'Sullivan B, Davis AM, Turcotte R et al. Preoperative versus postoperative radiotherapy in soft-tissue sarcoma of the limbs: a randomised trial. *Lancet* 2002; 359: 2235–41.
  71. Withers HR, Suwinski R. Radiation dose response for subclinical metastases. *Semin Radiat Oncol* 1998; 8: 224.



72. Ang KK, Trotti A, Brown BW et al. Randomized trial addressing risk features and time factors of surgery plus radiotherapy in advanced head-and-neck cancer. *Int J Radiat Oncol Biol Phys* 2001; 51: 571.
73. Awwad HK, Lotayef M, Shouman T et al. Accelerated hyperfractionation (AHF) compared to conventional fractionation (CF) in the postoperative radiotherapy of locally advanced head and neck cancer: influence of proliferation. *Br J Cancer* 2002; 86: 517–23.
74. Trotti A, Klotch D, Endicott J et al. Postoperative accelerated radiotherapy in high-risk squamous cell carcinoma of the head and neck: long-term results of a prospective trial. *Head Neck* 1998; 20: 119–23.
75. Muriel VP, Tejada MR, de Dios Luna del Castillo J. Time-dose-response relationships in postoperatively irradiated patients with head and neck squamous cell carcinomas. *Radiother Oncol* 2001; 60: 137–45.
76. Suwinski R, Sowa A, Rutkowski T et al. Time factor in postoperative radiotherapy: a multivariate locoregional control analysis in 868 patients. *Int J Radiat Oncol Biol Phys* 2003; 56: 399–412.
77. Frykholm GJ, Glimelius B, Pahlman L. Preoperative or postoperative irradiation in adenocarcinoma of the rectum: final treatment results of a randomized trial and an evaluation of late secondary effects. *Dis Colon Rectum* 1993; 36: 564–72.
78. Suit HD, Mankin HJ, Wood WC et al. Preoperative, intraoperative, and postoperative radiation in the treatment of primary soft tissue sarcoma. *Cancer* 1985; 55: 2659–67.
79. Taylor JM, Mendenhall WM, Parsons JT et al. The influence of dose and time on wound complications following post-radiation neck dissection. *Int J Radiat Oncol Biol Phys* 1992; 23: 41–6.
80. Nielsen OS, Cummings B, O'Sullivan B et al. Preoperative and postoperative irradiation of soft tissue sarcomas: effect of radiation field size. *Int J Radiat Oncol Biol Phys* 1991; 21: 1595–9.
81. Moore DH, Thomas GM, Montana GS et al. Preoperative chemoradiation for advanced vulvar cancer: a phase II study of the Gynecologic Oncology Group. *Int J Radiat Oncol Biol Phys* 1998; 42: 79–85.
82. Clarke M, Collins R, Darby S et al. Effects of radiotherapy and of differences in the extent of surgery for early breast cancer on local recurrence and 15-year survival: an overview of the randomised trials. *Lancet* 2005; 366: 2087–106.
83. Duchesne GM, Horwich A, Dearnaley DP et al. Orchidectomy alone for stage I seminoma of the testis. *Cancer* 1990; 65: 1115–8.
84. Fossa SD, Horwich A, Russell JM et al. Optimal planning target volume for stage I testicular seminoma: a Medical Research Council randomized trial. Medical Research Council Testicular Tumor Working Group. *J Clin Oncol* 1999; 17: 1146.
85. Scholten AN, van Putten WL, Beerman H et al. Postoperative radiotherapy for Stage 1 endometrial carcinoma: long-term outcome of the randomized PORTEC trial with central pathology review. *Int J Radiat Oncol Biol Phys* 2005; 63: 834–8.
86. Macdonald OK, Sause WT, Lee RJ et al. Adjuvant radiotherapy and survival outcomes in early-stage endometrial cancer: a multi-institutional analysis of 608 women. *Gynecol Oncol* 2006; 103: 661–6.
87. Lester JF, MacBeth FR, Coles B. Prophylactic cranial irradiation for preventing brain metastases in patients undergoing radical treatment for non-small-cell lung cancer: a Cochrane Review. *Int J Radiat Oncol Biol Phys* 2005; 63: 690–4.
88. Kristiansen K, Hagen S, Kollevold T et al. Combined modality therapy of operated astrocytomas grade III and IV. Confirmation of the value of postoperative irradiation and lack of potentiation of bleomycin on survival time: a prospective multicenter trial of the Scandinavian Glioblastoma Study Group. *Cancer* 1981; 47: 649–52.
89. Chang CH, Horton J, Schoenfeld D et al. Comparison of postoperative radiotherapy and combined postoperative radiotherapy and chemotherapy in the multidisciplinary management of malignant gliomas. A joint Radiation Therapy Oncology Group and Eastern Cooperative Oncology Group study. *Cancer* 1983; 52: 997–1007.
90. van den Bent MJ, Afra D, de Witte O et al. Long-term efficacy of early versus delayed radiotherapy for low-grade astrocytoma and oligodendroglioma in adults: the EORTC 22845 randomised trial. *Lancet* 2005; 366: 985–90.
91. Kapiteijn E, Marijnen CA, Nagtegaal ID et al. Preoperative radiotherapy combined with total mesorectal excision for resectable rectal cancer. *N Engl J Med* 2001; 345: 638–46.
92. Homesley HD, Bundy BN, Sedlis A et al. Radiation therapy versus pelvic node resection for carcinoma of the vulva with positive groin nodes. *Obstet Gynecol* 1986; 68: 733–40.
93. van Doorn HC, Ansink A, Verhaar-Langereis M et al. Neoadjuvant chemoradiation for advanced primary vulvar cancer. *Cochrane Database Syst Rev* 2006; (3): CD003752.
94. Fiorica F, Di Bona D, Schepis F et al. Preoperative chemoradiotherapy for oesophageal cancer: a systematic review and meta-analysis. *Gut* 2004; 53: 925–30.
95. Urschel JD, Vasan H. A meta-analysis of randomized controlled trials that compared neoadjuvant chemoradiation and surgery to surgery alone for resectable esophageal cancer. *Am J Surg* 2003; 185: 538–43.
96. Yang JC, Chang AE, Baker AR et al. Randomized prospective study of the benefit of adjuvant radiation therapy in the treatment of soft tissue sarcomas of the extremity. *J Clin Oncol* 1998; 16: 197–203.
97. Lindberg RD, Martin RG, Romsdahl MM et al. Conservative surgery and postoperative radiotherapy in 300 adults with soft-tissue sarcomas. *Cancer* 1981; 47: 2391–7.
98. Bartelink H, Breur K, Hart G et al. The value of postoperative radiotherapy as an adjuvant to radical neck dissection. *Cancer* 1983; 52: 1008–13.
99. Herr HW. Conservative management of muscle-infiltrating bladder cancer: prospective experience. *J Urol* 1987; 138: 1162–3.
100. Rodel C, Grabenbauer GG, Kuhn R et al. Combined-modality treatment and selective organ preservation in invasive bladder cancer: long-term results. *J Clin Oncol* 2002; 20: 3061–71.

# Principles of chemotherapy

4

Emily Chan and Jordan D Berlin

---

In recent years, chemotherapy options have expanded from cell cycle-specific and cell cycle non-specific drugs to biological therapies and small molecule targeted agents. To understand how these agents work, one needs to first have an understanding of tumor growth kinetics.

## TUMOR GROWTH KINETICS

In the early 1970s, it was recognized that leukemia cells divided rapidly in a logarithmic fashion since virtually all of the cells were actively dividing. However, single agent chemotherapy for the most part did not result in cures. This understanding led to models for the use of combination chemotherapy based upon the concepts of fractional or log-kill, as proposed by Skipper *et al.*<sup>1,2</sup>, heterogeneous drug-resistant tumor clones, as proposed by Goldie and Coldman<sup>3,4</sup>, and drug synergy<sup>5-7</sup>. Later, it was recognized that human solid tumors increased by Gompertzian growth<sup>8</sup> rather than by exponential growth because not all cells are actively dividing. Small tumors grew faster than larger tumors because as a tumor grows, feedback inhibition results in slower growth. This understanding of Gompertzian growth led to the concept of dose density in chemotherapy, as proposed by Norton and Simon<sup>7,9</sup>. The idea behind this concept is that when tumors are small, they have the highest percentage of proliferating cells, making them more susceptible to chemotherapy agents aimed at dividing cells.

## GOALS OF CHEMOTHERAPY

Chemotherapy may be given with curative or palliative intent.

Neoadjuvant chemotherapy is chemotherapy that is given before surgical resection, with the goals being downsizing and possible downstaging of the tumor. Sometimes, neoadjuvant chemotherapy can render a tumor that is initially unresectable to a resectable tumor or it can allow the surgeon to perform a less extensive operation. For example,

neoadjuvant chemotherapy can render a large breast mass small enough that a lumpectomy is possible instead of a mastectomy<sup>10</sup>. A combination of neoadjuvant chemotherapy followed by surgery and adjuvant chemotherapy has shown superiority to surgery alone for resectable gastric cancer<sup>11</sup>. The use of neoadjuvant chemotherapy has also shown a survival advantage in patients with at least clinical stage T3 bladder cancer<sup>12-14</sup>. The use of neoadjuvant chemotherapy can also help guide therapy after surgery. For example, patients with Ewing's sarcoma or high grade osteosarcoma can be treated with neoadjuvant chemotherapy, and if they do not respond, the chemotherapy can be changed after surgery.

Often, neoadjuvant chemotherapy is given in conjunction with radiation therapy, with the same goals of tumor downsizing and downstaging. The tumors in which neoadjuvant chemoradiation is commonly used include rectal cancer and esophageal cancer. In rectal cancer, neoadjuvant chemoradiation yields a pathological complete response in approximately 10–30% of patients<sup>15-18</sup>. In addition, some patients who would have required an abdominoperineal resection without neoadjuvant chemoradiation were able to undergo a low anterior resection after chemoradiation, with improvement in quality of life. Similarly, for esophageal cancer, neoadjuvant chemoradiation yields a pathological complete response in approximately 20–25% of patients, although there is no good way to identify which of the patients have achieved a complete pathological response other than surgery<sup>19-22</sup>. Another advantage of neoadjuvant chemoradiation is that it is better tolerated before surgery than afterwards.

Adjuvant chemotherapy refers to chemotherapy given after surgery to try to prevent the cancer from recurring. Its goal is to treat any micrometastatic disease that may have been left behind at the time of surgery. Table 4.1 lists some commonly used adjuvant chemotherapy regimens. Adjuvant chemotherapy is routinely considered for high risk stage II colorectal cancer, stage III colorectal cancer<sup>23-28</sup>, stage I, II and III breast cancer<sup>29-36</sup>, stage Ib to III lung cancer<sup>37-40</sup>, node positive or pT2–4 bladder cancer<sup>41-44</sup>, high risk stage I ovarian cancer, stage II to III ovarian cancer<sup>45-49</sup>,

**Table 4.1** Commonly used adjuvant chemotherapy regimens

<i>Cancer</i>	<i>Chemotherapy regimen</i>
Adjuvant breast cancer	AC→T(H): doxorubin, cyclophosphamide followed by paclitaxel (+trastuzumab for HER2/Neu + disease)  CMF: cyclophosphamide, methotrexate, 5-fluorouracil  CAF: cyclophosphamide, doxorubicin, 5-fluorouracil  FEC: 5-fluorouracil, epirubicin, cyclophosphamide  TAC: docetaxel, doxorubicin, cyclophosphamide
Adjuvant colorectal cancer	FOLFOX: folinic acid, 5-fluorouracil, oxaliplatin  5-FU/LV: 5-fluorouracil, folinic acid  FLOX: folinic acid, 5-fluorouracil, oxaliplatin
Adjuvant lung cancer	cisplatin, vinorelbine
Adjuvant ovarian cancer	carboplatin, paclitaxel
Adjuvant gastric cancer	ECF: Epirubicin, cyclophosphamide, 5-fluorouracil*
Adjuvant pancreatic cancer	Gemcitabine

\*Used neoadjuvantly and adjuvantly.

and pancreatic cancer<sup>50–53</sup>. Adjuvant intravesical therapy is recommended for superficial bladder cancer or carcinoma *in situ* of the bladder<sup>54</sup>. Adjuvant chemotherapy is also used in Ewing's sarcoma, high grade osteosarcoma, and rhabdomyosarcoma<sup>55–62</sup>.

Adjuvant chemoradiation is given with the goal of preventing locoregional recurrence. In many studies comparing chemoradiation with radiation alone in the adjuvant setting, the addition of chemotherapy increases local control over that provided by radiation alone. It is commonly used in patients with a positive surgical margin, such as in pancreas cancer. It is commonly given in patients with cervical cancer with positive pelvic nodes, a positive surgical margin, or a positive parametrium<sup>63</sup>. In patients with stage II or III rectal cancer who did not receive neoadjuvant chemoradiation, adjuvant chemoradiation should be given<sup>64,65</sup>.

Patients with metastatic solid tumors are treated with palliative chemotherapy. In general, once cancer has spread outside the primary site, it is considered incurable, and

palliative chemotherapy is given with the goal of trying to control the growth of the tumor. In general, even if a patient with metastatic disease responds to chemotherapy, they will at some point eventually progress. Because chemotherapy is not curative in the metastatic setting, it should only be offered to patients with a reasonable performance status.

There are, however, some instances where metastatic disease is potentially curable. Testicular cancer is potentially curable with chemotherapy even if it has already metastasized<sup>66</sup>. In colorectal cancer, isolated liver or lung metastases that are resectable are potentially curable<sup>67–69</sup>. The majority of these patients will recur, but a small proportion can be cured by complete surgical resection of metastases.

There are also times when chemotherapy can render initially unresectable metastases to resectable disease. The tumor type in which it has been most studied is colorectal cancer with liver metastases. As more effective chemotherapy drugs have been developed for metastatic colorectal cancer, this situation has become more common<sup>70</sup>.

## CYTOTOXIC CHEMOTHERAPY

The traditional chemotherapeutic agents were cytotoxic drugs that were either cell cycle specific or cell cycle non-specific. Cell cycle-specific drugs work at a specific stage of the cell cycle.

Many chemotherapeutic agents work only on actively dividing cells and therefore will not work on the cells in the G<sub>0</sub> phase. Cell cycle-specific chemotherapy drugs work at a specific stage of the cell cycle. For example, antimetabolites, such as 5-fluorouracil, gemcitabine, and methotrexate, are more active against the S phase of the cell cycle<sup>71</sup>. Vinca alkaloids<sup>72</sup>, epipodophyllotoxins<sup>73</sup>, and taxanes<sup>72</sup> work on the M phase of the cell cycle. Vinca alkaloids, such as vincristine, vinblastine, and vinorelbine, bind microtubule protein in its dimeric form and promotes depolymerization, leading to mitotic arrest. The taxanes, such as paclitaxel and docetaxel, bind microtubules and enhance tubulin polymerization, leading to mitotic arrest.

Cell cycle non-specific chemotherapeutic agents work at all stages of the cell cycle. The oldest class of chemotherapeutic agents, the alkylating agents, such as nitrogen mustards, are an example of such agents<sup>74</sup>. They bind to the negatively charged sites on DNA and cause DNA crosslinking and double strand DNA breaks, leading to ineffective cellular activity and cell death. The anthracyclines, including doxorubicin, epirubicin, daunorubicin, mitoxantrone, and idarubicin, are another example of cell cycle-non-specific chemotherapeutic drugs<sup>73</sup>. They form free radicals that result in DNA strand breaks. In addition, they inhibit topoisomerase II by forming a complex with the enzyme and DNA. The anthracyclines are also

known to have cumulative cardiotoxicity, and cardiac function should be monitored closely in patients receiving these agents. The camptothecins, such as irinotecan and topotecan, inhibit topoisomerase I and cause single strand DNA breaks<sup>73</sup>. The platinum, such as cisplatin, carboplatin, and oxaliplatin, crosslink DNA and inhibit

DNA synthesis and transcription<sup>75</sup>. They have activity across a broad range of solid tumors and are cell cycle non-specific.

Table 4.2 lists some commonly used chemotherapeutic drugs, their mechanism of action, and their approved indications.

**Table 4.2** Commonly used cytotoxic chemotherapy drugs

<i>Drug</i>	<i>Category</i>	<i>Mechanism of action</i>	<i>Approved indications</i>
Bleomycin	Antibiotic	Inhibition of DNA synthesis	Head and neck cancer, testicular cancer, malignant pleural effusion, cervical cancer, penile carcinoma, vulva carcinoma, Hodgkin's disease, non-Hodgkin's lymphoma
Carboplatin	Platinum	DNA cross linking. Cell cycle non-specific	Ovarian cancer
Cisplatin	Platinum	DNA cross linking, inhibition of DNA synthesis and transcription	Testicular cancer, ovarian cancer, bladder cancer, lung cancer, mesothelioma, gastric cancer
Cyclophosphamide	Alkylating agent	DNA crosslinking	Breast carcinoma, ovarian carcinoma, retinoblastoma, malignant lymphoma, Hodgkin's disease, CLL, AML, ALL, multiple myeloma, mycosis fungoides
Docetaxel	Taxane	Tubulin polymerization, mitotic arrest	Breast cancer, gastric cancer, head and neck cancer, prostate cancer, non-small cell lung cancer
Doxorubicin	Anthracycline	Topoisomerase II inhibitor	Breast carcinoma, bladder carcinoma, soft tissue sarcoma, bone sarcoma, AIDS-related Kaposi's sarcoma, ovarian carcinoma, thyroid carcinoma, gastric carcinoma, bronchogenic carcinoma, AML, ALL, Hodgkin's disease, malignant lymphoma, Wilms' tumor, neuroblastoma
Epirubicin	Anthracycline	Topoisomerase II inhibitor	Breast cancer
Etoposide	Epipodophyllotoxin	Topoisomerase II inhibitor	Small cell lung cancer, testicular cancer
5-fluorouracil	Antimetabolite	Inhibition of DNA and RNA synthesis	Colorectal carcinoma, breast carcinoma, gastric carcinoma, pancreatic carcinoma, basal cell carcinoma
Gemcitabine	Antimetabolite	Inhibition of DNA synthesis	Pancreatic carcinoma, breast carcinoma, non-small cell lung cancer, ovarian cancer

*Continued*

Table 4.2 Continued

<i>Drug</i>	<i>Category</i>	<i>Mechanism of action</i>	<i>Approved indications</i>
Ifosfamide	Alkylating agent	DNA crosslinking	Testicular cancer
Irinotecan	Camptothecin	Topoisomerase I inhibitor	Colorectal cancer
Oxaliplatin	Platinum	DNA crosslinking	Colorectal cancer
Paclitaxel	Taxane	Tubulin polymerization, mitotic arrest	Breast carcinoma, ovarian carcinoma, AIDS-related Kaposi's sarcoma, non-small cell lung cancer
Topotecan	Camptothecin	Topoisomerase I inhibitor	Ovarian carcinoma, lung cancer, cervical cancer
Vinblastine	Vinca alkaloid	Microtubule depolymerization	Testicular cancer, germ cell tumors, breast cancer, Kaposi's sarcoma, Hodgkin's disease, malignant lymphoma, mycosis fungoides

CLL, chronic lymphocytic leukemia; AML, acute myelogenous leukemia; ALL, acute lymphocytic leukemia.

## BIOLOGICAL THERAPY

### Monoclonal antibody therapy

With advances in the basic sciences, newer therapies have emerged in the treatment of cancer. One of the key developments was the use of antibody therapy. The first antibody approved for clinical use was rituximab, a chimeric monoclonal antibody against CD20, for non-Hodgkins lymphoma. It added to the efficacy of chemotherapy and also had single agent activity<sup>76</sup>. Subsequently, other anti-CD20 antibodies were developed that incorporated a radioactive moiety as part of their anticancer activity. Ibritumomab tiuxetan<sup>77</sup> is an anti-CD20 monoclonal antibody with an yttrium-90 label, and tositumomab<sup>78</sup> is an anti-CD20 monoclonal antibody with an iodine-131 label.

In solid tumors, the first monoclonal antibody approved for clinical use was trastuzumab. It is a humanized monoclonal antibody against the HER2 protein and was Food and Drug Administration (FDA) approved in 1998 for HER2 positive metastatic breast cancer<sup>79</sup>. Subsequently it has also been shown to be useful in the adjuvant setting<sup>80–82</sup>. Trastuzumab has been shown to cause a drop in the ejection fraction and congestive heart failure. In the adjuvant trial, cardiac dysfunction was high in patients who received trastuzumab in combination with anthracycline and cyclophosphamide. As a result, patients with HER2-Neu positive breast cancer are treated with trastuzumab after the completion of anthracycline and cyclophosphamide in the adjuvant setting.

Bevacizumab, a humanized monoclonal antibody against vascular endothelial growth factor (VEGF), was the first antiangiogenic agent to be FDA approved in 2004. Although it did not have any significant single agent activity, it was shown, in a pivotal phase III trial, to add to the response rate, progression free survival, and overall survival over chemotherapy alone in patients with metastatic colorectal cancer receiving treatment with irinotecan, 5-fluorouracil, and leucovorin in the first line setting<sup>83</sup>. Subsequent studies showed that it added to the efficacy of chemotherapy in metastatic colorectal cancer in the second line setting<sup>84</sup> and to the efficacy of chemotherapy in breast<sup>85</sup> and lung cancer<sup>86</sup>. It is now being actively explored in the adjuvant setting. It has also been shown to be active as a single agent in renal cell cancer<sup>87</sup>.

Although bevacizumab is generally well tolerated, it does have a few uncommon but potentially serious and life threatening side-effects. Hypertension is a common side-effect but is generally easily controlled with antihypertensive medication. Proteinuria is also a common side-effect. Uncommon but potentially life threatening side-effects include increased risk of bleeding and thrombosis, both venous and arterial, congestive heart failure, bowel perforation, hemorrhage, and impaired wound healing<sup>88</sup>. Bevacizumab has a half-life of approximately 20 days, which should be taken into account when planning elective surgery. The appropriate safe interval between the last dose of bevacizumab and elective surgery is unknown, but a recent study suggests that a 5-week interval between bevacizumab and liver resection may be adequate<sup>89</sup>. There have

also been reports that liver regeneration may be impaired after bevacizumab therapy<sup>90</sup>.

Cetuximab, a chimeric monoclonal antibody against epidermal growth factor receptor (EGFR), was initially FDA approved in 2004 for the treatment of patients with metastatic colorectal cancer intolerant of or refractory to irinotecan. Interestingly, a phase II study demonstrated a 23% response rate (RR) for the combination of cetuximab and irinotecan in patients with colorectal tumors who had progressed on irinotecan chemotherapy, suggesting that it may reverse irinotecan resistance<sup>91</sup>. More recently, in 2006, cetuximab received FDA approval for the treatment of head and neck cancer. A phase III trial had demonstrated improved locoregional control and survival when cetuximab was added to radiation over radiation alone<sup>92</sup>. In addition, in a phase II trial in the recurrent or metastatic setting, single agent cetuximab had been shown to have a 13% response rate in patients with head and neck cancer who had previously received platinum-based therapy<sup>93</sup>. Cetuximab is currently being actively studied in combination with chemotherapy in the first line setting for metastatic colorectal cancer and in the adjuvant setting for colon cancer.

Panitumumab, a fully human monoclonal antibody against EGFR, was recently approved by the FDA for treatment of refractory metastatic colorectal cancer. It is the first fully human monoclonal antibody approved for clinical use. Its mechanism of action is similar to cetuximab.

Table 4.3 lists some commonly used monoclonal antibodies in solid tumors, their mechanism of action, and their approved indications.

### Small molecule targeted agents

With the advances in molecular and cellular biology, anti-neoplastic agents have become more refined. Drugs have been designed against specific proteins in the tumor cell, and the responses seen with some of these agents have caused major shifts in the treatment of certain tumor types.

Imatinib, a small molecule tyrosine kinase inhibitor, was designed to target the *bcr-abl* transforming oncogene in chronic myelogenous leukemia (CML). It also targets *c-kit* and platelet derived growth factor (PDGF). In a phase I study, complete hematological responses were seen in 53 of 54 patients with CML given daily doses of 300 mg or more of imatinib in a population that had failed the then current standard therapy at the time<sup>94</sup>. These impressive results were later confirmed in a larger study<sup>95</sup>. It was FDA approved in 2001 for CML and dramatically altered the natural history of this previously poor prognosis disease. In 2002, imatinib also received an FDA indication for the treatment of gastrointestinal stromal tumor (GIST). Approximately 80–85% of GISTs

harbor an activating mutation in the proto-oncogene *c-KIT*, which encodes a tyrosine kinase. Constitutively activating mutations have been found in exons 11, 9, 13, and 17 of *c-kit*. GIST has traditionally been considered a chemoresistant tumor; however, imatinib has been shown to produce responses in over 50% of GIST patients, with a progression-free survival of 2 years<sup>96,97</sup>.

Other FDA approved tyrosine kinase inhibitors include gefitinib, which has limited activity in lung cancer, erlotinib, which is approved for lung and pancreas cancer<sup>98,99</sup>, and sunitinib, which is approved for renal cell carcinoma and GIST<sup>100,101</sup>. Other FDA approved targeted agents include sorafenib, an inhibitor of RAF kinase, VEGFR, and PDGFR, for renal cell carcinoma<sup>102</sup>, and bortezomib, a proteasome inhibitor, for multiple myeloma<sup>103</sup>.

Table 4.3 lists some commonly used small molecule targeted agents, their mechanism of action, and their approved indications.

### Drug delivery

The majority of chemotherapy is delivered systemically, either intravenously, orally, intramuscularly, or subcutaneously. There are, however, instances when regional therapy is used. The purpose of regional chemotherapy is to deliver higher concentrations of chemotherapy for longer periods of time locally to achieve higher local cell kill while minimizing systemic toxicity.

The addition of intraperitoneal chemotherapy has been shown to be superior to standard intravenous chemotherapy in three randomized phase III clinical trials for the management of small volume residual disease in epithelial ovarian cancer with improvement in overall survival for the intraperitoneal chemotherapy containing arm in all three trials<sup>104–106</sup>. The amount of systemic absorption depends on the chemotherapeutic agent. For example, a substantial proportion of the cisplatin given intraperitoneally will be absorbed systemically. However, paclitaxel administered intraperitoneally is poorly absorbed.

Cytoreductive surgery combined with perioperative intraperitoneal chemotherapy has also shown a survival advantage compared with systemic chemotherapy for isolated peritoneal carcinomatosis from colorectal carcinoma. The patients who do best with this approach are the ones who are able to undergo complete cytoreduction. However, this procedure has been associated with a high morbidity (23–44%) and mortality (0–12%) rate<sup>107</sup>.

Many chemotherapy agents given systemically do not achieve therapeutic levels in the central nervous system (CNS) because of the blood–brain barrier. To achieve therapeutic levels, intrathecal chemotherapy is used. Intrathecal chemotherapy may be given by lumbar puncture or through an Ommaya reservoir. Intrathecal chemotherapy

**Table 4.3** Commonly used biological drugs

<i>Drug</i>	<i>Category</i>	<i>Mechanism of action</i>	<i>Approved indications</i>
Trastuzumab	Humanized monoclonal antibody	Binds HER2 protein, thereby inhibiting tumor cell growth and mediating ADCC	HER2 overexpressing breast cancer
Bevacizumab	Humanized monoclonal antibody	Binds VEGF and inhibits formation of new blood vessels	Colorectal cancer, non-small cell lung cancer
Cetuximab	Chimeric monoclonal antibody	Binds to EGFR and blocks phosphorylation and activation of receptor associated kinases	Colorectal cancer, head and neck cancer
Panitumumab	Human monoclonal antibody	Binds EGFR and inhibits binding of ligands for EGFR	Colorectal cancer
Imatinib mesylate	Tyrosine kinase inhibitor	Inhibition of bcr-abl, c-kit, PDGFR	Philadelphia chromosome positive CML, Philadelphia positive ALL, chronic eosinophilic leukemia, dermatofibrosarcoma protuberans, Kit positive GIST, hypereosinophilic syndrome, MDS with PDGFR gene rearrangement, chronic myeloproliferative disorder with PDGFR gene rearrangement, systemic mast cell disease
Erlotinib	Tyrosine kinase inhibitor	Inhibition of phosphorylation of tyrosine kinase associated with EGFR	Non-small cell lung cancer, pancreatic cancer
Sunitinib	Tyrosine kinase inhibitor	Inhibition of tumor cell proliferation and angiogenesis	GIST, renal cell carcinoma
Sorafenib	Multikinase inhibitor	Blocks Raf kinase, VEGFR-2, VEGFR-3, PDGFR-B, Flt3, KIT, and RET	Renal cell carcinoma

ADCC, antibody-dependent cellular cytotoxicity; VEGF, vascular endothelial growth factor; EGFR, epidermal growth factor receptor; PDGFR, platelet derived growth factor receptor; GIST, gastrointestinal stromal tumor; CML, chronic myelogenous leukemia; ALL, acute lymphoid leukemia; MDS, Myelodysplastic syndrome.

is used to treat CNS metastases or as prophylaxis against CNS disease in acute lymphoblastic leukemia<sup>108</sup>. Commonly used intrathecal chemotherapy agents include methotrexate and cytarabine.

Isolated limb perfusion (ILP) with intra-arterial administration of chemotherapy has been used success-

fully for unresectable limb melanoma and isolated soft tissue sarcoma (STS) of the limb. To date, there have been no randomized clinical trials comparing ILP with other treatment options for unresectable limb melanoma, but unresectable limb melanoma is generally considered an accepted indication for this treatment modality.

Similarly, to date, there have been no randomized clinical trials comparing ILP with other treatment options for locally unresectable STS. However, a retrospective multicenter study of eight European centers involving 186 patients with unresectable STS of the limb treated with melphalan and tumor necrosis factor (TNF)- $\alpha$  ILP demonstrated a 29% complete response, 53% partial response, 16% stable disease, and 2% progressive disease, with a limb salvage rate of 82%<sup>109</sup>.

Hepatic arterial infusion (HAI) with chemotherapy has been used successfully for the treatment of liver only metastases in metastatic colorectal cancer<sup>110,111</sup>. Liver metastases greater than 3 cm derive most of their blood supply from the hepatic artery, whereas normal liver cells derive most of their blood supply from the portal vein. HAI allows the delivery of high dose regional chemotherapy with limited systemic toxicity. Furthermore, floxuridine, a chemotherapy agent commonly given via HAI, undergoes first pass metabolism in the liver; thereby, limiting systemic toxicity. HAI chemotherapy has shown higher objective response rates compared with systemic chemotherapy for liver only metastases in colorectal cancer and improved time to progression and overall survival in the adjuvant setting following hepatic resection. Toxicities of HAI therapy include peptic ulceration, chemical hepatitis, and biliary sclerosis.

Transcatheter arterial chemoembolization (TACE) is another modality that takes advantage of the dual blood supply of the liver<sup>112</sup>. Since the majority of the blood supply of primary and metastatic hepatic tumors are derived

from the hepatic artery, high doses of chemotherapy can be delivered regionally via the hepatic artery and be cleared by the liver, resulting in low systemic toxicity. The chemotherapy agents are given along with embolic agents to cut off the blood supply of the tumor and prolong exposure to the chemotherapeutic agents. Commonly used chemotherapy agents for this purpose include doxorubicin, cisplatin, and mitomycin. This therapy is used most commonly in hepatocellular carcinoma.

Intravesical therapy has been used successfully in superficial bladder cancer and carcinoma *in situ* of the bladder<sup>113</sup>. Agents used in intravesical therapy include chemotherapy agents such as mitomycin, thiotepa, epirubicin, doxorubicin, and gemcitabine, and biological agents such as *Bacillus Calmette-Guerin* (BCG). Intravesical therapy has been shown to prevent recurrence.

Intrapleural chemotherapy has been studied in the treatment of malignant pleural effusions, but has not been shown to be better than pleuradesis<sup>114</sup>.

## CONCLUSION

Chemotherapy treatments for cancer have advanced considerably in the past several decades. In addition, supportive measures have also improved significantly, and chemotherapy today is much better tolerated than it was only a decade ago. There are more treatment options, more effective therapies, and new ways of delivering drugs preferentially to the tumor.

## REFERENCES

1. Skipper HE, Schabel FM, Wilcox WS. Experimental evaluation of potential anticancer agents. XIV. Further studies on certain basic concepts underlying chemotherapy of leukemia. *Cancer Chemother Rep* 1965; 45: 5–28.
2. Skipper HE, Schabel FM, Wilcox WS. Experimental evaluation of potential anticancer agents. XII. On the criteria and kinetics associated with curability of experimental leukemia. *Cancer Chemother Rep* 1964; 35: 1–111.
3. Goldie JH, Coldman AJ. A mathematic model for relating the drug sensitivity of tumors to their spontaneous mutation rate. *Cancer Treat Rep* 1979; 63: 1727–33.
4. Goldie JH, Coldman AJ. A model for tumor response to chemotherapy: an integration of the stem cell and somatic mutation hypotheses. *Cancer Invest* 1985; 3: 553–64.
5. DeVita VT Jr, Young RC, Canellos GP. Combination versus single agent chemotherapy: a review of the basis for selection of drug treatment of cancer. *Cancer* 1975; 35: 98–110.
6. Chu E, DeVita VT. Principles of cancer management: chemotherapy. In: DeVita VT, Hellman S, Rosenberg SA, eds. *Cancer: Principles and Practice of Oncology*, 6th edn. New York: Lippincott Williams and Wilkins, 2001: 289–306.
7. Norton L. Conceptual basis for advances in the systemic drug therapy of breast cancer. *Semin Oncol* 1997; 24: S11–2.
8. Norton L, Simon R, Brereton HD et al. Predicting the course of Gompertzian growth. *Nature* 1976; 264: 542–5.
9. Norton L, Simon R. Tumor size, sensitivity to therapy, and design of treatment schedules. *Cancer Treat Rep* 1977; 61: 1307–17.
10. Kaufmann M, Hortobagyi GN, Goldhirsch A et al. Recommendations from an international expert panel on the use of neoadjuvant (primary) systemic treatment of operable breast cancer: an update. *J Clin Oncol* 2006; 24: 1940–9.
11. Cunningham D, Allum WH, Stenning SP et al. Perioperative chemotherapy versus surgery alone for resectable gastroesophageal cancer. *N Engl J Med* 2006; 355: 11–20.
12. International collaboration of trialists. Neoadjuvant cisplatin, methotrexate, and vinblastine chemotherapy for



- muscle-invasive bladder cancer: a randomized controlled trial. *Lancet* 1999; 354: 533–40.
13. Grossman HB, Natale RB, Tangen CM et al. Neoadjuvant chemotherapy plus cystectomy compared with cystectomy alone for locally advanced bladder cancer. *N Engl J Med* 2003; 349: 859–66.
  14. Garcia JA, Dreicer R. Adjuvant and neoadjuvant chemotherapy for bladder cancer: management and controversies. *Nat Clin Pract Urol* 2005; 2: 32–7.
  15. Sauer R, Becker H, Hohenberger W et al. Preoperative versus postoperative chemoradiotherapy for rectal cancer. *N Engl J Med* 2004; 351: 1731–40.
  16. Bosset JF, Calais G, Mineur L et al. Enhanced tumoricidal effect of chemotherapy with preoperative radiotherapy for rectal cancer: preliminary results – EORTC 22921. *J Clin Oncol* 2005; 23: 5620–7.
  17. Gerard JP, Conroy T, Bonnetain F et al. Preoperative radiotherapy with or without concurrent fluorouracil and leucovorin in T3–4 rectal cancers: results of FFC0 9203. *J Clin Oncol* 2006; 24: 4620–5.
  18. Calvo FA, Serrano FJ, Diaz-Gonzalez JA et al. Improved incidence of pT<sub>0</sub> downstaged surgical specimens in locally advanced rectal cancer (LARC) treated with induction oxaliplatin plus 5-fluorouracil and preoperative chemoradiation. *Ann Oncol* 2006; 17: 1103–10.
  19. Urschel JD, Vasan H. A meta-analysis of randomized controlled trials that compared neoadjuvant chemoradiation and surgery to surgery alone for resectable esophageal cancer. *Am J Surg* 2003; 185: 538–43.
  20. Walsh TN, Noonan N, Hollywood D et al. A comparison of multimodal therapy and surgery for esophageal adenocarcinoma. *N Engl J Med* 1996; 335: 462–7.
  21. Urba SG, Orringer MB, Turrisi A et al. Randomized trial of preoperative chemoradiation versus surgery alone in patients with locoregional esophageal carcinoma. *J Clin Oncol* 2001; 19: 305–13.
  22. Bosset J-F, Gignoux M, Triboulet J-P et al. Chemoradiotherapy followed by surgery compared with surgery alone in squamous-cell cancer of the esophagus. *N Engl J Med* 1997; 337: 161–7.
  23. Wolmark N, Rockette H, Fisher B et al. The benefit of leucovorin-modulated fluorouracil as postoperative adjuvant therapy for primary colon cancer: results from National Surgical Adjuvant Breast and Bowel Project Protocol C-03. *J Clin Oncol* 1993; 11: 1879–87.
  24. Mamounas E, Wieland S, Wolmark N et al. Comparative efficacy of adjuvant chemotherapy in patients with Dukes' B versus Dukes' C colon cancer: results from four National Surgical Adjuvant Breast and Bowel Project adjuvant studies (C-01, C-02, C-03, and C-04). *J Clin Oncol* 1999; 17: 1349–55.
  25. Andre T, Boni C, Mounedji-Boudiaf L et al. Oxaliplatin, fluorouracil, and leucovorin as adjuvant treatment for colon cancer. *N Engl J Med* 2004; 350: 2343–51.
  26. Benson AB, Schrag D, Somerfield MR et al. American Society of Clinical Oncology recommendations on adjuvant chemotherapy for stage II colon cancer. *J Clin Oncol* 2004; 22: 3408–19.
  27. Gill S, Loprinzi CL, Sargent DJ et al. Pooled analysis of fluorouracil-based adjuvant therapy for stage II and III colon cancer: who benefits and by how much? *J Clin Oncol* 2004; 22: 1797–1806.
  28. Figueredo A, Charette ML, Maroun J et al. Adjuvant therapy for stage II colon cancer: a systematic review from the Cancer Care Ontario Program in Evidence-based care's Gastrointestinal Cancer Disease Site Group. *J Clin Oncol* 2004; 3395–407.
  29. National Institutes of Health Consensus Development Panel. National Institutes of Health Consensus Development Conference statement: adjuvant therapy for breast cancer, November 1–3, 2000. *J Natl Cancer Inst* 2001; 93: 979–89.
  30. Early Breast Cancer Trialists' Collaborative Group. Effects of adjuvant tamoxifen and of cytotoxic therapy on mortality in early breast cancer. An overview of 61 randomized trials among 28,896 women. *N Engl J Med* 1988; 319: 1681–92.
  31. Mansour EG, Gray R, Shatila AH et al. Survival advantage of a djuvant chemotherapy in high-risk node-negative breast cancer: ten-year analysis – an intergroup study. *J Clin Oncol* 1998; 16: 3486–92.
  32. Fisher B, Jeong J-H, Dignam J et al. Findings from recent National Surgical Adjuvant Breast and Bowel Project adjuvant studies in stage I breast cancer. *J Natl Cancer Inst Monographs* 2001; 30: 62–6.
  33. Citron ML, Berry DA, Cirincione C et al. Randomized trial of dose-dense versus conventionally scheduled and sequential versus concurrent combination chemotherapy as postoperative adjuvant treatment of node-positive primary breast cancer: first report of Intergroup Trial C9741/Cancer and Leukemia Group B Trial 9741. *J Clin Oncol* 2003; 1431–9.
  34. Paradiso A, Schittulli F, Cellamare G et al. Randomized clinical trial of adjuvant fluorouracil, epirubicin, and cyclophosphamide chemotherapy for patients with fast-roliferating, node-negative breast cancer. *J Clin Oncol* 2001; 19: 3929–37.
  35. Piccart-Gebhart MJ, Procter M, Leyland-Jones B et al. Trastuzumab after adjuvant chemotherapy in HER2-positive breast cancer. *N Engl J Med* 2005; 353: 1659–72.
  36. Joensuu H, Kellokumpu-Lehtinen P-L, Bono P et al. Adjuvant docetaxel or vinorelbine with or without trastuzumab for breast cancer. *N Engl J Med* 2006; 354: 809–20.
  37. The International Adjuvant Lung Cancer Trial Collaborative Group. Cisplatin-based adjuvant chemotherapy in patients with completely resected non-small-cell lung cancer. *N Engl J Med* 2004; 350: 351–60.
  38. Pisters KMW, Le Chevalier T. Adjuvant chemotherapy in completely resected non-small-cell lung cancer. *J Clin Oncol* 2005; 23: 3270–8.
  39. Niiranen A, Niitamo-Korhonen S, Kouri M et al. Adjuvant chemotherapy after radical surgery for non-small-cell lung cancer: a randomized study. *J Clin Oncol* 1992; 10: 1927–32.
  40. Hotta K, Matsuo K, Ueoka H et al. Role of adjuvant chemotherapy in patients with resected non-small-cell lung cancer: reappraisal with a meta-analysis of randomized controlled trials. *J Clin Oncol* 2004; 22: 3860–7.
  41. Logothetis CJ, Johnson DE, Chong C et al. Adjuvant cyclophosphamide, doxorubicin, and cisplatin chemotherapy for bladder cancer: an update. *J Clin Oncol* 1988; 6: 1590–6.
  42. Freiha F, Reese J, Torti FM. A randomized trial of radical cystectomy versus radical cystectomy plus cisplatin, vinblastine and methotrexate chemotherapy for muscle invasive bladder cancer. *J Urol* 1996; 155: 495–500.
  43. Skinner DG, Daniels JR, Russell CA et al. The role of adjuvant chemotherapy following cystectomy for invasive bladder cancer: a prospective comparative trial. *J Urol* 1991; 145: 459–64.
  44. Ruggeri EM, Giannarelli D, Bria E et al. Adjuvant chemotherapy in muscle-invasive bladder carcinoma. A pooled analysis from Phase III studies. *Cancer* 2006; 106: 783–8.

45. Young RC, Walton LA, Ellenberg SS et al. Adjuvant therapy in stage I and stage II epithelial ovarian cancer. Results of two prospective randomized trials. *N Engl J Med* 1990; 322: 1021–7.
46. Trimbos JB, Vergote I, Bolis G et al. Impact of adjuvant chemotherapy and surgical staging in early-stage ovarian carcinoma: european Organisation for Research and Treatment of Cancer – Adjuvant ChemoTherapy in Ovarian Neoplasm Trial. *J Natl Cancer Inst* 2003; 95: 113–25.
47. International Collaborative Ovarian Neoplasm (ICON1) Collaborators. International Collaborative Ovarian Neoplasm Trial 1: a randomized trial of adjuvant chemotherapy in women with early-stage ovarian cancer. *J Natl Cancer Inst* 2003; 95: 125–32.
48. International Collaborative Ovarian Neoplasm 1 (ICON1) and European Organisation for Research and Treatment of Cancer Collaborators – Adjuvant ChemoTherapy in Ovarian Neoplasm (EORTC-ACTION). International Collaborative Ovarian Neoplasm Trial 1 and Adjuvant ChemoTherapy in Ovarian Cancer Trial: Two parallel randomized phase III trials of adjuvant chemotherapy in patients with early-stage ovarian carcinoma. *J Natl Cancer Inst* 2003; 95: 105–12.
49. Ozols RF, Bundy BN, Greer BE et al. Phase III trial of carboplatin and paclitaxel compared with cisplatin and paclitaxel in patients with optimally resected stage III ovarian cancer: a Gynecologic Oncology Group Study. *J Clin Oncol* 2003; 21: 3194–200.
50. Stocken DD, Buchler MW, Dervenis C et al. Meta-analysis of randomized adjuvant therapy trials for pancreatic cancer. *Br J Cancer* 2005; 92: 1372–81.
51. Oettle H, Post S, Neuhaus P et al. Adjuvant chemotherapy with gemcitabine vs observation in patients undergoing curative-intent resection of pancreatic cancer. *JAMA* 2007; 297: 267–77.
52. Neoptolemos JP, Dunn JA, Stocken DD et al. Adjuvant chemoradiotherapy and chemotherapy in resectable pancreatic cancer: a randomized controlled trial. *Lancet* 2001; 358: 1576–85.
53. Neoptolemos JP, Stocken DD, Friess H et al. A randomized trial of chemoradiotherapy and chemotherapy after resection of pancreatic cancer. *N Engl J Med* 2004; 350: 1200–10.
54. Lamm DL, Blumenstein BA, Crawford ED et al. A randomized trial of intravesical doxorubicin and immunotherapy with bacilli Calmette-Guerin for transitional-cell carcinoma of the bladder. *N Engl J Med* 1991; 325: 1205–9.
55. Rosen G, Caparros B, Nirenberg A et al. Ewing's sarcoma: ten-year experience with adjuvant chemotherapy. *Cancer* 1981; 47: 2204–13.
56. Link MP, Goorin AM, Miser AW et al. The effect of adjuvant chemotherapy on relapse-free survival in patients with osteosarcoma of the extremity. *N Engl J Med* 1986; 314: 1600–6.
57. Pratt CB, Champion JE, Fleming ID et al. Adjuvant chemotherapy for osteosarcoma of the extremity. Long-term results of two consecutive prospective protocol studies. *Cancer* 1990; 65: 439–45.
58. Link MP, Goorin AM, Horowitz M et al. Adjuvant chemotherapy of high-grade osteosarcoma of the extremity. Updated results of the multi-institutional osteosarcoma study. *Clin Orthop Relat Res* 1991; 270: 8–14.
59. Eilber F, Giuliano A, Eckardt J et al. Adjuvant chemotherapy for osteosarcoma: a randomized prospective trial. *J Clin Oncol* 1987; 5: 21–6.
60. Sarcoma Meta-analysis Collaboration. Adjuvant chemotherapy for localized resectable soft-tissue sarcoma of adults: meta-analysis of individual data. *Lancet* 1997; 350: 1647–54.
61. Crist W, Gehan EA, Ragab AH et al. The Third Intergroup Rhabdomyosarcoma Study. *J Clin Oncol* 1995; 13: 610–30.
62. Crist WM, Anderson JR, Meza JL et al. Intergroup Rhabdomyosarcoma Study-IV: results for patients with nonmetastatic disease. *J Clin Oncol* 2001; 19: 3091–102.
63. Peters WA, Liu PY, Barrett RJ et al. Concurrent chemotherapy and pelvic radiation therapy compared with pelvic radiation therapy alone as adjuvant therapy after radical surgery in high-risk early-stage cancer of the cervix. *J Clin Oncol* 2000; 18: 1606–13.
64. Gastrointestinal Tumor Study Group. Prolongation of the disease-free interval in surgically treated rectal carcinoma. *N Engl J Med* 1985; 312: 1465–72.
65. Krook JE, Moertel CG, Gunderson LL et al. Effective surgical adjuvant therapy for high-risk rectal carcinoma. *N Engl J Med* 1991; 324: 709–15.
66. International Germ Cell Cancer Collaborative Group. International Germ Cell Consensus Classification: a prognostic factor-based staging system for metastatic germ cell cancers. *J Clin Oncol* 1997; 15: 594–603.
67. Garden OJ, Rees M, Poston GJ et al. Guidelines for resection of colorectal cancer liver metastases. *Gut* 2006; 55 (Suppl III): iii1–8.
68. Fong Y, Cohen AM, Fortner JG et al. Liver resection for colorectal metastases. *J Clin Oncol* 1997; 15: 938–46.
69. Inoue M, Ohta M, Iuchi K et al. Benefits of surgery for patients with pulmonary metastases from colorectal carcinoma. *Ann Thorac Surg* 2004; 78: 238–44.
70. Delaunoy T, Alberts SR, Sargent DJ et al. Chemotherapy permits resection of metastatic colorectal cancer: experience from Intergroup N9741. *Ann Oncol* 2005; 16: 425–9.
71. Chu E, Mota AC, Fogarasi MC. Antimetabolites. In: DeVita VT, Hellman S, Rosenberg SA, eds. *Cancer: Principles and Practice of Oncology*, 6th edn. New York: Lippincott Williams and Wilkins, 2001: 388–415.
72. Rowinsky EK, Tolcher AW. Antimicrotubule agents. In: DeVita VT, Hellman S, Rosenberg SA, eds. *Cancer: Principles and Practice of Oncology*, 6th edn. New York: Lippincott Williams and Wilkins, 2001: 431–59.
73. Stewart CF, Ratain MJ. Topoisomerase interactive agents. In: DeVita VT, Hellman S, Rosenberg SA, eds. *Cancer: Principles and Practice of Oncology*, 6th edn. New York: Lippincott Williams and Wilkins, 2001: 415–31.
74. Colvin OM. Antitumor alkylating agents. In: DeVita VT, Hellman S, Rosenberg SA, eds. *Cancer: Principles and Practice of Oncology*, 6th edn. New York: Lippincott Williams and Wilkins, 2001: 363–76.
75. Johnson SW, Stevenson JP, Dwyer PJ. Cisplatin and its analogues. In: DeVita VT, Hellman S, Rosenberg SA, eds. *Cancer: Principles and Practice of Oncology*, 6th edn. New York: Lippincott Williams and Wilkins, 2001: 376–88.
76. Coiffier B, Lepage E, Briere J et al. CHOP chemotherapy plus Rituximab compared with CHOP alone in elderly patients with diffuse large B-cell lymphoma. *N Engl J Med* 2002; 346: 235–42.
77. Witzig TE, Gordon LI, Cabanillas F et al. Randomized controlled trial of yttrium-90-labeled ibritumomab tiuxetan radioimmunotherapy versus rituximab immunotherapy for patients with relapsed or refractory low-grade, follicular, or transformed

- B-cell non-Hodgkin's lymphoma. *J Clin Oncol* 2002; 20: 2453–63.
78. Fisher RI, Kaminski MS, Wahl RL et al. Tositumomab and iodine-131 tositumomab produces durable complete remissions in a subset of heavily pretreated patients with low-grade and transformed non-Hodgkin's lymphomas. *J Clin Oncol* 2005; 23: 7565–73.
  79. Slamon DJ, Leyland-Jones B, Shak S et al. Use of chemotherapy plus a monoclonal antibody against HER2 for metastatic breast cancer that overexpresses HER2. *N Engl J Med* 2001; 344: 783–92.
  80. Piccart-Gebhart MJ, Procter M, Leyland-Jones B et al. Trastuzumab after adjuvant chemotherapy in HER2-positive breast cancer. *N Engl J Med* 2005; 353: 1659–72.
  81. Romond EH, Perez EA, Bryant J et al. Trastuzumab plus adjuvant chemotherapy for operable HER2-positive breast cancer. *N Engl J Med* 2005; 353: 1673–84.
  82. Joensuu H, Kellokumpu-Lehtinen P-L, Bono P et al. Adjuvant docetaxel or vinorelbine with or without trastuzumab for breast cancer. *N Engl J Med* 2006; 354: 809–20.
  83. Hurwitz H, Fehrenbacher L, Novotny W et al. Bevacizumab plus irinotecan, fluorouracil, and leucovorin for metastatic colorectal cancer. *N Engl J Med* 2004; 350: 2335–42.
  84. Giantonio BJ, Catalano PJ, Meropol NJ et al. Bevacizumab in combination with oxaliplatin, fluorouracil, and leucovorin (FOLFOX4) for previously treated metastatic colorectal cancer. Results from the Eastern Cooperative Oncology Group Study E3200. *J Clin Oncol* 2007; 25: 1539–44.
  85. Miller KD, Wang M, Gralow J et al. E2100: a randomized phase III trial of paclitaxel versus paclitaxel plus bevacizumab as first-line therapy for locally recurrent or metastatic breast cancer. 2005 ASCO Meeting Proceedings. *J Clin Oncol* 2005; 23: abstr 701.
  86. Johnson DH, Fehrenbacher L, Novotny WF et al. Randomized phase II trial comparing bevacizumab plus carboplatin and paclitaxel with carboplatin and paclitaxel alone in previously untreated locally advanced or metastatic non-small-cell lung cancer. *J Clin Oncol* 2004; 22: 2184–91.
  87. Yang JC, Haworth L, Sherry RM et al. A randomized trial of bevacizumab, an anti-vascular endothelial growth factor antibody, for metastatic renal cancer. *N Engl J Med* 2003; 349: 427–34.
  88. Kabbinavar FF, Hambleton J, Mass RD et al. Combined analysis of efficacy: the addition of bevacizumab to fluorouracil/leucovorin improves survival for patients with metastatic colorectal cancer. *J Clin Oncol* 2005; 23: 3706–12.
  89. Ellis LM, Curley SA, Grothey A. Surgical resection after downsizing of colorectal liver metastasis in the era of bevacizumab. *J Clin Oncol* 2005; 23: 4853–5.
  90. Gruenberger B, Scheithauer W, Tamandl D et al. Neoadjuvant chemotherapy including bevacizumab in potentially curable metastatic colorectal cancer. ASCO Annual Meeting Proceedings (Post-Meeting Edition). *J Clin Oncol* 2006; 24: 3546.
  91. Cunningham D, Humblet Y, Siena S et al. Cetuximab monotherapy and cetuximab plus irinotecan in irinotecan-refractory metastatic colorectal cancer. *N Engl J Med* 2004; 351: 337–45.
  92. Bonner JA, Harari PM, Giralt J et al. Radiotherapy plus cetuximab for squamous cell carcinoma of the head and neck. *N Engl J Med* 2006; 354: 567–78.
  93. Trigo J, Hitt R, Koralewski R et al. Cetuximab monotherapy is active in patients (pts) with platinum-refractory recurrent/metastatic squamous cell carcinoma of the head and neck (SCCHN): results of a phase II study. *J Clin Oncol* 2004; 22: 488s.
  94. Druker BJ, Talpaz M, Resta DJ et al. Efficacy and safety of a specific inhibitor of the BCR-ABL tyrosine kinase in chronic myeloid leukemia. *N Engl J Med* 2001; 344: 1031–7.
  95. Kantarjian H, Sawyers C, Hochhaus A et al. Hematologic and cytogenetic responses to imatinib mesylate in chronic myelogenous leukemia. *N Engl J Med* 2002; 346: 645–52.
  96. Demetri GD, von Mehren M, Blanke CD et al. Efficacy and safety of imatinib mesylate in advanced gastrointestinal stromal tumors. *N Engl J Med* 2002; 347: 472–80.
  97. van der Zwan SM, DeMatteo RP. Gastrointestinal Stromal Tumor: 5 years later. *Cancer* 2005; 104: 1781–8.
  98. Shepherd FA, Pereira JR, Ciuleanu T et al. Erlotinib in previously treated non-small-cell lung cancer. *N Engl J Med* 2005; 353: 123–32.
  99. Moore MJ, Goldstein D, Hamm J et al. Erlotinib plus gemcitabine compared with gemcitabine alone in patients with advanced pancreatic cancer: A phase III trial of the National Cancer Institute of Canada Clinical Trials Group. *J Clin Oncol* 2007; 25: 1960–6.
  100. Motzer RJ, Rini BI, Bukowski RM et al. Sunitinib in patients with metastatic renal cell carcinoma. *JAMA* 2006; 295: 2516–24.
  101. Demetri GD, van Oosterom AT, Garrett CR et al. Efficacy and safety of sunitinib in patients with advanced gastrointestinal stromal tumour after failure of imatinib: a randomised controlled trial. *Lancet* 2006; 368: 1329–38.
  102. Escudier B, Szczylik C, Eisen T et al. Randomized phase III trial of the Raf kinase and VEGFR inhibitor sorafenib (BAY 43-9006) in patients with advanced renal cell carcinoma (RCC). 2005 ASCO Annual Meeting Proceedings. *J Clin Oncol* 2005; 23: 4510.
  103. Richardson PG, Sonneveld P, Schuster MW et al. Bortezomib or high-dose dexamethasone for relapsed multiple myeloma. *N Engl J Med* 2005; 352: 2487–98.
  104. Alberts DS, Liu PY, Hannigan EV et al. Intraperitoneal cisplatin plus intravenous cyclophosphamide versus intravenous cisplatin plus intravenous cyclophosphamide for stage III ovarian cancer. *N Engl J Med* 1996; 335: 1950–5.
  105. Markman M, Bundy BN, Alberts DS et al. Phase III trial of standard-dose intravenous cisplatin plus paclitaxel versus moderately high-dose carboplatin followed by intravenous paclitaxel and intraperitoneal cisplatin in small-volume stage III ovarian carcinoma: An intergroup study of the Gynecologic Oncology Group, Southwest Oncology Group, and Eastern Cooperative Oncology Group. *J Clin Oncol* 2001; 19: 1001–7.
  106. Armstrong DK, Bundy B, Wenzel L et al. Intraperitoneal cisplatin and paclitaxel in ovarian cancer. *N Engl J Med* 2006; 354: 34–43.
  107. Yan YD, Black D, Savady R et al. Systematic review on the efficacy of cytoreductive surgery combined with perioperative intraperitoneal chemotherapy for peritoneal carcinomatosis from colorectal carcinoma. *J Clin Oncol* 2006; 24: 4011–9.
  108. Aur RJA, Simone J, Hustu HO et al. Central nervous system therapy and combination chemotherapy of childhood lymphocytic leukemia. *Blood* 1971; 37: 272–81.
  109. Noorda EM, Vrouenraets BC, Nieweg OE et al. Isolated Limb Perfusion: what is the evidence for its use? *Ann Surg Oncol* 2004; 11: 837–45.

- 
110. Kemeny N, Huang Y, Cohen AM et al. Hepatic arterial infusion of chemotherapy after resection of hepatic metastases from colorectal cancer. *N Engl J Med* 1999; 341: 2039–48.
  111. Cohen AD, Kemeny NE. An update on hepatic arterial infusion chemotherapy for colorectal cancer. *Oncologist* 2003; 8: 553–66.
  112. Llovet JM, Bruix J for the Barcelona-Clinic Liver Cancer Group. Systematic review of randomized trials for unresectable hepatocellular carcinoma: Chemoembolization improves survival. *Hepatology* 2003; 37: 429–42.
  113. Brassell SA, Kamat AM. Contemporary intravesical treatment options for urothelial carcinoma of the bladder. *J Natl Compr Canc Netw* 2006; 4: 1027–36.
  114. Figlin R, Mendoza E, Piantadosi S et al. Intrapleural chemotherapy without pleuradesis for malignant pleural effusions. *LCSG Trial 861. Chest* 1994; 106: 363S–6S.



# Designing clinical trials in surgical oncology: the importance of quality assurance

5

Marcel den Dulk, Elma Meershoek-Klein Kranenbarg and  
Cornelis JH van de Velde

---

## INTRODUCTION

Medical knowledge is continuously developing. Everyday hundreds of papers are published in medical literature, but not all reports are based on proper research and not all conclusions should be transferred to routine clinical practice. Twenty years ago, Sackett *et al.* were the first to describe rules for classifying evidence<sup>1</sup>. These rules help to obtain information from the literature and find the best evidence.

## TYPES OF STUDIES

In order to introduce new and better treatments, the benefit of these treatments should be proven in studies. The following types of studies can be distinguished, shown in ranking order starting with the highest level of evidence: systematic review, multicenter randomized clinical trial, single center randomized clinical trial, multicenter prospective observational study, single center prospective observational study, population-based study, multicenter (retrospective) observational study, and single center (retrospective) observational study<sup>2</sup>. A systematic review summarizes all available trials. However, if no conclusive information is available, a multicenter randomized clinical trial is the preferred method to obtain new information.

## RANDOMIZED CLINICAL TRIALS

Many medical discoveries were not made in randomized clinical trials. Ambroise Paré, a famous French army surgeon (1510–1590), coincidentally discovered a better way to treat soldiers' wounds. Paré had run out of burning oil to cauterize the wounds and treated the remaining

wounds with a dressing of egg white, oil of roses and turpentine<sup>3</sup>. In this way he had created two test groups. The dressing successfully sealed the wound and provided relief from pain. Until 1948 few examples in literature can be found in which patients were randomized. From 1948, starting with the publication of a study from the Medical Research Council (MRC) in which the efficacy of streptomycin in the treatment of tuberculosis was tested<sup>4</sup>, many randomized clinical trials have been conducted. Although a randomized clinical trial is the best evidence that can be obtained, only a limited number of surgical clinical trials have been performed. In 1996 Richard Horton, editor of the *Lancet*, wrote in a commentary entitled 'Surgical research or comic opera: questions, but few answered'<sup>5</sup> that only 7% of surgical papers published in nine general surgical journals were randomized trials. In contrast, almost half of the publications consisted of case studies. Obviously, this article resulted in a lot of critical responses<sup>6</sup>.

## DIFFICULTIES IN CONDUCTING SURGICAL RANDOMIZED TRIALS

Randomized clinical trials in surgery are difficult to perform. If a new medicine is tested, a reproducible entity is given which can be relatively easily monitored. In contrast, randomization of patients to evaluate surgical procedures introduces unique problems related to the variability of the operation, such as the skill of the surgeon. The skill level of surgeons will not only vary among surgeons, but also will increase as a surgeon gains experience. Furthermore, surgeons with specific interests will perform better and develop more new techniques<sup>7,8</sup>. These new techniques are often tested and analyzed in their own center. This partly explains why so many non-randomized single center or personal series are reported in surgery.

It is a prerequisite for a randomized trial that the participating surgeons are equally skilled in both techniques. Differences in performances between individual surgeons are the rule rather than the exception. To solve this problem one group of surgeons could only perform the conventional procedure and another group only the experimental operation. The main objection against this model is that the change outside the trial occurs at a slower pace, because only some of the surgeons are able to perform the new procedure. Another option is to train all surgeons to perform the procedure in the same way and at a similar level.

An additional practical problem related to the conducting of a randomized trial in surgery is to test a procedure in the evolutionary phase of a new operation. An example is a trial in which extracorporeal shock wave lithotripsy was compared with open cholecystectomy, the golden standard in the treatment of symptomatic cholecystolithiasis at that time<sup>9</sup>. However, few patients were included in this study, because of the rapid introduction of laparoscopic cholecystectomy.

The difficulty in obtaining financial support is another burden to surgical trials. At the moment, financial support for surgical trials can be obtained from independent, grant-giving institutes willing to support research in oncology such as a cancer foundation. However, it is difficult to obtain a subsidy. Findings in surgical oncology trials are often very cost effective. For example, changing from the conventional, blunt dissection of rectal cancer to total mesorectal excision (TME) reduced the 5-year local recurrence rate for patients treated with surgery without radiotherapy from 27% (Swedish Rectal Cancer Trial) to 11% (TME trial)<sup>10,11</sup>. The costs of such a surgical trial are related to costs for obligatory insurance for each patient who enters the trial, costs associated with collection, editing and storage of data, and costs for the analyses. In contrast, trials for new chemotherapies involve extensive testing in phase I, II and III trials. Costs involved in these trials are many millions of euros and, if successful, result in an increased life expectancy of a few months. These trials are, however, fully supported by pharmaceutical industries, support which is lacking for surgical trials. A drastic change in this system should occur, for example to a system where a central board distributes financial support for costs related to the obligatory insurances and costs involved in data management and analyses. Whether a grant is provided for a trial could depend on expected improvement of life expectancy and quality of life. In this model, it is of financial interest for medical insurance companies and the government to support the trials which are most likely to be cost effective and overall reduce their

expenses. Such a system is already operational in the United Kingdom by the MRC, where government and insurance companies are the main contributors in medical research.

## DESIGNING A RANDOMIZED CLINICAL TRIAL

An essential question to address is ‘what do you want to study?’ In other words, what is the aim of the trial. First, a hypothesis is formulated. In general, data from exploratory research such as previous retrospective or observational studies are helpful in formulating the hypothesis. Second, treatment arms must be designed. Randomization is used to equally distribute all possible disturbing variables over the groups. After determination of the treatment groups, inclusion and exclusion criteria have to be determined. It should be emphasized that improper patient selection introduces a bias (selection bias). Why, for example, exclude patients above a certain age if you want to study a treatment that will be used for all patients regardless of age? Finally, all randomized clinical trials have to be approved by a medical ethics committee. In 1947, after the Second World War, ten standards were made which must be followed by physicians when carrying out experiments on humans (The Nuremberg Code)<sup>12</sup>. In 1964 this code was used in the Declaration of Helsinki<sup>13</sup>. Generally, journals will not publish results of trials that are not approved by a medical ethics committee. After this rough project outline, details of the trial should be documented in a study protocol.

## STUDY PROTOCOL

A study protocol is necessary for a trial, describing the trial and all involved steps in every detail. The protocol should for example contain a detailed description not only about surgeons, training, infrastructure, and definition of endpoints, but also about the type of surgery such as details about an anastomosis, treatment specifications for each complications and descriptions to grade complications. If the trial involves introducing a new surgical technique, it has to be introduced in different ways and at several levels, for example by booklets, videotapes, workshops, and at the dissection table by instructor surgeons. By this means, a standardized procedure could be performed by all involved surgeons which reduces variations. For the most reliable results, all involved specialists, such as surgeons, pathologists, oncologists,

and radiologists, have to be (quality) controlled for their adherence to the protocol.

## QUALITY ASSURANCE

In 1991, McArdle and Hole wrote that ‘some surgeons perform less than optimal surgery . . . If by meticulous attention to detail the results of surgery could be improved, and our results suggest that this would not be difficult, the impact on survival might be greater than that of any of the adjuvant treatment therapies currently under study’<sup>7</sup>. Quality assurance is focusing on this aspect and can be defined as the systematic measures required to achieve a treatment result that meets a certain standard. For radiotherapy<sup>14–19</sup> and chemotherapy<sup>20–22</sup> several criteria have already been defined. These criteria guarantee a standard of quality and enable quality assurance procedures to be initiated. In surgery it is difficult to make quality assurance guidelines as quantifiable parameters are absent, whereas the impact of surgical treatment is often underestimated.

For many years most treatment failures were considered to be the biological behavior of the tumor rather than the result of inadequate local therapy<sup>23</sup>. However, differences in quality of surgical procedures seem to be the main cause of wide variation in outcome of local treatment for most solid malignancies<sup>24–27</sup>. This is important not only in day-to-day practice, but also even more in clinical trials where consequently the effect of adjuvant therapy may be wrongly interpreted. In the Swedish Rectal Cancer Trial which studied preoperative radiotherapy in the treatment of rectal cancer, for example, 27% of local recurrence was observed in the surgery alone group versus 11% when combined with preoperative radiotherapy<sup>10</sup>. This local recurrence rate without radiotherapy is unacceptably high for well trained surgeons, which might be explained by large variations in surgery caused by an unclear description of the surgical procedure. Another example of high recurrence rates was seen in a trial testing the efficacy of radiotherapy following total mastectomy<sup>28</sup>. Mean local recurrence rates of 9% in the irradiated group versus 32% in the non-irradiated group were observed. The authors clearly identified important variations in the extent of the surgery. Management of both the axilla and the mastectomy procedure seemed to be inappropriate, since half of the recurrences appeared on the chest wall. It was concluded, that with current surgical methods of treatment, radiotherapy is required for adequate locoregional control. This resulted in the standard application of radiotherapy following mastectomy.

By using the word current in this example, the authors have already suggested that with improved surgical therapy, radiotherapy might not be necessary in most cases.

## QUALITY CONTROLLED SURGICAL TRIALS

In a proper designed and quality-controlled surgical trial, the level of training and expertise of those performing the procedure must be comparable and should always be documented<sup>29</sup>. Documentation should be done in local surgical reports, as well as in detailed case report forms. When a new procedure is introduced, videotapes and workshops can be used. In addition, instructor surgeons could facilitate the introduction of that new procedure in a clinic. These instructors should not only teach the local surgeon, but also guarantee standardization and quality of the procedure.

## TRIAL PARTICIPATION

After designing a trial and taking the aspects of quality assurance into account, patients should be accrued to the study. Trial participation depends on physician and patient participation. In an emotional period after the diagnosis of cancer where a lot of information has to be absorbed, the doctor informs the patient on treatment and possible trial participation. In a busy practice, physicians have little time to ask for written informed consent and this might be a threshold to ask the patients. A written patient information sheet is important, but detailed personal, oral information should always be provided. This information can be adapted to the patient's level of understanding.

Furthermore, all the paperwork does not motivate to accrue more patients. Data managers for administrative and organizational support and research nurses for the arrangement of informed consent might unburden the surgeon<sup>30</sup>. It might be stimulating for physicians to fill out the forms or even participate in the trial if they receive reports with results on their personal series. Motivation is very important and low accrual is more due to the doctor than to the patient. Moreover, it has been suggested that survival of participants in clinical trials in oncology is higher than those treated outside a trial structure<sup>31</sup>.

## LOGISTICS OF A RANDOMIZED CLINICAL TRIAL

In a randomized clinical trial a lot of information is gathered. It is essential to create a proper logistic and data





## THE DUTCH TOTAL MESORECTAL EXCISION TRIAL

### The design of a study in rectal carcinoma

In the early 1990s, before the introduction of the TME surgery, blunt digital resection was used, resulting in local recurrence rates of about 20%<sup>34,35</sup>. In The Netherlands the idea arose for a study of standardized surgery to reduce local recurrence rates. After 1994 these thoughts were further developed by some enthusiastic surgeons throughout the country. At that time, the idea for a phase III rectal cancer trial was to randomize patients for standard, limited lymph node dissection plus preoperative radiotherapy versus extended, intrapelvic lymph node dissection alone. A pilot study had been carried out from November 1994 to March 1995. During this pilot study, Professor Moriya from the National Cancer Center in Tokyo visited 24 hospitals throughout The Netherlands as instructor surgeon. Many Dutch surgeons, however, feared a considerable morbidity using the Japanese extended lymph node dissection technique in Dutch patients, as experienced with the extended, D2 dissection in the Dutch Gastric Cancer Trial as well as the MRC (United Kingdom) trial in which postoperative mortality after D2 dissection was twice as high as after limited, D1 dissection<sup>36,37</sup>. Therefore, the approach changed to the TME procedure, as advocated by Heald and Enker<sup>38,39</sup>. With this operative technique, the complete mesorectum is sharply excised under direct vision, with preservation of the hypogastric plexus.

In the second proposal, conventional surgery was compared with TME surgery, and in the third proposal, conventional versus TME surgery, with or without preoperative radiotherapy. However, both designs would allocate some of the patients to the inferior arm of conventional surgery without preoperative radiotherapy. At that time, data in the literature were so convincing with regard to the superiority of the TME technique over conventional surgery, that a majority of Dutch surgeons were of the opinion that it would be unethical to randomize patients in such a design. This example illustrates the difficulty of conducting a randomized trial in an evolutionary phase of a new operation<sup>9</sup>. Finally, the last proposal that was made was to compare TME surgery with or without preoperative radiotherapy. In other words: is radiotherapy still beneficial in combination with good surgery?

After obtaining financial support, the rectal cancer trial was launched in January 1996. In The Netherlands, each hospital has its own medical ethical committee and each committee had to approve the protocol. From the

early moments it was stated that the study should be a quality-controlled study to reduce variations. Quality assurance procedures were used for all involved specialties: radiotherapy, pathology and surgery.

### Radiotherapy quality control

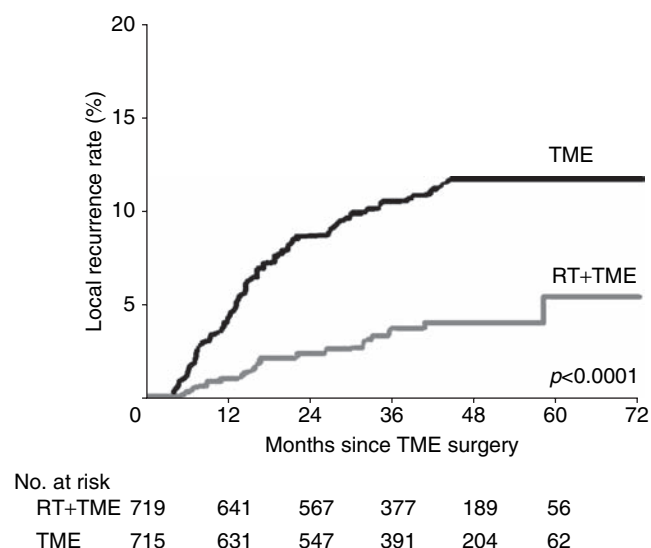
Results from a questionnaire which was mailed to all 21 Dutch radiotherapy departments showed that the use of the 5 × 5 Gy scheme, as used in Sweden<sup>40</sup>, was accepted by most institutes. Treatment details, like volume and fields were described meticulously in the protocol, including a mandatory simulation procedure. All institutes had to use a three or four fields portal box technique in order to avoid serious non-surgical morbidity which was observed in the Stockholm trial using fewer fields<sup>41</sup>. Recently, these findings were confirmed in a subgroup analysis of the Swedish Rectal Cancer Trial<sup>42</sup>.

### Pathology quality control

The TME procedure provides an excellent specimen and therefore the pathologist was able to check whether the procedure had been performed according to the protocol using the transverse slicing method of Quirke, which is highly predictive for the development of local recurrence<sup>43</sup>. For the pathologists, this way of analyzing the specimen was very different from their routine practice. How was the learning process of this method of Quirke facilitated? In addition to the TME study protocol, a special pathology protocol was written and distributed to 43 pathology laboratories. A pathology workshop was organized in December 1995 with the attendance of Quirke. A sheet was produced with a step-by-step protocol usable at the dissection table. In addition, the pathology coordinator had set up a pathology review committee to discuss problems and review the slides, reports and photographs of the specimen<sup>44</sup>.

### Surgical quality control

How to introduce the new TME procedure? First, a videotape on radicality and autonomic nerve preservation was produced, with operations performed by Professor Moriya. Heald from Basingstoke (United Kingdom) was installed as a visiting professor in Leiden. He performed almost 30 operations throughout The Netherlands and produced two videotapes, which were distributed to all participating hospitals. In addition, he attended all seven workshops, which were organized all over the country from May 1996 to April 2000.



**Figure 5.2** Local recurrence rates in the total mesorectal excision (TME) trial in 1434 eligible Dutch patients who underwent macroscopic complete local resection according to treatment group. At 43 months local recurrence was 4.1% in the group assigned preoperative radiotherapy (RT) and TME surgery and 11.5% in the group assigned surgery alone ( $p < 0.0001$ )<sup>47</sup>.

A total of 21 instructor surgeons were selected. Their task was to introduce, teach and control the TME operations in their region. In each hospital, the first five TME procedures had to be supervised by an instructor surgeon. This requirement meant that 66% of the TME operations during the first year and 58% during the first 500 TME procedures were attended by instructor surgeons<sup>32,45</sup>. Previously, this instructor system had been used successfully in the Dutch D1 and D2 gastric cancer trial<sup>46</sup>.

## Results

A total of 1861 patients were included in the study between January 1996 and December 1999, of which 1530 were from 84 Dutch hospitals. Follow-up results of the trial were published in the *New England Journal of Medicine* in August 2001<sup>11</sup>. Median follow-up for the analyses used in that article was 2 years. In Figure 5.2, local recurrence data of the Dutch patients are shown, with a median follow-up time 43 months. The local recurrence rate at 43 months is 4.1% for the group treated with preoperative radiotherapy and 11.5% for the group treated with surgery alone ( $p < 0.0001$ )<sup>47</sup>.

## CONCLUSION

Although surgical clinical trials are difficult to perform, it is not impossible to conduct a surgical clinical trial. Surgical variation is an additional difficulty when designing a surgical trial and influences the outcome of the study. Quality assurance should ensure standardization and good quality of the procedure. A detailed surgical protocol is mandatory for a properly designed study and should for example not only describe the procedure in every detail, but also how to treat complications. If a new technique is used in a study, intensive training with the aid of videos, workshops and instructors will reduce variations in the operation. Quality control of the specimen by the pathologist with feedback of any shortcoming to the surgeon and vice versa from the surgeon to the pathologists are useful for the learning process. The Dutch TME trial is a good example of a successful clinical randomized trial with quality control for radiotherapy, surgery and pathology. Quality control is expensive and labor intensive, but is absolutely worthwhile.

## REFERENCES

1. Sackett DL. Rules of evidence and clinical recommendations on the use of antithrombotic agents. *Chest* 1986; 89: 2S–3S.
2. Landheer ML, Therasse P, van de Velde CJ. The importance of quality assurance in surgical oncology. *Eur J Surg Oncol* 2002; 28: 571–602.
3. Coppi C. I dressed your wounds, God healed you – a wounded person's psychology according to Ambrose Pare. *Ostomy Wound Manage* 2005; 51: 62–4.
4. Medical Research Council Investigation. Streptomycin treatment of pulmonary tuberculosis. *Br Med J* 1948; 2: 769–82.
5. Horton R. Surgical research or comic opera: questions, but few answers. *Lancet* 1996; 347: 984–5.
6. Bell PR. Surgical research. *Lancet* 1996; 347: 1479.
7. McArdle CS, Hole D. Impact of variability among surgeons on postoperative morbidity and mortality and ultimate survival. *Br Med J* 1991; 302: 1501–5.
8. McCulloch P. Should general surgeons treat gastric carcinoma? An audit of practice and results, 1980–1985. *Br J Surg* 1994; 81: 417–20.
9. Plaisier PW, Berger MY, van der Hul RL et al. Unexpected difficulties in randomizing patients in a surgical trial: a prospective study comparing extracorporeal shock wave lithotripsy with open cholecystectomy. *World J Surg* 1994; 18: 769–72.
10. Improved survival with preoperative radiotherapy in resectable rectal cancer. Swedish Rectal Cancer Trial. *N Engl J Med* 1997; 336: 980–7.

11. Kapiteijn E, Marijnen CA, Nagtegaal ID et al. Preoperative radiotherapy combined with total mesorectal excision for resectable rectal cancer. *N Engl J Med* 2001; 345: 638–46.
12. The Nuremberg Code (1947). *Br Med J* 1996; 313: 1448.
13. Declaration of Helsinki (1964). *Br Med J* 1996; 313: 1448a–1449.
14. Belletti S, Dutreix A, Garavaglia G et al. Quality assurance in radiotherapy: the importance of medical physics staffing levels. Recommendations from an ESTRO/EFOMP joint task group. *Radiother Oncol* 1996; 41: 89–94.
15. Bentzen SM, Bernier J, Davis JB et al. Clinical impact of dosimetry quality assurance programmes assessed by radiobiological modelling of data from the thermoluminescent dosimetry study of the European Organization for Research and Treatment of Cancer. *Eur J Cancer* 2000; 36: 615–20.
16. Kehoe T, Rugg LJ. From technical quality assurance of radiotherapy to a comprehensive quality of service management system. *Radiother Oncol* 1999; 51: 281–90.
17. Leer JW, Corver R, Kraus JJ et al. A quality assurance system based on ISO standards: experience in a radiotherapy department. *Radiother Oncol* 1995; 35: 75–81.
18. Thwaites D, Scalliet P, Leer JW et al. Quality assurance in radiotherapy. European Society for Therapeutic Radiology and Oncology Advisory Report to the Commission of the European Union for the 'Europe Against Cancer Programme'. *Radiother Oncol* 1995; 35: 61–73.
19. Thwaites D. Quality assurance into the next century. *Radiother Oncol* 2000; 54: vii–vix.
20. Favalli G, Vermorken JB, Vantongelen K et al. Quality control in multicentric clinical trials. An experience of the EORTC Gynecological Cancer Cooperative Group. *Eur J Cancer* 2000; 36: 1125–33.
21. Vantongelen K, Steward W, Blackledge G et al. EORTC joint ventures in quality control: treatment-related variables and data acquisition in chemotherapy trials. *Eur J Cancer* 1991; 27: 201–7.
22. Verweij J, Nielsen OS, Therasse P et al. The use of a systemic therapy checklist improves the quality of data acquisition and recording in multicentre trials. A study of the EORTC Soft Tissue and Bone Sarcoma Group. *Eur J Cancer* 1997; 33: 1045–9.
23. MacFarlane JK. Nodal metastases in rectal cancer: the role of surgery in outcome. *Surg Oncol Clin North Am* 1996; 5: 191–202.
24. Enker WE, Thaler HT, Cranor ML et al. Total mesorectal excision in the operative treatment of carcinoma of the rectum. *J Am Coll Surg* 1995; 181: 335–46.
25. Havenga K, Enker WE, Norstein J et al. Improved survival and local control after total mesorectal excision or D3 lymphadenectomy in the treatment of primary rectal cancer: an international analysis of 1411 patients. *Eur J Surg Oncol* 1999; 25: 368–74.
26. Heald RJ, Ryall RD. Recurrence and survival after total mesorectal excision for rectal cancer. *Lancet* 1986; 327: 1479–82.
27. Martling AL, Holm T, Rutqvist LE et al. Effect of a surgical training programme on outcome of rectal cancer in the County of Stockholm. Stockholm Colorectal Cancer Study Group, Basingstoke Bowel Cancer Research Project. *Lancet* 2000; 356: 93–6.
28. Overgaard M, Hansen PS, Overgaard J et al. Postoperative radiotherapy in high-risk premenopausal women with breast cancer who receive adjuvant chemotherapy. Danish Breast Cancer Cooperative Group 82b Trial. *N Engl J Med* 1997; 337: 949–55.
29. van der Linden W. Pitfalls in randomized surgical trials. *Surgery* 1980; 87: 258–62.
30. Aaronson NK, Visser-Pol E, Leenhouts GH et al. Telephone-based nursing intervention improves the effectiveness of the informed consent process in cancer clinical trials. *J Clin Oncol* 1996; 14: 984–96.
31. Weijer C, Freedman B, Fuks A et al. What difference does it make to be treated in a clinical trial? A pilot study. *Clin Invest Med* 1996; 19: 179–83.
32. Klein Kranenbarg E, van de Velde CJ. Surgical trials in oncology: the importance of quality control in the TME trial. *Eur J Cancer* 2002; 38: 937–42.
33. Nagtegaal ID, Klein Kranenbarg E, Hermans J et al. Pathology data in the central databases of multicenter randomized trials need to be based on pathology reports and controlled by trained quality managers. *J Clin Oncol* 2000; 18: 1771–9.
34. Folkesson J, Birgisson H, Pahlman L et al. Swedish Rectal Cancer Trial: long lasting benefits from radiotherapy on survival and local recurrence rate. *J Clin Oncol* 2005; 23: 5644–50.
35. Kapiteijn E, Marijnen CA, Colenbrander AC et al. Local recurrence in patients with rectal cancer diagnosed between 1988 and 1992: a population-based study in the west Netherlands. *Eur J Surg Oncol* 1998; 24: 528–35.
36. Bonenkamp JJ, Songun I, Hermans J et al. Randomised comparison of morbidity after D1 and D2 dissection for gastric cancer in 996 Dutch patients. *Lancet* 1995; 345: 745–8.
37. Cuschieri A, Fayers P, Fielding J et al. Postoperative morbidity and mortality after D1 and D2 resections for gastric cancer: preliminary results of the MRC randomised controlled surgical trial. The Surgical Cooperative Group. *Lancet* 1996; 347: 995–9.
38. Enker WE. Total mesorectal excision – the new golden standard of surgery for rectal cancer. *Ann Med* 1997; 29: 127–33.
39. Heald RJ, Moran BJ, Ryall RD et al. Rectal cancer: the Basingstoke experience of total mesorectal excision, 1978–1997. *Arch Surg* 1998; 133: 894–9.
40. Initial report from a Swedish multicentre study examining the role of preoperative irradiation in the treatment of patients with resectable rectal carcinoma. Swedish Rectal Cancer Trial. *Br J Surg* 1993; 80: 1333–6.
41. Preoperative short-term radiation therapy in operable rectal carcinoma. A prospective randomized trial. Stockholm Rectal Cancer Study Group. *Cancer* 1990; 66: 49–55.
42. Birgisson H, Pahlman L, Gunnarsson U et al. Adverse effects of preoperative radiation therapy for rectal cancer: long-term follow-up of the Swedish Rectal Cancer Trial. *J Clin Oncol* 2005; 23: 8697–705.
43. Quirke P, Durdey P, Dixon MF et al. Local recurrence of rectal adenocarcinoma due to inadequate surgical resection. Histopathological study of lateral tumour spread and surgical excision. *Lancet* 1986; 2: 996–9.
44. Nagtegaal ID, van de Velde CJ, van der Worp E et al. Macroscopic evaluation of rectal cancer resection specimen: clinical significance of the pathologist in quality control. *J Clin Oncol* 2002; 20: 1729–34.
45. Kapiteijn E, Klein Kranenbarg E, Steup WH et al. Total mesorectal excision (TME) with or without preoperative radiotherapy in the treatment of primary rectal cancer. Prospective randomised trial with standard operative and histopathological techniques. Dutch ColoRectal Cancer Group. *Eur J Surg* 1999; 165: 410–20.
46. Bonenkamp JJ, Hermans J, Sasano M et al. Extended lymph-node dissection for gastric cancer. *N Engl J Med* 1999; 340: 908–14.
47. van den Brink M, Stiggelbout AM, van den Hout WB et al. Clinical nature and prognosis of locally recurrent rectal cancer after total mesorectal excision with or without preoperative radiotherapy. *J Clin Oncol* 2004; 22: 3958–64.



# Palliative care in surgical oncology

Iain Lawrie and Mari Lloyd-Williams

*Suffering has four components: physical, psychological, social and spiritual. When defined this way, palliative care is applicable across the spectrum of cancer care and not merely at the end of life<sup>1</sup>.*

## INTRODUCTION

To many, the specialties of surgery and palliative medicine must appear worlds apart. Surgery is often viewed as a heroic, life-saving and essentially physical domain, of the Cartesian school of thought where body is independent of mind, and where results are assessed in terms of death, disability or cure<sup>2</sup>, death being regarded as failure, the least acceptable outcome<sup>3</sup>. Palliative care is seen by some as a less dynamic branch of medicine, where patients and families are metaphorically shielded from the nastier aspects of their disease, and where intervention and practical management is viewed secondary to comfort and emotional support for the duration of the illness, often until death. Neither of these impressions is warranted.

In this chapter, we present an overview of palliative care in surgical oncology. The nature and origins of both palliative care and palliative surgery are discussed before the application of palliative care principles to a number of specific clinical problems. The place of palliative care in oncology, examples of good practice and potential barriers to an effective palliative care approach are then considered. Finally, we look towards the continued integration and future development of this approach in the field of surgical oncology.

## BACKGROUND

Care of patients with malignant disease, of the dying and, in different forms, hospice care has been practiced since the very beginnings of medicine<sup>4</sup>. The technological advances of the 20th century focused medical attention on pathology and cure, often accompanied by a denigration

of treatment aimed at symptomatic relief. However, as the limitations of modern medicine were acknowledged, a common element of palliative care emerged in the form of a holistic approach to patient care. This ‘whole person’ approach places emphasis not only on the physical aspects of diagnosis and treatment of disease, but also on comfort, freedom from distress and support of the individual and the family<sup>5</sup>.

Palliative care developed new prominence in 1967, with the opening of St Christopher's Hospice, England as the first research and teaching hospice and a center for provision of both patient and family care in the hospice itself, in the community and, for families, into bereavement. This was followed in the 1970s by diverse developments of the modern hospice movement across Europe and the USA. Palliative care as a distinct medical specialty is a relatively recent development of the mid-1980s and since then has developed rapidly throughout the world with local, national and international organizations founded to share good practice, provide education and to collaborate in research.

Several definitions of palliative care have been proposed and, in many respects, it can take different forms depending on the context in which it is practiced. The World Health Organization (WHO) defines palliative care as ‘the active total care of patients whose disease is not responsive to curative treatment’<sup>6</sup>. This includes the control of pain and other distressing symptoms and of psychological, social and spiritual problems. It affirms life and regards death as a normal process, its goal being to achieve the best quality of life for patients and families.

Surgery has its roots in palliation of both symptoms and disease and, until the 20th century, the vast majority of medical and surgical procedures were palliative in nature.

Procedures for palliation of symptoms of bowel obstruction, for drainage of abscesses and for removal of tumors were common. The management of patients with burns is probably the most developed example of palliative care in surgery<sup>7</sup>, where the primary aims are relief of pain and quality of life. The now commonplace procedure of coronary artery bypass grafting was initially developed to relieve the pain of angina before its place as a life-prolonging technique was evident<sup>7</sup>. Palliative surgery today still accounts for a significant proportion of both cancer and general surgery practice<sup>8,9</sup>.

It is clear, therefore, that both the historical basis of surgery and its present-day practice are intimately connected to many of the basic tenets of palliative care. The relief of suffering has long been the primary intention of surgeons and has helped develop medical practice in the prolongation of life for patients with both early and advanced disease.

Surgical palliative care encapsulates far more than malignant disease. Many illnesses, both acute and chronic, require palliation. However, practice relating to cancer is the main focus of attention of this chapter.

## SELECTED COMPONENTS OF PALLIATIVE CARE

Numerous physical and non-physical symptoms can cause distress and suffering for the patient with advanced disease. However, satisfactory symptom control can usually be accomplished when symptoms are both looked for and recognized, with 'a direct organized approach' to care<sup>10</sup>.

### Pain

Pain is common in patients with cancer, occurring in up to 75% of patients<sup>11</sup> and effective pain management is crucial. Pain is an 'unpleasant sensory and emotional experience'<sup>12</sup> and is what the experiencing person says it is<sup>13</sup>. The most important component of management is a thorough and accurate assessment of a patient's pains. Many different components contribute to pain and a multimodal approach to pain relief may be necessary (Figure 6.1). A number of tools for assessment of pain are available<sup>15-17</sup>.

There is no such thing as the perfect analgesic, and patients may require different classes, strengths, forms, and dosages of analgesic during the course of their illness. The basis of effective pain relief remains the analgesic ladder<sup>18</sup>, originally designed for the management of cancer pain but equally applicable to other situations (Figure 6.2). Attention to both background pain and incident, or 'breakthrough' pain is important. There is little point in a

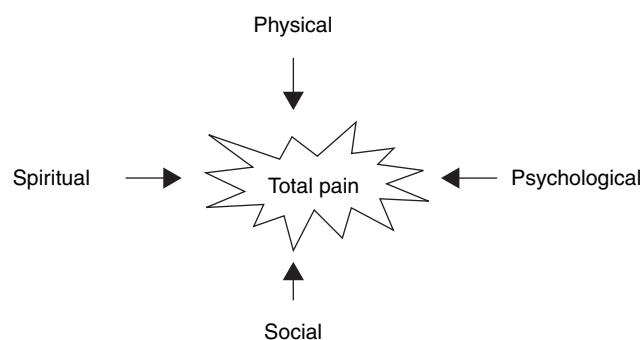


Figure 6.1 The concept of total pain. Adapted from reference 14.

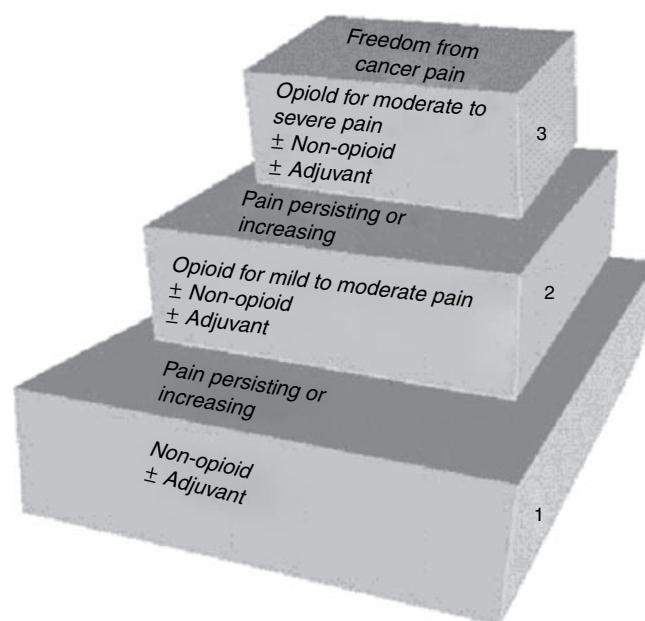


Figure 6.2 The World Health Organization analgesic ladder. Reproduced from reference 18, with permission.

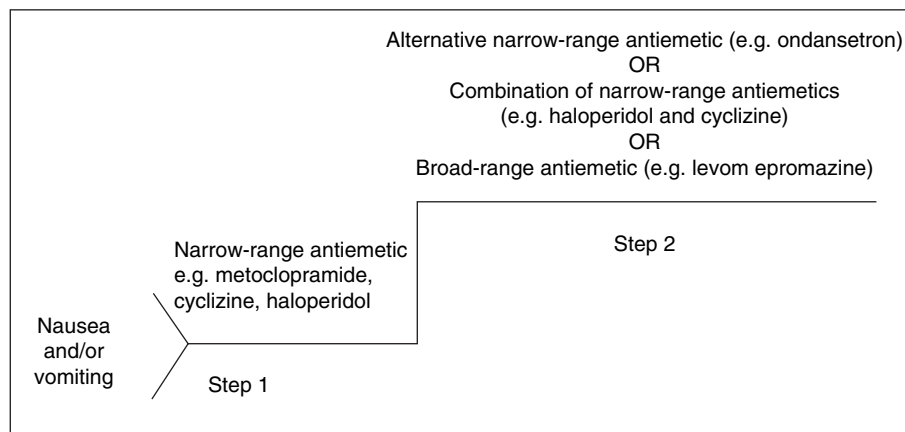
patient being comfortable at rest but being prevented from activity due to pain.

Analgesics can be split into three classes: non-opioids, opioids and adjuvants (Table 6.1). The analgesic ladder advocates a step-wise titration of analgesia to the needs of the individual patient, with both non-opioid and adjuvant analgesics being retained at each step. Non-opioids are the starting point towards effective pain relief, and may be supplemented by adjuvant analgesics according to the type and probable cause of pain. Opioid analgesics include those for mild to moderate pain (step 2 opioids) and others for moderate to severe pain (step 3 opioids). Step 2 analgesics display a 'ceiling' effect for analgesia<sup>14</sup> and, with increasing severity of pain, it may be necessary to progress to a stronger opioid (step 3). When using strong opioids with which they are unfamiliar, clinicians should liaise with palliative care or pain specialist colleagues.



**Table 6.1** Analgesics classified according to the World Health Organization ladder.

<i>Step 1</i>	<i>Step 2</i>	<i>Step 3</i>	<i>Adjuvants</i>
Paracetamol	Cocodamol	Morphine	Corticosteroids
Non-steroidal anti-inflammatory drugs (NSAIDs)	Dihydrocodeine	Oxycodone	Antidepressants
	Tramadol	Hydromorphone	Anti-epileptics
		Methadone	Antispasmodics
		Buprenorphine	Muscle relaxants
		Fentanyl	

**Figure 6.3** Proposed antiemetic ladder. Adapted from reference 5.

Apprehension regarding the use of opioids, displayed by both patients and professionals, can be a barrier to effective pain relief. These fears are largely unfounded. Neither addiction nor tolerance occurs when opioids are used to manage pain<sup>19</sup>. Respiratory depression can occur when large doses of opioids are given for acute pain or in error, and sedation is usually a short-lived feature of early opioid use or dose increase.

### Nausea and vomiting

Nausea and vomiting are distressing symptoms present in up to 70% of patients with advanced cancer<sup>20–22</sup> and four causes (gastric stasis, intestinal obstruction, drugs, and chemical) account for the majority of cases<sup>14–23</sup>. Identification of possible causes is imperative and should guide management. Reversible causes, such as uncontrolled pain, medication side-effects, constipation, and hypercalcaemia should be corrected where possible. Non-physical causes, such as anxiety, should always be considered.

Antiemetic drugs act on specific receptors, thus emphasizing the importance of accurate assessment of possible etiologies. Where gastric stasis or functional bowel obstruction is suspected, a prokinetic antiemetic

(e.g. metoclopramide) would be an appropriate first-line choice. Acting principally on the chemoreceptor trigger zone in the area postrema, haloperidol is effective for chemical causes of nausea and vomiting, whether biochemical or drug induced. An antispasmodic and antisecretory antiemetic (e.g. hyoscine butylbromide) is useful where colic is present, or where a reduction in gastrointestinal secretions is appropriate. Finally, for organic bowel obstruction, motion-induced symptoms and raised intracranial pressure cyclizine, which acts on the vomiting center, is appropriate. An ‘antiemetic ladder’ has been proposed (Figure 6.3)<sup>5</sup>.

Antiemetics should be prescribed regularly as well as ‘as needed’ and the route of administration should be considered. If oral absorption is likely to be affected by persistent vomiting, a continuous subcutaneous infusion (CSCI) is most appropriate. Unless the identified cause is self-limiting, it is advisable to continue antiemetic treatment.

Should first-line antiemetic treatment be ineffective, trial of a broad-spectrum drug such as levomepromazine is sensible. Other drugs which can be used in the management of nausea and vomiting include corticosteroids as an adjuvant in bowel obstruction, 5HT<sub>3</sub>-receptor

antagonists such as granisetron or tropisetron in bowel obstruction or in patients who have had chemotherapy or abdominal radiotherapy, and octreotide, a somatostatin analog, for reduction of secretions where hyoscine butylbromide has been ineffective.

### Bowel obstruction

Malignant bowel obstruction, most frequently seen in bowel and pelvic carcinoma, occurs in 3–15% of advanced cancers<sup>24</sup>. It can occur anywhere in the gastrointestinal tract, and may be the result of the cancer itself, drug induced (e.g. opioids, antimuscarinics), related to constipation or previous treatment (e.g. surgery, radiation), or an unrelated benign condition<sup>25</sup>. Obstruction can cause considerable distress to the patient and is often accompanied by nausea, vomiting and abdominal pain and distension.

Surgery for obstruction is often indicated where a procedure is technically feasible, it carries clear benefits and the patient is sufficiently fit, but is often not possible, especially in cases of diffuse intra-abdominal disease, rapidly recurring ascites, or where there has been previous radiotherapy or extensive surgery. That said, 40–70% of patients will have relief of their obstruction following surgery, although perioperative mortality can be high<sup>26</sup>.

Medical management of bowel obstruction rarely includes the use of a nasogastric tube or intravenous fluids<sup>14,27</sup>. Drugs are usually administered by CSCI in order to be effective and pain is controlled using an appropriate opioid. Gut motility can be improved using a prokinetic drug such as metoclopramide, possibly with dexamethasone to reduce bowel edema. However, if colic is a feature, prokinetic medications and stimulant laxatives should be avoided and hyoscine butylbromide used instead. Where constipation is thought to be a feature, a stool-softening laxative may be used. Finally, management of associated nausea, which can be troublesome, can be effected by means of either metoclopramide (no colic) or drugs such as haloperidol and/or cyclizine. Vomiting, often a feature of obstruction, may be improved by the measures already mentioned. However, if hyoscine butylbromide is inadequate, octreotide may be indicated to reduce the volume of such vomits. As with all CSCIs, drug compatibility should be checked prior to administration.

### Dyspnea

Dyspnea, seen in 40–80% of palliative care patients<sup>28</sup> is a source of considerable functional limitation and distress. The pathophysiological mechanisms of breathlessness are complex and remain unclear, and fatigue, muscle

weakness, anxiety, pleural effusion, direct tumor effects, and distortion of mechanoreceptors can all contribute<sup>5</sup>.

After correction of reversible causes, management of dyspnea can be difficult. Non-pharmacological strategies and interventions include pulmonary rehabilitation and activity-related education, positioning, use of oxygen, and non-invasive positive pressure ventilation. Pharmacological intervention relies mainly on the use of opioids, benzodiazepines and, possibly, buspirone. Opioids reduce the ventilatory response to raised carbon dioxide or reduced oxygen levels<sup>25,29</sup>, reduce anxiety and the sensation of breathlessness, and may act peripherally on local lung receptors<sup>30</sup>. Opioid-naïve patients should be commenced on small doses of oral morphine regularly and the dose titrated according to response. If patients already taking opioids find benefit from additional doses, their regular opioid can be titrated. Benzodiazepines such as diazepam, lorazepam and midazolam have been used and, although often empirically effective, evidence is lacking.

### Communication

It is vital at all stages of a terminal illness to communicate well with patients and their relatives. What is said and what the patient may hear or understand may be very different, leading to misunderstanding and, not infrequently, bitterness and resentment against the bearer of the bad news<sup>31</sup>.

Whilst many patients may have inkling that all is not well, the desire to hear good news can prevent information from being heard and assimilated. Giving bad news in whatever setting is never easy – nor should it be – but certain steps can help a diagnosis or prognosis to be communicated in an understandable way. Showing empathy and concern (e.g. saying ‘I realise this is very difficult for you’) can do much to avoid the feelings of abandonment which many patients feel when they are told that a diagnosis is terminal. Often, relatives will try to protect the patient and ask for them not to be told bad news. For the professional, where does loyalty lie? Ultimately, their main responsibility is to the patient. Collusion can pull families apart at a time when they most need to be close to each other. Offering to speak to patients with their relatives present can be helpful. Information needs to be given honestly, but always with the assurance that symptoms can be palliated – ‘there is nothing more that can be done to help you’ is both cruel and untrue, and should never be said. In addition to communicating with patients and relatives, it is also important to communicate what has been told to patients and management decisions, both within the hospital team and to primary care colleagues to ensure that patients receive a consistent message.

## Anorexia and cachexia

Cachexia (muscle wasting and marked weight loss) is common in patients with advanced malignant disease and may be due to any combination of direct tumor effect, nausea, cytokine action, medication, psychological factors, and unresolved pain<sup>27</sup>. Both anorexia and cachexia can lead to extreme fatigue and weakness, and are associated with reduced survival in many illnesses.

Management is complex and multidisciplinary. While artificial nutrition, for example via enteral tube feeding, is possible, it is not always beneficial or appropriate in patients with advanced cancer. However, the legal and ethical debate regarding artificial nutrition and hydration in advanced disease is beyond the scope of this book. That aside, attention must be paid to concerns regarding body image, skin care to prevent decubitus ulcers, dental review if appropriate, and occupational therapy involvement for help with activities of daily living.

Specific medical treatment, using megestrol acetate, steroids or thalidomide, may be of some use, but no medical management has proven effectiveness. Advice regarding nutrition and trial of commercial dietary supplements are often appropriate. However, when faced with advanced, often terminal disease, emphasis should remain on patient choice, and 'adequate' nutrition should not be an unshakable goal at the expense of this and of patient quality of life.

## Psychosocial problems

Patients may experience a number of different emotions when treatment is no longer curative. Distress is normal and is not on its own pathological, and it is difficult to distinguish appropriate sadness at the end of life from treatable depressive illness. Up to 32% of patients develop a significant mood disorder in advanced cancer<sup>32</sup>. Certain types of cancer, such as pancreatic cancer are associated with an increased incidence of depression. Depression is frequently missed and may present as anger, profound sadness, or irritability. Depression should always be suspected in a patient for whom the control of physical symptoms (e.g. pain) is difficult<sup>33</sup> and also in patients who appear more unwell than their disease stage suggests. Patients are often reluctant to mention depression, so it is important that mood is assessed as frequently as pain or any other symptom. A simple question such as 'how are you feeling in your mood?' can allow patients the opportunity to share their symptoms. Screening tools are also available and the Edinburgh Depression Scale is one of the most sensitive in the palliative care population<sup>34</sup>.

Depression should be treated with an appropriate antidepressant and psychosocial support from members of the treating team. Appropriate antidepressants include citalopram, mirtazepine and venlafaxine. A small dose of steroids (e.g. dexamethasone 4–6 mg once daily) can help increase mood quickly and improve general well-being whilst waiting for an antidepressant to work.

## End-of-life care

At some point in most patients' final illness, it becomes apparent that they are in a phase of terminal deterioration and that no further traditional active intervention is either appropriate or beneficial. This, however, does not mean that no further active intervention is necessary. Palliative care strives to challenge the attitude that 'there is nothing more we can do'<sup>3,14</sup> and serves to prevent patients' possible feelings of abandonment by professionals involved in their care<sup>14,35,36</sup>.

A good death is one which is appropriate for the individual patient and the challenge is to provide care tailored to the patient, whilst fostering independence, autonomy and control. Factors which are considered important at the end of life are shown in Table 6.2. Good communication is essential, as is control of symptoms which may distress the patient, while also discontinuing any medication, observation or intervention which does not fulfil this aim.

Quality of life in the last few days and hours of life largely depends on the care the patient has previously received. Careful thought and planning can achieve this and is within the capabilities of all health professionals.

**Table 6.2** Important factors at the end of life.

---

Dignity of patient and caregivers
Respect for the patient's wishes
Effective and timely communication with patient and caregivers
Management of pain and other symptoms
Attention to psychological, social and spiritual concerns
Continuity of care
Access to specialist palliative care services where appropriate
Effective interprofessional communication
Provision of appropriate treatments and discontinuation of those inappropriate at the end of life

---

## Bereavement

When a patient dies, the grief felt may take many forms. In first few hours, there may be numbness, denial, or even relief that suffering is over, or anger at the patient for dying. Relatives appreciate support given at the time of death. Information regarding death certification and the practicalities of registering the death is helpful, as can be asking whether they wish to see the chaplain or other members of the team who may have been particularly involved in the patient's care. Good communication with the primary care team is essential as they will be the key support for the family in the community. It is also important to acknowledge that the team may well also feel a sense of bereavement if they have cared for the patient over a long period of time. Allowing team members time to share any thoughts or feelings after a death can be helpful in allowing staff also to move on. Some deaths will impact more than others on the team and the provision of support from chaplaincy or occupational health can be helpful in such situations.

## DISCUSSION

Palliation has long been part of the surgeon's remit and, as a result of advances in oncology and the changing demographics of death<sup>37</sup> this role has expanded. Several definitions of palliative surgery have been proposed<sup>36,38,39</sup> and, while this can cause confusion, many acknowledge the importance of alleviation of symptoms and improvement in quality of life<sup>40</sup>. Palliative care need not be synonymous with end-of-life care, however<sup>9</sup>. Major components of the palliative care approach are symptom control and psychological support, both of which are applicable in most clinical situations.

Significant advances have been made in the integration of skills from both disciplines. The various British royal surgical colleges, the American College of Surgeons, American Thoracic Society, Society of Critical Care Medicine, and others have agreed that palliative care will increasingly influence the care of patients<sup>3</sup>. The Promoting Excellence in End-of-Life Care national program<sup>41</sup> in the US and the prominence of both palliative care and end-of-life care in the new syllabus of the Intercollegiate Surgical Curriculum Project<sup>42</sup> in the UK are excellent examples of such integration.

However, potential barriers to an effective palliative care approach in surgical oncology exist. The lack of a universally accepted definition of surgical palliative care has been mentioned. This may influence clinicians' perception, as lack of clarity, coupled with surgeons' conceptualization of success and failure in terms of death, disability and cure<sup>3,7,43</sup> could prevent cultural change.

The background of the surgeon has been described as leading to lack of awareness of non-physical suffering<sup>36</sup> and of 'heroic optimism'<sup>43</sup> which may, in turn, prevent attention to palliative care principles in favor of attempts at cure. Indeed, until recently there has been a lack of formal education in palliative and end-of-life care in surgical training<sup>9,37,44,45</sup> and little in the literature<sup>9,36,39,46,47</sup>.

Problems related to communication can impact negatively on the relationship between surgeon and patients with malignant disease. Lack of common language in discussing disease and management can be troublesome. Uncertainty regarding prognosis can pose significant challenges and the surgeon may find it difficult to be candid with the patient regarding their illness for fear of removing hope<sup>9,36</sup>. This may be a reflection of discomfort with emotional challenges associated with managing advanced illness, but may be more the result of difficulty in acknowledging death as 'a natural end-point of the normal process of dying'<sup>39</sup>, where the emphasis of care addresses patient needs rather than prognosis.

## THE FUTURE

It is clear that palliative care principles have been acknowledged by surgeons and are being integrated into basic and postgraduate training and practice, and that both disciplines could 'benefit by coming together . . . [to] . . . reclaim the lost ground of the surgeon-patient relationship'<sup>39</sup>. The prevailing bias towards separating care into a curative and then a palliative phase ('cure, then comfort') is not acceptable. Provision of palliative care alongside comprehensive, possibly curative care should be available to every patient at an early stage<sup>48</sup>. This would represent a shift towards patient-centered care<sup>1</sup> (Figure 6.4).

The integration of a palliative care approach into general hospital practice has demonstrated improved terminal care<sup>49,50</sup>. Such practice centers on outcomes that are meaningful to the patient and thus may be a focus for further research. Some work into quality of life in surgical oncology has been undertaken<sup>2,51</sup>, a relatively new focus in palliative surgery<sup>52</sup>. This increased interest in quality of life should be welcomed and developed further, and may help surgeons to identify appropriate procedures for patients with advanced disease<sup>2</sup> and reflect goals important to patients themselves<sup>9</sup>.

In palliative surgery there is a lack of evidence-based benefit and risk in many instances<sup>40</sup>. There can be a reluctance to involve palliative care patients in research, perhaps due to ethical concern or fear of creating false hope of cure. Such concern is largely unnecessary. Patients are often keen to be involved in clinical trials, if not for their own benefit, then for the 'common good' and researchers

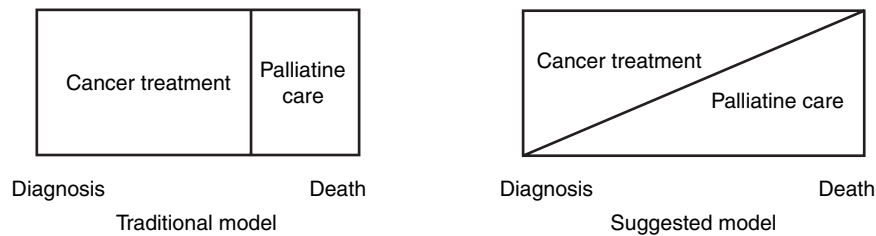


Figure 6.4 Traditional and suggested place of palliative care in cancer management. Adapted from reference 14.

should not avoid them through any such fears or thoughts that the trial would be weakened<sup>1</sup>.

## CONCLUSION

It is encouraging to reflect on the origins of palliation in surgical oncology and recent developments towards further integration of the specialties. Important lessons

have been learned through the realization that quality of life, rather than patient prognosis or survival, is an appropriate focus for professional involvement in patients with advanced disease. A palliative care approach to patient care is within the capabilities of all professionals involved in patient care and can only serve to improve such care to the benefit of patients, families and professionals themselves.

*‘... the closer to the bedside, the better’<sup>7</sup>.*

## REFERENCES

1. Meyers FJ, Linder J. Simultaneous care: disease treatment and palliative care throughout illness. *J Clin Oncol* 2003; 21: 1412–5.
2. Langenhoff BS, Krabbe PFM, Wobbes T et al. Quality of life as an outcome measure in surgical oncology. *Br J Surg* 2001; 88: 643–52.
3. Mosenthal AC, Lee KF, Huffman J. Palliative care in the surgical intensive care unit. *J Am Coll Surg* 2002; 194: 75–83.
4. Saunders C. Introduction – history and challenge. In: Saunders C, Sykes N, eds. *The Management of Terminal Malignant Disease*, 3rd edn. London: Edward Arnold, 1993: 1–14.
5. Watson M, Lucas C, Hoy A, Back I, eds. *Oxford Handbook of Palliative Care*. Oxford: Oxford University Press, 2005.
6. World Health Organization (WHO). Cancer pain relief and palliative care. Technical Report Series 804. Geneva: World Health Organization, 1990.
7. Dunn GP, Milch RA. Introduction and historical background of palliative care: where does the surgeon fit in? *J Am Coll Surg* 2001; 193: 325–8.
8. Krouse RS, Nelson RA, Farrell BR et al. Surgical palliation at a cancer center: incidence and outcomes. *Arch Surg* 2001; 136: 773–8.
9. McCahill Krouse RS, Chu DZJ et al. Decision making in palliative surgery. *J Am Coll Surg* 2002; 195: 411–422.
10. Byock I. Completing the continuum of cancer care: integrating life-prolongation and palliation. *CA Cancer J Clin* 2000; 50: 123–32.
11. Bonica JJ. Cancer pain: current status and future needs. In: Bonica JJ, ed. *The Management of Pain*, 2nd edn. Philadelphia: Lea & Febiger, 1990: 400–45.
12. International Association for the Study of Pain, Subcommittee on Taxonomy (IASP). Descriptions of chronic pain syndromes and definitions of pain terms. *Pain* 1986; S3: 1–226.
13. McCaffery M. *Nursing Management of the Patient in Pain*. Philadelphia: JB Lippincott, 1972.
14. Twycross R. *Introducing Palliative Care*, 3rd edn. Oxford: Radcliffe Medical Press Ltd 1997: 66.
15. Melzack R. The McGill pain questionnaire. In: Melzack R, ed. *Pain Measurement and Assessment*. New York: Raven Press, 1983: 41–48.
16. Jensen MP, Karoly P, Braver S. The measurement of clinical pain intensity: a comparison of six methods. *Pain* 1986; 27: 117–26.
17. Bennett MI. The LANSS pain scale – the Leeds assessment of neuropathic symptoms and signs. *Pain* 2001; 92: 147–57.
18. World Health Organization. WHO Guidelines: Cancer Pain Relief (2nd edn). Geneva: World Health Organization 1996.
19. Bennett M, Forbes K, Faull C. The principles of pain management. In: Faull C, Carter Y, Daniels L, eds. *Handbook of Palliative Care*, 2nd edn. Oxford: Blackwell Publishing Ltd 2005: 116–49.
20. Grond S, Zech D, Diefenbach C et al. Prevalence and pattern of symptoms in patients with cancer pain: a prospective evaluation of 1635 cancer patients referred to a pain clinic. *J Pain Symptom Manage* 1994; 9: 372–82.
21. Dunlop GM. A study of the relative frequency and importance of gastrointestinal symptoms, and weakness in patients with far advanced cancer. *Palliat Med* 1989; 4: 37–43.
22. Meuser T, Pietruck C, Radbruch L et al. Symptoms during cancer pain treatment following WHO-guidelines: a longitudinal follow-up study of symptom prevalence, severity and etiology. *Pain* 2001; 93: 247–57.
23. Lichter I. Results of antiemetic management in terminal illness. *J Palliat Care* 1993; 9: 19–21.
24. Ripamonti C, Mercadante S. Pathophysiology and management of malignant bowel obstruction. In: Doyle D, Hanks G,

- Cherny N et al., eds. Oxford Textbook of Palliative Medicine, 3rd edn. Oxford: Oxford University Press, 2004: 496–507.
25. Twycross R, Wilcock R. Symptom Management in Advanced Cancer, 3rd edn. Abingdon: Radcliffe Medical Press Ltd, 2001: 111–5.
26. Dunn GP, Milch RA, Mosenthal AC et al. Palliative care by the surgeon: how to do it. *J Am Coll Surg* 2002; 194: 509–37.
27. Chilton A, Faull C. The management of gastrointestinal symptoms and advanced liver disease. In: Faull C, Carter Y, Daniels L, eds. *Handbook of Palliative Care*, 2nd edn. Oxford: Blackwell Publishing Ltd 2005: 150–84.
28. Bruera E. The frequency and correlates of dyspnoea in patients with advanced cancer. *J Pain Symptom Manage* 2000; 19: 357–62.
29. Wade R, Booth S, Wilcock A. The management of respiratory symptoms. In: Faull C, Carter Y, Daniels L, eds. *Handbook of Palliative Care*, 2nd edn. Oxford: Blackwell Publishing Ltd 2005: 185–207.
30. Zebraski SE, Kochenash SM, Raffa RB. Lung opioid receptors: pharmacology and possible target for nebulized morphine in dyspnea. *Life Sci* 2000; 66: 2221–31.
31. Heaven C, Maguire P. Communication issues. In: Lloyd-Williams M, ed. *Psychosocial Issues in Palliative Care*. Oxford: Oxford University Press, 2003: 13–34.
32. Hotopf M, Chidgey J, Addington-Hall J, Lan Ly K. Depression in advanced disease: a systematic review. Part 1: Prevalence and case finding. *Palliat Med* 2002; 16: 81–97.
33. Lloyd-Williams M, Dennis M, Taylor F. A prospective study to determine the association between physical symptoms and depression in patients with advanced cancer. *Palliat Med* 2004; 18: 558–63.
34. Lloyd-Williams M, Friedman T, Rudd N. The criterion validation of the EDS for the assessment of depression in patients with advanced metastatic disease. *J Pain Symptom Manage* 2000; 20: 259–65.
35. Dunphy JE. Annual discourse on caring for the patient with cancer. *N Engl J Med* 1976; 295: 313–9.
36. Dunn GP. Restoring palliative care as a surgical tradition. *Bull Am Coll Surg* 2004; 89: 23–9.
37. Easson AM, Crosby JA, Librach SL. Discussion of death and dying in surgical textbooks. *Am J Surg* 2001; 182: 34–9.
38. McCahill Krouse RS, Chu DZJ et al. Indications and use of palliative surgery – results of Society of Surgical Oncology survey. *Ann Surg Oncol* 2002; 9: 104–112.
39. Palliative Care Workgroup. Office of promoting excellence in end-of-life care: surgeons' palliative care workgroup report from the field. *J Am Coll Surg* 2003; 197: 661–86.
40. Hofmann B, Håheim LL, S reide JA. Ethics of palliative surgery in patients with cancer. *Br J Surg* 2005; 92: 802–9.
41. Bryock I, Twohig JS. Expanding the realm of the possible. *J Palliat Med* 2003; 6: 331–3.
42. Intercollegiate Surgical Curriculum Project. <http://www.ISCP.ac.ulc/2006>.
43. Buchman TG, Cassell J, Ray SE et al. Who should manage the dying patient?: rescue, shame, and the surgical ICU dilemma. *J Am Coll Surg* 2002; 194: 665–73.
44. Goldberg R, Guandanoli E, LaFarge S. A survey of housestaff attitudes towards terminal care education. *J Cancer Educ* 1987; 2: 163.
45. Rappaport W, Prevel C, Witzke D et al. Education about death and dying during surgical residency. *Am J Surg* 1991; 161: 690–2.
46. Carron AT, Lynn J, Keaney P. End-of-life care in medical textbooks. *Ann Int Med* 1999; 130: 82–6.
47. Rabow MW, Hardie GE, Fair JM et al. End-of-life care content in 50 textbooks from multiple specialties. *JAMA* 2000; 283: 771–8.
48. Fisher JA, Parker MC. Joint surgical/palliative care ward round in a district general hospital. *Palliat Med* 1999; 13: 249–50.
49. Manfredi P, Morrison S, Morris J et al. Palliative care consultations: how do they impact the care of hospital patients? *J Pain Symptom Manage* 2002; 24: 91–6.
50. Virik K, Glare P. Profile and evaluation of a palliative medicine consultation service within a tertiary teaching hospital in Sydney, Australia. *J Pain Symptom Manage* 2002; 23: 17–25.
51. McCahill LE, Smith DD, Borneman T et al. A prospective evaluation of palliative outcomes for surgery of advanced malignancies. *Ann Surg Oncol* 2003; 10: 654–63.
52. Lee KF, Purcell GP, Hinshaw DB et al. Clinical palliative care for surgeons: part 1. *J Am Coll Surg* 2004; 198: 303–19.

# Communication and psychological needs of the cancer surgery patient

Clare Byrne and Graeme J Poston

## BACKGROUND

When confronted by cancer, patients may experience a sense of loss of control, fear and even anger. The principal concern with the psychological aspects of cancer is to alleviate the emotional distress which affects patients. There is a current trend to view psychological care within the context of 'supportive care' in a multidisciplinary team approach<sup>1</sup>. Supportive care refers to a culture of care that has evolved from the palliative care ethos and focuses on generic cancer teams assisting the patient and their carers to cope with cancer and its treatments at all stages of the cancer journey. It helps the patient to maximize the benefits of treatment and to live as well as possible with the effects of the disease.

The key principles underpinning supportive care are<sup>1</sup>:

- A focus on quality of life
- A whole person approach
- Care to include the patient and those who matter to them
- Respect for patient autonomy and choice
- An emphasis on open and sensitive communication.

Communication that assists patients and their carers to express emotions and concerns can reduce fears and anxiety, and promote working together in the cancer experience. An individualized approach to information can empower patients to be involved in decision making and exercise choice, resulting in a greater sense of control and self-esteem.

## HISTORICAL PERSPECTIVE

Communication with, and the psychological response by patients to their cancer was barely investigated before the 1950s, when it was commonplace not to disclose a cancer diagnosis. Outcomes tended to be restricted to survival time and recurrence-free survival. Cancer surgeons

traditionally obtained consent for surgery without discussing the definite diagnosis, or likelihood of a diagnosis, of cancer, and following surgery, cancer was not revealed as the diagnosis because it was considered as something that it was best for the patient not to know. At this time there was also a commonly believed assumption that because anxiety and depression were natural, inevitable reactions to cancer, psychological treatment was not feasible. Set against this model of care, systematic enquiry that included the patient perspective on how patients felt about their cancer, and their quality of life was simply not accessible.

Decades before this, many radical surgical procedures for the treatment of cancer had been developed and utilized, surgery being the main treatment approach for cancer. Much of the seminal work had been undertaken at the Memorial Hospital in New York, USA. At this same unit, some of the first studies into the psychological aspects of cancer surgery were undertaken by Sutherland (a psychiatrist), who examined psychological adaptation to mastectomy and colostomy<sup>2,3</sup>. However, Sutherland and others<sup>4</sup> struggled to have these psychological studies accepted as necessary, let alone, scientific, as psychology was not viewed as an important aspect of cancer patient management.

It was during the 1960s that a more enlightened view of the ethical issues surrounding disclosure of a cancer diagnosis to patients started to be acknowledged. Alongside this, the importance of the relationship between the psychological effects of cancer and cancer treatments such as surgery also began to develop and measurement of outcomes in cancer care began to include the psychological issues of quality of life of individuals affected by cancer.

In the USA, papers were presented by cancer surgeons at academic meetings<sup>5</sup> and published in recognized journals<sup>6</sup>, resulting in an increased recognition of the psychological needs in the management of the patient with cancer. Practical guidance was provided<sup>6</sup>, which is still very pertinent today and included how to:

- Establish rapport with the patient in the preoperative period
- Allay the patient's fears



- Inform the patient that incurable cancer was found at surgery
- Establish close communication with the patient whose cancer was found to be incurable at surgery.

Across the Atlantic, developments in the hospice movement in the UK saw a shift from only relying on the measurement of clinical outcomes to the measurement of factors that were likely to be of direct concern to patients, such as cancer and depression or discussion about preferred place to die<sup>7</sup>. In cancer surgery, a number of studies arose through psychiatric and psychological academic links with oncology units<sup>8</sup>. Some of this early work involved those affected by breast cancer, both in the acute phase around diagnosis and during treatment<sup>8,9</sup> and at the stage of recurrence, development of metastases or dissemination<sup>10</sup>. Therapeutic interventions for the psychological management of cancer patients were also developed in those having breast cancer surgery<sup>11</sup>, and for those who presented with advanced breast disease<sup>12</sup>.

## COMMUNICATION SKILLS IN CANCER

The ability to communicate with patients is a core requirement for all health-care professionals. Much of the research in this field has been undertaken in cancer care and disability<sup>13–15</sup>. Having the skills to elicit patient concerns, and to appropriately respond to them, to individualize patient information and to involve patients in decision preferences about their care calls upon a range of both interpersonal and communication skills<sup>16,17</sup>.

Studies have shown repeatedly that many health-care professionals do not have such skills<sup>16–19</sup>, and it is the lack of these skills which seems to be the main reason why communication breaks down. It has been identified that these skills are not innate in most health-care professionals, and need to be developed to a level of competence and confidence through research-based communication skills training<sup>19,20</sup>.

## INFORMATION AND CANCER

The information given to cancer patients about their diagnosis, treatment options and concerns about the future can have a profound impact on their psychological well-being<sup>21</sup>. Increasing evidence in cancer studies points to a need for an individualized approach to information giving<sup>15,22</sup>, as too much or too little (in areas such as treatment options or prognosis), can contribute to psychological distress. The challenge seems to lie in assessing what information individual patients require, rather than using

routine ways of supplying information, which ignores the individual's needs or preferences<sup>15</sup>.

Of concern in patients faced with surgery as an option for treatment of their cancer, whilst informed consent necessitates full information to patients, it does not currently require an interpretation or expression of comprehension of that information. Lack of access to not only an adequate level of information, but also interpretation and application of accepted treatment guidelines (including potential risks and even uncertain benefits), appears to be a crucial issue in the provision of information and patient autonomy<sup>23</sup>. It is also suggested that supportive, individualized information strategies may have positive consequences for accruing patients to clinical trials<sup>24</sup>.

## DECISION MAKING AND CANCER

The concept of user involvement in the development, monitoring and delivery of cancer treatment has been accompanied by a reduction in the paternalistic approach to patients, where patient opinion and decisions about treatment are valued as an essential component, and where consideration of the whole person, including their carers, is incorporated into a more holistic and supportive approach to care. Patients' attitudes, their coping resources, and their ability and willingness to be involved in decisions about their management may be influenced by previous experience of disclosure and information received<sup>25,26</sup>. Furthermore, how patients feel about how they have been included and involved in decision making can result in dissatisfaction and non-compliance<sup>27</sup>, and may contribute to an adverse outcome<sup>28</sup>.

Decision making is not just a one way process of the health-care professional telling the patient what will be. In today's environment, the 'expert patient'<sup>28</sup> is better informed than their predecessor and many will expect to be involved in the decision process that determines their treatment. In many cancers, combination therapy utilizing surgery, chemotherapy, radiotherapy, and biotherapy may be the norm. Different ways of describing the outcomes of treatment can have a dramatic impact on patient treatment decisions<sup>29</sup>. This has implications for not only what is said, but also how it is said and by whom, and contributes to the complexity faced by health-care professionals in supporting patients through information giving and decision making<sup>23</sup>.

Translating scientific data from clinical trials into layman's language contributes to the dilemma for health-care professionals. Patient involvement in decision making seems to be influenced by<sup>25</sup>:

- Conflicting expectations between doctor and patient about the most appropriate treatment

- Unexpected information
- Issues related to treatment costs and benefits
- Lack of clear treatment recommendations from the oncologist.

Marked differences in decision making role preferences, but similarities in information needs have been identified<sup>26</sup>. In breast cancer patients only 52% chose a passive role in decision making as compared to 78% of colorectal cancer patients. Of colorectal patients 80% and of breast patients 61% recalled the doctor making treatment decisions. The main concerns for information in both patient cohorts were in relation to:

- Cure
- Spread of disease
- Treatment options.

A later study<sup>30</sup> confirmed that whilst patients wanted information and to feel included in the consultation, they did not necessarily want to be involved in decisions about their care.

## PSYCHOLOGICAL DISTRESS AND CANCER

### Anxiety

Most patients will be apprehensive about their cancer, and some may experience stronger psychological responses including feelings of anxiety, resentment, anger, and even panic attacks<sup>31</sup>. Anxiety in the patient with cancer may be induced by the patient perceiving threats to survival and well being, as well as their uncertainty about the future<sup>31</sup>. Applying this to the patient faced with cancer surgery, anxiety may be compounded by fear of death from surgery or anesthetic, as well as fear of pain and mutilation. Integral to this major significant area influencing the level of anxiety is the stage of cancer<sup>31</sup>. Whilst patients with early stage cancer can often have a long life expectancy and anticipation of curative surgery, patients diagnosed with advanced cancer or those with a recurrence or metastatic spread have to face the emotional consequences of imminent death. This emotional burden usually causes intense emotional reactions, including clinical states of anxiety.

### Depression

Depression in the patient with cancer, like anxiety is one of the most difficult psychological problems to identify<sup>32</sup>, and some suggest it may be underestimated<sup>33</sup>. As a simple cut-off point it is said to be significant when the sadness

response (e.g. depressed mood, insomnia, fatigue, feelings of worthlessness, diminished ability to think) to a disclosure of a cancer diagnosis or poor prognosis, lasts more than 2 weeks<sup>34</sup>. A useful concept when considering whether a patient is depressed is that the patient who blames the illness for how they are feeling is probably experiencing sadness, whereas the patient who blames themselves for their illness and how they are feeling may well be depressed<sup>32</sup>. The surgeon and the whole health-care team should be receptive to any signs of depression in the patient.

The concern is that if health-care professionals assess depression as a normal feature of cancer, there is a risk that depressed cancer patients may go undiagnosed and untreated<sup>35</sup>. It has been suggested that there is some reluctance amongst many health-care professionals to initiate and explore psychological issues with their patients as they are concerned that this will exacerbate patients' distress<sup>35</sup>. Another reason suggested is that health professionals feel powerless to influence the situation and so do not intervene<sup>35</sup>. However, other studies<sup>17,18,20</sup> indicate that the main reason why they do not pursue these sensitive issues with patients is the lack of communication and interpersonal skills of health-care professionals to draw out and explore patients' concerns and so fail to identify and meet their information needs and decision making preferences.

## THE PSYCHOLOGICAL NEEDS OF THE CANCER SURGERY PATIENT

The psychological needs of the patient having cancer surgery are similar to those of any patient having surgery. They include:

- An ability to understand the need for surgery and the procedure proposed
- Having the resources to deal with the physical and mental discomfort involved to achieve the intention of improved health and survival.

Surgery plays a crucial role in the curative treatment of cancer, so the stigma of cancer and its threat to survival can add to the psychological demands on an individual and their family/carers. Developing rapport with the patient, acknowledging the existence of stress factors, supplying empathetic support and information from the point of disclosure of diagnosis and especially during the preoperative period, can have an impact on how patients cope with their cancer, their postoperative recovery and rehabilitation, including their psychological well-being.

The majority of patients affected by cancer will undergo some sort of surgical procedure, as surgical

oncology is not just the removal of a tumor, but can include diagnosis and staging of cancer, by for example biopsy at staging laparoscopy, prevention, reconstruction, palliation, and supportive surgery.

The impact of cancer surgery, and where the procedure sits within the context of the individual's cancer journey, coping resources and responses must be considered. The meaning a patient attaches to the surgical procedure will vary according to both their previous experience and the aims of the surgery. This may also be influenced by the explorative or definitive nature of the surgery, whether the tumor is resectable, and any functional consequences including loss or deficit. The meaning an individual attaches to a biopsy taken for diagnostic purposes at staging laparoscopy, a curative liver resection, or palliative surgery to relieve gastric outflow obstruction in cholangiocarcinoma will be different for each individual.

## PSYCHOLOGICAL ADAPTATION

### Medical variables

Medical variables that may influence psychological adaptation to cancer surgery include:

- Site, stage and potential for curability with either surgery alone or as part of a multimodal approach to treatment
- Functional deficit as a consequence of surgery
- Rehabilitation available including reconstruction
- The surgeon and other health-care professionals' acknowledgment of and management of the patient's psychological needs.

### Patient variables

Patient variables that may influence psychological adaptation to cancer surgery include:

- Meaning attached to the cancer diagnosis (or potential diagnosis)
- The risks and benefits the patient perceives of the surgical procedure, including the anesthetic
- The functional consequences
- The individual patient's psychological response and ability to cope with both the stress of surgery and the cancer diagnosis
- History of psychiatric disorder, particularly depression
- Response to surgeon and relationship established.

## PREOPERATIVE CARE

How the patient presents for possible surgery for cancer and how they are adapting and coping with their cancer diagnosis may well be influenced by how they have been managed during their cancer journey. Patients who have experienced a protracted diagnosis associated with doubt about their symptoms, poor disclosure of diagnosis and delay in receiving an appointment to meet with the cancer specialist may be more psychologically maladjusted to their cancer diagnosis than someone whose experience has been well managed with prompt referral from their general practitioner through a speedy process of investigations (accompanied by information and support from health-care professionals along the way), and timely recall to discuss diagnosis and ongoing management options.

As such, it is important at the time of meeting with the patient for the first time for the surgeon to assess the patient's experience and understanding of why they are there, to check their understanding of their diagnosis, to elicit any concerns, to identify and clarify any misconceptions they may have about their cancer. It is only then that the surgeon can start to explore surgical treatment options with the patient. Encouraging the inclusion of a family member or friend to be present acts as resource to the patient for support and also acknowledges the carer's important role in the patient's life as well as their potential involvement in care and rehabilitation after discharge.

Whilst preoperative information to the patient could almost be seen as a checklist, how that information is divulged in response to an individual assessment of the patient's information needs and concerns should be accompanied by a collaborative and proactive approach with the patient as it may be that the patient when asked if they have any questions or concerns will respond 'but I don't know what I need to know'. Again, inclusion of the carer should be encouraged. Providing the patient with a preclinic list of questions may help them prepare questions to ask, and endorse that it is okay to ask questions. An example of such a list is given in Table 7.1.

Questions that acknowledge that the patient may have concerns such as 'how are you feeling about this surgery?' encourage them to explore fears, and to voice any related anxieties they may have about probable pain, discomfort or any physical changes. If surgery involves loss of a limb, formation of a stoma, or involves the sexual organs, such open-ended questions allow the patient to explore concerns they may have about sexual function and body image.

**Table 7.1** List of questions to be given to patients prior to attendance at clinic to help them prepare their own questions

Attending hospital and undergoing tests can be quite an anxious time for you. Whilst we try very hard to give you all the information you require to understand and decide about the most appropriate treatments available to you, you and your family may have questions to ask. However, these may only occur to you after you have met with the consultant. **SO, WHY NOT WRITE THEM DOWN?**

Other patients with cancer have found it useful to ask some of the following questions

- What are the results of my tests?
- Where exactly is the tumor and how big is it?
- Is it malignant or non-malignant?
- Has the tumor spread to any other areas?
- What treatments are available to me?
- Do I need surgery or do I need chemotherapy?
- Would I benefit from a combination of treatments?
- Why is this particular treatment recommended for me?
- Can I be cured?
- What will happen if I don't have treatment?
- What are the chances of the tumor returning or spreading?
- Is this a unit specializing in my type of tumor?
- Who will be treating me?
- Has the doctor received specialist training for treating my type of tumor?
- What will the treatment entail, e.g. time in hospital, side-effects, the risks involved, the number of treatments I will need?
- Once I have had my treatment how will I be followed up?
- Is there anyone I can talk to who has had my type of treatment?

### **Important issues to explore with the patient include:**

- The purpose of surgery – is it prophylactic, diagnostic, staging, curative, or palliative?
- The benefits of the surgery proposed
- The risks of surgery for the individual (complications, peri/postoperative death) taking into account other co-morbidity
- What kind of surgery will be performed and what pre-operative preparation is required (e.g. bowel prep, fasting). Proposed incision, postoperative drains, infusions and pain control
- Admission to a high dependency area if necessary
- Treatment options if inoperable disease is found at time of surgery
- Proposed admission date, preoperative screening, anticipated recovery time, and potential discharge plan
- Control of postoperative pain, including pain assessment, methods of pain control (e.g. epidural, patient controlled analgesia), and managing pain and discomfort postdischarge.
- Anticipated rehabilitation postdischarge
- Location of carer on day of surgery, and contact telephone number. Access to carer accommodation during patient stay.

Having access to a contact number of a member of the multidisciplinary team such as a clinical nurse specialist or nurse practitioner who ideally has been present at the consultation and is available to discuss any related concerns or queries can be useful to both the patient and their carer, but also acts as a support to the surgeon,

knowing that any concerns will be acknowledged, and when possible addressed, prior to the patient's admission. Following discussion at the outpatient appointment patients and their carers may find it helps to write down information, and a summary sheet can be provided with the following headings:

- Your diagnosis
- The need for any further investigations
- Treatment options discussed
- The next stage of treatment
- The questions and answers we have explored together.

## ENHANCING PHYSICAL WELL-BEING AND PSYCHOLOGICAL DISTRESS

The cancer patient awaiting surgery may be affected by a number of symptoms associated with their cancer, including side-effects of tumor mass, tumor obstruction, tumor toxicity, and side-effects of chemotherapy or radiotherapy. Assessing and alleviating physical symptoms such as pain, nausea, vomiting, diarrhea, fatigue, or anorexia can contribute to both the patient's physical and mental recovery. Proactive preoperative treatment and management of these side-effects are more likely to equip the patient to deal better with the trauma of surgery and the challenges of recovery. Immediate postoperative needs of all surgical patients including cancer patients are primarily physical and the usual postoperative care protocols should be adhered to.

## PREPARING THE PATIENT FOR UNEXPECTED FINDINGS AT TIME OF SURGERY

An important area of information to discuss with patients preoperatively is the issue of finding inoperable disease at the time of surgery. Acknowledging that this can happen (despite improvements in radiological imaging and access to staging laparoscopy), and exploring strategies for alternative management of the patient's cancer are important areas to cover, preferably in the company of their family/carer. Preparing the patient in such a way sows the seeds for dealing with the 'open and close' situation more positively and maintains hope by reminding the patient that although surgery has not been possible, and that their cancer may therefore be incurable, there are other treatment options that will be considered to manage their cancer.

## POSTOPERATIVE PSYCHOLOGICAL NEEDS

When the patient is rousing from anesthetic it has to be anticipated that they will start to ask questions such as 'was it cancer?', 'as it all gone?', and 'has it spread anywhere else?' Answering questions at this stage should be avoided until the patient has recovered from the anesthetic and the surgeon is able to explain the findings at surgery and the procedure performed, or not, to the patient accompanied preferably by their relative or carer.

It is of further historical interest to note that in relation to discussing incurable disease found at surgery it has been suggested that<sup>6</sup>:

*If the doctor-patient relationship is one which each feels free to communicate with the other, telling the patient that he is incurable, although never easy, is less painful. Here, again, if we listen to the patient he will let us know when he can be told and how much he can tolerate hearing.*

*Once the essentials of truth are explained in the proper manner, the way becomes clear for the next phase . . . hope . . . the words 'incurable' and 'hopeless' are not synonymous. To tell a patient that his condition is hopeless is both cruel and technically incorrect. Incurability is a state of mind, a giving up – a situation that must be avoided at all cost. A patient can tolerate knowing he is incurable; he cannot tolerate hopelessness<sup>6</sup>.*

For the patient who has inoperable disease found at surgery, the surgeon and the multidisciplinary team should anticipate and encourage discussion with the patient and carer in the postoperative period about the implications of inoperable disease, and support the adjustment to the fact that inoperable in most cancers also means incurable. Again, the clinical nurse specialist or nurse practitioner who knows the patient is best placed to support the individual and their carers and to meet their information needs. Setting up an early appointment with the medical oncologist to discuss palliative treatment options can be beneficial, prior to, or soon after discharge.

## PSYCHOLOGICAL ISSUES

Psychological issues to be explored in the context of the aims of surgery include:

- Prophylactic
- Diagnostic
- Definitive

- Reconstructive
- Palliative
- Supportive surgery.

### Prophylactic surgery and psychological needs

Prophylactic surgery is usually considered in those individuals who have a family history of a certain type of cancer such as breast, ovarian, or colorectal cancer, and in whom an underlying condition or a genetic predisposition may put them at higher risk of developing the disease<sup>36</sup>. The psychological challenges to an individual faced with the decision to undergo surgery to remove currently benign tissue or organs to prevent the development of cancer, may be compounded by the knowledge that they have a genetic defect that can be passed on with or without surgery. Whilst surgery at this time might prevent the disease developing, there are also consequences to quality of life following surgical removal of body parts resulting in, for example, altered body image, sexual function, and how an individual feels about their self-image and confidence. Benefits may not always be as great as the individual had anticipated<sup>37</sup>. However, this also has to be weighed up against the alternative of intensive screening which may cause both reassurance with good results, but also at times distress in both the time leading up to the screening and when results are not favorable<sup>38</sup>.

For women with breast cancer it is necessary to acknowledge their social situation. Often, these women come from families where grandmothers, mothers, aunts, and cousins have been diagnosed, treated and died from breast cancer. As such, they live within an environment of uncertainty and fear of not only the occurrence of breast cancer but also fear about the effectiveness of treatments such as mastectomy, chemotherapy and radiotherapy. Ultimately, they live with the fear of living with cancer and the uncertainty of survival, and this along with concerns about their husband or partner and children, may influence their decision to undergo prophylactic mastectomy.

Supporting individuals faced with the prospect of prophylactic surgery is crucial. Accurate information about the benefits of surgery according to evidence available as well as the risks of surgery, and reconstructive surgery as an option must be explored. Time and timing are important. The decision should not be rushed. It is suggested that eliciting patient's concerns about their decision in the context of their role and responsibilities within their family and society, their age, occupation, culture, and religion and their own subjective assessment of the risk of developing cancer as well as their previous experiences with illness, death and the medical system are all important areas to be considered<sup>39</sup>.

Whilst prophylactic surgery might relieve an individual of the fear of developing cancer, the effects of the operation may take some adjustment, and this aspect must be acknowledged and discussed with the individual both prior to and as part of a rehabilitation following surgery to prepare them for both the physical discomfort of surgery, but also altered body image. After surgery, ongoing psychological support is essential as this is the time when they may be concerned about how they now appear to their husband or wife, whether they are as attractive with a stoma or having had a mastectomy. As such, the impact on their sexuality can be severely affected, not only in the way of sexual function, but also their self image and self confidence.

Psychological issues related to loss in for example young women that surgery will result in their inability to breast feed in the future, set against the thought that they may never have developed cancer anyway, are issues that must be acknowledged during the process of preparing the patient for prophylactic surgery.

### Diagnostic surgery and psychological needs

When malignancy is suspected, the accuracy of information gained during the diagnostic process is crucial in order that the most effective treatment decisions can be made. Whilst diagnostic imaging such as computed tomography (CT) or magnetic resonance (MR) scan and biochemistry and tumor markers can often confirm diagnosis, where there is uncertainty, a surgical procedure may be required. The major role for surgery at this stage is to acquire a sample of tissue for histological diagnosis, and techniques include fine needle aspiration, excisional biopsy, endoscopic biopsy, bone marrow biopsy, examination under anesthetic, and biopsy at staging laparoscopy.

Whilst many of these procedures may seem simple and routine to health-care professionals, for the individual patient affected by the uncertainty of their presenting symptoms, the time leading up to and including diagnosis can be associated with great anxiety and fear. Whilst they may seek an answer, the fear of what the results may show and the impact the diagnosis may have on their life as well as on those close to them, their role in their family, or their job compounds this anxiety. The coordination and management of the diagnostic phase is important as it can greatly affect the adjustment to and coping with a diagnosis of cancer. Waiting for an appointment, waiting for a scan and, waiting for results can increase anxiety and fear associated with uncertainty and loss of control, as well as fear that if it is cancer it will be growing and getting worse. Part of this coordination should include access to a key member of the cancer multidisciplinary team, such as a clinical nurse specialist who can acknowledge any

concerns, provide both support and information about how investigations are proceeding and who can act as a resource and coordinator during this crucial aspect of the patient's journey. This is particularly important as many diagnostic procedures take place in an outpatient or day case setting where the time available to assess patient's concerns and to meet their psychological needs may be limited. Another aspect of time and timing is delay in coming to definitive surgery which can affect the quality of life in newly diagnosed cancer patients<sup>40</sup>.

### Definitive surgery and psychological reaction

The aim of definitive surgery is to remove the cancerous tumor as well as a safe margin of normal tissue surrounding it<sup>41</sup>. In many patients with solid tumors, where the disease is confined to the anatomical site of origin, and the tumor is small (e.g. Dukes A cancer of the colon), this may be excised through a local resection, and will be the optimal chance of cure. However, it also carries with it anxiety in the patient that surgery has a successful outcome.

When discussing treatment options with the patient, it is important to know the stage of the cancer in order to know whether surgery might effect a cure, or whether combination treatment including surgery and adjuvant treatment such as chemotherapy might be necessary. Sometimes it is only after the tumor is excised and examined by the histopathologist that this essential staging information can be secured and the chances of cure or need for further treatment decided.

Where the tumor is large and there is a suspicion or evidence of metastatic spread, a more radical resection is usually necessary. This involves not only resection of the tumor but also resection of local and regional tissue, the lymphatics and a margin of tumor-free tissue, in an attempt to prevent further metastatic spread and local recurrence.

Psychological reactions to cancer surgery can be related to the site of surgery and the extent of functional loss<sup>42,43</sup>. Adverse emotional reactions correlate with the psychological significance of the loss, especially with the face, breast, genitals, or colon<sup>42,43</sup>. Site-specific problems also arise when surgery results in a major loss of a particular function. Examples of this include loss of normal bowel function with the formation of a colostomy, and the loss of normal speech when laryngectomy is performed<sup>43,44</sup>.

### Surgery as part of a multimodal approach to cancer treatment

When cancer is first detected, about 50% of all patients will have metastatic disease, with a probable high incidence of undiagnosed, occult metastases. Surgery, therefore, is

often used as a localized treatment and as part of a multimodal approach to increase chance of cure and to prolong disease-free survival.

The use of multimodal therapies does have consequences that need to be considered if surgery is part of the treatment plan. The timing of chemotherapy or radiotherapy before or after surgery can affect how the body copes with surgery. For example risk of chest infection or wound infection where neutropenia is a side-effect of chemotherapy, and delayed wound healing where radiotherapy has caused fibrosis and damage to lymphatic and vascular channels. The patient needs to be aware of these considerations such as allowing the body to recover following chemotherapy and prior to surgery, as they may associate delay of surgery with a less favorable outcome, rather than it being a considered decision within their treatment plan.

As well as curative intent, surgery with other treatment modalities may also be performed to debulk a tumor in for example ovarian cancer or in metastatic neuroendocrine cancer. However, debulking is usually only of benefit when it is used in conjunction with other treatments such as chemotherapy to control the residual disease left behind. Reduction of tumor mass can improve the outcome of radiotherapy or chemotherapy.

Traditionally, the presence of metastatic disease in the liver or the lungs has precluded the chance of cure. However, in such cancers as colorectal cancer, there is increasing evidence to show that surgical resection of liver metastases can play a part in cure<sup>45</sup> and as part of a multimodal, palliative oncological approach.

Furthermore, disease-free survival is also improving in those colorectal cancer patients who later develop lung metastases and undergo pulmonary resection<sup>45</sup>. However, treatment of metastatic disease very much depends on the primary cancer, and this is an important information issue for patients, and needs to be actively addressed by health-care professionals, to ensure that patients understand why surgical treatment options might, or might not, be available to them. For example, surgery is not a treatment option for liver metastases in the presence of pancreas cancer or breast cancer, but may be considered in a primary ocular melanoma or for lung metastases in soft tissue sarcoma.

### Reconstructive surgery and psychological needs

Radical cancer surgery can often result in marked physical deformity or loss of function. This physical loss also carries with it the risk of major psychological distress and social isolation. Approaches to reconstructive surgery to improve anatomical defects, function and cosmetic appearance have developed in an attempt to restore an



individual to as normal a life as possible following cancer surgery. Examples of reconstructive surgery include breast reconstruction, skin grafting, head and neck surgery, and artificial joints in sarcoma patients.

Reconstructive surgery must be considered as part of the treatment plan when considering surgery as an option, as in many cases, for example breast surgery, reconstruction may be carried out at the time of the initial operation. Health-care professionals need to consider that not only are patients often grappling with their diagnosis of cancer and radical surgery such as mastectomy, but also a further psychological challenge for patients is the decision whether to have reconstructive surgery at this time or later<sup>42</sup>. Options for reconstruction should be discussed clearly with the patient and having support of the presence of a spouse or family member may help. Whilst breast reconstruction is often considered to be in the individual's best interest and can minimize some of the negative consequences of breast cancer<sup>42</sup>, it can be undertaken at a later date if the individual would prefer or cannot decide.

In head and neck cancer surgery, reconstruction is not an option as it is a necessary part of the surgery to excise the tumor. Overall, head and neck surgery is viewed as more complex than other regions as it carries challenges to the surgeon in both essential and social functions as well as the individual's appearance.

Studies have shown that as well as coping with a cancer diagnosis, patients who have had head and neck cancer surgery view themselves as different to how they were, physically, emotionally and in their self-identity, and this can result in a negative outcome in their relationship with others and their sexuality<sup>43</sup>. Techniques in head and neck surgery are improving all the time in an attempt to reduce physical disfigurement and loss of function, and to optimize cosmetic appearance. However, a major difficulty in this cancer type is finding the balance between surgical excision and reconstruction with the challenge and prospect of early local recurrence in relation to physical and psychological morbidity and quality of life<sup>44</sup>. It has to be considered that the loss of ability to eat and talk, and to be physically disfigured is a high price to pay if prognosis is limited<sup>41</sup>.

Whilst a diagnosis of cancer has associated physiological, psychological and social challenges, the decision or the ability to have reconstructive surgery can affect an individual's lifestyle and sense of self<sup>42</sup>. Reconstruction can facilitate self-esteem, promote return to a normal lifestyle, and helps the individual to cope with their diagnosis and treatment. When exploring diagnosis and treatment options, health-care professionals need to provide a supportive environment where options and information about consequences of surgical treatment can be discussed and concerns acknowledged. Where appropriate, careful

emotional and physical planning and information about reconstruction must be included so that the individual can come to an informed decision. It has to be stressed<sup>39</sup> that whilst reconstructive surgery will result in 'a breast' or 'a tongue', it will not be the same as the real thing, in that a reconstructed breast will not feel or move in the same way or have the same sensual feeling. Likewise the replacement of a tongue with a platform of tissue (a latissimus dorsi myocutaneous flap) may help to restore some of the ability to swallow and maintain intelligible speech, but it will not be the same. As such, a balance needs to be made between optimism and realism, and between quality of life and length of life.

Individuals having reconstructive surgery and their spouse/carers will also need support with adjusting to their new self and their new identity. Whilst uncertainties will still exist about the outcome of treatment, and future prognosis, reconstructive surgery may play a vital role in allowing the individual to face that uncertain future<sup>41</sup>. New approaches to psychological support that include the patient's partner in a psychosocial model of support has demonstrated some success in breast cancer<sup>46</sup>. Findings of a randomized controlled trial indicate that such an intervention increases quality of life, reduces uncertainty and improves family communication. Patients and their family members gained benefit from help focusing on the here and now, as well as strategies for supporting one another.

### Palliative surgery and psychological needs

When cure is no longer an option, surgery can be effective for relieving symptoms that develop in the advanced stages of cancer. Examples of palliative surgery include:

- Treatment of a fungating breast wound
- Relief of bowel obstruction in ovarian cancer
- Debulking of a tumor to control discharge, the formation of fistulae, or hemorrhage
- Prevention of hemorrhage when a tumor is pressing on a vital blood vessel
- Prophylactic or therapeutic pinning of metastases in long bones
- Spinal surgery to prevent or stabilize spinal cord compression
- Debulking of tumor to control infiltration of nerves which cause neuropathic pain
- Insertion of intraepidural or intrathecal catheters for spinal opioids or neuro-lytic blocks for pain in such cancers as pancreas or gallbladder cancer.

The aim of palliative surgery is to relieve suffering and to minimize the symptoms of the disease, so that if the quality of life will not be improved, or if there is an unnecessary risk of morbidity or mortality, then palliative surgery should not be considered. Individuals and their spouse/carers need to be informed of the aims of palliative surgery, so that they can be realistic in their expectations of the surgery and make an informed decision. Some individuals may refuse palliative surgery, preferring to spend what time they have left without submitting themselves to a hospital stay or the risks of surgery, whilst others may welcome the surgical intervention and see it as a treatment that may prolong their life. Again, individuals should be supported in their decision, as the signs and symptoms that require palliative surgery are invariably those of progressive disease, and as such realistic expectations of surgery should be reiterated, and the patient supported to understand these. Palliative surgery needs to be considered on an individual basis and the decision based on each individual's symptoms and their current quality of life against how surgery might improve that quality.

### Supportive surgery and psychological needs

Supportive surgery for the individual with cancer may include any of the following:

- Providing venous and arterial access for the administration of cytotoxic drugs
- Providing venous and arterial access for the administration of nutritional support
- The ablation of functioning ovaries in women under 50 years old with early breast cancer.

The use of an indwelling catheter such as a Hickman line has been shown to have not only made a marked improvement to the safety of administering cytotoxic drugs, but also to the quality of life of the individual with cancer<sup>47</sup>, though the altered body image seems to be under researched, and this should be assessed with the individual when considering use of an indwelling catheter. The reason why the line is proposed needs careful discussion with the individual and their spouse/carers. Whether the line is going to be used with the intention of a curative procedure, such as bone marrow transplant, or is to be used for palliative intervention such as palliative chemotherapy when the goal is to prolong life but not cure should be discussed. Furthermore, the individual and their spouse/carers need to be taught about all aspects of care, function and maintenance of the line, to ensure that they understand the implications and are prepared and supported to care for it safely.

### Cancer surgery and carers

Increasing evidence demonstrates the need to involve family members and carers at all stages of the patient's cancer journey<sup>48</sup> with consequences for their psychological health if excluded<sup>48,49</sup>. There is a trend towards shorter hospital stay, and once fit for discharge following cancer treatment including surgery, most individuals continue their rehabilitation at home being cared for by a spouse or carer. The emergence of 'informal carers', usually a family member or close friend, who provide unpaid assistance for their dependant relatives living in the community is becoming more specifically recognized on the health and social care policy agenda<sup>50</sup>. However, there are still significant gaps in our understanding of family care with concern about the fact that caring relationships are rarely seen as reciprocal and tend to be interpreted as unrewarding and damaging, with an emphasis on the physical burden of caring<sup>50</sup>.

### Carers and psychological distress

Studies looking at the experiences of carers have helped to inform the factors which predict psychological distress in carers in cancer and palliative care<sup>48,51,52</sup>. The emphasis on information need is prevalent in many of these cancer studies with carers indicating that they would have welcomed more information and support at an earlier stage<sup>48</sup>, someone to talk to<sup>52</sup>, that their information needs are different to those of patients, and should be assessed on an individual basis<sup>51</sup>. Understanding details related to the illness seemed to help carers cope with the situation<sup>51</sup>, and fear of not knowing what to do or expect greatly increased carers stress, as did poor coordination of care<sup>52</sup>. Overall carers would have appreciated more educational input from health-care professionals.

The attitude of health-care professionals who view the carer 'not as a person in their own right, but merely as an appendage to the patient' or even 'a co-worker' may contribute to increased levels of psychological distress<sup>53</sup>. Whilst carers are apparently recognized in policy, there are still uncertainties as to whether carers are providers or users of services, or whether they should be acknowledged as experts in their own right<sup>50</sup>.

### SUMMARY

Whilst the communication and psychological needs associated with cancer surgery reflect those of an individual undergoing any type of surgery, the added impact of a cancer diagnosis, its uncertainty and threat to life make increased demands on coping resources for psychological well-being. The meaning of surgery to the patient with

cancer is important and will vary for each individual. In order for health-care professionals to give the care that is necessary, effective communication skills and an understanding of the range of psychological responses to cancer and cancer surgery are essential. It would appear that preparation for surgery through preoperative discussion, acknowledgment of uncertainties, information exchange,

and support in decision making can make a difference, and can influence the postoperative course and adjustment. Inclusion of spouse or carer at all stages, with appropriate information and involvement can enhance both the patient's and the carer's psychological well-being and may result in a more favorable outcome of the cancer surgery experience.

## REFERENCES

- Jeffrey D. What do we mean by psychosocial care in palliative care? In: Lloyd-Williams M, ed. *Psychosocial Issues in Palliative Care*. Oxford: Oxford University Press 2003: 1–5.
- Sutherland AM, Orbach CE. Psychological impact of cancer and cancer surgery: II. Depressive reactions associated with surgery for cancer. *Cancer* 1953; 6: 958–62.
- Bard M, Sutherland AM. Psychological impact of cancer and its treatment: IV. Adaptation to radical mastectomy. *Cancer* 1955; 8: 652–72.
- Renneker R, Cutler M. Psychological problems of adjustment to breast cancer. *JAMA* 1952; 148: 833–8.
- Pack GT. Counselling the cancer patient: surgeon's counsel. The Physician and the total care of the cancer patient: A symposium presented at the 161 scientific session of the American Cancer Society. New York: American Cancer Society, 1962: 56–61.
- Stehlin JS, Beach KH. Psychological aspects of cancer therapy. *JAMA* 1966; 197: 140–4.
- Hinton J. The physical and mental distress of the dying. *Q J Med* 1963; 32: 1–21.
- Maguire GP, Lee EG, Bevington DJ et al. Psychiatric problems in the first year after mastectomy. *Br Med J* 1978; 1: 963.
- Greer S, Morris T. Psychological attributes of women who develop breast cancer; a controlled study. *J Psychosom Res* 1975; 19: 147–53.
- Schmale AH. Psychological reactions to recurrences, metastases, or disseminated cancer. *Int J Radiat Oncol Biol Phys* 1976; 1: 515–20.
- Maguire GP, Tait A, Brooke M et al. Effect of counselling on the psychiatric morbidity associated with mastectomy. *Br Med J* 1980; 281: 1454–6.
- Hopwood P, Howell A, Maguire P. Psychiatric morbidity in patients with advanced cancer of the breast: prevalence measured by two self-rating questionnaires. *Br J Cancer* 1991; 64: 349–52.
- Taylor KM. Telling bad news: physicians and the disclosure of undesirable information. *Sociol Health Illn* 1988; 10: 109–32.
- Fallowfield LJ. No news is not good news. *Psychooncology* 1995; 4: 197–202.
- Maguire P. Breaking bad news. *Eur J Surg Oncol* 1998; 24: 188–91.
- Maguire P, Faulkner A, Booth K et al. Helping cancer patients disclose their concerns. *Eur J Cancer* 1996; 32A: 78–81.
- Heaven CM, Maguire P. Training hospice nurses to elicit patient concerns. *J Adv Nurs* 1996; 23: 280–6.
- Booth K, Maguire P, Butterworth T et al. Perceived professional support and the use of blocking behaviours by hospice nurses. *J Adv Nurs* 1996; 24: 522–7.
- Fallowfield L, Jenkins V, Farewell V et al. Efficacy of a cancer research UK communication skills training model for oncologists: a randomised controlled trial. *Lancet* 2002; 359: 650–6.
- Wilkinson S, Roberts A, Aldridge J. Nurse-patient communication in palliative care; an evaluation of a communication skills programme. *Palliat Med* 1998; 12: 13–22.
- Butow PN, Kazemi JN, Beeney NJ et al. When the diagnosis is cancer: patient communication experiences and preferences. *Cancer* 1996; 77: 2630–7.
- Fallowfield LJ, Hall A, Maguire P et al. Psychological outcomes of different treatment policies in women with early breast cancer outside a clinical trial. *Br Med J* 1990; 301: 575–80.
- Poston GJ, Byrne CH. Decision making for patients with colorectal cancer liver metastases. *Ann Surg Oncol* 2006; 13: 10–1.
- Wright JR, Whelan TJ, Schiff S et al. Why cancer patients enter randomised clinical trials: exploring the factors that influence their decision. *J Clin Oncol* 2004; 22: 12–8.
- Sanders T, Skevington S. Participation as an expression of patient uncertainty: an exploration of bowel cancer consultations. *Psychooncology* 2004; 13: 675–88.
- Beaver K, Bogg J, Luker KA. Decision making role preferences and information needs: a comparison of colorectal and breast cancer. *Health Expect* 1999; 2: 266–76.
- Dowsett SM, Saul JL, Butow PN et al. Communication style in the cancer consultation: preferences for a patient-centred approach. *Psychooncology* 2000; 9: 147–56.
- Coulter A. Paternalism or partnership? Patients have grown-up and there's no going back. *Br Med J* 1999; 319: 719–20.
- Martin RCG, Studts JL, McGuffin SA et al. Method of presenting oncology treatment outcomes influences patient treatment decision making in metastatic colorectal cancer. *Ann Surg Oncol* 2006; 13: 86–95.
- Beaver K, Jones D, Susnerwala S et al. Exploring decision making preferences of people with colorectal cancer. *Health Expect* 2005; 8: 103–13.
- Maguire P. Psychosocial interventions to reduce affective disorders in cancer patients: research priorities. *Psychooncology* 1995; 4: 113–9.
- Lloyd-Williams M. Screening for depression in palliative care. In: Lloyd-Williams M, ed. *Psychosocial Issues in Palliative Care*. Oxford: Oxford University Press. 2003: 105–18.
- Ibbotson T, Maguire P, Selby P et al. Screening for anxiety and depression in cancer patients. *Eur J Cancer* 1994; 30A: 37–40.
- Barracough J. *Cancer and Emotion: Practical guide to Psychooncology*. Chichester: Wiley, 1994.
- Block S. Assessing and managing depression in the terminally ill patient. *Ann Intern Med* 2000; 132: 209–18.

36. Rosenberg SA. Principles of cancer management: surgical oncology. In: De Vita VT, Hellman S, Rosenberg SA, eds. *Cancer: Principles and Practice of Oncology*, 5th edn. Philadelphia, PA: Lippincott-Raven, 1997; 1: 295–306.
37. Grann VR, Panageas KS, Whang W et al. decision analysis of prophylactic mastectomy and oophorectomy in BRCA1-positive or BRAC2-positive patients. *J Clin Oncol* 1998; 16: 979–85.
38. Fentiman IS. Prophylactic mastectomy: deliverance or delusion? *Br Med J* 1998; 317: 1402–3.
39. Downing J. Surgery. In: Corner J, Bailey C, eds. *Cancer Nursing: Care in Context*. Blackwell Science Ltd. London, England. 2001; Chapter 10, 156–78.
40. Visser MR, van Lanschot JJ, van der Velden J et al. Quality of life in newly diagnosed cancer patients waiting for surgery is seriously impaired. *J Surg Oncol* 2006; 93: 571–7.
41. Davidson T, Sacks N. Principles of surgical oncology. In: Horwich A ed. *Oncology: A Multidisciplinary textbook*. London: Chapman and Hall, 1995: 101–15.
42. Neill KM, Armstrong N, Burnett CB. Choosing reconstruction after mastectomy: a qualitative analysis. *Oncol Nurs Forum* 1998; 25: 743–50.
43. Gamba A, Romano M, Grosso IM et al. Psychosocial adjustment of patients surgically treated for head and neck cancer. *Head Neck* 1992; 14: 218–23.
44. Rhys-Evans F. Tumours of the head and neck. In: Saunders C ed. *Nursing the patient with cancer*. London: Prentice Hall, 1996; 178–201.
45. Poston GJ. Surgical strategies for colorectal liver metastases. *Surg Oncol* 2004; 13: 125–36.
46. Northouse L. Factors affecting couples adjustment to recurrent breast cancer. *Res Nurs Health* 1995; 18: 515–24.
47. Alexander H. Vascular access and specialised techniques of drugs delivery. In: De Vita VT, Hellman S, Rosenberg SA, eds. *Cancer: Principles and Practice of Oncology*, 1, 5th edn. Philadelphia, PA: Lippincott-Raven, 1997; 725–34.
48. Payne S, Smith P, Dean S. Identifying the concerns of informal carers in palliative care. *Palliative Medicine* 1999; 13: 37–44.
49. Davis BD, Cowley SA, Ryland RK. The effects of terminal illness on patients and their carers. *J Adv Nurs* 1996; 23: 512–20.
50. Nolan M, Grant G, Keady J. The Carers Act: realising the potential. *Br J Community Health Nurs* 1996; 1: 317–22.
51. Rose KE. A qualitative analysis of the information needs of informal carers of terminally ill cancer patients. *J Clin Nurs* 1999; 8: 81–91.
52. Beaver K, Luker KA, Woods S. Primary care services received during terminal illness. *Int J Palliative Nurs* 2000; 6: 220–7.
53. Twigg J. Models of carers: how do social care agencies conceptualise their relationship with informal carers. *J Soc Policy* 1989; 18: 53–66.

# Oropharynx

J Matthew Conoyer and James L Netterville

## GENERAL INTRODUCTION

Recognized for millennia, oropharyngeal malignancies have become commonplace only in recent centuries due to longer life expectancies and widespread tobacco abuse. Surgical resection of the oropharyngeal primary was attempted only by those of exceptional fortitude before the advent of modern anesthesia. In the early 19th century, Sedillot described an early mandibular swing approach, splitting the lip, mandible and floor of mouth on a conscious, restrained patient<sup>1</sup>. Such heroic efforts were extraordinarily morbid and disfiguring, and offered poor oncological control. Exsanguination and tracheotomy were common, as were postoperative infection, dysarthria and dysphagia. For decades, surgeons and patients alike approached oropharyngeal cancer with great timidity. General Ulysses S Grant died in 1885 having slowly succumbed to tonsillar squamous cell carcinoma (SCC) with only symptomatic treatment.

Radiation therapy was introduced as an oncological treatment modality near the beginning of the 20th century. In its infancy, radiation doses were measured by the skin toxicity they produced. Treatment-related morbidity was lessened with the introduction of shielding techniques, and between 1920 and 1940 radiotherapy was heralded as a non-disfiguring panacea for pharyngeal cancer. Local control rates remained poor with 30–40% developing early-onset regional metastasis. The need for improved locoregional control led to a surgical resurgence based on the neck dissections popularized by Butlin and Crile. Superior control was soon realized by using radiotherapy in conjunction with radical surgery. Multidisciplinary care became standard in the mid-to-late 20th century, leading to nominally improved cure rates in the setting of advanced disease<sup>2</sup>.

Systemic cytotoxic chemotherapy was introduced as a viable adjunct to head and neck cancer treatment in the 1970s, but neoadjuvant and adjuvant applications failed to improve cure rates. It was not until the mid-1980s that significant progress was made with the first concurrent chemoradiation protocol. In the past quarter century, further

clinical trials have proven the efficacy of this modality. Concurrent chemoradiation demonstrates better local control, fewer systemic recurrences, and improved disease-specific and overall survival. Among all demographics, head and neck cancer mortality rates declined more from 1990 to 1997 than those of any other malignancy<sup>3</sup>.

## BIOLOGICAL PERSPECTIVE

### Introduction

The oropharynx is a dynamic fibromuscular conduit connecting the oral cavity to the nasopharynx and hypopharynx. It is composed of four major subsites: the tonsil, tongue base soft palate and pharyngeal wall. The oropharynx plays a central and active role in respiration, phonation and deglutition.

Tumors of the oropharynx are responsible for 2100 deaths annually in the USA<sup>4</sup>. The oropharynx does not lend itself well to routine self-examination, commonly delaying detection of an invasive malignancy. While early lesions are diagnosed regularly, most present with locally advanced primaries and regional cervical metastases. Oropharyngeal cancer presents a complex therapeutic challenge to the head and neck surgeon, who must optimize both oncological control and functional outcome. The oropharynx is exquisitely sensitive to radiotherapy and chemotherapy and is amenable to large scale surgical resection. A multidisciplinary team approach is therefore essential to design treatment protocols with minimal impositions on the patient's quality of life.

### Etiology

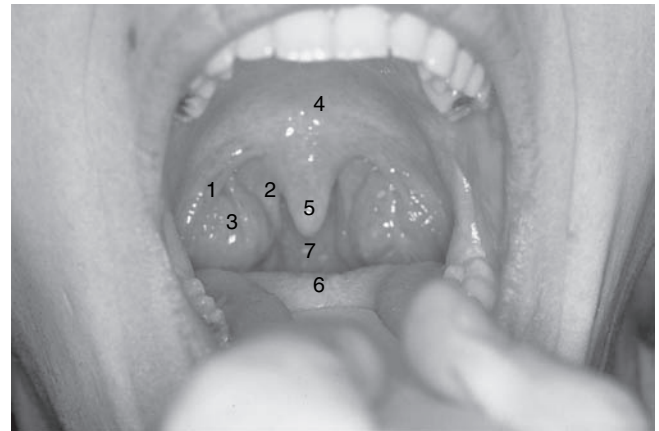
In an attempt to explain the relatively high incidence of second primary tumors and recurrences in the head and neck, Slaughter first introduced the concept of 'field cancerization' in his classic 1953 treatise<sup>5</sup>. His theory has evolved to describe multistep carcinogenesis in head and neck mucosa exposed to environmental toxins over time.

*TP-53* mutated epithelial stem cells escape normal growth controls, giving rise to a clonal population of daughter cells that displaces normal epithelium<sup>6</sup>. Recent studies suggest these preneoplastic ‘fields’ are of monoclonal origin, as are many of the multiple malignant foci arising from them<sup>7,8</sup>. The implications of field effect on the diagnosis, management, prognosis, and follow-up of oropharyngeal cancer remain uncertain.

Precancerous lesions of the oropharynx often manifest as leukoplakia and erythroplakia, descriptive terms derived from the Greek for ‘white plaque’ and ‘red plaque’, respectively. Leukoplakia is a commonly encountered white patch of abnormal mucosa that cannot be removed without excision or ablation. The lesions frequently regress with removal of the offending agent, but can progress to invasive carcinoma in 3–17% of cases. Leukoplakia is thought to herald 18% of all invasive oropharyngeal SCCs<sup>9</sup>. True erythroplakia is a more concerning finding. Present in less than 1% of the population, erythroplakia harbors invasive carcinoma in 51%, carcinoma *in situ* in 40%, and mild to moderate dysplasia in 9%<sup>10</sup>. Both leukoplakia and erythroplakia are more common in the oral cavity, but in the oropharynx are found primarily on the soft palate. Both lesions warrant excisional biopsy and careful follow-up surveillance.

## Histopathology

Of oropharyngeal malignancies 90% of oropharyngeal malignancies are SCC and its variant subtypes (Figure 8.1). Conventional SCC exhibits a 2–6 week doubling time. Its rapid growth is accompanied by a propensity for early local invasion and regional metastasis. Keratinizing, non-keratinizing and spindle cell variants all behave and are treated similarly to conventional SCC. Verrucous carcinoma is characterized by its white, fungating fronds of well-differentiated keratinized tissue. Slow growing, it has low metastatic potential and is often amenable to wide local excision. The basaloid squamous variant is a rare, aggressive tumor with a propensity for submucosal spread. Anecdotal evidence in the literature suggests regional and distant metastases are more common than in classic SCC, with predictably worse survival<sup>11</sup>. Oropharyngeal lymphoepithelioma usually arises from the palatine tonsil. Histologically identical to undifferentiated nasopharyngeal carcinoma, it favors younger patients without a substance use history. High rates of delayed regional and distant metastasis confer a 5-year disease-specific survival of only 59% despite its exquisite radiosensitivity<sup>12</sup>. Malignant neoplasms of the minor salivary glands occasionally present in the oropharynx. The most common of these are mucoepidermoid carcinoma, adenoid cystic carcinoma and the adenocarcinomas. Treatment is surgical



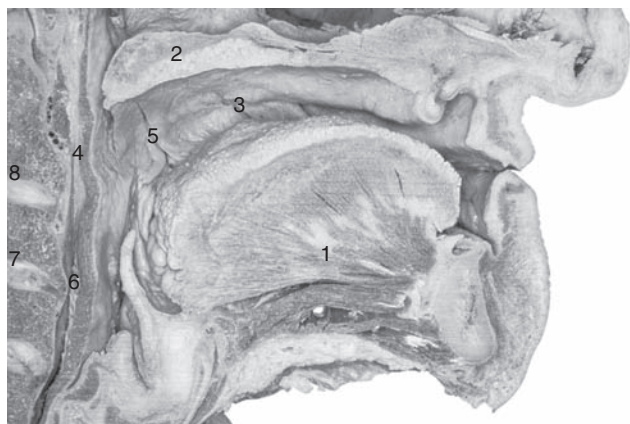
**Figure 8.1** Transoral examination of the oropharynx: (1) anterior tonsillar pillar (palatoglossus), (2) posterior tonsillar pillar (palatopharyngeus), (3) palatine (faucial) tonsil within tonsillar fossa, (4) soft palate, (5) uvula, (6) dorsal surface of tongue, and (7) posterior pharyngeal wall. Reproduced from reference 16, with permission.

excision with postoperative radiation therapy added for close margins, perineural invasion, high tumor grade, or palliation. Primary extranodal non-Hodgkins lymphomas (NHL) of the head and neck comprise 10–20% of all NHL. Most arise from Waldeyer's ring lymphoid tissue. The palatine tonsil is implicated as the site of origin in 12–54% and the base of tongue in 8%<sup>13,14</sup>. Adult tonsillectomies are frequently performed for asymmetric enlargement, and approximately 5% of these specimens harbor NHL<sup>15</sup>. Surgery is limited to establishing diagnosis and tumor grade in these cases. Often biopsies are needed to diagnose those benign lesions of the oropharynx which clinically mimic malignant entities. These include median rhomboid glossitis, pyogenic granulomas, papillomas, and necrotizing sialometaplasias.

## ANATOMIC CONSIDERATION

### Surgical anatomy

The oropharynx is a structurally diverse anatomical construct (Figures 8.1 and 8.2). It is separated from the nasopharynx superiorly at the level of the posterior hard palate, and inferiorly from the hypopharynx and supra-glottic larynx at the pharyngoepiglottic folds in the axial plane of the hyoid bone. Its anterior extent is delineated by the lingual circumvallate papillae, the junction of the hard and soft palate, and the anterior aspect of the anterior tonsillar pillars. The remainder is bounded subcircumferentially by the lateral and posterior pharyngeal walls. The four major structural divisions, or subsites, of the oropharynx are the tonsils, tongue base, soft palate, and posterior pharyngeal wall.



**Figure 8.2** The cadaveric oropharynx in sagittal section: (1) tongue, (2) soft palate, (3) anterior tonsillar pillar (palatoglossus), (4) posterior tonsillar pillar (palatopharyngeus), (5) tonsillar fossa, (6) epiglottis, (7) vallecula, and (8) posterior pharyngeal wall. Reproduced from reference 16, with permission.

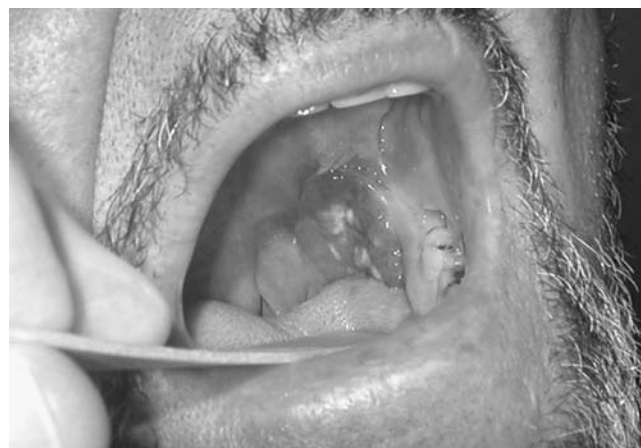### *Tonsil*

The tonsil and tonsillar fossa comprise the bulk of the lateral pharyngeal wall. Part of Waldeyer's ring, the palatine tonsils are reniform lymphoid structures of dubious utility surrounded by a fibrous capsule. They are enveloped by the tonsillar pillars, mucosal prominences that connect the soft palate superiorly to the tongue base at the glossopalatine sulcus. The anterior and posterior tonsillar pillars are considered part of the tonsillar fossa. They are composed of the vagally innervated palatoglossus and palatopharyngeus muscles, respectively.

Tonsillar primaries account for 73% of all oropharyngeal cancers<sup>17</sup> (Figure 8.3). These frequently involve the soft palate superiorly, the base of tongue inferiorly, and the retromolar trigone anteriorly. Lateral extension can violate the superior and middle pharyngeal constrictors, gaining access to the parapharyngeal space. The parapharyngeal space offers little resistance to tumor spread. It is classically described as having the shape of an inverted pyramid, extending from temporal skull base to the greater cornu of the hyoid bone. Tumor invasion of parapharyngeal space structures such as the carotid artery, internal jugular vein and cranial nerves (CN) IX–XII may add significant morbidity to operative resection.

### *Tongue base*

The tongue's base is its posterior one-third, extending from circumvallate papillae to vallecula. Its surface anatomy can be quite variable. Lingual tonsillar tissue lends a markedly irregular superficial appearance which can be mistaken for neoplasm. The tongue's muscular body is composed of the styloglossus, hyoglossus and genioglossus



**Figure 8.3** Squamous cell carcinoma of the left tonsillar fossa. Courtesy of James L Netterville.

muscles innervated by the hypoglossal nerve (CN XII), as well as the palatoglossus muscle (CN X). Tongue base malignancies are notoriously insidious, often clinically silent until locally advanced. Presenting symptoms may include referred otalgia, trismus and dysphagia. Base of tongue primaries frequently involve contiguous sites including the oral tongue, lateral pharyngeal wall, pre-epiglottic space, and supraglottic larynx. Most present with cervical metastases.

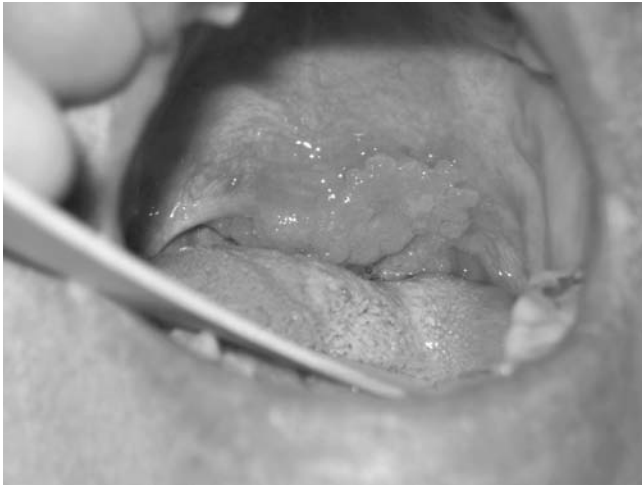
### *Soft palate*

The fibromuscular soft palate is composed of the tensor veli palatini (CN V), levator veli palatini (CN X) and musculus uvulae (CN X). Their highly coordinated contractions elevate and posteriorly displace the palate, partitioning oropharynx from nasopharynx as it contacts the posterior pharyngeal wall. Known as velopharyngeal closure, this action is essential to normal speech production and deglutition. Extensive soft palate resection or tethering may cause velopharyngeal insufficiency, with associated hypernasal speech and nasopharyngeal reflux of swallowed foodstuffs. Primary malignancies of the soft palate are uncommon, but may occur on the inferior (oropharyngeal) surface (Figure 8.4). Extension to the tonsillar fossa and retromolar trigone is likely.

### *Posterior pharyngeal wall*

The posterolateral oropharynx is bounded by the posterior pharyngeal wall. Contraction of the superior and middle pharyngeal constrictors (CN X) displaces the posterior pharyngeal wall intraluminally to modulate speech resonance and assure velopharyngeal closure. Pharyngeal wall primaries are also relatively rare, but are frequently locally advanced on presentation. Posterior extension may access the retropharyngeal space, a potential space of





**Figure 8.4** Squamous cell carcinoma of the soft palate. Courtesy of James L. Netterville.

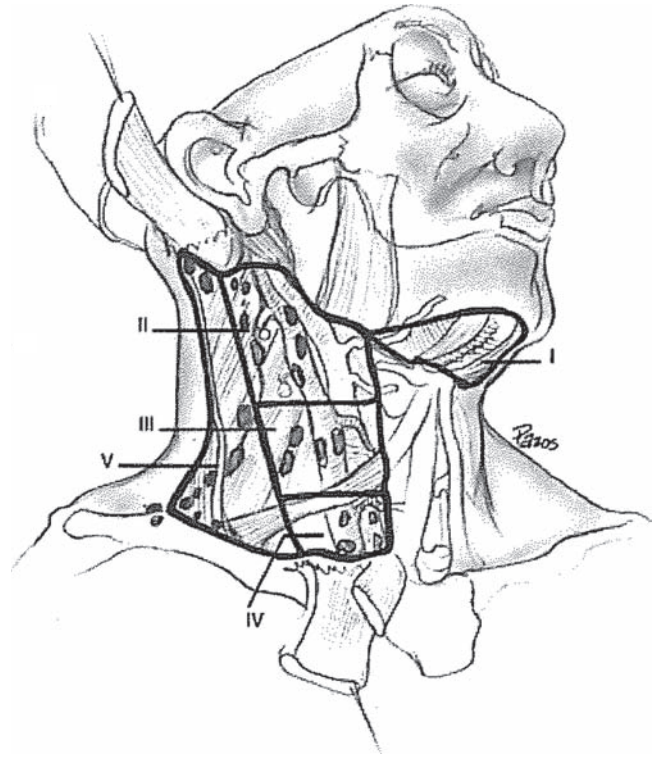
areolar and nodal tissue located between the pharyngo-basilar and prevertebral fasciae. Contiguous with the parapharyngeal space and superior mediastinum, it allows unencumbered regional spread. Tumor invasion into the prevertebral fascia is incompatible with complete oncological resection.

### *Lymphatic drainage*

Oropharyngeal malignancies readily metastasize to the cervical lymphatics. The probability of regional metastasis is based in part on the primary tumor's histopathological classification and size (T stage). Nodal status at presentation is most prognostic of survival.

Familiarity with lymphatic anatomy and with patterns of cervical metastasis in head and neck cancer is crucial when devising an oncological treatment plan for the at-risk neck. For purposes of discussion and treatment the neck is divided into six major regions, or levels, of nodal tissue based on the initial description of Rouvière<sup>18</sup> (Figure 8.5). The retropharyngeal lymph node group of the retropharyngeal space is not included in this classification system. Anatomic boundaries delineate one nodal level from another as follows.

- (1) Level I includes the submental and submandibular triangles. It is bordered by the mandibular ramus, ipsilateral anterior and posterior digastric bellies, and contralateral anterior digastric belly.
- (2) Level II, also known as the jugulodigastric group, surrounds the superior one-third of the internal jugular vein from skull base to hyoid. Like levels III–IV, its lateral limit is the posterior aspect of the sternocleidomastoid (SCM) muscle.



**Figure 8.5** Lymph node regions of the neck. Reproduced from reference 19, with permission.

- (3) Level III is the midjugular chain, spanning from hyoid to the superior aspect of the omohyoid muscle.
- (4) Level IV (inferior jugular) is bordered by the omohyoid superiorly and the clavicle inferiorly. It is the inferior limit of the standard neck dissection.
- (5) Level V comprises the posterior cervical triangle, formed by the posterior aspect of SCM, the anterior extent of trapezius and clavicle.
- (6) Level VI holds the anterior paratracheal nodes, surrounding the midline visceral structures from hyoid to sternal notch.

Dense lymphatic networks are present throughout the pharynx, promoting early metastasis of oropharyngeal cancers. Metastasis typically proceeds in sequential fashion, often from level II inferiorly along the lateral neck. In general, levels II, III and IV are most commonly implicated with disease in the clinically positive (N+) neck<sup>20</sup>. In most cases involvement of levels I and V is associated with disease elsewhere in the ipsilateral neck, although 'skip' metastases do occur<sup>21,22</sup>. Large tumors and those crossing the midline have a higher propensity for bilateral metastasis.

**Table 8.1** Percentage incidence of cervical lymph node metastasis as determined by clinical examination

Location and tumor stage	Node stage		
	N0	N1	N2
<i>Tonsillar fossa</i>			
T1	30	41	30
T2	33	14	54
T3	30	18	52
T4	11	13	77
<i>Base of tongue</i>			
T1	30	15	55
T2	29	15	57
T3	26	23	52
T4	16	9	76
<i>Soft palate</i>			
T1	92	0	8
T2	64	12	25
T3	35	26	39
T4	33	11	56
<i>Oropharyngeal wall</i>			
T1	75	0	25
T2	70	10	20
T3	33	23	45
T4	24	24	52

From reference 23, with permission.

The primary tumor's size and subsite of origin influence the probability of regional metastasis. Table 8.1 shows the expected extent of nodal metastasis by T stage and subsite. Subsite of origin is also predictive of where regional metastatic deposits will present. The tonsil and lateral pharyngeal walls typically spread first to ipsilateral level II, III and the retropharyngeal chain. The tongue base has the highest incidence of bilateral adenopathy, and of metastasis in general (78% N+ at presentation). It drains primarily to ipsilateral levels II and III, as well as contralateral level II. Soft palate and posterior pharyngeal wall primaries are least likely to be associated with cervical metastases, but can implicate the retropharynx and bilateral levels I–III<sup>23</sup>. These considerations help govern modern treatment approaches to the clinically negative (N0) neck, as acceptable regional control is dependent on prophylactic, targeted eradication of micrometastatic deposits.

## Functional considerations

Highly coordinated autonomic control of the dynamic oropharyngeal apparatus enables normal deglutition and speech production. Pathologic disruption of these functions is often a late manifestation of advanced disease. Many patients with oropharyngeal cancer present with normal speech and swallowing. It is vitally important to comprehend the intricacies of pharyngeal function so that therapeutic protocols can minimize treatment-associated morbidity. Dysarthria and dysphagia have dramatic negative effects on quality of life scores<sup>24,25</sup>. Modern reconstructive techniques and organ preservation strategies have proven meaningful advances in this regard.

Compromising the integrity or mobility of oropharyngeal structures can cause communication deficits that can be only partially ameliorated by months of intensive rehabilitation. Voluntary movement of the pharyngeal walls and base of tongue is necessary for sound modulation and articulation. Large soft palatal defects (>2 cm) cause velopharyngeal incompetence and the attendant hypernasal voice if not properly reconstructed<sup>26</sup>. Palatal obturators are poorly tolerated by most patients and offer only a nominal improvement in vocal clarity. Neo-total glossectomy predictably limits speech intelligibility irrespective of rehabilitation.

Swallowing is an astonishing feat of coordination classically divided into four stages. The first is the oral preparatory stage, a fully voluntary process during which the food bolus is lubricated and masticated to an appropriate size. The oral proper stage follows, lasting approximately 1 second. Also voluntary, this second stage is most susceptible to oropharyngeal pathology and surgical manipulation. Adequate sensation is crucial as the bolus is manipulated onto the posterior one-third of the tongue. With a piston-like motion, the tongue base forces the bolus posteriorly and inferiorly toward the hypopharynx. The third, or pharyngeal stage, is fully involuntary. The soft palate elevates to contact the constricted posterior pharyngeal wall, closing the velopharynx and preventing nasopharyngeal reflux of solid or liquid. The suprahyoid muscles contract, elevating the larynx to a position just under the bulky tongue base. Along with simultaneous epiglottic retroversion, this creates a physical barrier to aspiration and generates a negative pressure in the hypopharynx. The rapid, powerful peristaltic contractions of the pharyngeal constrictors begin, generating a swallowing force of nearly 400 mmHg. The cricopharygeus (upper esophageal sphincter) relaxes, and the bolus passes to the cervical esophagus. The esophageal phase lasts 8–20 s and completes the swallowing cycle. Every attempt is made to

facilitate post-treatment swallowing recovery by preserving soft tissue mass, mobility and sensation. Those failing rehabilitation may become dependent on gastrostomy tube feedings, and a minority suffers debilitating recurrent aspiration events.

## INCIDENCE AND PREVALENCE

Fewer than 8000 new cases of oropharyngeal cancer are diagnosed each year in the United States. Incidence ranges from 4.8 to 17.7 cases per 100 000 persons, depending on race and gender classification. The disease shows a 4:1 male-to-female predominance, but it is believed most intergroup variability can be explained by differing alcohol and tobacco consumption habits. Of oropharyngeal carcinomas occur in those over 40 years of age, with most being diagnosed in their sixth decade of life.

## PREDISPOSING RISK FACTORS

Environmental factors have long been recognized to play a profound role in oropharyngeal carcinogenesis. Prolonged exposure to alcohol and tobacco increases risk in a dose-dependent and synergistic fashion. Together they are thought to account for 80–90% of all cancers in the head and neck<sup>27</sup>. Heavy smoking alone (>60 pack year history) confers a relative risk of 23.4<sup>28</sup>. Poor oral hygiene and prior irradiation are thought to play minor but significant etiological roles, as are some occupational exposures. Local customs such as betel nut use have been implicated. Human papillomavirus type 16 (HPV-16) infection is associated with an increased risk for oropharyngeal squamous cell carcinoma<sup>29</sup> although no causal relationship has been identified. HPV-16 seropositivity may confer a favorable prognosis<sup>30</sup>.

## PRESENTATION

Most oropharyngeal cancers are asymptomatic until they have reached a significant size or are associated with a clinically evident cervical metastasis. Early lesions of the soft palate and tonsil can be incidentally discovered on dental or medical examination. Most present with advanced disease (stage III–IV) as diagnosis is usually preceded by many months of vague complaints. Early symptoms can include throat discomfort, foreign body sensation (GLOBUS HYSTERICUS), or referred ipsilateral otalgia. Poorly fitting dentures should raise concern for tonsillar cancer with retromolar trigone involvement. Advanced disease can be associated with dysphagia, trismus

and weight loss. Fifty four percent of patients present with node-positive (N+) disease<sup>31</sup>; distant metastases (M+ disease) to lung, liver and bone are found in 2–5% at presentation.

## SCREENING

Screening strategies for head and neck cancer are in their infancy, and none have been proven to decrease mortality rates for oropharyngeal cancer. Radiological studies have poor sensitivity and specificity when used to detect early malignancies of the upper aerodigestive tract, and cannot be considered cost-effective when applied to large groups of at-risk patients. Comprehensive gene expression analyses are currently being conducted on tumor cell populations in an effort to identify clinically relevant biomarkers. In the future, serum or sputum testing may allow the clinician to identify the presence of disease as well as its biological behavior<sup>32</sup>.

## DIAGNOSTIC STRATEGIES

Those suspected to harbor oropharyngeal cancer should be subjected to an exhaustive work-up. It is imperative to establish a diagnosis with tissue biopsy. Equally important is accurate clinical staging, which is essential to choosing an appropriate treatment regimen.

### History

A thorough history is the cornerstone of diagnosis. A chronologically ordered history of present illness and review of systems may give clues as to the site of origin and extent of locoregional spread. Information gleaned from a past medical history may influence therapeutic decision making. Past and present tobacco and alcohol use should be ascertained and appropriate steps taken to cease substance abuse before treatment commences.

### Physical examination

Most staging information can be gleaned from examining the patient in the clinic setting. All mucosal surfaces of the upper aerodigestive tract should be inspected to define local tumor extent. Flexible fiberoptic nasopharyngoscopy is employed to supplement direct and mirror visualization. The nasopharyngoscope is used to inspect the nasopharynx, superior posterior pharyngeal wall, tongue base, and supraglottic and glottic larynx. Gross disease is precisely measured and involvement of any contiguous structures catalogued. Suspicious lesions are biopsied. Of special

importance is the search for a second primary malignancy. Due to the field cancerization phenomenon, head and neck carcinomas are associated with second primary tumors in 8–20% of cases. All mucosal surfaces are palpated. A cranial nerve examination is performed, and dentition is assessed for possible extraction should radiotherapy be needed. The neck is examined for regional metastases. The size, number, location, and mobility of pathological nodes are recorded, and a fine needle aspiration of the involved node is performed.

### Further investigations

Routine blood work is obtained when the diagnosis is established. Tests should include electrolyte panel, liver function tests, coagulation profile, and complete blood count with differential. Serum prealbumin levels correlate well with nutritional status and are beneficial in some patients.

Clinical staging is rarely complete without radiological imaging of the oropharyngeal soft tissues and neck. Contrasted computed tomography (CT) scans are excellent for assessing nodal status and detecting mandibular cortex involvement. Magnetic resonance imaging (MRI) offers superior soft tissue resolution and is better suited to estimation of local tumor extent, especially in the base of tongue and deep neck spaces. Posteroanterior and lateral chest radiographs are adequate screening tools for pulmonary metastases. Suspicious findings warrant additional imaging.

Fluorodeoxyglucose positron emission tomography (FDG PET) is a nuclear imaging modality that can localize tumors by taking advantage of their increased metabolic activity. The radiopharmaceutical glucose analog FDG cannot be metabolized, and is disproportionately accumulated by tumor cells. Images display the approximate anatomic locations of increased FDG uptake. PET scans may have a role in localizing the unknown primary tumor, and can be used in the search for metastatic disease<sup>33</sup>. PET is now primarily used to detect residual or recurrent disease after definitive treatment.

### Staging endoscopy

When cancer of aerodigestive tract is strongly suspected 'triple' endoscopy is performed in every case to confirm accurate staging. In the operating room under general anesthesia, the surgeon performs direct laryngoscopy, bronchoscopy and esophagoscopy. The primary tumor is extensively inspected, palpated and biopsied. Its pattern of spread is carefully diagrammed. The absence of a second primary tumor is confirmed. When completed, the patient's final clinical stage is assigned.

## STAGING

Staging of oropharyngeal cancers is based on the TNM classification of the American Joint Committee on Cancer (AJCC) shown in Table 8.2. TNM designations are used to classify tumors into one of four stages (Table 8.3). It is a clinical staging system, intended to be applied after physical examination, radiological evaluation and staging endoscopy. The size of the primary tumor (T) is measured superficially in its greatest dimension, and cervical nodes (N) are typically measured by CT or MRI. T and N status have prognostic significance, as survival rates

**Table 8.2** TNM classification: oropharynx

<i>Primary tumor (T)</i>	
TX	Primary tumor cannot be assessed
T0	No evidence of primary tumor
Tis	Carcinoma <i>in situ</i>
T1	Tumor ≤2 cm in greatest dimension
T2	Tumor >2 cm but ≤4 cm in greatest dimension
T3	Tumor >4 cm in greatest dimension
T4a	Tumor invades the larynx, deep/extrinsic muscle of tongue, medial pterygoid, hard palate, or mandible
T4b	Tumor invades lateral pterygoid muscle, pterygoid plates, lateral nasopharynx, or skull base or encases carotid artery
<i>Regional lymph nodes (N)</i>	
NX	Regional lymph nodes cannot be assessed
N0	No regional lymph node metastasis
N1	Metastasis in a single ipsilateral lymph node, ≤3 cm in greatest dimension
N2a	Metastasis in a single ipsilateral lymph node >3 cm but ≤6 cm in greatest dimension
N2b	Metastasis in multiple ipsilateral lymph nodes, none >6 cm in greatest dimension
N2c	Metastasis in bilateral or contralateral lymph nodes, none >6 cm in greatest dimension
N3	Metastasis in a lymph node >6 cm in greatest dimension
<i>Distant metastasis (M)</i>	
MX	Distant metastasis cannot be assessed
M0	No distant metastasis
M1	Distant metastasis

From reference 34, with permission.

**Table 8.3** Stage grouping: oropharynx

	<i>T</i>	<i>N</i>	<i>M</i>
Stage 0	Tis	N0	M0
Stage I	T1	N0	M0
Stage II	T2	N0	M0
Stage III	T3	N0	M0
	T1	N1	M0
	T2	N1	M0
	T3	N1	M0
Stage IVA	T4a	N0	M0
	T4a	N1	M0
	T1	N2	M0
	T2	N2	M0
	T3	N2	M0
	T4a	N2	M0
Stage IVB	T4b	Any N	M0
	Any T	N3	M0
Stage IVC	Any T	Any N	M1

From reference 34, with permission.

decline with more advanced disease. Table 8.4 shows 5-year disease-specific survival for oropharyngeal carcinoma by T and N stage. The most significant declines in disease-specific survival occur with >T2, N+ disease<sup>35</sup>.

A patient's initial clinical stage can be modified when pathological examination reveals neoplastic deposits in areas previously thought to be free of disease. In this case, special notation is used to designate pathological staging. For example, a clinically negative neck (cN0) may undergo selective neck dissection, producing a single, small metastatic node. The neck is then upstaged from cN0 to pN1.

## TREATMENT CONSIDERATIONS

Most oropharyngeal cancers are locally advanced on presentation, and the majority of these are technically

amenable to surgical excision by a variety of means. However, aggressive multisite resections performed with intent to cure in past decades regularly resulted in life-changing functional disability. Treatment in the modern era aims to optimize both oncological and quality of life measures. To this end, organ preservation protocols have proven worthy alternatives to radical surgery for many cancers of the head and neck. Radiation therapy with or without platinum-based chemotherapy has recently become the standard primary treatment for many presentations of oropharyngeal SCC. Surgery is reserved for salvage in these cases.

Tumor-specific factors must be taken into account when planning a treatment regimen. Many authorities recommend that single modality therapy be preferentially used when oncologically appropriate, reserving other modalities for salvage if necessary. Early disease (stage I–II) is adequately treated with single modality therapy, while advanced disease (stage III–IV) usually requires a multimodality approach. Large primaries are associated with decreased disease-free survival<sup>36</sup>, and therefore require a more aggressive approach. Waldeyer's ring neoplasms (tonsil, base of tongue) are prone to unpredictable submucosal spread, sometimes compromising surgical margins. The resultant surgical defect may be larger than anticipated, requiring advanced reconstruction to avoid a poor functional outcome. Others may need adjuvant radiotherapy based on intraoperative or pathological discovery of close margins, extracapsular extension, more than four involved nodes, perineural spread, or lymphovascular invasion<sup>37</sup>. High grade (poorly differentiated) primaries are more prone to perineural spread and lymphovascular invasion, and may also negatively influence outcomes<sup>38,39</sup>.

N+ status is the most reliable indicator of poor outcomes<sup>35</sup>. Approximately 67% of oropharyngeal carcinomas present with pathologically proven cervical metastases (pN+), including 43% of T1 lesions<sup>23</sup>. Bilateral adenopathy is not uncommon. Despite the routine use of CT and/or MRI, 19–30% of clinically negative (cN0) necks harbor occult metastases<sup>35,40,41</sup>. Locoregional failure is responsible for most disease-related deaths. It is therefore imperative that at-risk cervical lymph nodes be addressed

**Table 8.4** Five-year disease-specific survival for oropharynx squamous cell carcinoma patients by T and N stage

	<i>N0</i>	<i>N1</i>	<i>N2</i>	<i>N3</i>
T1	61.3% (84/137)	50.0% (16/32)	41.1% (41/99)	50.0% (7/14)
T2	56.4% (31/55)	60.0% (9/15)	60.0% (27/45)	0.0% (0/6)
T3	16.7% (3/18)	12.5% (1/8)	33.3% (7/21)	0.0% (0/1)
T4	47.8% (11/23)	25.0% (2/8)	23.3% (10/43)	25.0% (3/12)

From reference 35, with permission.

electively in the cN0 neck<sup>42</sup>. In most cases, the neck is treated with the same modality used to address the primary tumor.

## SURGERY FOR CURE: T1N0 DISEASE

Definitive surgery with intent to cure remains a good option in some cases. Careful patient selection must be exercised when choosing surgery as the primary or sole modality. Surgical resection with staging neck dissection is a valid approach to some T1N0 disease, especially with a well-differentiated primary limited to one subsite. These lesions can be quite accessible and well-defined, amenable to excision with adequate margins. Many small surgical defects heal quickly without lasting functional implications. One can expect good local control rates in this ideal scenario, but failing to adequately address the neck may lead to regional failure in up to 40% of patients. When surgery is chosen as the primary curative modality, prophylactic (staging) neck dissection should be performed simultaneously. Selective neck dissection does not add an appreciable amount of treatment-related morbidity and allows for definitive pathological staging of the neck.

No single surgical approach to the oropharyngeal primary is adequate for all oncological scenarios. If possible, T1N0 disease should be resected via a transoral approach to limit healing times and functional morbidity. Mouth gags and nasotracheal intubation may facilitate transoral visualization, but trismus and dentition may render the approach impossible. Despite the complex anatomy and often difficult exposure, faithfulness to sound oncological surgical principles is paramount. Resected specimens should include clear margins of 1–2 cm in all dimensions, confirmed by frozen section. Many sites that lend themselves to transoral resection heal well by secondary intention, such as the tonsillar fossa after wide-field tonsillectomy. Others are suitably reconstructed by one of several methods covered later.

Inaccessible T1 lesions and those exhibiting submucosal spread may require more than one approach to enable critical exposure in all dimensions. Performing a selective neck dissection prior to addressing the primary facilitates transcervical pharyngotomy if needed, and allows for identification and control of major neurovascular structures. Pharyngotomy is a viable approach for T1–T2 tumors of the tongue base and posterolateral pharyngeal wall, provided superior extension is limited. The pharynx is entered at the vallecula on the uninvolved side via a suprahyoid incision, and the tongue base is delivered into the wound for resection. Visualization of the posterolateral wall can be improved by extending the incision down the posterior aspect of the thyroid ala (lateral pharyngotomy).

With rehabilitation, most patients tolerate a regular diet within 7–10 days. In spite of meticulous primary closure, the risk of pharyngocutaneous fistula and neck infection is not negligible. For many head and neck surgeons, these concerns are sufficient justification to opt for radiation therapy or chemoradiation in this population.

For T1N0 disease, selective neck dissection should accompany resection of the oropharyngeal primary. Bilateral dissections are performed for all primaries that cross the midline. Most authorities deem it necessary to remove the contents of levels I–III (supraomohyoid selective neck dissection), but much controversy surrounds the status of the level IV nodal basin<sup>21</sup>. The most oncologically conservative approach is the anterior modified radical neck dissection, which addresses levels I–IV without sacrificing the jugular vein, sternocleidomastoid muscle, or CN XI<sup>22</sup>. Neither operation classically addresses the retropharyngeal nodes, but the retropharyngeal space should be investigated intraoperatively to rule out bulky adenopathy.

Neck dissection and histological examination remain the diagnostic gold standard for ascertaining the presence or absence of metastatic disease. No further treatment of the neck is needed in most cases. Adjuvant radiation therapy is indicated with extracapsular nodal spread, perineural or lymphovascular invasion, or with the discovery of significant, unsuspected metastatic disease (>pN1) in the specimen. The cumulative dose of adjuvant radiotherapy is approximately 5.4–6.2 Gy, less than primary modality radiation for cure. Adjuvant radiotherapy is therefore better tolerated and carries less risk of xerostomia, ageusia and mandibular osteoradionecrosis.

## RADIOTHERAPY FOR CURE: APPROACHING EARLY-STAGE DISEASE IN THE cN0 NECK

Some early oropharyngeal primaries are not favorable surgical candidates due to patient factors or unacceptable risks of lasting dysarthria and dysphagia. Some patients cannot tolerate even minor surgical procedures but may be candidates for curative radiation therapy. Radiotherapy may also treat subclinical microscopic foci of neoplastic cells which may not be included in a surgical specimen. This includes undetected submucosal extension and carcinoma *in situ* located elsewhere in the cancerized field.

Radiation therapy has a proven record of success with early-stage cancer of the oropharynx. When all stages are considered, disease control rates are similar with either surgery (with or without adjuvant radiation) or radiation alone, but functional consequences often favor radiation<sup>43</sup>. It is particularly effective in treating small (T1–T2) primary tumors and necks without bulky adenopathy.

In a review of 175 patients with stage I–II oropharyngeal cancer, treated with radiation alone, Selek *et al.* achieved a 5-year disease-specific survival of 85%. Locoregional control at 5 years was 88% for T1 lesions and 72% for T2<sup>44</sup>. Although the use of brachytherapy implants has been reported with promising results<sup>45</sup>, external beam delivery is the mainstay of head and neck radiotherapy. Hyperfractionated schedules can achieve local control rates approaching 100% for T1 disease<sup>46,47</sup> with less morbidity. Concurrent irradiation of the cN0 neck yields a 5-year regional control rate of 86–93%<sup>44,47</sup>. As with local incomplete responses, surgical salvage should be performed for residual malignancy in the neck 4–6 weeks post-treatment. Radiation therapy alone has been shown to achieve 5-year disease-specific survival rates >90% with stage I–II tonsillar SCC, and is considered essentially curative in these patients<sup>48,49</sup>.

Radiation therapy is not without its own morbidity when used as a primary modality. Curative radiotherapy requires high cumulative doses (typically 6.4–7.2 Gy) to achieve acceptable locoregional control. Treatment-related deaths occur in 1%, mostly due to severe dysphagia and carotid artery rupture. Lesser complications occur in approximately 20%, including severe xerostomia, osteoradionecrosis of the mandible, dental decay, esophageal stricture, and temporomandibular joint fixation with trismus. Loss of taste sensation (dysgeusia) is a universal complaint, but is rarely permanent. Recent advances in external beam radiation delivery, such as intensity modulated radiation therapy (IMRT), have proven useful in avoiding common complications. IMRT permits high dose delivery to target tissues while limiting the exposure of critical susceptible structures such as the parotid, larynx and spinal cord. Its use offers similar oncological results with improved long-term quality of life when compared to conventional external beam radiation therapy (EBRT)<sup>50,51</sup>.

### CHEMORADIOTHERAPY FOR CURE: APPROACHING T1/T2 N1 DISEASE

Radiation therapy alone is an inadequate treatment for advanced oropharyngeal SCC. Of all treatment modalities for the N+ neck, radiation alone yields the worst outcomes<sup>35</sup>. When EBRT is used as a primary therapy for stage III–IV disease, 5-year locoregional control rates of >75% are achieved only with frequent surgical salvage. Bulky adenopathy often harbors an anaerobic necrotic core that is especially resistant to ionizing radiation. In the 1950s, the ‘radiosensitizing’ properties of certain compounds were found able to combat this phenomenon. Radiosensitizers biochemically boost local oxygen concentration, enabling higher concentration of tumoricidal oxygen free radicals

and increasing the efficacy of each treatment. 5-fluorouracil (5-FU) and the platinum-based chemotherapeutic agents are known radiosensitizers, making them ideal adjuncts to radiotherapy in the treatment of advanced oropharyngeal cancer. The synergy of these two modalities offers great promise as an organ preservation approach.

Debate continues as to which chemotherapeutic combination, administration schedule and radiation fractionation schema offers the lowest risk profile with the greatest oncological benefit. The administration of platinum-based agents with EBRT is the only combination proven to improve disease-free survival over radiotherapy alone. Concomitant chemoradiation protocols have consistently proved superior to other chemoradiation protocols in achieving locoregional control in advanced (stage III/IV) oropharyngeal cancer<sup>52–58</sup>. Neoadjuvant and alternating regimens are thought to provide ample time for neoplastic repopulation between treatments, limiting efficacy<sup>59</sup>. Concomitant chemoradiation boasts excellent local control, and has been pathologically proven to decrease the incidence of nodal positivity in the N+ neck<sup>55</sup>. It can be considered a curative approach to T1–T2, N1 oropharyngeal carcinoma, but has been used in the treatment of all stages with some success. Of those N1 necks clinically deemed to be complete responders, 92% will be pathologically free of disease after treatment<sup>60</sup>. Surgical salvage is reserved for incomplete responders. It should be noted that no randomized study has ever directly compared chemoradiation with primary modality surgery for advanced oropharyngeal carcinoma. However, the current chemoradiation survival data compare favorably with historically reported surgical controls<sup>61</sup>.

The synergy of chemotherapy and radiation therapy increases rates of severe acute toxicity. Deaths from neutropenic sepsis occur in approximately 2%. With single daily fractionated radiation plus concurrent chemotherapy, up to 89% will experience major treatment-related toxicity<sup>58</sup>. High grade mucositis afflicts approximately 75% with combined modality treatment, often necessitating gastrostomy tube placement<sup>52,54</sup>. Long-term dysphagia can result from xerostomia, radiation-induced esophageal stricture, or chemotherapy-induced hypopharyngeal stenosis. Recent prospective studies have experimented with different radiotherapy fractionation schema in attempts to limit treatment-related morbidity and mortality.

### MULTIMODALITY THERAPY FOLLOWING INDUCTION CHEMOTHERAPY FOR ADVANCED DISEASE: THE N2/N3 NECK

Stage III–IV SCC is characterized by large primary tumor volumes and bulky cervical adenopathy. Treatment

outcomes have historically been poor. Little consensus exists concerning the appropriate treatment strategy, but aggressive multimodality approaches seem to offer the best oncological results. Concomitant chemoradiation induces a pathologically proven complete response in only 65% of N2–N3 necks, and clinical predictions of response are rarely accurate<sup>60</sup>. Planned modified radical neck dissection has been shown to improve locoregional control when performed within 6 weeks after chemoradiation<sup>62</sup>, though this is not thought necessary for all such patients.

The Department of Veterans Affairs Laryngeal Study Group concluded in 1991 that head and neck cancer patients who respond to induction chemotherapy have greater success with subsequent organ preservation approaches<sup>63</sup>. Recently, randomized studies have demonstrated a slight survival benefit when neoadjuvant chemotherapy precedes definitive measures for oropharyngeal carcinoma<sup>64</sup>. In an attempt to avoid radical surgery, some centers now advocate a 6–8 week course of neoadjuvant chemotherapy as first-line treatment for stage III–IV disease. Significant response to induction therapy is commonplace – 90% are clinically downstaged at its completion<sup>3</sup>. Those experiencing 50–75% reduction in tumor volumes are thought to be candidates for definitive chemoradiation. Insufficient tumor response necessitates composite resection, followed by adjuvant chemoradiation 6 weeks postoperatively. Locoregional control rates of 70–82% have been achieved with variations of this protocol. Up to 50–65% achieve complete clinical response to induction chemotherapy alone<sup>3,65</sup>, and 89% are complete responders after definitive chemoradiation<sup>66</sup>.

## SURGICAL SALVAGE

Salvage surgery is performed for residual or recurrent locoregional disease. The detection and diagnosis of therapeutic failure is often quite difficult, as widespread tissue fibrosis from prior therapy decreases the accuracy of physical and radiological examination. Treatment dilemmas are especially common following definitive chemoradiation for bulky N2–N3 disease. Of these necks 77% will be pathologically free of disease, but the remainder harbor residual malignancy<sup>66</sup>. Most bulky adenopathy will exhibit a significant clinical response, often shrinking to a dense, fibrotic mass. Not all such patients require neck dissection, and fine needle aspiration lacks acceptable sensitivity in this scenario. FDG PET is a useful management tool in these postchemoradiation patients. If used within 2 months after definitive treatment, FDG PET is plagued by an inordinately high false negative rate. Current guide-

lines recommend PET scans be obtained 12 weeks after completion of chemoradiation, at which time the negative predictive value is >95%<sup>67</sup>. PET-negative necks without residual lymphadenopathy can be safely observed. Approximately 50% will have a residual PET-positive neck mass, and should undergo selective neck dissection of levels I–IV. Most authorities will observe the residual PET-negative neck mass. In this case, neck dissection is performed for nodal enlargement, conversion to PET-positive status, or positive fine needle aspiration<sup>31</sup>.

In most cases of treatment failure, response is less equivocal. For advanced disease with an incomplete clinical response to definitive chemoradiation (<75% regression), aggressive composite resection should be performed promptly. Stage III–IV disease is rarely amenable to resection transorally or via a transcervical pharyngotomy. For these larger tumors not accessible by more conservative means a mandibular osteotomy and swing enables the widest available exposure. It can be used to access all oropharyngeal subsites as well as the parapharyngeal and lateral retropharyngeal spaces. Standard modified radical neck dissections are performed via subplatysmal apron flap. The lower lip is split in the midline and retracted laterally following incisions through the gingivobuccal sulci. A lateral mandibular incisor is then extracted anterior to the mental foramen, allowing an inferior alveolar nerve-sparing parasymphiseal mandibulotomy. The mandibular segments are swung laterally and the floor of mouth is incised through its full thickness, exposing the tumor. Free tissue transfer is often needed for reconstruction, and the mandibulotomy is repaired with compression plates.

Advanced cancers of the oropharynx erode mandibular bone. If bony invasion is suspected, the oncological status of the mandible itself must be addressed. A partial-thickness marginal mandibulectomy can be performed for cortical erosion without marrow space involvement. In some cases, a full-thickness (segmental) mandibulectomy is necessary. This morbid defect usually necessitates use of a large titanium mandibular reconstruction bar with osseocutaneous free flap. It is necessary to confirm tumor clearance by frozen section biopsy of the periosteum and/or inferior alveolar nerve.

Disease recurrence afflicts up to 42% of complete responders, and is not well correlated with initial T or N stage<sup>35</sup>. Recurrent SCC is rarely amenable to cure. Prognosis is predictably poor, with a 5-year actuarial survival rate of 32%<sup>68</sup>. Most recur within 2 years of definitive treatment and at advanced stages. Locoregional recurrences can be treated with chemotherapy to maximal response, followed by radical resection. Patients with distant metastases are offered low-dose chemotherapy for palliation.



## RECONSTRUCTION

Large-scale oropharyngeal resections require primary reconstruction if postoperative speech and swallowing function is to be serviceable. The ideal reconstruction provides tissue coverage with excellent reliability, good tissue match, sensory restoration, low donor site morbidity, and a tension-free fit in three dimensions<sup>69</sup>. Modern reconstruction techniques are superb for reconstituting relatively static, supportive structures. Despite considerable advances in the past 30 years, the form and function of the soft palate and tongue base remain difficult to reconstitute after a critical mass is resected. Most authorities agree that resecting >50% of the mobile soft palate will result in poor functional outcomes, although combining free and local flaps yields promising results in some cases<sup>26,70</sup>. Consensus guidelines allow for primary closure or secondary intention healing to follow resection of up to one-third of the base of tongue. Swallowing results are favorable in these cases, as sufficient sensate bulk remains and no significant tethering occurs. With base of tongue resections approaching 50%, the driving force of the swallowing mechanism is lost. Its function cannot be surgically replicated, and aspiration frequently results. Functional disability can be mitigated by simultaneous base of tongue reconstruction, which with rehabilitation can enable a return to oral alimentation. Supple, appropriately sized soft tissue bulk is inset into the wound, replacing lost mass with viable, autologous tissue. With sufficient reconstruction the laryngeal introitus is protected from aspiration. Regional flaps are adequate for 50% defects, but free tissue transfer is the current gold standard for these and all larger defects involving contiguous subsites.

The optimal choice of reconstruction for a given defect depends on extent, location and experience of the surgeon, as well as biological and social factors unique to the patient. The simplest appropriate reconstruction often yields the best functional results. The reconstructive ladder (Table 8.5) illustrates this concept, although primacy is given to functional outcome in the decision-making process.

Healing by secondary intention is often not a viable option outside of the tonsillar fossa. Inevitable wound contracture can tether mobile structures and lead to sub-optimal outcomes. Select small defects allow for primary closure, but reconstruction is often required for excisions more extensive than one-third of tongue base, more than one-quarter soft palate, or a wide-field tonsillectomy. Split-thickness skin grafts are suited to small, accessible defects. Local flaps translocate vascular mucosa from adjacent sites to preserve native tissue mobility. The palatal island flap popularized by Millard and Seider<sup>71</sup> is based on the greater palatine artery. A local mucoperiosteal flap

**Table 8.5** Reconstructive options for the oropharynx: a practical approach

	<i>Reconstructive option</i>
Small defects	Healing by secondary intention
	Primary closure
	Split-thickness skin grafts
	Buccal mucosal flap
	Submental flaps
Moderate defects	Palatal island flaps
	Healing by secondary intention
	Primary closure
	Split-thickness skin grafts
	Local flaps
	Pectoralis major myocutaneous flap
	Lower trapezius flap
Large defects	Pedicled latissimus dorsi flap
	Large pedicled flaps
	Microvascular free flaps
	radial forearm – sensate
	lateral arm – sensate
	rectus abdominus
	jejunum
	gastro-omental
Large composite bone defects	latissimus dorsi
	Scapula osseocutaneous free flap
	Fibula (sensate) free flap

From reference 69, with permission

harvested from the hard palate, it is well suited for single-stage reconstruction of the lateral pharyngeal wall, retro-molar trigone and some superficial soft palate defects. Oral diet can resume within days, and re-epithelialization of the donor site is complete by 4-6 weeks<sup>72</sup>. Through-and-through palatal defects carry a 20% oronasal fistula rate, and should be reconstructed by other means. The superiorly based pharyngeal flap harvested from the posterior pharyngeal wall can be secured to the palatal remnant, restoring velopharyngeal competence and obviating the need for a palatal prosthesis. Other local options such as the buccal mucosal flap have some utility in closing small, anterior defects.

More advanced reconstructive techniques must be employed following moderate to extensive resections.

Regional pedicled flaps remain good reconstructive options for larger defects. The pectoralis major myocutaneous flap first described by Ariyan in 1979<sup>73</sup> is widely considered the workhorse of head and neck reconstruction. Based on the pectoral branch of the thoracoacromial artery, it is large, reliable and remarkably versatile. Today it remains a common method of reconstructing the tongue base and pharyngeal walls. Other regional flaps of note for pharyngeal reconstruction include the lower trapezius, latissimus dorsi and deltopectoral myocutaneous flaps<sup>74–76</sup>. These flaps can readily restore oropharyngeal integrity to one or more contiguous subsites, and do not require microvascular expertise. Disadvantages include lack of sensation and limited reach. Excessive bulk and marginal necrosis can contribute to suboptimal functional outcomes<sup>77</sup>.

Microvascular free tissue transfer is the current state of the art for reconstructing the oropharyngeal defect. The free flap is harvested from distant sites with its vascular pedicle, which is surgically anastomosed to native arterial and venous channels with 9-0 nylon suture. Some flaps include an osseous component for use in mandibular reconstruction. When the sensory nerve is preserved, it can be anastomosed to branches of CN IX to re-establish sensation in 75%. Extraordinarily versatile, flaps can be designed to reconstruct complex three-dimensional cavities without spatial limitation or tension. Flap viability rates of >97% are reported in most series<sup>78</sup>. The radial forearm free tissue transfer is the most commonly used flap in oropharyngeal reconstruction. It is based on the radial artery and its *venae comitantes*, and sensation can be restored via the lateral antebrachial cutaneous nerve. It offers pliable skin with properties similar to native epithelium. This flap is ideal for repair of extensive soft palate, composite tonsillar and tongue base defects. Sensate free tissue transfer probably offers improved swallowing results versus regional pedicled flaps<sup>79</sup>. Additional free tissue options for the oropharynx include the lateral forearm, fibular and rectus abdominus free flaps.

## PALLIATIVE CARE

Palliative measures for incurable advanced oropharyngeal cancer are largely limited to low-dose chemotherapy and hospice care. Palliative trials conducted with curative chemotherapeutic agents (cisplatin plus 5-FU/paclitaxel) have suggested improved quality of life measures, but at the expense of significant treatment-related mortality<sup>80,81</sup>. Surgical debulking procedures are infrequently performed for large cervical metastatic deposits. Tracheotomy, gastrostomy tube placement and hospice care remain the

mainstays of treatment for incurable metastatic oropharyngeal cancer.

## OUTCOMES

### Oncological outcomes

Chemoradiation regimens increase locoregional control and disease-specific survival for advanced stage III–IV rates. Approaches vary considerably among major centers given the widely disparate treatment regimens employed in available studies. No randomized study has ever proven a treatment benefit for concomitant chemoradiation applied to stage I–II oropharyngeal carcinoma. Some have extrapolated the existing data to recommend concurrent chemoradiation as a definitive approach for early disease<sup>57</sup>. One must be willing to accept higher treatment-related acute morbidity and mortality with this approach compared with surgery and radiation alone or in combination.

### Functional outcomes

Organ preservation approaches seem to allow better speech and swallowing outcomes for locally advanced primaries when compared with surgery plus radiotherapy. Chemoradiation preserves sensation without significantly disrupting structural integrity in most cases. It is associated with better self-perceived swallowing and less risk of aspiration<sup>82,83</sup>. Among those receiving definitive resection, the percentage and total volume of tongue base resection exert the greatest negative correlation with swallowing<sup>84</sup>. Radial forearm free flap reconstruction offers equally promising swallowing preservation, allowing the resumption of normal diet in 94% with 93% speech intelligibility<sup>26</sup>. Radiotherapy is associated with slightly worse subjective swallowing function<sup>84,85</sup>.

Speech and swallowing function factor strongly into most quality of life instruments. Discernible speech and the ability to easily consume a normal diet are essential ingredients of a social lifestyle. As such, radical therapy impacts quality of life measures more for advanced-stage oropharyngeal cancer than for other sites in the head and neck. As modern surgical resection and reconstructive efforts have become more focused on preserving function, chemoradiation protocols are increasingly aggressive in pursuit of cures – often pushing the limits of patient tolerance. Six months after completing therapy, patients in both cohorts demonstrate a return to pretreatment quality of life scores<sup>86–88</sup>. Maximizing long-term quality of life should factor strongly into the decision-making process when selecting the appropriate oncological treatment strategy.

## REFERENCES

- Martin HE. The history of lingual cancer. *Am J Surg* 1940; 98: 703–16.
- McGurk M, Goodger NM. Head and neck cancer and its treatment: historical review. *Br J Oral Maxillofac* 2000; 38: 209–20.
- Al-Sarraf M. Treatment of locally advanced head and neck cancer: historical and critical review. *Cancer Control* 2002; 9: 387–99.
- Jemal A, Murray T, Ward E et al. Cancer statistics, 2005. *CA Cancer J Clin* 2005; 55: 10–30.
- Slaughter DP, Southwick HW, Smejkal W. Field cancerization in oral stratified squamous epithelium: clinical implications of multicentric origin. *Cancer* 1953; 6: 963.
- Braakhuis BJ, Tabor MP, Kummer JA et al. A genetic explanation of Slaughter's concept of field cancerization. *Cancer Res* 2003; 63: 1727–30.
- Tabor MP, Brakenhoff RH, Ruijter-Schippers HJ et al. Multiple head and neck tumors frequently originate from a single preneoplastic lesion. *Am J Pathol* 2002; 161: 1051–60.
- Braakhuis BJ, Tabor MP, Leemans CR et al. Second primary tumors and field cancerization in oral and oropharyngeal cancer: molecular techniques provide new insights and definitions. *Head Neck* 2002; 24: 198–206.
- Bouquot JE, Weiland LH, Kurland LT. Leukoplakia and carcinoma in situ synchronously associated with oral/oropharyngeal carcinoma in Rochester, Minn., 1935–1984. *Oral Surg Oral Med Oral Pathol* 1988; 65: 199–207.
- Reichart PA, Philipsen HP. Oral erythroplakia—a review. *Oral Oncol* 2005; 41: 551–61.
- Zbaren P, Nuyens M, Stauffer E. Basaloid squamous cell carcinoma of the head and neck. *Curr Opin Otolaryngol Head Neck Surg* 2004; 12: 116–21.
- Dubey P, Ha CS, Ang KK et al. Nonnasopharyngeal lymphoepithelioma of the head and neck. *Cancer* 1998; 82: 1556–62.
- Hanna E, Wanamaker J, Adelstein D et al. Extranodal lymphomas of the head and neck. A 20-year experience. *Arch Otolaryngol Head Neck Surg* 1997; 123: 1318–23.
- Economopoulos T, Asprou N, Stathakis N et al. Primary extranodal non-Hodgkin's lymphoma of the head and neck. *Oncology* 1992; 49: 484–8.
- Syms MJ, Birkmire-Peters DP, Holtel MR. Incidence of carcinoma in incidental tonsil asymmetry. *Laryngoscope* 2000; 110: 1807–10.
- Berkowitz BKB, Moxham BJ. *Head and Neck Anatomy: a Clinical Reference*. London: Taylor & Francis, 2002: 401.
- Canto MT, Devesa SS. Oral cavity and pharynx cancer incidence rates in the United States: 1975–1998. *Oral Oncol* 2002; 38: 610–7.
- Rouvière H. *Anatomie des Lymphatiques de l'Homme*. Masson et Cie, Paris, France 1932.
- Calhoun KH, Healy GB, Johnson JT et al. *Head and Neck Surgery – Otolaryngology*, 3rd edn. Philadelphia: Lippincott, Williams & Wilkins, 2002; 2: 1348.
- Shah JP. Patterns of cervical lymph node metastasis from squamous carcinomas of the upper aerodigestive tract. *Am J Surg* 1990; 160: 405–9.
- Vartanian JG, Pontes E, Agra IM et al. Distribution of metastatic lymph nodes in oropharyngeal carcinoma and its implications for the elective treatment of the neck. *Arch Otolaryngol Head Neck Surg* 2003; 129: 729–32.
- Candela FC, Kothari K, Shah JP. Patterns of cervical node metastases from squamous cell carcinoma of the oropharynx and hypopharynx. *Head Neck* 1990; 12: 197–203.
- Lindberg R. Distribution of cervical lymph node metastases from squamous cell carcinoma of the upper respiratory and digestive tracts. *Cancer* 1972; 29: 1446.
- Krischke S, Weigelt S, Hoppe U et al. Quality of life in dysphonic patients. *J Voice* 2005; 19: 132–7.
- Nguyen NP, Frank C, Moltz CC et al. Impact of dysphagia on quality of life after treatment of head and neck cancer. *Int J Radiat Oncol Biol Phys* 2005; 61: 772–8.
- Seikaly H, Reiger J, Wolfaardt J et al. Functional outcomes after primary oropharyngeal cancer resection and reconstruction with the radial forearm free flap. *Laryngoscope* 2003; 113: 897–904.
- Rothman KJ. Epidemiology of head and neck cancer. *Laryngoscope* 1978; 88: 435–8.
- Maier H, Dietz A, Gewelke U et al. Tobacco and alcohol and the risk of head and neck cancer. *Clin Invest* 1992; 70: 320–7.
- Dahlstrom AR, Adler-Storthz K, Etzel CJ et al. Human papillomavirus type 16 infection and squamous cell carcinoma of the head and neck in never-smokers: a matched pair analysis. *Clin Cancer Res* 2003; 9: 2620–6.
- Ritchie JM, Smith EM, Summersgill KF et al. Human papillomavirus infection as a prognostic factor in carcinomas of the oral cavity and oral pharynx. *Int J Cancer* 2003; 104: 336–44.
- Yao M, Smith RB, Graham MM et al. The role of FDG PET in management of neck metastasis from head-and-neck cancer after definitive radiation treatment. *Int J Radiat Oncol Phys* 2005; 63: 991–9.
- Chung CH, Levy S, Yarbrough DG. Clinical applications of genomics in head and neck cancer. *Head Neck* 2006; 28: 360–8.
- Weber AL, Romo L, Hashmi S. Malignant tumors of the oral cavity and oropharynx: clinical, pathologic, and radiologic evaluation. *Neuroimaging Clin North Am* 2003; 13: 443–64.
- Greene FL, Page OL, Fleming ID et al. *American Joint Committee on Cancer (AJCC). AJCC Cancer Staging Manual*, 6th edn. New York: Springer-Verlag, 2002; 35–37.
- Layland MK, Sessions DG, Lenox J. The influence of lymph node metastasis in the treatment of squamous cell carcinoma of the oral cavity, oropharynx, larynx, and hypopharynx: N0 versus N+. *Laryngoscope* 2005; 115: 629–39.
- Sundaram K, Schwartz J, Har-El G et al. Carcinoma of the oropharynx: factors affecting outcome. *Laryngoscope* 2005; 115: 1536–42.
- Olsen KD, Caruso M, Foote RL et al. Primary head and neck cancer. Histopathologic predictors of recurrence after neck dissection in patients with lymph node involvement. *Arch Otolaryngol Head Neck Surg* 1994; 120: 1370–4.
- Close LG, Brown PM, Vuitch MF et al. Microvascular invasion and survival in cancer of the oral cavity and oropharynx. *Arch Otolaryngol Head Neck Surg* 1989; 115: 1304–9.
- Conte CC, Ergin MT, Ricci A Jr et al. Clinical and pathology prognostic variables in oropharyngeal squamous cell carcinoma. *Am J Surg* 1989; 159: 619–20.
- Jose J, Coatesworth AP, Johnston C et al. Cervical node metastases in oropharyngeal squamous cell carcinoma: prospective analysis of prevalence and distribution. *J Laryngol Otol* 2002; 116: 925–8.

41. O'Brien CJ, Traynor SJ, McNeil E et al. The use of clinical criteria alone in the management of the clinically negative neck among patients with squamous cell carcinoma of the oral cavity and oropharynx. *Arch Otolaryngol Head Neck Surg* 2000; 126: 360–5.
42. Duvvari U, Simental AA Jr, D'Angelo G et al. Elective neck dissection and survival in patients with squamous cell carcinoma of the oral cavity and oropharynx. *Laryngoscope* 2004; 114: 2228–34.
43. Parsons JT, Mendenhall WM, Stringer SP et al. Squamous cell carcinoma of the oropharynx: surgery, radiation therapy, or both. *Cancer* 2002; 94: 2967–80.
44. Selek U, Garden AS, Morrison WH et al. Radiation therapy for early-stage carcinoma of the oropharynx. *Int J Radiat Oncol Phys* 2004; 59: 743–51.
45. Rudoltz MS, Perkins RS, Luthmann RW et al. High-dose-rate brachytherapy for primary carcinomas of the oral cavity and oropharynx. *Laryngoscope* 1999; 109: 1967–73.
46. Hicks WL Jr, Kuriakose MA, Loree TR et al. Surgery versus radiation therapy as single modality treatment of tonsillar fossa carcinoma: the Roswell Park Cancer Institute experience (1971–1991). *Laryngoscope* 1998; 108: 1014–9.
47. Fein DA, Lee WR, Amos WR et al. Oropharyngeal carcinoma treated with radiotherapy: a 30-year experience. *Int J Radiat Oncol Phys* 1996; 34: 289–96.
48. Perez CA, Patel MM, Chao KS et al. Carcinoma of the tonsillar fossa: prognostic factors and long-term therapy outcome. *Int J Radiat Oncol Biol Phys* 1998; 42: 1077–84.
49. Lee WR, Mendenhall WM, Parsons JT et al. Carcinoma of the tonsillar region: a multivariate analysis of 243 patients treated with radical radiotherapy. *Head Neck* 1993; 15: 283–8.
50. Yao M, Dornfeld KJ, Buatti JM et al. Intensity-modulated radiation treatment for head-and-neck squamous cell carcinoma—the University of Iowa experience. *Int J Radiat Oncol Phys* 2005; 63: 410–21.
51. Jabbari S, Kim HM, Feng M et al. Matched case-control study of quality of life and xerostomia after intensity-modulated radiotherapy or standard radiotherapy for head-and-neck cancer: initial report. *Int J Radiat Oncol Biol Phys* 2005; 63: 725–31.
52. Calais G, Alfonsi M, Bardet E et al. Randomized trial of radiation therapy versus concomitant chemotherapy and radiation therapy for advanced-stage oropharynx carcinoma. *J Natl Cancer Inst* 1999; 91: 2081–6.
53. Olmi P, Crispino S, Fallai C et al. Locoregionally advanced carcinoma of the oropharynx: conventional radiotherapy versus accelerated hyperfractionated radiotherapy versus concomitant radiotherapy and chemotherapy—a multicenter trial. *Int J Radiat Oncol Biol Phys* 2003; 55: 78–92.
54. Brizel DM, Albers ME, Fisher SR et al. Hyperfractionated irradiation with or without concurrent chemotherapy for locally advanced head and neck cancer. *N Engl J Med* 1998; 338: 1798–804.
55. Moore MG, Bhattacharyya N. Effectiveness of chemotherapy and radiotherapy in sterilizing cervical nodal disease in squamous cell carcinoma of the head and neck. *Laryngoscope* 2005; 115: 570–3.
56. Denis F, Garaud P, Bardet E et al. Final results of the 94-01 French Head and Neck Oncology and Radiotherapy Group randomized trial comparing radiotherapy alone with concomitant radiochemotherapy in advanced-stage oropharynx carcinoma. *J Clin Oncol* 2004; 22: 69–76.
57. Browman GP, Hodson DI, Mackenzie RJ et al. Choosing a concomitant chemotherapy and radiotherapy regimen for squamous cell head and neck cancer: a systematic review of the published literature with subgroup analysis. *Head Neck* 2001; 23: 579–89.
58. Adelstein DJ, Adams GL, Wagner H et al. An intergroup phase III comparison of standard radiation therapy and two schedules of concurrent chemoradiotherapy in patients with unresectable squamous cell head and neck cancer. *J Clin Oncol* 2003; 21: 92–8.
59. Merlano M, Vitale V, Rosso R et al. Treatment of advanced squamous-cell carcinoma of the head and neck with alternating chemotherapy and radiotherapy. *N Engl J Med* 1992; 327: 1115–21.
60. Brizel DM, Prosnitz RG, Hunter S et al. Necessity for adjuvant neck dissection in setting of concurrent chemoradiation for advanced head-and-neck cancer. *Int J Radiat Oncol Phys* 2004; 60: 1338.
61. Moyer JS, Wolf GT, Bradford CR. Current thoughts on the role of chemotherapy and radiation in advanced head and neck cancer. *Curr Opin Otolaryngol Head Neck Surg* 2004; 12: 82–7.
62. Frank DK, Hu KS, Culliney BE et al. Planned neck dissection after concomitant radiochemotherapy for advanced head and neck cancer. *Laryngoscope* 2005; 115: 1015–20.
63. The Department of Veterans Affairs Laryngeal Cancer Study Group. Induction chemotherapy plus radiation compared with surgery plus radiation in patients with advanced laryngeal cancer. *N Engl J Med* 1991; 324: 1685–90.
64. Domette C, Hill C, Lefebvre JL et al. Randomized trial of neo-adjuvant chemotherapy in oropharyngeal carcinoma. French Groupe D'Etude des Tumeurs de la tete et du cou (GETTEC). *Br J Cancer* 2000; 83: 1594–8.
65. Mantz CA, Vokes EE, Stenson K et al. Induction chemotherapy followed by concomitant chemoradiotherapy in the treatment of locoregionally advanced oropharyngeal cancer. *Cancer J* 2001; 7: 140–8.
66. Machtay M, Rosenthal DI, Hershock D et al. Organ preservation therapy using induction plus concurrent chemoradiation for advanced respectable oropharyngeal carcinoma: a University of Pennsylvania Phase II trial. *J Clin Oncol* 2002; 20: 3964–71.
67. Yao M, Smith RB, Graham MM et al. The role of FDG-PET in management of neck metastasis from head-and-neck cancer after definitive radiation treatment. *Int J Radiat Oncol Phys* 2005; 63: 991–9.
68. Goncalves AI, Lopes CA, Samsonovski UF et al. Prognostic factors in salvage surgery for recurrent oral and oropharyngeal cancer. *Head Neck* 2006; 28: 107–13.
69. Sabri A, Burkey BB. Oropharyngeal reconstruction: current state of the art. *Curr Opin Otolaryngol Head Neck Surg* 2003; 11: 251–4.
70. Brown JS, Rogers SN, Lowe D. A comparison of tongue and soft palate squamous cell carcinoma treated by primary surgery in terms of survival and quality of life outcomes. *Int J Oral Maxillofac Surg* 2006; 35: 208–14.
71. Millard DR, Seider HA. The versatile palatal island flap: its use in soft palate reconstruction and nasopharyngeal and choanal atresia. *Br J Plast Surg* 1977; 30: 300–5.
72. Genden EM, Lee BB, Urken ML. The palatal island flap for reconstruction of palatal and retromolar trigone defects revisited. *Arch Otolaryngol Head Neck Surg* 2001; 127: 837–41.
73. Ariyan S. The pectoralis major myocutaneous flap: a versatile flap for reconstruction in the head and neck. *Plast Reconstr Surg* 1979; 63: 73–81.
74. Netteville JL, Wood DE. The lower trapezius flap. Vascular anatomy and surgical technique. *Arch Otolaryngol Head Neck Surg* 1991; 117: 73–6.
75. Watson JS, Robertson GA, Lendrum J et al. Pharyngeal reconstruction using the latissimus dorsi myocutaneous flap. *Br J Plast Surg* 1982; 35: 401–7.

76. Mendelson BC, Woods JE, Masson JK. Experience with the deltopectoral flap. *Plast Reconstr Surg* 1977; 59: 360–5.
77. Martini DV, Har-El G, Lucente FE et al. Swallowing and pharyngeal function in postoperative pharyngeal cancer patients. *Ear Nose Throat J* 1997; 76: 450–3, 456.
78. Rosenthal E, Carroll W, Dobbs M. Simplifying head and neck microvascular reconstruction. *Head Neck* 2004; 26: 930–6.
79. Civantos FJ Jr, Burkey B, Lu FL et al. Lateral arm microvascular flap in head and neck reconstruction. *Arch Otolaryngol Head Neck Surg* 1997; 123: 830–6.
80. Gibson MK, Li Y, Murphy B et al. Randomized phase III evaluation of cisplatin plus fluorouracil versus cisplatin plus paclitaxel in advanced head and neck cancer (E1395): an intergroup trial of the Eastern Cooperative Oncology Group. *J Clin Oncol* 2005; 23: 3562–7.
81. Pantvaidya GH, D'Cruz AK, Prabhash K. Palliation in incurable head and neck cancers: chemotherapy? *J Clin Oncol* 2005; 23: 8128–9.
82. Gillespie MB, Brodsky MB, Day TA et al. Laryngeal penetration and aspiration during swallowing after the treatment of advanced oropharyngeal cancer. *Arch Otolaryngol Head Neck Surg* 2005; 131: 615–9.
83. Gillespie MB, Brodsky MB, Day TA et al. Swallowing-related quality of life after head and neck cancer treatment. *Laryngoscope* 2004; 114: 1362–7.
84. Pauloski BR, Rademaker AW, Logemann JA et al. Surgical variables affecting swallowing in patients treated for oral/oropharyngeal cancer. *Head Neck* 2004; 26: 625–36.
85. Zuydam AC, Lowe D, Brown JS et al. Predictors of speech and swallowing function following primary surgery for oral and oropharyngeal cancer. *Clin Otolaryngol* 2005; 30: 428–37.
86. El-Deiry M, Funk GF, Nalwa S et al. Long-term quality of life for surgical and nonsurgical treatment of head and neck cancer. *Arch Otolaryngol Head Neck Surg* 2005; 131: 879–85.
87. Netscher DT, Meade RA, Goodman CM et al. Quality of life and disease-specific functional status following microvascular reconstruction for advanced (T3 and T4) oropharyngeal cancers. *Plast Reconstr Surg* 2000; 105: 1628–34.
88. Murry T, Madasu R, Martin A et al. Acute and chronic changes in swallowing and quality of life following intraarterial chemoradiation for organ preservation in patients with advanced head and neck cancer. *Head Neck* 1998; 20: 31–7.

# Lung and bronchus

9

Joe B Putnam

---

## OVERVIEW

Carcinoma of the lung and bronchus constitutes a significant public health threat worldwide. The politics of tobacco use and tobacco taxes significantly complicate prevention efforts. In the US, carcinoma of the lung is projected to account for approximately 15% of all new cancer diagnoses and 29% of all cancer deaths in 2007. This will include an estimated 213 380 total new cases (114 760 men, 98 620 women), and an estimated 160 390 deaths (89 510 men, 70 880 women). In men, the death rate from lung cancer is declining; however, in women the death rate has stabilized. Lung cancer is the number one cancer killer in women in the US surpassing breast cancer deaths in 1987<sup>1</sup>.

In the US, non-small cell lung carcinoma (NSCLC) accounts for approximately 87% of all lung cancer. Small cell lung carcinoma (SCLC) accounts for 13% of all lung cancer. SCLC is not typically treated by resection. Limited stage SCLC is treated with chemotherapy (platinum based) with thoracic radiotherapy and prophylactic cranial radiation. Extensive stage SCLC is treated typically with chemotherapy alone. For NSCLC, the most frequent histologies are adenocarcinoma, squamous cell carcinoma and large cell carcinoma. NSCLC treatment depends upon the stage of the cancer and the patient's overall physical status. For localized tumors, resection is recommended. Various studies have suggested that post-operative (adjuvant) chemotherapy improves overall survival. In locally advanced tumors, radiation therapy and chemotherapy used together provide better outcome than chemotherapy or radiation alone. Combinations of chemotherapy, radiation therapy and surgery may be considered in selected patients (Table 9.1). The overall 5-year survival rate for all stages combined is only 16%. If the NSCLC is localized, 5-year survival can be 49%; however, only 16% of patients with lung cancer are diagnosed in this early stage<sup>1</sup>.

## EVALUATION OF THE PATIENT WITH NON-SMALL CELL LUNG CARCINOMA

Evaluation of the patient with a known or suspected diagnosis of NSCLC will include an accurate clinical assessment of the extent of the disease itself, and a decision for the most effective therapy based upon the clinical stage of the patient, the patient's physiological fitness, as well as other subjective patient and physician factors<sup>20</sup>. Patients are selected for specific treatment (including surgery) based on the clinical stage, e.g. the clinician's best and final estimate of the extent of the NSCLC, based on all available data prior to the initiation of definitive therapy. This clinical staging includes the diagnostic, non-invasive and invasive studies to evaluate the extent of disease before therapy is begun.

Initially, the clinician performs a careful history and physical examination. The presence of cervical or supraclavicular lymph nodes, and paraneoplastic syndromes may suggest a more locally advanced or metastatic tumor. A few patients may be asymptomatic with a solitary pulmonary nodule<sup>21,22</sup>. Lesions that are radiologically stable by chest X-ray or computed tomography (CT) of the chest for a minimum of 2 years are very likely to be benign<sup>21,22</sup>. Most patients with NSCLC will have specific symptoms such as cough, dyspnea, chest pain, or hemoptysis. Fever or upper airway obstruction may also be present. Constitutional symptoms such as anorexia, malaise, fatigue, and weight loss may occur in up to 70% of patients.

In patients with a clinically suspicious lung lesion and non-diagnostic bronchoscopy and/or transthoracic needle aspiration studies, more invasive diagnostic studies means for diagnosis are indicated<sup>20</sup>. In a physiologically fit patient with a suspicious pulmonary lesion, resection provides both diagnosis and treatment. Peripheral lesions can often be assessed with a non-anatomic ('wedge') resection by thoracoscopy or open procedures. Confirmation of

**Table 9.1** Primary therapy considerations for non-small cell lung carcinoma (NSCLC) by stage. Note that all patients should be considered for participation into therapeutic clinical trials

#### *Stage I*

Anatomic resection (lobectomy) with mediastinal lymph node dissection often cures NSCLC

Induction or adjuvant therapy is not standard, although has been evaluated for stages I–IIIA<sup>2,3</sup>, IB<sup>4</sup>, IB–IIIA<sup>5</sup>, and IB–II<sup>6</sup>. One meta-analysis suggested that chemotherapy does not benefit stage IA<sup>7</sup> but may benefit other stages<sup>8</sup>

For medically inoperable patients, radiation therapy is commonly used for local control

Clinical trials are currently underway evaluating sublobar resection with brachytherapy, stereotactic radiation, radiofrequency ablation, and other modalities

#### *Stage II*

Anatomic resection with mediastinal lymph node dissection often cures NSCLC. Induction therapy is not standard but has been evaluated<sup>9</sup>. Adjuvant (postoperative) therapy improves survival<sup>12,3,5–7,10</sup>. Cisplatin-based adjuvant chemotherapy improves survival following resection of NSCLC<sup>7</sup>

For medically inoperable patients, radiation therapy or chemoradiotherapy<sup>11</sup> is typically used

#### *Stage IIIa*

Accurate clinical staging with FDG-PET is essential for optimizing therapeutic recommendations<sup>12</sup>

If clinical staging confirms (histologically) metastasis to N2 lymph nodes, chemoradiotherapy is effective<sup>11</sup>. Following R0 resection, patients with metastasis to N2 lymph nodes should be considered for adjuvant chemotherapy to enhance survival<sup>12,3,5,7,10,13</sup>

The role of preoperative chemotherapy and radiation therapy for limited stage IIIa is unclear<sup>14</sup>

Preoperative chemotherapy and radiation therapy has been shown to be effective for superior sulcus tumors<sup>15</sup>

#### *Stage IIIB*

Chemoradiotherapy generally recommended. Resection is recommended in highly selected patients for isolated T4N0M0 to achieve an R0 resection<sup>16</sup>

Contralateral nodal disease (N3) not considered ‘resectable’

Malignant pleural effusion treatment should focus on palliation of dyspnea and control of recurrent effusions<sup>17</sup>

#### *Stage IV*

Chemotherapy with a two-drug combination is recommended (platinum-based)<sup>18</sup>. Survival following chemotherapy together with a targeted agent (e.g. bevacizumab) appears to be better than chemotherapy alone. Some increased risk of treatment-related deaths did occur<sup>19</sup>

Resection not recommended; palliation of sequelae of advanced disease may be required

---

FDG-PET, <sup>18</sup>fluorodeoxyglucose-positron emission tomography.

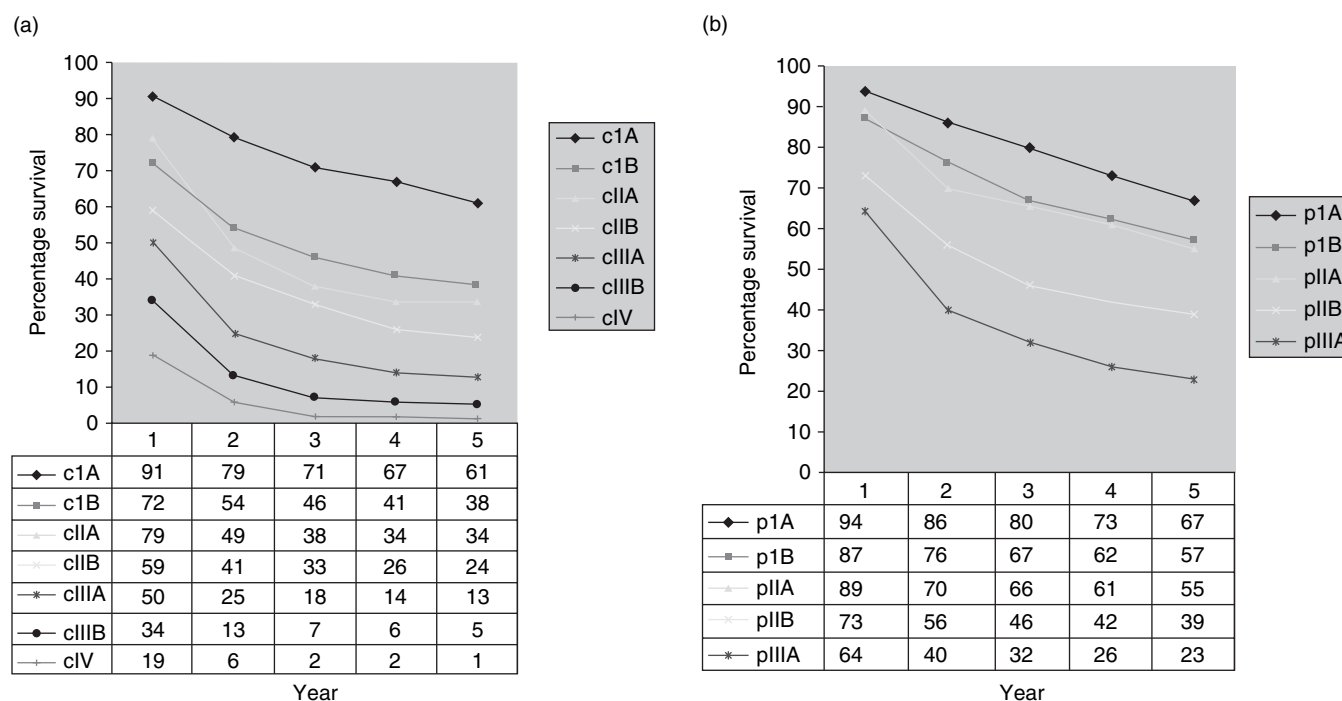
NSCLC should be followed by definitive resection for patients of appropriate stage.

## STAGING

The current international staging system has demonstrated survival differences by stage<sup>23–25</sup> based upon anatomic differences in tumor size and location, characteristics of hilar, mediastinal, or other nodal groups, and presence or absence of metastatic disease (Figure 9.1). The tumor, node, metastases (TNM) definitions and stage groupings of the TNM subsets are presented in Tables 9.2, 9.3, 9.4 and 9.5. Descriptions of all T and N disease are given in Table 9.2. Stage grouping definitions are shown in Tables 9.3 and 9.4. The lymph node map definitions are shown in Table 9.6. The regional lymph node

classification schema is presented in Figure 9.2. This map presents a graphical representation of the mediastinal and pulmonary lymph nodes in relationship to other thoracic structures for optimal dissection and correct anatomic labeling by the surgeon. A pathology report will include the results of examination of all submitted tissue which will affect the pathological stage (see Table 9.7).

The assessment of lymph node involvement by NSCLC is the most challenging and most critical aspect of clinical staging. Simple identification of enlarged mediastinal lymph nodes cannot be used as equivalent to involvement with metastasis from the primary NSCLC. Normal lymph nodes may be enlarged from infection or other inflammatory processes. Enlarged (≥1 cm) mediastinal lymph nodes require additional evaluation to include <sup>18</sup>fluorodeoxyglucose-positron emission



**Figure 9.1** Survival by stage in non-small cell lung carcinoma. (a) Survival by clinical stage. (b) Survival by pathological stage. Adapted from reference 23.

**Table 9.2** TNM characteristics of non-small cell lung carcinoma (NSCLC)

*Primary tumor (T)*

TX Tumor proven by the presence of malignant cells in bronchopulmonary secretions but not visualized roentgenographically or bronchoscopically, or any tumor that cannot be assessed, as in a retreatment staging

T0 No evidence of primary tumor

Tis Carcinoma *in situ*

T1 A tumor that is  $\leq 3.0$  cm in greatest dimension, surrounded by lung or visceral pleura, and without evidence of invasion proximal to a lobar bronchus at bronchoscopy\*

T2 A tumor  $> 3.0$  cm in greatest dimension, or a tumor of any size that either invades the visceral pleura or has associated atelectasis or obstructive pneumonitis extending to the hilar region. At bronchoscopy, the proximal extent of demonstrable tumor must be within a lobar bronchus or at least 2.0 cm distal to the carina. Any associated atelectasis or obstructive pneumonitis must involve less than an entire lung

T3 A tumor of any size with direct extension into the chest wall (including superior sulcus tumors), diaphragm, or the mediastinal pleura or pericardium without involving the heart, great vessels, trachea, esophagus, or vertebral body, or a tumor in the main bronchus within 2 cm of the carina without involving the carina, or associated atelectasis or obstructive pneumonitis of entire lung

T4 A tumor of any size with invasion of the mediastinum or involving heart, great vessels, trachea, esophagus, vertebral body, or carina or presence of malignant pleural or pericardial effusion†, or with satellite tumor nodules within the ipsilateral, primary tumor lobe of the lung

*(N) Nodal involvement*

N0 No demonstrable metastasis to regional lymph nodes

N1 Metastasis to lymph nodes in the peribronchial or the ipsilateral hilar region, or both, including direct extension

N2 Metastasis to ipsilateral mediastinal lymph nodes and subcarinal lymph nodes

*Continued*



**Table 9.2** *Continued*

N3 Metastasis to contralateral mediastinal lymph nodes, contralateral hilar lymph nodes, ipsilateral or contralateral scalene, or supraclavicular lymph nodes

(M) *Distant metastasis*

M0 No (known) distant metastasis

M1 Distant metastasis present‡. Specify site(s)

\*The uncommon superficial tumor of any size with its invasive component limited to the bronchial wall which may extend proximal to the main bronchus is classified as T1.

†Most pleural effusions associated with NSCLC are due to tumor. There are, however, some few patients in whom cytopathological examination of pleural fluid (on more than one specimen) is negative for tumor, the fluid is non-bloody and is not an exudate. In such cases where these elements and clinical judgment dictate that the effusion is not related to the tumor, the patients should be staged T1, T2, or T3, excluding effusion as a staging element.

‡Separate metastatic tumor nodules in ipsilateral nonprimary tumor lobe(s) of the lung also are classified M1. From references 23 and 24.

**Table 9.3** Stage grouping of the TNM subsets. The TNM subsets are combined in seven stage groups, in addition to stage 0, that reflect fairly precise levels of disease progression and their implications for treatment selection and prognosis. Staging is not relevant for occult carcinoma, TXN0M0

Stage 0 is assigned to patients with carcinoma *in situ*, which is consistent with the staging of all other sites

Stage IA includes only patients with tumors ≤3 cm in greatest dimension and no evidence of metastasis, the anatomic subset T1N0M0

Stage IB includes only patients with a T2 primary tumor classification and no evidence of metastasis, the anatomic subset T2N0M0

Stage IIA is reserved for patients with a T1 primary tumor classification and metastasis limited to the intrapulmonary, including hilar, lymph nodes, the anatomic subset T1N1M0

Stage IIB includes two anatomic subsets: patients with a T2 primary tumor classification and metastasis limited to the ipsilateral intrapulmonary, including hilar, lymph nodes, the anatomic subset T2N1M0; and patients with primary tumor classification of T3 and no evidence of metastasis, the anatomic subset T3N0M0

Stage IIIA includes four anatomic subsets that reflect the implications of ipsilateral, limited, extrapulmonary extension of the NSCLC. Patients included are those with a T3 primary tumor classification and metastasis limited to the ipsilateral intrapulmonary, including hilar, lymph nodes, T3N1M0 disease, and patients with T1, T2, or T3 primary tumor classifications and metastasis limited to the ipsilateral mediastinal and subcarinal lymph nodes – the T1N2M0, T2N2M0 and T3N2M0 subsets

Stage IIIB designates patients with extensive primary tumor invasion of the mediastinum and metastases to the contralateral mediastinal, contralateral hilar, and ipsilateral and contralateral scalene/supraclavicular lymph nodes. Patients with a T4 primary tumor classification or N3 regional lymph node metastasis, but no distant metastasis, are included

Stage IV is reserved for patients with evidence of distant metastatic disease, M1, such as metastases to brain, bone, liver, adrenal gland, contralateral lung, pancreas, and other distant organs, and metastases to distant lymph node groups such as axillary, abdominal, inguinal, etc. Patients with metastasis in ipsilateral nonprimary tumor lobes of the lung are also designated M1

From references 23 and 24.

tomography (FDG-PET) scan, endoscopic bronchial ultrasound and transbronchial biopsy, esophageal ultrasound with transesophageal needle biopsy, cervical mediastinoscopy, video-assisted thoracic surgery/thoracoscopy (VATS), transthoracic fine needle aspiration, or other staging modalities. Pathological assessment of metastasis

to suspicious lymph nodes must be confirmed prior to any initiation of treatment. Treatment algorithms are generally based on clinical staging and physiological evaluation<sup>26</sup> (see also Table 9.1).

A chest X-ray and CT of the chest and upper abdomen provide excellent assessment of tumor and

**Table 9.4** TNM subsets by stage

Stage	TNM subsets
Stage 0	Carcinoma <i>in situ</i>
Stage IA	T1N0M0
Stage IB	T2N0M0
Stage IIA	T1N1M0
Stage IIB	T2N1M0
	T3N0M0
Stage IIIA	T3N1M0
	T1N2M0, T2N2M0, T3N2M0
Stage IIIB	T4N0M0, T4N1M0, T4N2M0
	T1N3M0, T2N3M0, T3N3M0
	T4N3M0
Stage IV	Any T, any N, M1

From references 23 and 24.

**Table 9.5** A simplified mnemonic for TNM subsets by stage of lung cancer

	N0	N1	N2	N3
T1	IA	IIA	IIIA	IIIB
T2	IB	IIB	IIIA	IIIB
T3	IIB	IIIA	IIIA	IIIB
T4	IIIB	IIIB	IIIB	IIIB

From references 23 and 24.

mediastinal lymph node size (Figure 9.3) and correlates with metastatic involvement in 26–32% of patients<sup>27</sup>. Mediastinal lymph node metastases (N2 and N3 disease) significantly alter therapeutic recommendations. Patients with mediastinal lymph node involvement (confirmed N2 or N3 disease) do not consistently benefit from resection as the sole therapy or as the initial therapy for NSCLC. The availability of chemotherapy and radiation therapy with or without resection as potential treatment for stage IIIA NSCLC further underscores the importance of accurate staging prior to definitive resection<sup>9,14,28,29</sup>. ‘Pathological’ mediastinal adenopathy is most often defined as a maximal transverse diameter above 1 cm on axial CT images<sup>30</sup>. Enlargement does not equal metastasis; tissue confirmation is needed. In the absence of enlarged mediastinal nodes ( $\geq 1$  cm in

diameter), the likelihood of N2 or N3 disease is low. For patients with a T1 tumor, most would agree that no further nodal staging is needed prior to surgical exploration<sup>20</sup>. If mediastinal nodes of 1 cm or more are identified, lymph node tissue must be examined before definitive resection. No CT size criteria are entirely reliable for the determination of mediastinal lymph node involvement<sup>30</sup>.

PET is recommended or preoperative staging<sup>31</sup>. PET is based upon the differential metabolism of FDG by cancer cells compared with normal tissues. Increased uptake reflects elevated glucose consumption. The degree of abnormal uptake on PET is often expressed with use of a semiquantitative measure known as standardized uptake value (SUV), where the activity in a specific area is correlated with the background metabolism (Figure 9.3c). A PET scan is not a cancer-specific study, as high cellular glucose metabolism is seen in inflammation or infection. Areas of FDG uptake must be evaluated for histological evidence of NSCLC. Reed *et al.*<sup>12</sup> identified that PET and CT together were better than either study alone in determining the patient's suitability for resection. A PET negative (by FDG avidity) and CT negative (lymph nodes  $< 1$  cm in diameter) examination accurately predicted no mediastinal node involvement in 87% of patients.

Cervical mediastinoscopy (CME) is traditionally indicated in patients with otherwise operable NSCLC with enlarged paratracheal or subcarinal lymph nodes and considered the gold standard for mediastinal nodal staging prior to definitive resection. CME is commonly performed for biopsy of bilateral paratracheal (level 2 and 4) and subcarinal (level 7) lymph nodes. Additional sampling techniques may be accurate in selective situations. Level 5 and 6 nodes are more often examined with the use of a limited left parasternal incision in the 2nd or 3rd intercostal space (Chamberlain's procedure or anterior mediastinotomy) or with VATS. VATS techniques can evaluate enlarged level 5 or 6 lymph nodes, and as well, enlarged level 8 or 9 or low level 7 lymph nodes. Esophageal ultrasound-guided aspiration can be easily used for transesophageal needle aspiration of subcarinal, left aortopulmonary window, and other periesophageal lymph nodes<sup>30</sup>.

Metastatic adrenal involvement is identified in up to 7% of patients at presentation<sup>32</sup>. The standard CT evaluation of the chest should also extend through and include evaluation of the adrenal glands as minimal additional cost, time, or radiation exposure occurs. Indeterminate adrenal lesions on CT may be further evaluated with magnetic resonance imaging (MRI) or with CT-guided percutaneous biopsy.

Reed *et al.*<sup>12</sup> identified over 6% of patients with unsuspected metastatic disease or second primary

**Table 9.6** Lymph node map definitions (see also Figure 9.2)*N2 nodes – all N2 nodes lie within the mediastinal pleural envelope*

- 1 Highest mediastinal nodes: nodes lying above a horizontal line at the upper rim of the brachiocephalic (left innominate) vein where it ascends to the left, crossing in front of the trachea at its midline
  - 2 Upper paratracheal nodes: nodes lying above a horizontal line drawn tangential to the upper margin of the aortic arch and below the inferior boundary of #1 nodes
  - 3 Prevascular and retrotracheal nodes: pre- and retrotracheal nodes may be designated 3A and 3P. Midline nodes are considered to be ipsilateral
  - 4 Lower paratracheal nodes: the lower paratracheal nodes on the right lie to the right of the midline of the trachea between a horizontal line drawn tangential to the upper margin of the aortic arch and a line extending across the right main bronchus at the upper margin of the upper lobe bronchus, and contained within the mediastinal pleural envelope; the lower paratracheal nodes on the left lie to the left of the midline of the trachea between a horizontal line drawn tangential to the upper margin of the aortic arch and a line extending across the left main bronchus at the level of the upper margin of the left upper lobe bronchus, medial to the ligamentum arteriosum and contained within the mediastinal pleural envelope
- Researchers may wish to designate the lower paratracheal nodes as No. 4s (superior) and No.4i (inferior) subsets for study purposes; the No. 4s nodes may be defined by a horizontal line extending across the trachea and drawn tangential to the cephalic border of the azygos vein; the No. 4i nodes may be defined by the lower boundary of No. 4s and the lower boundary of No. 4, as described above

*Regional lymph node classification*

- 5 Subaortic (A–P window): subaortic nodes are lateral to the ligamentum arteriosum or the aorta or left pulmonary artery and proximal to the first branch of the left pulmonary artery, and lie within the mediastinal pleural envelope
  - 6 Para-aortic nodes (ascending aorta or phrenic): nodes lying anterior and lateral to the ascending aorta and the aortic arch or the innominate artery, beneath a line tangential to the upper margin of the aortic arch
  - 7 Subcarinal nodes: nodes lying caudal to the carina of the trachea, but not associated with the lower lobe bronchi or arteries within the lung
  - 8 Paraesophageal nodes (below carina): nodes lying adjacent to the wall of the esophagus and to the right or left of the midline, excluding subcarinal nodes
  - 9 Pulmonary ligament nodes: nodes lying within the pulmonary ligament, including those in the posterior wall and lower part of the inferior pulmonary vein
- N1 nodes – all N1 nodes lie distal to the mediastinal pleural reflection and within the visceral pleura
- 10 Hilar nodes: the proximal lobar nodes, distal to the mediastinal pleural reflection and the nodes adjacent to the bronchus intermedius on the right; radiographically, the hilar shadow may be created by enlargement of both hilar and interlobar nodes
  - 11 Interlobar nodes: nodes lying between the lobar bronchi
  - 12 Lobar nodes: nodes adjacent to the distal lobar bronchi
  - 13 Segmental nodes: nodes adjacent to segmental bronchi
  - 14 Subsegmental nodes: nodes around the subsegmental bronchi

From references 23 and 24.

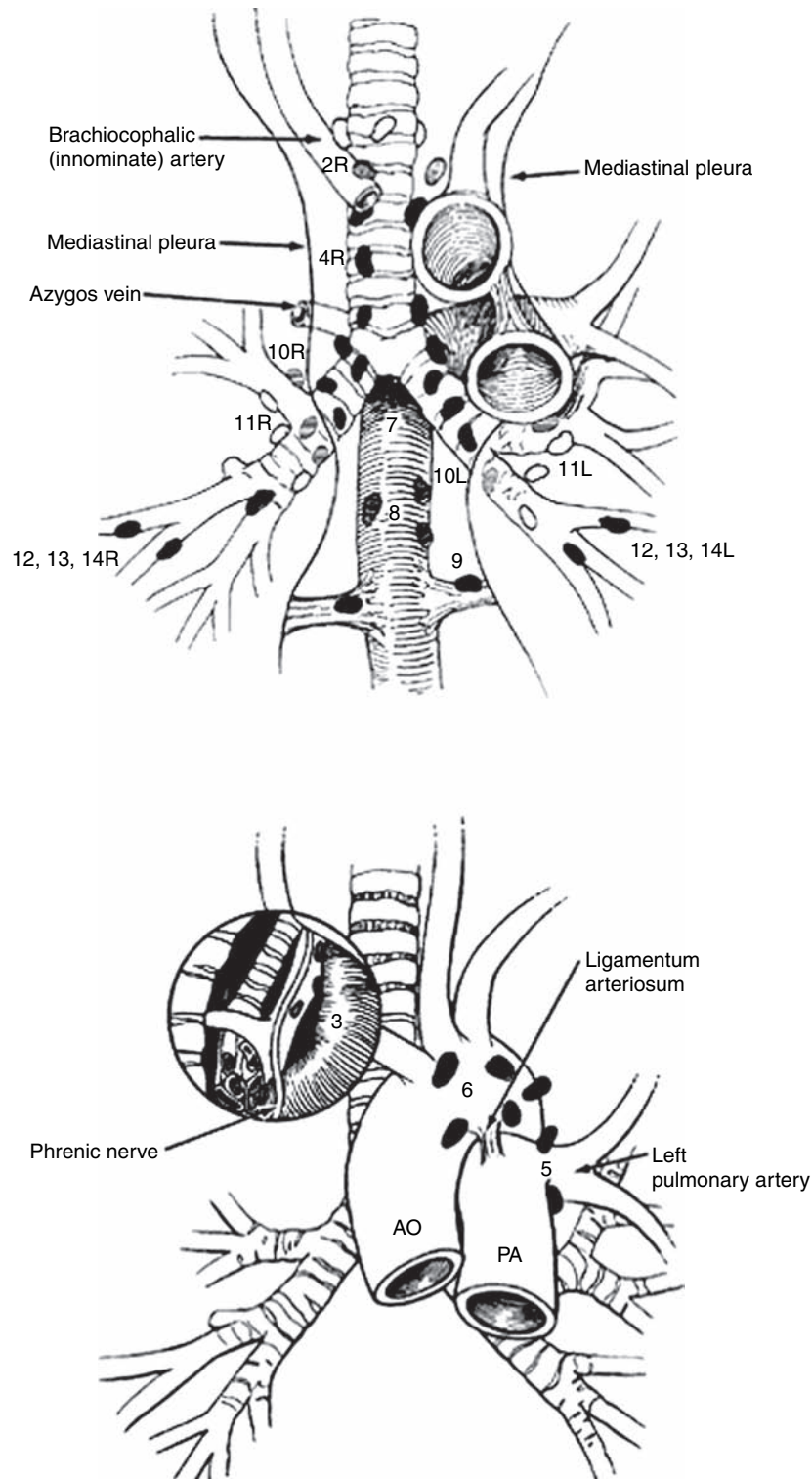
malignancy in otherwise resectable patients with NSCLC. A recent randomized trial of whole-body PET in NSCLC staging further supported its potential role in metastatic evaluation<sup>33</sup>.

In early stage NSCLC, other studies such as bone scan, or CT or MRI of the brain should only be performed if the patient has symptoms related to that organ, or if small cell carcinoma is suspected. It is not cost-effective to perform a CT scan of the brain in an otherwise

asymptomatic patient who is physiologically fit and stage-appropriate for surgery.

## PHYSIOLOGICAL EVALUATION

The physiological evaluation must be individualized for each patient. The assessment of a patient's ability to tolerate lung resection from a cardiopulmonary



**Figure 9.2** Lymph node (1–14) map for mediastinal lymph node stations. Single digit nodal stations represent mediastinal lymph nodes (N2); double digit nodal stations represent intraparenchymal or intrapleural stations (N1). PA, pulmonary artery; AO, aorta; L; left; R, right. From references 23 and 24.

standpoint is fundamental to patient selection for surgery. Patients with advanced pulmonary disease and severe pulmonary dysfunction may have prohibitive risk despite otherwise resectable disease. Cigarette smoking is

associated with increase in the incidence of postoperative pulmonary complications after surgery. Preoperative smoking abstinence reduces the incidence of complications<sup>34</sup>.

**Table 9.7** Pathology report. The pathology report is expected to include specific information for demographic and cancer center statistics. An R0 result was accomplished in this patient. An example is presented of summary findings (from the pathology report of the patient described in Figure 9.3)

---

Specimen type: left upper lobectomy
Laterality: left
Tumor site: left upper lobe
Tumor size: 10.0 cm
Histological type: adenocarcinoma
Histological grade: moderate (2 of 3)
Pathological staging (pTNM): IB
primary tumor: pT2
regional lymph nodes: pN0
distant metastasis: NA
Margins (give distance of tumor from closest margin if uninvolved): 1.0 cm
Direct extension of tumor: through visceral pleura
Venous (large vessel invasion): not identified
Arterial (large vessel invasion): not identified
Lymphatic (small vessel invasion) (optional): not identified

---

Advanced age is an independent predictor of mortality after resection for NSCLC<sup>35</sup> and most likely serves as a surrogate marker for additional co-morbidities rather than an independent risk factor. Pulmonary resection may be performed with acceptable rates of morbidity and mortality in patients well beyond the age of 70.

Spirometry is mandatory for patients being considered for pulmonary resection and provides an objective assessment of pulmonary function (Figure 9.3d). The forced expiratory volume in 1 second (FEV-1) is the historical standard to determine suitability for resection. A predicted postoperative FEV-1 (ppoFEV-1) can be estimated based on the planned extent of resection:  $\text{ppoFEV-1} = \text{preoperative FEV-1} \times (\text{number of segments remaining} / \text{total segments})^{34}$ . FEV-1 is an independent predictor of mortality from surgery for NSCLC<sup>35</sup>, and serves as the primary determinant of the need for further physiological assessment prior to surgery for NSCLC. The criterion of ppoFEV-1 of at least 0.8 l has been widely used in decisions for NSCLC resection. However, an absolute value of FEV-1 predicts postresection pulmonary function less accurately than FEV-1 expressed as a percentage of the expected value for age and size. In general, patients with an absolute FEV-1 of greater than 2.0 l are likely to tolerate pneumonectomy, and those with an FEV-1 >1.5 l lobectomy<sup>20,36</sup>. Patients deemed unable to tolerate lobectomy from a pulmonary functional standpoint may be

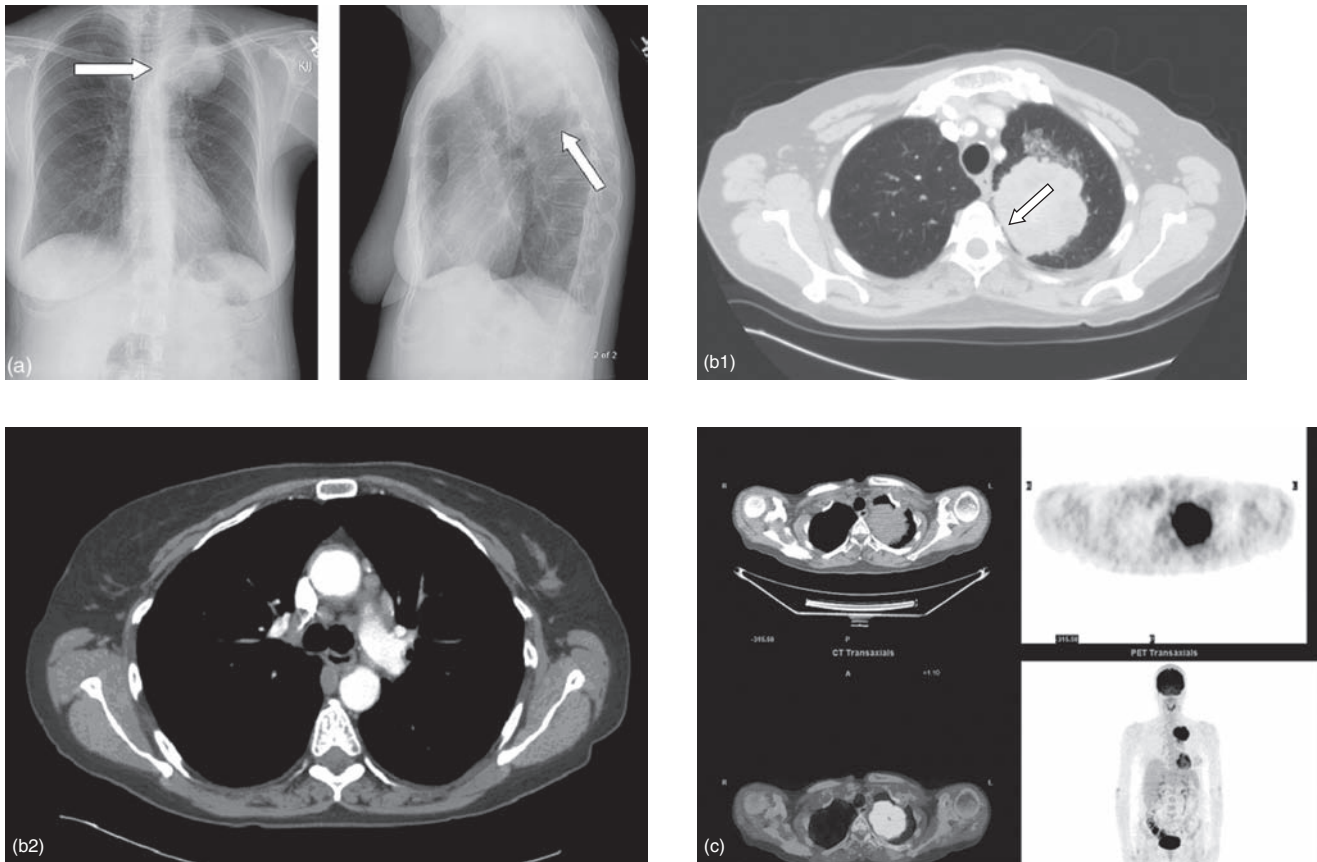
candidates for more limited resections, such as wedge or anatomic segmental resection. Although such procedures are associated with significantly higher rates of local recurrence and a trend towards decreased survival<sup>37,38</sup>, minimally invasive techniques and improved postoperative pain management techniques (patient controlled analgesia, epidural anesthesia, etc.) may allow pulmonary resection in many patients previously considered medically inoperable.

Pulmonary diffusing capacity for carbon monoxide (DLCO) provides a measurement of the lung surface area available for gas exchange, and is determined by measuring expired carbon monoxide levels during controlled exhalation. A low DLCO reflects the presence of emphysema, fibrosis, or pulmonary vascular disease. Similar to FEV-1, preoperative DLCO measurement is most useful when expressed as a percentage of predicted value<sup>36</sup> and may be used to estimate predicted postoperative DLCO (ppoDLCO).

Cardiopulmonary exercise testing can be extremely useful in evaluating patients who appear more disabled than expected from simple spirometry measurements or with ppoFEV-1 or DLCO <40% predicted. These studies include exercise electrocardiography, heart rate response to exercise, and the measurements of minute ventilation and oxygen uptake per minute. Maximal oxygen consumption (VO<sub>2</sub>max) evaluates the 'cardiopulmonary axis' and may identify clinically occult cardiac disease and provide a more accurate assessment of pulmonary function than spirometry and DLCO<sup>39</sup>. A patient's risk of perioperative morbidity and mortality may be stratified by VO<sub>2</sub>max. Those with VO<sub>2</sub>max above 20 ml/kg/min are not at increased risk for complications or death after resection of NSCLC. A level below 15 ml/kg/min is associated with an increased risk, and VO<sub>2</sub>max <10 ml/kg/min indicates very high risk, generally precluding operation<sup>40,41</sup>.

Observed performance during stair climbing has historically been utilized in the preoperative assessment of patients with NSCLC. Stair climbing ability has some correlation with values on spirometry<sup>42</sup>, but perhaps is most correlated with a patient's global cardiopulmonary status and determination, both of which are fundamental to a successful outcome after surgery.

Quantitative radionuclide perfusion scanning, involves the injection of <sup>99m</sup>Tc-radiolabeled albumin particles, followed by the visual inspection of planar images (Figure 9.3e). Unlike perfusion scanning in the setting of suspected pulmonary thromboembolism, concomitant ventilation scanning is not routinely performed for preoperative assessment, as studies have demonstrated both are usually well matched and equally effective in assessing function. Quantitative perfusion provides a



**Figure 9.3** A 57-year-old woman with hemoptysis and 20 lb weight loss in the past year. She quit smoking cigarettes with this episode, but previously had smoked two packs per day for 30 years. She has no cough, fever, chills, or subsequent hemoptysis; she has some dyspnea on mild to moderate exertion. The patient also related 3/10 left posterior apical chest discomfort. (a) Chest X-ray posterior–anterior view and lateral view demonstrating a 6.7 cm left upper lobe mass near the lung apex. (b) Computed tomography (CT) of the chest confirmed a left upper lobe mass near the lung apex. A CT-guided biopsy of the lesion was significant for adenocarcinoma. (b) (upper) The mass itself extends to but does not appear to invade the prevertebral fascia. A soft tissue (pleural) plane is identified. A chest wall resection would not be expected, but an extrapleural dissection in this area may be required. (b) (lower) The mediastinal lymph nodes are identified and are enlarged ( $>1$  cm in the pretracheal area). The aortopulmonary window lymph nodes are identified but are non-specific. FDG-PET would be helpful in determining the extent of metabolic activity in these areas. (c) FDG-PET with integrated CT. CT demonstrates the large left upper lobe mass, and FDG-PET demonstrates significant metabolic activity in this area. No sites of metastases are noted in the mediastinum or elsewhere. Physiological uptake is noted in the brain, bones, liver, spleen, kidney, and musculature, and in the renal collecting system and the bladder. Some activity in the colon is noted as well. Although PET did not identify FDG avid lesions in the mediastinum, CT demonstrated some enlarged  $>1$  cm lymph nodes in the pretracheal space. Based on these findings, additional invasive staging with mediastinoscopy or other mediastinal staging (endobronchial ultrasound, esophageal ultrasound) is warranted. Clinically these findings are associated with reactive adenopathy or subclinical metastases. (d) Pulmonary function studies (spirometry) with diffusing capacity of the lung for carbon monoxide (DLCO). This patient has good pulmonary function despite a long history (60 pack-years) of cigarette smoking. A flow-volume loop is normal in appearance. FVC, forced vital capacity; FEV1, forced expiratory volume in 1 second; FEF, forced expiratory flow; PEF, peak expiratory flow; TLC, total lung capacity; VC, vital capacity; FRC PL, functional residual capacity; ERV, expiratory reserve volume; RV; DL; VA; IVC,. (e) Quantitative ventilation perfusion scan. The location of the tumor and its proximity to the proximal hilum suggests that pneumonectomy may be required. The ability of the patient to tolerate left pneumonectomy would be determined with pulmonary function studies. A quantitative ventilation perfusion lung scan would be performed. The perfusion phase is shown here. The images are viewed from a posterior to anterior direction. The left upper lung field has marginal function (5.5%). Even if the patient did require a pneumonectomy she would still have sufficient pulmonary reserve in her right lung (56.6%). Her predicted postoperative (ppo) FEV1 would be  $1.79 \text{ l/sec} \times 0.566 \text{ perfusion in right lung} = 1.011 \text{ ppoFEV1}$  remaining. Cardiology evaluation was not performed given the patient's active lifestyle and no symptoms of cardiovascular disease. Given the overall physiological fitness of the patient, the location of the primary tumor and the ability to remove all disease with a lobectomy or possibly a pneumonectomy, resection is possible. The operation would include bronchoscopy, cervical mediastinal staging with mediastinoscopy or other technique. If negative, pulmonary resection and mediastinal lymph node dissection would be performed to achieve a R0 resection. Should occult lymph node involvement be identified in the postresection specimen, adjuvant chemotherapy would be recommended.

VANDERBILT MEDICAL CENTER PULMONARY LAB  
1301 22ND AVENUE, NASHVILLE, TN 37232

Age: 53  
Weight(lb): 131  
Race: Caucasian

Height(in): 62  
Gender: Female

			Ref	Pre	% Ref	Post	% Ref	% Chg	<div>Flow</div> <div>Volume</div>
Spirometry									
FVC	Liters		2.97	2.57	86	2.69	91	5	
FEV1	Liters		2.44	1.67	68	1.79	73	7	
FEV1/FVC	%		82	65		66			
FEF25-75%	l/sec		2.66	0.88	33	1.00	37	13	
PEF	l/sec		6.88	3.93	57	3.92	57	-0	
Lung Volumes									
TLC	Liters		4.73	4.43	94				
VC	Liters		2.97	2.74	92				
FRC PL	Liters		2.63	2.37	90				
ERV	Liters			0.68					
RV	Liters		1.74	1.70	98				
RV/TLC	%		36	38					
Diffusing Capacit (Hb 12.8)									
DLCO	ml/mmHg/min		19.7	13.6	69				
DL Adj	ml/mmHg/min		19.7	13.6	71				
DLCO/VA	ml/mHg/min/l		3.96	3.41	86				
DL/VA Adj	ml/mHg/min/l			3.48					
VA	Liters		4.23	4.00	94				
IVC	Liters			2.50					

#### Comments

All data is ACCEPTABLE and REPRODUCIBLE according to ATS standards.

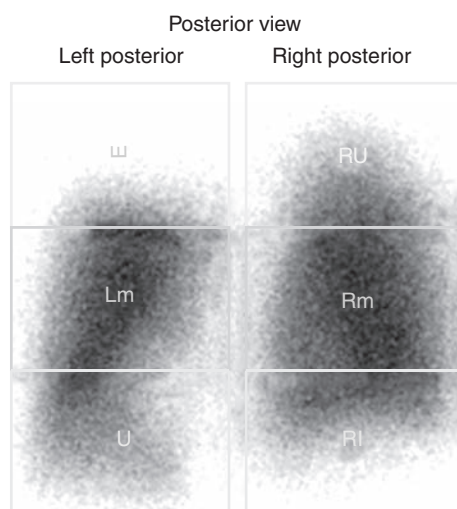
Calibration Data: Temp: 22 PBar: 743

Flow Cal Date: 02/13/07 Pred Volume: 3.00 Expire Avg: 3.03 Inspire Avg: 3.02

PF Reference: Vanderbilt

Version: IVS-0101-12-3A

(d)



	Left	Right
Upper	5.5	11.5
Middle	25.2	32.4
Lower	12.7	12.7
Total	43.4%	56.6%

(e)

Figure 9.3 Continued



measurement of the relative function of each lobe and lung, allowing a prediction of pulmonary function after lung resection.

Arterial blood gas (ABG) analysis is not a mandatory component of preoperative assessment for lung resection. It may be indicated in marginal candidates, or if there is a clinical suspicion of significant hypoxia or carbon dioxide retention.

Cardiovascular evaluation should therefore conform to American College of Cardiology (ACC) and American Heart Association (AHA) guidelines for non-cardiac surgery.

### **Surgical management of non-small cell lung carcinoma**

Fundamentals of surgical management of NSCLC include complete resection with negative margins (R0), systematic mediastinal lymph node dissection, and integration of multidisciplinary teams in all but the earliest (clinical stage IA) or metastatic (stage IV) disease. Resection of NSCLC is safe with modern mortality of 1.35% based upon a multi-institutional prospective randomized trial of over 1000 patients evaluating mediastinal lymph node sampling compared with dissection<sup>43</sup>. Resection of NSCLC can be curative in the earliest stages<sup>44</sup>. Postoperative convalescent care must include aggressive mobilization, pulmonary hygiene and pain control (typically with thoracic epidural catheter).

## **STAGE-SPECIFIC THERAPY**

### **Occult non-small cell lung carcinoma (TX, TisN0M0)**

Screening for second aerodigestive malignancies can result in identification of carcinoma *in situ* or microinvasive tumor by flexible bronchoscopy. These lesions may be treated with endoluminal therapy; however, most patients would be considered for resection with segmentectomy or lobectomy. The choice of anatomic resection must be carefully considered as field cancerization may be present with multiple involved areas present. Mucosal ablating techniques include photodynamic therapy, brachytherapy, electrocautery, cryotherapy, and neodymium-yttrium-garnet (Nd-Yag) laser therapy.

### **Stage I non-small cell lung carcinoma (T1–2N0M0)**

Patients with stage IA and IB NSCLC benefit from complete – R0 – resection. For stage IA patients, 5-year

survival may range from 67 to 75%. Lobectomy and mediastinal lymph node dissection remain the gold standard for stage I NSCLC<sup>37</sup>, although lesser resections (wedge, segmentectomy, etc.) have advantages in patients with more limited pulmonary reserve<sup>45</sup>. Other reports have suggested that segmental resection, when compared with lobectomy, tends to spare pulmonary reserve without significant impairment of survival<sup>46</sup>. Iodine brachytherapy mesh applied to the suture line may be helpful in decreasing local recurrence<sup>47</sup>. Such therapy may provide local control that approaches lobectomy.

VATS techniques have advanced to a common level commensurate with safe anatomic resection of parenchymal neoplasms and lymph node sampling<sup>48</sup>, and are preferred to VATS wedge resection of NSCLC as these patients have increased local recurrence<sup>49</sup>.

Adequate pathological staging derives from a systematic approach to the mediastinum for nodal dissection. Although the minimal requirement is sampling the mediastinal lymph nodes (at least one lymph node from various lymph node stations), a systematic mediastinal lymph node dissection is recommended (a dissection of all lymph nodes from various lymph node stations). Mediastinal lymph node dissection (lymphadenectomy) optimizes the accuracy of the pathological stage and provides information to the clinician as to potential survival and the need for postresection therapy for the individual patient. The American College of Surgeons Oncology Group (ACOSOG) Z0030 studied patients with N0 or N1 (less than hilar) NSCLC who underwent lymph node sampling and frozen section. Those patients with negative mediastinal sampling were randomized to lymph node dissection, or no additional lymph node manipulation. Until this trial is completed, mediastinal lymph node dissection is preferred to enhance accuracy from pathological staging. Adjuvant therapy is an increasingly important postoperative consideration which is based upon the pathology findings, particularly mediastinal lymph nodes, margin status and patient health<sup>2–8</sup>.

Patients are commonly followed for second primary tumors, although the cost benefit of this strategy has not been clearly defined<sup>50</sup>. About 5% of stage I NSCLC patients will develop a second primary cancer (incidence 1.99/100 patient-years)<sup>51,52</sup> and benefit from resection with 5-year survival 44%<sup>53</sup>.

### **Stage II non-small cell lung carcinoma (T1–T2N1M0, T3N0M0)**

Stage II NSCLC accounts for approximately 5% of all patients with NSCLC<sup>54</sup> with overall 38.7% actuarial



survival. Clinical stage II NSCLC (T1–2N1M0) is infrequently diagnosed before resection, most patients being considered clinical stage I. The hilar nodal involvement is often obscured by the primary tumor. Patients with T3 tumors have invasion of the chest wall, diaphragm, or peripheral mediastinum, e.g. mediastinal pleura, pericardium, phrenic nerve, azygos vein, or right or left pulmonary artery. T3 tumors are within the main bronchus within 2 cm of the carina without involving the carina. These hilar tumors may be complex and require pneumonectomy if both the upper and lower lobar bronchi are involved. Adjuvant therapy can be considered following resection of stage II NSCLC<sup>2–8</sup>.

### *Superior sulcus tumors*

NSCLC arising from the apex of the lung, superior sulcus tumors, should always be considered for surgery to improve function and relieve pain. These tumors account for approximately 3% of NSCLC. Symptoms include shoulder and arm pain, Horner's syndrome, and occasionally paresthesias in the ulnar nerve distribution of the hand (4th and 5th fingers). Patients with all these characteristics may be classified as having 'Pancoast syndrome'. Pain comes from the C8 and T1 nerve roots. Sympathetic nerve involvement may result in Horner's syndrome (miosis, ptosis, anhidrosis, and enophthalmos). Typically, the first, second and third ribs are involved requiring resection. Reconstruction of the defect is not required as the scapula and arm protect the defect. CT and MRI are used to assess local extent of the tumor and treatment options.

Tumors involving the superior sulcus are frequently treated inadequately and inconsistently with 30 Gy of external beam radiation to the primary tumor prior to resection. No prospective trial has proven the benefit of this therapy over surgery alone and several disadvantages may occur. The North American Lung Intergroup trial 0160<sup>15</sup> evaluated 110 eligible mediastinoscopy negative patients with induction chemoradiation (two cycles of cisplatin and etoposide with concurrent radiation (45 Gy) followed by resection NSCLC of the superior sulcus 3–5 weeks later). Of 88 (80%) which, underwent thoracotomy and 83 (76%) had complete resection. Operative mortality was patients who ( $n=2$ ) 1.8%. In all, 61 (56%) patients had complete or minimal microscopic disease remaining. Five-year survival was 44% overall and 54% in patients with complete resection. Local control is improved with this strategy. Systemic failure, mostly cerebral metastases, occurred in about 25% of patients. A subsequent study SWOG 0220 is evaluating chemoradiotherapy (45 Gy) followed by resection and then adjuvant chemotherapy.

### *Mainstem bronchus tumor less than 2 cm from the carina*

Complete resection of NSCLC even when in the proximal airway is recommended in selected patients. Although pneumonectomy can be performed, specific techniques that spare non-involved lung parenchyma are preferred. Parenchymal-sparing approaches decrease perioperative morbidity and mortality, and maintain good survival. These techniques include 'sleeve resection', bronchoplasty, pulmonary artery sleeve resection, pulmonary arterioplasty, and tracheal resection/reconstruction. These techniques are infrequently required; however, they may be critical in patients with marginal pulmonary reserve, and highly desirable in all others. Five-year survival with complete resection is approximately 50%<sup>55</sup>. Bronchial sleeve resection with or without pulmonary artery resection and reconstruction can be accomplished with excellent results and good long-term survival. Morbidity, mortality and functional data suggest that such reconstructions are comparable with lobectomy in terms of pulmonary function<sup>56</sup>.

### **Locally advanced non-small cell lung carcinoma: stage IIIA**

Survival following resection of clinical stage IIIA NSCLC is approximately 20% at 5 years. Patients with T3N1 and T1–3N2 are included in this group. The management of this stage of disease challenges the surgeon and the multidisciplinary team given the heterogeneity of the local disease and the variable incidence of regional and systemic metastasis. Invasive staging with pathology examination of lymph node or other tissues further describes the clinical extent of the disease to refine treatment decisions. Pathological staging occurs after resection and relates the clinical stage (before treatment is initiated) to the extent of disease in the resected tissue. Patients with enlarged mediastinal lymph nodes must undergo mediastinoscopy prior to the initiation of treatment as size alone does not confirm pathology. Patients with positive N2 nodes by mediastinoscopy or other mediastinal staging technique should be considered for definitive chemotherapy and radiation therapy, or entry into a prospective clinical trial. Resection following chemotherapy and radiation therapy should not routinely take place outside a clinical trial or without a multidisciplinary plan established prior to initiation of any therapy.

Induction therapy has been undertaken to improve survival in patients with clinical stage IIIA (N2) disease. Small single institution studies<sup>28,29</sup> and other multi-institutional studies<sup>9</sup> have suggested a benefit from

induction chemotherapy. Adjuvant therapy has shown survival benefit in various prospective randomized clinical trials and meta-analyses<sup>2,3,5-8,10</sup>.

The North American Intergroup 0139 phase III study of concurrent chemotherapy and radiotherapy versus chemotherapy and radiotherapy followed by surgical resection for stage IIIA (pN2) NSCLC was designed to evaluate the role of resection after chemotherapy and radiation therapy. Pneumonectomy accounted for 14/15 postoperative deaths and may have compromised overall survival. The study showed that progression-free survival was better with resection after chemoradiotherapy, a non-significant survival advantage was shown with chemotherapy and radiotherapy followed by surgical resection, pN0 status was associated with prolonged survival, and although S may be considered in fit patients, the results with pneumonectomy are no different than with chemotherapy and radiotherapy alone<sup>14,57</sup>.

The down-staging identified with induction therapy is important in identifying patients with improved chances for survival. Patient with persistent N2 disease after induction therapy have poorer survival and should not typically be considered as operative candidates. SWOG 8805 (phase II) evaluated induction chemoradiotherapy followed by resection for patients with cstage IIIA and cstage IIIB. This strategy provided a pathological complete response in 22%; overall survival (3 years) was 27%. Patients with no residual mediastinal lymph node metastasis had a median survival of 30 months compared with 10 months with residual disease ( $p=0.0005$ )<sup>58</sup>. Another study identified a complete response rate of 28% following induction chemoradiotherapy. The 5-year survival was 35.8% compared with 9% with residual nodal disease ( $p=0.023$ )<sup>59</sup>. Alternatives to the initial mediastinal staging include esophageal ultrasound and transbronchial ultrasound<sup>60</sup>. Resection should be avoided after induction therapy in patients who have biopsy-proven residual tumor in the mediastinal nodes. The benefit of resection over and above that achieved with combined chemotherapy and radiation therapy is small and carries significant operative and perioperative risk. If a lobectomy only can be performed, 5-year survival may reach 40% following induction chemotherapy and radiotherapy.

### **Locally advanced non-small cell lung carcinoma: stage IIIB**

Stage IIIB includes patients with tumor invading into the trachea, carina, esophagus, vertebrae, aorta, vena cava, great vessels, or atrium/cardiac structures, any N3 nodal involvement, malignant pleural effusion, or more than one nodule in one lobe. Resection is typically reserved for those patients with clinically localized T4N0M0 status in

whom the tumor can be removed with negative margins (R0 resection)<sup>16</sup>. Survival may approach 25–30% at 5 years for selected patients. Tracheal resection and reconstruction for NSCLC is infrequently performed, although palliation of airway obstruction to relieve dyspnea may be accomplished by external beam radiation therapy, or by mechanical or laser debridement, intrabronchial stents, or endoluminal brachytherapy.

### *Malignant pleural effusions*

Patients with malignant pleural effusions frequently present with dyspnea, cough and loss of function. Treatment for patients with initial or recurrent malignant pleural effusions should focus on relief of symptoms of dyspnea and restoration of normal activity<sup>17</sup>. Treatment options for malignant pleural effusion include thoracentesis or repeat thoracentesis; tube thoracostomy, drainage and sclerotherapy using talc, bleomycin, or other material; placement of a chronic indwelling pleural catheter; and thoracoscopy with drainage and talc insufflation

Various other clinical presentations are included in stage IIIB NSCLC. These include satellite nodules, and extrathoracic or contralateral nodal metastasis (N3). A satellite nodule is a separate NSCLC of identical histology contained within the same lobe as the primary tumor. These are resectable with good survival. A satellite nodule is a secondary tumor nodule in the same lobe as the primary cancer having histology identical to that of the primary tumor. These are resectable with a 5-year survival of 33%<sup>61</sup>. These patients should be carefully staged for occult nodal or distant metastasis. Even with treatment, patients with extranodal or contralateral nodal disease typically have poor survival (15% 5-year survival)<sup>62</sup>. The presence of contralateral mediastinal disease or supraclavicular disease suggests a more widely advanced tumor that would be treated with chemotherapy and radiation therapy.

### **Stage IV non-small cell lung carcinoma**

Patients with metastatic NSCLC benefit from systemic therapy, e.g. chemotherapy alone or with bevacizumab<sup>18,19</sup>. Surgery is reserved for palliation of symptoms or resection of metastases with significant local manifestations (brain metastasis and seizures, etc.). Patients with two synchronous nodules of NSCLC with identical histology in different lobes have M1 disease by the current staging system, although it is impossible to exclude synchronous stage I NSCLC by clinical means alone. When doubt exists, the benefit of resection should be considered in selected physiologically fit patients. Appropriate staging with FDG-PET + CT and cervical mediastinoscopy would be required.

Patients with isolated brain metastases will do well with resection of the symptomatic lesion, and then treatment of the primary NSCLC based on the T and N status of the tumor. All patients should have additional staging which would include FDG-PET + CT. In patients considered as candidates for resection, cervical mediastinoscopy should also be performed – even in the presence of CT of the mediastinum with no enlarged nodes, and no FDG-avid lesions. The primary lung tumor is then treated according to T and N stage. Survival may range between 20 and 40% at 5 years<sup>63</sup>.

Hematogenous metastases to the adrenal gland and elsewhere, in general, portend a poor survival. Although isolated reports of resection have occurred, this treatment strategy is not uniformly successful<sup>64</sup>. Resection of metastatic NSCLC with curative intent is not recommended. The survival advantage seen in some patients following resection of systemic metastasis may be related to over-diagnosis bias in patients with early primary stage disease.

### Biological variability

The current staging system for NSCLC makes no provision for differences in biological tumor behavior. Of patients with stage I disease 30–40% will manifest locoregional or distant recurrence after apparently complete resection<sup>23</sup>. Microarray and proteomic technologies form the basis of molecular fingerprinting in NSCLC that may in turn allow us to predict a tumor's phenotypic behavior<sup>65,66</sup>. The identification of patients at higher molecular risk for recurrence has the potential to supplement our current anatomic staging model with biological tumor characteristics that may predict a selective benefit from specific adjuvant therapies, a higher risk for recurrence, or a specific pattern for recurrence. Potti *et al.*<sup>67</sup> described a 'metagene' model for NSCLC, based on gene-expression profiles predictive of recurrence after treatment for early stage NSCLC. This molecular model predicted recurrence more accurately than clinical prognostic features across all tumor stages, highlighting the appeal of this evolving technology for enhanced staging and more accurate treatment models for NSCLC. Additional strategies to identify the molecular characteristics of the tumor as part of the initial staging could also improve survival by creating better models for treatments of NSCLC.

### Experimental surgical techniques

Experimental techniques for treatment of parenchymal NSCLC in medically inoperable patients include radio-frequency ablation<sup>68</sup> and stereotactic thoracic radiation<sup>69</sup>.

### Second primary tumors or metastasis?

Recurrent tumors may be resected safely and with good survival. Generally, NSCLC that recurs with identical histology within 2 years is considered a metastasis; NSCLC that recurs after 2 years is considered a second primary. Patients with resection of second (metachronous) primary NSCLC can have a 5-year survival of 40% after resection which is based on the T and N status of the second primary<sup>52</sup>. Completion pneumonectomy if required, can be performed safely, with good local control, and up to a 25% 5-year survival.

### SUMMARY

The surgeon balances the risks from mechanical extirpation of NSCLC (local disease control, pain relief, improved survival) and the benefits of improvement in survival and quality of life, based upon the individual patient's characteristics, co-morbidities, clinical stage, and perioperative evaluation. Typically, when the risks are 'high', resection is not considered; however, in some high-risk patients, risk may be successfully managed with good local control and survival. Resection of NSCLC can be performed safely in most patients who meet certain minimal physiological thresholds. Consistency of approach, application of proven intraoperative and perioperative techniques, completeness of resection, and adequacy of mediastinal lymph node dissection all benefit the patient in optimizing local control and subsequent therapeutic decisions. Selection of optimal surgical treatment for the patient with NSCLC requires excellent pre-treatment staging and clinical evaluation with discussion of all therapeutic possibilities by the integrated multidisciplinary care team: thoracic surgeon, pulmonologist, radiation oncologist, medical oncologist, and allied specialties. Future clinical trials should consider accurate and non-invasive measures of local control and recurrence, specific measures of response, and quality of life measures, as well as overall and disease-free survival.

## REFERENCES

- American Cancer Society. Cancer Facts and Figures 2007. 1–56. Atlanta, GA: American Cancer Society.
- Douillard JY, Rosell R, De LM et al. Adjuvant vinorelbine plus cisplatin versus observation in patients with completely resected stage IB–IIIA non-small-cell lung cancer (Adjuvant Navelbine International Trialist Association [ANITA]): a randomised controlled trial. *Lancet Oncol* 2006; 7: 719–27.
- Kato H, Ichinose Y, Ohta M et al. A randomized trial of adjuvant chemotherapy with uracil-tegafur for adenocarcinoma of the lung. *N Engl J Med* 2004; 350: 1713–21.
- Strauss GM, Herndon JE, Maddaus MA et al. Adjuvant chemotherapy in stage IB non-small cell lung cancer (NSCLC): update of Cancer and Leukemia Group B (CALGB) protocol 9633. 2006 ASCO Annual Meeting Proceedings. *J Clin Oncol* 2006; 24: abstr 7007.
- Arriagada R, Bergman B, Dunant A et al. Cisplatin-based adjuvant chemotherapy in patients with completely resected non-small-cell lung cancer. *N Engl J Med* 2004; 350: 351–60.
- Winton T, Livingston R, Johnson D et al. Vinorelbine plus cisplatin vs. observation in resected non-small-cell lung cancer. *N Engl J Med* 2005; 352: 2589–97.
- Pignon JP, Tribodet H, Scagliotti GV et al. Lung Adjuvant Cisplatin Evaluation (LACE): A pooled analysis of five randomized clinical trials including 4,584 patients. 2006 ASCO Annual Meeting Proceedings. *J Clin Oncol* 2006; 24: abstr 7008.
- Hotta K, Matsuo K, Ueoka H et al. Role of adjuvant chemotherapy in patients with resected non-small-cell lung cancer: reappraisal with a meta-analysis of randomized controlled trials. *J Clin Oncol* 2004; 22: 3860–7.
- Depierre A, Milleron B, Moro-Sibilot D et al. Preoperative chemotherapy followed by surgery compared with primary surgery in resectable stage I (except T1N0), II, and IIIA non-small-cell lung cancer. *J Clin Oncol* 2002; 20: 247–53.
- Chemotherapy in non-small cell lung cancer: a meta-analysis using updated data on individual patients from 52 randomised clinical trials. Non-small Cell Lung Cancer Collaborative Group. *BMJ* 1995; 311: 899–909.
- Dillman RO, Herndon J, Seagren SL et al. Improved survival in stage III non-small-cell lung cancer: seven-year follow-up of cancer and leukemia group B (CALGB) 8433 trial. *J Natl Cancer Inst* 1996; 88: 1210–5.
- Reed CE, Harpole DH, Posther KE et al. Results of the American College of Surgeons Oncology Group Z0050 trial: the utility of positron emission tomography in staging potentially operable non-small cell lung cancer. *J Thor Cardiovasc Surg* 2003; 126: 1943–51.
- Hotta K, Matsuo K, Kiura K et al. Advances in our understanding of postoperative adjuvant chemotherapy in resectable non-small-cell lung cancer. *Curr Opin Oncol* 2006; 18: 144–50.
- Albain KS, Swann RS, Rusch VR et al. Phase III study of concurrent chemotherapy and radiotherapy (CT/RT) vs CT/RT followed by surgical resection for stage IIIA(pN2) non-small cell lung cancer (NSCLC): outcomes update of North American Intergroup 0139 (RTOG 9309). 2005 ASCO Annual Meeting Proceedings. *J Clin Oncol* 2005; 23: 7014.
- Rusch VW, Giroux DJ, Kraut MJ et al. Induction chemoradiation and surgical resection for superior sulcus non-small-cell lung carcinomas: long-term results of Southwest Oncology Group Trial 9416 (Intergroup Trial 0160). *J Clin Oncol* 2007; 25: 313–8.
- Strand TE, Rostad H, Moller B et al. Survival after resection for primary lung cancer: a population based study of 3211 resected patients. *Thorax* 2006; 61: 710–5.
- Putnam JB Jr. Malignant pleural effusions. *Surg Clin North Am* 2002; 82: 867–83.
- Schiller JH, Harrington D, Belani CP et al. Comparison of four chemotherapy regimens for advanced non-small-cell lung cancer. *N Engl J Med* 2002; 346: 92–8.
- Sandler A, Gray R, Perry MC et al. Paclitaxel-carboplatin alone or with bevacizumab for non-small-cell lung cancer. *N Engl J Med* 2006; 355: 2542–50.
- The American Thoracic Society and The European Respiratory Society. Pretreatment evaluation of non-small-cell lung cancer. *Am J Respir Crit Care Med* 1997; 156: 320–32.
- Ost D, Fein AM, Feinsilver SH. Clinical practice. The solitary pulmonary nodule. *N Engl J Med* 2003; 348: 2535–42.
- Tan BB, Flaherty KR, Kazerooni EA et al. American College of Chest Physicians. The solitary pulmonary nodule. *Chest* 2003; 123 (1 Suppl): 89S–96S.
- Mountain CF. Revisions in the International System for Staging Lung Cancer. *Chest* 1997; 111: 1710–7.
- Mountain CF, Dressler CM. Regional lymph node classification for lung cancer staging. *Chest* 1997; 111: 1718–23.
- Naruke T, Tsuchiya R, Kondo H, Asamura H. Prognosis and survival after resection for bronchogenic carcinoma based on the 1997 TNM-staging classification: the Japanese experience. *Ann Thorac Surg* 2001; 71: 1759–64.
- Ettinger DS. The NCCN Clinical Practice Guidelines in Oncology: Non-Small Cell Lung Cancer. (Version 1.2007). National Comprehensive Cancer Network, Inc. <http://www.nccn.org> [Accessed 14 February 2007].
- Tolozza EM, Harpole L, Detterbeck F, McCrory DC. Invasive staging of non-small cell lung cancer: a review of the current evidence. *Chest* 2003; 123 (1 Suppl): 157S–66S.
- Rosell R, Gomez-Codina J, Camps C et al. A randomized trial comparing preoperative chemotherapy plus surgery with surgery alone in patients with non-small-cell lung cancer. *N Engl J Med* 1994; 330: 153–8.
- Roth JA, Fossella F, Komaki R et al. A randomized trial comparing perioperative chemotherapy and surgery with surgery alone in resectable stage IIIA non-small-cell lung cancer. *J Natl Cancer Inst* 1994; 87: 873–80.
- Silvestri GA, Tanoue LT, Margolis ML et al. American College of Chest Physicians. The noninvasive staging of non-small cell lung cancer: the guidelines. *Chest* 2003; 123 (1 Suppl): 147S–56S.
- Juweid ME, Cheson BD. Positron-emission tomography and assessment of cancer therapy. *N Engl J Med* 2006; 354: 496–507.
- Silvestri GA, Littenberg B, Colice GL. The clinical evaluation for detecting metastatic lung cancer. A meta-analysis. *Am J Respir Crit Care Med* 1995; 152: 225–30.
- van Tinteren H, Hoekstra OS, Smit EF et al. Effectiveness of positron emission tomography in the preoperative assessment of patients with suspected non-small-cell lung cancer: the PLUS multicentre randomised trial. *Lancet* 2002; 359: 1388–93.
- Bluman LG, Mosca L, Newman N et al. Preoperative smoking habits and postoperative pulmonary complications. *Chest* 1998; 113: 883–9.

35. Iizasa T, Suzuki M, Yasufuku K et al. Preoperative pulmonary function as a prognostic factor for stage I non-small cell lung carcinoma. *Ann Thorac Surg* 2004; 77: 1896–902.
36. British Thoracic Society, Society of Cardiothoracic Surgeons of Great Britain and Ireland Working Party. BTS guidelines: guidelines on the selection of patients with lung cancer for surgery. *Thorax* 2001; 56: 89–108.
37. Ginsberg RJ, Rubinstein LV. Randomized trial of lobectomy versus limited resection for T1 N0 non-small cell lung cancer. Lung Cancer Study Group. *Ann Thorac Surg* 1995; 60: 615–23.
38. Landreneau RJ, Sugarbaker DJ, Mack MJ et al. Wedge resection versus lobectomy for stage I (T1 N0 M0) non-small-cell lung cancer. *J Thor Cardiovasc Surg* 1997; 113: 691–8.
39. Smetana GW, Lawrence VA, Cornell JE. American College of Physicians. Preoperative pulmonary risk stratification for noncardiothoracic surgery: systematic review for the American College of Physicians. *Ann Intern Med* 2006; 144: 581–95.
40. Martin J, Ginsberg RJ, Abolhoda A et al. Morbidity and mortality after neoadjuvant therapy for lung cancer: the risks of right pneumonectomy. *Ann Thor Surg* 2001; 72: 1149–54.
41. Walsh GL, Morice RC, Putnam JBJ et al. Resection of lung cancer is justified in high-risk patients selected by exercise oxygen consumption. *Ann Thorac Surg* 1994; 58: 704–10.
42. Beckles MA, Spiro SG, Colice GL et al. American College of Chest Physicians. The physiologic evaluation of patients with lung cancer being considered for resectional surgery. *Chest* 2003; 123 (1 Suppl): 105S–14S.
43. Allen MS, Darling GE, Pechet TT et al. Morbidity and mortality of major pulmonary resections in patients with early stage lung cancer: initial results of the randomized, prospective ACOSOG Z0030 trial. *Ann Thor Surg* 2006; 81: 1013–20.
44. International Early Lung Cancer Action Program, Henschke CI, Yankelevitz DF et al. Survival of patients with stage I lung cancer detected on CT screening. *N Engl J Med* 2006; 355: 1763–71.
45. Watanabe T, Okada A, Imakiire T et al. Intentional limited resection for small peripheral lung cancer based on intraoperative pathologic exploration. *Jpn J Thor Cardiovasc Surg* 2005; 53: 29–35.
46. Bando T, Yamagihara K, Ohtake Y et al. A new method of segmental resection for primary lung cancer: intermediate results. *Eur J Cardiothorac Surg* 2002; 21: 894–9.
47. Fernando HC, Santos RS, Benfield JR et al. Lobar and sublobar resection with and without brachytherapy for small stage IA non-small cell lung cancer. *J Thorac Cardiovasc Surg* 2005; 129: 261–7.
48. McKenna RJ Jr, Houck W, Fuller CB. Video-assisted thoracic surgery lobectomy: experience with 1,100 cases. *Ann Thorac Surg* 2006; 81: 421–5.
49. Shennib H, Bogart J, Herndon JE et al. Video-assisted wedge resection and local radiotherapy for peripheral lung cancer in high-risk patients: the Cancer and Leukemia Group B (CALGB) 9335, a phase II, multi-institutional cooperative group study. *J Thorac Cardiovasc Surg* 2005; 129: 813–8.
50. Pasic A, Brokx HA, Vonk NA et al. Cost-effectiveness of early intervention: comparison between intraluminal bronchoscopic treatment and surgical resection for T1N0 lung cancer patients. *Respiration* 2004; 71: 391–6.
51. Rice DC, Kim HW, Smythe WR et al. The risk of second primary lung cancer after resection of stage I non small cell lung cancer. *Ann Thorac Surg* 2003; 76: 1001–8.
52. Brock MV, Alberg AJ, Hooker CM et al. Risk of subsequent primary neoplasms developing in lung cancer patients with prior malignancies. *J Thorac Cardiovasc Surg* 2004; 127: 1119–25.
53. Aziz TM, Saad RA, Glasser J et al. The management of second primary lung cancers. A single centre experience in 15 years. *Eur J Cardiothorac Surg* 2002; 21: 527–33.
54. Scott WJ, Howington J, Movsas B, American College of Chest Physicians. Treatment of stage II non-small cell lung cancer. *Chest* 2003; 123 (1 Suppl): 188S–201S.
55. Takeda S, Maeda H, Koma M et al. Comparison of surgical results after pneumonectomy and sleeve lobectomy for non-small cell lung cancer: trends over time and 20-year institutional experience. *Eur J Cardiothorac Surg* 2006; 29: 276–80.
56. Rendina EA, Venuta F, De GT et al. Sleeve resection after induction therapy. *Thor Surg Clin* 2004; 14: 191–7.
57. DeCamp MM Jr, Ashiku S, Thurmer R. The role of surgery in N2 non-small cell lung cancer. *Clin Cancer Res* 2005; 11: 5033S–7S.
58. Albain KS, Rusch VW, Crowley JJ et al. Concurrent cisplatin/etoposide plus chest radiotherapy followed by surgery for stages IIIA (N2) and IIIB non-small-cell lung cancer: mature results of Southwest Oncology Group phase II study 8805. *J Clin Oncol* 1995; 13: 1880–92.
59. Bueno R, Richards WG, Swanson SJ et al. Nodal stage after induction therapy for stage IIIA lung cancer determines patient survival. *Ann Thorac Surg* 2000; 70: 1826–31.
60. Cerfolio RJ, Bryant AS, Ojha B et al. Improving the inaccuracies of clinical staging of patients with NSCLC: a prospective trial. *Ann Thorac Surg* 2005; 80: 1207–13.
61. Battaferano RJ, Force SD, Meyers BF et al. Benefits of resection for metachronous lung cancer. *J Thorac Cardiovasc Surg* 2004; 127: 836–42.
62. Albain KS, Crowley JJ, Turrisi AT III et al. Concurrent cisplatin, etoposide, and chest radiotherapy in pathologic stage IIIB non-small-cell lung cancer: a Southwest Oncology Group phase II study, SWOG 9019. *J Clin Oncol* 2002; 20: 3454–60.
63. Hu C, Chang EL, Hassenbusch SJ III et al. Nonsmall cell lung cancer presenting with synchronous solitary brain metastasis. *Cancer* 2006; 106: 1998–2004.
64. Hunt I, Rankin SC, Lang-Lazdunski L. Combined lung resection and transdiaphragmatic adrenalectomy in patients with non-small cell lung cancer and homolateral solitary adrenal metastasis. *Eur J Cardiothorac Surg* 2006; 30: 194–5.
65. Yanagisawa K, Xu BJ, Carbone DP, Caprioli RM. Molecular fingerprinting in human lung cancer. *Clin Lung Cancer* 2003; 5: 113–8.
66. Massion PP, Carbone DP. From clinical and pathologic to molecular staging of lung cancer. *Am J Resp Crit Care Med* 2003; 167: 1587–8.
67. Potti A, Mukherjee S, Petersen R et al. A genomic strategy to refine prognosis in early-stage non-small-cell lung cancer. *N Engl J Med* 2006; 355: 570–80.
68. Fernando HC, De HA, Landreneau RJ et al. Radiofrequency ablation for the treatment of non-small cell lung cancer in marginal surgical candidates. *J Thorac Cardiovasc Surg* 2005; 129: 639–44.
69. Whyte RI, Crownover R, Murphy MJ et al. Stereotactic radiosurgery for lung tumors: preliminary report of a phase I trial. *Ann Thorac Surg* 2003; 75: 1097–101.

Joseph B Zwischenberger, Daina W Parker, Casey M Smólarz,  
Kristin Kucera and Brent C Parker

---

## BENIGN ESOPHAGEAL TUMORS AND CYSTS

Non-malignant neoplasms of the esophagus make up 0.5–0.8% of all esophageal tumors, with leiomyomas as the majority (60%), followed by cysts and polyps (20% and 5%, respectively)<sup>1,2</sup>.

### Leiomyomas

Leiomyomas are gastrointestinal stromal tumors (GISTs) of mesenchymal origin, and are the most frequently occurring mesenchymal neoplasms of the alimentary canal. They may be benign, of intermediate malignant potential, or malignant. Mutations of the *c-KIT* oncogene are thought to be primarily responsible for most GISTs. Leiomyomas occur usually in patients between 20 and 50 years of age, they affect both genders, are located in the middle and lower thirds of the esophagus, and rarely present as multiple lesions. Furthermore, they do not infiltrate the surrounding tissue but may grow large enough to impede upon other structures<sup>3</sup>.

### Diagnosis

Despite luminal infringement by the tumor, complaints of dysphagia, retrosternal pressure, or pain are found most often in patients with tumors larger than 5 cm, as the uninvolved esophagus is highly distensible. A distinctive appearance on esophagogram (Figure 10.1) often reveals a well-localized, non-circumferential mass with a smooth surface and identifiable margins. Leiomyomas are often discovered during endoscopy. Typical findings on endoscopic examination include intact mucosa, luminal narrowing and easy displacement of the mass. Biopsy samples should not be obtained in order to avoid formation of adhesions and ulcerations. Endoscopic ultrasound typically shows a hypoechoic lesion in the muscularis propria or submucosa.

### Treatment

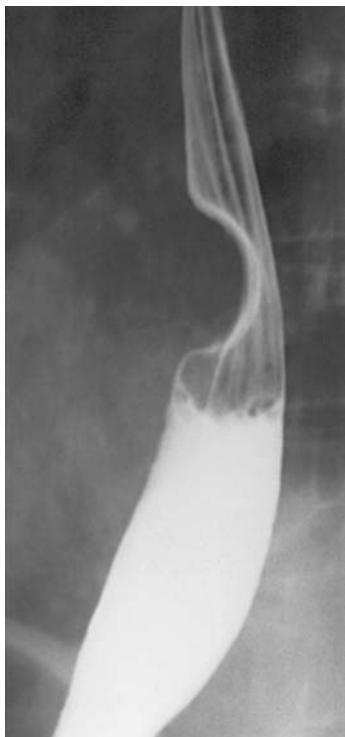Symptomatic leiomyomas or those that are larger than 5 cm should be excised (Figure 10.2). Smaller tumors require observation with yearly follow-up, as they have a very small risk of malignant conversion. However, the only absolute proof of their benign nature is removal. To remove tumors in the proximal third of the esophagus, a cervical incision is used. For lesions in the middle third, either a right thoracotomy or video-assisted thoracoscopic surgery (VATS) approach is used, and, finally, tumors in the distal third are approached from the left side. The tumor is located, and the overlying longitudinal esophageal muscle is split in the direction of its fibers, to reveal the mass. The tumor is then gently dissected away from contiguous tissues and the underlying submucosa. Once the tumor has been enucleated, the longitudinal muscle should be reapproximated if possible.

### Polyps

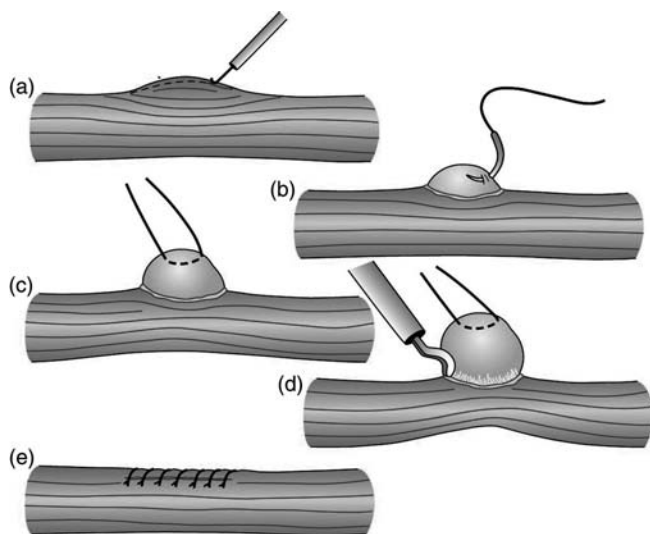
Cervical esophageal polyps are intraluminal growths generally covered with normal epithelium, and have a core of fibroelastic material. The polyp may be removed by endoscopic electrocoagulation, or resected under direct vision using a lateral cervical esophagomyotomy.

## ESOPHAGEAL CANCER

Esophageal cancer is the sixth most common malignancy worldwide. There are two main types, squamous cell carcinoma (SCC) and adenocarcinoma. SCC of the esophagus is most commonly found in African-Americans, while adenocarcinoma is more common in whites<sup>5</sup>. Unfortunately, most North American patients present with locally advanced (stage T3 and/or N1) disease, with lymphatic metastasis already present<sup>6</sup>. Within North America and Europe, the incidence of adenocarcinoma rose 100% in



**Figure 10.1** Esophagogram shows a typical leiomyoma.



**Figure 10.2** Operation for leiomyoma of the esophagus. (a) Incision of the muscle wall. (b) Dissection of the muscle wall. (c) A traction stitch placed through the tumor. (d) Separation of the tumor from the mucosa. (e) Closure of the myotomy. Adapted from reference 4, with permission.

the 1990s and strongly correlated with gastroesophageal reflux disease (GERD), Barrett's metaplasia and diets high in fat<sup>6</sup>.

### Risk factors

By far, the biggest risk factors for carcinoma of the esophagus are smoking and alcohol abuse. The combination

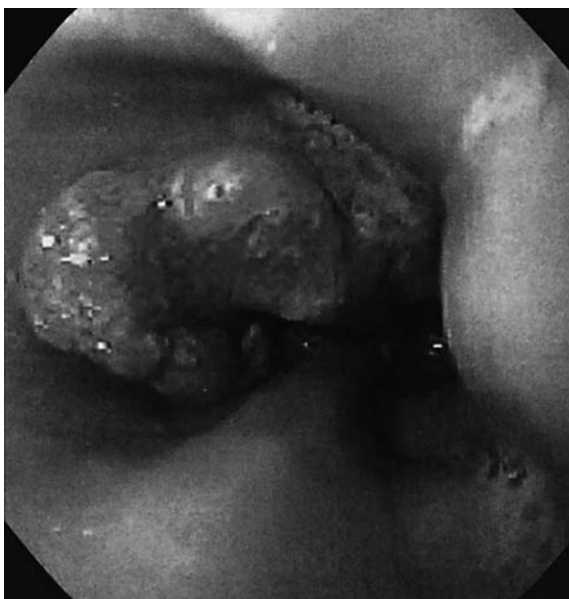of both can increase a patient's risk of SCC from 25- to 100-fold. An increased incidence of esophageal carcinoma is found in patients with familial keratosis palmaris et plantaris (tylosis). Other environmental and/or nutritional factors that have been incriminated include zinc or nitrosamine exposure, malnutrition, vitamin deficiencies, anemia, poor oral hygiene and dental caries, previous gastric surgery, and long-term ingestion of hot foods or beverages. Furthermore, the following esophageal insults may also increase a patient's risk for cancer: achalasia, reflux esophagitis, Barrett's esophagus<sup>7</sup>, radiation esophagitis<sup>8</sup>, caustic burns, Plummer-Vinson syndrome, leukoplakia, esophageal diverticula, and ectopic gastric mucosa.

### Characteristics and prognosis

Esophageal cancer, regardless of cell type, is aggressive for local growth and metastatic spread. Lack of an esophageal serosal layer favors local infiltration of surrounding tissue and adjacent lymph nodes, while the tumor tends to metastasize via the extensive submucosal lymphatics and blood supply. Cancers of the cervical esophagus drain to the deep cervical, paraesophageal, posterior mediastinal, and tracheobronchial lymph nodes and can infiltrate the tracheobronchial tree, aorta and left recurrent laryngeal nerve. Tumors affecting the distal third of the esophagus (including most esophageal adenocarcinomas) spread to paraesophageal, celiac and splenic hilar lymph nodes and may invade the diaphragm, pericardium, stomach, lungs, or liver. The extensive mediastinal lymphatic communication is responsible for the finding of mediastinal, supraclavicular, or celiac lymph node metastasis in at least 75% of patients with esophageal carcinoma.

Histologically, SCC accounts for approximately 95% of esophageal cancers worldwide. Located mainly in the thoracic esophagus, approximately 60% of these tumors are seen in the middle third and approximately 30% in the distal third. On gross pathology, SCCs can be grouped into four major categories: fungating, ulcerating, infiltrating, and polypoid<sup>9</sup>. Polypoid tumors have a 5-year survival rate of 70%, while the other three types have a 5-year survival of less than 15%<sup>10</sup>.

Currently, adenocarcinoma is the most common type of esophageal cancer in the US. It originates from the superficial and deep glands of the esophagus most frequently near the gastroesophageal junction (Figure 10.3). The ratio of whites to African-Americans with adenocarcinoma is 4 : 1, while the ratio of male : female is 8 : 1. The prognosis for patients with adenocarcinoma is largely dependent on tumor size<sup>12</sup>. Tumors less than 5 cm in diameter are localized 40% of the time, while 25% have spread beyond the esophagus, and 35% have metastasized or are unresectable. Conversely, when the tumor is larger than 5 cm, 10% are



**Figure 10.3** Adenocarcinoma of the esophagogastric junction. From reference 11, with permission.

localized, 15% have invaded mediastinal structures, and 75% have metastasized<sup>12</sup>.

## Diagnosis

Esophageal carcinoma may present with non-specific retrosternal discomfort, followed by dysphagia and weight loss (Table 10.1). Patients tend to present in later stages of the disease because usually two-thirds of the lumen must be obstructed to cause dysphagia. Patients frequently complain of food 'getting stuck' at the location of the lesion. Pain can be caused by spasms or contractions proximal to an obstruction, tumor invasion, interference with swallowing, or related to metastases in the surrounding esophageal lymph nodes. Because dysphagia is the chief complaint in 80–90% of patients with esophageal carcinoma<sup>15</sup>, any adult with symptoms should undergo esophagoscopy to rule out carcinoma. Likewise, esophagoscopy and biopsy are mandatory in every patient found to have esophageal stricture. Coughing and hoarseness are two other less common complaints and are usually associated with tumors of the cervical esophagus. As the tumor enlarges, esophageal obstruction results in progressive weight loss, regurgitation and aspiration. These factors contribute to the morbidity and mortality, regardless of the selected therapeutic regimen.

Various imaging techniques (chest X-ray, barium swallow, computed tomography (CT), and positron emission tomography (PET)) can determine the presence and extent of disease; however, the diagnosis of esophageal cancer is based upon esophageal biopsy. Plain chest X-ray is abnormal in only 50% of patients with esophageal cancer.

**Table 10.1** Clinical features of esophageal cancer

<i>Sign or symptom</i>	<i>Patients with symptom (%)</i>
Dysphagia	87–95
Weight loss	42–71
Vomiting or regurgitation	29–45
Pain	20–46
Cough or hoarseness	7–26
Dyspnea	5

From reference 13, with permission.

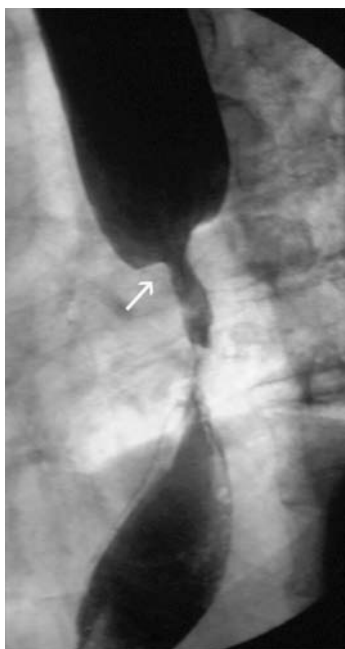
The abnormalities most commonly seen are an air-fluid level in the obstructed esophagus, a dilated esophagus, abnormal mediastinal soft tissue representing adenopathy, or tracheal deviation. Unfortunately, the chest X-ray may be normal even when the patient has advanced disease. Double-contrast barium swallow is used to determine tumor length and location. Advanced cancers present with luminal narrowing, ulceration and strictures, with an abrupt shelf-like proximal border (Figure 10.4). CT or endoscopic ultrasound may be used to identify the anatomic location and enlargement of the mediastinal, perigastric, or celiac lymph nodes. When used, contrast-enhanced CT scans should extend from the thoracic inlet to the liver, during full inspiration. Although magnetic resonance imaging (MRI) has not shown significant advantages over CT scan, recent studies show that T2-weighted MRI images are capable of showing seven layers of the esophagus. Further studies may reveal advantages of MRI compared with CT<sup>16</sup>.

Esophagoscopy, with subsequent brush cytology and tissue biopsy, is used to diagnose and determine the extent of longitudinal intramural tumor spread. The accuracy of brush cytology alone ranges from 85 to 97%, and biopsy alone ranges from 83 to 90%. When combined, they are more than 97% accurate<sup>16</sup>. If the depth of the tumor prevents diagnosis by biopsy or brush cytology, endoscopic ultrasound-guided fine-needle aspiration (FNA) should be used. Since the incidence of esophageal cancer is still relatively low in Western countries, early detection programs (i.e. mass screening with barium swallow, flexible fiber optic esophagoscopy, or exfoliative cytology) are not cost effective.

## Staging

Survival is closely correlated with the T and N stage, and celiac node involvement<sup>17</sup>. Stages of esophageal cancer are associated with 5-year survival rates of stage I 50–94%, stage II 15–65%, stage III 6–23%, and stage IV less than 5%, although reported stage IV survival varies (Table 10.2)<sup>18,19</sup>.





**Figure 10.4** Double-contrast barium swallow shows abrupt shouldered narrowing (arrow) at the transition between normal-appearing esophagus and the esophageal cancer.

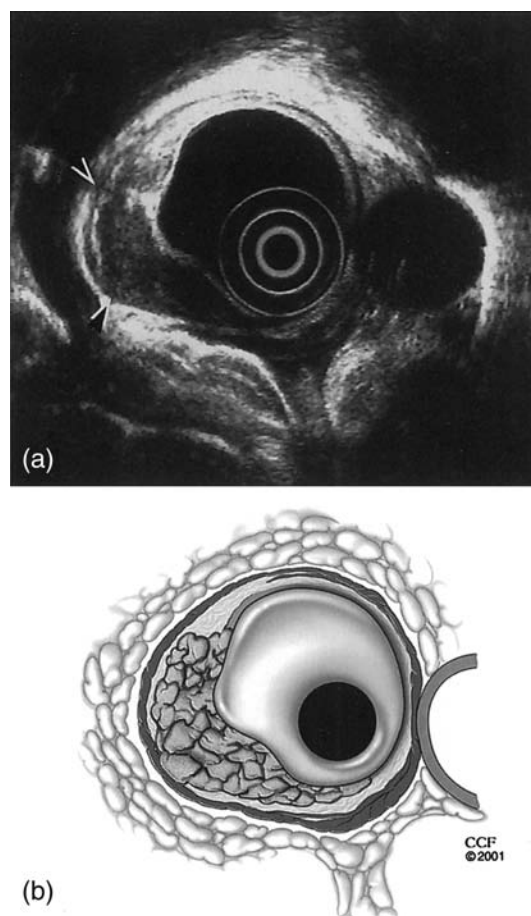
**Table 10.2** American Joint Committee on Cancer (AJCC) stage groupings for esophageal cancer

<i>AJCC stage</i>	<i>TNM grouping</i>
Stage 0	Tis, N0, M0
Stage I	T1, N0, M0
Stage IIA	T2, N0, M0; T3, N0, M0
Stage IIB	T1, N1, M0; T2, N1, M0
Stage III	T3, N1, M0; T4, any N, M0
Stage IV	Any T, any N, M1
Stage IVA	Any T, any N, M1a
Stage IVB	Any T, any N, M2a

T1 lesions are limited to the mucosa or submucosa. T2 lesions penetrate into the muscularis propria, but not beyond (Figure 10.5). T3 lesions penetrate the muscularis propria. T4 lesions invade locally into an adjacent structure, such as the aorta<sup>21</sup>. T4 cancers can be reliably identified by endoscopic ultrasound to prevent unnecessary surgical procedures while reducing associated morbidity and costs.

#### *Lymph nodes (N stage)*

Esophageal lymphatics are extensive and form a continuous network from the neck to the abdomen. Lymph node



**Figure 10.5** A T2 esophageal carcinoma. (a) A T2 tumor as seen by endoscopic ultrasound. The hypoechoic (black) tumor invades the hypoechoic (black) fourth ultrasound layer (muscularis propria) but does not breach the boundary between the fourth and fifth ultrasound layers (arrows). (b) A T2 tumor invades but does not breach the muscularis propria. From reference 20, with permission.

involvement may be assessed using endoscopic ultrasound, CT, PET, MRI, or VATS combined with laparoscopy (Table 10.3). Lymph nodes are considered malignant by endoscopic ultrasound when they are larger than 1 cm, hypoechoic with distinct margins, and are round in shape<sup>22</sup>. CT and endoscopic ultrasound imaging both rely on the anatomic size of the node to predict malignancy, but neither can differentiate between hyperplastic nodes and nodes enlarged due to metastasis. Cytological sampling of lymph nodes and PET are currently used to evaluate N status. Endoscopic ultrasound and CT are used for image-directed FNA of mediastinal or celiac nodes. A more invasive staging technique, when indicated, combines VATS with laparoscopy, and has a 90–94% accuracy.

Unfortunately, even patients with negative nodal involvement often have recurrent disease. A study by Aloia *et al.* utilized immunohistochemical analysis using multiple tumor markers in node-negative esophageal cancer patients and showed significant prognostic value of certain tumor markers (low-level P-gp expression, high-level expression

**Table 10.3** Accuracy of staging techniques

Modality	Accuracy (%)		
	T	N	M
Computed tomography	49–60	39–74	85–90
Endoscopic ultrasound	76–92	50–88	66–86
Magnetic resonance imaging	96	56–74	
Positron emission tomography		48–76	71–91
Thoracoscopy or laparoscopy		90–94	

From reference 13, with permission.

of p53, and low-level expression of transforming growth factor- $\alpha$  (TGF- $\alpha$ ) in predicting outcomes following esophagectomy. Genetic mapping does continue to show promise regarding risk stratification<sup>23</sup>.

#### *Distant metastasis (M stage)*

Endoscopic ultrasound is ideal for visualizing lymph nodes around the celiac axis and the left liver lobe; however, it cannot fully assess the extent of metastatic disease. It is the most accurate method for assessing locoregional disease, including depth of tumor invasion, length of tumor, degree of luminal stenosis, regional nodal disease, and involvement of adjacent structures. Endoscopic ultrasound has a reported accuracy of 80–92% for T stage and 45–100% for N stage<sup>24</sup>. CT is the most efficient screen for locoregional and distant metastatic disease. Although CT and MRI can detect mediastinal lymphadenopathy, mediastinal invasion and distant metastases<sup>25</sup>, FNA or transbronchial biopsy is necessary to document malignancy. Patients with tumors of the upper and middle third of the esophagus also require bronchoscopy to view the pharynx, larynx and tracheobronchial tree for synchronous and metachronous malignancies. Furthermore, if a patient complains of bone pain, a bone scan should be ordered to evaluate for bone metastases<sup>26</sup>.

The role of PET in esophageal cancer staging is evolving; uniquely, PET does not rely on anatomic or structural distortion for detecting malignancy. <sup>18</sup>F-fluorodeoxyglucose (FDG)-PET increases recognition of distant metastasis, with increased emission in areas of increased glucose metabolism, but provides poor overall anatomic detail<sup>27</sup>. The sensitivity of PET in evaluating distant metastases ranges from 67 to 88%, compared with 61–83% for CT. The specificity of PET ranges from 92 to 93%, compared with 71–75% for CT<sup>27–29</sup>. Postchemoradiotherapy FDG-PET was found to be predictive of pathological response and survival in patients who underwent preoperative

chemoradiotherapy<sup>30–32</sup>. Additional studies such as MRI, bone scan and staging mediastinoscopy are not performed routinely, and should be performed only if indicated based on the patient's complaints. MRI accurately detects T4 and metastatic disease, especially disease involving the liver; however, it tends to overstage lymph node involvement and is only 56–74% accurate in detecting lymph node involvement<sup>33–35</sup>. Comparing CT with MRI, the sensitivity and specificity for metastatic detection are almost equal, although CT scan is more cost-effective. Recent studies have found incremental increase in staging value of FDG-PET over CT scan, and some authors recommend PET-CT as the most effective preoperative staging technique<sup>23</sup>.

#### *Thoracoscopy and minimally invasive staging*

VATS enables the surgeon to evaluate the extent of disease because the entire thoracic cavity and esophagus can be visualized. In addition, lymph node biopsies may be taken as well<sup>34</sup>. Thoracoscopy can also visualize metastatic disease involving nearby or adjacent structures, such as the trachea, azygos vein, aorta, pericardium, and diaphragm. Krasna *et al.*<sup>36</sup> reported the sensitivity, specificity, and positive and negative predictive values to be 80%, 100%, 100%, and 88%, respectively, with an accuracy of 93% for the detection of thoracic lymph node involvement in patients with a primary esophageal tumor.

Abdominal laparoscopy is useful to determine whether the cancer has metastasized to the abdominal cavity. During this procedure, biopsies are taken from the celiac axis, the surface of the peritoneal cavity, the esophagogastric junction, and the liver<sup>37</sup>. Finally, laparoscopic ultrasound can visualize lymph nodes as small as 3 mm in diameter and helps to improve overall TNM staging accuracy.

### **Treatment**

Tumor stage determines whether therapy should be curative or palliative. Patients who have lower-stage tumors (stage T1 or T2N0M0) have acceptable surgical cure rates. Patients with more advanced tumors (T3 or N1) may require multimodality treatment as survival is less with surgery alone. Patients with T4 lesions with local invasion into surrounding vital structures and those with evidence of metastases should be treated palliatively.

#### *Curative approaches*

Early esophageal cancers are rare; however, when detected before invading beyond the mucosa and submucosa, less invasive methods of therapy may be used. Superficial esophageal cancers have been treated endoscopically by

mucosal resection, laser therapy, argon plasma coagulation, or photodynamic therapy.

Typically curative treatment for tumors staged higher than 'in situ' consists of a multimodality approach tailored to specific patient presentations. The multimodality approach is used because numerous reviews and clinical trials have failed to show that using any of the treatment options as a monotherapy decreases morbidity or mortality in patients with esophageal cancer. In patients with operable gastric or lower esophageal adenocarcinomas, a perioperative regimen of cisplatin, epirubicin, and fluorouracil has been reported to decrease tumor size and stage and significantly improve overall survival<sup>38</sup>.

However, there are many co-morbid factors that may decrease the likelihood of a patient tolerating a curative surgical procedure. These include heart disease, liver failure, metastatic disease, malnutrition, infection, multisystem dysfunction, or invasion of a vital structure.

Once the patient is accepted for surgery, there are four described techniques for esophagectomies. These include transhiatal, transthoracic, en bloc, and video-assisted approaches. It is noteworthy that no one technique has been shown to significantly decrease morbidity and mortality or increase survival rates. However, the majority of surgeons do agree that the tumor location, surgeon experience and co-morbidities should influence the surgical approach<sup>39</sup>. Transthoracic exposure is recommended for mid- and upper-esophageal tumors that are adherent to adjacent structures.

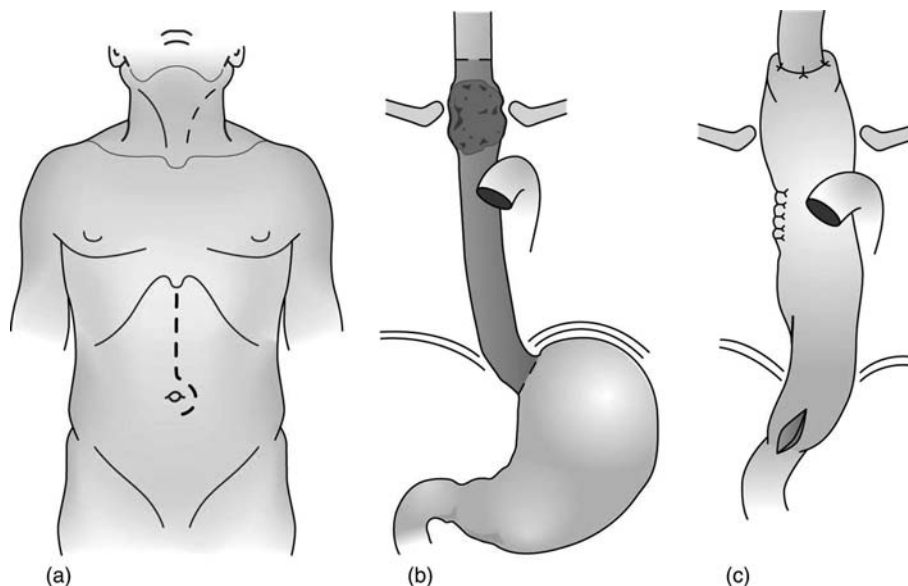
### Preoperative management

If the patient is malnourished and the esophageal obstruction is tight, endoscopic dilatation of the malignant

stricture and insertion of a nasogastric feeding tube or an intraluminal stent for enteral nutrition are performed to achieve an intake of approximately 2000 calories per day. Additionally total parenteral nutrition can be started for severe malnutrition. Some recommend a gastric feeding tube. Although expedient, a transabdominal gastric feeding tube can compromise the stomach for reconstruction. Abscessed or severely carious teeth should be removed or repaired preoperatively to minimize the infection risk. If the patient has a history of prior gastric operations that may preclude the use of the entire stomach as an esophageal substitute, a barium enema or colonoscopy should be performed to assess the suitability of the colon as an esophageal replacement. Furthermore, the patient should undergo appropriate bowel prep in the event that a colonic interposition is required.

### Transhiatal esophagectomy

Orringer *et al.*<sup>40,41</sup> developed the transhiatal esophagectomy without thoracotomy to avoid pulmonary and intrathoracic leak complications. During a transhiatal esophagectomy, the entire thoracic esophagus is resected via an enlarged hiatus and reconstructed by connecting the stomach to the residual cervical esophagus above the level of the clavicles (Figure 10.6). A recent review of the literature and subsequent meta-analysis has shown that no esophagectomy technique has proven superior. Transhiatal esophagectomies, however, result in significantly less blood loss when compared with the transthoracic approach<sup>43</sup>. Contraindications specific to the transhiatal approach include evidence of tumor invasion of the aorta, pericardium, and/or tracheobronchial tree<sup>44</sup>.



**Figure 10.6** Overview of transhiatal esophagectomy with gastric mobilization and gastric pull-up for cervical-esophagogastric anastomosis. Adapted from reference 42.

While the transhiatal approach results in fewer pulmonary complications versus transthoracic resections, it results in a higher rate of leaks at the cervical anastomosis. The majority of these leaks, however, are found with routine postoperative barium swallows and will resolve spontaneously or with drainage<sup>43</sup>. Because there are fewer risks associated with the transhiatal approach, some surgeons advocate its use regardless of tumor location if no local tumor invasion is anticipated.

### *Transthoracic esophagectomy*

Transthoracic esophagectomy allows complete lymph node dissection under direct vision, complete resection of tumor mass and adjacent tissue, but is associated with higher perioperative morbidity. The stomach is mobilized using a midline celiotomy and either a right thoracotomy (to approach proximal esophageal lesions) or a left thoracotomy (to approach distal lesions). Unfortunately, a combined thoracic and abdominal operation in a debilitated patient may lead to respiratory insufficiency that requires prolonged mechanical ventilatory assistance and increased mortality<sup>45,46</sup>. Although disruption of an intrathoracic esophageal anastomosis is reported less frequently than a cervical anastomotic leak from a transhiatal esophagectomy, the consequences, including mediastinitis and sepsis, are fatal in 50% of patients. An additional disadvantage of the intrathoracic esophageal anastomosis is inadequate long-term relief of dysphagia due to anastomotic suture-line tumor recurrence or the development of reflux esophagitis above the anastomosis. Finally, intrathoracic esophago-gastric anastomoses are almost invariably associated with the development of reflux esophagitis, due to disruption of the lower esophageal sphincter mechanism.

### *En bloc esophagectomy*

Because many patients present with metastases to regional lymph nodes and surrounding tissue and organs, a more radical resection, the en bloc esophagectomy, may be necessary. An envelope of normal tissue is removed, along with the spleen, celiac nodes, posterior pericardium, azygos vein, thoracic duct, and adjacent diaphragm. With this aggressive surgery, operative mortality ranges from 5.1 to 11%<sup>47</sup>. The two major complications contributing to mortality again include anastomotic leak and respiratory complications.

### *Thoracoscopic esophagectomy*

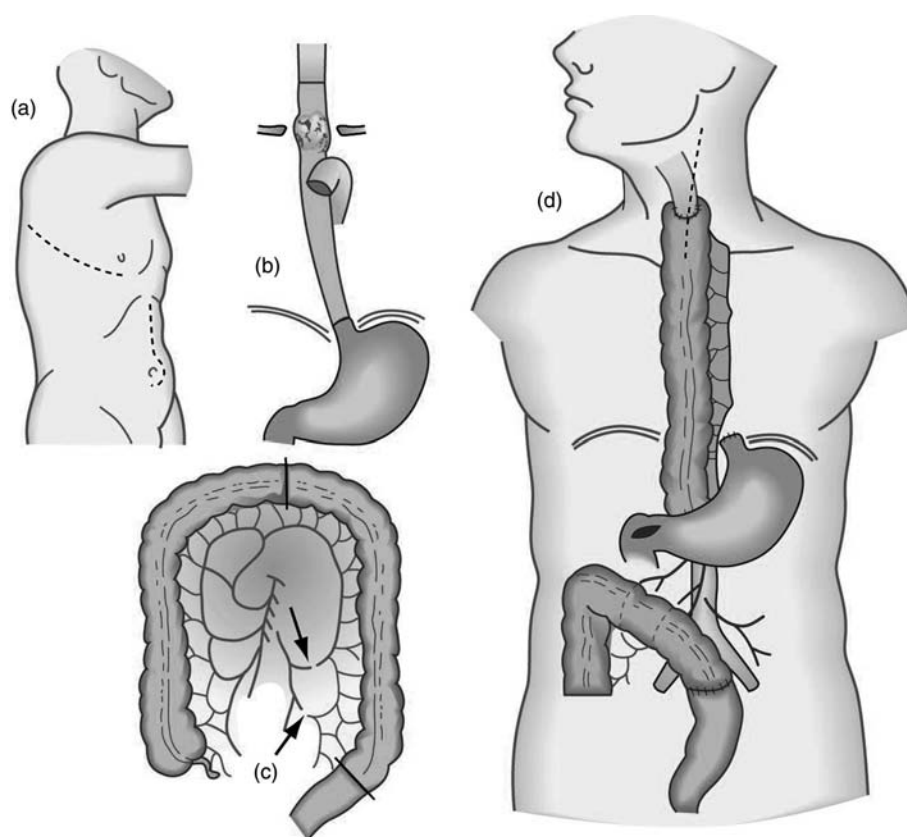
Several authors have reported the use of VATS or laparoscopy in performing esophagectomies<sup>48-52</sup>. Techniques described include standard laparotomy with thoracoscopic

mobilization of the esophagus, laparoscopic transhiatal technique, laparoscopic gastric mobilization with a right mini-thoracotomy, and thoracoscopic mobilization of the esophagus followed by laparoscopic gastric mobilization<sup>49,53</sup>. The success of thoracoscopic esophagectomy is highly dependent on the experience of the surgeon, and no current technique is considered standard. Thoracoscopic esophagectomy has not been shown to reduce the length of hospitalization or complications when compared with open surgical procedures.

### *Reconstruction after esophagectomy*

After a portion, or all, of the esophagus is removed, a conduit must be established for alimentary continuity. The most direct route for the conduit of reconstruction is the posterior mediastinum in the prevertebral space created by the resected esophagus. Most surgeons prefer the stomach for reconstruction but alternatives include the colon and roux-en-Y loop of the jejunum<sup>54-57</sup> (Figure 10.7). The stomach is the conduit of choice because of ease in mobilization and ample vascular supply. A higher incidence of mortality is noted with the use of the colon because of the necessity for three anastomoses (coloesophagostomy, colojejuno-stomy and colocolostomy). The colon is used if the patient has undergone a partial or total gastrectomy previously, or if the tumor involves the stomach to preclude a 5-cm margin (Figure 10.8). Jejunal loops can also be used, but their limited vascular supply restricts mobility and length. Once reconstructed, some surgeons advocate placing the neoesophagus in a substernal position to reduce the likelihood of a local recurrence that causes obstruction.

Carcinomas involving the cervicothoracic esophagus (and frequently the larynx), either primarily or secondarily, pose unique problems for esophageal reconstruction after laryngopharyngectomy. Concomitant radical neck dissection is often required because of regional lymph node involvement. Resection of tumors that involve the high retrosternal trachea is facilitated by removal of the anterior breast plate and construction of a mediastinal tracheostomy<sup>59,60</sup>. Replacement of the pharynx and cervical esophagus is possible with skin tubes, myocutaneous flaps and isolated segments of jejunum anastomosed to a cervical and venous blood supply using microvascular techniques. These operations, however, are frequently multistaged, prolonged and technically difficult<sup>61-63</sup>. Laryngopharyngectomy for cervicothoracic tumors and concomitant transhiatal esophagectomy without thoracotomy provide the maximum distal esophageal margin beyond the tumor and permit restoration of continuity of the alimentary tract. A colon interposition is often recommended for restoring alimentary continuity in this situation, as regurgitation



**Figure 10.7** Esophagectomy with interposition of antiperistaltic segment of left colon. (a) Incisions used in performance of esophagectomy, cervical esophagostomy, pyloromyotomy, and gastrostomy. (b) Extent of esophageal resection. (c) Preparation of segment of left colon for interposition based on middle colic artery (note sites of vascular interruption (arrows), which maintain the integrity of the vascular arcade). (d) Completed operation. Adapted from reference 42.

after a pharyngogastric anastomosis gives a less satisfactory functional result. The risks and benefits of such large resections must be assessed in each patient.

### Multimodality therapy

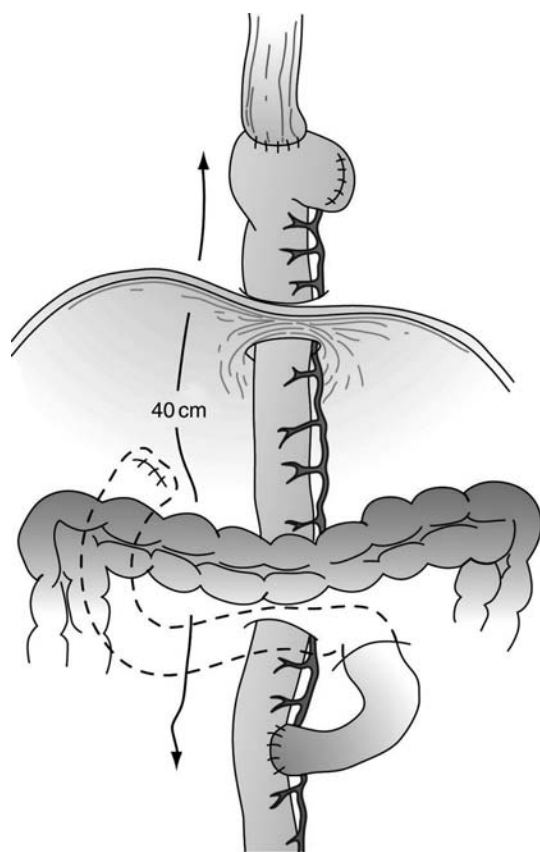
In general, radiation therapy alone should be reserved for palliation or for patients who are medically unable to tolerate surgery and/or chemotherapy<sup>64</sup>. Radiation therapy has low morbidity and can improve esophageal obstruction in most patients within 4–7 days. Relief of dysphagia, however, is short-lived and recurrence is usually seen within 6 months<sup>65</sup>. The field typically includes a 5-cm margin above and below the tumor, a 2-cm radial margin and adjacent lymph node stations. The supraclavicular or celiac lymph nodes are targets if the tumor is in the proximal or distal esophagus, respectively. Radiation therapy is contraindicated in the presence of a transesophageal fistula (TEF). Radiation necrosis of the tumor promotes fistula formation when the tumor has penetrated the trachea or bronchus.

The Radiation Therapy Oncology Group (RTOG) compared radiation alone (64 Gy) with radiation (50 Gy) plus concurrent chemotherapy (fluorouracil and cisplatin).

The results of this study revealed that the chemoradiation regimen showed significant improvement in locoregional control over radiation alone, even at a lower radiation dose<sup>66</sup>. This marked the end of using radiation therapy alone as treatment for esophageal cancers except in patients whose tumor is unresectable or who are unable to tolerate chemotherapy.

The subsequent RTOG protocol intensified the chemotherapy component and divided the patients into two groups, one receiving the standard 50.4 Gy radiation dose, and the other receiving a high dose of 64.8 Gy. The results of this study demonstrated that the higher radiation dose did not increase survival or locoregional control<sup>67</sup>. Consequently, radiation in the treatment of esophageal cancer has been in combination with concurrent chemotherapy and delivered to a dose of 50.4 Gy. Investigation into hyperfractionated delivery of the radiation has not been shown to improve patient outcome, and may, in fact, lead to increased complications.

The goal of postoperative radiation therapy is to destroy residual malignant cells after surgical resection, especially if positive tumor margins are discovered. A recent prospective randomized study comparing surgery alone to surgery plus postoperative radiotherapy (50–60 Gy) showed



**Figure 10.8** Roux-en-Y reconstruction of the distal esophagus after distal esophagectomy and total gastrectomy for tumor involving the cardia of the stomach. Adapted from reference 58.

significantly improved survival in patients with stage III tumors who underwent surgery and radiation<sup>68</sup>. Others suggest that postoperative radiation therapy is effective in reducing recurrences in patients after resection, but does not improve overall survival<sup>69,70</sup>.

The most recent study comparing multimodality therapy with surgery alone found that the multimodality treatment regimens provided better outcomes. The Cancer and Leukemia Group B (CALGB) carried out a prospective

study that compared triple therapy (radiation, chemotherapy and surgery) with surgery alone in stage I–III cancers. The results of this study demonstrated that the triple therapy regimen significantly improved survival when compared with surgery alone. The 5-year survival rate was 39% for triple therapy and 16% with surgery alone<sup>71</sup>.

A study by Wang *et al.*<sup>72</sup> indicates that the volume of lung spared from doses of 5 Gy or higher was found to be the only independent predictive factor associated with postoperative pulmonary complications for esophageal cancer patients treated with concurrent chemoradiotherapy followed by surgery. The use of intensity modulated radiation therapy (IMRT) allows for improved conformation of the delivered dose distribution around the tumor. Chandra *et al.*<sup>73</sup> have provided data demonstrating that the use of IMRT can reduce lung damage in treatment of distal esophageal cancer. Complications from radiation therapy can include pneumonitis, pericarditis, myocarditis, stricture, fistula formation, and spinal cord damage<sup>74</sup>.

### Palliative treatment

Palliative therapy is appropriate when patients are too debilitated to undergo resection or the tumor is unresectable because of extensive invasion of vital structures, recurrence, and/or metastases. The goals of palliation include relief of dysphagia and discomfort, improvement of nutritional intake, and limiting hospitalization. Depending on the predicted life expectancy, palliation may include dilation, intubation, photodynamic therapy, radiotherapy, chemoradiotherapy, surgical bypass, and/or laser therapy. No single treatment method has proved superior and when successful, mean survival is 140 days<sup>75</sup>. When palliative treatments are unsuccessful, a feeding tube may be placed to provide adequate nutrition or in rare cases, a palliative esophagectomy can be performed. Quality of life and prognosis must be in mind when choosing a palliative treatment as some are invasive and uncomfortable.

## REFERENCES

1. Postlethwait RW, Lowe JE. Benign tumors and cysts of the esophagus. In: Orringer MB, Zuidema GD, eds. Shackelford's Surgery of the Alimentary Tract, 4th edn. Philadelphia: WB Saunders, 1996.
2. Shamji F, Todd TR. Benign tumors. In: Pearson FG, Cooper JD, Deslauriers J et al. eds. Esophageal Surgery, 2nd edn. Philadelphia: Churchill Livingstone, 2002: 636–48.
3. Seremetis MG, Lyons WS, deGuzman VC, Peabody JW Jr. Leiomyomata of the esophagus. An analysis of 838 cases. *Cancer* 1976; 38: 2166–77.
4. Lerut T. Thoracoscopic esophageal surgery. In: Baue AE, Geha AS, Hammond GL et al. eds. Glenn's Thoracic and Cardiovascular Surgery, 6th edn. Norwalk, CT: Appleton & Lange, 1996; 1: 867.
5. American Cancer Society. [www.cancer.org](http://www.cancer.org) [Accessed 7 March 2006].
6. Lagergren J, Bergstrom R, Lindgren A et al. Symptomatic gastroesophageal reflux as a risk factor for esophageal adenocarcinoma. *N Engl J Med* 1999; 340: 825–31.
7. Sarr MG, Hamilton SR, Marrone GC et al. Barrett's esophagus: its prevalence and association with adenocarcinoma in patients with symptoms of gastroesophageal reflux. *Am J Surg* 1985; 149: 187–93.
8. Sherrill DJ, Grishkin BA, Galal FS et al. Radiation associated malignancies of the esophagus. *Cancer* 1984; 54: 726–8.

9. Previtera C, Giusti F, Guglielmi M. Predictive value of visible lesions (cheeks, lips, oropharynx) in suspected caustic ingestion: may endoscopy reasonably be omitted in completely negative pediatric patients? *Pediatr Emerg Care* 1990; 6: 176–8.
10. Sasajima K, Takai A, Taniguchi Y et al. Polypoid squamous cell carcinoma of the esophagus. *Cancer* 1989; 64: 94–7.
11. Rice TW, Zuccaro G Jr. Flexible esophagoscopy. In: Pearson FG, Cooper JD, Deslauriers J et al. eds. *Esophageal Surgery*, 2nd edn. Philadelphia: Churchill Livingstone, 2002: 153.
12. Takagi I, Karasawa K. Growth of squamous cell esophageal carcinoma observed by serial esophagographies. *J Surg Oncol* 1982; 21: 57–60.
13. Zwischenberger JB et al. Esophagus. In: Townsend CM Jr, Beauchamp RD, Evers BM, Mattox KL, eds. *Sabiston Textbook of Surgery*, 17th edn. Philadelphia: Elsevier, 2004: 1120, 1123.
14. Riddell RH. Dysplasia and regression in Barrett's epithelium. In: Spechler SJ, Goyal RK, eds. *Barrett's Esophagus: Pathophysiology, Diagnosis, and Management*. New York: Elsevier; 1985: 143–53.
15. Ferguson MK, Skinner DB. Carcinoma of the esophagus and cardia. In: Orringer MG, Zuidema GD, eds. *Shackelford's Surgery of the Alimentary Tract*. 4th ed. Philadelphia: W.B. Saunders; 1990: 305–32.
16. Meyer GW, Castell DO. In support of the clinical usefulness of lower esophageal sphincter pressure determination. *Dig Dis Sci* 1981; 26: 1028–31.
17. Pfau PR, Ginsberg GG, Lew RJ et al. EUS predictors of long-term survival in esophageal carcinoma. *Gastrointest Endosc* 2001; 53: 463–9.
18. Ellis FH, Jr. Treatment of carcinoma of the esophagus or cardia. *Mayo Clin Proc* 1989; 64: 945–55.
19. Hagen JA, DeMeester SR, Peters JH et al. Curative resection for esophageal adenocarcinoma: analysis of 100 en bloc esophagectomies. *Ann Surg* 2001; 234: 520–31.
20. Rice TW, Zuccaro G Jr. Endoscopic esophageal ultrasound. In: Pearson FG, Cooper JD, Deslauriers J et al. *Esophageal Surgery*, 2nd edn. Philadelphia: Churchill Livingstone, 2002: 688.
21. Vickers J. Role of endoscopic ultrasound in the preoperative assessment of patients with oesophageal cancer. *Ann R Coll Surg Engl* 1998; 80: 233–9.
22. Parmar KS, Zwischenberger JB, Reeves AL et al. Clinical impact of endoscopic ultrasound-guided fine needle aspiration of celiac axis lymph nodes (M1a disease) in esophageal cancer. *Ann Thorac Surg* 2002; 73: 916–21.
23. Aloia TA, Harpole DH Jr, Reed CE et al. Tumor marker expression is predictive of survival in patients with esophageal cancer. *Ann Thorac Surg* 2001; 72: 859–66.
24. Patel AN, Preskitt JT, Kuhn JA et al. Surgical management of esophageal carcinoma. *Proc (Bayl Univ Med Cent)* 2003; 16: 280–4.
25. Kumbasar B. Carcinoma of esophagus: radiologic diagnosis and staging. *Eur J Radiol* 2002; 42: 170–80.
26. Halvorsen RA Jr, Thompson WM. Primary neoplasms of the hollow organs of the gastrointestinal tract. Staging and follow-up. *Cancer* 1991; 67: 1181–8.
27. Luketich JD, Schauer PR, Meltzer CC et al. Role of positron emission tomography in staging esophageal cancer. *Ann Thorac Surg* 1997; 64: 765–9.
28. Flanagan FL, Dehdashti F, Siegel BA et al. Staging of esophageal cancer with 18F-fluorodeoxyglucose positron emission tomography. *AJR Am J Roentgenol* 1997; 168: 417–24.
29. Wren SM, Stijns P, Srinivas S. Positron emission tomography in the initial staging of esophageal cancer. *Arch Surg* 2002; 137: 1001–7.
30. Swisher SG, Maish M, Erasmus JJ et al. Utility OF PET, CT, and EUS to identify pathologic responders in esophageal cancer. *Ann Thorac Surg* 2004; 78: 1152–60.
31. Downey RJ, Akhurst T, Ilson D et al. Whole body 18FDG-PET and the response of esophageal cancer to induction therapy: results of a prospective trial. *J Clin Oncol* 2003; 21: 428–32.
32. Flamen P, Van Cutsem E, Lerut A et al. Positron emission tomography for assessment of the response to induction radiochemotherapy in locally advanced oesophageal cancer. *Ann Oncol* 2002; 13: 361–8.
33. Krasna MJ, McLaughlin JS. Thoracoscopic lymph node staging for esophageal cancer. *Ann Thorac Surg* 1993; 56: 671–4.
34. Krasna MJ, Reed CE, Jaklitsch MT et al. Thoracoscopic staging of esophageal cancer: a prospective, multiinstitutional trial. *Cancer and Leukemia Group B Thoracic Surgeons. Ann Thorac Surg* 1995; 60: 1337–40.
35. Petrillo R, Balzarini L, Bidoli P et al. Esophageal squamous cell carcinoma: MRI evaluation of mediastinum. *Gastrointest Radiol* 1990; 15: 275–8.
36. Krasna MJ, Reed CE, Nedzwiecki D et al. CALGB 9380: a prospective trial of the feasibility of thoracoscopy/laparoscopy in staging esophageal cancer. *Ann Thorac Surg* 2001; 71: 1073–9.
37. Krasna MJ. The role of thoracoscopic lymph node staging in esophageal cancer. *Int Surg* 1997; 82: 7–11.
38. Cunningham D, Allum WH, Stenning SP et al. Perioperative chemotherapy versus surgery alone for resectable gastroesophageal cancer. *N Engl J Med* 2006; 355: 11–20.
39. Bousamra M 2nd, Haasler GB, Parviz M. A decade of experience with transthoracic and transhiatal esophagectomy. *Am J Surg* 2002; 183: 162–7.
40. Orringer MB. Transhiatal esophagectomy without thoracotomy for carcinoma of the esophagus. *Adv Surg* 1986; 19: 1–49.
41. Orringer MB, Sloan H. Esophagectomy without thoracotomy. *J Thorac Cardiovasc Surg* 1978; 76: 643–54.
42. Ellis FH Jr. Esophagogastrectomy for carcinoma: technical considerations based on anatomic location of lesion. *Surg Clin North Am* 1980; 60: 265–79.
43. Hulscher JB, Tijssen JG, Obertop H et al. Transthoracic versus transhiatal resection for carcinoma of the esophagus: a meta-analysis. *Ann Thorac Surg* 2001; 72: 306–13.
44. Pac M, Basoglu A, Kocak H et al. Transhiatal versus transthoracic esophagectomy for esophageal cancer. *J Thorac Cardiovasc Surg* 1993; 106: 205–9.
45. Fok M, Law SY, Wong J. Operable esophageal carcinoma: current results from Hong Kong. *World J Surg* 1994; 18: 355–60.
46. Savage C, McQuitty C, Wang D et al. Postthoracotomy pain management. *Chest Surg Clin North Am* 2002; 12: 251–63.
47. Anderson KD, Rouse TM, Randolph JG. A controlled trial of corticosteroids in children with corrosive injury of the esophagus. *N Engl J Med* 1990; 323: 637–40.
48. Jagot P, Sauvanet A, Berthouix L, Belghiti J. Laparoscopic mobilization of the stomach for oesophageal replacement. *Br J Surg* 1996; 83: 540–2.
49. Luketich JD, Schauer PR, Christie NA et al. Minimally invasive esophagectomy. *Ann Thorac Surg* 2000; 70: 906–12.
50. Dexter SP, Martin IG, McMahon MJ. Radical thoracoscopic esophagectomy for cancer. *Surg Endosc* 1996; 10: 147–51.
51. Law S, Fok M, Chu KM, Wong J. Thoracoscopic esophagectomy for esophageal cancer. *Surgery* 1997; 122: 8–14.
52. Robertson GS, Lloyd DM, Wicks AC, Veitch PS. No obvious advantages for thoracoscopic two-stage oesophagectomy. *Br J Surg* 1996; 83: 675–8.
53. Nguyen NT, Schauer PR, Luketich JD. Combined laparoscopic and thoracoscopic approach to esophagectomy. *J Am Coll Surg* 1999; 188: 328–32.

54. Kirk RM. A trial of total gastrectomy, combined with total thoracic oesophagectomy without formal thoracotomy, for carcinoma at or near the cardia of the stomach. *Br J Surg* 1981; 68: 577–9.
55. Ikeda Y, Tobari S, Niimi M et al. Reliable cervical anastomosis through the retrosternal route with stepwise gastric tube. *J Thorac Cardiovasc Surg* 2003; 125: 1306–12.
56. Davis PA, Law S, Wong J. Colonic interposition after esophagectomy for cancer. *Arch Surg* 2003; 138: 303–8.
57. Young MM, Deschamps C, Trastek VF et al. Esophageal reconstruction for benign disease: early morbidity, mortality, and functional results. *Ann Thorac Surg* 2000; 70: 1651–5.
58. Akiyama H. Total gastrectomy and Roux-en-Y reconstruction. In: Pearson FG, Deslauriers J, Ginsberg RJ et al. eds. *Esophageal Surgery*. New York: Churchill Livingstone, 1995: 736.
59. Orringer MB. Partial median sternotomy: anterior approach to the upper thoracic esophagus. *J Thorac Cardiovasc Surg* 1984; 87: 124–9.
60. Grillo HC, Mathisen DJ. Cervical exenteration. *Ann Thorac Surg* 1990; 49: 401–9.
61. Chen HC, Kuo YR, Hwang TL et al. Microvascular prefabricated free skin flaps for esophageal reconstruction in difficult patients. *Ann Thorac Surg* 1999; 67: 911–6.
62. Spriano G, Pellini R, Roselli R. Pectoralis major myocutaneous flap for hypopharyngeal reconstruction. *Plast Reconstr Surg* 2002; 110: 1408–16.
63. Wadsworth JT, Futran N, Eubanks TR. Laparoscopic harvest of the jejunal free flap for reconstruction of hypopharyngeal and cervical esophageal defects. *Arch Otolaryngol Head Neck Surg* 2002; 128: 1384–7.
64. Minsky BD. Combined modality therapy for esophageal cancer. *Semin Oncol* 2003; 30: 46–55.
65. Hishikawa Y, Kurisu K, Taniguchi M et al. High-dose-rate intraluminal brachytherapy (HDRIBT) for esophageal cancer. *Int J Radiat Oncol Biol Phys* 1991; 21: 1133–5.
66. Cooper JS, Guo MD, Herskovic A et al. Chemoradiotherapy of locally advanced esophageal cancer: long-term follow-up of a prospective randomized trial (RTOG 85-01). *Radiation Therapy Oncology Group. JAMA* 1999; 281: 1623–7.
67. Minsky BD, Pajak TF, Ginsberg RJ et al. INT 0123 (Radiation Therapy Oncology Group 94-05) phase III trial of combined-modality therapy for esophageal cancer: high-dose versus standard-dose radiation therapy. *J Clin Oncol* 2002; 20: 1167–74.
68. Xiao ZF, Yang ZY, Liang J et al. Value of radiotherapy after radical surgery for esophageal carcinoma: a report of 495 patients. *Ann Thorac Surg* 2003; 75: 331–6.
69. Teniere P, Hay JM, Fingerhut A et al. Postoperative radiation therapy does not increase survival after curative resection for squamous cell carcinoma of the middle and lower esophagus as shown by a multicenter controlled trial. *French University Association for Surgical Research. Surg Gynecol Obstet* 1991; 173: 123–30.
70. Nishimura Y, Ono K, Imamura M et al. Postoperative radiation therapy for esophageal cancer. *Radiat Med* 1989; 7: 88–94.
71. Krasna M, Tepper JE, Niedzwiecki D et al. Trimodality therapy is superior to surgery alone in esophageal cancer: results of CALGB 9781. Abstract presented at American Society of Clinical Oncology: *Advances in the Treatment of Esophageal and Gastric Cancers*; 2006; 2006.
72. Wang SL, Liao Z, Vaporciyan AA et al. Investigation of clinical and dosimetric factors associated with postoperative pulmonary complications in esophageal cancer patients treated with concurrent chemoradiotherapy followed by surgery. *Int J Radiat Oncol Biol Phys* 2006; 64: 692–9.
73. Chandra A, Guerrero TM, Liu HH et al. Feasibility of using intensity-modulated radiotherapy to improve lung sparing in treatment planning for distal esophageal cancer. *Radiother Oncol* 2005; 77: 247–53.
74. O'Rourke IC, Tiver K, Bull C et al. Swallowing performance after radiation therapy for carcinoma of the esophagus. *Cancer* 1988; 61: 2022–6.
75. Gee DW, Rattner DW. Management of gastroesophageal tumors. *Oncologist* 2007; 12: 175–85.

## Other useful references

- Akiyama H, Tsurumaru M, Udagawa H, Kajiyama Y. Radical lymph node dissection for cancer of the thoracic esophagus. *Ann Surg* 1994; 220: 364–73.
- Corti L, Skarlatos J, Boso C et al. Outcome of patients receiving photodynamic therapy for early esophageal cancer. *Int J Radiat Oncol Biol Phys* 2000; 47: 419–24.
- Meunier B, Spiliopoulos Y, Stasik C et al. Retrosternal bypass operation for unresectable squamous cell cancer of the esophagus. *Ann Thorac Surg* 1996; 62: 373–7.
- Conlan AA, Nicolaou N, Hammond CA et al. Retrosternal gastric bypass for inoperable esophageal cancer: a report of 71 patients. *Ann Thorac Surg* 1983; 36: 396–401.
- Spechler SJ. Clinical practice. Barrett's Esophagus. *N Engl J Med* 2002; 346: 836–42.
- Sampliner RE. Practice guidelines on the diagnosis, surveillance, and therapy of Barrett's esophagus. The Practice Parameters Committee of the American College of Gastroenterology. *Am J Gastroenterol* 1998; 93: 1028–32.
- Cameron AJ. Epidemiology of columnar-lined esophagus and adenocarcinoma. *Gastroenterol Clin North Am* 1997; 26: 487–94.
- Hirota WK, Loughney TM, Lazas DJ et al. Specialized intestinal metaplasia, dysplasia, and cancer of the esophagus and esophago-gastric junction: prevalence and clinical data. *Gastroenterology* 1999; 116: 277–85.
- Oberg S, DeMeester TR, Peters JH et al. The extent of Barrett's esophagus depends on the status of the lower esophageal sphincter and the degree of esophageal acid exposure. *J Thorac Cardiovasc Surg* 1999; 117: 572–80.
- Skacel M, Petras RE, Gramlich TL et al. The diagnosis of low-grade dysplasia in Barrett's esophagus and its implications for disease progression. *Am J Gastroenterol* 2000; 95: 3383–7.
- Weston AP, Sharma P, Topalovski M et al. Long-term follow-up of Barrett's high-grade dysplasia. *Am J Gastroenterol* 2000; 95: 1888–93.
- Peters JH, Clark GW, Ireland AP et al. Outcome of adenocarcinoma arising in Barrett's esophagus in endoscopically surveyed and nonsurveyed patients. *J Thorac Cardiovasc Surg* 1994; 108: 813–22.
- Wright TA. High-grade dysplasia in Barrett's oesophagus. *Br J Surg* 1997; 84: 760–6.
- Poneros JM, Brand S, Bouma BE et al. Diagnosis of specialized intestinal metaplasia by optical coherence tomography. *Gastroenterology* 2001; 120: 7–12.
- Wang KK. Current Strategies in the Management of Barrett's Esophagus. *Current Gastroenterology Reports* 2005; 7: 196–201.
- Csendes A, Braghetto I, Burdiles P et al. Comparison of forceful dilatation and esophagomyotomy in patients with achalasia of the esophagus. *Hepatogastroenterology* 1991; 38: 502–5.
- Ganz RA, Utley DS, Stern RA et al. Complete ablation of esophageal epithelium with a balloon-based bipolar electrode: a phased evaluation in the porcine and in the human esophagus. *Gastrointest Endosc* 2004; 60: 1002–10.





# Screen-detected breast cancer

Emiel J T Rutgers

## INTRODUCTION

Despite debates about the quality and validity of the randomized trials on breast cancer screening<sup>1,2</sup>, it is generally accepted that mammography screening will lead to a breast cancer related mortality reduction of about 15% (10–30%) in the screened population<sup>3</sup>. Screen-detected breast cancers are usually smaller, lower grade and less frequently associated with lymph node involvement as compared with clinically detected breast cancers, resulting in better survival rates. Even in comparable stages, screen-detected breast cancers appear to have a better outcome than non-screen-detected cancers<sup>4–8</sup>. Furthermore, about 15–20% of screen-detected breast cancers are *in situ* carcinomas, predominantly ductal carcinoma *in situ* (DCIS)<sup>9,10</sup>. It is suggested that screening-detected breast cancers have different biology. Interval cancers do have much more similar clinicopathological features and consequently biological behavior to clinically detected breast cancers as compared with screening-detected cancers<sup>11</sup>.

The outcome of the treatment of screening-detected breast cancers could be measured by the cosmetic result (number of breast conserving therapies versus mastectomies), by the locoregional relapse rate and finally and most importantly by the breast cancer related survival. These outcomes very much depend on the adequacy of the diagnostic process and consequently the local, regional and systemic adjuvant treatments. Particularly in screen-detected breast cancer this process is best secured in a multidisciplinary breast unit<sup>12,13</sup>.

## INCIDENCE

Worldwide the breast cancer incidence is rising, with the highest incidences in north western Europe and northern America<sup>14</sup>. In northern America the standardized incidence (rate per 100 000 persons and age adjusted to the 2000 US standard population using 19 age groups) of breast cancer is about 132<sup>15</sup>. Incidence rates are increasing, and

the incidence is currently about 400 per 100 000 in women over 50 years, usually the age where population screening is offered<sup>16</sup>. About 80% of all breast cancers are detected by mammography in the screened population, 20% are so-called interval cancers<sup>17</sup>. The pick-up rate by mammography screening depends on the screening interval and the attendance rate. The recall rate for further assessment is related to the mammography interval, single or double reading and whether assessment is directly linked to the screening units<sup>18</sup>. Recall rates vary from 1 to 5%. When patients are referred for further assessment, about 40% are diagnosed by further imaging only (magnification views, digital mammography, ultrasound or magnetic resonance imaging (MRI)) and classified as benign, 20% will have some benign biopsy (fine needle aspiration (FNA) cytology, core or open biopsies) and 40% will have cancer. 20% of all patients with screen-detected breast cancers are diagnosed with DCIS<sup>18</sup>.

## PRESENTATION

The majority (Approximately 80%) of screen-detected cancers are clinically not visible or palpable. Mammograms show micro-calcifications, densities, architectural distortions, or combinations thereof<sup>17</sup>.

## DIAGNOSTIC STRATEGY

Women referred for a screen-detected breast lesion deserve a fully equipped breast unit, working according to generally accepted guidelines<sup>12,17</sup> for an adequate and swift assessment. Assessment includes:

- History and physical examination
- Usually a new mammography and magnification views as needed
- Ultrasound in case of density and/or architectural distortion

- Image-guided biopsy, either FNA cytology or histological core biopsy; image-guided biopsy is preferred even in palpable lesions.

Ideally this process should be executed within 2 weeks after referral and diagnosis discussed with the patient within 1 week<sup>12</sup>. Before disclosing diagnosis and discussing therapeutic consequences with the patient, all imaging and histological/cytological results and further management of the patient with alternatives, are discussed in a multidisciplinary meeting.

If the diagnosis is unequivocally benign, the patient can be referred back to screening or the general practitioner with a minimal risk of misdiagnosis of malignancy<sup>19</sup>. When a histological core biopsy shows atypical features, frequently referred to as atypical ductal hyperplasia, lobular carcinoma *in situ* (lobular neoplasia), or sclerosing adenosis, the chance of associated malignancy is more than 5%. In such situations, an image-guided open surgical biopsy (see below) is advised<sup>20</sup>.

If cancer is diagnosed, either *in situ* or invasive, further treatment strategy steps should be taken. In invasive cancer, further assessment of size and lymph node involvement is warranted. Particularly in younger women (<55–60 years) in whom breast conserving therapy is considered, MRI of the breast is of help to better estimate size, multifocality and contralateral breast cancers<sup>21,22</sup>. Also, if upfront neoadjuvant systemic therapy by chemotherapy or hormonal therapy is considered – although rare in screen-detected cancers – MRI is of more help for further monitoring of this therapy as compared with clinical examination, mammography, or ultrasound<sup>23–25</sup>. Furthermore, ultrasound of the axilla to screen for lymph node metastasis is very useful: to prevent one sentinel node procedure, approximately six ultrasounds of the axilla have to be performed<sup>26,27</sup>. Nowadays, most breast radiologists will screen the axilla for lymph node metastasis if a malignancy in the breast is suspected at the same time. If a suspicious lymph node is encountered, ultrasound directed FNA cytology or core biopsy should be taken. All this will lead to an optimal surgical treatment strategy to be discussed with the patient. It is aimed for that more than 90% of patients with breast cancer have their diagnosis before any surgical intervention<sup>12,13,28</sup>, since it is generally accepted that the chance of successful first – therapeutic – surgical intervention is highest with optimal imaging and known diagnosis of breast cancer<sup>28</sup>. The diagnostic strategy of screen-detected breast lesions is summarized in Algorithm 1.

## SURGERY

The aim of the resection of an *in situ* or invasive breast cancer is to achieve clear margins and a good

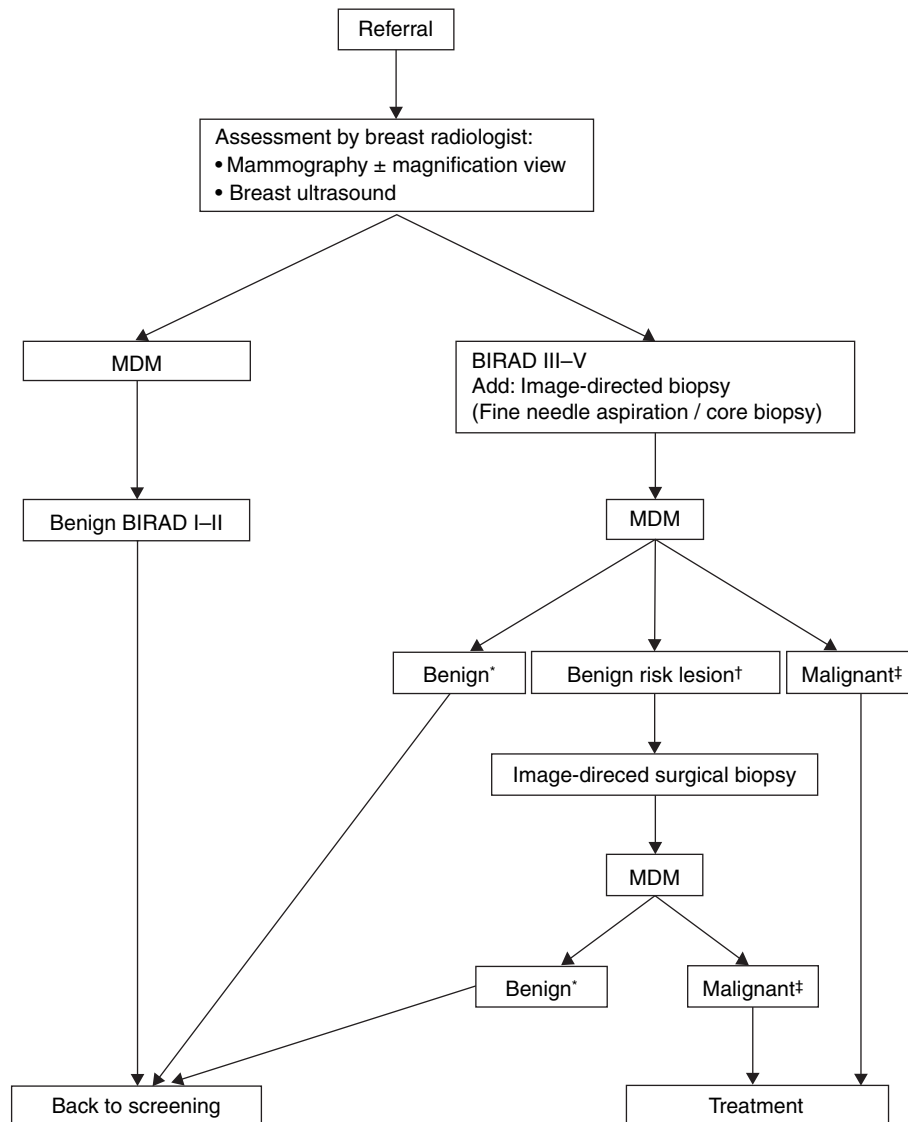
cosmetic outcome<sup>13,28</sup>. Screen-detected breast cancers are usually non-palpable. This has two implications for surgery:

- (1) Most patients can or preferably should be treated with breast conserving therapy, since a majority of lesions are small;
- (2) The surgeon should be guided to the lesion to facilitate complete excision.

A number of guiding tools are available in non-palpable cancers: the guide wire<sup>29</sup>, multiple bracketing guide wires<sup>30</sup>, charcoal or other dyes<sup>31–33</sup>, and radioactive tracers, for instance technetium-99m colloid<sup>34,35</sup>, iodine-125 seeds<sup>36</sup>. The advantage of the guide wire is the general availability, relatively easy application and low costs<sup>37</sup>. The disadvantages are that frequently the wire is inserted not via the shortest route and not near the lesion leading to incomplete excision or even missed excisions<sup>38</sup>. The advantages of radioactive occult lesion localization (ROLL) are two-fold in that exact localization is possible with a drop of the radioactive tracer in the center of the lesion, either by ultrasound or stereotaxis, and the possibility of performing lymphoscintigraphy and probe-guided sentinel node identification<sup>39,40</sup>. Radioguided excision biopsy appears to lead to more complete excisions as compared with guide wire excisions<sup>41,42</sup>. In palpable cancer a wide local excision on palpation is performed.

A wide local excision, aiming to resect with a 1-cm free margin, is best performed by a so-called segmental excision<sup>43</sup>. In principle a full thickness excision of breast parenchyma from skin (may be included) to fascia, and subsequently the lateral borders of the cancer and ending with the central (nipple) side of the parenchyma should be performed. The specimen should be marked for the pathologist to facilitate eventual re-excisions. Preferably the resection should be performed in one specimen and if more excisions are performed, careful re-orientation to secure margin assessment is mandatory<sup>44</sup>. After excision, the breast tissue should be adapted by mobilization of parenchyma flaps or by other oncoplastic techniques<sup>45</sup>, to minimize dead space and to provide the best possible cosmetic result. The advantages of closing breast tissue and minimizing that space are less seroma/hematoma formation, fewer complications, usually a good cosmetic result, and less fibrosis in the long term<sup>43–46</sup>.

If the breast cancer is too large (DCIS, or infiltrating cancer with or without extensive intraductal component) to achieve clear margins or a good cosmetic outcome, large excision with latissimus dorsi muscle-mini-flap or skin-sparing mastectomy with reconstruction (implant or free flaps) are the methods of choice. Of course patients should be informed about possibilities of breast reconstruction and this should be performed according to the wishes of the patient<sup>47</sup>. If well informed, many women do prefer to have



**Algorithm 1** Screen-detected breast lesions. \*Benign: no signs of malignancy in sufficient number of representative core biopsies, concordant with mammographical lesion, and agreed in multidisciplinary meeting (MDM). †Benign risk lesion with >5% chance of associated cancer: atypical ductal hyperplasia, sclerosing adenosis. ‡Malignant: ductal carcinoma *in situ* any invasive cancer. BIRAD, Breast Imaging Report and Data System of the American College of Radiology.

a breast reconstruction immediately resulting in fewer operative procedures and a better cosmetic outcome<sup>48,49</sup>. If lymph nodes in the axilla are proven to be involved, a complete axillary lymph node dissection should be performed in the same session<sup>28</sup>.

DCIS is a proliferation of morphologically malignant cells within the ducts and lobules of the breast without evidence, by light microscopy, of invasion through the basement membrane into the surrounding stroma. The optimal treatment of DCIS is controversial. In the pre-screening era DCIS was rare and accounted for 2–3% of all breast cancers. At that time, mastectomy was the treatment of choice. Nowadays the proportion of DCIS among screen-detected breast cancers has increased

to 20%<sup>50</sup>. It is not known whether all these DCIS will progress into symptomatic and/or invasive lesions<sup>51</sup>. Since breast-conserving treatment (BCT) became an appropriate alternative for mastectomy in women diagnosed with invasive breast cancer<sup>52</sup>, this treatment modality as a matter of course was also tested in DCIS. In several randomized clinical trials wide local excision (WLE) alone was compared with WLE and radiotherapy, and it was shown that by adding radiotherapy a 40–50% reduction of local failure could be achieved compared with WLE alone with a local recurrence rate of 15% at 10–12 years<sup>53,54</sup>. As a result of this obvious beneficial local effect of radiotherapy, the breast cancer-specific death rate is the same for all treatments<sup>53–55</sup>.

## STAGING

About 90% of screen-detected breast cancers are stage 1 or 2 (<5 cm, clinically node negative). In these patients distant metastasis are rarely found at primary diagnosis (<1%)<sup>56</sup>. In general, no routine assessment or search for distant disease with imaging techniques or biochemical tests is warranted in women with screen-detected breast cancer. Lymph node involvement is found in up to 20% of patients with a small (usually screen-detected) breast cancer<sup>57</sup>. Once invasive cancer is diagnosed on core biopsy, a sentinel node procedure can be considered as standard care<sup>58</sup>. If not available, an axillary lymph node dissection can be performed as well. In 'pure' DCIS diagnosed on an excision specimen (either wide local excision or ablative) and after full histological work-up, lymph node involvement is extremely rare and lymph node staging is not necessary<sup>59</sup>. Nowadays most DCIS is diagnosed after stereotactic or ultrasound-guided core biopsies. The nature of the disease is underestimated in 13–38% of patients diagnosed with core needle biopsy to have DCIS<sup>60,61</sup>. Therefore, about a quarter of patients diagnosed with DCIS on core biopsy will have invasive cancer. Most probably this occurs as result of a sampling error since only a small part of the lesion can be examined by this minimal invasive technique, which is used for preoperative diagnosis in about 80% of the patients<sup>62</sup>. Consequently, these patients are at risk of having axillary metastases. Lymphatic mapping by sentinel lymph node biopsy (SLNB) is an accurate technique with a low morbidity to investigate nodal involvement in invasive breast cancer and is also considered in the initial management of patients diagnosed with DCIS. At present, there are no uniform criteria to select patients who benefit most from SLNB. When invasive cancer is found after definitive surgery, lymph node staging should have been indicated. This finding has led to the reasonable practice that the sentinel node procedure is performed in patients with extensive DCIS for whom ablative surgery is indicated. Particularly when breast reconstructions are performed, axillary lymph node dissection later is difficult. Also, in patients with DCIS and possible signs of invasion on mammography, ultrasound, or MRI and scheduled for breast conserving therapy, a sentinel node procedure can be performed<sup>63–66</sup>.

## ADJUVANT TREATMENTS

Adjuvant systemic therapy is advised according to the generally accepted guidelines as for non-screen-detected cancers<sup>67</sup>. To estimate prognosis and indications for adjuvant systemic treatment the following features

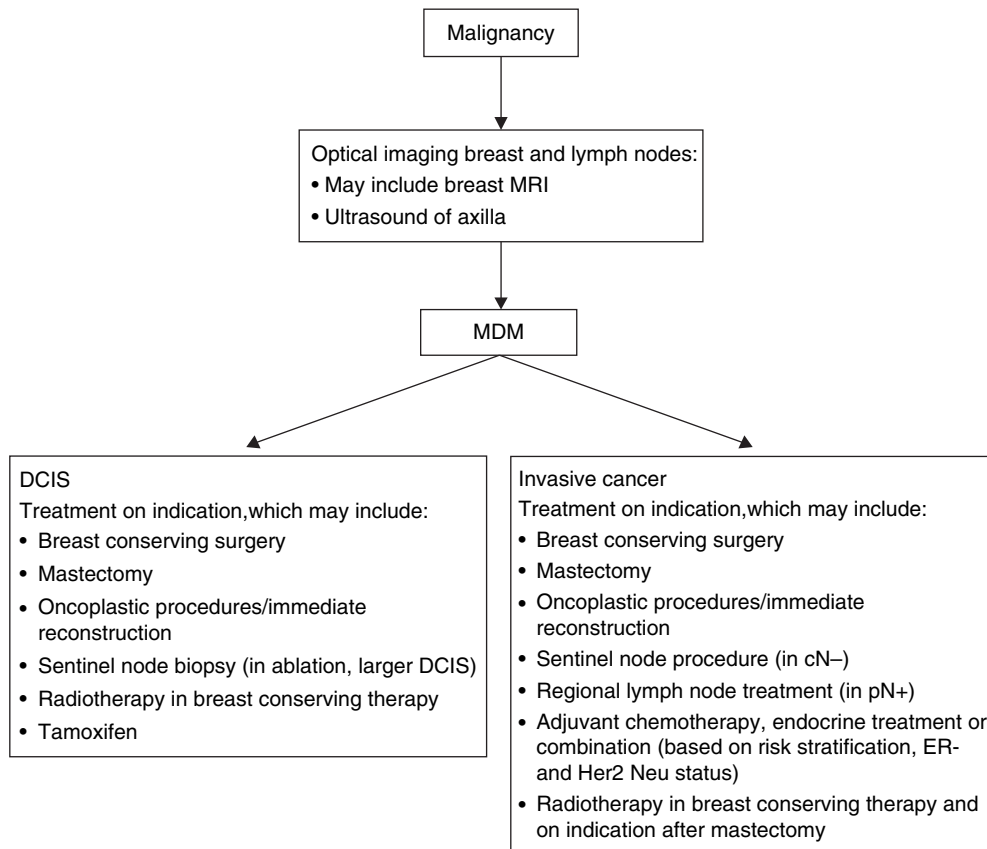
should be available: the size of the invasive part of the cancer, the grade, the number of involved lymph nodes, estrogen and progesterone receptor expression by immunohistochemistry staining, and HER2-neu expression level by immunohistochemistry staining or fluorescence *in situ* hybridization (FISH)/chromogenic *in situ* hybridization (CISH) techniques<sup>68</sup>. For an individual patient, it has become rather simple to estimate the contributions to survival for endocrine treatment and chemotherapy. Basic patient and tumor characteristics can be entered in the program Adjuvant Online, which is offered free of charge through the worldwide web<sup>69</sup>. This decision aid has vastly improved the information that must routinely be given to patients who must decide to accept or decline adjuvant systemic therapy. The program's predictions are based on population-based data from the Surveillance, Epidemiology, and End Results (SEER) registry and use Early Breast Cancer Trialists Collaborative Group (the EBCTCG) database to predict treatment effects<sup>70</sup>. The precise performance of this program has been validated, employing data from the Vancouver Cancer Registry<sup>71</sup>. The treatments strategy of screen-detected breast cancers is summarised in Algorithm 2.

## PROGNOSIS AND OUTCOME

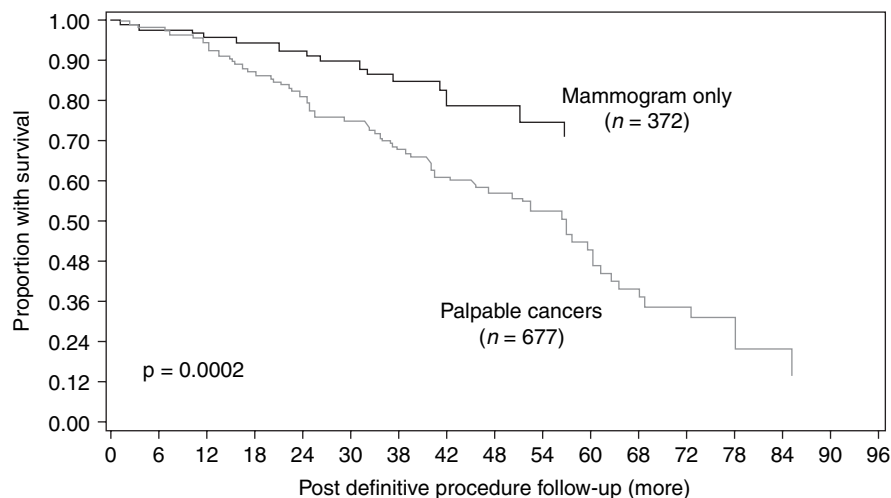
Traditionally the prognosis of breast cancer is best estimated by tumor size, grade and lymph node involvement. Prognostic aids to estimate a patient's individual prognosis such as Adjuvant Online<sup>69</sup> make use of these parameters. However, in itself screen-detected breast cancer appears to have a better prognosis, irrespective of stage<sup>4,5</sup>. Screen-detected breast cancers thus have a lower risk of recurrence<sup>72</sup>. In general 5–10-year survival rates of patient groups with screen-detected breast cancer are good, irrespective of stage<sup>73–76</sup>. The 5-year overall survival for patients with screen-detected breast cancers is reported to be between 92 and 94%, compared with between 79 and 87% for non-screen-detected cancers. These reports come from different countries: USA (see Figure 11.1), Italy and UK<sup>73–75</sup>. In a Finnish study the 10-year overall survival was 90% for screen-detected versus 70% for patients who had non-screen-detected cancers<sup>74</sup>. To achieve this patients with screen-detected breast cancer generally do have less need for adjuvant systemic treatments<sup>77</sup>.

## SUMMARY

- (1) Population screening by mammography will result in a 15% reduction in breast cancer mortality.



**Algorithm 2** Screen-detected breast cancers. MRI, magnetic resonance imaging; MDM, multidisciplinary meeting; DCIS, ductal carcinoma *in situ*.



**Figure 11.1** Observed overall survival rates according to method of detection in 1049 patients with invasive breast cancers diagnosed 1994–2001. From reference 74, with permission.

- (2) Usually non-palpable cancers are found; the radiologist is the key person in the diagnosis of screen-detected lesions.
- (3) Diagnosis of screen-detected lesions should be performed within the framework of a multidisciplinary breast unit according to generally accepted guidelines.
- (4) A preoperative diagnosis of malignancy leads to fewer surgical interventions, more complete excisions at first surgery and breast conserving therapy in most patients.

- (5) Lymph node mapping by sentinel node procedure should be considered standard when invasive cancer is proven or suspected.
- (6) Screen-detected breast cancer appears to have a better prognosis than non-screen-detected breast cancer.
- (7) Adjuvant systemic therapy should be given according to the generally accepted biological and prognostic parameters.
- (8) Last but not least, the expensive efforts of screening should not be wasted by insufficient diagnostic work-up or therapy.

## REFERENCES

1. Gotzsche PC, Olsen O. Is screening for breast cancer with mammography justifiable? *Lancet* 2000; 355: 129–34.
2. de Koning HJ. Mammographic screening: evidence from randomised controlled trials. *Ann Oncol* 2003; 14: 1185–9.
3. Humphrey LL, Helfand M, Chan BK, Woolf SH. Breast cancer screening: a summary of the evidence for the U.S. Preventive Services Task Force. *Ann Intern Med* 2002; 137: 347–60.
4. Shen Y, Yang Y, Inoue LY et al. Role of detection method in predicting breast cancer survival: analysis of randomized screening trials. *J Natl Cancer Inst* 2005; 97: 1195–203.
5. Joensuu H, Lehtimäki T, Holli K et al. Risk for distant recurrence of breast cancer detected by mammography screening or other methods. *JAMA* 2004; 292: 1064–73.
6. BORDAS P, Jonsson H, Nystrom L, Lennner P. Survival from invasive breast cancer among interval cases in the mammography screening programmes of northern Sweden. *Breast* 2007; 16: 47–52.
7. Paaanen H, Kyhala L, Varjo R, Rantala S. Effect of screening mammography on the surgery of breast cancer in Finland: a population-based analysis during the years 1985–2004. *Am Surg* 2006; 72: 167–71.
8. Cortesi L, Chiuri VE, Ruscelli S et al. Prognosis of screen-detected breast cancers: results of a population based study. *BMC Cancer* 2006; 6: 17.
9. Weaver DL, Rosenberg RD, Barlow WE et al. Pathologic findings from the Breast Cancer Surveillance Consortium: population-based outcomes in women undergoing biopsy after screening mammography. *Cancer* 2006; 106: 732–42.
10. Ernster VL, Ballard-Barbash R, Barlow WE et al. Detection of ductal carcinoma in situ in women undergoing screening mammography. *J Natl Cancer Inst* 2002; 94: 1546–54.
11. Ernst MF, Voogd AC, Coebergh JW, Roukema JA. Breast carcinoma diagnosis, treatment, and prognosis before and after the introduction of mass mammographic screening. *Cancer* 2004; 100: 1337–44.
12. Perry NM; EUSOMA Working Party. Quality assurance in the diagnosis of breast disease. EUSOMA Working Party. *Eur J Cancer* 2001; 37: 159–72.
13. Rutgers EJ; EUSOMA Consensus Group. Quality control in the locoregional treatment of breast cancer. *Eur J Cancer* 2001; 37: 447–53.
14. Parkin DM, Fernandez LM. Use of statistics to assess the global burden of breast cancer. *Breast J* 2006; 12 (Suppl 1): S70–80.
15. Edwards BK, Brown ML, Wingo PA et al. Annual report to the nation on the status of cancer, 1975–2002, featuring population-based trends in cancer treatment. *J Natl Cancer Inst* 2005; 97: 1407–27.
16. Smigal C, Jemal A, Ward E et al. Trends in breast cancer by race and ethnicity: update 2006. *CA Cancer J Clin* 2006; 56: 168–83.
17. Perry N, Broeders M, de Wolf C et al. European Commission European Guidelines for Quality Assurance in Breast Cancer Screening and Diagnosis, 4th edn. Luxembourg: Office for Official Publications of the European Communities, 2006: 416.
18. Smith-Bindman R, Chu PW, Miglioretti DL et al. Comparison of screening mammography in the United States and the United Kingdom. *JAMA* 2003; 290: 2129–37.
19. Verkooijen HM; Core Biopsy After Radiological Localisation (COBRA) Study Group. Diagnostic accuracy of stereotactic large-core needle biopsy for non palpable breast disease: results of a multicenter prospective study with 95% surgical confirmation. *Int J Cancer* 2002; 99: 853–9.
20. Levine P, Simsir A, Cangiarella J. Management issues in breast lesions diagnosed by fine-needle aspiration and percutaneous core breast biopsy. *Am J Clin Pathol* 2006; 125: S124–34.
21. Blair S, McElroy M, Middleton MS et al. The efficacy of breast MRI in predicting breast conservation therapy. *J Surg Oncol* 2006; 94: 220–5.
22. Deurloo EE, Klein Zeggelink WF, Teertstra HJ et al. Contrast-enhanced MRI in breast cancer patients eligible for breast-conserving therapy: complementary value for subgroups of patients. *Eur Radiol* 2006; 16: 692–701.
23. Yeh E, Slanetz P, Kopans DB et al. Prospective comparison of mammography, sonography, and MRI in patients undergoing neoadjuvant chemotherapy for palpable breast cancer. *AJR Am J Roentgenol* 2005; 184: 868–77.
24. Londero V, Bazzocchi M, Del Frate C et al. Locally advanced breast cancer: comparison of mammography, sonography and MR imaging in evaluation of residual disease in women receiving neoadjuvant chemotherapy. *Eur Radiol* 2004; 14: 1371–9.
25. Pickles MD, Lowry M, Manton DJ et al. Role of dynamic contrast enhanced MRI in monitoring early response of locally advanced breast cancer to neoadjuvant chemotherapy. *Breast Cancer Res Treat* 2005; 91: 1–10.
26. de Kanter AY, van Eijck CH, van Geel AN et al. Multicentre study of ultrasonographically guided axillary node biopsy in patients with breast cancer. *Br J Surg* 1999; 86: 1459–62.
27. van Rijk MC, Deurloo EE, Nieweg OE et al. Ultrasonography and fine-needle aspiration cytology can spare breast cancer patients unnecessary sentinel lymph node biopsy. *Ann Surg Oncol* 2006; 13: 31–5.
28. Rutgers EJ. Guidelines to assure quality in breast cancer surgery. *Eur J Surg Oncol* 2005; 31: 568–76.
29. Chadwick DR, Shorthouse AJ. Wire-directed localization biopsy of the breast: an audit of results and analysis of factors influencing therapeutic value in the treatment of breast cancer. *Eur J Surg Oncol* 1997; 23: 128–33.
30. Liberman L, Kaplan J, Van Zee KJ et al. Bracketing wires for preoperative breast needle localization. *AJR Am J Roentgenol* 2001; 177: 565–72.
31. Moss HA, Barter SJ, Nayagam M et al. The use of carbon suspension as an adjunct to wire localisation of impalpable breast lesions. *Clin Radiol* 2002; 57: 937–44.
32. Rose A, Collins JP, Neerhut P et al. Carbon localization of impalpable breast lesions. *Breast* 2003; 12: 264–9.

33. Zografos GC, Doumitriou C, Lappas D et al. Localization of non palpable breast lesions using hook-wire combined with isosulfan blue dye. *J Surg Oncol* 2003; 82: 73–4.
34. Gennari R, Galimberti V, De Cicco C et al. Use of technetium-99m-labeled colloid albumin for preoperative and intraoperative localization of non palpable breast lesions. *J Am Coll Surg* 2000; 190: 692–8.
35. Rampaul RS, Bagnall M, Burrell H et al. Randomized clinical trial comparing radioisotope occult lesion localization and wire-guided excision for biopsy of occult breast lesions. *Br J Surg* 2004; 91: 1575–7.
36. Gray RJ, Pockaj BA, Karstaedt PJ, Roarke MC. Radioactive seed localization of non palpable breast lesions is better than wire localization. *Am J Surg* 2004; 188: 377–84.
37. Abrahamson PE, Dunlap LA, Amamoo MA et al. Factors predicting successful needle-localized breast biopsy. *Acad Radiol* 2003; 10: 601–6.
38. Jackman RJ, Marzoni FA Jr. Needle-localized breast biopsy: why do we fail? *Radiology* 1997; 204: 677–84.
39. Tanis PJ, Deurloo EE, Valdes Olmos RA et al. Single intralesional tracer dose for radio-guided excision of clinically occult breast cancer and sentinel node. *Ann Surg Oncol* 2001; 8: 850–5.
40. Zgajnar J, Besic N, Frkovic-Grazio S et al. Radio guided excision of the non palpable breast cancer and simultaneous sentinel lymph node biopsy using a single radiopharmaceutical: an original approach to accurate administration of the blue dye. *J Surg Oncol* 2003; 83: 48–50.
41. Gallegos Hernandez JF, Tanis PJ, Deurloo EE et al. Radio-guided surgery improves outcome of therapeutic excision in non-palpable invasive breast cancer. *Nucl Med Commun* 2004; 25: 227–32.
42. Nadeem R, Chagla LS, Harris O et al. Occult breast lesions: a comparison between radio guided occult lesion localization (ROLL) vs. wire-guided lumpectomy (WGL). *Breast* 2005; 14: 283–9.
43. Aspegren K, Holmberg L, Adami HO. Standardization of the surgical technique in breast-conserving treatment of mammary cancer. *Br J Surg* 1988; 75: 807–10.
44. Schwartz GF, Veronesi U, Clough KB et al. Consensus Conference Committee. Consensus conference on breast conservation. *J Am Coll Surg* 2006; 203: 198–207.
45. Anderson BO, Masetti R, Silverstein MJ. Oncoplastic approaches to partial mastectomy: an overview of volume-displacement techniques. *Lancet Oncol* 2005; 6: 145–57.
46. Evans SB, Kaufman SA, Price LL et al. Persistent seroma after intraoperative placement of MammoSite for accelerated partial breast irradiation: incidence, pathologic anatomy, and contributing factors. *Int J Radiat Oncol Biol Phys* 2006; 65: 333–9.
47. Kronowitz SJ, Kuerer HM. Advances and surgical decision-making for breast reconstruction. *Cancer* 2006; 107: 893–907.
48. Wilkins EG, Cederna PS, Lowery JC et al. Prospective analysis of psychosocial outcomes in breast reconstruction: one-year postoperative results from the Michigan Breast Reconstruction Outcome Study. *Plast Reconstr Surg* 2000; 106: 1014–25.
49. Al-Ghazal SK, Sully L, Fallowfield L et al. The psychological impact of immediate rather than delayed breast reconstruction. *Eur J Surg Oncol* 2000; 26: 17–9.
50. Ernster VL, Ballard-Barbash R, Barlow WE et al. Detection of ductal carcinoma in situ in women undergoing screening mammography. *J Natl Cancer Inst* 2002; 94: 1546–54.
51. Sanders ME, Schuyler PA, Dupont WD et al. The natural history of low-grade ductal carcinoma in situ of the breast in women treated by biopsy only revealed over 30 years of long-term follow-up. *Cancer* 2005; 103: 2481–4.
52. Fisher B, Anderson S, Bryant J et al. Twenty-year follow-up of a randomized trial comparing total mastectomy, lumpectomy, and lumpectomy plus irradiation for the treatment of invasive breast cancer. *N Engl J Med* 2002; 347: 1233–41.
53. Bijker N, Meijnen P, Peterse JL et al. Breast-conserving treatment with or without radiotherapy in ductal carcinoma-in-situ: ten-year results of European Organisation for Research and Treatment of Cancer randomized phase III trial 10853 – a study by the EORTC Breast Cancer Cooperative Group and EORTC Radiotherapy Group. *J Clin Oncol* 2006; 24: 3381–7.
54. Fisher B, Land S, Mamounas E et al. Prevention of invasive breast cancer in women with ductal carcinoma in situ: an update of the national surgical adjuvant breast and bowel project experience. *Semin Oncol* 2001; 28: 400–18.
55. Warnberg F, Bergh J, Zack M et al. Risk factors for subsequent invasive breast cancer and breast cancer death after ductal carcinoma in situ: a population-based case-control study in Sweden. *Cancer Epidemiol Biomarkers Prev* 2001; 10: 495–9.
56. Puglisi F, Follador A, Minisini AM et al. Baseline staging tests after a new diagnosis of breast cancer: further evidence of their limited indications. *Ann Oncol* 2005; 16: 263–6.
57. Heimann R, Munsell M, McBride R. Mammographically detected breast cancers and the risk of axillary lymph node involvement: is it just the tumor size? *Cancer J* 2002; 8: 276–81.
58. Lyman GH, Giuliano AE, Somerfield MR et al. American Society of Clinical Oncology. American Society of Clinical Oncology guideline recommendations for sentinel lymph node biopsy in early-stage breast cancer. *J Clin Oncol* 2005; 23: 7703–20.
59. Schwartz GF, Solin LJ, Olivetto IA et al. Consensus Conference on the Treatment of In Situ Ductal Carcinoma of the Breast, April 22–25, 1999. *Cancer* 2000; 88: 946–54.
60. Jackman RJ, Burbank F, Parker SH et al. Stereotactic breast biopsy of nonpalpable lesions: determinants of ductal carcinoma in situ underestimation rates. *Radiology* 2001; 218: 497–502.
61. Hoorntje LE, Schipper ME, Peeters PH et al. The finding of invasive cancer after a preoperative diagnosis of ductal carcinoma-in-situ: causes of ductal carcinoma-in-situ underestimates with stereotactic 14-gauge needle biopsy. *Ann Surg Oncol* 2003; 10: 748–753.
62. Meijnen P, Peterse JL, Oldenburg HS et al. Changing patterns in diagnosis and treatment of ductal carcinoma in situ of the breast. *Eur J Surg Oncol* 2005; 31: 833–9.
63. Goyal A, Douglas-Jones A, Stevens G et al. Role of sentinel lymph node biopsy in screen-detected ductal carcinoma in situ: analysis of 587 cases. *Breast Cancer Res Treat* 2005; 94: S261–2.
64. Mittendorf EA, Arciero CA, Gutchell V et al. Core biopsy diagnosis of ductal carcinoma in situ: an indication for sentinel lymph node biopsy. *Curr Surg* 2005; 62: 253–7.
65. Wilkie C, White L, Dupont E et al. An update of sentinel lymph node mapping in patients with ductal carcinoma in situ. *Am J Surg* 2005; 190: 563–6.
66. Yen TW, Hunt KK, Ross MI et al. Predictors of invasive breast cancer in patients with an initial diagnosis of ductal carcinoma in situ: a guide to selective use of sentinel lymph node biopsy in management of ductal carcinoma in situ. *J Am Coll Surg* 2005; 200: 516–26.
67. Goldhirsch A, Glick JH, Gelber RD et al. Panel members. Meeting highlights: international expert consensus on the primary therapy of early breast cancer 2005. *Ann Oncol* 2005; 16: 1569–83.
68. Carlson RW, Moench SJ, Hammond ME et al. NCCN HER2 Testing in Breast Cancer Task Force. HER2 testing in breast cancer: NCCN Task Force report and recommendations. *J Natl Compr Canc Netw* 2006; 4 (Suppl 3): S1–22.
69. <http://www.AdjuvantOnline.com>. Accessed 21 June 2007.
70. Ravdin PM, Siminoff LA, Davis GJ et al. Computer program to assist in making decisions about adjuvant therapy for women with early breast cancer. *J Clin Oncol* 2001; 19: 980–91.



71. Olivotto IA, Bajdik CD, Ravdin PM et al. Population-based validation of the prognostic model ADJUVANT! for early breast cancer. *J Clin Oncol* 2005; 23: 2716–25.
72. Immonen-Raiha P, Kauhava L, Parvinen I et al. Mammographic screening reduces risk of breast carcinoma recurrence. *Cancer* 2005; 103: 474–82.
73. Sener SF, Winchester DJ, Winchester DP et al. Survival rates for breast cancers detected in a community service screening mammogram program. *Am J Surg* 2006; 191: 406–9.
74. Cortesi L, Chiuri VE, Ruscelli S et al. Prognosis of screen-detected breast cancers: results of a population based study. *BMC Cancer* 2006; 6: 17.
75. Yassin MM, Peel AL, Thompson WD et al. Does screen-detected breast cancer have better survival than symptomatic breast cancer? *Asian J Surg* 2003; 26: 101–7.
76. Paajanen H, Kyhala L, Varjo R et al. Effect of screening mammography on the surgery of breast cancer in Finland: a population-based analysis during the years 1985–2004. *Am Surg* 2006; 72: 167–71.
77. Barth RJ Jr, Gibson GR, Carney PA et al. Detection of breast cancer on screening mammography allows patients to be treated with less-toxic therapy. *AJR Am J Roentgenol* 2005; 184: 324–9.

Megan Baker Ruppel and David J Cole

---

## INTRODUCTION

Breast cancer prevalence, particularly that of *in situ* disease continues to increase, largely attributable to the increasing use of screening mammography for early detection. According to American Cancer Society Surveillance Research in 2005, a North American female has a 13% life-time risk of developing breast cancer. Furthermore, the incidence of disease differs among demographic groups, i.e. 141/100 000 white women versus 90/100 000 for Latina/Hispanic women. The manner in which women present can be as varied as these statistics, ranging from asymptomatic mammographic abnormalities to exophytic fungating chest wall masses. The focus of this chapter is to clearly define the principles involved with the evaluation and management of breast cancer when it presents in a symptomatic manner, from its initial presentation as a breast mass or nipple discharge to the presence of recurrent disease. Although most breast related symptoms and masses are not associated with the presence of cancer, any and all breast related complaints which bring a patient to the physician for assessment warrant thoughtful evaluation. The principles of this investigation may not differ across patient populations but the interpretation of findings must be put into appropriate patient related context. As such the evaluation of any breast complaint begins with a thorough breast cancer oriented history and physical examination. The history should focus on the following factors of risk assessment: patient gender; patient age; family history of breast or ovarian cancer; hormonal history (age of menarche, menopause, gravidy, and parity, use of exogenous hormones); personal history of breast disease; and prior breast biopsies or procedures with relevant pathology. With a specific focus on the current breast issue at hand, information regarding the duration of symptoms, size or nature of any perceived masses, new or persistent tenderness, associated skin or nipple changes, ameliorating or worsening factors, and any associated trauma need to be ascertained.

The physical examination should be thorough, but is necessarily focused on the examination of the breast and

regional lymph nodes. This begins with visual inspection of both breasts assessing for any evidence of skin dimpling, puckering, retraction, or asymmetry. Second, a careful clinical breast examination (CBE) should be performed noting any discrete nodularity or masses to palpation. Any abnormalities should be characterized according to their texture (smooth, soft, hard), borders (well circumscribed, irregular), and mobility (mobile or fixed.) The breast abnormality is then often described with reference to the quadrant of the breast, the distance from the nipple areola complex and its orientation as it would appear on the face of a clock. This enables not only the patient and surgeon to be exact but also facilitates clear communication with other members of a multidisciplinary breast care team. Next, the breast and nipple areola complex should be examined to illicit any nipple discharge. If present, its color should be noted and any sanguinous drainage should be sent for cytology. A thorough examination of axillary, cervical and supraclavicular lymph nodes should be performed and documented bilaterally. Finally, the patient should have a timely completion of any baseline or follow-up mammographic evaluations according current recommendations. The information obtained from the patient's history, the history of present illness and physical examination can then be used to inform the clinician's level of suspicion which can influence the evaluation, and provide the basis for the initial steps involved in the management of symptomatic breast cancer.

## THE BREAST MASS

### Evaluation of the breast mass

The majority of breast masses are benign. Nevertheless, dominant or asymmetrical masses require evaluation. After completing a thorough history and physical examination, a radiographic assessment is required as described above. CBE although helpful, lacks sensitivity detecting only 44% of breast cancers<sup>1</sup>. The sensitivity of detection can be augmented greatly to 89% from 44% with the

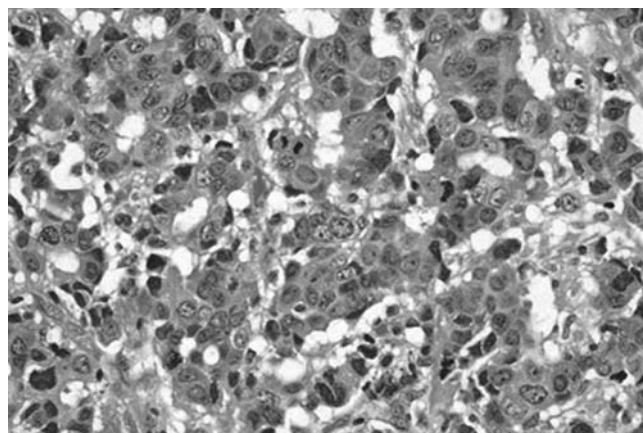
addition of breast ultrasonographic evaluation<sup>2</sup>. In fact, ultrasound has been shown to be superior to mammography in the evaluation of the palpable breast mass<sup>3</sup>. An ultrasonographic evaluation assesses the relative density of the area in question with respect to the normal surrounding breast parenchyma. This allows the investigator to define the presence of a lesion and characterize it as cystic or solid, or a combination thereof. Furthermore, worrisome ultrasound characteristics which include posterior shadowing, irregular borders or lesions which are longer than they are wide can be identified. Finally, this allows the clinician the opportunity to sample the lesion in a more exact manner.

Historically, fine needle aspiration (FNA) has been widely advocated in the evaluation of a palpable mass. Its main advantages being a rapid well tolerated procedure with a high level of specificity in experienced hands. Although useful for rapidly establishing a diagnosis in the setting of a highly suspicious mass, a negative FNA finding does not exclude the presence of tumor when the mass is clinically suspect. Technical limitations of FNA have been well described, including potentially problematic receptor status and special staining to characterize the tumor and an inability to differentiate between *in situ* and invasive disease. This has led to the current favored use of core biopsy or ultrasound-guided aspiration of cystic lesions<sup>4</sup>. Core biopsy which commonly utilizes a 14–18 gauge cutting needle achieves a sensitivity of 99% when a minimum of four core samples are obtained<sup>5</sup>. It is notable that even core biopsy may not distinguish between fibroadenoma and phyllodes tumor, a distinction which may require surgical excision. Should there be any discordance between physical examination, radiographic imaging and tissue sampling, then excisional biopsy remains the gold standard<sup>6</sup>.

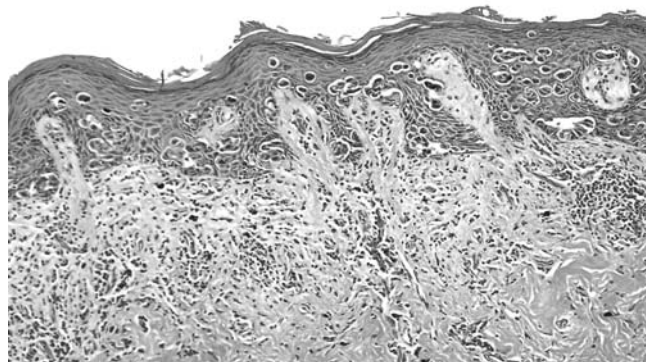
If a cystic lesion presents as a palpable mass, this should be aspirated using either manual or image guidance to assess for complete resolution of the cyst. Although there have been many advocates of cytological evaluation of cystic fluid on the initial aspirate, current evidence is that this practice is not useful or cost effective unless the fluid is bloody<sup>7</sup>. If a mass does not disappear completely after aspiration, then it must be approached as a persistent mass with mammography, and repeat biopsy as indicated. Should the ultrasound evaluation reveal a complex cystic lesion or solid lesion, then the surgeon should proceed with a core biopsy. Finally, after a tissue diagnosis has been reached, a bilateral diagnostic mammogram should be performed to assay for concomitant imaging abnormalities.

Once the biopsy or aspiration is complete, histopathological characterization and grading ensues. A breast mass of a non-benign nature will be described as either *in situ* carcinoma or invasive disease. With respect to the former, this may result in a diagnosis of ductal carcinoma *in situ*

which necessitates local regional control or lobular carcinoma *in situ* which serves as a marker for risk. For those tumors deemed to be invasive, the vast majority will be ductal in origin but approximately 10% will be of lobular histology (Figure 12.1). Less common invasive disease includes inflammatory, medullary, mucinous and papillary carcinomas (Figure 12.2). With one exception, that being medullary, all invasive breast carcinomas should be graded using the Nottingham combined histological grade.



**Figure 12.1** Invasive ductal carcinoma. Hematoxylin and eosin staining of breast biopsy sample demonstrating features consistent with invasive ductal breast cancer, Nottingham grade III. Histologically, breast cancer cells are larger than normal epithelium, and can assume a variety of patterns usually within a dense stroma with glandular formation, cords of cells, broad sheets of cells, or a mixture of all of these. Well differentiated tumors demonstrate glandular formation, whereas poorly differentiated tumors contain solid sheets of pleomorphic neoplastic cells. Courtesy of William Gillanders.



**Figure 12.2** Inflammatory breast cancer. Hematoxylin and eosin staining of an incisional breast biopsy specimen demonstrating typical dermal invasion seen in inflammatory breast cancer. Additional common pathological findings include infiltration of the subepidermal lymphatics and vessels by tumor cells. Courtesy of John Metcalf.

This grading system can then be used to infer prognostic information<sup>8</sup>. Specific tumor characteristics such as estrogen and progesterone hormone receptor status and her-2-neu amplification must also be discerned as this serves not only a prognostic purpose but also allows patient therapy to be individualized.

### Treatment of the breast mass

After a diagnosis of *in situ* or invasive disease is confirmed, definitive surgical planning and attempts to determine cancer stage should ensue (Table 12.1). Preoperative evaluation for early stage breast cancer requires a thorough history and physical examination, bilateral mammogram, chest X-ray, and routine blood work. A more extensive metastatic evaluation would be indicated in the setting of locally advanced disease, clinically pathological lymphadenopathy, or concerning systemic symptoms. This could include ultrasound evaluation of the axilla, computed tomography (CT) scan of chest, abdomen and pelvis, or nuclear bone scan. In the absence of such findings, standard surgical planning can continue.

The surgical management of breast cancer has evolved considerably from the time of Halstead with the introduction of the radical mastectomy (surgical removal of the breast, pectoralis major and minor muscles with a full axillary lymph node dissection)<sup>10</sup>. Since the early 20th century, great efforts have been made to obtain not only locoregional control and long-term survival, but also breast preservation. In 1985, results from the National Surgery Adjuvant Breast and Bowel Protocol (NSABP) B-04 trial demonstrated that total mastectomy with axillary radiation, total mastectomy followed by axillary dissection in the setting of regional recurrence, and radical mastectomy had equivalent breast cancer outcomes<sup>11</sup>. Shortly thereafter the results of National Surgical Adjuvant Breast and Bowel Project (NSABP) B06 were published, establishing the efficacy and safety of breast conservation therapy (BCT)<sup>12</sup>. In fact, a National Cancer Institute consensus statement was released in 1991 stating that 'breast conservation treatment is an appropriate method of primary therapy for the majority of women with Stage I and II breast cancer and is preferable because it provides survival equivalent to total mastectomy with axially dissection'. Although the incidence of local recurrence has been reported to be slightly higher for lumpectomy patients in several randomized series reported<sup>13</sup>, a meta-analysis of nine prospective randomized trials comparing conservative surgery and radiation with mastectomy showed no survival differences, and an equivalent local recurrence rate<sup>14</sup>.

A patient's desire for and candidacy for BCT must then be assessed. Eligibility for BCT remains a function of the ability to obtain clear surgical margins on the lumpectomy

specimen, the ability to safely deliver radiation therapy, and the likelihood of achieving a cosmetically acceptable result<sup>13</sup>. Generally accepted absolute exclusion criteria to BCT include multicentric disease, diffuse malignant appearing microcalcifications, prior chest irradiation of the proposed field, pregnancy, inability to adequately clear margins, and tumor size of more than 5 cm<sup>13</sup>. Recently, breast magnetic resonance imaging (MRI) has been gaining increasing popularity as a local staging methodology to help determine BCT eligibility in the setting of a known cancer diagnosis<sup>15</sup>. Ultimately, it should be noted that patient perceptions, support/peer groups, and treating surgeon's bias clearly can significantly impact a patient's choice for BCT<sup>16</sup>.

BCT can be undertaken with or without the aid of wire (needle) localization. The adequacy of lumpectomy is determined by extent of margin clearance and presence of an extensive intraductal component (EIC) of disease. With respect to the former, no general consensus exists. However, several studies have identified a clear margin of 2 mm or more as being associated with an acceptable (7%) rate of local recurrence<sup>17</sup>. Early research suggested that the presence EIC resulted in unacceptable rates of local recurrence. More recent studies, however, have demonstrated that when effective margin clearance is obtained, EIC does not increase the likelihood of local recurrence<sup>18</sup>.

Should a patient not meet criteria for BCT eligibility then they should undergo total mastectomy. The evolution of surgical technique for mastectomy parallels that of breast cancer therapy. Remote are the days of the radical mastectomy. Current standards of care endorse the use of skin-sparing mastectomy techniques for those patients desiring reconstruction or traditional total mastectomy for those patients not undergoing simultaneous reconstruction<sup>19</sup>. In either approach the entirety of the breast mound is removed from its lateral extent at the latissimus dorsi muscle to its superior, inferior, medial, and posterior boundaries at the clavicle, inframammary ridge, lateral edge of the sternum, and pectoralis fascia, respectively. Careful attention should be given to the thickness of the skin flaps so as not to devascularize the overlying skin while removing macroscopic breast tissue.

Either treatment (BCT or total mastectomy) of the breast pathology, however, needs to be paired with surgical staging of the patient's axilla. With the ever increasing use of preoperative core biopsy this is often accomplished simultaneously. Because of its ability to provide a focused and accurate histopathological evaluation of the axilla, the sentinel lymph node biopsy (SLN) technique has supplanted prophylactic axillary dissection for the purposes of staging at major cancer centers. A recent consensus conference on sentinel node biopsy in breast cancer stated that:

- (1) Sentinel node biopsy can accurately stage the axilla and can replace traditional staging with ALND.

**Table 12.1** Tumor, node, metastases (TNM) and stage classification for breast cancer

<i>Classification</i>	<i>Definition</i>
<i>Primary Tumor (T)</i>	
TX	Primary tumor cannot be assessed
T0	No evidence of primary tumor
Tis	Carcinoma <i>in situ</i>
T1	Tumor $\leq 2$ cm in greatest dimension
T2	Tumor $> 2$ cm but $\leq 5$ cm
T3	Tumor $> 5$ cm
T4	Tumor of any size with direct extension to chest wall or skin, includes inflammatory breast cancer
<i>Regional lymph nodes (N)</i>	
NX	Regional lymph nodes cannot be assessed
N0	No regional lymph node metastasis
N1	Metastasis in movable ipsilateral axillary lymph node(s)
N2	Metastasis in ipsilateral lymph nodes fixed or matted, or in clinically apparent ipsilateral internal mammary nodes in the absence of clinically evident axillary lymph node metastasis
N3	Metastasis in ipsilateral infraclavicular lymph node(s) or in clinically apparent ipsilateral internal mammary lymph node(s) and in the presence of clinically evident axillary lymph node metastasis; or metastasis in ipsilateral supraclavicular lymph node with or without axillary or internal mammary lymph node involvement
<i>Regional lymph nodes (pN)</i>	
pNX	Regional lymph nodes cannot be assessed
pN0	No regional lymph node metastasis histologically, no additional examination for isolated tumor cells
pN1	Metastasis in one to three axillary lymph nodes, and/or in internal mammary nodes with microscopic disease detected by sentinel lymph node dissection but not clinically apparent
pN2	Metastasis in four to nine lymph nodes, or in clinically apparent internal mammary lymph nodes in the absence of axillary lymph node metastasis
pN3	Metastasis in ten or more axillary lymph nodes, or in infraclavicular lymph nodes, or in clinically apparent ipsilateral internal mammary lymph nodes in the presence of one or more positive axillary lymph nodes; or in more than three axillary lymph nodes with clinically negative microscopic metastasis in internal mammary lymph nodes; or in ipsilateral supraclavicular lymph nodes
<i>Distant metastasis (M)</i>	
MX	Distant metastasis cannot be assessed
M0	No distant metastasis
Stage 0	Tis, N0, M0
Stage I	T1*, N0, M0
Stage IIA	T0, N1, M0 T1*, N1, M0
Stage IIB	T2, N0, M0
	T2, N1, M0
	T3, N0, M0

*Continued*

Table 12.1 Continued

Classification	Definition
Stage IIIA	T0, N2, M0 T1*, N2, M0 T2, N2, M0 T3, N1, M0 T3, N2, M0
Stage IIIB	T4, N0, M0 T4, N1, M0 T4, N2, M0
Stage IIIC	Any T, N3, M0
Stage IV	Any T, Any N, M1

\*T1 includes T1mic.  
From reference 9.

- (2) Identification of a tumor-free sentinel node is highly predictive of no additional axillary nodal metastases and no further treatment of the axilla being needed.
- (3) Identification of a sentinel node containing metastases requires further axillary treatment with either axillary lymph node dissection, axillary radiation, or participation in ongoing clinical trials<sup>20</sup>.

The techniques for sentinel lymph node biopsy are well established and include localization using blue dye (1% isosulfan blue, methylene blue and vital blue dye), radioisotope (technetium-99m sulfur colloid or technetium-99m albumin), or a combination of the two. The rate of identification of the sentinel lymph node using accepted SLN technique in experienced hands exceeds 97%<sup>21</sup>. The need for completion axillary dissection is dictated by gross pathological findings of the sentinel node using hematoxylin and eosin staining. Current standards call for completion dissection when any gross tumor measuring more than 2 mm is discovered in the sentinel lymph node<sup>22</sup>.

Like surgical techniques, radiation therapy techniques and indications have also become more sophisticated. Radiotherapy remains an integral and essential component of BCT but can vary in its method of delivery. Radiotherapy can be delivered using external beam, interstitial brachytherapy catheter implantation, balloon catheter-based partial breast irradiation, or three-dimensional conformal techniques. The largest and most established of these remains the external beam modality. External beam principles include the use of tangential photon fields so as to limit visceral organ injury as well as the use of an

additional boost dose to the tumor bed itself, thereby more directly targeting the involved tissue. The efficacy of radiotherapy in decreasing the rate of local recurrence following the surgical treatment of ductal carcinoma *in situ* and invasive carcinoma is well established<sup>23,24</sup>. More recently attention has been directed towards the concept of partial breast irradiation. Short-term studies using all three modalities have resulted in rates of local recurrence comparable with traditional whole breast irradiation<sup>25</sup>. According to a recent consensus statement from the American Society of Breast Surgeons, a partial breast irradiation is considered most appropriate for patients younger than age 45 with tumors less than 3 cm and who have node negative disease. A large prospective randomized multi-institutional trial is underway to ascertain the efficacy of partial versus whole breast irradiation, NSABP B-39/Radiation Therapy Oncology Group (RTOG) Study 0319. Reports of success using intraoperative radiation exist<sup>26</sup>; however, given the technical and physical equipment considerations associated with this modality its use remains infrequent.

Depending on a patient's tumor stage and tumor characteristics surgical and radiation treatments may be augmented by adjuvant chemotherapy or hormonal therapy. This remains a function of tumor size, nodal involvement and hormonal status as well as molecular characteristics. In general, when used in the adjuvant setting, chemotherapy is given to patients prior to radiation treatments, with two exceptions. Patients receiving partial breast irradiation are treated closer to the time of surgical intervention as well as those few patients who are being treated with intraoperative radiotherapy techniques. Hormonal therapy is commonly not given until all radiation therapy has been

completed as its concomitant or prior use can increase the rate of radiation recall injuries.

Recent advances in adjuvant treatment have included the expanded use of anthracycline based and taxane based regimens, both of which have been shown to improve disease-free survival (DFS)<sup>27</sup>. Similarly, hormonal therapies have also evolved and are no longer limited to tamoxifen. Most recently, the aromatase inhibitors have been shown to be superior to tamoxifen in the prevention of recurrence<sup>28</sup>. Currently, ongoing research is attempting to determine the optimal timing and/or sequencing of tamoxifen and the aromatase inhibitors therapies. Finally, adjuvant therapies now include targeted molecular strategies, namely trastuzumab which have been shown to improve DFS in selected patient groups<sup>29</sup>.

## NIPPLE DISCHARGE

Nipple discharge remains a common breast symptom, accounting for 5% of breast complaints. Although usually benign in nature, pathological nipple discharge has an associated incidence of malignancy of 9–21%<sup>30</sup>. Drainage

from the nipple is often characterized as milky, green, brown, bloody, serous, cloudy, or purulent. The significance of bloody nipple discharge is its association with papillary lesions or carcinoma<sup>31</sup>. These various discharges are often classified as either physiological (evidence of secretory products) or pathological (serous or bloody in nature). Discharge that is of a physiological nature is often bilateral, from multiple ducts, may vary in color but is most often non-bloody, non-spontaneous, and contains normal proteinaceous material. In contrast, pathological nipple discharge is asymmetrical, limited to one or a few ductal orifices, may be bloody, tests positive on occult blood assay, and can be associated with a mass or imaging abnormality. Recent reports have suggested that association of malignancy and nipple drainage of a non-bloody nature have been underestimated<sup>31</sup>.

## Evaluation of nipple discharge

The goal of evaluation in patients with nipple discharge is to distinguish nipple discharge originating from causes from nipple discharge related to breast cancer. Evaluation of a patient presenting with pathological nipple discharge

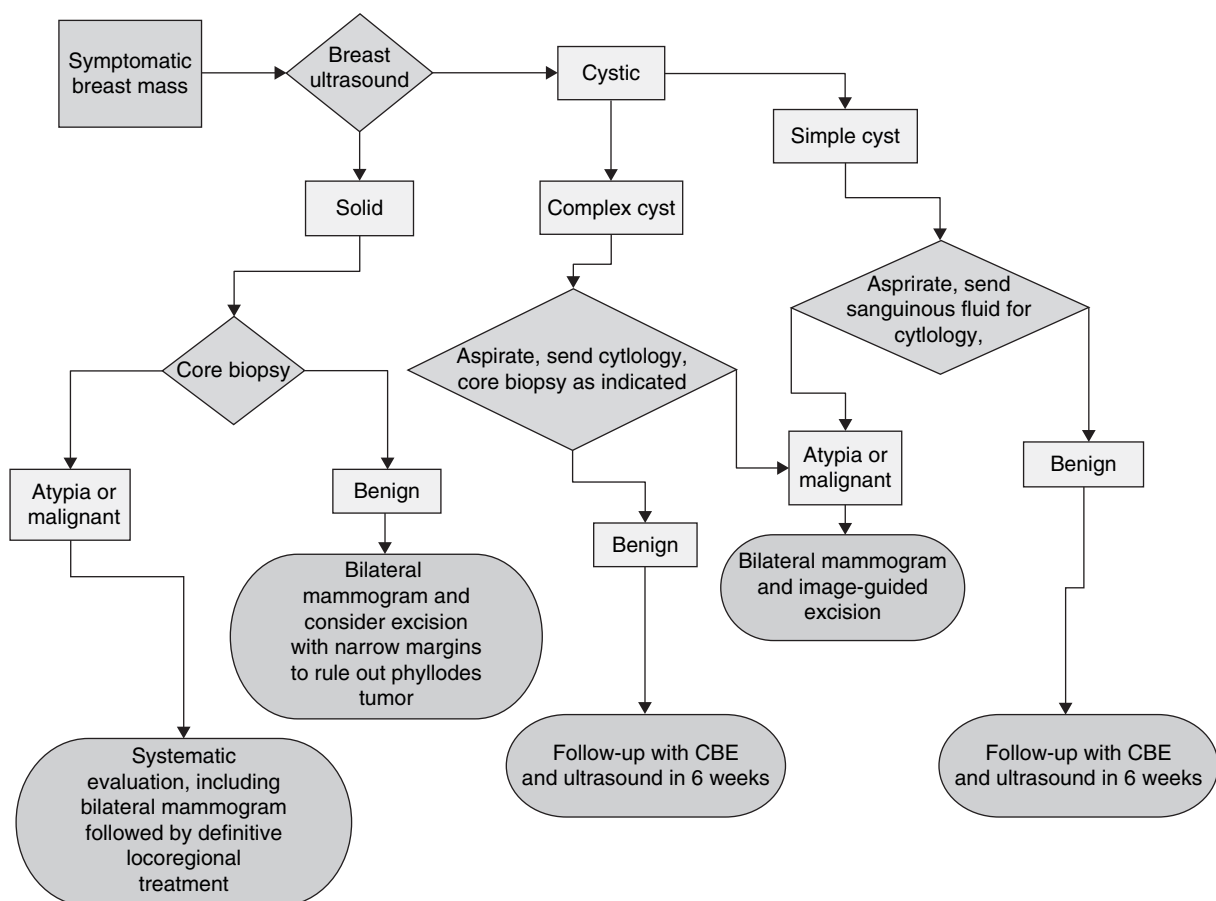


Figure 12.3 Evaluation of symptomatic breast mass algorithm. CBE, clinical breast examination.

begins with a thorough history and physical examination, with careful attention focused on the presence or absence of breast mass, spontaneous or non-spontaneous discharge and any skin changes at the nipple-areola complex. Evaluation is generally only required if a discharge occurs spontaneously in the absence of breast manipulation. History and physical examination are then complemented with bilateral mammogram and breast ultrasound of the involved nipple-areola complex. Any mass identified should be biopsied as described above in the Evaluation of the breast mass section. It should be noted that currently there is no consensus about the use of the various diagnostic tests available to rule out the presence of breast cancer in the patient with nipple discharge<sup>30</sup>. Ductography has recently been revisited in the literature and has been shown to be more sensitive than less invasive methods of evaluation. The sensitivity and specificity of mammography were 10 and 94%, of ultrasonography 36 and 68%, and of ductography 75 and 49%, respectively<sup>32</sup>. Although ductography can provide localizing information and also assess the likelihood of malignancy, definitive diagnosis still requires central or terminal duct excision<sup>33</sup>. Exfoliative cytological examination is useful when positive for cancer or abnormal cytology. However, the high false negative rate does not allow this to be used to definitively exclude cancer<sup>34</sup>. Ductal lavage has had recent popularity as a new procedure for collecting ductal cells using a microcatheter which could potentially improve cell retrieval and so improve the analysis of nipple discharge fluid<sup>35</sup>. Currently, however, it has a more well defined role in the management of high risk breast cancer patients<sup>36</sup>. Recently, breast MRI has enjoyed an increasing diagnostic application for breast cancer. When compared with ultrasonography and galactography, MRI was found to be superior to traditional methods of imaging and demonstrated a sensitivity and specificity of 75% with a positive predictive value of 100%<sup>37</sup>.

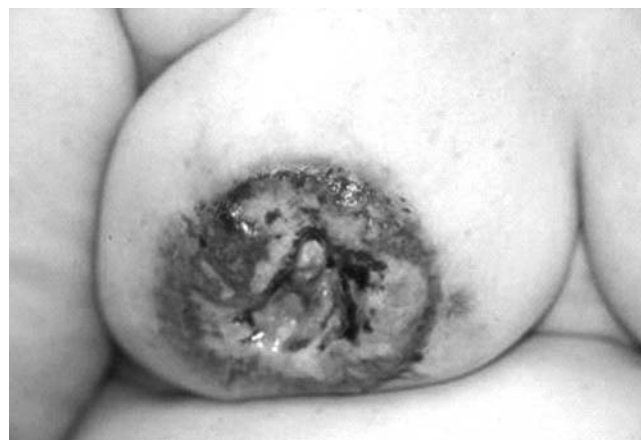### Treatment of nipple discharge

Surgical management of pathological nipple discharge is a function of findings on physical examination, cytology and imaging. Any breast mass detected with CBE or imaging after being biopsied should be excised as indicated for the identified pathology. Duct excision *per se* is indicated when no specific mass can be identified. Wire (needle) localization or intraoperative ultrasound guidance may be useful at the time of excisional biopsy. If the lesion was only identified using ductography, then intraoperative methylene blue injection, lacrimal probe guided excision, or percutaneous hook-wire technique may be required<sup>30</sup>. Some authors have noted that preoperative galactography and intraoperative methylene blue injection may increase the yield of major duct excision. When a patient is found to

have pathological nipple discharge but no associated lesion identified by imaging or physical examination, then complete subareolar duct excision should be performed<sup>32</sup>. Potential implications of the procedure in terms of cosmetic and functional impact on the nipple should be carefully discussed, especially in a younger patient in whom childbearing and lactation may still be a consideration.

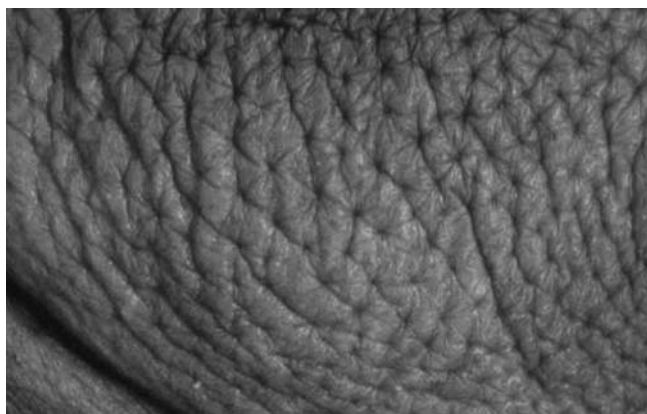### LOCALLY ADVANCED BREAST CANCER

Locally advanced breast cancer (LABC) refers to large breast tumors (>5 cm in diameter) associated with either skin or chest-wall involvement, fixed (matted) axillary lymph nodes, or with spread to the ipsilateral internal mammary or supraclavicular nodes (Figure 12.4)<sup>38</sup>. Since the advent of screening mammography, the percentage of patients diagnosed with LABC has declined<sup>39</sup>. Inflammatory breast cancer, a subtype of LABC, commonly manifests clinically with rapid onset of breast erythema, warmth and dermal edema (peau d'orange) (Figure 12.5). A palpable or dominant mass may or may not be associated with these skin findings. It is staged according to the American Joint Committee on Cancer (AJCC) TNM classification as either IIIB or IV, depending on whether metastases are present. In the past, patients with LABC were routinely treated with radical mastectomy. In fact, the need to gain better local control was a large impetus for Halstead's development of this procedure<sup>10</sup>. Later a series published in 1943 from Memorial Hospital assessed the surgical treatment of patients with LABC. This landmark paper described eight physical findings that at that time made a tumor inoperable including distant metastases, inflammatory carcinoma, supraclavicular lymph node involvement, edema of the arm, satellite breast skin nodules, intercostal



**Figure 12.4** Locally advanced breast cancer. Evidence of skin involvement in a woman who presented with a large palpable breast mass and locally advanced disease. Courtesy of Virginia Herrmann.





**Figure 12.5** Peau d' orange. Common presentation of dermal edema with evidence of skin pitting in patient with inflammatory breast cancer. Courtesy of Virginia Herrmann.

or parasternal nodules, extensive edema of the skin over the breast, and carcinoma that developed during pregnancy or lactation<sup>40</sup>. Although fewer patients with LABC underwent mastectomy as a result of this article, survival rates were unchanged. This latter fact provided impetus for the use of primary radiation therapy in the population of inoperable LABC patients. Despite improvements in techniques, however, results remained disappointing and increasing attention was given to adjuvant and neoadjuvant chemotherapy<sup>40</sup>.

### Prognosis of locally advanced breast cancer

Prognostic factors for LABC do not differ significantly from those of other types of breast cancer presentations. Axillary lymph node status remains the most important prognostic variable. Five-year overall survival for LABC declines as the number of nodes involved increases: overall survival is 72–87% for N0 disease, 73% for one to three positive nodes, and 46% for four or more positive axillary nodes<sup>41</sup>. Women with inflammatory breast cancer commonly have a high rate of lymph node involvement which similarly portends a poorer prognosis. However, additional factors such as erythema involving the whole breast at time of presentation, and the persistence of erythema at the end of chemotherapy have also been shown to predict worse outcome in multivariate analysis<sup>42</sup>. Even with multimodality treatments the overall local recurrence rate for inflammatory breast cancer approaches 30%. The recent MD Anderson experience noted an inflammatory breast cancer survival rate at 15 years of 28% with median survival time of 37 months. Overall survival at 5 and 10 years was 40% and 33%, respectively<sup>43</sup>.

The size of the primary tumor at presentation in the setting of LABC also has prognostic significance. Tumors

between 5 and 6 cm have a 5-year disease-free survival rate of 72%. This decreases to 57% for patients with LABC whose tumor size exceeds 6 cm<sup>44</sup>. Like other forms of breast cancer, an increasing tumor size also predicts a greater likelihood of lymph node involvement. Fisher *et al.* demonstrated that the incidence of nodal involvement was 38% for patients with tumors measuring 1–2 cm, but increased to 63% for those patients with tumor diameters in excess of 6 cm<sup>45</sup>.

Although the incidence of hormonal sensitivity is lower in inflammatory breast tumor when compared with LABC, hormone receptor status does appear to influence prognosis of this disease<sup>46</sup>. Several authors have demonstrated longer disease free survival and overall survival for patients with estrogen or progesterone sensitive LABC and inflammatory breast cancer or for those patients who achieved a rapid and complete remission with chemotherapy<sup>47</sup>. The LABC patient's clinical response and the presence of residual metastatic axillary lymph nodes following neoadjuvant chemotherapy have been identified as important predictors of disease-free survival. Patients with a complete response to neoadjuvant therapy had a much improved disease-free survival compared with those patients with LABC who had a poor clinical response to their primary chemotherapy<sup>48</sup>.

### Evaluation of locally advanced breast cancer

Evaluation of patients with LABC begins with confirmation of the histological diagnosis with a determination of hormone receptor status and HER-2-neu amplification. If a patient has clinical findings of inflammatory breast cancer, then a punch biopsy of the involved skin can often confirm the clinical diagnosis. The characteristic pathological finding of inflammatory breast cancer is dermal lymphatic invasion by carcinoma. Additional systemic evaluation includes liver function tests, complete blood counts, serum chemistry, CT scan of chest, abdomen and pelvis, and a nuclear bone scan. Some authors recommend ultrasonographic staging of the axilla prior to initiation of any treatment<sup>49</sup>. Once metastatic disease has been ruled out a determination of operability needs to be made. This requires tumor characterization using the TNM staging system. Operable tumors include stage IIB and IIIA disease. Inoperable tumors typically include stage IIIB and IIIC disease.

### Treatment of locally advanced breast cancer

The complex management of LABC commonly involves a multidisciplinary approach. Any care plan must be individualized to each patient as the indications for and the sequence of treatments will vary based on stage of disease.

As an example, patients with stage IIB or IIIA breast cancer are often operable. These patients can be offered modified radical mastectomy (MRM) followed by adjuvant systemic therapy and radiotherapy, or they may undergo neoadjuvant chemotherapy in the preoperative period followed by surgery and radiotherapy<sup>50</sup>. Notably when comparing the efficacy of neoadjuvant versus adjuvant chemotherapy, no difference in disease-free survival or overall survival has been demonstrated<sup>51,52</sup>. The main difference noted was an overall increase in BCT in the group of patients who underwent neoadjuvant chemotherapy<sup>53</sup>. Although there are smaller trials which suggest an increase in local recurrence rates for those patients with large tumors who underwent neoadjuvant chemotherapy, this observation has not held up in larger trials such as NSABP B1, and European Organization for Research and Treatment of Cancer (EORTC) trial 10902<sup>51,52</sup>.

The choice of chemotherapy in the treatment of stage IIB and IIIA tumors, whether it be in the pre- or postoperative setting is largely based on clinical data involving women with metastatic breast cancer. Several studies in this metastatic group and two in LABC group have demonstrated superior disease-free survival with anthracycline-containing regimens<sup>54,55</sup>. Furthermore, six cycles of chemotherapy (epirubicin, adriamycin, or vincristine containing regimens) should be administered<sup>56</sup>. Evidence also exists demonstrating improved disease-free survival and overall survival when taxanes are included in the chemotherapy regimen<sup>57,58</sup>. For those patients with stage IIIB, IIIC disease (including inflammatory breast cancer) who are typically deemed inoperable, neoadjuvant chemotherapy should be anthracycline based and may benefit from the addition of a taxane<sup>59</sup>. Additionally, pre- and postmenopausal patients with operable and inoperable hormonally responsive tumors benefit from 5 years of tamoxifen. Improved disease-free survival has also been demonstrated with the use of aromatase inhibitors<sup>60,61</sup>.

Any surgical therapy should generally be undertaken 3 weeks after completion of chemotherapy and after granulocyte and platelet counts have reached their nadir. Attitudes towards locoregional control of LABC have evolved over time. Currently many patients with LABC, with the exception of those with inflammatory breast cancer, are candidates for BCT<sup>62,63</sup>. Predictors of locoregional recurrence and ipsilateral breast tumor recurrence include advanced nodal involvement at diagnosis, residual tumor larger than 2 cm, multifocal residual disease, and lymphovascular space invasion<sup>62</sup>. Consideration for total mastectomy should be given to those patients identified for increased risk of local failures. The goal of any surgery is to achieve the optimal local control within the breast, on the chest wall and within the axilla. In some patients with large bulky tumors or those tumors with an incomplete

response to neoadjuvant chemotherapy, an en bloc chest wall resection may be required. Chest wall closure can present a surgical challenge. Closure techniques range from skin graft, through myocutaneous flaps, fasciocutaneous flaps, to cutaneous and local flaps. For those patients with LABC who undergo mastectomy, reconstruction should be considered. Research has demonstrated that immediate reconstruction does not influence time of detection of chest wall recurrences or overall survival<sup>64</sup>. However, it should be avoided in those patients who have a positive margin at the time of mastectomy as this remains a statistically significant negative predictor of survival<sup>65</sup>. Additionally, timing and use of radiation therapy in relation to breast reconstruction should be discussed with the patient and other members of the multidisciplinary team.

With respect to the postchemotherapy surgical management of inflammatory breast cancer, attention needs to be given to the tendency of this disease to be diffuse and prone to recurrence. As a result of this significant chance for recurrence, BCT is considered inadequate local therapy. Even with optimal therapy including mastectomy, recurrence rates remain high (16%)<sup>66,67</sup>. As such, total mastectomy remains standard care for surgical local control. Radiation therapy can be used after mastectomy in those patients who showed a clinical response to neoadjuvant therapy or before mastectomy to improve probability of resection<sup>68</sup>.

All patients who undergo surgical therapy for the treatment of their LABC require axillary staging. Considerable attention and debate has been devoted to the use of SLN biopsy in LABC and inflammatory breast cancer specifically. Multiple studies advocate the use of SLN biopsy in the setting of neoadjuvant chemotherapy<sup>69,70</sup>. Most recently, the results of NSABP B-27 established the safe use of SLN biopsy after neoadjuvant chemotherapy with a false negative rate of 10.7%. The authors noted no significant differences in false negative rate according to clinical patient and tumor characteristics, method of lymphatic mapping, or breast tumor response to chemotherapy<sup>71</sup>. Furthermore, a recent meta-analysis confirmed these findings, noting an identification rate of 91% and sensitivity of 88%<sup>72</sup>. Fewer data exist regarding the efficacious use of SLN biopsy in patients with inflammatory breast cancer. One study suggests that the false negative rate is unacceptably high (25%) and attributes this finding to dermal lymphatic plugging commonly seen in the setting of inflammatory breast cancer<sup>73</sup>.

## PAGET'S DISEASE

Paget's disease of the breast has been recognized as a clinical entity for more than 125 years, since it was first described

by Sir James Paget in 1874<sup>74</sup>. Classically it is associated with the nipple-areola complex and remains a relatively infrequent event, being associated with only 1–3% of primary breast cancer presentations<sup>75</sup>. Although its presence does not inherently imply the presence of diffuse disease, associated malignancy (*in situ* or invasive) can be seen within the breast, even distant from the nipple itself. Only 10% of cases have disease confined to the nipple<sup>75</sup>. Ductal carcinoma *in situ* is most commonly seen in the setting of pagetoid changes of the nipple areola<sup>76</sup>. Given our current understanding of this malady, Paget's disease should not be considered as a separate category of breast cancer, but rather as an unusual presentation of this neoplasm<sup>77</sup>.

### Evaluation and treatment of Paget's disease

The age on onset of Paget disease is similar to that of other forms of breast cancer. Frequent early complaints are pruritus, burning and hypersensitivity. Clinical findings suggestive of Paget's disease include eczematous change of nipple, cracked, scaly skin, mastitis or cellulitis, or weeping from skin overlying the nipple<sup>77</sup>. Palpable masses are present in 60% of all patients presenting with Paget's disease<sup>78,79</sup>. After a careful history and physical examination have been completed, mammography should be utilized to help identify underlying breast pathology. Ultimately, a high level of clinical suspicion concerning any persistent periareolar skin changes is required in order to not contribute to a delay in diagnosis. Ultimately, a punch biopsy of the involved skin should be able to confirm the presence of pagetoid changes. Once a cancer diagnosis is established, standard chest radiograph and preoperative laboratory studies should be performed.

Historically, Paget's disease has been treated with modified radical mastectomy. Today, primary treatment of Paget's disease still remains surgical but is complemented with adjuvant therapy as dictated by the nature and stage of underlying associated disease. Notably, BCT has seen an ever expanding role in the management of Paget's disease. BCT has been shown to result in local control and survival rates similar to those achieved by mastectomy<sup>80</sup>. Long-term follow-up data for patients with disease amenable to breast conservation treatment and radiotherapy show an overall survival rate of 93% at 5 years and 90% at 10 and 15 years<sup>81,82</sup>. Furthermore, acceptable cosmetic results have been obtained in breast conserving resection of the nipple-areola complex and associated pathology followed by radiation therapy<sup>83</sup>. Mastectomy is now reserved for those patients with contraindications to BCT or radiation therapy. Staging of the axilla is dictated by the nature of the underlying disease.

## LOCOREGIONAL RECURRENCE

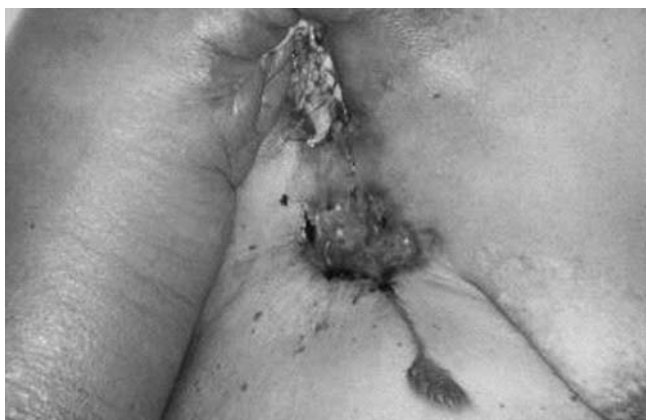Approximately one-third of all breast cancer patients will experience a recurrence of their disease, the majority of which will be systemic in nature. The same advances in breast cancer treatment that have improved survival and palliation are also responsible for increasing the complexity of treatment of recurrent disease. For example, the vast majority of patients with breast cancer now undergo BCT, many of whom will have been treated with neoadjuvant chemotherapy and/or adjuvant radiation. The majority of patients also have hormonally sensitive tumors and will have been treated with adjuvant hormonal therapy. These developments present unique challenges of chemoresistant tumor biology, utilization of newer hormonal agents such as the aromatase inhibitors, and surgical considerations involving irradiated tissue.

### Treatment of ipsilateral breast tumor recurrence

Ipsilateral breast tumor recurrence (IBTR) is associated with a younger age, positive surgical margins and omission of radiotherapy<sup>84</sup>. Ten-year IBTR rates for patients who underwent BCT with radiation were 8.5% compared with 17.2% in those patients in whom radiation therapy was omitted. Additionally, IBTR correlated with a subsequent rate of distant metastases which represents an increased rate of three to five times that of patients without IBTR<sup>85</sup>. Within this patient group, those patients whose breast cancer was associated with initial lymph node metastases or short interval to IBTR were found to be most likely to develop systemic disease<sup>84</sup>. Although some discussion exists regarding repeat attempts at BCT in the setting of IBTR, standard surgical principles would call for an aggressive approach, namely total mastectomy. For the small number of patients who had not previously required any axillary staging, their IBTR should be treated with total mastectomy and sentinel lymph node biopsy. If the patient had previously undergone sentinel lymph node biopsy, then a modified radical mastectomy is indicated. Should the patient with IBTR already have had an axillary lymph node dissection, then total mastectomy is indicated<sup>85</sup>. The addition of adjuvant chemo-, hormonal, or radiotherapies following surgical resection is largely dictated by the patient's previous treatments.

### Treatment of local recurrence after mastectomy

Local recurrence after mastectomy is uncommon with rates as low as 7%, but remains a function of the extent of initial disease<sup>86</sup>. Local recurrence after mastectomy can



**Figure 12.6** Local recurrence of breast cancer postmastectomy. Patient with evidence of disease recurrence within mastectomy scar.

present as a mass within skin flaps, a change in the surgical scar or involvement of regional lymphatics (Figure 12.6). FNA or core biopsy is most helpful in establishing the diagnosis. The appearance of chest wall recurrence is associated with a high rate of systemic metastasis. However, radical chest wall resection in the absence of systemic disease and in the setting of a long disease-free interval has been shown to achieve 5-year overall survival rate of 43–47%<sup>87</sup>. Gilliland *et al.* studied 60 patients with local recurrence after mastectomy and, although surgery resulted in the best method of local control, all patients succumbed to systemic disease<sup>88</sup>. In the absence of systemic disease, surgical management should be considered if technically feasible. Surgical management of local recurrence following mastectomy is often followed by radiotherapy. Should the recurrence be unresectable, then adjuvant radiation and chemotherapy may be utilized in an attempt to improve respectability.

### Treatment of regional nodal recurrence

Although the historical rate of axillary recurrence is low, the incidence may theoretically increase with the mainstream use of SLN biopsy. In patients who have not had axillary staging or have previously undergone SLN biopsy only, any axillary recurrence should be treated with complete axillary node dissection<sup>89</sup>. Regional radiotherapy may be added as dictated by the number of involved lymph nodes, presence or absence of extracapsular extension, or unresectability. Regional recurrences in the internal mammary and supraclavicular nodal basins should be treated with a combination of systemic adjuvant therapy and radiation<sup>90</sup>.

**Table 12.2** Breast cancer survival and TNM stage

Stage	5-year Relative survival rate (%)
0	100
I	98
IIA	88
IIB	76
IIIA	56
IIIB	49
IV	16

From American Cancer Society.

### SUMMARY

The evaluation and management of symptomatic breast cancer can be as varied as the disease itself. However, several principles remain essential so as to ensure accurate diagnosis, staging and treatment. First, the importance of a thorough history and physical examination cannot be understated as they continue to guide the diagnostic algorithm. Additionally, the clinical presentation of breast cancer has clear prognostic implications. Second, obtaining a tissue diagnosis prior to definitive surgical management has largely become standard care. The ever-increasing use of neoadjuvant therapies and the standard use of sentinel lymph node biopsy underscore the benefit and advantages of preoperative pathological identification. Finally, the treatment of breast cancer remains multidisciplinary and should be broached from that perspective. This multispecialty approach to the evaluation and treatment of symptomatic breast cancer allows for efficient and effective patient care. Furthermore, it is the many specific advances in every area of this multidisciplinary approach that have led to improved survival rates (Table 12.2).

### ACKNOWLEDGMENTS

We would like to gratefully acknowledge the administrative assistance provided by Susan Scherer, and the images generously provided by Dr John Metcalf (Medical University of South Carolina, Charleston, SC), Dr William Gillanders (Washington University, St Louis, MO) and Dr Virginia Herrmann (Memorial Hospital, Savannah, GA).

## REFERENCES

1. Baines CJ, Miller AB. Mammography versus clinical examination of the breasts. *J Natl Cancer Inst Monogr* 1997; 22: 125–9.
2. Moss HA, Britton PD, Flower CD et al. How reliable is modern breast imaging in differentiating benign from malignant breast lesions in the symptomatic population? *Clin Radiol* 1999; 54: 676–82.
3. Lister D, Evans AJ, Burrell HC et al. The accuracy of breast ultrasound in the evaluation of clinically benign discrete, symptomatic breast lumps. *Clin Radiol* 1998; 53: 490–2.
4. Saxe A, Phillips E, Orfanou P, Husain M. Role of sample adequacy in fine needle aspiration biopsy of palpable breast lesions. *Am J Surg* 2001; 182: 369–71.
5. Schoonjans JM, Brem R. Fourteen-gauge ultrasonographically guided large-core needle biopsy of breast masses. *J Ultrasound Med* 2001; 20: 967–72.
6. Morris KTPR, Morris A, Schmidt WA et al. Usefulness of the triple test score for palpable breast masses. *Arch Surg* 2002; 136: 1008–12.
7. Cowen PN, Benson EA. Cytological study of fluid from breast cysts. *Br J Surg* 1979; 66: 209–11.
8. Fitzgibbons PL, Page DL, Weaver D et al. Prognostic factors in breast cancer. College of American Pathologists Consensus Statement 1999. *Arch Pathol Lab Med* 2000; 124: 966–78.
9. AJCC Cancer Staging Manual, 6th edn. Springer-Verlag, 2002.
10. Halstead W. The results of radical operations for the cure of carcinoma of the breast. *Ann Surg* 1907; 46: 1–19.
11. Fisher B, Redmond C, Fisher ER et al. Ten-year results of a randomized clinical trial comparing radical mastectomy and total mastectomy with or without radiation. *N Engl J Med* 1985; 312: 674–81.
12. Fisher B, Anderson S, Redmond CK. Reanalysis and results after 12 years of follow-up in a randomized clinical trial comparing total mastectomy with lumpectomy with or without irradiation in the treatment of breast cancer. *N Engl J Med* 1995; 333: 1456–61.
13. Winchester JD, Cox J. Standards for diagnosis and management of invasive breast carcinoma. *CA Cancer J Clin* 1998; 48: 83–107.
14. Clarke DH, Le MG, Sarrazin D et al. Analysis of local-regional relapses in patients with early breast cancers treated by excision and radiotherapy: experience of the Institut Gustave-Roussy. *Int J Radiat Oncol Biol Phys* 1985; 11: 137–45.
15. Esserman L, Hylton N, Yassa L et al. Utility of magnetic resonance imaging in the management of breast cancer: evidence for improved preoperative staging. *J Clin Oncol* 1999; 17: 110–9.
16. Benedict S, Cole DJ, Baron L, Baron P. Factors influencing choice between mastectomy and lumpectomy for women in the Carolinas. *J Surg Oncol* 2001; 76: 6–12.
17. Freedman G, Fowble B, Hanlon A et al. Patients with early stage invasive cancer with close or positive margins treated with conservative surgery and radiation have an increased risk of breast recurrence that is delayed by adjuvant systemic therapy. *Int J Radiat Oncol Biol Phys* 1999; 44: 1005–15.
18. Anscher MS, Jones P, Prosnitz LR et al. Local failure and margin status in early-stage breast carcinoma treated with conservation surgery and radiation therapy. *Ann Surg* 1993; 218: 22–8.
19. Downes KJ, Glatt BS, Kanchwala SK et al. Skin-sparing mastectomy and immediate reconstruction is an acceptable treatment option for patients with high-risk breast carcinoma. *Cancer* 2005; 103: 906–13.
20. Schwartz GF, Guiliano A, Veronesi U. Proceedings of the consensus conference of the role of sentinel lymph node biopsy in carcinoma of the breast, April 19–22, 2001. *Breast J* 2002; 8: 124.
21. Newman L. Lymphatic mapping and sentinel lymph node biopsy in breast cancer patients: a comprehensive review of variation in performance and technique. *J Am Coll Surg* 2004; 199: 804–16.
22. Calhoun KE, Hansen N, Turner RR, Guiliano AE. Nonsentinel lymph node metastases in breast cancer patients with isolated tumor cells in sentinel lymph node: implications for completion axillary dissection. *Am J Surg* 2005; 190: 588–91.
23. Fisher B, Redmond C, Poisson R. Eight-year results of a randomized clinical trial comparing total mastectomy and lumpectomy with or without irradiation in the treatment of breast cancer. *N Engl J Med* 1989; 320: 822–8.
24. Julien J, Bijker N, Fentiman IS et al. Radiotherapy in breast-conserving treatment for ductal carcinoma in situ: first results of the EORTC randomized phase III trial 10853. *Lancet* 2000; 355: 528.
25. Vincini F, Winter K, Straube W et al. A phase I/II trial to evaluate three-dimensional conformal radiation therapy confined to the region of the lumpectomy cavity for Stage I/II breast carcinoma: initial report of feasibility and reproducibility of Radiation Therapy Oncology Group (RTOG) Study 0319. *Int J Radiat Oncol Biol Phys* 2005; 63: 1531–7.
26. Harper JL, Jenrette JM, Vanek KN et al. Acute complications of MammoSite brachytherapy: a single institution's initial clinical experience. *Int J Radiat Oncol Biol Phys* 2005; 61: 169–74.
27. Goble S, Bear HD. Emerging role of taxanes in adjuvant and neoadjuvant therapy for breast cancer: the potential and the questions. *Surg Clin North Am* 2003; 83: 943–71.
28. Thurlimann BKA, Coates AS, Mouridsen H et al. A comparison of letrozole and tamoxifen in postmenopausal women with early breast cancer. *N Engl J Med* 2005; 353: 2747–57.
29. Romond EH, Perez E, Bryant J et al. Trastuzumab plus adjuvant chemotherapy for operable HER2-positive breast cancer. *N Engl J Med* 2005; 353: 1673–84.
30. Cabioglu N, Hunt K, Singletary SE et al. Surgical decision making and factors determining a diagnosis of breast carcinoma in women presenting with nipple discharge. *J Am Coll Surg* 2003; 196: 354–64.
31. Sauter ER, Schlatter L, Lininger J et al. The association of bloody nipple discharge with breast pathology. *Surgery* 2004; 136: 780–5.
32. Adepoju LJ, Chun J, El-Tamer M et al. The value of clinical characteristics and breast-imaging studies in predicting a histopathologic diagnosis of cancer or high-risk lesion in patients with spontaneous nipple discharge. *Am J Surg* 2005; 190: 644–6.
33. Hou MF, Huang TJ, Liu GC. The diagnostic value of galactography in patients with nipple discharge. *Clin Imaging* 2001; 25: 75–81.
34. Dinkel HP, Gassel AM, Muller T et al. Galactography and exfoliative cytology in women with abnormal nipple discharge. *Obstet Gynecol* 2001; 97: 625–9.
35. Dooley WC, Ljung BM, Veronesi U et al. Ductal lavage for detection of cellular atypia in women at high risk for breast cancer. *J Natl Cancer Inst* 2001; 93: 1624–32.
36. Francescatti DS, Kluskens L, Shah L. Ductal lavage in the high-risk patient. *Am J Surg* 2005; 189: 340–1.
37. Ishikawa T, Momiyama N, Hamaguchi Y, Takenchi M. Evaluation of dynamic studies of MR mammography for the diagnosis

- of intraductal lesions with nipple discharge. *Breast Cancer* 2004; 11: 288–94.
38. Singletary SE, Allred C, Ashley P et al. Revision of the American Joint Committee on Cancer Staging System for Breast Cancer. *J Clin Oncol* 2002; 20: 3628–36.
39. Seidman H, Gelb SK, Silverberg E et al. Survival experience in the Breast Cancer Detection Demonstration Project. *CA Cancer J Clin* 1987; 37: 258–90.
40. Haagensen CDSA. Carcinoma of the breast. II: Criteria of operability. *Ann Surg* 1943; 118: 859–70, 1032–51.
41. Carter CL, Allen C, Henson DE. Relation of tumor size, lymph node status and survival in 24,740 breast cancer cases. *Cancer* 1989; 63: 181.
42. Chevallier B, Asselain B, Kunlin A et al. Inflammatory breast cancer. Determination of prognostic factors by univariate and multivariate analysis. *Cancer* 1987; 60: 897–902.
43. Ueno NT, Buzdar A, Singletary SE et al. Combined-modality treatment of inflammatory breast carcinoma: twenty years of experience at M.D. Anderson Cancer Center. *Cancer Chemother Pharmacol* 1997; 40: 321–9.
44. Clark G. Prognostic and Predictive Factors. Philadelphia: Lippincott Williams & Wilkins, 2000.
45. Fisher B, Slack NH, Bross ID. Cancer of the breast: size of neoplasm and prognosis. *Cancer* 1969; 24: 1071.
46. Paradiso A, Tommasi S, Brandi M et al. Cell kinetics and hormonal receptor status in inflammatory breast carcinoma. Comparison with locally advanced disease. *Cancer* 1989; 64: 1922–7.
47. Palangie T, Mosseri V, Mihura J et al. Prognostic factors in inflammatory breast cancer and therapeutic implications. *Eur J Cancer* 1994; 30A: 921–7.
48. Kuerer HM, Newman L, Buzdar AU et al. Residual metastatic axillary lymph nodes following neoadjuvant chemotherapy predict disease-free survival in patients with locally advanced breast cancer. *Am J Surg* 1998; 176: 502–9.
49. Khan A, Sabel M, Nees A et al. Comprehensive axillary evaluation in neoadjuvant chemotherapy patients with ultrasonography and sentinel lymph node biopsy. *Ann Surg Oncol* 2005; 12: 697–704.
50. Wolff AC, Davidson N. Primary systemic therapy in operable breast cancer. *J Clin Oncol* 2000; 18: 1558–69.
51. Van der Hage JA, van de Velde C, Julien JP et al. Preoperative chemotherapy in primary operable breast cancer: results from the European Organization for Research and Treatment of Cancer trial 10902. *J Clin Oncol* 2001; 19: 4224–37.
52. Wolmark N, Wang J, Mamounas E et al. Preoperative chemotherapy in patients with operable breast cancer: nine-year results from National Surgical Adjuvant Breast and Bowel Project B-18. *J Natl Cancer Inst Monogr* 2001; 30: 96–102.
53. Makris A, Powles T, Ashley SE et al. A reduction in the requirements for mastectomy in a randomized trial of neoadjuvant chemohormonal therapy in primary breast cancer. *Ann Oncol* 1998; 9: 1179–84.
54. Casper ES, GC, Bosl GJ et al. Combined modality treatment of locally advanced breast cancer: adjuvant combination chemotherapy with and without doxorubicin. *Breast Cancer Res Treat* 1987; 9: 39–44.
55. Falkson G, Tomey D, Carey P et al. Long-term survival of patients treated with combination chemotherapy for metastatic breast cancer. *Eur J Cancer* 1991; 27: 973–7.
56. Mouridsen HT, AJ, Andersson M et al. Adjuvant anthracycline in breast cancer. Improved outcome in premenopausal patients following substitution of methotrexate in the SMF combination with epirubicin. *Prog Proc Am Soc Clin Oncol* 1999; 18: 68a.
57. Henderson IC, Berry D, Demetri GD et al. Improved outcomes from adding sequential paclitaxel but not from escalating doxorubicin dose in an adjuvant chemotherapy regimen for patients with node positive primary breast cancer. *J Clin Oncol* 2003; 21: 976–83.
58. Mamounas E, BJ, Lembersky BC et al. Paclitaxel following doxorubicin/cyclophosphamide as adjuvant chemotherapy for node positive breast cancer: Results from NSABP B-28. *Prog Proc Am Soc Clin Oncol* 2003; 22: 4.
59. Smith IC, Heys S, Hutcheon AW et al. Neoadjuvant chemotherapy in breast cancer: significantly enhanced response with docetaxel. *J Clin Oncol* 2002; 20: 1456–66.
60. Albain KS, GS, Ravdin PM et al. Adjuvant chemohormonal therapy for primary breast cancer should be sequential instead of concurrent: initial results of Intergroup Trial 0100 (SWOG-8814). *Prog Proc Am Soc Clin Oncol* 2002; 21: 37.
61. Winer EP, Hudis C, Burstein HF et al. American Society of Clinical Oncology technology assessment on the use of aromatase inhibitors as adjuvant therapy for women with hormone receptor-positive breast cancer: status report 2002. *J Clin Oncol* 2002; 20: 3317–27.
62. Chen AM, Meric-Bernstam F, Hunt KK et al. Breast conservation after neoadjuvant chemotherapy: the MD Anderson cancer center experience. *J Clin Oncol* 2004; 22: 2303–12.
63. Schwartz GF, Meltzer A, Lucarelli EA et al. Breast conservation after neoadjuvant chemotherapy for stage II carcinoma of the breast. *J Am Coll Surg* 2005; 201: 327–34.
64. Langstein HN, Cheng M, Singletary SE et al. Breast cancer recurrence after immediate reconstruction: patterns and significance. *Plast Reconstr Surg* 2003; 111: 712–20.
65. Chin PL, Andersen J, Somlo G et al. Esthetic reconstruction after mastectomy for inflammatory breast cancer: is it worthwhile? *J Am Coll Surg* 2000; 190: 304–9.
66. Fields JN, Perez C, Kuske RR et al. Inflammatory cancer of the breast: treatment results in 107 patients. *Int J Radiat Oncol Biol Phys* 1989; 17: 249–55.
67. Brun B, Otmazquaine Y, Feuilhade F et al. Treatment of inflammatory breast cancer with combination chemotherapy and mastectomy versus breast conservation. *Cancer* 1988; 61: 1096–103.
68. Liao Z, Strom E, Buzdur AM et al. Locoregional irradiation for inflammatory breast cancer: effectiveness of dose escalation in decreasing recurrence. *Int J Radiat Oncol Biol Phys* 2000; 47: 1191–200.
69. Cohen LF, Breslin TM, Kuerer HM et al. Identification and evaluation of axillary sentinel lymph nodes in patients with breast carcinoma treated with neoadjuvant chemotherapy. *Am J Surg Pathol* 2000; 24: 1266–72.
70. Sabel MS, Schott AF, Kleer CG et al. Sentinel node biopsy prior to neoadjuvant chemotherapy. *Am J Surg* 2003; 186: 102–5.
71. Mamounas EP, Brown A, Anderson S et al. Sentinel node biopsy after neoadjuvant chemotherapy in breast cancer: results from National Surgical Adjuvant Breast and Bowel Project Protocol B-27. *J Clin Oncol* 2005; 23: 2694–702.
72. Xing Y, Foy M, Cox DD et al. Meta-analysis of sentinel lymph node biopsy after preoperative chemotherapy in patient with breast cancer. *Br J Surg* 2006; 93: 539–46.
73. Stearns V, Ewing C, Slack R et al. Sentinel lymphadenectomy after neoadjuvant chemotherapy for breast cancer may reliably represent the axilla except for inflammatory breast cancer. *Ann Surg Oncol* 2002; 9: 235–42.
74. Paget J. On disease of the mammary areola preceding cancer of the mammary gland. *St. Bartholomew's Hosp Rep* 1874; 10: 87.

75. Lagios MD, Westdahl P, Rose MR, Concannon S. Paget's disease of the nipple: alternative management in cases without or with minimal extent of underlying breast carcinoma. *Cancer* 1984; 54: 545.
76. Page DC, Steel C, Dixon JM. ABC of breast diseases: carcinoma in situ and patients at high risk of breast cancer. *BMJ* 1995; 310: 39.
77. Bulens P, Vanuytsel L, Rijnders A, van der Schueren E. Breast conserving treatment of Paget's disease. *Radiother Oncol* 1990; 17: 305–9.
78. el-Sharkawi A, Waters JS. The place for conservative treatment in the management of Paget's disease of the nipple. *Eur J Surg Oncol* 1992; 18: 301–3.
79. Ashikari R, Park K, Huvo AG, Urban JA. Paget's disease of the breast. *Cancer* 1970; 26: 680–5.
80. Kawase K, Dimaio DJ, Tucker SL et al. Paget's disease of the breast: there is a role for breast-conserving therapy. *Ann Surg Oncol* 2005; 12: 391–7.
81. Marshall JK, Griffith KA, Haffty BG et al. Conservative management of Paget disease of the breast with radiotherapy: 10- and 15-year results. *Cancer* 2003; 97: 2142–9.
82. Bijker N, Rutgers E, Duchateau L et al. Breast-conserving therapy for Paget disease of the nipple: a prospective European Organization for Research and Treatment of Cancer study of 61 patients. *Cancer* 2001; 91: 472–7.
83. Pezzi CM, Kukora JS, Audet IM et al. Breast conservation surgery using nipple-areolar resection for central breast cancers. *Arch Surg* 2004; 139: 32–7.
84. Komoike Y, Akiyama F, Iino Y et al. Ipsilateral breast tumor recurrence (IBTR) after breast-conserving treatment for early breast cancer. *Cancer* 2006; 106: 35–41.
85. Lannin D, Haffty B. End results of salvage therapy after failure of breast-conservation surgery. *Oncology* 2004; 18: 272–9.
86. Medina-Franco H, Vasconez LO, Fix RJ et al. Factors associated with local recurrence after skin-sparing mastectomy and immediate breast reconstruction for invasive breast cancer. *Ann Surg* 2002; 235: 814–9.
87. Toi M, Tanaka S, Bando M, Tominaga T. Outcome of surgical resection for chest wall recurrence in breast cancer patients. *J Surg Oncol* 1997; 64: 23–6.
88. Gilliland MD, Barton R, Copeland EM. The implications of local recurrence of breast cancer as the first site of therapeutic failure. *Ann Surg* 1983; 197: 284–7.
89. de Boer R, Hillen HF, Roumen RM et al. Detection, treatment and outcome of axillary recurrence after axillary clearance for invasive breast cancer. *Br J Surg* 2001; 88: 118–22.
90. Clemons M, Hamilton T, Mansi J, Goss P. Management of recurrent locoregional breast cancer: oncologist survey. *Breast* 2003; 12: 328–37.

# Oncoplastic surgery for breast cancer

13

Judy C Boughey, Kelly K Hunt and Elisabeth K Beahm

---

## INTRODUCTION

For many women with stage I or II breast cancer, the combination of partial mastectomy and radiation therapy – together referred to as breast-conserving therapy (BCT) – is preferable to total mastectomy because BCT produces survival rates equivalent to those after total mastectomy while preserving the breast<sup>1</sup>. Six prospective randomized trials have shown that overall and disease-free survivals are similar with BCT and mastectomy (Table 13.1)<sup>2–7</sup>. These same studies also evaluated local recurrence rates; four found that local recurrence rates were similar for BCT and mastectomy, and two showed higher local recurrence rates with BCT (Table 13.2). However, in the two of these three studies showing higher recurrence rates with BCT, the criteria for histologically negative margins were not clear. Recent data from the Early Breast Cancer Trialists' Collaborative Group<sup>9</sup> showed that avoidance of local recurrence translates into a survival advantage. BCT is considered oncologically equivalent to mastectomy.

BCT use has been increasing in recent years because of several factors. First, screening has resulted in increased detection of early-stage breast cancers. Second, the increasing use of adjuvant chemotherapy and endocrine therapies has resulted in lower risk of ipsilateral breast tumor events. Third, the introduction of preoperative chemotherapy for patients with operable breast cancer has meant that some tumors initially too large to be treated with BCT ultimately shrink enough to be amenable to this treatment approach.

In addition to being equivalent to mastectomy in terms of oncological safety, BCT offers advantages over mastectomy in terms of quality of life and esthetic outcomes. BCT retains the original breast, which has several benefits, including preservation of breast shape and skin, preservation of sensation and the psychological advantage associated with breast preservation. Mastectomy with breast reconstruction can replace the breast mound and restore the patient's body image. However, with autologous tissue breast reconstruction, there can be significant donor site morbidity (scarring and functional loss), and with implant-based breast reconstruction, there can be complications

such as capsular contracture, infection and extrusion. In addition, after mastectomy, women lack sensation along the chest wall and in the reconstructed breast mound. Finally, the psychological effects of mastectomy ('breast amputation') can be deleterious.

Quality of life after breast surgery is affected by preservation of the breast, preservation of function, cosmetic results, treatment duration, and convenience. All of these factors must be considered in the assessment of a patient who appears to be an appropriate candidate for BCT.

However, reports suggest that in 10–35% of patients who undergo BCT, esthetic outcomes are suboptimal<sup>10–14</sup>, and some patients with suboptimal outcomes eventually seek additional corrective surgery. In patients at risk for a suboptimal esthetic outcome after partial mastectomy, oncoplastic breast surgery – partial mastectomy to remove the tumor followed immediately by simple plastic surgery to improve the esthetic outcome – can potentially decrease the need and magnitude of surgery necessary for correction.

## GOALS OF ONCOPLASTIC BREAST SURGERY

The term oncoplastic is derived from the Greek 'onco', meaning tumor, and 'plastic', meaning to mould, and combines oncological principles with plastic surgical techniques. In the setting of breast-conserving surgery, oncoplastic surgery means that after appropriate excision of the cancer, the remaining breast tissue is reshaped to achieve the best possible esthetic result. The goals of oncoplastic breast surgery are to:

- Resect the tumor with adequate oncological margins
- Completely remove all imaging-detected abnormalities
- Obtain pathologically negative margins
- Retain natural breast size and contour and improve cosmetic results and symmetry
- Simplify recovery compared with the recovery associated with major reconstructive procedures



**Table 13.1** Survival comparisons for breast-conserving therapy (BCT) and radiation versus mastectomy in prospective randomized trials

Trial	Follow-up time (years)	Number of patients	Overall survival (%)			Disease-free survival (%)		
			BCT	Mastectomy	p Value	BCT	Mastectomy	p Value
Milan <sup>2</sup>	18	701	65	65	NS			
Institut Gustave-Roussy <sup>3</sup>	15	179	73	65	0.19			
NSABP B-06 <sup>4</sup>	12	1219	63	59	0.12	50	49	0.21
National Cancer Institute <sup>5</sup>	10	237	77	75	0.89	72	69	0.93
EORTC <sup>6</sup>	10	874	65	66	NS			
Danish Breast Cancer Group <sup>7</sup>	6	904	79	82	NS	70	66	NS

EORTC, European Organization for Research and Treatment of Cancer; NSABP, National Surgical Adjuvant Breast and Bowel Project; NS, not significant.

Adapted from reference 8.

**Table 13.2** Local recurrence rates in prospective randomized trials of breast-conserving therapy (BCT) and mastectomy

Trial	Follow-up time (years)	BCT (%)	Mastectomy (%)	p Value
Milan <sup>2</sup>	18	7	4	NS
Institut Gustave-Roussy <sup>3</sup>	15	9	14	NS
NSABP B-06 <sup>4</sup>	12	10	8	
National Cancer Institute <sup>5</sup>	Median follow-up of 10.1	19	6	0.01
EORTC <sup>6</sup>	10	20	12	0.01
Danish Breast Cancer Group <sup>7</sup>	Median follow-up of 3.3	3	4	NS

NSABP, National Surgical Adjuvant Breast and Bowel Project; EORTC, European Organization for Research and Treatment of Cancer; NS, not significant.

Adapted from reference 8.

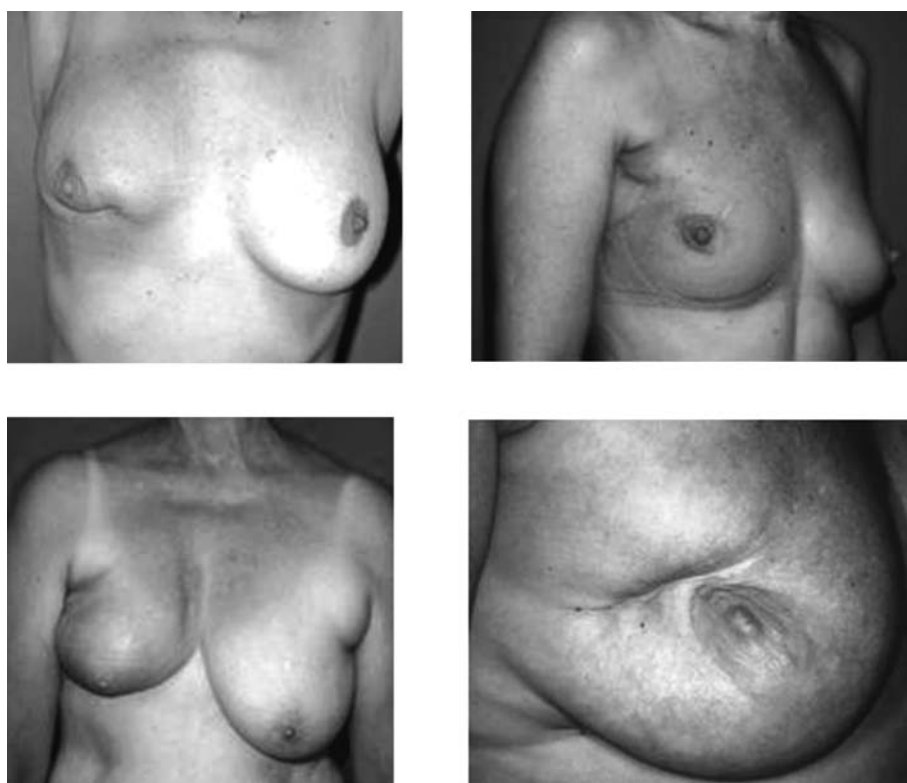
- Minimize disturbance of surrounding body structures (muscle, nerve and skin).

## COSMETIC CHALLENGES OF THE PARTIAL MASTECTOMY

The usual operative technique for partial mastectomy involves making an incision directly over the tumor, excising the tumor with a margin of normal tissue, and then closing the skin without reapproximating any breast

tissue beneath the incision. Several deformities can occur as a result of this approach (Figure 13.1), including:

- Volumetric deformity – large parenchymal resection
- Retraction deformity – a deformity in the breast that becomes apparent as the seroma absorbs over time
- Skin–pectoral muscle adherence deformity – adherence of the skin to the pectoral muscle
- Lower pole deformity – downward turning of the nipple due to excision of a tumor in the lower hemisphere



**Figure 13.1** Defects after partial mastectomy, including (a) lower pole deformity with skin and parenchymal loss, (b) nipple malposition and retraction, (c) volume asymmetry, and (d) contour asymmetry. Photographs (b) and (c) courtesy of the late Dr Stephen Kroll.

of the breast with a circumareolar rather than a radial incision.

Such deformities can make it difficult for a patient to wear bras and certain types of clothing and she may require a prosthesis to improve symmetry.

## PATIENT SELECTION CRITERIA FOR ONCOPLASTIC BREAST SURGERY

In patients with early-stage breast cancer, whether oncoplastic breast surgery is appropriate depends on several factors, including the extent of the planned resection, the tumor location, and the patient's breast size and body habitus. In general, oncoplastic techniques should be considered when a significant area of skin needs to be resected with the specimen, a large-volume defect is expected, the tumor is located in an area associated with unfavorable cosmetic outcomes (e.g. between the nipple and the inframammary fold), or excision may result in nipple malposition. Key factors influencing patient selection for oncoplastic breast surgery are discussed in more detail below.

In all cases, patients need to participate in the decision-making process in order to maximize their

satisfaction with treatment outcomes. Assessment of patient satisfaction and quality of life after breast cancer treatment is highly problematic, but cumulative assessment suggests that patient satisfaction after reconstructive breast surgery largely correlates with the degree of their involvement in the process and has little concordance with physicians' assessment of outcomes. Medical oncologists, radiation oncologists, surgical oncologists, and plastic surgeons must work together to help guide patient decisions. Initial satisfaction with risk reduction and cure may fade over time if patients are not satisfied with the appearance of the breast.

## Extent of resection

It is not the absolute defect volume but rather the ratio of the defect volume to the volume of the remaining breast parenchyma that is important in determining whether oncoplastic breast surgery is appropriate. A large defect in a large breast is better tolerated than a large defect in a small breast. In patients with a small breast, even a small defect can create a big problem. Oncoplastic surgery should be considered when the anticipated defect is greater than 20–30% and any resection in the lower breast (see below regarding tumor location).

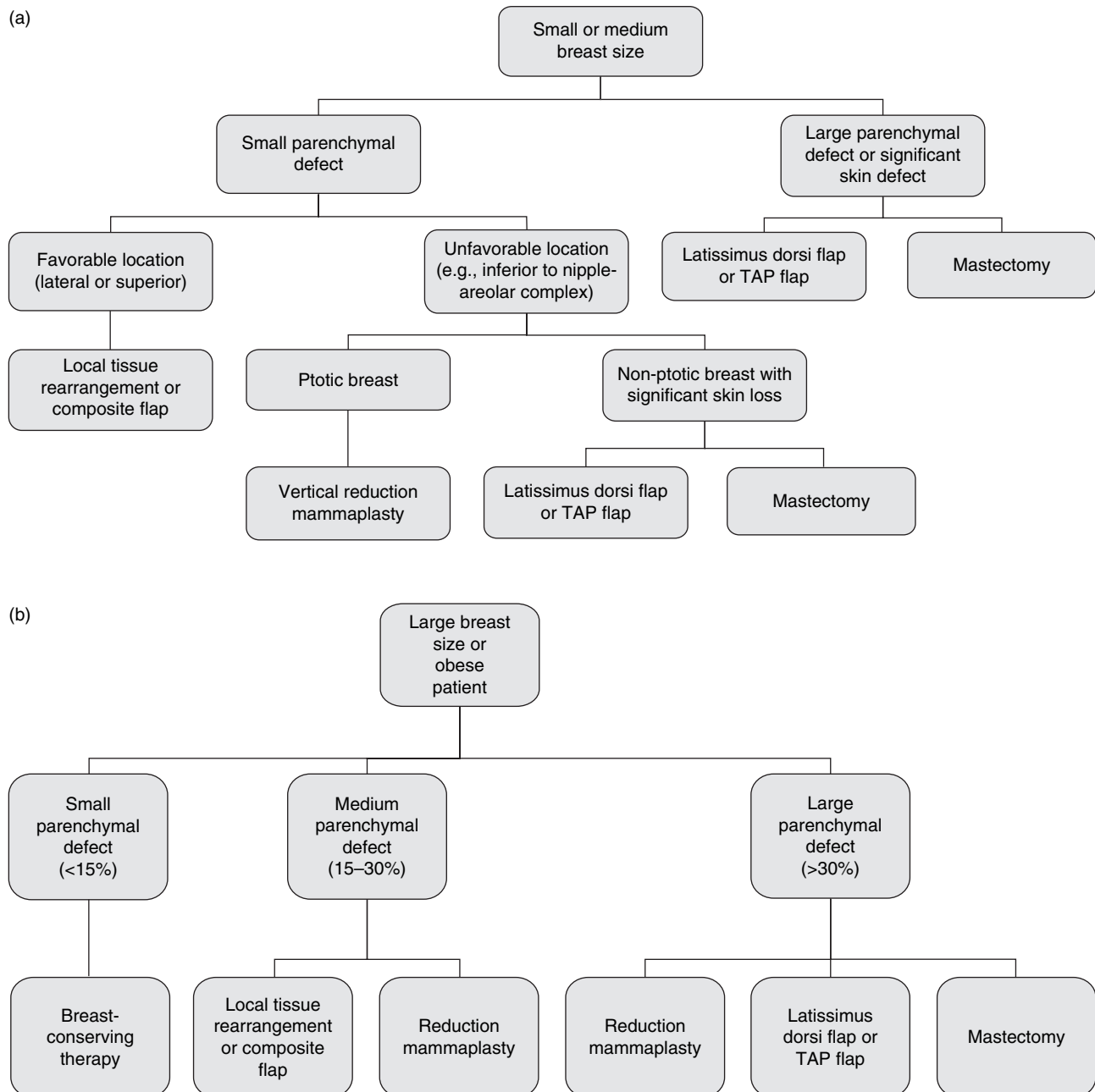
## Breast size and body habitus

Obese patients and patients with large breasts are optimal candidates for tumor resection and bilateral reduction mammoplasty performed with the assistance of a plastic surgeon. Breast reduction strategies can permit good esthetic outcomes after resection of large volumes at any location in the breast. Obese patients present a challenge when considering total mastectomy as they are often poor candidates for autologous tissue reconstruction (especially transverse rectus abdominis myocutaneous (TRAM) flap), and implants

are not large enough to recreate a proportional breast for their body size. In these patients, breast reduction surgery remains the best option for partial mastectomy defects and at the same time can relieve their symptoms of macromastia. Algorithms for immediate reconstruction techniques in partial mastectomy are shown in Figure 13.2.

## Tumor location

Tumors under the nipple-areolar complex, tumors between the nipple-areolar complex and the inframammary fold, and



**Figure 13.2** Treatment algorithm for immediate reconstruction after partial mastectomy. Recommended surgical approach with (a) small or medium breasts and (b) large or ptotic breasts. TAP, thoracodorsal artery perforator.

tumors with a significant superomedial component must be managed very carefully to avoid significant nipple-areolar complex distortion and contour deformity. Unless there is a compensatory adjustment of skin and well-vascularized parenchyma to correct for removal of breast parenchyma in these areas, contour deformities will develop and persist (although they may be masked by edema and seroma in the immediate postoperative period) and will be exacerbated by radiation. Contour deformities are significant because options to correct these deformities secondarily are limited and technically challenging and the results of secondary correction are usually deemed unsatisfactory by patients.

### Other factors

Other factors that have been shown to be associated with worse esthetic outcome after BCT include older age, inner as opposed to outer quadrant tumor location, a radiation boost (compared with no boost), radiation therapy with iridium as opposed to electrons, smaller breast size, scar orientation not along skin creases, need for re-excision for margin control, need for axillary lymph node dissection, and greater extent of surgery.

Extent of surgery can be assessed by estimating the specimen weight, the specimen volume and the specimen volume as a percentage of the breast volume. Resection of less than 100 cm<sup>3</sup> results in better cosmesis than when larger volumes are resected<sup>15</sup>. The total breast volume can be estimated from a mammogram using the formula for a cone:  $V = 1/3\pi r^2 h$ , where  $h$  is the height of the breast off the chest wall and  $2r$  is the diameter of the breast. Patients respond to radiation differently, and therefore patients with similar volumes of resection in breasts of similar size may have very different outcomes depending on their idiosyncratic response to radiation. Fatty replaced breasts tend to have a worse cosmetic outcome after radiation than dense breasts.

### Timing

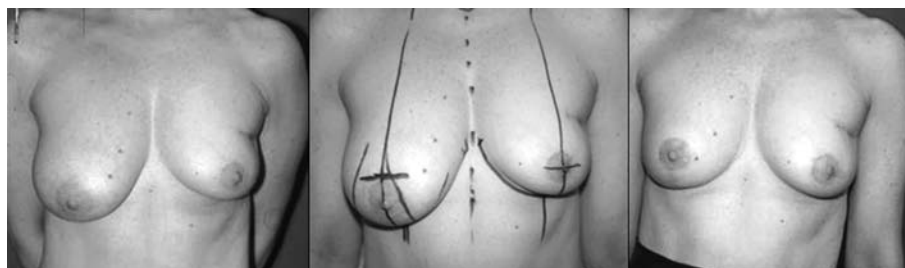The timing of reconstruction after partial mastectomy is a much-debated topic. In general, reconstruction prior to radiation therapy is the optimal situation. If it is anticipated that the oncological resection will leave a significant deformity, oncoplastic techniques with tissue advancement and local tissue rearrangement at the time of the initial operation are the easiest and optimal solution. This does not usually lead to any delay in delivery of adjuvant therapy, does not require any additional trips to the operating room, and does not involve transposition or violation of any muscle, fat, or skin from other areas. If local tissue transfers are required, these should be performed prior to radiation therapy as they are not an option after

radiation therapy. It is also preferred to perform breast reduction prior to radiation. Tissue expanders and implants are not a good option for repair of partial mastectomy defects in any time frame due to long-term complications with the interface of a prosthetic device in a radiated bed. Fibrous capsular contracture, distortion, infection, and eventual implant loss may occur in this setting.

Reconstruction of the ipsilateral breast after radiation therapy should be delayed until resolution of edema and radiation-related changes. Some surgeons suggest waiting 3 years for complete resolution of these changes, prior to beginning reconstruction. Considering reconstruction 1–2 years after radiation therapy has been completed, provided the clinical picture is favorable and radiation changes appear stable, is quite reasonable in most cases<sup>16,17</sup>. In a delayed setting, tissue expanders and implants are not a good option for repair of partial mastectomy defects due to long-term complications noted above. Breast reduction in a delayed setting carries a very high complication rate. In this irradiated tissue, tissue loss, seroma formation and infection are common. The use of remote vascularized tissue from outside the radiation field is the most tenable option for reliable repair of delayed partial mastectomy defects. Alternatively, if a volume defect is the main deformity, contralateral adjustment or mastopexy may be the better option as this avoids manipulation of the irradiated breast. In general, manipulation of an irradiated breast should be minimized since even when the skin changes associated with irradiation have resolved, healing and recovery remain impaired.

### Symmetry

Partial mastectomy can result in volume deformity, contour deformity, or a combination of volume and contour deformity. Most women have a slight volume discrepancy between their breasts, and when a tumor involves the smaller breast and a significant amount of tissue needs to be resected, further asymmetry between the breasts will result. In such cases, a contralateral breast reduction can be performed either during the same operation when the oncological surgery is performed or later – once the pathological analysis has been finalized, radiation therapy has been completed, and the overall cosmetic result, breast shape and breast volume have been assessed. The question of how much to over-correct the deformity due to the effects of radiation is unclear. In general it is felt that irradiation of the breast results in a 10–20% decrease in breast size, and this has been a general approach, but not well defined volumetrically. In a delayed setting, contralateral reduction is usually delayed until at least 12–24 months after completion of radiation therapy to ensure a stable contour and volume (Figure 13.3). A bilateral mammogram



**Figure 13.3** Delayed correction of asymmetry after partial mastectomy. (a) This patient presented 2.5 years after partial mastectomy and irradiation of the left breast requesting improved symmetry. (b) The index breast was generally well shaped, apart from a superolateral contour deformity, yet quite discrepant in volume in comparison to the untreated breast. In this case, as the patient desired minimal intervention and did not mind a smaller breast volume, modification of the contralateral, untreated breast was deemed the optimal approach for restoring symmetry. A parenchymal pedicle approach to reduction mammoplasty was utilized, applying the dimensions of the irradiated breast to the contralateral side to achieve symmetry. (c) The patient's 4-year postoperative result is demonstrated.

must be obtained prior to undertaking a contralateral reduction to make sure no cancer is present in either breast.

In cases in which contour deformity is the main problem, the best approach is to repair the deformity prior to radiation. The deformity would be exaggerated by radiation treatment, and local tissue rearrangement and/or breast reduction are a good option for correction of the deformity prior to radiation therapy. Unfortunately, while appealing, local rearrangement of the radiated tissues will simply not work. This approach will instead lead to numerous complications including seroma formation, infection, tissue loss, and scarring. If the defect is due to a tissue deficit, this deficit must be corrected with remote tissue and, in accordance with the above rationale, the tissue flap used to correct the deformity, is usually overcompensated by 20% to allow for shrinkage during radiation therapy.

Cases with both volume and contour deformity offer the biggest challenge. In this situation, tissue flaps or, if the breast size allows, breast reduction are the best options.

### Re-excision for margin control

If a margin is found to be positive on final pathology review, re-excision of that margin is required. If the patient already has a volume or contour deformity of the breast, consultation with a plastic surgeon prior to re-excision may be beneficial, and a combined procedure can be planned for the re-excision. If the specimen was oriented and inked properly, only the involved margin(s) need to be re-excised. If all margins are positive, mastectomy should be considered depending on the volume required to obtain clear margins. If the clips placed to mark the initial resection margin are excised during the re-excision, new clips should be placed to mark the new margin so that clips remain outlining the final cavity for radiation planning.

### PREOPERATIVE PLANNING FOR ONCOPLASTIC BREAST SURGERY

Whenever possible, the diagnosis of breast cancer should be confirmed by core needle biopsy before surgery because this practice has been shown to decrease the number of operative procedures and increase the chance of achieving negative margins of resection with a single operative procedure<sup>18</sup>.

The extent of involvement of the breast by invasive and non-invasive disease should be assessed using physical examination along with imaging studies – mammography, sonography of the breast and nodal basins, and, in selected cases, magnetic resonance imaging. Once the extent and location of disease are known, the operation can be planned.

Careful planning of the resection is the key to successful oncoplastic surgery. Preoperative review of the images facilitates decision-making regarding the appropriate localization technique (mammography or sonography), the number of needles to be placed for marking the extent of disease, and the best placement of the incision. The area to be resected must be identified, and the volume to be resected must be estimated. It is important to center the lesion in the partial mastectomy specimen to minimize the amount of normal tissue that must be resected to obtain a negative margin.

The skin incision should be planned and the patient should be marked while the patient is either sitting or standing. The important areas to mark are the midline of the chest, the inframammary fold and the point of maximal projection of the breast (i.e. where a vertical line that passes through the nipple intersects the inframammary fold). If skin is to be excised along with breast parenchyma, the skin excision should be designed to allow exposure to the tumor and cosmetic closure, and the skin and tumor should be resected en bloc.

Patients with large primary tumors may benefit from neoadjuvant (preoperative) chemotherapy to shrink the tumor. In patients with tumors that are initially too large to permit BCT, neoadjuvant chemotherapy may make BCT possible. Survival and local recurrence rates are similar for patients treated with neoadjuvant chemotherapy followed by breast-conserving surgery and patients treated with breast-conserving surgery followed by adjuvant chemotherapy. In patients who are candidates for BCT at initial presentation, neoadjuvant chemotherapy may reduce the volume of tissue that has to be resected and thereby lead to improved cosmesis<sup>19</sup>.

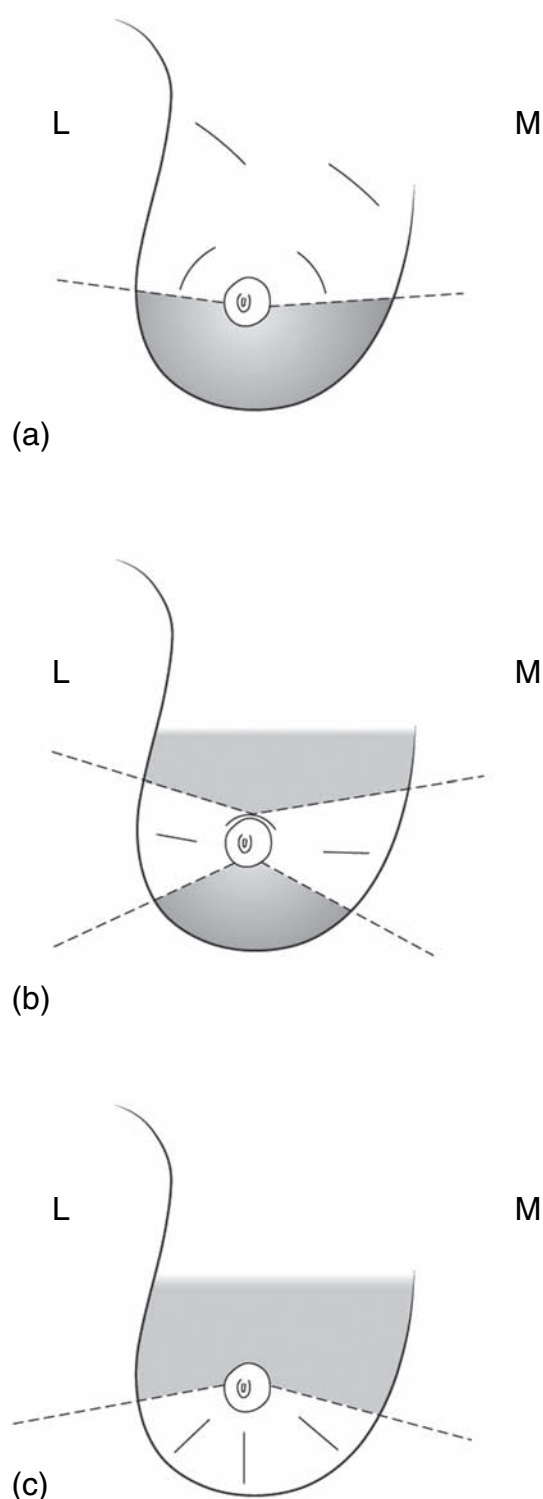
Pathological complete response rates with neoadjuvant chemotherapy have been reported to be 10–20% with anthracycline-based therapy and 30% with the combination of anthracycline and a taxane. The addition of trastuzumab in patients with HER-2/neu-overexpressing breast cancer has led to pathological complete response rates as high as 65%<sup>20</sup>. In women with estrogen-receptor-positive tumors, neoadjuvant hormonal therapy has been used successfully in Europe and the UK and is currently being evaluated in the American College of Surgeons Oncology Group Z1031 trial. In the European and UK experience, neoadjuvant endocrine therapy was able to decrease tumor size and allow for improved rates of BCT in women with estrogen-receptor-positive tumors.

When resecting lesions in the upper outer quadrant care should be taken with the placement of the axillary incision and breast incision especially when a reduction mammoplasty is performed, to ensure an adequate skin bridge is left between the two incisions. When performing sentinel node surgery the incision should be placed such that it can be used for a completion axillary dissection if indicated and not just placed directly over the hotspot detected with the hand-held probe.

## TECHNICAL ASPECTS OF PARTIAL MASTECTOMY

### Skin incision

The skin incisions used for partial mastectomy should be centered over the tumor. In general, above the nipple, curvilinear incisions following Langer's lines (concentric lines parallel to the edge of the areola) or Kraissl's lines (natural horizontally oriented skin creases) are optimal. Radial incisions above the nipple cause nipple elevation. Below the nipple, incisions should be oriented along Kraissl's lines, or, if wide excisions or skin resections are planned, radial incisions are recommended (Figure 13.4) to avoid downward retraction of the nipple. Skin incisions should be planned such that if a mastectomy is ultimately required



**Figure 13.4** Skin incisions. Incisions superior to the nipple (a) should preferentially be circumareolar. If this is untenable then curvilinear incisions should be utilized to avoid undue scar contracture. An effort should be made to avoid medial incisions that will be visible in clothing with a lower neck line. Necessary incisions in the medial and lateral aspects (at the 3 o'clock and 9 o'clock areas) (b) should be radial but if possible, preferentially periareolar. Incisions inferior to the nipple (c) should usually be radial. In all cases, incisions should be oriented so that they can be incorporated into a mastectomy flap should conversion to mastectomy be required. L, lateral; M, medial.

for margin control, the incision site can be comfortably included within the mastectomy skin island. At the 3 o'clock and 9 o'clock positions, radial incisions are the most favorable. Utilization of a parallelogram skin incision allows removal of a larger area of skin with better access to the tumor and more cosmetic closure. Circumareolar skin incisions can achieve a good cosmetic result but should not be used for lesions located in the periphery of the breast because tunneling through the breast should be avoided.

Planning the skin incision while the patient is in a sitting or standing position allows better evaluation of skin lines and tension along those lines than does planning the incision while the patient is supine. If a tumor is superficial, overlying skin may need to be resected with the specimen; however, skin does not need to be resected routinely for every tumor.

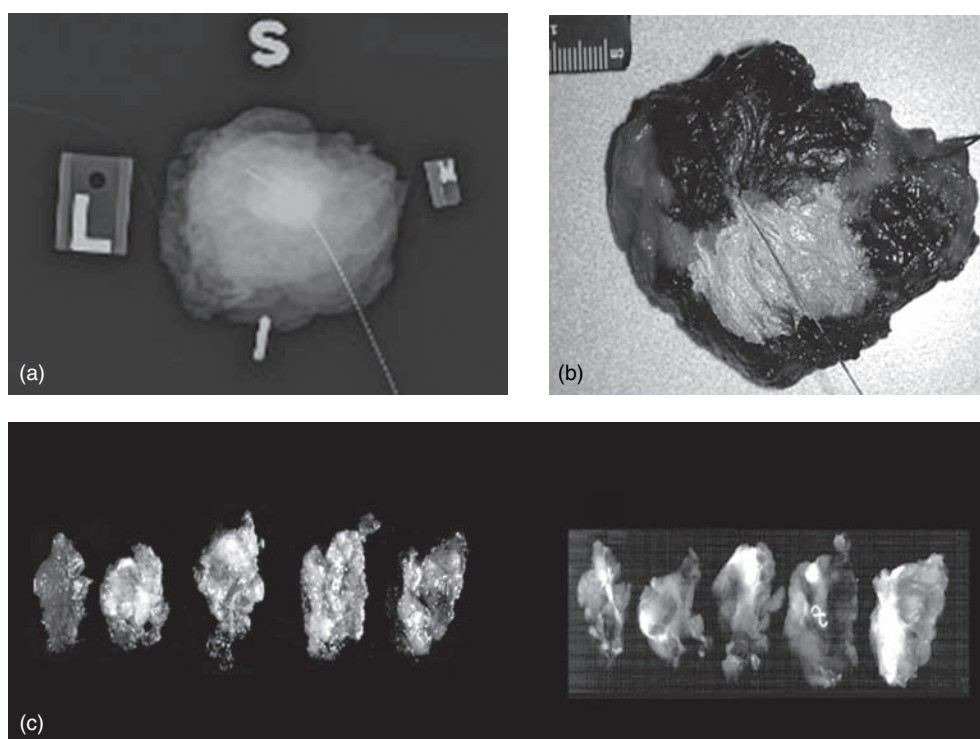
### Intraoperative margin assessment

The main goal of surgery for breast cancer is to achieve long-term disease control. Positive margins have been shown to be predictors of local recurrence and decreased disease-specific survival after BCT<sup>21</sup>. Aggressive local

therapy is necessary to ensure adequate surgical margins and to minimize the risk of ipsilateral breast tumor recurrence. The specimen must be oriented by the operating surgeon so that if margin re-excision is necessary, the re-excision can be limited to the area of involvement. If the specimen is not oriented and a margin is found to be positive or close, the entire partial mastectomy cavity will need to be re-excised.

Intraoperatively, once the tumor has been excised and oriented, the specimen should be inked with different colors (yellow, green, black, blue, orange, and red) to indicate its superior, inferior, superficial, deep, medial, and lateral edges and grossly examined by the pathologist. For non-palpable tumors, specimen radiography is crucial to the intraoperative assessment of margins. The specimen is then serially sectioned, each specimen slice is grossly examined by the pathologist, and radiographs of the sliced specimens are obtained (Figure 13.5) and reviewed by the radiologist and the pathologist. It is important to confirm that all microcalcifications and any marking clips placed preoperatively have been excised with the specimen.

Once the surgeon, pathologist and radiologist are comfortable that margins are negative and all abnormalities have been excised, tissue rearrangement can begin.



**Figure 13.5** Processing of the partial mastectomy specimen. (a) A specimen radiograph is taken of the whole specimen. A localization wire will permit assessment of the location of the lesion within the surgical specimen. (b) The specimen is then inked with 6 different colors (to indicate the superficial, deep, lateral, medial, superior, and inferior edges). (c) The specimen is then sectioned, and (d) a specimen radiograph is taken. The gross specimen and sectioned specimen are examined by the pathologist and the specimen radiographs are reviewed by the radiologist. The surgeon reviews the gross and pathologically prepared specimens and radiographs. Only after negative margins have been confirmed is tissue rearrangement undertaken.

Surgical clips should be placed to delineate the territory of resection. These clips are important for guiding treatment planning by the radiation oncologist.

Although intraoperative margin assessment can be time-consuming and labor-intensive, it is worthwhile, especially if tissue rearrangement is planned. Barros *et al.* showed that intraoperative evaluation of surgical margins by macroscopic, cytological and histological analysis at the time of initial surgery revealed inadequate margins and led to re-excision in 37.3% of cases<sup>22</sup>. Intense intraoperative processing of the breast specimen as described above can significantly decrease the need for re-excision to achieve negative margins from 40% to 22%<sup>23</sup>.

### Closure of the partial mastectomy cavity

The partial mastectomy cavity fills with fluid immediately after surgery, and this fluid initially maintains the volume and contour of the breast. However, the seroma reabsorbs over time, leading to a volume defect, and this volume defect is often exaggerated after irradiation. Especially in patients with large defects, reapproximation of the breast tissue to close the partial mastectomy cavity may be appropriate. In addition to preventing volume defects, closure of the partial mastectomy cavity can prevent adherence of the breast skin to the pectoral muscle (so-called skin-pectoral muscle adherence deformity).

## TECHNICAL ASPECTS OF DEFECT REPAIR AFTER PARTIAL MASTECTOMY

Options for repair of defects resulting from partial mastectomy can generally be grouped into three main categories: local tissue rearrangement with composite breast flaps, reduction mammoplasty, and transfer of remote tissue in the form of a vascularized regional or distant flap.

### Local tissue rearrangement

Local tissue rearrangement is the most straightforward option for repair of partial mastectomy defects, and for this reason, it should be the first option considered. Esthetic outcomes of local tissue rearrangement are best when the defect is of limited size and the rearrangement is performed during the same operative procedure as the oncological resection.

To ensure that the tissues to be transferred are well vascularized, the breast parenchyma is elevated along one plane just overlying the pectoralis major muscle and another plane below the subdermal plexus of the skin, and the breast parenchyma is then advanced over the muscle to fill in the tissue defect. Breast tissue is reapproximated with

absorbable suture at the deepest and superficial surfaces of the parenchyma. Care must be taken to avoid undue tension or excessive parenchymal sutures as this may result in areas of tissue compromise and fat necrosis. The overlying subcutaneous tissue and skin are then closed. If there is a risk of nipple malposition, elevation of the breast parenchyma is extended beneath the nipple-areolar complex to avoid pulling of the nipple-areolar complex toward the scar.

Care should be taken to preserve the vascular supply of the breast, which is derived primarily from perforators from the lateral thoracic, internal mammary and intercostal arteries. The extensive collateral blood supply permits flexibility in operative approaches, but in all cases an adequate vascular supply must be assured for the breast skin and parenchyma, and the nipplareolar complex.

Composite breast flaps include full-thickness breast parenchyma plus skin and are rotated or transposed en bloc (Figure 13.6). These flaps, which were popularized by the late Stephen Kroll and others, are primarily used to effect a subaxillary shift of tissues from lateral to medial<sup>24,25</sup>. Composite flaps assure a reliable vascular base and breast contour but are not appropriate for large defects, for which composite flaps can result in very noticeable scarring and distortion of the nipple.

With all methods of local tissue rearrangement, predictable patterns of tissue advancement are necessary to avoid confusion regarding the location of the original defect, and clips should be placed at the original margins of excision. These precautions ensure that targeted margin re-excision will be possible if positive or close margins are discovered on final pathology review.

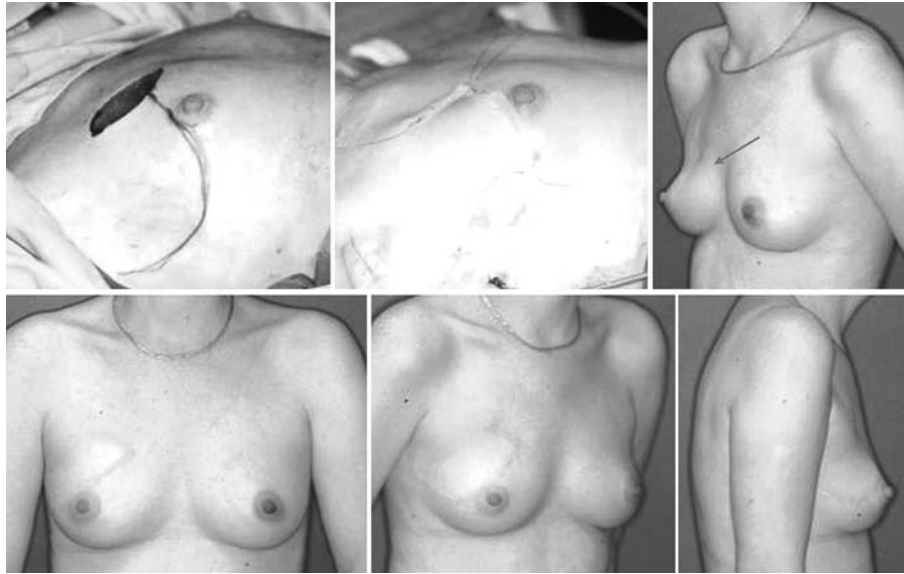
### *Batwing mastopexy*

The 'batwing' mastopexy can be used in patients when the tumor is adjacent to or under the nipple-areolar complex, but not directly involving it. In this technique, two semi-circular incisions of equal size are made, one around the areola and the other parallel to the first incision on the other side of the tumor (Figure 13.7). The skin incisions are then extended laterally so that the two incisions together resemble the wings of a bat. The skin between the incisions, the underlying subcutaneous tissue, and the tumor and a surrounding margin of normal breast tissue are then excised en bloc, and the remaining breast tissues are advanced medially to close the defect. This technique works extremely well with tumors located superior to the nipple-areolar complex and can be designed in any circumareolar orientation, as dictated by the individual tumor.

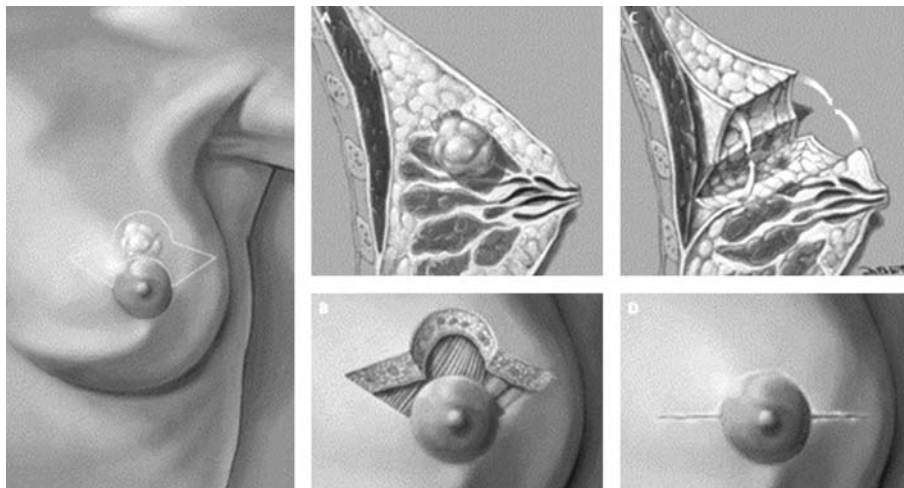
### *Quadrantectomy*

Quadrantectomy may be the best approach for larger tumors and tumors extending along a ductal system.





**Figure 13.6** Local tissue rearrangement. A 33-year-old woman 15 months after superior composite rotation flap. This technique should generally be limited to small volume defects. Note contour deformity overlying pectoralis muscle (arrow). Replacement of a skin resection in this location would result in a poorly color matched and highly visible 'patch'. Reproduced in part from reference 26, with permission.



**Figure 13.7** Batwing mastopexy. Two semicircular incisions of equal size are made, one around the areola and the other parallel to the first incision on the other side of the tumor. The skin incisions are then extended laterally so that the two incisions together resemble the wings of a bat. The skin between the incisions, the underlying subcutaneous tissue, and the tumor and a surrounding margin of normal breast tissue are then excised en bloc, and the remaining breast tissues are advanced medially to close the defect. Reproduced from reference 27, with permission.

The incision is oriented radially, and skin, subcutaneous tissue and breast tissue down to the pectoral muscle are resected en bloc. To preserve breast shape and contour, the remaining tissues are advanced together without tension and closed meticulously in layers to minimize contour deformities and nipple distortion. Scarring may result in contracture, which can be exacerbated by irradiation and can lead to significant and difficult-to-correct deformities.

#### *Donut mastopexy*

The 'donut' mastopexy – more appropriately termed round block mastopexy – credited to Benelli<sup>28</sup> is a variation of 'short scar' reduction mammoplasty technique. The round block approach limits scars on the breast because it is performed through a periareolar incision, eliminating the vertical and horizontal scars associated with the more traditional mastopexy/reduction mammoplasty incision design.

While a reduction in breast scarring is appealing, the clinical results of the donut mastopexy approach have been disappointing. Use of a periareolar cerclage (purse-string suture) without a vertical component results in flattening and loss of projection of the breast mound off the chest wall and may lead to a widened and unattractive periareolar scar. Reduced scarring has been noted with use of a permanent cerclage suture of Gortex or Prolene to prevent recidivism and widening of the scar. Use of the donut mastopexy technique for repair of partial mastectomy defects is best limited to small defects in which the tissue can be safely removed through a periareolar incision. A periareolar 'donut' of skin is removed, and the defect is closed with a purse-string suture after meticulous closure of the parenchymal defect in layers. Deep and superficial sutures in the skin around the nipple are imperative to avoid flattening of the nipple. The patient must be reassured that the 'gathering' of skin around the nipple will settle over several weeks.

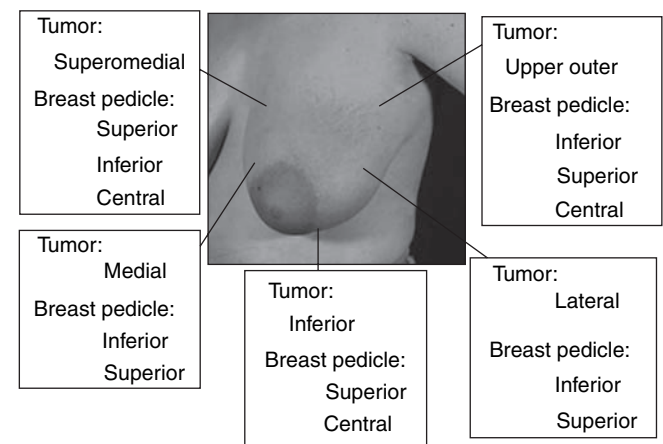
## Reduction mammoplasty techniques

### *Rationale*

Macromastia has traditionally been considered a relative contraindication to partial mastectomy, primarily because of concerns that it is difficult to achieve radiation dose homogeneity in women with large breasts<sup>29</sup> and because the risk of moderate to severe late radiation changes is increased in women with large breasts owing to an increase in breast fibrosis<sup>30–32</sup>. In women with macromastia, performing breast reduction in conjunction with the oncological surgery permits BCT and produces excellent cosmetic results<sup>33–35</sup> (Figures 13.8, 13.9 and 13.10). The reduction surgery permits better dosimetry and reduces the number of 'hot spots' and the volume of the lung and thoracic structures in the irradiation field. Reduction mammoplasty also relieves symptomatic macromastia, a disease complex that manifests with shoulder grooving, cervical and thoracic strain, and mastodynia and can be considered to improve breast health<sup>37–41</sup>. Reduction mammoplasty applications to partial mastectomy are quite favorable reconstructive options in the obese and large breasted patients as these women often have limited traditional reconstructive options after total mastectomy. In large breasted women with a small abdominal pannus, autologous tissue is insufficient to create a large breast. In obese women autologous tissue options carry a high, often prohibitive, complication rate. Breast implants are inadequate in both volume and shape to replicate a large native breast.

Other potential benefits of reduction mammoplasty for oncoplastic breast surgery are reduction in the risk of cancer of the contralateral breast. Although the efficacy of

Reduction mammoplasty for BCT: tumor location and breast pedicle



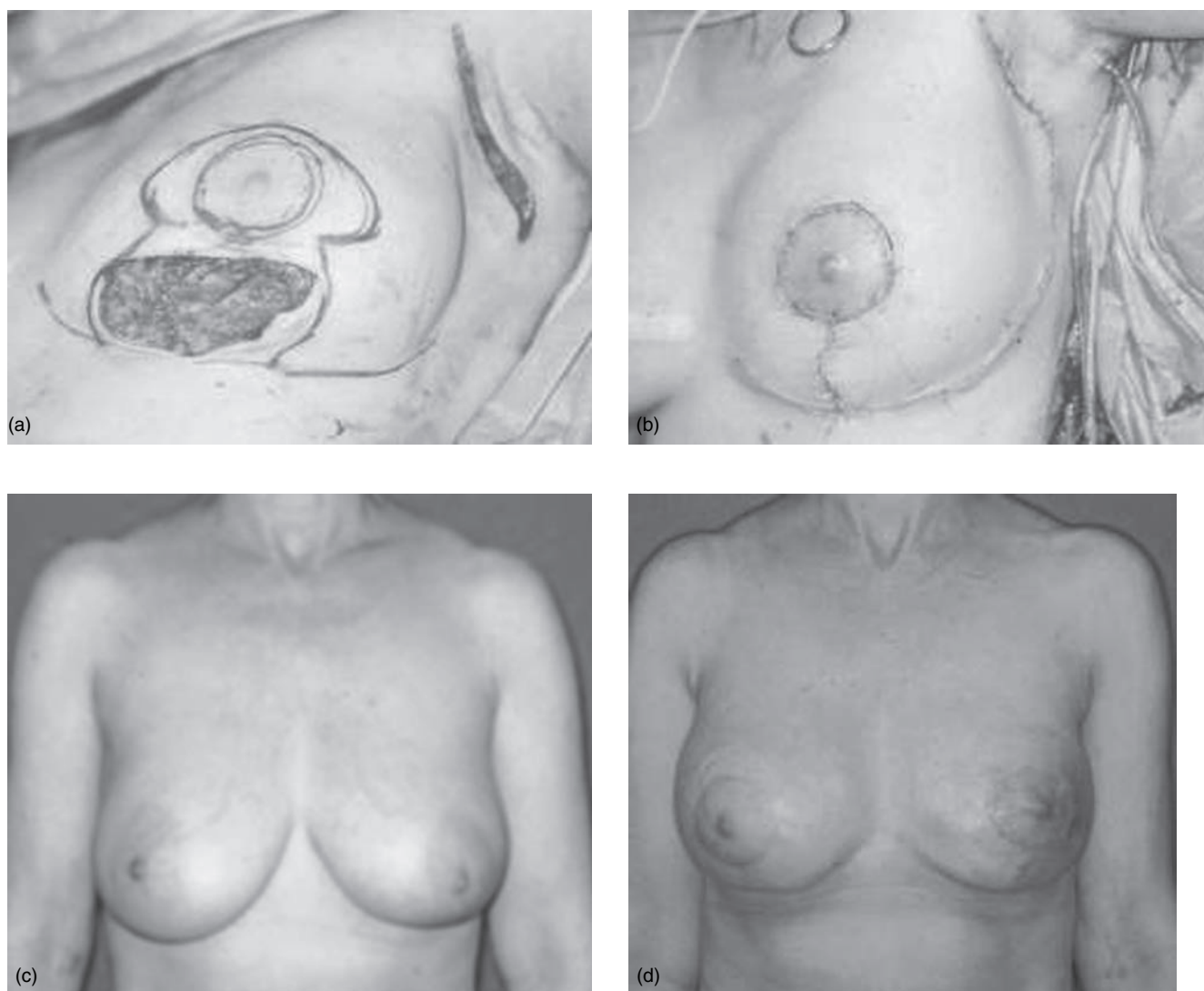
**Figure 13.8** Application of the reduction mammoplasty approach in partial mastectomy by tumor location. Adjusting the neurovascular base of the breast tissue used for reconstruction of the breast may permit application of the reduction mammoplasty technique with tumors in essentially any location in the breast. As tumors are primarily focused in the upper outer quadrant of the breast, a superior or superomedial flap is the most commonly utilized for a reduction approach, and is quite reliable due to the robust vascular supply afforded by the medially based perforating vessels from the internal mammary system. Adapted from reference 36.

reduction mammoplasty as a risk reduction procedure is controversial, this premise has some support<sup>39,42,43</sup>. While the incidence of finding an occult cancer in a routine breast reduction specimen is low (0.16–0.5%), the risk may be higher when a contralateral breast cancer has already been diagnosed<sup>44</sup>. This highlights the need for bilateral diagnostic mammography prior to any surgical interventions.

### *Patient selection and counseling*

Successful use of the reduction mammoplasty approach to oncoplastic breast surgery requires that the affected breast be large enough to permit reduction without deformation and that the patient be amenable to an operation on the contralateral breast. Patients must be counseled preoperatively about the potential complications, which can affect the contralateral breast as well as the index breast and include unfavorable scarring, temporary or permanent loss of nipple sensibility, and poor healing resulting in loss of tissue, potentially including loss of the nipple-areolar complex.

When a reduction mammoplasty approach is being considered, the expected oncological and esthetic outcomes must be carefully considered. If there are concerns about obtaining negative margins or about significant distortion of the breast, remote flaps or conversion to a total mastectomy need to be carefully considered. These concerns are most common in small breasted patients. In patients with macromastia, the volume of the partial mastectomy



**Figure 13.9** Immediate reduction mammoplasty for reconstruction after partial mastectomy. (a) The patient had a small inferior defect after partial mastectomy, ideally suited to a reduction mammoplasty approach. (b) The defect was corrected with medial and lateral advancement of breast flaps on the index breast and a contralateral mastopexy. There was minimal volume change in the breasts and excellent symmetry of the breasts. (c) and (d) The patient's result is demonstrated 3 months postoperatively. Case figures reproduced from reference 26, with permission.

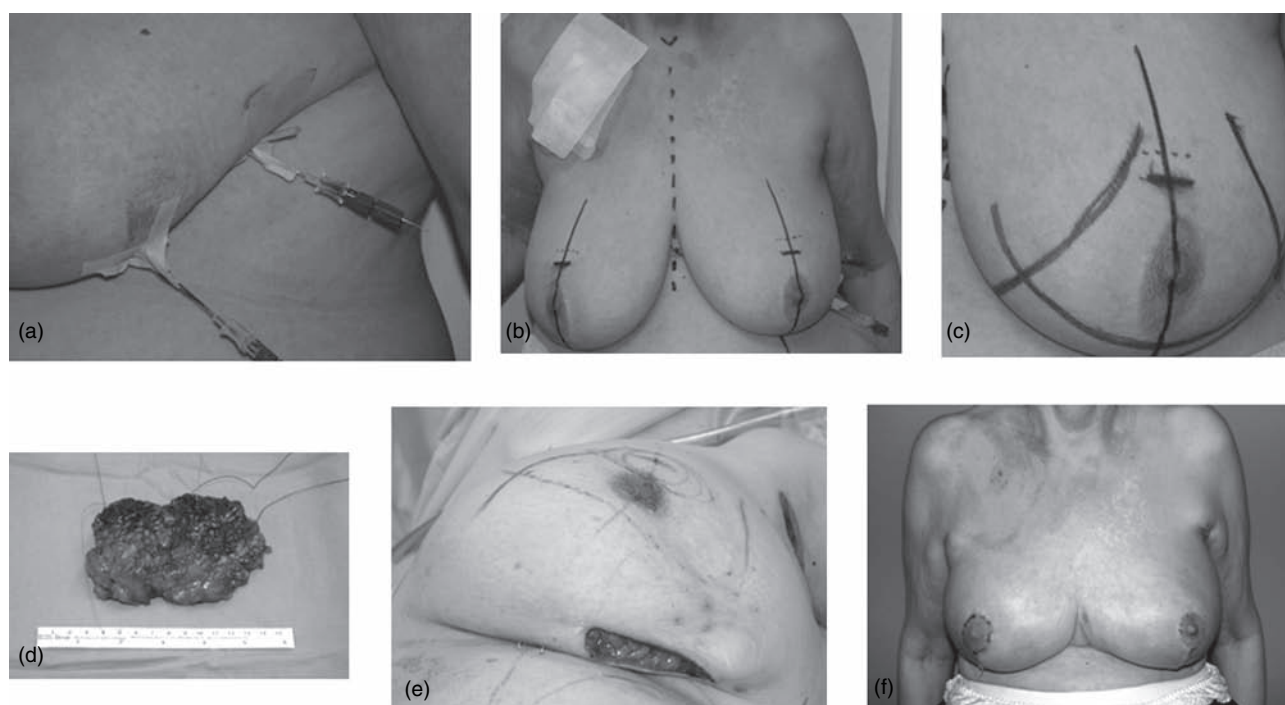
specimen is most often significantly smaller than the volume of tissue removed for breast reduction. Provided that preoperative assessment is careful, it is usually possible to achieve adequate margins with a reduction mammoplasty approach.

The effects of radiation on the breast after partial mastectomy and reduction mammoplasty are difficult to anticipate. In the early postoperative setting, edema and residual seroma pockets give the breast a quite favorable appearance that may be different from the final outcome at 18–36 months after radiation therapy. Some authors suggest 'overreducing' the contralateral breast to account for the likely fibrosis and shrinkage of the index breast in response to irradiation. However, this approach is not universally endorsed given the highly variable and unpredictable

outcome of radiotherapy. The patient should be advised preoperatively that an additional small balancing procedure may be required on the non-irradiated contralateral breast. Breast reduction and adjustment of the irradiated breast has been reported but is associated with a high risk of complications and should be avoided. The reports of successful use of this approach noted poor wound healing, tissue loss and nipple compromise<sup>45,46</sup>.

#### *Technical aspects*

Several principles must be followed to achieve the best possible esthetic results of reduction mammoplasty. It is imperative that both the parenchyma and the skin of the index breast be considered. Unless the patient has true



**Figure 13.10** Immediate reduction mammoplasty for partial mastectomy. This patient underwent partial mastectomy for a lower outer quadrant tumor. A medially based breast flap and contralateral reduction mammoplasty for symmetry were employed for immediate reconstruction. This technique is well suited to patients with baseline macromastia who desire smaller breasts. (a) Preoperative needle localization bracketing the area to be resected. (b) and (c) Preoperative markings of critical breast landmarks, including the proposed new nipple point and paramedian line of the breast (where the inframammary fold intersects the nipple line) will help with ultimate symmetry of the two sides. (d) Extensive intraoperative processing of surgical margins is critical to the success of this approach, and the reconstructive 'reassembly' the breast is best deferred until all margins are confirmed. (e) A total of 256g of breast tissue was removed, resulting in a central and lateral deficit. (f) The patient had an uneventful postoperative course, with preservation of the nipple sensibility bilaterally. Early postoperative result 6 weeks after reduction mammoplasty utilizing a modified vertical reduction mammoplasty approach.

macromastia, resection of more than 30% of the breast will usually result in a defect that is unattractive. When such extensive resection is anticipated, mastectomy and reconstruction may be a better option. To achieve symmetry, similar reduction techniques and scar placement must be used for the index breast and the contralateral breast. This is best achieved if the contralateral breast is shaped after the oncological surgery on the index breast has been completed.

The reduction mammoplasty approach to oncoplastic breast surgery is based on standard techniques of breast reduction. Both the skin envelope and the breast mound must be tailored such that an esthetic breast shape results without compromise of the skin or parenchymal vascular supply. The vascular pedicle of the breast mound, which supports the parenchyma and nipple-areolar complex, has traditionally been based inferiorly, centrally, and/or superomedially<sup>47-49</sup>. The ultimate shape of the breast may be considered to result from the parenchyma as well as the skin which in a 'Wise pattern' approach may be considered to function as a 'brassiere' to help shape the breast.

The traditional basis of surgical technique for reduction mammoplasty has been the combination of a

vertical and a horizontal skin excision, known as a Wise pattern<sup>50</sup> or 'inverted T' incision. This approach is reliable, easily learned and permits control of breast shape and size intraoperatively.

Hypertrophic scars and long-term 'bottoming out' of the breast in which the parenchyma of the breast descends inferiorly resulting in an elongated distance from the inframammary fold and an upward pointing 'stargazing' nipple have prompted more attention to short scar/vertical approaches for mammoplasty. These techniques use more aggressive shaping of the parenchyma and minimize or eliminate the horizontal component of the scar in an effort to limit breast scarring and maximize breast projection<sup>51-56</sup>. Either the short scar or the inverted T scar can be used, with the vascular pedicle adjusted to the tumor location as nicely delineated by Losken<sup>36</sup>. As tumors more commonly occur in the lateral quadrants, medially based pedicles, which derive their vascular supply from the internal mammary perforators, are very useful.

Successful reduction mammoplasty requires extensive and accurate intraoperative processing of margins. The need for re-excision because a positive margin is discovered on the final pathology review is not only oncologically significant

but also can seriously compromise the esthetic outcome. Therefore, every attempt should be made to avoid the need for re-excision. Some authors suggest that in light of these considerations, the contralateral breast reduction should be deferred until the final pathology review on the index breast is complete. However, most patients prefer to undergo immediate reduction of the contralateral breast to minimize the number of operative procedures, and this has been our standard approach except when there are extenuating circumstances. Patients must be counseled preoperatively that if there are questions about margin status or if the tumor is more extensive than initially suspected, contralateral breast reduction might be delayed or an alternate reconstructive approach might be needed. In cases in which margins are a concern – for example, in patients with large tumors managed with neoadjuvant chemotherapy – reduction mammoplasty can be performed after the final pathology review but prior to radiation therapy. As performing the mammoplasty as a separate procedure can delay the delivery of radiation, it is important to discuss this possibility with all members of the multidisciplinary breast team.

### Use of regional and distant flaps

Regional or distant flaps can be used for oncoplastic breast surgery if the amount of breast tissue remaining after the oncological resection is not sufficient for tissue rearrangement. In patients with an established breast deformity after BCT, vascularized autologous flaps are the mainstay for re-establishment of a normal breast form because of the extraordinarily high complication rate of implant-based reconstruction of irradiated breasts. Autologous tissue provides an unparalleled match for the native breast, remains stable over time, and in some circumstances can obviate the need for significant contralateral breast surgery to achieve symmetry. The potential disadvantages of vascularized flaps are related to the donor site: these flaps involve an additional scar and can result in morbidity as a result of flap harvest, including contour deformity, pain, dysesthesias, and even hernia formation. A wide variety of flaps are available for reconstruction, but those from the back, lower abdomen and buttock are most often used for breast reconstruction because they are optimal in terms of the amount of tissue available for reconstruction and functional and esthetic donor-site issues.

Flap choices were traditionally considered in order from simplest to most complex. Current knowledge, however, favors an approach in which the most appropriate reconstructive option is considered first even if this option is not the simplest. In general, the most appropriate flap is the one that results in the best outcomes in terms of repair of the defect and minimization of donor site morbidity.

It should be noted that repair of partial mastectomy defects using autologous tissue from the abdomen or buttocks limits the patient's future breast reconstruction options. In the event that the patient later requires total mastectomy and total breast reconstruction, the abdominal and buttock tissues will not be available.

### *Latissimus dorsi flap*

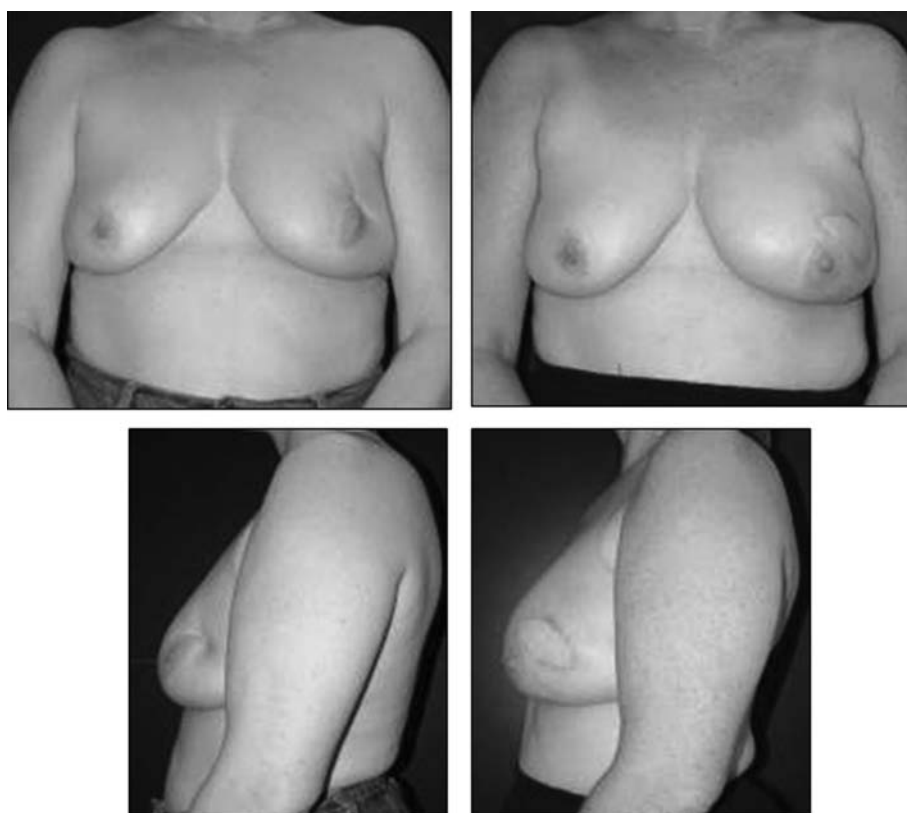The latissimus dorsi (LD) myocutaneous flap, based on the thoracodorsal vessels, has long been a mainstay of breast reconstruction after partial mastectomy (Figure 13.11). The LD flap is robust, reliable and relatively easy to harvest and has been utilized for reconstructive purposes as a pedicled flap for more than 100 years<sup>57,58</sup>. LD flaps are often employed to repair defects in the lateral quadrants and the upper inner pole and are especially useful for repair of defects in small breasts, where even a relatively small-volume resection may result in distortion of the nipple position and loss of breast contour and volume.

Compared with delayed defect repair, immediate defect repair with the LD flap is technically easier, is associated with a lower complication rate, and potentially involves fewer operative steps. The difficulty with the immediate approach is that it is difficult to predict the degree of LD muscle atrophy and the impact of radiation therapy on breast volume and shape, which in turn makes it difficult to determine the degree of correction necessary. Most practitioners overcorrect the defect by 10–25% in an effort to compensate for LD muscle atrophy and the effects of radiation, but this approach is imprecise.

The LD flap contains combinations of LD muscle, fat and skin. The skin paddle should be placed in the proximal third of the muscle to maximize its vascularity, and the skin paddle can be oriented in any of several directions according to the configuration of the defect. Patients generally prefer a transverse scar placed in the bra line (this can be marked out preoperatively) or a scar that is lateral and low enough on the back to be hidden when the patient wears low-cut clothing. It is wise to discuss these preferences with the patient ahead of time. Retention of the innervation of the flap is controversial. Some practitioners argue that an innervated LD muscle preserves volume better than a denervated LD muscle and advocate preservation of the thoracodorsal nerve to maintain the bulk of the transposed muscle. However, others advocate denervation because preserving the nerves results in muscular contractions with activity and even at times spontaneously, which may be quite disturbing to patients. At a minimum, if the flap is innervated, the tendinous muscle insertion should be divided to decrease muscle activity.

The most common complications of LD flap harvest are persistent seroma at the donor site and an unattractive,





**Figure 13.11** Delayed repair of a partial mastectomy defect that includes asymmetry of volume and a significant contour deformity. (a) and (c) A 42-year-old woman presented for correction of her partial mastectomy defect 2 years after the completion of her radiation treatment. As the patient wished to maintain her breast size and shape, an ipsilateral pedicled latissimus dorsi myocutaneous flap was utilized to correct both the contour deformity and volumetric discrepancy. (b) and (d) The patient is seen 14 months post-operatively. Courtesy of Roman Skoracki.

widened scar. There have been numerous attempts to minimize these sequelae by modifications of flap design and instillation of adhesive agents. At present, the best means of minimizing these complications seem to be conservative flap harvest to minimize tension on the donor site, minimal undermining or beveling of the flap to avoid a depressed scar, and plication of the back flaps to the lumbar fascia of the donor site. If there is no skin paddle, endoscopic- or endoscopic-assisted harvest will provide a far more favorable donor site in terms of scar and seroma accumulation. Traditional LD myocutaneous flaps with or without skin sacrifice a functional muscle, and the impact of muscle harvest on shoulder function is not entirely clear. Early reports suggested that there was little or no functional loss with muscle harvest, while some recent studies suggest a negative impact of LD muscle harvest on the activities of daily living in a certain proportion of patients. Accordingly, LD muscle sacrifice is not suggested in patients heavily reliant of their shoulder girdle strength, such as patients who have to use crutches.

Several modifications of the LD muscle flap have been proposed to minimize the functional impact on the donor site, including the 'split' LD flap described by Tobin *et al.*<sup>59</sup>

and, more recently, LD 'mini' flaps. In these modifications, the LD muscle is split along the vascular axis utilizing either the descending (vertical) branch or the transverse (horizontal) branch of the thoracodorsal artery. The most recent evolution the LD flap is the thoracodorsal artery perforator (TAP) flap, described in the next section, in which no muscle or only a very small amount of muscle is harvested<sup>60,61</sup>. The true advantages of these modifications in terms of functional outcome are not well defined.

### *Thoracodorsal artery perforator flap*

The TAP flap is based on one of the two to three cutaneous perforators off the vertical thoracodorsal artery. The pedicle is located preoperatively by Doppler sonography while the patient is in the standing position. The proximal perforator pierces the muscle and enters the subcutaneous tissue approximately 8 cm below the posterior axillary fold and 2–3 cm posterior to the lateral border of the muscle, a second perforator is usually present 2–4 cm distal to the first.

The TAP flap can be used as a pedicled or free flap and appears to lower incidence of the most common

complication of the LD flap – seroma formation. Use of the TAP flap, both as a free flap and as a pedicled flap, is increasing. In certain instances, additional muscle needs to be harvested around the thoracodorsal artery perforators to avoid flap compromise.

The TAP flap represents the current evolution in reconstructive surgery towards flap designs that reduce donor site deformity through flap harvest in which the perforating vessels are dissected free from the surrounding muscle and left in the donor site<sup>62,63</sup>. This approach permits ‘free style’ free flaps in which flap tissue can be harvested around small, cutaneous vessels to truly limit donor site functional deformity, but it is technically complex, subject to anatomic variations, and requires an experienced microsurgeon. The utility of TAP flaps for delayed reconstruction after irradiation remains unclear and awaits further study. In this setting, a traditional myocutaneous LD flap is most likely the safest and also the best option for repair of partial mastectomy defects.

### *Intercostal artery perforator flap*

The intercostal artery perforator (ICAP) flap evolved from the thoracoepigastric flap, which was one of the first flaps used in breast reconstruction. The ICAP flap is based on a perforator found anterior to the LD muscle border and can be harvested without any compromise of the thoracodorsal vessels. The intercostal vessels are dissected to their origin through a split serratus anterior muscle, and a sensate nerve may be included. As the pedicle is short (4–5 cm), the ICAP flap is best utilized as a perforator flap for small lateral defects. While the pedicle can be extended with dissection along the rib margin, this is difficult and may compromise the integrity of the vascular pedicle. The cutaneous territory of this flap is not well studied and awaits further delineation<sup>52,64,65</sup>.

### *Flaps from the lower abdominal wall*

Vascularized flaps from the lower abdominal wall are the gold standard for breast reconstruction. The lower abdominal territory provides an unparalleled volume of high-quality skin and subcutaneous tissue for reconstruction. However, harvest of lower-abdominal-wall flaps can result in visible scarring, contour deformity, pain, and abdominal hernia or bulge. The transverse rectus abdominis myocutaneous (TRAM) flap is the autologous flap most commonly used for breast reconstruction. Over time, the TRAM flap has been refined to improve the vascularity of the flap and minimize abdominal donor site morbidity.

The TRAM flap is a transverse flap based on the perforators that emanate through the rectus abdominis muscle to supply the overlying skin and subcutaneous tissue of

the abdomen. The skin paddle is harvested transversely to maximize the amount of tissue that can be harvested and to ensure that the donor scar can be well hidden even when the patient wears a bathing suit. The TRAM flap was first described and refined for breast reconstruction as a pedicled flap and subsequently adapted as a free flap based on the deep inferior epigastric circulation.

**Pedicled TRAM flap** The pedicled TRAM flap is supplied by the superior epigastric artery and vein. The TRAM flap is the autologous tissue flap most commonly used for breast reconstruction because flap harvest is straightforward (microsurgical techniques are not required) and the flap is reliable. The TRAM flap may be based ipsilaterally or contralaterally and is passed through a subcutaneous tunnel from the lower abdomen into the defect. Muscle-sparing variants of this flap have been described. However, in general, reliable transfer of the vascular pedicle running through the muscle involves sacrifice of the entire width of the rectus abdominis muscle.

The vascularity of the pedicled TRAM flap has been described in zones I–IV, with vascularity decreasing from zone I to IV with increasing distance from the pedicle. A single vascular pedicle cannot usually reliably support a TRAM flap that includes the entire abdominal territory. To increase the blood supply when a large TRAM flap is needed, both vascular pedicles and both rectus muscles can be included. This technique is generally discouraged, because it is associated with a very high rate of postoperative abdominal weakness and an increased risk of hernia.

One alternative to improve the vascularity of the pedicled TRAM flap is to perform a procedure referred to as a surgical delay. The precise techniques of surgical delay vary, but in general this is a two-stage procedure. First, the skin paddle is incised down to the fascia and the deep inferior epigastric arteries are divided. Because the inferior vessels are dominant, dividing them induces some ischemia, which encourages opening up of existing and creation of new vascular networks and which enriches the blood supply of the flap isolated to the superior vascular pedicle to the superior epigastric arteries in an effort to recruit more reliable tissue to one vascular pedicle. Seven to 14 days after the first step, when augmentation of circulation is maximal, the flap is transferred. The amount of extra tissue that may be reliably recruited by surgical delay is not clear, and this method entails an additional operative procedure. Delay does permit identification of tissues that are not well perfused and should be discarded. Inclusion of poorly perfused tissues results in fat necrosis and firmness of the breast and may result in wound breakdown and the need for revisionary procedures.

Pedicled TRAM flaps are not recommended in patients with the potential for poor perfusion, such as smokers and obese patients.

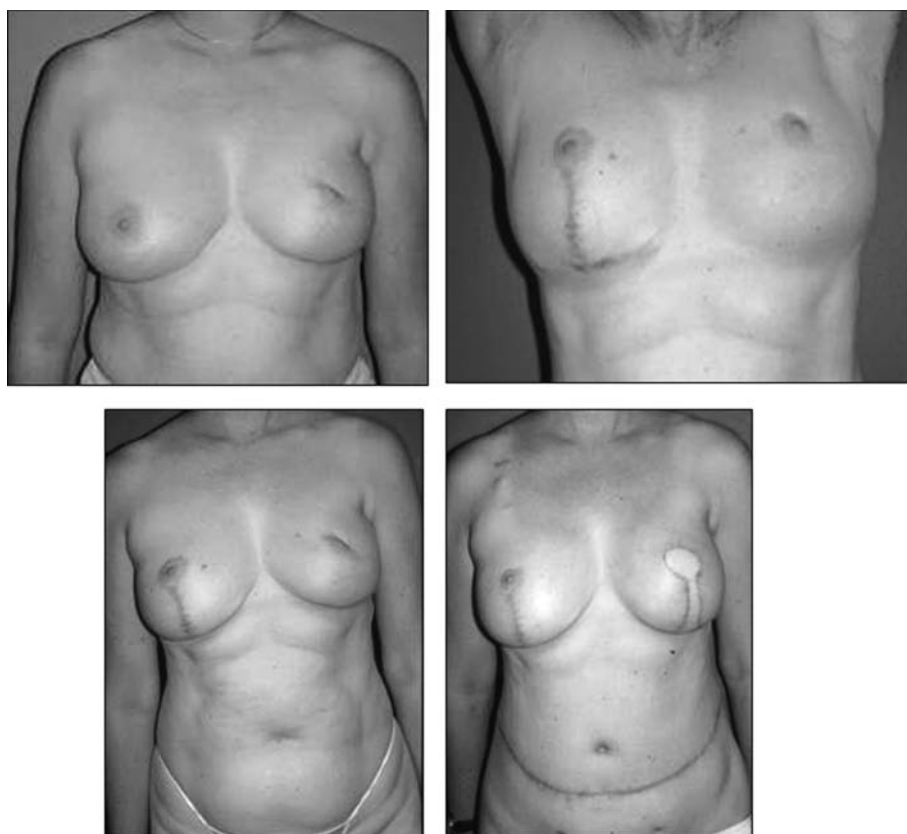
**Free TRAM flap** The free TRAM flap is based on the deep inferior epigastric vessels, which are the dominant vessels supplying blood to the rectus muscle. Free TRAM flaps were developed in an effort to increase the reliable vascular territory of the TRAM flap. Free TRAM flaps are transferred microsurgically and revascularized into the thoracodorsal vessels, or more commonly today, the internal mammary vessels. This technique requires microsurgical expertise but permits a larger flap to be transferred; can be used in patients who are obese or smokers, in whom pedicled flaps are contraindicated; permits better flap positioning; and requires less muscle sacrifice, which should decrease the potential for postoperative abdominal weakness. Microvascular techniques in the breast are highly reliable: flap loss rates are less than 5% nationally and less than 2% in our center and other high-volume centers (Figure 13.12). While it is generally agreed that there is less fat necrosis in free than in pedicled TRAM flaps, the advantages of free versus pedicled TRAM flaps in terms of donor site function are far from clear. Common sense would suggest that decreased violation of the muscle and/or fascia of the abdominal wall would decrease the potential

for postoperative abdominal weakness, and techniques to limit the potential donor site deformities have become a major focus of breast reconstructive surgery.

The use of pedicled flaps from the abdominal wall and the use of free flaps such as the free TRAM flap, the deep inferior epigastric perforator flap, the muscle-sparing free TRAM flap, the superficial inferior epigastric flap, and gluteal flaps require advanced plastic surgical training including microvascular techniques (Figure 13.12). In the event that such flaps are required for reconstruction, the surgeon should strongly consider a total mastectomy with definitive breast reconstruction.

### Implants after partial mastectomy

The use of implants for correction of partial mastectomy defects is fraught with significant short-term and long-term complications, and we do not advise the use of implants for either immediate or delayed defect repair. Implant loss and fibrous capsular contracture with pain and distortion of the breast may occur, and the esthetic outcomes are generally considered to be poor<sup>66</sup>. True assessment of the



**Figure 13.12** Recurrence after partial mastectomy. (a) This 47-year-old woman underwent partial mastectomy and irradiation of the left breast, which resulted in a volume deformity. (b) and (c) She presented for correction of her deformity 3 years after treatment. She refused flap reconstruction and underwent contralateral reduction mammoplasty. (d) Six months later, she developed a recurrent breast cancer in the index breast necessitating mastectomy with reconstruction. The patient's postoperative result 12 months after a unilateral free DIEP (deep inferior epigastric perforator) flap is demonstrated. Patient refused nipple-areolar reconstruction.



complication rate and outcomes with implants is particularly difficult because of the retrospective nature of the studies published to date, use of subjective, non-standardized measures of outcome, short follow-up, and small study size.

## SUMMARY

The surgical management of breast cancer is critical for both the staging and treatment of the disease. Communication amongst the multidisciplinary team members, including the general surgeon, medical oncologist, breast radiologist, radiation oncologist, and plastic and reconstructive surgeon, is key in delivering the most appropriate

care for each individual breast cancer patient. By applying important oncological principles together with plastic surgery techniques to breast conserving therapy, the goals of tumor control and improved esthetic results may be achieved. The first oncological resection is critical – it offers the best opportunity to resect the entire lesion, assess extent of disease with negative margins, and achieve the best possible cosmetic result. Local tissue rearrangement or reduction mammoplasty at the initial surgery can avoid potential deformity. Composite flaps, local and distant flaps can be used to repair any resultant deformity and the breast surgeon and plastic and reconstructive surgeon should work closely together to achieve the best outcome.

## REFERENCES

1. NIH consensus conference. Treatment of early-stage breast cancer. *JAMA* 1991; 265: 391–5.
2. Veronesi U, Luini A, Galimberti V, Zurrada S. Conservation approaches for the management of stage I/II carcinoma of the breast: Milan Cancer Institute trials. *World J Surg* 1994; 18: 70–5.
3. Arriagada R, Le MG, Rochard F, Contesso G. Conservative treatment versus mastectomy in early breast cancer: patterns of failure with 15 years of follow-up data. Institut Gustave-Roussy Breast Cancer Group. *J Clin Oncol* 1996; 14: 1558–64.
4. Fisher B, Anderson S, Redmond CK et al. Reanalysis and results after 12 years of follow-up in a randomized clinical trial comparing total mastectomy with lumpectomy with or without irradiation in the treatment of breast cancer. *N Engl J Med* 1995; 333: 1456–61.
5. Jacobson JA, Danforth DN, Cowan KH et al. Ten-year results of a comparison of conservation with mastectomy in the treatment of stage I and II breast cancer. *N Engl J Med* 1995; 332: 907–11.
6. van Dongen JA, Voogd AC, Fentiman IS et al. Long-term results of a randomized trial comparing breast-conserving therapy with mastectomy: European Organization for Research and Treatment of Cancer 10801 trial. *J Natl Cancer Inst* 2000; 92: 1143–50.
7. Blichert-Toft M, Rose C, Andersen JA et al. Danish randomized trial comparing breast conservation therapy with mastectomy: six years of life-table analysis. *Danish Breast Cancer Cooperative Group. J Natl Cancer Inst Monogr* 1992; 11: 19–25.
8. Morrow M, Strom EA, Bassett LW et al. Standard for breast conservation therapy in the management of invasive breast carcinoma. *CA Cancer J Clin* 2002; 52: 277–300.
9. Clarke M, Collins R, Darby S et al. Effects of radiotherapy and of differences in the extent of surgery for early breast cancer on local recurrence and 15-year survival: an overview of the randomised trials. *Lancet* 2005; 366: 2087–106.
10. Petit JY, Rigaut L, Zekri A, Le M. [Poor esthetic results after conservative treatment of breast cancer. Technics of partial breast reconstruction]. *Ann Chir Plast Esthet* 1989; 34: 103–8.
11. Olivetto IA, Rose MA, Osteen RT et al. Late cosmetic outcome after conservative surgery and radiotherapy: analysis of causes of cosmetic failure. *Int J Radiat Oncol Biol Phys* 1989; 17: 747–53.
12. Abner AL, Recht A, Vicini FA et al. Cosmetic results after surgery, chemotherapy, and radiation therapy for early breast cancer. *Int J Radiat Oncol Biol Phys* 1991; 21: 331–8.
13. Bajaj AK, Kon PS, Oberg KC et al. Aesthetic outcomes in patients undergoing breast conservation therapy for the treatment of localized breast cancer. *Plast Reconstr Surg* 2004; 114: 1442–9.
14. Rose MA, Olivetto I, Cady B et al. Conservative surgery and radiation therapy for early breast cancer. Long-term cosmetic results. *Arch Surg* 1989; 124: 153–7.
15. Taylor ME, Perez CA, Halverson KJ et al. Factors influencing cosmetic results after conservation therapy for breast cancer. *Int J Radiat Oncol Biol Phys* 1995; 31: 753–64.
16. Montague ED, Paulus DD, Schell SR. Selection and follow-up of patients for conservation surgery and irradiation. *Front Radiat Ther Oncol* 1983; 17: 124–30.
17. Braw M, Erlandsson I, Ewers SB, Samuelsson L. Mammographic follow-up after breast conserving surgery and postoperative radiotherapy without boost irradiation for mammary carcinoma. *Acta Radiol* 1991; 32: 398–402.
18. Al-Refai WB, Cormier J, Xing Y et al. Initial biopsy procedure for breast cancer diagnosis influences number of surgical procedures and cost of care. *J Clin Oncol* 2006; 24: 27.
19. Boughey JC, Peintinger F, Meric-Bernstam F et al. Impact of preoperative versus postoperative chemotherapy on the extent and number of surgical procedures in patients treated in randomized clinical trials for breast cancer. *Ann Surg* 2006; 244: 464–70.
20. Buzdar AU, Ibrahim NK, Francis D et al. Significantly higher pathologic complete remission rate after neoadjuvant therapy with trastuzumab, paclitaxel, and epirubicin chemotherapy: results of a randomized trial in human epidermal growth factor receptor 2-positive operable breast cancer. *J Clin Oncol* 2005; 23: 3676–85.
21. Meric F, Mirza NQ, Vlastos G et al. Positive surgical margins and ipsilateral breast tumor recurrence predict disease-specific survival after breast-conserving therapy. *Cancer* 2003; 97: 926–33.
22. Barros A, Pinotti M, Ricci MD et al. Immediate effects of intraoperative evaluation of surgical margins over the treatment of early infiltrating breast carcinoma. *Tumori* 2003; 89: 42–5.
23. Chagpar A, Yen T, Sahin A et al. Intraoperative margin assessment reduces reexcision rates in patients with ductal carcinoma in situ treated with breast-conserving surgery. *Am J Surg* 2003; 186: 371–7.
24. Bold RJ, Kroll SS, Baldwin BJ et al. Local rotational flaps for breast conservation therapy as an alternative to mastectomy. *Ann Surg Oncol* 1997; 4: 540–4.
25. Clough KB, Kroll SS, Audretsch W. An approach to the repair of partial mastectomy defects. *Plast Reconstr Surg* 1999; 104: 409–20.

26. Kroll SS, Singletary SE. Repair of partial mastectomy defects. *Clin Plast Surg* 1998; 25: 303–10.
27. Anderson BO, Masetti R, Silverstein MJ. Oncoplastic approaches to partial mastectomy: an overview of volume-displacement techniques. *Lancet Oncol* 2005; 6: 145–57.
28. Benelli L. A new periareolar mammaplasty: the “round block” technique. *Aesthetic Plast Surg* 1990; 14: 93–100.
29. Moody AM, Mayles WP, Bliss JM et al. The influence of breast size on late radiation effects and association with radiotherapy dose inhomogeneity. *Radiother Oncol* 1994; 33: 106–12.
30. Brierley JD, Paterson IC, Lallemand RC, Rostom AY. The influence of breast size on late radiation reaction following excision and radiotherapy for early breast cancer. *Clin Oncol (R Coll Radiol)* 1991; 3: 6–9.
31. Gray JR, McCormick B, Cox L, Yahalom J. Primary breast irradiation in large-breasted or heavy women: analysis of cosmetic outcome. *Int J Radiat Oncol Biol Phys* 1991; 21: 347–54.
32. Prosnitz LR, Goldenberg IS, Packard RA et al. Radiation therapy as initial treatment for early stage cancer of the breast without mastectomy. *Cancer* 1977; 39 (2 Suppl): 917–23.
33. Smith ML, Evans GR, Gurlek A et al. Reduction mammaplasty: its role in breast conservation surgery for early-stage breast cancer. *Ann Plast Surg* 1998; 41: 234–9.
34. Stoller A, Allen R, Linares L. Breast conservation therapy with concomitant breast reduction in large-breasted women. *Breast J* 2003; 9: 269–71.
35. Spear SL, Pelletiere CV, Wolfe AJ et al. Experience with reduction mammaplasty combined with breast conservation therapy in the treatment of breast cancer. *Plast Reconstr Surg* 2003; 111: 1102–9.
36. Losken A, Elwood ET, Styblo TM, Bostwick J 3rd. The role of reduction mammaplasty in reconstructing partial mastectomy defects. *Plast Reconstr Surg* 2002; 109: 968–75.
37. Shestak KC, Johnson RR, Greco RJ, Williams SL. Partial mastectomy and breast reduction as a valuable treatment option for patients with macromastia and carcinoma of the breast. *Surg Gynecol Obstet* 1993; 177: 54–6.
38. Bruhlmann Y, Tschopp H. Breast reduction improves symptoms of macromastia and has a long-lasting effect. *Ann Plast Surg* 1998; 41: 240–5.
39. Brinton LA, Persson I, Boice JD Jr et al. Breast cancer risk in relation to amount of tissue removed during breast reduction operations in Sweden. *Cancer* 2001; 91: 478–83.
40. Sood R, Mount DL, Coleman JJ 3rd et al. Effects of reduction mammaplasty on pulmonary function and symptoms of macromastia. *Plast Reconstr Surg* 2003; 111: 688–94.
41. Goffman TE, Schneider H, Hay K et al. Cosmesis with bilateral mammoreduction for conservative breast cancer treatment. *Breast J* 2005; 11: 195–8.
42. Boice JD Jr, Persson I, Brinton LA et al. Breast cancer following breast reduction surgery in Sweden. *Plast Reconstr Surg* 2000; 106: 755–62.
43. Brown MH, Weinberg M, Chong N et al. A cohort study of breast cancer risk in breast reduction patients. *Plast Reconstr Surg* 1999; 103: 1674–81.
44. Jansen DA, Murphy M, Kind GM, Sands K. Breast cancer in reduction mammaplasty: Case reports and a survey of plastic surgeons. *Plast Reconstr Surg* 1998; 101: 361–4.
45. Handel N, Lewinsky B, Waisman JR. Reduction mammaplasty following radiation therapy for breast cancer. *Plast Reconstr Surg* 1992; 89: 953–5.
46. Spear SL, Burke JB, Forman D et al. Experience with reduction mammaplasty following breast conservation surgery and radiation therapy. *Plast Reconstr Surg* 1998; 102: 1913–6.
47. McKissock PK. Reduction mammaplasty with a vertical dermal flap. *Plast Reconstr Surg* 1972; 49: 245–52.
48. Strombeck JO. Mammaplasty: report of a new technique based on the two-pedicle procedure. *Br J Plast Surg* 1960; 13: 79–90.
49. Biesenberger H. Eine neue methode der mammaplastik. *Zentralbl Chir* 1928; 55: 2382.
50. Wise RJ. A preliminary report on a method of planning the mammaplasty. *Plast Reconstr Surg* 1956; 17: 367–75.
51. Hall-Findlay EJ. A simplified vertical reduction mammaplasty: Shortening the learning curve. *Plast Reconstr Surg* 1999; 104: 748–59.
52. Lassus C. Breast reduction: evolution of a technique – a single vertical scar. *Aesthetic Plast Surg* 1987; 11: 107–12.
53. Regnault P. Reduction mammaplasty by the “b” technique. *Plast Reconstr Surg* 1974; 53: 19–24.
54. Courtiss EH, Goldwyn RM. Reduction mammaplasty by the inferior pedicle technique. An alternative to free nipple and areola grafting for severe macromastia or extreme ptosis. *Plast Reconstr Surg* 1977; 59: 500–7.
55. Lejour M, Abboud M. Vertical mammaplasty without inframammary scar and with breast liposuction. *Perspect Plast Surg* 1990; 4: 67.
56. Hammond DC. The spair mammaplasty. *Clin Plast Surg* 2002; 29: 411–21.
57. Maxwell GP, Manson PN, Hoopes JE. Experience with thirteen latissimus dorsi myocutaneous free flaps. *Plast Reconstr Surg* 1979; 64: 1–8.
58. Maxwell GP, Iginio tansini and the origin of the latissimus dorsi musculocutaneous flap. *Plast Reconstr Surg* 1980; 65: 686–92.
59. Tobin GR, Schusterman M, Peterson GH et al. The intramuscular neurovascular anatomy of the latissimus dorsi muscle: the basis for splitting the flap. *Plast Reconstr Surg* 1981; 67: 637–41.
60. Angrigiani C, Grilli D, Siebert J. Latissimus dorsi musculocutaneous flap without muscle. *Plast Reconstr Surg* 1995; 96: 1608–14.
61. Hamdi M, Van Landuyt K, Monstrey S, Blondeel P. Pedicled perforator flaps in breast reconstruction: a new concept. *Br J Plast Surg* 2004; 57: 531–9.
62. Wei FC, Mardini S. Free-style free flaps. *Plast Reconstr Surg* 2004; 114: 910–6.
63. Koshima I, Saisho H, Kawada S et al. Flow-through thin latissimus dorsi perforator flap for repair of soft-tissue defects in the legs. *Plast Reconstr Surg* 1999; 103: 1483–90.
64. Badran HA, El-Helaly MS, Safe I. The lateral intercostal neurovascular free flap. *Plast Reconstr Surg* 1984; 73: 17–26.
65. Ogawa R, Hyakusoku H, Murakami M et al. An anatomical and clinical study of the dorsal intercostal cutaneous perforators, and application to free microvascular augmented subdermal vascular network (ma-svn) flaps. *Br J Plast Surg* 2002; 55: 396–401.
66. Thomas PR, Ford HT, Gazet JC. Use of silicone implants after wide local excision of the breast. *Br J Surg* 1993; 80: 868–70.



David J Joyce and Peter McCulloch

---

## INCIDENCE/PREVALENCE/PREDISPOSING RISK FACTORS

Gastric cancer is the second most common cancer in the world, with 10 000 new cases diagnosed every year in the UK<sup>1</sup>. In the UK, it is the fifth most common cancer in males and the eighth most common cancer in females<sup>2</sup>. The male to female ratio is 1.8 : 1<sup>2</sup>. The age standardized incidence of gastric adenocarcinoma in the UK is 18.9 per 100 000 for men and 7.3 per 100 000 for women<sup>3</sup>. This represents a 41% and 51% reduction from 1971 to 1998, respectively<sup>3</sup>. Despite these trends, gastric cancer remains a more common diagnosis than esophageal cancer. Risk factors include advanced age, black or Hispanic ethnicity and certain geographic regions (Japan, China, the Middle East, Eastern Europe, and South/Central America).

## PRESENTATION

Gastric cancer is most often asymptomatic in its early stages. However, as it becomes more advanced, symptoms of anorexia, fatigue, weight loss, and epigastric pain may develop. Less commonly, patients may complain of dysphagia, early satiety, vomiting, or hematemesis. Physical signs, while typically absent in early disease, may include jaundice, ascites, or a palpable mass in advanced disease. A number of eponyms have been assigned to the various regions of lymph node involvement in gastric cancer. Peri-umbilical nodes are termed 'Sister Mary Joseph nodules', named for the scrub nurse to the Mayo brothers who first described them. 'Irish nodes' are palpable nodes in the left axilla. 'Virchow's node' describes a supraclavicular node in the setting of gastric cancer.

## SCREENING

Screening techniques for gastric cancer have not achieved widespread success. However, endoscopic mass screening

has been proposed as a technique for screening high risk patients<sup>4</sup>. However, this technique relies on a sufficient number of skilled endoscopists to be successful.

## DIAGNOSTIC STRATEGIES

When a patient presents with symptoms and signs of gastric cancer, esophagogastroduodenoscopy (EGD) is the diagnostic modality of choice. Through direct visualization of the mucosa, EGD can detect the presence of risk factors such as peptic ulcer disease and hiatus hernia. In addition, tissue biopsies (at least seven for diagnosis) can be easily made for suspicious lesions. Patency of the esophagogastric junction can be assessed. In patients who present with bleeding, therapeutic maneuvers can also be carried out. For all of these advantages, endoscopy has largely replaced double contrast barium swallow studies for diagnosis of gastric cancer. Factors that should be quantified during endoscopy include size, location and appearance of the tumor, as well as other mucosal abnormalities that are noted. In patients with unresectable disease, EGD can also facilitate palliation via techniques such as stenting, balloon dilatation, or laser ablation. Endoscopic ultrasonography has emerged as a newer adjunct to diagnosis and staging. Endoscopic ultrasound carries the advantage of aiding in determination of the degree of gastric wall invasion. It can also help determine lymph node involvement.

## STAGING

A summary of the current internationally accepted staging system for gastric cancer is briefly set out in Table 14.1. A computed tomography (CT) scan of the chest and abdomen is the core of the staging process. CT scan is moderately effective at estimating the T stage of the lesion, and the involvement of local and regional lymph nodes. It is extremely useful in the detection of lung and liver metastasis, where its sensitivity approaches

**Table 14.1** International Union Against Cancer system for staging of gastric cancer*Primary tumor (T)*

Tx	Tumor cannot be assessed
T0	No evidence of primary tumor
Tis	Intraepithelial tumor confined to the lamina propria
T1	Tumor extends into but not beyond the submucosa
T2a	Tumor extends into but not beyond the muscularis propria
T2b	Tumor invades the subserosa
T3	Tumor extends into the serosa but not into adjacent organs
T4	Tumor invades into adjacent organs

*Regional lymph nodes (N)*

Nx	Regional lymph nodes cannot be assessed
N0	No regional lymph nodes involved
N1	Metastases in 1–6 regional lymph nodes
N2	Metastases in 7–15 regional lymph nodes
N3	Metastases in more than 15 lymph nodes

*Distant metastasis (M)*

Mx	Distant metastatic spread cannot be assessed
M0	No evidence of distant metastases
M1	Evidence of distant metastases

Regional lymph node groups are defined as perigastric nodes (along both curvatures), regional nodes around the celiac axis and along its main tributaries (left gastric, splenic and common hepatic arteries), and the nodes in the hepatoduodenal ligament. There is a minimum requirement of 15 analyzed lymph nodes before an N stage can be assigned. From reference 5.

90% and its specificity 98%<sup>6–8</sup>. Some centers take a selective approach to endoscopic ultrasound for stomach tumors. Personally, we take considerable comfort from an endoscopic ultrasound which demonstrates that there is no direct invasion of the pancreas posteriorly, as this question can be very difficult to determine by either laparoscopy or CT scan, and can make a substantial difference to case selection and operative tactics.

Positron emission tomography (PET) scanning using 5-fluorodeoxyglucose as a probe for highly metabolic tumor tissue has proved extremely sensitive in reports on a wide variety of cancers both pre- and post-treatment. Difficulties in defining its exact role have arisen because of:

- Its limited availability in many countries
- The plethora of other staging tests which pre-dated it
- Its relative lack of specificity.

Since we already have sensitive and specific tests for liver and lung metastasis and loco-regional disease, PET (or increasingly CT/PET) currently tends to be used as the arbiter in cases where there is discomfort with the results of other methods. In current UK practice the common uses of PET are therefore

- to provide corroborating evidence for or against the presence of small metastasis in the lungs or liver following reports of possible lesions at the limits of discrimination of CT scanning
- as a further screen for evidence of inoperable disease in patients whose clinical and staging characteristics have caused suspicion of this but have failed to unearth conclusive proof.

Current evidence suggests that PET/CT has a sensitivity of 98–100% and a specificity of up to 89% in detecting lung and liver metastasis in gastrointestinal tumors<sup>9–11</sup>, but is less effective in detecting peritoneal disease<sup>12,13</sup>. There is a considerable need for further research on the appropriate management of patients with very small volume metastatic disease detected by PET.

Laparoscopy pre-dates the other commonly used staging methods but remains extremely valuable because of its high degree of accuracy for small volume peritoneal disease<sup>13–19</sup>. Its sensitivity for peritoneal metastasis is quoted at 96%<sup>18</sup> and its specificity nearly 100%, which compares favorably with the best figures quoted for PET, CT and other modalities. There is an extensive literature on the use of peritoneal washings for cytology. Using a fairly straightforward lavage and conventional cytological staining, the yield of this technique is fairly low, but the prognostic implications if cancer cells are found are grave<sup>20–22</sup>. Most surgeons currently use washings for cytology on a limited basis or not at all. The other benefits of laparoscopy include the ability to pick up small surface liver metastasis missed by CT scanning, and the opportunity for surgeon and anesthetist to assess the response of the patient to a brief anesthetic.

The American Society of Anesthesiologists (ASA) grade of the patient and the physiological POSSUM score component are independent predictors of mortality in large prospective series<sup>20,23,24</sup>, and the Goldman cardiac index has been validated in general and vascular surgery, although it seems less predictive than ASA<sup>25–28</sup>. An index scoring the preoperative function of multiple organs has been derived by Bartels *et al.*<sup>29</sup>, and has been carefully validated in esophageal cancer patients including many with cancer at the gastroesophageal junction. Whether this is accurate for gastrectomy patients is unclear. At present most experienced surgeons rely on crude

subjective assessment of the patient's overall functional capacity, sometimes assessed slightly more rigorously by climbing stairs with the patient.

## SURGERY FOR CURE

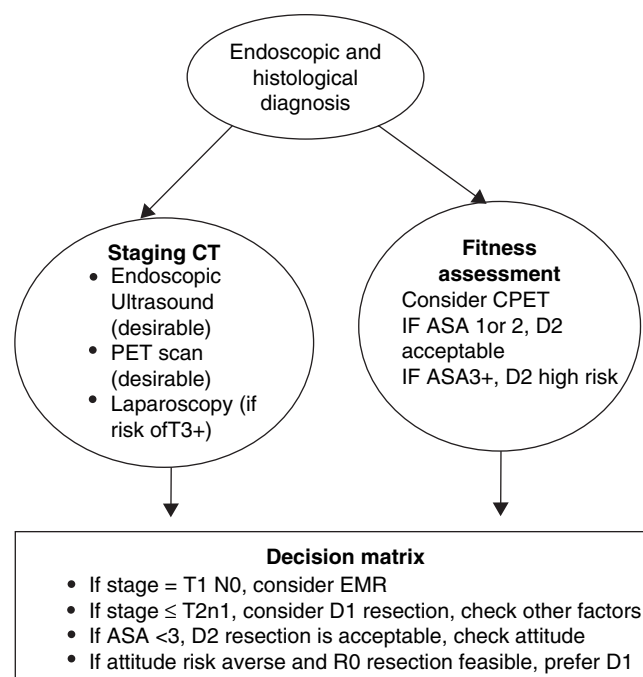
Surgery remains the cornerstone of treatment for non-mucosal gastric cancer, being the only form of treatment that reliably produces cure or long-term survival in a significant proportion of patients. The extent of resection required has been the subject of considerable debate. The mode of spread of gastric cancer differs substantially from that of colorectal cancer. Whilst liver metastasis without evidence of other metastatic disease is relatively common in colorectal disease, it is very rare in gastric cancer<sup>30</sup>, which conversely has a tendency to remain confined to the stomach and locoregional nodes until a very late stage. This observation has been used by some as an argument for more radical surgical therapy.

### Potential procedures

There is considerable evidence available about the outcomes of the various surgical options, but the selection of the correct procedure for the individual patient remains a matter where experience and judgment are important. The decision-making algorithm illustrated in Figure 14.1 shows the factors involved and the choices available, but it is not possible to put exact weights on these.

### Limited surgery for cure

Where disease is confined to the mucosa (or in strictly defined circumstances to the sub-mucosa) endoscopic mucosal resection may be a satisfactory treatment option. Next in order of prognosis there is a group of patients with relatively early disease, whose staging investigations predict a low likelihood of nodal metastasis. Where there is a high statistical probability of more extensive nodal metastasis, more radical surgery is justified. Essentially, the surgeon is required to make four choices in designing the appropriate operation for an individual patient: first, the proximal and distal extent of the resection of the stomach (with or without esophagus or duodenum); second, the extent and site of the lymph node dissection required to give the best chance of removing any locoregional disease; third, the least invasive option combining adequate resection of both the gastrointestinal tube and the lymph nodes; and, finally, what reconstruction technique should be used.



**Figure 14.1** Surgical treatment decision algorithm for gastric cancer, illustrating the multifactorial nature of the decision process. This algorithm does not discuss adjuvant treatment, but current evidence suggests that either perioperative chemotherapy or postoperative chemoradiation may be appropriate. The recommendations relating to D2 resection are based principally on expertise and physiological reasoning: current literature evidence does not conclusively demonstrate survival benefit for radical surgery<sup>31</sup>. PET, positron emission tomography; CPET, cardiopulmonary exercise testing; ASA, American Society of Anesthesiologists; EMR, endoscopic mucosal resection; Ro, microscopically complete resection; D.

### Extent of gastric resection


Tumors in the pyloric canal, antrum or on the lesser curve in the body of the stomach can be treated by subtotal gastrectomy. A 5 cm margin in the operative specimen is generally adequate. There is considerable evidence of additional mortality risk and a poorer nutritional result with a total gastrectomy<sup>23,32</sup>, and this should sway the surgeon towards preservation of a portion of the stomach where this can be carried out safely. For relatively early tumors in the distal stomach, techniques have been described preserving the vagus nerves and pylorus, to improve gastric emptying and function<sup>23,33–35</sup>.

For disease in the proximal half of the stomach, the time-honored treatment is total gastrectomy. One attractive alternative for relatively small or early tumors is a proximal gastrectomy with jejunal interposition. This was originally described by Merendino *et al.* as a possible antireflux procedure<sup>36–38</sup>, but Japanese surgeons have reported good results using it for early proximal cancer<sup>39</sup>,

and our own limited experience of it has been satisfactory. Further comments on the selection of reconstructive technique after gastrectomy are contained in the section on side-effects of surgery below, as the choice is usually driven by the aim of avoiding both bile reflux and malnutrition.

### Nodal dissection

The appropriate extent of lymph node dissection in gastric cancer surgery has been a major topic of surgical controversy for several decades. The survival results of limited surgery, as reported in the Western literature prior to 1970, were extremely poor<sup>40–43</sup>, whilst a number of features of gastric cancer suggested that radical en-bloc lymph node dissection might improve survival rates. Japanese surgeons developed the concept of the 'D2' gastrectomy, involving resection of not only the perigastric nodes in the vascular arcades along the curvatures, but also all the nodes along the main branches of the celiac axis, to which the majority of the lymphatic flow from the stomach gravitates. The Japanese staging system is complex and is based on numbered nodal 'stations' of which numbers 7–11 roughly correspond to the nodal groups resected during the D2 gastrectomy which would not be removed in the more limited operation traditionally performed in Western countries (see Figure 14.2). Any statement about lymph node dissection in gastric cancer surgery is liable to prove controversial, but a



**Figure 14.2** Topographical distribution of lymph node stations as defined by the 2nd English edition of the Japanese classification of gastric carcinoma. The numbers indicate the recognized nodal 'stations'. D2 radical dissection can involve resection of stations up to and including 12, D1 dissection only up to station 6.

reasonable summary based on the evidence would be as follows:

- (1) Gastric cancer frequently spreads to local and regional lymph nodes once the submucosa is invaded, and consideration should therefore be given to resection of lymph nodes which are liable to be involved with cancer.
- (2) The extent of nodal invasion can be predicted with reasonable accuracy from the characteristics of the primary tumor. Modern staging investigations provide further information.
- (3) The main argument against radical lymph node dissection in gastrectomy is its association with increased morbidity and mortality. This type of surgery should therefore only be carried out in units which can demonstrate satisfactory results in a properly conducted audit.
- (4) In patients where there is clear evidence of locoregional node involvement curative surgery must of necessity involve the resection of these nodes. There will therefore be a subset of patients for whom the surgical choices are palliative resection or radical lymph node dissection. It is important that specialist surgical units retain the skills to deal with these cases.
- (5) Both the randomized trials and case series indicate very clearly that splenectomy and distal pancreatectomy are strongly associated with increased morbidity and mortality. They should not therefore be carried out unless this is strictly necessary to ensure clearance of all tumor tissue.
- (6) A randomized trial performed in Japan shows that very extensive (D4) resection is not substantially more dangerous than conventional radical dissection (D2), but evidence of a survival benefit has not yet been provided. These results are regarded as strongly context specific, and D4 resection should not be regarded as a suitable treatment option in centers without very extensive experience of this and other radical cancer operations.

In patients with a poor level of general fitness in particular, the arguments in favor of radical lymph node dissection need to be balanced against the possibility that it may increase morbidity and mortality. A commonly selected option for such patients is the 'D1+7' operation, involving removal of the stomach and perigastric nodes together with the whole of the left gastric artery and associated lymph nodes.

## Minimally invasive surgery

Laparoscopic distal gastrectomy was first performed in 1992<sup>44</sup> and total gastrectomy in 1996<sup>45</sup> but most initially regarded it as impractical because of long operating times and concerns about the ability to perform appropriate dissections. Technical advances, particularly the development of the harmonic scalpel, together with increasing experience with laparoscopic surgery generally in the surgical community, mean that laparoscopic resection is now a serious option for a significant number of patients. Laparoscopic resection appears safe, with a mortality rate which may be lower than that for open operation in the same type of patient<sup>46</sup>. In the only two randomized comparisons published to date, parameters such as average hospital stay and return to normal activities were shorter than for open operation<sup>47,48</sup>. As yet there are insufficient data to allow definite conclusions about the place of laparoscopic gastrectomy, but it seems likely that it will become an option in most specialist centers in the near future, probably for small bulk disease and in poorer risk patients.

## PALLIATIVE SURGERY

Palliative surgeries for cancer should, by definition, concentrate on relieving symptoms. The role of surgery in palliating symptoms of gastric cancer has declined in recent years because of the improving results of non-surgical options. The principal symptoms which require treatment in patients with advanced gastric cancer are pain, vomiting, bleeding, and anorexia. Gastrectomy has no role to play in correcting anorexia, but can effectively deal with the other three symptoms in particular circumstances. Intractable pain from gastric cancer is relatively rare, and is often associated with very widespread disease that cannot be successfully resected. Operation for pain should therefore only be undertaken when there is good evidence from CT or other modalities that a resection is feasible, and non-surgical measures have failed to relieve the pain. Chronic hemorrhage from gastric cancer commonly leads to anemia, but this can very often be dealt with by top-up transfusions on a fortnightly basis. Since the life expectancy of a patient in this situation is extremely limited, this is often sufficient to relieve the symptoms without resorting to surgery. Intractable vomiting from gastric cancer commonly arises from pyloric obstruction, complete paralysis of the gastric tube due to widespread infiltration, or multiple peritoneal and retroperitoneal metastases causing effective paralysis of the entire gastrointestinal tract. Occasionally patients in good condition can derive benefit from a palliative total

gastrectomy for linitis plastica, and experience an improved quality of life for a worthwhile period of time. This is a relatively rare situation but one well worth defining since there are no other effective treatments for it. Pyloric obstruction, on the other hand, is now being dealt with successfully by duodenal stenting in the majority of cases, and this should undoubtedly be preferred to surgical bypass if it is technically possible.

## NEOADJUVANT AND ADJUVANT CHEMOTHERAPY

Neoadjuvant chemotherapy has been proposed as an additional treatment modality in patients with advanced gastric cancer, either as a means of rendering some inoperable patients surgical candidates, or to increase the cure rate in operable patients by eliminating systemic micrometastatic disease. Early data on this approach showed mixed results<sup>49-51</sup>. One recent study demonstrated promising findings in the former group, with downstaging achieved in 13 of 30 patients<sup>52</sup>. In the recent MAGIC trial, Cunningham *et al.* demonstrated that a perioperative regimen of epirubicin, cisplatin and infused fluorouracil (ECF) decreased tumor size and stage, and significantly improved progression-free and overall survival among patients with operable gastric and lower esophageal adenocarcinoma<sup>53</sup>. Opponents of this strategy argue that the tendency of gastric cancer to be resistant to chemotherapy makes neoadjuvant treatment ill advised<sup>54</sup>. Phase II studies have evaluated multidrug regimens such as cisplatin-fluorouracil, doxorubicin, high-dose methotrexate (FAMTX), and other cisplatin-containing regimens<sup>55</sup>.

Adjuvant chemoradiotherapy has proved to be beneficial in comparison with surgery alone for cases of adenocarcinoma of the gastroesophageal junction or stomach. In a recent trial, 556 patients who underwent resection of gastric or gastroesophageal adenocarcinoma were randomly assigned to surgery plus postoperative chemoradiotherapy or surgery alone<sup>56</sup>. In this study, median survival in the surgery-only group was 27 months, compared with 36 months in the group receiving chemoradiotherapy<sup>56</sup>. The regimen instituted in this trial consisted of 425 mg of fluorouracil per square meter of body-surface area per day, plus 20 mg of leucovorin per square meter per day, for 5 days, followed by 4500 cGy of radiation at 180 cGy per day, given 5 days per week for 5 weeks<sup>56</sup>. One month following completion of radiotherapy, two 5-day cycles of fluorouracil and leucovorin were given 1 month apart<sup>56</sup>. Criticism of this study has centered on the inadequacy of surgery in a large percentage of the patients, and the relatively poor stage-specific



survival in both groups, permitting the charge that chemoradiation merely compensated for insufficiently radical surgery.

## PALLIATIVE CHEMOTHERAPY AND RADIOTHERAPY

The importance of palliation is obvious in treating gastric cancer, since more than two-thirds of patients present with advanced disease<sup>57,58</sup>. While surgery, radiotherapy and chemotherapy have all been implemented for palliation, chemotherapy appears to be the best option for prolonging survival and improving quality of life<sup>59,60</sup>. Median survival for patients with metastatic disease is between 6 and 9 months<sup>61</sup>. Combination chemotherapy demonstrates improved response rates without a significant difference in survival when compared with monotherapy<sup>61</sup>. ECF regimens are most often used, but irinotecan- or taxane-based regimens have also been shown to be effective<sup>61</sup>. Nevertheless, prognosis remains poor for patients with metastatic disease and response to palliative treatment is limited at best.

## OUTCOMES

The chief outcome measure for the efficacy of surgery for established gastric cancer is long-term patient survival. Figures for this vary greatly depending on the stage of the tumor at the time of operation. As with short-term outcomes, specialist units report considerably better survival figures than cross-sectional surveys. The majority of cancer recurrence in gastrectomy occurs during the first 2 years after the operation. For established gastric cancer, the commonest cause of failure is recurrence in the peritoneal cavity, followed by locoregional disease originating from the regional lymph nodes or the resection margin. Since the overall mean survival figure is so highly dependent on the stage distribution of the population, it is not a useful parameter for comparing results between centers, but overall figures of 30–40% 5-year survival are now frequently reported for apparently curative resections from major Western centers, and much higher figures have been reported<sup>62</sup>.

### Mortality

Figures for operative mortality have in fact improved steadily over the past 3 decades, in common with those for most other major abdominal operations. Mortality results remain highly variable depending on the patient population and the setting, and the difference between

results reported from specialist expert centers and those from confidential surveys and population data is enormous. The National Cancer Center Hospital in Tokyo has published an account of 1000 consecutive gastrectomies without a death<sup>63</sup>, whilst a contemporary confidential survey of British hospitals showed a mean mortality rate of 10.3%<sup>23</sup>. Publications from high volume expert centers in countries with well developed health systems currently report mortality rates under 5%, and often under 3%<sup>64–66</sup>. Total gastrectomy is consistently at least twice as dangerous as distal gastrectomy<sup>23,65,67</sup>, although there are some notable exceptions to this rule<sup>68</sup>. Mortality results are critically dependent on case selection, and need to be interpreted with an eye to the philosophy underlying this. This is often difficult to determine from published reports. Apart from selection of procedure, the factor with the strongest association with increased mortality is co-morbid pathology. Studies using the POSSUM system and the ASA scale show strong correlations between decreasing fitness and operative risk<sup>23,24,67,69</sup>. Age is certainly a risk factor, although interestingly not an independent one in studies using logistic regression to factor out the effect of fitness<sup>70</sup>. Sex is a factor in some series, female patients doing better than males. In common with other forms of major cancer surgery, gastrectomy morbidity is associated with uncorrected preoperative malnutrition<sup>70</sup> and mortality with unit case volume<sup>71–73</sup>.

### Postoperative complications

Gastrectomy shares many postoperative complications with other major abdominal operations. The most common serious complications are respiratory failure/infection and anastomotic leak (including leakage from the duodenal stump). In elderly Western populations cardiac arrhythmias, failure and perioperative infarction and venous thrombo-embolism are also significant and dangerous complications, whereas these are much less frequently reported in series from East Asian countries. Enteric fistulas can occur after anastomotic leakage, and trauma to the pancreas in radical operations can result in pancreatitis, pancreatic fistula, or abscess formation, the last being extremely dangerous as it tends to erode local vessels and cause major hemorrhage. The spleen is always at risk of damage during total gastrectomy, especially in obese patients with multiple capsular adhesions, and this can necessitate splenectomy (as can local or nodal extension of the tumor). The resultant depression of opsonization increases the risk of both early and late infection. One clear lesson from the trials of radical 'D2' surgery was that resection of the spleen and distal pancreas both add very significantly to the risks of morbidity, and

therefore should only be carried out if oncologically essential for complete tumor resection. Bleeding and wound dehiscence are relatively rare, but the issue of hospital acquired infection has grown in importance over the past decade, and the risk of acquiring invasive methicillin-resistant *Staphylococcus aureus* (MRSA) infection or *Clostridium difficile* colitis is now a significant problem in many hospitals.

In addition to the complications described, the normal uncomplicated course of events after a gastrectomy will include a number of expected but undesirable health consequences. The weakness and tiredness associated with any major surgery usually takes several months to resolve completely, and in the case of gastrectomy this is further added to by the nutritional problems induced by removal of part or all of the stomach. Patients can expect to have a smaller appetite and small capacity, and to lose weight for some time after leaving hospital until they reach a stable metabolic state. The long-term nutritional consequences of gastrectomy are well recognized.

As well as protein-calorie malnutrition (which is much worse in total gastrectomy but tends to improve after 3 years in survivors) there are specific problems with calcium, vitamin C, iron, and vitamin B12 absorption. These can be dealt with by supplements except for the osteoporosis associated with calcium malabsorption. Dumping, a syndrome comprising faintness, hypotension, sweating and sometimes diarrhea, occurs occasionally or to a mild degree in many gastrectomized patients, but to a severe extent in relatively few. Treatment is mainly by dietary manipulation, although various authors have claimed success for surgical revisions to slow transit. Bile reflux can cause devastating symptoms of reflux, vomiting and anorexia, and can be dramatically improved by creating or lengthening a Roux loop. Diarrhea and postprandial pain affect a significant minority of patients, often for reasons which cannot be definitively demonstrated. Despite this catalogue, the majority of 5-year survivors live relatively normal lives with well-controlled or minor symptoms only.

## REFERENCES

- Office for National Statistics, Cancer Statistics Registrations. Registrations of cancer diagnosed in 2003, England, series MB1, no. 34, 2006, National Statistics: London.
- Office for National Statistics. Cancer Statistics Registrations. Registrations of cancer diagnosed in 2002, England. 2005. Series MB1 no. 33. London: 2006.
- Newnham A, Quinn MJ, Babb P et al. Trends in oesophageal and gastric cancer incidence, mortality and survival in England and Wales 1971–1998/1999. *Aliment Pharmacol Ther* 2003; 17: 655–64.
- Tashiro A, Sano M, Kinameri K et al. Comparing mass screening techniques for gastric cancer in Japan. *World J Gastroenterol* 2006; 12: 4873–4.
- Sobin LH, Wittekind CH. TNM Classification of Malignant Tumours, 6th edn. New York: Wiley, 2003.
- Adachi Y, Sakino I, Matsumata T et al. Preoperative assessment of advanced gastric carcinoma using computed tomography. *Am J Gastroenterol* 1997; 92: 872–5.
- D'Elia F, Zingarelli A, Palli D et al. Hydro-dynamic CT preoperative staging of gastric cancer: correlation with pathological findings. A prospective study of 107 cases. *Eur Radiol* 2000; 10: 1877–85.
- Wakelin SJ, Deans C, Crofts TJ et al. A comparison of computerised tomography, laparoscopic ultrasound and endoscopic ultrasound in the preoperative staging of oesophago-gastric carcinoma. *Eur J Radiol* 2002; 41: 161–7.
- Nakamoto Y, Higashi T, Sakahara H et al. Contribution of PET in the detection of liver metastases from pancreatic tumours. *Clin Radiol* 1999; 54: 248–52.
- Rasanen JV, Sihvo EI, Knuuti MJ et al. Prospective analysis of accuracy of positron emission tomography, computed tomography, and endoscopic ultrasonography in staging of adenocarcinoma of the esophagus and the esophagogastric junction. *Ann Surg Oncol* 2003; 10: 954–60.
- Zhuang H, Sinha P, Pourdehnad M et al. The role of positron emission tomography with fluorine-18-deoxyglucose in identifying colorectal cancer metastases to liver. *Nucl Med Commun* 2000; 21: 793–98.
- Chen F, Ni YC, Zheng KE et al. Spiral CT in gastric carcinoma: comparison with barium study, fiberoptic gastroscopy and histopathology. *World J Gastroenterol* 2003; 9: 1404–8.
- Ozmen MM, Zulfikaroglu B, Ozalp N et al. Staging laparoscopy for gastric cancer. *Surg Laparosc Endosc Percutan Tech* 2003; 13: 241–4.
- Blackshaw GR, Barry JD, Edwards P et al. Laparoscopy significantly improves the perceived preoperative stage of gastric cancer. *Gastric Cancer* 2003; 6: 225–9.
- D'Ugo DM, Persiani R, Caracciolo F et al. Selection of locally advanced gastric carcinoma by preoperative staging laparoscopy. *Surg Endosc* 1997; 11: 1159–62.
- Lavonius MI, Gullichsen R, Salo S et al. Staging of gastric cancer: a study with spiral computed tomography, ultrasonography, laparoscopy, and laparoscopic ultrasonography. *Surg Laparosc Endosc Percutan Tech* 2002; 12: 77–81.
- McCulloch P, Johnson M, Jairam R, Fischer W. Laparoscopic staging of gastric cancer is safe and affects treatment strategy. *Ann R Coll Surg Engl* 1998; 80: 400–2.
- O'Brien MG, Fitzgerald EF, Lee G et al. A prospective comparison of laparoscopy and imaging in the staging of esophagogastric cancer before surgery. *Am J Gastroenterol* 1995; 90: 2191–4.
- Sotiropoulos GC, Kaiser GM, Lang H et al. Staging laparoscopy in gastric cancer. *Eur J Med Res* 2005; 10: 88–91.

20. Bryan RT, Cruickshank NR, Needham SJ et al. Laparoscopic peritoneal lavage in staging gastric and oesophageal cancer. *Eur J Surg Oncol* 2001; 27: 291–7.
21. Hayes N, Wayman J, Wadehra V et al. Peritoneal cytology in the surgical evaluation of gastric carcinoma. *Br J Cancer* 1999; 79: 520–4.
22. Ribeiro U Jr, Gama-Rodrigues JJ, Bitelman B et al. Value of peritoneal lavage cytology during laparoscopic staging of patients with gastric carcinoma. *Surg Laparosc Endosc* 1998; 8: 132–5.
23. McCulloch P, Ward J, Tekkis PP. Mortality and morbidity in gastro-oesophageal cancer surgery: initial results of ASCOT multicentre prospective cohort study. *BMJ* 2003; 327: 1192–7.
24. Tekkis PP, McCulloch P, Poloniecki JD et al. Risk-adjusted prediction of operative mortality in oesophagogastric surgery with O-POSSUM. *Br J Surg* 2004; 91: 288–95.
25. Goldman L, Caldera DL, Nussbaum SR et al. Multifactorial index of cardiac risk in noncardiac surgical procedures. *N Engl J Med* 1977; 297: 845–50.
26. Prause G, Ratzenhofer-Comenda B, Pierer G et al. Can ASA grade or Goldman's cardiac risk index predict peri-operative mortality? A study of 16, 227 patients. *Anaesthesia* 1997; 52: 203–6.
27. White GH, Advani SM, Williams RA, Wilson SE. Cardiac risk index as a predictor of long-term survival after repair of abdominal aortic aneurysm. *Am J Surg* 1988; 156: 103–7.
28. Zeldin RA. Assessing cardiac risk in patients who undergo noncardiac surgical procedures. *Can J Surg* 1984; 27: 402–4.
29. Bartels H, Stein HJ, Siewert JR. Preoperative risk analysis and postoperative mortality of oesophagectomy for resectable oesophageal cancer. *Br J Surg* 1998; 85: 840–4.
30. Ochiai T, Sasako M, Mizuno S et al. Hepatic resection for metastatic tumours from gastric cancer: analysis of prognostic factors. *Br J Surg* 1994; 81: 1175–8.
31. McCulloch P, Niita ME, Kazi H, Gama-Rodrigues JJ. Gastrectomy with extended lymphadenectomy for primary treatment of gastric cancer. *Br J Surg* 2005; 92: 5–13.
32. Davies J, Johnston D, Sue-Ling H et al. Total or subtotal gastrectomy for gastric carcinoma? A study of quality of life. *World J Surg* 1998; 22: 1048–55.
33. Imada T, Rino Y, Takahashi M et al. Gastric emptying after pylorus-preserving gastrectomy in comparison with conventional subtotal gastrectomy for early gastric carcinoma. *Surg Today* 1998; 28: 135–8.
34. Kodama M, Koyama K. Indications for pylorus preserving gastrectomy for early gastric cancer located in the middle third of the stomach. *World J Surg* 1991; 15: 628–33.
35. Shibata C, Shiiba KI, Funayama Y et al. Outcomes after pylorus-preserving gastrectomy for early gastric cancer: a prospective multicenter trial. *World J Surg* 2004; 28: 857–61.
36. Dillard DH, Griffith CA, Merendino KA. The surgical construction of an esophageal valve to replace the cardiac sphincter; an experimental study. *Surg Forum* 1954; 5: 306–14.
37. Merendino KA, Thomas GI. The jejunal interposition operation for substitution of the esophagogastric sphincter; present status. *Surgery* 1958; 44: 1112–5.
38. Thomas GI, Merendino KA. Jejunal interposition operation; analysis of thirty-three clinical cases. *JAMA* 1958; 168: 1759–66.
39. Katai H, Sano T, Fukagawa T et al. Prospective study of proximal gastrectomy for early gastric cancer in the upper third of the stomach. *Br J Surg* 2003; 90: 850–3.
40. Adashek K, Sanger J, Longmire WP Jr. Cancer of the stomach. Review of consecutive ten year intervals. *Ann Surg* 1979; 189: 6–10.
41. Dupont JB Jr, Lee JR, Burton GR, Cohn I Jr. Adenocarcinoma of the stomach: review of 1,497 cases. *Cancer* 1978; 41: 941–7.
42. Inberg MV, Heinonen R, Rantakokko V, Viikari SJ. Surgical treatment of gastric carcinoma: a regional study of 2,590 patients over a 27-year period. *Arch Surg* 1975; 110: 703–7.
43. White RR, Mackie JA, Fitts WT Jr. An analysis of twenty years' experience with operations for carcinoma of the stomach. *Ann Surg* 1975; 181: 611–5.
44. Goh P, Tekant Y, Isaac J et al. The technique of laparoscopic Billroth II gastrectomy. *Surg Laparosc Endosc* 1992; 2: 258–60.
45. Ablassmaier B, Gellert K, Said S et al. [Laparoscopic gastrectomy. A case report]. *Chirurg* 1996; 67: 643–7.
46. Kitano S, Shiraishi N. Current status of laparoscopic gastrectomy for cancer in Japan. *Surg Endosc* 2004; 18: 182–5.
47. Kitano S, Shiraishi N, Fujii K et al. A randomized controlled trial comparing open vs laparoscopy-assisted distal gastrectomy for the treatment of early gastric cancer: an interim report. *Surgery* 2002; 131: S306–11.
48. Huscher CG, Mingoli A, Sgarzini G et al. Laparoscopic versus open subtotal gastrectomy for distal gastric cancer: five-year results of a randomized prospective trial. *Ann Surg* 2005; 241: 232–7.
49. Wilke H, Preusser P, Fink U et al. Preoperative chemotherapy in locally advanced and nonresectable gastric cancer: a phase II study with etoposide, doxorubicin, and cisplatin. *J Clin Oncol* 1989; 7: 1318–26.
50. Plukker JT, Sleijfer DT, Verschueren RC et al. Neo-adjuvant chemotherapy with carboplatin, 4-epidriamycin and teniposide (CET) in locally advanced cancer of the cardia and the lower oesophagus: a phase II study. *Anticancer Res* 1995; 15: 2357–61.
51. Ajani JA, Mayer RJ, Ota DM et al. Preoperative and postoperative combination chemotherapy for potentially resectable gastric carcinoma. *J Natl Cancer Inst* 1993; 85: 1839–44.
52. D'Ugo D, Persiani R, Rauzei S et al. Response to neoadjuvant chemotherapy and effects of tumor regression in gastric cancer. *Eur J Surg Oncol* 2006; 32: 1105–9.
53. Cunningham D, Allum WH, Stenning SP et al. Perioperative chemotherapy versus surgery alone for resectable gastroesophageal cancer. *N Engl J Med* 2006; 355: 11–20.
54. Nakajima T, Nashimoto A, Kitamura M et al. Adjuvant mitomycin and fluorouracil followed by oral uracil plus tegafur in serosa-negative gastric cancer: a randomised trial. *Gastric Cancer Surgical Study Group. Lancet* 1999; 354: 273–7.
55. Kelsen D. Neoadjuvant therapy for upper gastrointestinal tract cancers. *Curr Opin Oncol* 1996; 8: 321–8.
56. Macdonald JS, Smalley SR, Benedetti J et al. Chemoradiotherapy after surgery compared with surgery alone for adenocarcinoma of the stomach or gastroesophageal junction. *N Engl J Med* 2001; 345: 725–30.
57. Greenlee RT, Hill-Harmon MB, Murray T, Thun M. Cancer statistics, 2001. *CA Cancer J Clin* 2001; 51: 15–36.
58. Greenlee RT, Murray T, Bolden S, Wingo PA. Cancer statistics, 2000. *CA Cancer J Clin* 2000; 50: 7–33.
59. Pyrhonen S, Kuitunen T, Nyandoto P, Kouri M. Randomised comparison of fluorouracil, epidoxorubicin and methotrexate (FEMTX) plus supportive care with supportive care alone in patients with non-resectable gastric cancer. *Br J Cancer* 1995; 71: 587–91.
60. Murad AM, Santiago FF, Petroianu A et al. Modified therapy with 5-fluorouracil, doxorubicin, and methotrexate in advanced gastric cancer. *Cancer* 1993; 72: 37–41.
61. Wohrer SS, Raderer M, Hejna M. Palliative chemotherapy for advanced gastric cancer. *Ann Oncol* 2004; 15: 1585–95.

62. Degiuli M, Sasako M, Ponti A, Calvo F. Survival results of a multicentre phase II study to evaluate D2 gastrectomy for gastric cancer. *Br J Cancer* 2004; 90: 1727–32.
63. Sano T, Katai H, Sasako M, Maruyama K. One thousand consecutive gastrectomies without operative mortality. *Br J Surg* 2002; 89: 123.
64. Kan YF, Zheng Y, Li SY et al. [Postoperative mortality after gastrectomy for gastric cancer: analysis of 1142 cases]. *Zhonghua Wei Chang Wai Ke Za Zhi* 2005; 8: 422–4.
65. Degiuli M, Sasako M, Ponti A et al. Morbidity and mortality after D2 gastrectomy for gastric cancer: results of the Italian Gastric Cancer Study Group prospective multicenter surgical study. *J Clin Oncol* 1998; 16: 1490–93.
66. Bittner R, Butters M, Ulrich M et al. Total gastrectomy. Updated operative mortality and long-term survival with particular reference to patients older than 70 years of age. *Ann Surg* 1996; 224: 37–42.
67. Wu CW, Hsieh MC, Lo SS et al. Morbidity and mortality after radical gastrectomy for patients with carcinoma of the stomach. *J Am Coll Surg* 1995; 181: 26–32.
68. Bozzetti F, Marubini E, Bonfanti G et al. Total versus subtotal gastrectomy: surgical morbidity and mortality rates in a multicenter Italian randomized trial. The Italian Gastrointestinal Tumor Study Group. *Ann Surg* 1997; 226: 613–20.
69. Prause G, Ratzehofer-Comenda B, Pierer G et al. Can ASA grade or Goldman's cardiac risk index predict peri-operative mortality? A study of 16,227 patients. *Anaesthesia* 1997; 52: 203–6.
70. Bittner R, Butters M, Ulrich M et al. Total gastrectomy. Updated operative mortality and long-term survival with particular reference to patients older than 70 years of age. *Ann Surg* 1996; 224: 37–42.
71. McCulloch P, Nita ME, Kazi H, Gama-Rodrigues J. Extended versus limited lymph nodes dissection technique for adenocarcinoma of the stomach. *Cochrane Database Syst Rev* 2004; (4): CD001964.
72. Tekkis PP, McCulloch P, Steger AC et al. Mortality control charts for comparing performance of surgical units: validation study using hospital mortality data. *BMJ* 2003; 326: 786–8.
73. Fujita T, Yamazaki Y. Influence of surgeon's volume on early outcome after total gastrectomy. *Eur J Surg* 2002; 168: 535–8.
- Rossi M, Broglia L, Arata FM et al. [The diagnostic accuracy and reproducibility of computed tomography with water distention and induced hypotonia in the preoperative staging of gastric tumors]. *Radiol Med (Torino)* 1997; 94: 486–91.
- Polkowski M, Palucki J, Wronska E et al. Endosonography versus helical computed tomography for locoregional staging of gastric cancer. *Endoscopy* 2004; 36: 617–23.
- Ong KC, Benedicto JP, Chan AH et al. Cardiopulmonary exercise testing in heart transplant candidates. *Ann Acad Med Singapore* 2000; 29: 442–6.
- Weisman IM. Cardiopulmonary exercise testing in the preoperative assessment for lung resection surgery. *Semin Thorac Cardiovasc Surg* 2001; 13: 116–25.
- Kampschoer GH, Maruyama K, van d et al. Computer analysis in making preoperative decisions: a rational approach to lymph node dissection in gastric cancer patients. *Br J Surg* 1989; 76: 905–8.
- Bozzetti F, Marubini E, Bonfanti G et al. Total versus subtotal gastrectomy: surgical morbidity and mortality rates in a multicenter Italian randomized trial. The Italian Gastrointestinal Tumor Study Group. *Ann Surg* 1997; 226: 613–20.
- Takahashi S, Maeta M, Mizusawa K et al. Long-term postoperative analysis of nutritional status after limited gastrectomy for early gastric cancer. *Hepatogastroenterology* 1998; 45: 889–94.
- Hiarayama R, NZMTUJIS. The clinico-embryological basis to the surgical management of carcinoma of the upper and middle stomach. *Jpn J Gastroenterol* 1979; 12: 966–70.
- Soga J, KKSJFMMM. The role of lymphadenectomy in curative surgery for gastric cancer. *World J Surg* 1979; 3: 701–8.
- Evaluation of extensive lymph node dissection for carcinoma of the stomach. *World J Surg* 1981; 5: 241–8.
- McNeer G, Bowden L, Booner RJ, McPeak CJ. Elective total gastrectomy for cancer of the stomach: end results. *Ann Surg* 1974; 180: 252–6.
- Evaluation of extensive lymph node dissection for carcinoma of the stomach. *World J Surg* 1981; 5: 241–8.
- Kajitani TTK. Cancer of the stomach at Cancer Institute Hospital, Tokyo. *Gann Monograph on cancer research* 1979; 22: 77–87.
- Maruyama K, Okabayashi K, Kinoshita T. Progress in gastric cancer surgery in Japan and its limits of radicality. *World J Surg* 1987; 11: 418–25.
- Cuschieri A, Weeden S, Fielding J et al. Patient survival after D1 and D2 resections for gastric cancer: long-term results of the MRC randomized surgical trial. Surgical Co-operative Group. *Br J Cancer* 1999; 79: 1522–30.
- Cuschieri A, Fayers P, Fielding J et al. Postoperative morbidity and mortality after D1 and D2 resections for gastric cancer: preliminary results of the MRC randomised controlled surgical trial. The Surgical Cooperative Group. *Lancet* 1996; 347: 995–9.
- Bonenkamp JJ, Hermans J, Sasako M et al. Extended lymph-node dissection for gastric cancer. *N Engl J Med* 1999; 340: 908–14.
- Bonenkamp JJ, Songun I, Hermans J et al. Randomised comparison of morbidity after D1 and D2 dissection for gastric cancer in 996 Dutch patients. *Lancet* 1995; 345: 745–8.
- Kitagawa Y, Fujii H, Kumai K et al. Recent advances in sentinel node navigation for gastric cancer: a paradigm shift of surgical management. *J Surg Oncol* 2005; 90: 147–51.
- Ryu KW, Lee JH, Kim HS et al. Prediction of lymph nodes metastasis by sentinel node biopsy in gastric cancer. *Eur J Surg Oncol* 2003; 29: 895–9.
- Ajisaka H, Miwa K. Micrometastases in sentinel nodes of gastric cancer. *Br J Cancer* 2003; 89: 676–80.
- Kitagawa Y, Fujii H, Mukai M et al. Radio-guided sentinel node detection for gastric cancer. *Br J Surg* 2002; 89: 604–8.
- Hiratsuka M, Miyashiro I, Ishikawa O et al. Application of sentinel node biopsy to gastric cancer surgery. *Surgery* 2001; 129: 335–40.
- Profilì S, Meloni GB, Bifulco V et al. Self-expandable metal stents in the treatment of antro-pyloric and/or duodenal strictures. *Acta Radiol* 2001; 42: 176–80.
- Takachi K, Doki Y, Ishikawa O et al. Postoperative ghrelin levels and delayed recovery from body weight loss after distal or total gastrectomy. *J Surg Res* 2006; 130: 1–7.
- Dornonville de la CC, Lindqvist A, Eggecioglu E et al. Ghrelin treatment reverses the reduction in weight gain and body fat in gastrectomised mice. *Gut* 2005; 54: 907–13.
- von TC, Reinshagen M. Management of osteoporosis in patients with gastrointestinal diseases. *Eur J Gastroenterol Hepatol* 2003; 15: 869–76.
- Lehnert T, Buhl K. Techniques of reconstruction after total gastrectomy for cancer. *Br J Surg* 2004; 91: 528–39.
- Hoerr SO. Prognosis for carcinoma of the stomach. *Surg Gynecol Obstet* 1973; 137: 205–9.

Hundahl SA, Menck HR, Mansour EG, Winchester DP. The National Cancer Data Base report on gastric carcinoma. *Cancer* 1997; 80: 2333–41.

Hundahl SA, Macdonald JS, Benedetti J, Fitzsimmons T. Surgical treatment variation in a prospective, randomized trial of chemoradiotherapy in gastric cancer: the effect of undertreatment. *Ann Surg Oncol* 2002; 9: 278–86.

Harrison LE, Karpeh MS, Brennan MF. Extended lymphadenectomy is associated with a survival benefit for node-negative gastric cancer. *J Gastrointest Surg* 1998; 2: 126–31.

Martin RC, Jaques DP, Brennan MF, Karpeh M. Extended local resection for advanced gastric cancer: increased survival versus increased morbidity. *Ann Surg* 2002; 236: 159–65.

# Small bowel and appendiceal tumors

15

Sarah T O'Dwyer

---

## INTRODUCTION

Despite accounting for 90% of the surface area of the gastrointestinal tract (GIT) tumors of the small bowel are rare, contributing in the order of 3% of all GIT neoplasms. True benign tumors including hamartomas, hyperplastic and inflammatory polyps account for approximately 20% of lesions; tumors with malignant potential such as adenomatous polyps, gastrointestinal stromal tumors and non-malignant carcinoids amount to 30% of the total, leaving 50% of small bowel tumors which are considered malignant at presentation. In the past, patients were rarely diagnosed preoperatively but advances in imaging techniques have opened up opportunities for less invasive and more accurate diagnosis and staging. Taken alongside a better organized and aggressive approach to multimodality treatment a more optimistic outcome for patients with small bowel tumors is anticipated.

## EPIDEMIOLOGY

Due to the rarity of these tumors very few large series have been reported. Over the past decade in the ten reported series four have had greater than 50 cases with only one series reporting on greater than 100 patients<sup>1-10</sup> (Table 15.1). Cancer registers in the UK and USA are a valuable source of information particularly for less common cancers. Interrogation of the US Surveillance Epidemiology and End Results (SEER) database compiled from 11 tumor registries has revealed incidence rates for the most common major histological types of small bowel cancers. Over an 18-year registry the average annual incidence of small bowel cancer was almost 10 per million population with malignant carcinoid and adenocarcinomas of almost equal incidence of 3.8 and 3.7 per million, respectively<sup>11</sup>. Sarcomas and lymphomas occurred in 1.3 and 1.1 per million, respectively, and, whilst the incidence of sarcoma remained static over the study period, the number of carcinoids and lymphomas slowly increased, the increase in lymphomas being more prominent. For all four histological subtypes

rates were higher in men than women and over 90% of cases occurred in patients over 40 years of age.

Similar UK incidence rates for small bowel cancers are documented as 12 per million population with a slightly higher rate in males of 14 versus 11 in females per million<sup>12</sup>. Valuable data have also been generated from the British Society of Gastroenterology (BSG) register of 395 small bowel tumors reported in 2003<sup>13</sup>. The registry was compiled over 2 years (1998–2000) and identified adenocarcinoma in 44% of the cohort, lymphomas in 27%, and carcinoid tumors in 20%. Evaluation of the other reported larger series from US, Europe and Australia demonstrate similar patterns of incidence by histological type<sup>1-3, 8</sup>. Adenocarcinomas tend to be located more proximally in the duodenum and jejunum, carcinoids in the ileum (and appendix), and lymphomas evenly distributed throughout the small bowel.

## RISK FACTORS

The different histological types of small bowel malignancies are associated with individual predisposing conditions that increase the risk for an individual of developing a tumor (Table 15.2). The most recognized group are patients with celiac disease who have a greater incidence of both small bowel lymphoma and adenocarcinoma, and it is thought that treatment of the underlying condition seems to decrease their risk<sup>13,14</sup>. Adenocarcinomas are also associated with the gastrointestinal polyposis syndromes (familial polyposis) and hereditary non-polyposis colon cancer families (HNPCC). Assessment of tumor incidence from a HNPCC registry revealed 42 individuals from 40 families who developed 42 primary and seven metachronous small bowel tumors<sup>15</sup>. It is notable that the small bowel rather than the colon was the first site of carcinoma in 57% of cases and that in polyposis families the small bowel tumors presented at an earlier age (49 years) than those occurring in the general population (~60 years)<sup>16</sup>.

Genetic predisposition is also associated with neurofibromatosis and carcinoid tumors. Analysis of the Swedish

**Table 15.1** Published series of small bowel tumors 1996–2005

<i>Authors</i>	<i>Year</i>	<i>Number of cases</i>	<i>Length of series (year)</i>
Cunningham <i>et al.</i> <sup>1</sup>	1997	73	21
Minadi <i>et al.</i> <sup>2</sup>	1998	89	10
Brucher <i>et al.</i> <sup>3</sup>	1998	71	—
Rodriguez <i>et al.</i> <sup>4</sup>	1998	42	—
O'Boyle <i>et al.</i> <sup>5</sup>	1998	25	10
Bozdag <i>et al.</i> <sup>6</sup>	2003	15	10
Teres-Maria <i>et al.</i> <sup>7</sup>	2003	13	2
Rangiah <i>et al.</i> <sup>8</sup>	2004	166	10
Mussi <i>et al.</i> <sup>9</sup>	2005	45	20
Cateno <i>et al.</i> <sup>10</sup>	2005	34	10

**Table 15.2** Risk factors for small bowel tumors

<i>Family history</i>	<i>Immunological</i>	<i>Treatment related</i>
FAP	Crohn's	Postradiotherapy
HNPCC	Celiac	Ileal conduits
Carcinoids	HIV/AIDS	
	Transplant recipients	

FAP, familial adenomatous polyposis; HNPCC, hereditary non-polyposis colon cancer; HIV, human immunodeficiency virus.

family cancer database revealed that a history of carcinoids in first-degree relatives is associated in a relative risk of 3.6 over the population at large<sup>17</sup>. Furthermore, small bowel carcinoids are more common in men and appendiceal carcinoids are more common in women. Additional risk is dependent on chronic inflammatory bowel disease particularly Crohn's disease and nodular lymphoid hyperplasia but is also recognized in patients with ileal conduits for urinary diversion. Immunodeficiency syndromes (e.g. HIV/AIDS), transplant recipients and previous radical abdominal radiotherapy also predispose to the generation of small bowel malignancies of varying histological type<sup>14</sup>. Awareness of these at risk groups should generate enhanced vigilance and alert health-care workers to the need for more intensive investigation of non-specific gastrointestinal symptoms.

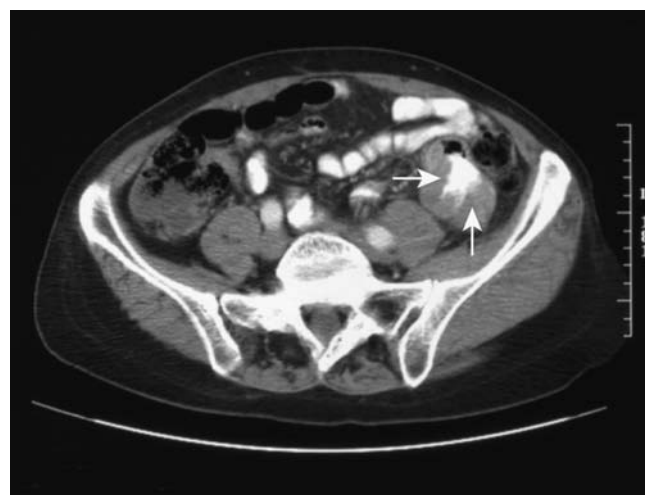
## SMALL BOWEL TUMORS

### Clinical presentation, investigations and diagnosis

Small bowel neoplasms are notorious for their insidious presentation, vague symptoms and lack of physical signs

that leads to a significant delay in reaching a definitive diagnosis. In a number of series the duration of symptoms is greater than 6 months. Abdominal pain, nausea and vomiting are the commonest symptoms with anemia and GI hemorrhage occurring in more benign tumors and obstruction in more malignant variants<sup>10</sup>. Emergency presentations include bleeding, commonly in gastrointestinal stromal tumors (GISTs), perforation in lymphomas, obstruction in adenocarcinomas and carcinoids, and intussusception in melanoma<sup>8,10</sup>. Earlier series note the few cases that have been satisfactorily diagnosed prior to surgery (~20%)<sup>1</sup>, whilst more recently in a series of 166 cases a preoperative diagnosis was made in 77%<sup>8</sup>.

Improved imaging using multi-thin slice computed tomography (CT) scanning of the abdomen allows better definition of the small bowel allowing evaluation of extrinsic and intrinsic disease (Figure 15.1). The use of CT has now superseded the need for standard contrast and fluoroscopic evaluation of the small bowel with CT enterography enhancing the appearance of mucosal and intramural lesions<sup>18</sup>. Additional value is obtained in staging the malignant tumors and assisting in planning treatment pathways that may include neoadjuvant treatments in adenocarcinoma and carcinoid tumors, and avoid unnecessary surgery in lymphoma. Improved planning allows decisions directed toward curative or palliative surgical approaches where appropriate. Functional techniques including positron emission tomography (PET) and radionuclide octreotide scanning can also assist in defining extent of disease in both adenocarcinoma and carcinoids. In more localized disease standard endoscopy, small bowel enteroscopy and wireless capsule enteroscopy has been successfully employed to achieve a diagnosis and may prove worthwhile in surveillance of polyposis syndromes and hopefully



**Figure 15.1** Arrows indicate soft tissue shadow adherent to small bowel causing partial obstruction in a patient previously diagnosed with malignant melanoma.

assist in early identification of progression to more aggressive disease<sup>19</sup>.

Definitive diagnosis will usually require tissue sampling but for carcinoid tumors morphological and secretory functional evidence may be adequate to allow systemic treatment to be initiated. Urinary HIAA assessment alongside positive octreotide scanning is often diagnostic, although histological assessment remains the gold standard<sup>20</sup>. Elevation of circulating tumor markers including carcinoembryonic antigen (CEA) and CA19.9 provides supporting evidence for adenocarcinomas but surgical resection of the primary is usually undertaken unless there is obvious metastatic disease that lends itself to radiologically guided biopsy. Laparoscopy has its place, particularly where there is evidence of peritoneal involvement allowing more accurate staging than CT in these circumstances, with the added advantage of multiple site biopsies to assist in planning treatment extent. There remain questions regarding port site implantation particularly for mucinous tumors and if open surgery is contemplated at a later date during treatment excision of port site scars may be advisable (see appendiceal tumors below).

## DEFINITIVE TREATMENT

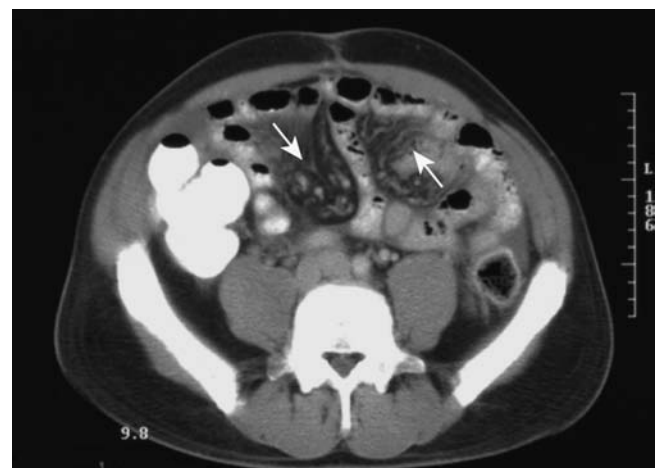For the majority of small bowel tumors surgical excision offers the best chance of cure: the notable exception being multifocal lymphoma that is best treated with minimal surgery and systemic chemotherapy. Benign lesions are usually easily resectable with minimal morbidity, whilst malignant tumors may be locally advanced rendering them unresectable or metastatic to lymph nodes, liver, peritoneum, and occasionally extra-abdominal sites. Overall at preoperative radiological staging extragastrointestinal metastatic disease is present in around 45% of cases<sup>8</sup>, and, although in most reported series the majority of primary tumors are resectable (>80%), curative resection is achieved in less than 65% of patients. Furthermore, where resection had been considered curative, recurrence occurred in 42% at a median time of 17 months<sup>1</sup>. Occasionally synchronous primary tumors occur of either similar or distinct histological types (e.g. adenocarcinomas and carcinoids) when multiple resections are appropriate but more commonly multiple tumors reflect metastatic serosal deposits from a single primary. Careful histological and immunohistochemical evaluation using cytokeratin, neuronal and mesenchymal markers is often necessary to accurately define tumor types which will in turn guide the team in considering appropriate non-surgical adjuvant therapies.

The surgical management of metastatic disease is largely confined to liver lesions that may be suitable for resection, embolization, or ablative treatment. Such an approach

may be aimed at cure but even if palliative, these interventions can assist in decreasing tumor burden prior to the use of systemic therapy. Palliative procedures including the positioning of intraluminal stents can successfully allow relief of proximal small bowel obstruction and restoration of intestinal function<sup>21</sup>. Surgical by-pass procedures and limited resections for serosal deposits leading to obstruction and/or intussusception may be necessary but, where there is evidence of diffuse multifocal peritoneal disease, surgery should be avoided and good supportive care employed (Figure 15.2). It is the author's view that the introduction of parenteral nutrition in the presence of intestinal failure from inoperable disease is not appropriate. The insertion of a drainage gastrostomy may be a useful palliative maneuver to assist in keeping a terminal patient more comfortable.

## ADJUVANT TREATMENTS

Following surgery patients should be discussed by a multidisciplinary team and specialist advice sought for these rare tumors. Whilst there is little place for radiotherapy except in the targeted palliation of pain, systemic therapies are now coming to the fore as neoadjuvant, adjuvant and supportive treatments. Examples of good response rates include the use of adjuvant immunotherapy in c-KIT positive GISTs<sup>22</sup>, downstaging tumors rendering resectability<sup>23</sup>; c-KIT negative sarcomas, however, have a less than 15% response rate to adjuvant treatment hence an aggressive surgical approach with resection of multifocal disease is advised where possible<sup>24</sup> (Figure 15.3). Combination chemotherapy and antivascular endothelial growth factor (VEGF) immunotherapy in carcinoids and adenocarcinoma show promise and are currently the subject of clinical trials.



**Figure 15.2** Multifocal intraperitoneal disease involving the serosa of the small bowel with tethering of bowel loops.



## Outcome

In 2002 the number of deaths from small bowel cancer in the UK was recorded as 5 per million<sup>12</sup>. Taking the annual incidence as 12 per million the overall prognosis remains poor. Reported series are inevitably hindered by the length of time needed to acquire adequate numbers from which to draw meaningful conclusions. Furthermore, new and current treatments that may influence response rates and survival will not be reflected in such figures. The most accurate evaluation of overall survival in current practice emanates from the BSG registry that reported survival at 30 months as 78% for carcinoid, 58% for adenocarcinoma, and 45% for lymphoma<sup>13</sup>. Unfortunately, because of the rarity of these tumors and the indolent and diverse mode of presentation, patients may be treated by non-specialist groups and denied access to state of the art treatments. It is hoped that with current imaging and less invasive methods of diagnosis as well as earlier referral to specialist units will allow structured treatment with better outcomes in future.

## APPENDICEAL TUMORS

The past 10 years have seen a major shift in our knowledge and understanding regarding the origin and treatments for appendiceal tumors. Whilst the commonest tumor arising at this site is the neuroendocrine carcinoid, the majority of which are diagnosed incidentally and do not metastasize, epithelial adenomatous tumors are now known to be more pervasive, associated with the development of diffuse peritoneal neoplasia. When the tumor is mucinous in nature the features are best described as Pseudomyxoma peritonei (PMP). The incidence of epithelial tumors that go on to generate the PMP syndrome is estimated as 1–2 per million of the population.

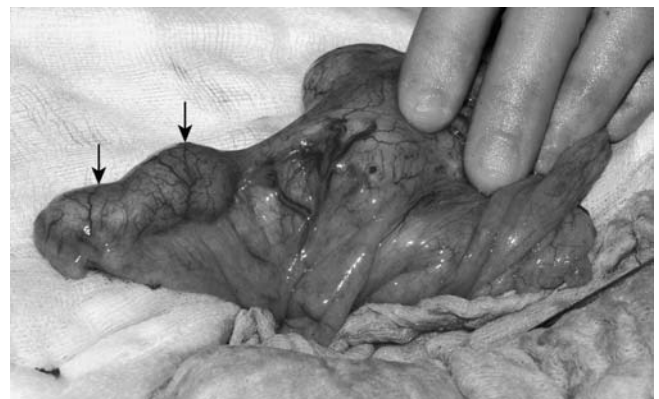## Epidemiology

Tumors of the appendix are rare accounting for 0.5% of GIT tumors. The principle tumor types are carcinoids, adenomas, adenocarcinomas, and rarer pathologies include GISTs, mesenchymal tumors, metastatic carcinomas of colorectal origin, and rarely melanomas. On analysis of appendicectomy specimens, removed largely for the presentation of appendicitis, <1% are found to have tumors and only one-tenth of these are primary malignant tumors<sup>25</sup>. Overall, 30–55% of tumors prove to be carcinoid, 15% adenomas, 10% primary adenocarcinomas and 15% secondary malignancy half of which were adenocarcinomas in patients with colorectal cancer. It is notable that in patients with appendiceal tumors of all histological types there is a high incidence of synchronous and

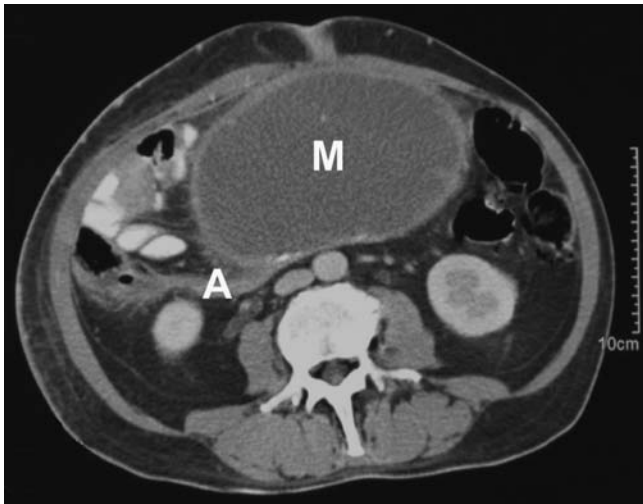
metachronous colorectal cancer: carcinoids 10%, adenomas 33%, secondary malignancy 55%<sup>26</sup>. Further support for an association between epithelial appendiceal tumors and colorectal cancer is provided from an observation of a 5% incidence of such tumors in appendices removed electively in patients undergoing rectal and colonic cancer surgery<sup>27</sup>.

## Clinical presentation, investigation and diagnosis

For most patients an appendiceal tumor is diagnosed following removal for presumed appendicitis. At operation the appendix may appear swollen and bulbous (Figure 15.3) but the majority of tumors are diagnosed coincidentally by the histopathologist. If extra-appendiceal mucus or other peritoneal disease is noted at operation this must be considered when planning further treatment (see section on Outcome below). Carcinoid tumors are generally indolent, rarely perforate or metastasize, although the risk of progression increases with increasing size above 2 cm and with adenocarcinoid cellular differentiation<sup>20</sup>. Appendiceal carcinoids are often diagnosed at an early age: 15–19 years in females and 20–29 years in males; and family history in first-degree relatives increases the risk threefold<sup>17</sup>. Rarely patients present with a full blown secretory carcinoid syndrome due to the systemic effects of 5-hydroxytryptamine (5HT): flushing, fever, diarrhea, bronchospasm, and cardiac dysfunction. Perforation of the appendix does occur with benign epithelial mucinous tumors and adenocarcinomas both of which tend to reseed having disseminated cells into the peritoneal cavity (Figure 15.4). Adenomatous lesions of the appendix tend to generate mucinous PMP which is relatively indolent, whilst peritoneal carcinomatosis will follow perforated adenocarcinoma and progress rapidly with signs of multifocal intestinal involvement.



**Figure 15.3** Macroscopic appearance of a distended swollen appendix containing tumor confined to the lumen.



**Figure 15.4** Appendix (A) with an extramural mucocoele (M) following perforation. Classical appearance of very early localized Pseudomyxoma peritonei.

### Carcinoid tumors

Patients with diagnosed carcinoids should be investigated for 5HT secretion using urinary 5HIAA analysis. CT scan of the thorax, abdomen and pelvis is required as synchronous primaries and metastatic disease needs to be determined. The majority of appendiceal carcinoids do not metastasize. Debate remains regarding long-term follow-up as there are recorded cases of presentation with metastatic liver disease >10 years following excision of the primary. Metastatic carcinoid may be diagnosed following identification of liver lesions on CT scan or occult lesions may be found using octreotide radionucleotide scanning. Recently more aggressive surgical excision and ablation has been adopted for control of systemic symptoms and the use of adjuvant chemotherapy and pharmacological manipulation with somatostatin helps palliate the disease<sup>20</sup>. Adenocarcinoid tumors run a more aggressive course in some cases progressing with peritoneal deposits requiring treatment similar to PMP<sup>28</sup>.

### Epithelial tumors and Pseudomyxoma peritonei

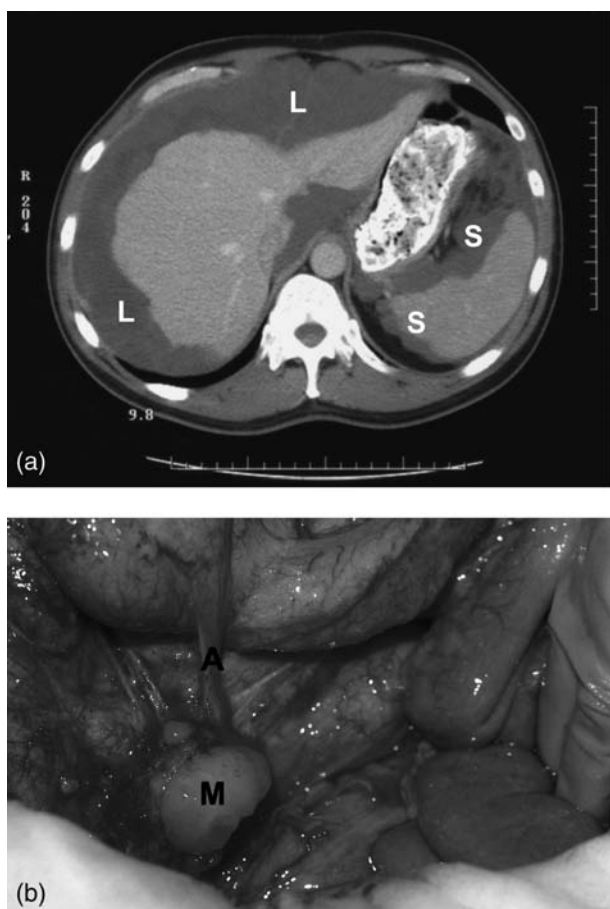
In 2000 the pioneering work of Professor Sugarbaker from Washington DC was explored in a conference at the Royal College of Surgeons, London. At that time few surgeons and oncologists understood the pathophysiology of PMP and many patients were erroneously treated: women commonly for ovarian cancer and men misdiagnosed as gastric cancer or unknown GIT primaries. Although it is true that some mucin-producing tumors will mimic a PMP picture and produce a PMP syndrome (characterized by abundant production of mucinous ascites, gross abdominal distension, loss of peripheral lean body mass

secondary to limited nutritional intake, and GIT compression), it is now accepted that true PMP develops secondary to an epithelial adenomatous tumor of the appendix<sup>29</sup>. The spectrum of disease ranges from abundant production of mucin with very scant epithelial cell proliferation (diffuse peritoneal adenomucinosis) through peritoneal mucinous carcinoma of intermediate/discordant type (PMCA I/D) to peritoneal mucinous carcinomatosis (PMCA). The unique feature of PMP is the ability to develop surface peritoneal implants without progressing to intra-organal or lymph node metastases. Recent evaluation of adhesion molecules in PMP and colorectal cancer has demonstrated a distinct profile that may explain the pattern of disease and offer potential for molecular targeting to prevent invasion<sup>30</sup>.

Many patients with PMP present to non-specialist centers and are misdiagnosed as having ovarian pathology<sup>31</sup>. Some are treated with repeated laparotomies, debulking of the tumor and/or removing mucin, while others receive systemic chemotherapy with minimal response. In men incidental presentation of peritoneal nodules or mucin in a hernial sac whilst undergoing hernia repair is often the case<sup>31,32</sup>. It is now recognized that repeat laparotomy is unlikely to achieve cure and the recommended treatment is an attempt at complete cytoreduction and administration of heated intraoperative intraperitoneal chemotherapy<sup>33</sup>. In the UK there are now two centers designated for the treatment of tumors of appendiceal origin: North Hampshire Hospital, Basingstoke and the Christie Hospital, Manchester. This approach is supported by the UK National Institute of Clinical Excellence (NICE) whose recommendations for PMP treatment in designated centers were published in 2004<sup>34</sup>. The concentration of patients to these treatment centers has allowed the teams to adopt techniques and gain experience in the radical approach of cytoreductive surgery and intraperitoneal chemotherapy. Although this approach is associated with significant morbidity, with experience this can be minimized and satisfactory outcomes achieved<sup>35</sup>.

Investigations include CT scanning that often demonstrates classical features of disease in the right and left upper quadrants, porta hepatus, omentum, right iliac fossa, and pouch of Douglas (Figure 15.5). Tumor markers (CEA and CA19.9) are helpful in determining disease activity, response to treatment and relapse during follow-up<sup>36</sup>.

Unfortunately some patients have severely advanced disease at presentation such that the more radical treatment cannot be offered. Palliative debulking has a place in these patients and a recent pilot study at the Christie Hospital, Manchester, UK using systemic mitomycin and oral capecitabine has achieved tumor response and clinical benefit in one-third of 40 patients treated to date (paper submitted for publication BJC 2007).



**Figure 15.5** (a) Computed tomography (CT) scan demonstrating classical appearance of advanced Pseudomyxoma peritonei: scalloping of liver (L) and involvement of spleen (S). (b) large appendiceal mucocele (M) and appendix (A).

## Outcome

The prognosis for patients diagnosed with tumors of the appendix is determined principally by the histological type but also by whether the disease is confined to the appendix. Benign carcinoid tumors are removed without

long-term sequelae and overall appendicular carcinoids have an 80–90% 5-year survival. For epithelial tumors the prognosis is dependent upon the ability to achieve complete cytoreduction which is influenced by the histological variant and the distribution of the disease<sup>37</sup>. Debate continues regarding the need for right hemicolectomy for tumors confined to the appendix but in the presence of peritoneal disease more extensive resection does not incur a survival advantage unless required for complete macroscopic cytoreduction<sup>38</sup>. The overall outlook for PMP patients is a 50–70% 5-year survival following cytoreduction and intraoperative chemotherapy<sup>39</sup>. The influence of histological type is also important as patients with intermediate/discordant features and PMCA do less well with 30% and 10% 3-year survival, respectively<sup>40</sup>. In all reported series the single most important factor that influences outcome is whether the surgeon can achieve complete macroscopic eradication of disease.

Advice regarding follow-up for patients with appendiceal tumors is difficult particularly when the tumor has been fully removed and confined to a non-perforated appendix. There are, however, reports of patients presenting with metastatic disease decades later hence a healthy respect must be shown for early reinvestigation of occult symptoms in patients with a history of tumors of the appendix.

## SUMMARY

Tumors of the small intestine and appendix are rare but can have devastating effects on individual patients as diagnosis is difficult and often delayed. The outcome for patients is influenced by their ability to access specialist teams that can offer multimodality treatment where appropriate. It is hoped that with increased knowledge and education about new treatment options patients will benefit from advances in both surgical and non-surgical treatments.

## REFERENCES

1. Cunningham JD, Aleali R, Aleali M et al. Malignant small bowel neoplasms: histological determinants of recurrence and survival. *Ann Surg* 1997; 225: 300–6.
2. Minardi AJ Jr, Zibari GB, Aultman DF et al. Small bowel tumours. *J Am Coll Surg* 1998; 186: 664–8.
3. Brucher BL, Roder JD, Fink U et al. Prognostic factors in resected primary small bowel tumours. *Dig Surg* 1998; 15: 42–51.
4. Rodriguez BMA, Vasen HF, Lynch HT et al. Characteristics of small bowel carcinoma in hereditary nonpolyposis colorectal carcinoma. *Cancer* 1998; 83: 240–4.
5. O'Boyle CJ, Kerin MJ, Feeley K et al. Primary small bowel tumours: increased incidence of lymphoma and improved survival. *Ann R Coll Surg Engl* 1998; 80: 332–4.
6. Bozdog AD, Nazli O, Tansug T et al. Primary tumours of the small bowel: diagnosis, treatment and prognostic factors. *Hepato-gastroenterology* 2003; 50S2: 117–18.
7. Torres M, Matta E, Chinae B et al. Malignant tumours of the small intestine. *J Clin Gastroenterol* 2003; 37: 372–80.
8. Rangiah DS, Cox M, Richardson M et al. Small bowel tumours: a 10 year experience in four Sydney teaching hospitals. *ANZ J Surg* 2004; 74: 788–92.

9. Mussi C, Caprotti R, Sciani A et al. Management of small bowel tumours: personal experience and new diagnostic tools. *Int Surg* 2005; 90: 209–14.
10. Catena F, Ansaloni L, Gazzotti F et al. Small bowel tumours in emergency surgery: specificity of clinical presentation. *ANZ J Surg* 2005; 75: 997–9.
11. Chow JS, Chen CC, Ahsan H et al. A population based study of the incidence of malignant small bowel tumours: SEER, 1973–1990. *Int J Epidemiol* 1996; 25: 722–8.
12. Toms JR. Cancer incidence survival and mortality in the UK and EU. *CancerStats Monograph*. London: Cancer Research UK, 2004.
13. Howdie PD, Jalal PK, Holmes GKT et al. Primary small bowel malignancy in the UK and its association with coeliac disease. *QJM* 2003; 96: 345–53.
14. Ryan JC. Premalignant conditions of the small intestine. *Semin Gastrointest Dis* 1996; 7: 88–93.
15. Rossini FP, Risio M, Pennazio M. Small bowel tumours and polypoid syndromes. *Gastrointest Endosc Clin North Am* 1999; 9: 93–114.
16. Hemminki K, Li X. Incidence trends and risk factors of carcinoid tumours: a nationwide epidemiologic study from Sweden. *Cancer* 2001; 92: 2204–10.
17. Paulson SR, Huprich JE, Fletcher JG et al. CT enterography as a diagnostic tool in evaluating small bowel disorders. *Radiographics* 2006; 26: 641–57.
18. Schwartz GD, Barkin JS. Small bowel tumours. *Gastrointest Endosc Clin North Am* 2006; 16: 267–75.
19. Ramage JK, Davies AHG, Ardill J et al. Guidelines for the management of gastroenteropancreatic neuroendocrine (including carcinoid) tumours. *Gut* 2005; 54: 1–16.
20. Adler DG, Merwat SN. Endoscopic approaches for palliation of luminal gastrointestinal obstruction. *Gastroenterol Clin North Am* 2006; 35: 65–82.
21. Chiang KC, Chen TW, Yeh CN et al. Advanced gastrointestinal stromal tumor patients with complete response after treatment with imatinib mesylate. *World J Gastroenterol* 2006; 12: 2060–4.
22. Sakakura C, Hagiwara A, Soga K et al. Long-term survival of a case with multiple liver metastases from duodenal gastrointestinal stromal tumor drastically reduced by the treatment with imatinib and hepatectomy. *World J Gastroenterol* 2006; 12: 2793–7.
23. Guidelines for the management of Gastrointestinal stromal tumours (GISTs). *Augis* 2005: [www.augis.org/news/articles/gist](http://www.augis.org/news/articles/gist).
24. Nowain A, Bhakta H, Pais S et al. Isolated hepatic metastasis from a gastrointestinal stromal tumor (GIST) 17 years after initial resection: need for long-term surveillance. *J Clin Gastroenterol* 2005; 39: 925.
25. Esmer-Sanchez DD, Martinez OJL, Roman ZP et al. Appendiceal tumours: Clinicopathologic review of 5,307 appendicectomies. *Cir Cir* 2004; 72: 375–8.
26. Connor SJ, Hanna GB, Frizelle FA. Appendiceal tumours: retrospective clinicopathologic analysis of appendiceal tumours from 7,970 appendicectomies. *Dis Colon Rectum* 1998; 41: 75–80.
27. Kjan J, Sexton R, Moran BJ. Five percent of patients undergoing surgery for left colon or rectal cancer have synchronous appendiceal neoplasia. *Colorectal Dis* 2006; 8S2: 20–1.
28. Lin-Bryan T, Gown AM. Mixed carcinoid and adenocarcinoma of the appendix: report of four cases with immunohistochemical studies and a review of the literature. *Appl Immunohistochem Mol Morphol* 2004; 12: 271–6.
29. Sych C, Staebler A, Connolly DC et al. Molecular genetic evidence supporting the clonality and appendiceal origin of Pseudomyxoma peritonei in women. *Am J Pathol* 1999; 154: 1849–55.
30. Bibi R, Pranesh N, O'Dwyer ST et al. A specific cadherin phenotype may characterise the disseminating yet non-metastatic behaviour of pseudomyxoma peritonei. *Br J Cancer* 2006; 95: 1258–64.
31. Esquivel J, Sugarbaker PH. Clinical presentation of the Pseudomyxoma peritonei syndrome. *Br J Surg* 2000; 87: 1414–8.
32. Esquivel J, Sugarbaker PH. Pseudomyxoma peritonei in a hernia sac: analysis of 20 patients in whom mucoid fluid was found during hernia repair. *Eur J Surg Oncol* 2001; 27: 54–8.
33. Sugarbaker PH. New standard of care for appendiceal epithelial neoplasms and pseudomyxoma peritonei syndrome? *Lancet Oncol* 2006; 7: 69–76.
34. Complete cytoreduction for pseudomyxoma peritonei (Sugarbaker technique) [www.nice.org.uk/IPG056](http://www.nice.org.uk/IPG056), 2004.
35. Moran BJ, Mukherjee A, Sexton R. Operability and early outcome in 100 consecutive laparotomies for peritoneal malignancy. *Br J Surg* 2006; 93: 100–4.
36. Carmifnani CP, Hampton R, Sugarbaker CE et al. Utility of CEA and CA 19.9 tumour markers in diagnosis and prognostic assessment of mucinous epithelial cancers of the appendix. *J Surg Oncol* 2004; 87: 162–6.
37. Ito H, Osteen RT, Bleday R et al. Appendiceal adenocarcinoma: long term outcomes after surgical therapy. *Dis Colon Rectum* 2004; 47: 474–80.
38. Gonzalez MS, Sugarbaker PH. Right hemicolectomy does not confer a survival advantage in patients with mucinous carcinoma of the appendix and peritoneal seeding. *Br J Surg* 2004; 91: 304–11.
39. Yan TD, Black D, Savady R et al. A systematic review on the efficacy of cytoreductive surgery and perioperative intraperitoneal chemotherapy for Pseudomyxoma Peritonei. *Ann Surg Oncol* 2006; 10: 1245–58.
40. Ronnett BM, Yan H, Karman RJ et al. Patients with pseudomyxoma peritonei associated with disseminated peritoneal adenomucinosis have a significantly more favourable prognosis than patients with peritoneal mucinous carcinomatosis. *Cancer* 2001; 92: 85–91.

## RELEVANT WEBSITES

[www.christie.nhs.uk/profinfo/departments/Pseudomyxoma](http://www.christie.nhs.uk/profinfo/departments/Pseudomyxoma)  
[www.surgicaloncology.com](http://www.surgicaloncology.com)  
[www.augis.org/news/articles/gist](http://www.augis.org/news/articles/gist)



# Cancer of the colon, rectum and anus

16

Nipun B Merchant, Alexander A Parikh, Carl R Schmidt and R Daniel Beauchamp

---

## CANCER OF THE COLON AND RECTUM

### Epidemiology and etiology

Worldwide, colorectal cancers (CRC) occur in approximately 8.1 million people and cause 5.2 million deaths each year. Nearly 150 000 new cases of colon and rectal cancer are diagnosed each year in the US, and it is the second leading cause of cancer death in this country<sup>1</sup>. These include approximately 106 000 colon cancers with the remainder being rectal cancers. Of sporadic CRC 90% occur in people after their fifth decade and it is uncommon before the age of 40. There has been an overall decrease in the incidence rates over the past 20 years which is attributed to increased screening and prevention with the more widespread use of colonoscopy. During this time, however, the incidence of right-sided colon cancers has been increasing in the US and Europe. The overall incidence is higher in patients who have an inherited predisposition to CRC. This occurs in fewer than 10% of patients with CRC and these cases are subdivided according to whether or not colonic polyps are a major disease manifestation.

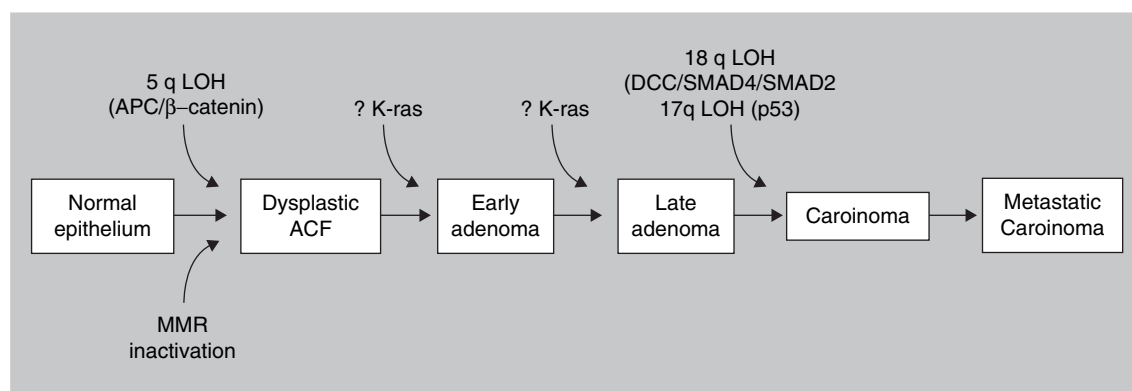
It is now understood that development of sporadic colon cancer is a multistep process of genetic mutations which drives the transformation from normal colonic epithelium to an invasive cancer. Pioneering work by Fearon and Vogelstein first identified the basic sequence of these events with mutations in the tumor suppressor adenomatous polyposis coli (APC) gene occurring early in the process, while others, such as mutations of the p53 suppressor gene, generally occur late in the process. Chromosomal instability and many other important genetic and epigenetic events play important roles in colon cancer pathogenesis, including alterations in  $\beta$ -catenin and the *wnt* signaling pathway, DNA mismatch repair genes, and transforming growth factor (TGF)- $\beta$ /SMAD pathways (adenoma-carcinoma sequence, see Figure 16.1).

Two inherited disorders are associated with the greatest risk of developing colon cancer: familial adenomatous polyposis (FAP) and hereditary non-polyposis colorectal cancer (HNPCC)<sup>3,4</sup>. FAP is characterized by the development of hundreds to thousands of colon and rectal polyps which generally develop during the second to third decade of life, have an early and high incidence of development of CRC, and account for less than 1% of all CRC. There are three variants of FAP:

- (1) Gardner's syndrome, which is associated with extraintestinal tumors including desmoid tumors, sebaceous or epidermoid cysts, lipomas, osteomas (especially of the mandible), and polyps of the proximal gastrointestinal tract (stomach and duodenum);
- (2) Turcot's syndrome is associated with brain tumors, primarily medulloblastomas;
- (3) Attenuated familial adenomatous polyposis, having fewer number of colonic polyps (generally <100) and a delayed onset of CRC formation than the other variants.

These disorders are autosomal dominant diseases caused by mutations in the APC gene, located on chromosome 5q21-q22.

HNPCC is more common than FAP, accounting for about 2–3% of all CRC and results from mutations in one of several DNA mismatch repair genes resulting in microsatellite instability (MSI)<sup>4</sup>. Traditionally, this disorder was classified as Lynch I and Lynch II syndromes. These patients developed early onset, predominantly right-sided colon cancers that tend to develop from flat, villous polyps rather than tubular adenomas compared with patients with sporadic CRC. Lynch II patients were additionally characterized by having a high risk of developing extracolonic tumors including endometrial, gastric, small bowel, ovarian, pancreatic, hepatobiliary, or renal cancers. However, as more families are studied and



**Figure 16.1** A genetic model for colorectal tumorigenesis. LOH, loss of heterozygosity; DCC, deleted in colon cancer gene; APC, adenomatous polyposis coli gene; ACC, aberrant crypt foci; MMR, DNA mismatch repair enzyme. Modified from reference 2.

the genetics of this disorder is better understood, patients are being categorized by genetic classification. Currently, several clinical criteria exist to diagnose patients with HNPCC and include the Amsterdam I and II criteria, and the Bethesda criteria<sup>5</sup>. Patients with MSI CRCs have been shown to be resistant to many cytotoxic drugs, including 5-fluorouracil (5-FU), but appear to have a better overall survival than microsatellite stable tumors.

Peutz-Jeghers syndrome (PJS) is an autosomal dominant disorder caused by mutations on chromosome 19p13.3 and involves a mutation on a gene encoding a novel serine threonine kinase (STK-11)<sup>6</sup>. PJS is characterized by multiple gastrointestinal hamartomatous polyps and melanocytic macules of the lips, buccal mucosa and terminal digits. The hamartomatous polyps occur primarily in the small intestine, but can also occur in the colon, and the stomach. Patients with PJS tend to develop recurrent bouts of small bowel intussusception, obstruction and bleeding, often requiring recurrent bowel resection. The risk of gastrointestinal cancer is thought to occur via adenomatous change within the hamartomas. PJS has also been associated with an increased risk of developing other cancers including gynecological, lung, breast, thyroid, basal cell, prostate, and pancreatic cancers.

The United States National Cancer Institute home website contains links with detailed and current information regarding the epidemiology, etiology, genetics, diagnosis, and treatment of CRC<sup>7</sup>.

### Early detection and screening

The rationale for screening for CRC stems from the fact that most CRCs progress through an adenoma-carcinoma sequence (Figure 16.1), a process that may take up to 10 years. This progression from small adenomatous polyps to large polyps which undergo dysplasia and

then develop cancer provides an opportunity to prevent cancer by removing polyps prior to the onset of cancer. The length of time of the progression from polyp to cancer also provides a time frame in which screening tests such as colonoscopy do not need to be repeated yearly, and less sensitive tests such as fecal occult blood, performed annually may identify lesions missed on earlier screening.

Colonoscopy has become the gold standard for detection of colon polyps and colorectal cancers. Increasing use of routine screening colonoscopy for detection and prevention of colon cancer has reduced the burden of this disease in recent years. Furthermore, it has been shown that the first screening colonoscopy and polypectomy produces the greatest effect on reducing the incidence of CRC in patients with adenomatous polyps<sup>8</sup>. Recommendations for screening for sporadic CRC are described in Table 16.1.

Recently, the US Multi-Society Task Force on Colorectal Cancer and the American Cancer Society have jointly published guidelines for colonoscopy surveillance after polypectomy<sup>3</sup>.

Screening in patients with familial or suspected familial syndromes is evolving. Genetic testing is available for patients and families suspected of having either FAP or HNPCC, and the specific type of gene mutation in either case may affect prognosis and guide treatment decisions.

The American Cancer Society website contains consensus recommendations for CRC screening and surveillance<sup>10</sup>.

### Diagnosis and staging

Diagnosis of colon and rectal cancer requires the combined effort of surgeons, gastroenterologists, radiologists

**Table 16.1** Screening recommendations for sporadic colorectal cancer (CRC)

<i>Risk category</i>	<i>Preferred screening</i>	<i>Alternative approaches</i>
Average (age >50, no history of adenoma, IBD, negative family history)	Colonoscopy at age 50 and repeated every 10 years if no polyps	FOBT every year and flexible sigmoidoscopy every 5 years or double contrast barium enema every 5 years
Inflammatory bowel disease	Begin 8–10 years after onset of symptoms with colonoscopy every 1–2 years with four quadrant biopsies every 10 cm with >30 total samples; strictures and masses also sampled extensively	NA
Positive family history (first-degree relative with CRC at any age or two related second-degree relatives with CRC any age)	Begin screening colonoscopy at age 40 or 10 years prior to earliest colorectal cancer in family	

IBD, inflammatory bowel disease; FOBT, fecal occult blood test.  
Adapted from reference 9.

and pathologists. Almost all colorectal cancers are adenocarcinomas that arise from the mucosa. Colonoscopy is the single best diagnostic test to localize lesions throughout the colon. Any mass suspicious for cancer within the colon or rectum should be biopsied for pathological confirmation. The entire colon and rectum must be evaluated to check for synchronous cancers or adenomatous polyps. This may be performed with colonoscopy or with air contrast barium enema supplemented with flexible sigmoidoscopy, although the diagnostic yield of this combination is less than that of colonoscopy.

Virtual colonoscopy is an emerging technology which is a non-invasive method of evaluating the entire colon. After complete bowel preparation, the colon is distended with air and a spiral computed tomography (CT) is used to obtain serial images. Computer software is used to postprocess the images and the entire colon can be navigated in either direction.

The clinical utility of virtual colonoscopy is still being determined. It remains an option in patients who may otherwise be unable to tolerate an invasive colonoscopy. Limitations of its widespread use include the local expertise in performing and interpreting the images, the lack of standardization of technique and the fact that a positive finding on virtual colonoscopy may still require an optical colonoscopy (gold standard) to obtain/confirm a diagnosis. Sensitivity of virtual colonoscopy, compared with optical colonoscopy, for detecting polyps >10 mm ranges from 55 to 90%, and for smaller polyps from 39 to 55%<sup>11</sup>.

### Clinical staging evaluation

Once the diagnosis of cancer is confirmed, preoperative staging is important to determine local extent of the

primary tumor and presence or absence of distant metastases and to discuss therapy and prognosis.

The TNM staging system of the American Joint Committee on Cancer (AJCC) is the preferred system for staging CRC. It classifies the extent of disease, estimates prognosis and measures therapeutic outcomes. The 6th edition of the AJCC staging system modified the previous edition for colon and rectal cancer staging by increasing the stratification of stage II and stage III colorectal cancers<sup>12</sup>. The overall staging system emphasizes depth of penetration into bowel wall (T stage), lymph node involvement (N stage) and presence or absence of distant metastases (M stage). Five-year survival rates decrease predictably with increasing overall stage (Tables 16.2 and 16.3). Interestingly, early stage III cancers have better 5-year survival when compared with later stage II cancers, and this may reflect the use of adjuvant therapy in stage III colon cancer. Survival statistics for colorectal cancer are similar for the US and the UK<sup>13</sup>.

Preoperative staging evaluation primarily involves physical examination including digital rectal examination (DRE), CT scan of the abdomen and pelvis, and chest X-ray.

Physical examination should focus on the presence of ascites, lymphadenopathy and hepatomegaly. For patients with rectal cancer, DRE is critical to determine the relationship of the tumor to the anorectal ring and to determine the degree of circumferential involvement of tumor within the rectum and fixation of the tumor within the pelvis. In experienced hands, DRE has an accuracy of up to 80% in determining T stage of the tumor. Although most rectal tumors are described as a distance from the anal verge, it is important to remember that the anal verge



**Table 16.2** AJCC TNM classification for colon and rectal cancer

Tis	Primary tumor confined to mucosa only
T1	Primary tumor invades submucosa
T2	Primary tumor invades muscularis propria
T3	Primary tumor invades through muscularis propria into subserosa or pericolic fat
T4	Primary tumor invades adjacent organs or primary tumor causes bowel perforation
N0	No regional lymph nodes involved
N1	Tumor identified 1–3 locoregional lymph nodes
N2	Tumor identified in greater than four locoregional lymph nodes
M0	No distant metastases
M1	Metastatic disease

**Table 16.3** AJCC stage grouping for colon and rectal cancer

	<i>T stage</i>	<i>N stage</i>	<i>M stage</i>	<i>Actuarial 5-year survival (%)</i>
I	T1–2	N0	M0	93.2
IIa	T3	N0	M0	84.7
IIb	T4	N0	M0	72.2
IIIa	T1–2	N1	M0	83.4
IIIb	T3–4	N1	M0	64.1
IIIc	T1–4	N2	M0	44.3
IV	T1–4	N0–2	M1	8.1

Adapted from reference 12.

is a variable landmark that may be up to 2 cm distal to the dentate line, at the transition of the squamous mucosa of the anus to the columnar mucosa of the rectum. Just cephalad to the dentate line is the anorectal ring comprised of the musculature of the internal and external anal sphincter (Figure 16.2). On DRE, determining the relationship of the tumor to the anorectal ring is more informative in determining the ability of performing a sphincter preserving procedure. Even if colonoscopy has been performed, patients with rectal cancer should have a rigid proctosigmoidoscopy performed by the operating surgeon to accurately assess the location and extent of the rectal tumor.

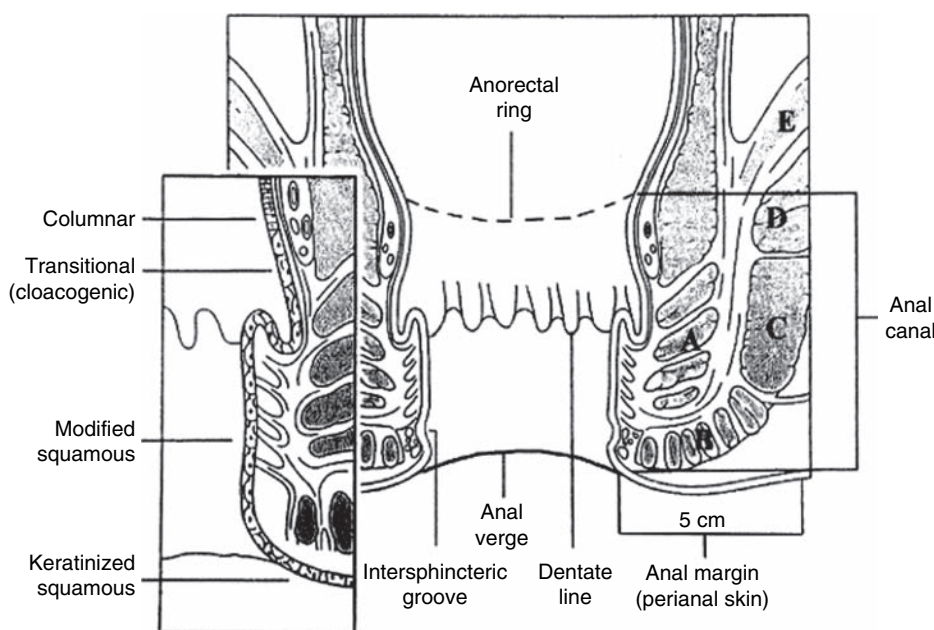
Routine laboratory studies including complete blood count, electrolytes, blood urea nitrogen (BUN), creatinine, and liver analyses are usually included in the preoperative work-up for colorectal cancer. Abnormalities in liver function tests suggest the possibility of metastatic disease and deserve further investigation; however, liver

enzymes may be normal in the setting of small liver metastases.

### *Computed tomography scan*

The need for preoperative CT scan remains a matter of debate for patients with colon cancer as it may not alter surgical management of the primary tumor especially in patients with symptomatic tumors (bleeding, obstruction). Its role in preoperative staging for patients with rectal cancer is better established. The advantages of preoperative CT scan of the abdomen and pelvis include the assessment of regional tumor extension and regional lymphatic and distant metastases<sup>15</sup>. The sensitivity of CT for detecting distant metastasis ranges from 75 to 87%, while its sensitivity for detecting nodal involvement or the depth of transmural invasion is only around 50%<sup>15</sup>.

The lung represents the next most likely site, after the liver, of metastatic disease. CT of the chest is more



**Figure 16.2** The anal canal is defined by the anorectal ring (proximal) and the anal verge (distal). The anal margin corresponds to a 5-cm area of perianal skin, measured from the anal verge. A, Internal sphincter; B, subcutaneous external sphincter; C, superficial external sphincter; D, deep external sphincter and puborectalis muscle; E, levator ani muscle. Insert depicts the epithelial differentiation of the anal region. Reproduced from reference 14, with permission.

sensitive than is chest X-ray in detecting metastatic lung lesions. However, the usefulness of chest CT in the evaluation of patients with CRC provides only a positive yield of 4% and a positive predictive value of 36% for the detection of malignant lesions of the lung. While CT of the chest is more sensitive than conventional chest X-ray in the detection of lung metastases, the low positive yield and low positive predictive value of chest CT in the setting of a negative chest X-ray limits the usefulness of chest CT in the routine staging assessment of CRC.

### Tumor markers

Several serum tumor markers have been associated with CRC; however, none have been shown to provide the ability to diagnose primary CRC and they are not recommended as a screening test for CRC<sup>16</sup>. Serum carcinoembryonic antigen (CEA) on the other hand has been shown to have prognostic value in patients with CRC. Patients with preoperative elevated CEA levels >5 ng/ml have a worse overall prognosis than patients with lower levels. In addition, elevated levels of CEA that do not return to baseline postoperatively suggest residual disease<sup>16</sup>. The American Society of Clinical Oncology (ASCO) clinical practice guidelines for the use of tumor markers in CRC recommend that serum CEA levels be measured preoperatively if it would change surgical management. It is recommended that CEA levels be monitored every

2–3 months for 2 years or more, if resection of liver metastasis would be clinically indicated. The data are insufficient to recommend the routine use of other tumor markers such as lipid-associated sialic acid (LASA), CA 19-9, DNA index, DNA flow cytometric proliferation analysis, *p53* tumor suppressor gene, and *ras* oncogene<sup>17</sup>.

### Positron emission tomography scan

Positron emission tomography (PET) scanning complements CT scans in the evaluation of patients considered to be candidates for resection of liver metastasis of CRC to localize extrahepatic disease and in the setting of rising serum CEA levels to localize sites of recurrence. It is generally not indicated for the preoperative staging of primary CRC.

### Endorectal ultrasound

Endorectal ultrasound (ERUS) is used for rectal cancers to determine depth of tumor invasion and presence of locoregional lymph node metastases, which are critical parameters in determining therapeutic intervention in these patients, and is the best available modality for preoperative T and N stage analysis of rectal cancer. The accuracy of ERUS in determining the depth of rectal wall invasion (T stage) ranges from 80 to 94% compared

with 65 to 75% for CT, and 75 to 85% for magnetic resonance imaging (MRI). The overall accuracy of ERUS is operator dependent and there is a tendency to overestimate the T stage in inexperienced hands. The accuracy of ERUS in assessing mesorectal lymph node metastasis (N stage) is diminished compared with its accuracy of T stage assessment, ranging from 65 to 75%; however, it still remains superior to that of CT (55–65%) and MRI (60–65%)<sup>18</sup>. Another advantage of ERUS is the ability to perform fine needle aspirations of suspected positive lymph nodes that may improve the accuracy of staging.

### Preoperative bowel preparation

Preoperative decontamination of colonic bacteria has been shown to decrease the risk of infectious complications after elective surgery of the colon or rectum. This is performed by various methods of mechanical bowel preparation including the use of a clear liquid diet for up to 3 days preoperatively in addition to laxatives, enemas, or cleansing of the gastrointestinal tract with a polyethylene glycol (PEG) electrolyte solution. These methods of bowel preparation have been shown to decrease the fecal content within the colon but do not decrease the bacterial content<sup>19</sup>. Therefore the use of oral antibiotics including neomycin, erythromycin base, or metronidazole have been advocated.

The routine use of mechanical bowel preparation and the methods of bowel preparation prior to elective colon or rectal resection have been recently questioned. A randomized trial from Platell *et al.* found that use of an oral bowel prep with 3 liters of polyethylene glycol was associated with fewer anastomotic leaks than use of a single preoperative phosphate enema (4.1 vs. 0%,  $p=0.013$ )<sup>20</sup>. Interestingly, another randomized study comparing mechanical bowel preparation with 3 liters of polyethylene glycol versus no preparation in elective left-sided colon resection found an increased rate of morbidity and longer hospital stay in the group receiving preoperative mechanical bowel preparation<sup>21</sup>.

Many surgeons have abandoned the use of preoperative oral antibiotics prior to elective colorectal resection due to the lack of data supporting its benefit in terms of decreased infectious complications as well as patient intolerance.

### Surgical resection

Complete surgical extirpation of primary colon and rectal cancer is the only chance for long-term cure and all other therapy is either adjunctive or palliative. The best operative approach and resection for each patient

depends on several factors including age, body habitus, co-morbidities, extent of tumor burden, and availability and feasibility of laparoscopic colectomy.

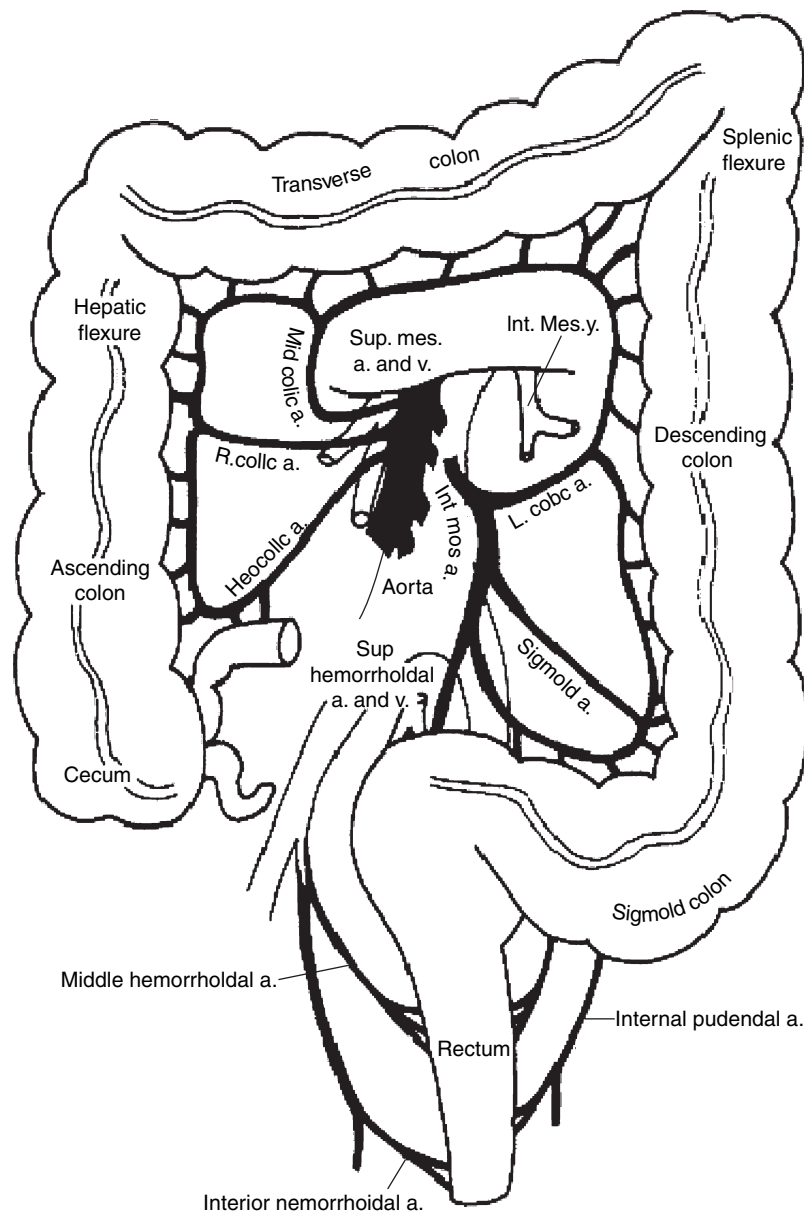
### Colon cancer

An adequate resection of a colon primary tumor requires removal of the involved segment of large intestine with the mesentery and associated vascular supply back to their origin from the superior mesenteric artery or inferior mesenteric artery to completely excise the associated lymphatics which run alongside the vascular arcade (Figures 16.3 and 16.4). Any nearby organs or structures involved by tumor should be resected en bloc with the primary tumor.

At least 12 lymph nodes should be removed and pathologically evaluated in order to accurately determine N stage of colon and rectal tumors to provide adequate therapeutic and prognostic value to determine the role of adjuvant therapy (see Table 16.4)<sup>23</sup>. In the US, however, less than 40% of patients receive adequate lymph node evaluation<sup>24</sup>. Sentinel lymph node evaluation in CRC has not been shown to be accurate for predicting the presence of conventional or micrometastatic disease and should not replace standard regional lymphadenectomy<sup>25</sup>.

Management of the patient with a colon or rectal polyp that has been removed during colonoscopy is an interesting and controversial topic. Non-invasive lesions can be managed with endoscopic resection as long as the margins of resection are negative. Patients with cancer confined to polyp may be managed with endoscopic resection if the area of invasive cancer is in the head of a pedunculated polyp and the stalk and polypectomy margins are not involved. Any evidence of adverse pathological features such as lymphovascular or perineural invasion, or poorly differentiated histology portend a worse prognosis and should be managed by surgical resection. In addition, if there is evidence of cancer at the resection or stalk margin, invasive cancer in a sessile polyp or invasive cancer in a polypectomy specimen removed in a piece-meal fashion in which margin status cannot be determined should be considered for colectomy. The patient's overall medical condition and ability to undergo a major operation should also be considered.

Laparoscopic resection of colon cancer has emerged as an alternative approach to conventional open surgery. Early reports of laparoscopic resection suggested significant benefits over open resection including earlier return to bowel function, reduced post-operative pain and shorter length of hospital stay. A significant concern with the early experience of laparoscopic colon resection was the incidence of port site recurrences at both the site of tumor extraction and at sites not involved in



**Figure 16.3** Sup, superior; Inf, inferior; a, artery; v, vein; mes, mesenteric; Mid, middle.

specimen removal<sup>26</sup>. However, ongoing experience indicates a declining incidence of port-site recurrence over time. Concern that this approach would compromise survival by failing to achieve a proper oncological resection or adequate staging or by altering patterns of recurrence (based on frequent reports of tumor recurrences within surgical wounds) has prompted controlled trials. In the US, the intergroup Clinical Outcomes of Surgical Therapy (COST) trial randomized 827 patients with colon cancer to open or laparoscopic resection by credentialed surgeons<sup>27</sup>. This study showed that there was no significant difference between groups in the 3-year time to recurrence or overall survival (OS) for patients with any stage of cancer. Perioperative recovery was faster in the

laparoscopic-surgery group than in the open-colectomy group, as reflected by a shorter median hospital stay (5 days vs. 6 days,  $p < 0.001$ ) and briefer use of parenteral narcotics (3 days vs. 4 days,  $p < 0.001$ ) and oral analgesics (1 day vs. 2 days,  $p = 0.02$ ). The rates of morbidity or 30-day mortality were similar between both groups. There was, however, a 21% conversion rate to open surgery in the laparoscopic group, even with experienced surgeons. In addition, the overall operative time was significantly higher in the laparoscopy group resulting in higher overall costs for the procedure. Other studies have also suggested equivalence or slight advantage to the laparoscopic approach in terms of postoperative morbidity and quality of life<sup>28</sup>.

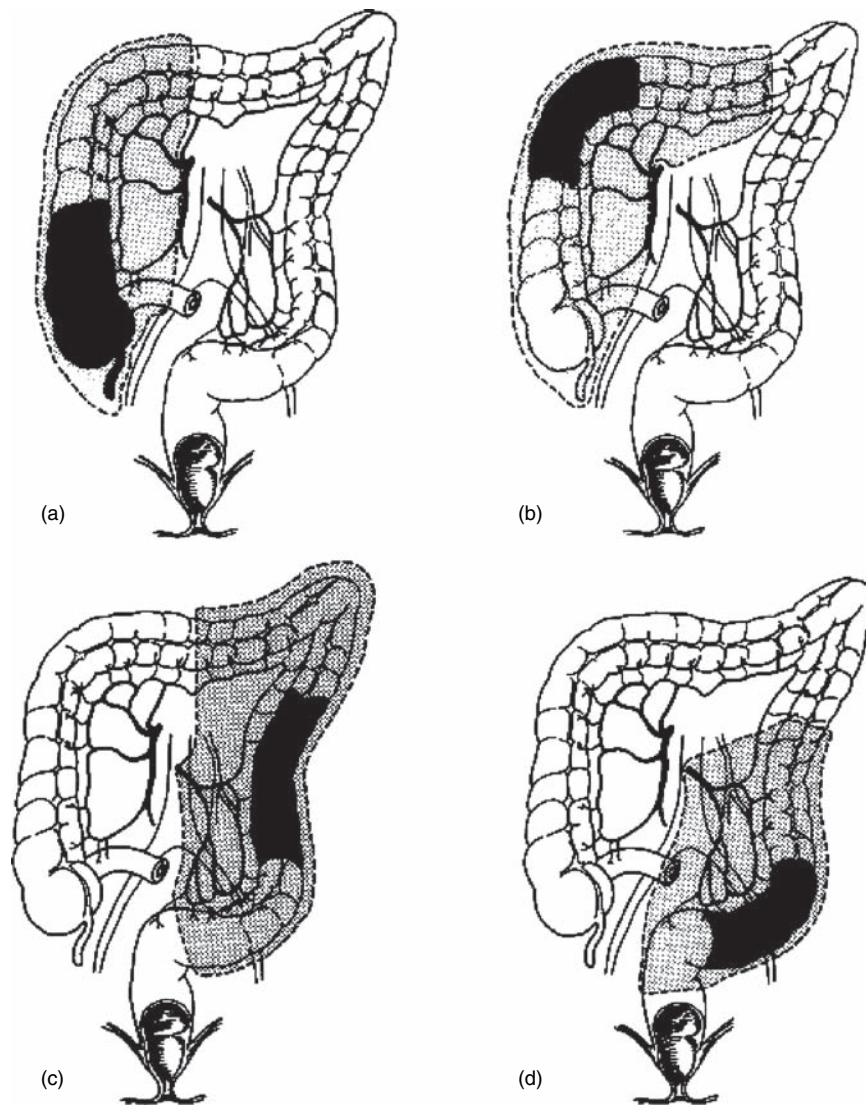


Figure 16.4

### Rectal cancer

The goals of surgery for rectal cancer include:

- Cure – which involves complete en bloc resection of the primary cancer and prevention of systemic spread
- Local control – to avoid pelvic recurrence
- Sphincter preservation – restoration of continuity and preservation of anorectal function
- Preservation of sexual and urinary function – preserving the integrity of pelvic autonomic nervous system.

The curative surgical options for rectal cancer include local excision, sphincter-preserving abdominal surgery or low anterior resection (LAR), and abdominal perineal resection (APR). Selection of the appropriate surgical option involves multiple factors including: the depth of

tumor invasion into the rectal wall (T stage); the presence or absence of regional lymph node metastases (N stage); the size of the tumor; degree of circumferential involvement of the tumor; tumor location in relation to the anorectal ring; and patient's body habitus (see Table 16.4).

### Margins of resection

Rectal cancers can spread proximally or distally through intra- and extramural lymphatic and vascular channels. Several studies have evaluated the optimal distal margin of resection in rectal cancer<sup>29,30</sup>. Analyses of these studies suggest that rectal tumors generally do not spread distally within the rectal wall beyond 2 cm unless they have adverse pathological features such as poor histological differentiation.

**Table 16.4** Surgical guidelines for resection of colon and rectal cancer

<i>Tumor location</i>	<i>Recommendations</i>
Colon	<p>Lymphadenectomy should extend to the level of the origin of the primary feeding vessel; suspected positive lymph nodes outside the standard resection should be removed when feasible. At least 12 lymph nodes should be excised and evaluated</p> <p>Bowel margins – 5 cm proximally and distally should be used</p>
Rectum	<p>The ideal bowel margin is 2 cm distally and 5 cm proximally, measured fresh with the use of full thickness. The minimally acceptable distal margin for sphincter preservation is 1 cm</p> <p>Lymphovascular resection of the rectum should include a wide anatomic resection of the mesorectum, including the mesorectal fascia propria and at least 4 cm of clearance distal to the tumor and proximal ligation of the primary feeding vessel</p> <p>Extended lateral lymphatic dissection cannot be supported on current evidence</p> <p>Length of bowel cannot be supported as an important surgical variable</p>
Colon and rectum	<p>En bloc resection should be performed for tumors adherent to local structures</p> <p>Inadvertent bowel perforation increases the risk of recurrence and should be avoided</p> <p>Thorough abdominal exploration for metastatic and locally advanced primary and lymph node disease should be performed</p> <p>The no-touch technique is debated with little evidence to support it</p> <p>Bowel washout may have theoretical benefits in rectal cancer, but such benefits have not been proven</p> <p>Ovaries grossly involved with tumor should be removed; prophylactic oophorectomy cannot be supported</p>

Adapted from reference 22.

Traditionally, APR was performed in the majority of patients with rectal cancer due to the dogma suggesting a 5 cm margin was required for adequate extirpation of the rectal tumor and the surrounding lymph nodes. Reappraisal of this 'rule' through larger and randomized trials has shown no improvement in local control or survival with margins of resection >5 cm versus <5 cm<sup>30</sup>, or with margins ranging from <2 cm to >3 cm<sup>31</sup>. Therefore, a 2 cm distal margin of resection is acceptable particularly when sphincter preservation is an issue.

In addition to the adequate distal margins of resection, the adequacy of the circumferential (radial) margin of resection has also been shown to be an independent factor in determining the outcome of patients with rectal cancer. Extensive pathological analysis of resected rectal cancer specimens has shown that while the primary tumor rarely extends transmurally beyond 2 cm, tumor deposits within the mesorectum can spread up to 3–4 cm distal to the primary tumor<sup>32</sup>. A positive radial margin correlates strongly with local recurrence and is attributed to inadequate surgical resection or inadequate assessment by the pathologist in many circumstances. Conventional surgery with blunt pelvic dissection violates the mesorectal circumference during blunt dissection, leaving residual mesorectum in the pelvis and yields positive radial margins in 20–33% of

patients even with negative proximal and distal margins of resection. Of these patients 80–85% have been shown to develop local recurrence within 2 years<sup>33</sup>. Concerns about achieving negative radial and circumferential margins are addressed by the concept of total mesorectal excision (TME) (see below).

### *Abdominal perineal resection*

APR has been considered the gold standard of surgical resection in patients with distal rectal cancer. This procedure involves a combined abdominal and perineal approach to removing the rectum and anus, and results in a permanent colostomy (see Total mesorectal excision section below for details of the procedure). However, there has been a decrease in the frequency of APRs being performed which correlates with a trend in increasing amounts of sphincter-saving procedures (SSP) being performed. Oncological outcomes are similar following LAR and APR<sup>30,34</sup>. Procedure-related morbidity has been shown to be equivalent<sup>34</sup> or worse for APR compared with LAR. While reports have suggested that quality of life (QOL) is significantly worse in patients undergoing APR due to the change in their body image<sup>30</sup>, poor postoperative sphincter function after LAR can also result in an inferior QOL compared with APR,

especially after low rectal anastomoses are performed (below 5 cm)<sup>35</sup>.

### *Sphincter-sparing procedures*

Sphincter-sparing surgical approaches include local excision and LAR with or without a coloanal anastomosis. The selection of the approach depends on factors such as tumor histology, size, location, mobility, anatomic constraints, and the technical expertise of the surgeon.

#### *Local excision*

Selection issues for local excision of rectal tumors are based on both clinical and pathological evaluation of the tumor. All patients should be evaluated by ERUS as this provides the best determination of T and N stage of the tumor. DRE is also critical in assessing the ability to perform a local excision. It provides information about location of the tumor in relation to the anorectal ring and also the size and mobility of the tumor in the rectum. Pathological evaluation of the tumor is also important in the evaluation process. The major limitation of performing a local excision is the lack of complete pathological staging. The incidence of positive lymph node involvement increases with increased depth of tumor penetration (T stage: T1 0–12%, T2 20–28%, T3 50–67%) as well as with increase in adverse pathological features (tumor grade: well 0%, moderate 30%, poor 50%, vascular invasion (–) 30%, vascular invasion (+) 37%, lymphatic invasion (–) 32%, lymphatic invasion (+) 50%)<sup>36</sup>. See Table 16.4 for selection criteria for local excision of rectal cancer.

Rectal tumors fitting the selection criteria may undergo local excision by three different approaches: transanal excision, through the anus; Kraske procedure, through a posterior parasacral approach; and York-Mason procedure, through a trans-sphincteric posterior approach. The transanal approach is most commonly used. The goal of all three types of procedures is to perform a complete full-thickness excision of the tumor down to the perirectal fat using electrocautery without fragmenting the tumor. A minimum lateral margin of 1 cm and a negative deep margin should be attained. Primary closure of the resulting defect is usually performed. Once the tumor is removed, it should be pinned to a piece of Styrofoam and oriented for the pathologist to assess the inked margins, histological differentiation, vascular or lymphatic invasion, and depth of penetration. If the margins are found to be positive for tumor or adverse pathological features are identified, then additional resection or consideration for a radical resection is necessary.

Transanal endoscopic microsurgery (TEM) is a minimally invasive endoscopic technique of transanal excision. The rectum is insufflated with CO<sub>2</sub> and dissection is performed through four ports. This procedure allows for excision of larger tumors and tumors up to 18–20 cm from the dentate line<sup>37</sup>. Limitations of this procedure, however, are the need for expensive equipment and the significant learning curve for the procedure.

#### *Low anterior resection*

Several advances have led to the increased rate of sphincter preservation in the management of rectal cancer. There is increasing interest in the use of preoperative radiation therapy with the goal of sphincter preservation in the treatment of resectable rectal cancer. The goal of preoperative radiation therapy is to decrease the volume of the primary tumor. When the tumor is located in close proximity to the dentate line, this decrease in tumor volume may allow the surgeon to perform a sphincter-preserving procedure that would otherwise not be possible. Advances in circular stapling devices have also enabled surgeons to perform anastomoses for middle and low rectal tumors that otherwise may have resulted in APRs (see Total mesorectal excision section below for details of the procedure).

Absolute contraindications to performing a LAR are involvement of the sphincter complex with the tumor and pelvic fixation of the tumor due to spread to adjacent organs. A relative contraindication to perform an LAR is if the tumor is located <2 cm from the upper part of the anorectal ring.

Enhanced surgical techniques such as the coloanal anastomosis allow for preservation of the sphincter mechanism in patients with very low-lying rectal cancer in whom the distal margin is at the minimally acceptable level, yet adequate for cancer clearance. This operation is reserved for patients who have a distal rectal cancer that does not invade the sphincter musculature, and in whom a standard extended LAR is technically not possible.

To perform a coloanal anastomosis, using the technique of Parks<sup>38</sup>, the rectal mucosa is stripped from the dentate line to just above the levator ani muscles. At the level of the anorectal ring, the muscular rectal wall is divided by cautery and the specimen removed. The proximal colon is brought into the anal canal and a direct hand-sewn anastomosis is performed to the dentate line (including some internal sphincter muscle) with interrupted 2-0 polyglycolic acid sutures.

Local recurrence and survival are not compromised in patients with distal-third rectal cancer when treated by sphincter-saving resection, provided that oncological



principles are not violated and coloanal anastomosis can be performed with an acceptable morbidity. Oncological outcomes of LAR with coloanal anastomosis are similar to those of APR<sup>39</sup>.

Due to the low anastomosis, however, functional results after coloanal reconstruction are often compromised. In study by Paty *et al.*, evaluating long-term sphincter function in 81 patients after coloanal anastomosis, fecal continence was complete in 51%, incontinence to gas only in 21%, minor leak in 23%, and significant leak in 5%. Complete evacuation of the neorectum was problematic in 32%. Overall function was excellent in 28%, good in 28%, fair in 32%, and poor in 12%<sup>40</sup>. However, the functional results continue to improve over the course of the first 5 postoperative years.

### Total mesorectal excision

In the past two decades, there has been a significant evolution in the management of rectal cancer. Except for the small subset of patients with very early tumors, most patients have disease beyond the rectal wall, either by direct extension or lymphatic spread. Conventional surgical technique for rectal cancer has often used blunt pelvic dissection and results in local recurrence rates of 15–65%, with survival rates of 35–56% for transmural and/or node-positive disease<sup>41,42</sup>. These results prompted the addition of adjuvant or neoadjuvant pelvic irradiation with or without chemotherapy to reduce local recurrence rates and improve survival rates.

The initial experience of Heald *et al.* suggested that meticulous pelvic dissection minimized local failure rates<sup>43</sup>. Using this approach of sharp perimesorectal dissection and expanding the concept to total mesorectal excision (TME), both Heald *et al.*<sup>44</sup> and Enker *et al.*<sup>45</sup> have reported low local recurrence rates with or without the use of adjuvant radiation therapy.

The operation is performed in the Trendelenburg lithotomy position, with the patient in Lloyd-Davies stirrups. The entire left colon to the level of the middle colic artery is mobilized, with ligation of the inferior mesenteric artery and vein. The distal left colon is divided with a linear stapler at a level to ensure adequate length to reach to the pelvic floor. TME involves sharp dissection under direct vision in the areolar plane lateral (peripheral) to the visceral fascia that envelops the rectum and mesorectum. Posteriorly, the plane of dissection is along the parietal fascia overlying the presacral vessels.

Laterally, this plane continues between the mesorectum and the parietal fascia overlying the piriformis and levator muscles. The so-called lateral ligaments, or the junction between the mesorectum and the pelvic plexus, is dissected sharply, preserving the autonomic nerve

trunks. The anterior dissection in men is performed with scissors and cautery, usually anterior to Denonvillier's fascia, except for small, posterior tumors, for which the dissection is posterior to Denonvillier's fascia. In women, the posterior vagina is dissected under direct vision. The rectosacral (Waldeyer's) fascia is sharply incised posteriorly to mobilize the entire rectum to the level of the anorectal ring. When possible and when appropriate based on the cancer size and penetration, the sympathetic and parasympathetic pelvic autonomic nerve trunks are preserved medial to the parietal fascia. For middle to low rectal cancers, the entire rectal mesentery, including that distal to the tumor, is removed as an intact unit, producing the characteristic smooth, bilobed appearance of the mesorectum covered by intact visceral fascia. For high rectal cancers (above the peritoneal reflection), sharp perimesorectal dissection allows mobilization to the pelvic floor, after which the mesorectum is divided at right angles to the bowel, 5–6 cm distal to the tumor (Figures 16.5 and 16.6). Anastomoses are performed using an intraluminal circular stapling device or are hand-sewn (primarily for coloanal reconstruction).

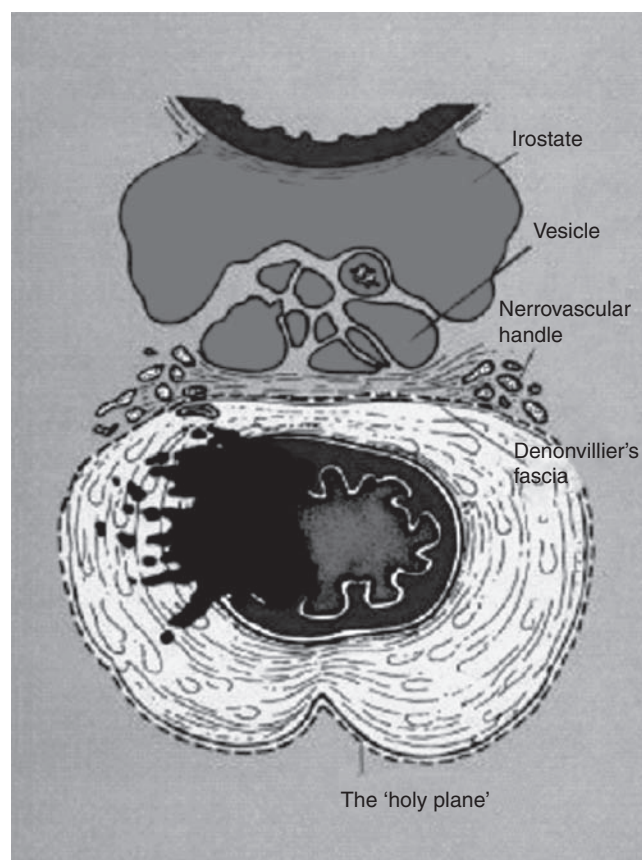
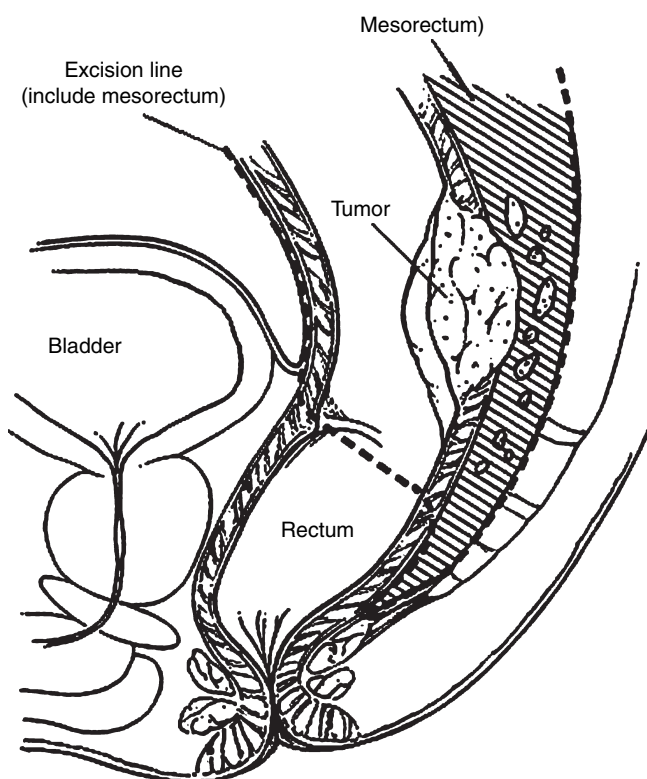


Figure 16.5





**Figure 16.6** Mesorectal excision. Excision line for mesorectal excision of a rectal adenocarcinoma. Reproduced from reference 46, with permission.

The advent of TME in the surgical management of rectal tumors has now consistently shown local recurrence rates below 10% and 5- and 10-year survival rates of 68–78% without the use of any additional therapy<sup>44,47</sup>. While these data call into question the need for any additional therapy when TME is properly employed, the addition of neoadjuvant radiation therapy with TME has been shown to improve local control but not survival<sup>48</sup>. In light of the significant response rates to neoadjuvant therapy, surgeons have advocated limiting the aggressiveness of further therapy in patients with a ‘significant’ response to transanal excision alone in selected patients<sup>49</sup>.

Several areas of controversy in surgical resection of CRC have been studied in recent years. These controversies and differences in surgical technique for colectomy are described in the ‘Guidelines 2000 for colon and rectal surgery’<sup>22</sup>. Some of these findings are summarized in Table 16.4.

### Palliation for unresectable disease

Some patients may present with locally advanced or metastatic disease that is not amenable to surgical resection. These patients may, however, have signs and symptoms of bowel obstruction or hemorrhage from their tumors. The goal of surgery in this setting is towards relief of symptoms rather than for cure.

### Palliation of obstruction

Most colonic obstructions occur with tumors in the distal colon. Palliative surgery in these patients involves the creation of a diverting colostomy for diversion of the fecal stream and also creation of a mucous fistula of the distal colon to allow for decompression of secretions and prevention of a closed loop obstruction.

Obstruction resulting from tumors in the proximal colon occurs less frequently. Palliative surgery in this setting usually involves a bypass procedure with a side-to-side anastomosis from a proximal loop of colon or small bowel to a segment of colon distal to the obstruction. This allows for internal decompression of the obstructed bowel and avoids a colostomy. In patients with proximal colonic obstruction, it is important to evaluate the distal colon with a barium enema or colonoscopy prior to surgical intervention to ensure that there are no synchronous lesions in the distal colon which may affect the placement of the bypass anastomosis.

Expandable metal stents may be placed under fluoroscopic or endoscopic guidance for relief of colonic obstructions in patients who are poor surgical candidates<sup>50</sup>. These stents have been shown to provide acute relief of obstruction within 24 hours in the majority of patients. Placement of the stents, however, may result in complication rates of up to 30%<sup>50</sup>. Expandable metal stents should not be placed in patients who have a life expectancy of more than 4–6 months due to the risk of erosion of the stent through the bowel wall.

### Palliation of bleeding

Bleeding colonic tumors are much more difficult to manage. At times, diversion or bypass may control the bleeding by diverting the fecal stream; however many times a palliative resection of the primary tumor may have to be performed. Bleeding tumors in the rectum may be treated with external beam radiation therapy which is often effective in helping to control bleeding.

### Adjuvant and neoadjuvant therapy

#### Colon cancer

Even after successful surgical resection, many patients with colon cancer remain at high risk of locoregional and distant recurrence. These recurrences are thought to occur secondary to clinically occult micrometastases that were present at the time of surgical resection. The goal of adjuvant systemic therapy, therefore, is to eradicate micrometastatic disease and to improve survival after

curative resection. The first evidence of a potential survival advantage of adjuvant therapy in colon cancer was a meta-analysis of 25 randomized trials and nearly 10 000 patients published in 1988<sup>51</sup>. In this analysis, a small, but significant, survival benefit was noted in patients who had received systemic 5-fluorouracil (5-FU) after surgical resection when compared with those who did not (OR 0.83, 95% CI 0.70–0.98)<sup>51</sup>. Also in 1988, results from the large randomized National Surgical Adjuvant Breast and Bowel Project (NSABP) C-01 trial showed a significant survival benefit of adjuvant 5-FU/semustine/vincristine (MOF) over surgery alone<sup>52</sup>. Subsequent studies using the combination of 5-FU and levamisole (LEV) showed a statistically significant benefit for the adjuvant use of this regimen when compared with surgery alone in reducing recurrence rate and increasing survival in stage III (node-positive) colorectal cancers. These trials formed the basis of the National Institutes of Health (NIH) consensus recommendation of adjuvant 5-FU/LEV for patients with stage III colon cancer after resection.

Additional studies in the early 1990s also suggested a benefit of using 5-FU and leucovorin (LV), a reduced folate, in the adjuvant treatment of colon cancer. When 5-FU/LV was compared with 5-FU/LEV or MOF, overall survival was either equivalent or improved<sup>53,54</sup>. This led to the acceptance of adjuvant 5-FU/LV for 6–8 months as the standard treatment for surgically resected stage III colon cancer. Subsequent studies have demonstrated infusional 5-FU/LV regimens to be as effective as, but safer than bolus 5-FU/LV<sup>55</sup>. In addition, capecitabine, an oral fluoropyrimidine derivative, has also been shown to be as effective as 5-FU/LV regimens in the adjuvant treatment of stage III colon cancer<sup>56</sup>.

More recently, newer agents such as oxaliplatin and irinotecan, which are approved for the treatment of metastatic colon cancer, have also been studied in the adjuvant setting. In the international MOSAIC randomized trial, oxaliplatin was added to 5-FU/LV (FOLFOX) and compared with infusional 5-FU/LV in patients with stage II and stage III colon cancer<sup>57</sup>. After a median follow-up of over 3 years, disease-free survival (DFS) was superior in the FOLFOX group (78% vs. 73%, HR 0.77,  $p = 0.002$ ). Overall survival (OS), however, was not statistically different (88% vs. 87%). In a subgroup analysis, the improvement in DFS was noted to be significant for stage III disease only (72% vs. 65%, HR 0.76, 95% CI 0.62–0.92) but not in stage II disease (87% vs. 84%, HR 0.80, 95% CI 0.56–1.15)<sup>57</sup>. Similarly, in the randomized NSABP C-07 trial, the addition of oxaliplatin to bolus 5-FU/LV also led to a significantly improved DFS (77% vs. 72%, HR 0.79), albeit with more toxicity than infusional regimens<sup>58</sup>. Based upon these early results,

oxaliplatin was approved in combination with infusional 5-FU/LV for the adjuvant treatment of stage III colon cancer and is currently considered an acceptable alternative to 5FU/LV or capecitabine for resected stage III patients<sup>59</sup>. In contrast, irinotecan-containing regimens have not been shown to provide survival benefit in the adjuvant setting<sup>60</sup>.

*Stage II colon cancer* In contrast to the significant benefit of adjuvant systemic chemotherapy for patients with stage III colon cancer, its role in the treatment of resected stage II (node negative) colon cancer remains controversial. Many trials that have shown a benefit for adjuvant chemotherapy consisted of patients with both stage II and stage III disease, and have failed to show a significant survival advantage for stage II patients<sup>53,57,61,62</sup>. When subgroup analyses were performed, most trials have been underpowered to detect small differences in outcome in stage II colon cancer, however, almost all have shown a trend toward improved DFS and OS<sup>53,57,61–63</sup>. Similarly, several meta-analyses have suggested only a trend toward a benefit for adjuvant chemotherapy in stage II disease<sup>64</sup>. Based on these equivocal results, current ASCO and National Comprehensive Cancer Network (NCCN) clinical guidelines do not recommend the routine use of adjuvant chemotherapy for patients with resected stage II colon cancer. In healthy patients considered at high risk for recurrence, such as those with inadequate lymph node sampling (<12 nodes), T4 lesions, perforation, or poorly differentiated histology, adjuvant therapy is a reasonable option<sup>65</sup>.

An area of ongoing investigation is the impact of molecular factors on the prognosis and response of colon cancers to adjuvant therapy. For example, some preliminary studies have suggested that tumors with high levels of microsatellite instability (MSI-H) actually have an improved survival and that adjuvant chemotherapy may not be beneficial in these patients<sup>66–68</sup>. Other studies have suggested that the loss of heterozygosity (LOH) at the 18q chromosome region leads to stage II patients having a similar prognosis as stage III patients, and therefore may represent more aggressive disease<sup>68,69</sup>. Interestingly, the combination of microsatellite-stable (MSS) colon cancer and the loss of an 18q allele is associated with up to a 2.75-fold higher risk of dying when compared with patients with a retained 18q allele<sup>70</sup>. Although the significance of these findings is still unclear, an ongoing clinical trial (ECOG E5202) is currently stratifying stage II patients according to MSI and 18q status. Patients with MSS or MSI-low and 18q LOH are considered high-risk for recurrence and are randomized to adjuvant 5-FU/LV/oxaliplatin with or without the antiangiogenic agent bevacizumab. Patients with

retention of 18q alleles or MSI-H are considered low-risk and will be observed. Accrual is ongoing and results may better help us better decide which patients with stage II disease may benefit from adjuvant chemotherapy.

*Adjuvant chemoradiotherapy in colon cancer* Although the role of adjuvant chemoradiotherapy is well established in the adjuvant treatment of rectal cancer (see below), its role in the treatment of patients with resected colon cancer is less clear. Selected patients who may be at a high risk for local recurrence including those with positive resection margins, T4 disease, or perforated cancers may benefit from the addition of adjuvant chemoradiotherapy in addition to systemic chemotherapy. The only randomized trial that attempted to study the role of adjuvant radiotherapy was closed prior to the planned recruitment due to poor accrual, but did not show any benefit for the addition of adjuvant radiation to systemic 5-FU/LEV<sup>70</sup>.

### Rectal cancer

Surgical therapy remains the only curative option for rectal cancer but only results in a high rate of cure in patients with early stage disease. Following curative resection, approximately 50% of patients will experience either local or distant recurrence, depending on the stage of their disease<sup>71,72</sup>. In contrast to colon cancer which generally recurs with distal metastases, rectal cancer tends to recur both distally and locally with equal frequency. The goal of adjuvant therapy for rectal cancer is therefore directed at both reducing local recurrence in the pelvis as well as distant disease.

*Adjuvant radiotherapy alone* Several randomized trials have reported significantly improved local recurrence rates using adjuvant radiotherapy for resected stage II and stage III patients. A significant survival advantage, however, has not been demonstrated. In a large meta-analysis of over 8000 patients, adjuvant radiotherapy reduced local recurrence rates from 28 to 17% when compared with surgery alone, but no difference in survival was present<sup>73</sup>.

*Adjuvant chemoradiotherapy* In contrast to adjuvant radiotherapy alone, the use of 5-FU-based chemoradiotherapy and maintenance systemic 5-FU chemotherapy after resection of stage II and stage III rectal cancers has been shown to improve both local control and overall survival in randomized trials<sup>42,74</sup>. This led to the 1990 National Cancer Institute (NCI)/NIH consensus conference recommendation of the use of postoperative 5-FU-based chemotherapy and chemoradiotherapy

(45–50.4 Gy) for the treatment of stage II and stage III resected rectal cancer<sup>75</sup>. It must be mentioned that along with these advantages, control of bowel function is worse after adjuvant chemoradiation therapy and resection as compared with surgical resection alone<sup>76</sup>.

Subsequent studies have focused on optimizing various 5-FU-based regimens and in general, infusional 5-FU chemoradiotherapy has been shown to be the most effective and least toxic regimen. The optimal timing of chemotherapy and radiotherapy is still unclear. Most trials have utilized a sandwich approach consisting of one to two cycles of chemotherapy followed by chemoradiotherapy, followed by additional chemotherapy, rather than chemoradiotherapy first followed by systemic chemotherapy, although neither strategy has been proven to be superior.

*Neoadjuvant therapy* The benefits of postoperative combined chemotherapy and radiation led to increasing use of preoperative (neoadjuvant) combined chemotherapy and radiation for rectal cancer. The benefits of neoadjuvant therapy for rectal cancer are several and include tumor downstaging with increased rates of respectability and sphincter preservation, and decreased toxicity when compared with postoperative therapy.

*Neoadjuvant radiotherapy versus surgery alone* Several trials have compared different neoadjuvant or preoperative radiotherapy strategies followed by surgical resection compared with resection alone. When evaluating these trials, however, it is important to note that the most common schema for preoperative combined chemoradiation therapy for rectal cancers differs markedly between the US and many European countries. In the US, preoperative therapy generally includes 5-FU-based chemotherapy with concomitant radiotherapy (4500–5040 cGy), followed by surgery 4–8 weeks later. In many European countries, however, preoperative treatment for rectal cancer involves high-fraction, short-course radiotherapy (25 Gy over 5 days) followed by surgery within 1 week. The relative benefits of each have not been compared, although a small randomized trial did report a higher pathological complete response rate and margin positivity rate for those receiving conventional fraction (50.4 Gy) chemoradiotherapy in patients with T3–4 rectal cancers<sup>77</sup>. The rate of sphincter preservation was similar, but the local failure and survival rates were not reported.

The results of several randomized trials comparing preoperative radiotherapy with surgery alone are shown in Table 16.5. For patients receiving moderate and high preoperative doses of radiotherapy, there does appear to be a significant decrease in the local failure rate.

**Table 16.5** Preoperative radiotherapy versus surgery alone for rectal cancer

Study	n	Dose/days	5-year local recurrence			5-year overall survival		
			XRT	Surg	p Value	XRT	Surg	p Value
MRC, 1984 <sup>79</sup>	823	20 Gy/10	—	—	—	40%	38%	>0.9
EORTC, 1988 <sup>80</sup>	466	34.5 Gy/15	15%	30%	0.003	69%	59%	0.08
Swedish trial, 1997 <sup>78</sup>	1168	25 Gy/5	11%	27%	<0.001	58%	48%	0.004
Kapiteijn, 2001 <sup>48</sup>	1861	25 Gy/5	2.4%	8.2%	<0.001	82%	82%	0.8

\*2-year local recurrence OS.

XRT, radiotherapy; Surg; surgery alone; MRC; EORTC, European Organization for Research and Treatment of Cancer.

In addition, the Swedish rectal cancer trial, which consisted of preoperative short-course radiotherapy (25 Gy in 5 days) versus surgery alone in patients with resectable rectal cancer, reported a significant decrease in local recurrence (11% vs. 27%,  $p < 0.001$ ) as well as a significant increase in OS and DFS (58% vs. 48%,  $p = 0.004$ , 74% vs. 65%,  $p = 0.002$ , respectively) for the group receiving preoperative radiotherapy<sup>78</sup>. In a second trial from The Netherlands of over 1800 patients randomized to total mesorectal excision (TME) alone or high-dose preoperative radiotherapy followed by resection with TME, preoperative radiotherapy resulted in a significantly lower rate of local failure at 2 years (2.4% vs. 8.2%,  $p < 0.001$ ) but overall survival was similar (82% vs. 81.8%,  $p = 0.84$ )<sup>48</sup>. When stratified by stage, a significant benefit in local control was seen in stage II and III patients only. Although perioperative complication rates were similar in both groups, the preoperative radiotherapy group had a significantly higher rate of postoperative complications (48% vs. 41%,  $p = 0.008$ ) and in patients undergoing APR, a higher perineal wound complication rate (29% vs. 18%,  $p = 0.008$ ). In addition, patients undergoing preoperative radiotherapy had a higher rate of sexual dysfunction, slower recovery of bowel function, fecal incontinence (62% vs. 38%,  $p < 0.001$ ), anal blood loss (11% vs. 3%,  $p = 0.004$ ), and overall rate of dissatisfaction with bowel function<sup>81</sup>.

Data from meta-analyses are also somewhat conflicting. Neoadjuvant radiotherapy was associated with a significantly lower rate of local recurrence, DFS and OS in one<sup>82</sup>, while only associated with a significant decrease in overall and local recurrence but with similar OS in the second<sup>73</sup>. Taken together, it appears that the use of neoadjuvant radiotherapy improves local control in patients with resectable rectal cancers, although the impact on survival is less clear.

**Neoadjuvant chemoradiotherapy** In randomized studies comparing the use of preoperative 5-FU-based

chemoradiotherapy with radiotherapy alone, combined chemoradiation has been associated with higher pathological response rates and lower local failure rates as compared with preoperative radiotherapy alone but overall survival has not been significantly different<sup>83</sup>. Encouraging results have also been seen with the use of capecitabine as a radiosensitizing agent, although a direct comparison against infusional 5-FU in the neoadjuvant setting is ongoing.

**Neoadjuvant versus adjuvant chemoradiotherapy** Since benefits have been reported with the use of chemoradiotherapy in both the neoadjuvant and adjuvant settings, there has been some debate as to which approach may be better in regards to patient tolerance and toxicity, local control and survival. The recently published German Rectal Cancer Study randomized T3/T4 or node positive rectal cancers to either preoperative or postoperative standard course chemoradiotherapy (50.4 Gy in 28 fractions with concomitant 5-FU)<sup>39</sup>. All patients underwent TME. With a 4-year median follow-up, preoperative chemoradiotherapy was associated with a significantly higher rate of sphincter preservation (39% vs. 19%,  $p = 0.004$ ), less grade 3/4 toxicity (27% vs. 40%,  $p = 0.001$ ), and a lower incidence of local relapse (6% vs. 13%,  $p = 0.006$ ). Overall 5-year survival, was not different between treatment groups (76% vs. 74%,  $p = 0.80$ )<sup>39</sup>. In a similar trial performed in the US, the NSABP R-03 attempted to randomize patients to preoperative 5-FU/LV chemotherapy followed by 5-FU/LV/radiotherapy followed by surgery and postoperative 5-FU/LV versus surgery followed by the similar chemoradiotherapy and systemic chemotherapy. The trial was closed early due to poor accrual. Given the results of the completed German trial, it appears that preoperative chemoradiotherapy may offer some significant advantages over postoperative therapy including downstaging, increased sphincter preservation and better local control, although overall survival is probably not different.

**Adjuvant chemotherapy** Although the use of adjuvant chemotherapy is well established in stage III and perhaps high-risk stage II colon cancers as discussed earlier, the role of postoperative systemic chemotherapy in rectal cancer patients undergoing preoperative radiotherapy or chemoradiotherapy is less clear. In the recently published EORTC trial, patients were randomized to preoperative radiotherapy, preoperative 5-FU/LV chemoradiotherapy, preoperative radiotherapy and postoperative 5-FU/LV chemotherapy or preoperative 5-FU/LV chemoradiotherapy and postoperative 5-FU/LV chemotherapy<sup>83</sup>. Similar to prior studies, preoperative chemoradiotherapy led to a more reduced tumor size and less advanced stage when compared with preoperative radiotherapy. There was no significant difference in overall 5-year survival or progression-free survival in the groups receiving postoperative chemotherapy compared with those who did not (67.2% vs. 63.2%,  $p=0.12$  and 58.2% vs. 52.2%,  $p=0.13$ , respectively)<sup>83</sup>. When looking at local recurrences, 17.1% recurred in the preoperative radiotherapy alone group, which was significantly higher than all three other groups (7.6–9.6%). There were no significant differences in local recurrences between the other three groups however<sup>83</sup>. This study suggested that adding systemic 5-FU either preoperatively or postoperative does not alter survival, but does confer a significant advantage in local control.

**Rectal cancer summary** From the above discussion, it is evident that several options exist for the neoadjuvant and adjuvant treatment of rectal cancer and which one is chosen depends on several factors. The current NCCN guidelines therefore provide the following recommendations. For stage I rectal cancer, surgical resection is adequate and there is no role for the routine use of neoadjuvant or adjuvant therapy. For stage II and III rectal cancer, either neoadjuvant fluoropyrimidine-based chemoradiotherapy followed by resection and adjuvant systemic 5-FU/LV  $\pm$  oxaliplatin or upfront surgical resection followed by fluoropyrimidine-based chemoradiotherapy followed adjuvant systemic 5-FU/LV  $\pm$  oxaliplatin is recommended<sup>59</sup>.

Algorithms for treatment of colon, rectal and anal carcinoma may be found at the National Comprehensive Cancer Network website<sup>84</sup>.

#### *Surveillance after potentially curative treatment of colorectal cancers*

The American Society of Clinical Oncology (ASCO) consensus recommendations for surveillance after treatment of primary CRC include history and physical

examination every 3–6 months for the first 3 years after treatment with carcinoembryonic antigen every 3 months postoperatively for at least 3 years after diagnosis, if the patient is a candidate for surgery or systemic therapy for a recurrence. The follow-up is recommended for every 6 months during years 4 and 5. Our practice is to follow patients annually after 5 years. ASCO recommends annual CT of the chest and abdomen for 3 years after primary therapy for patients who are at higher risk of recurrence and a pelvic CT scan should be included for rectal cancer surveillance. This is especially true for patients with poor prognostic factors. ASCO recommends colonoscopy at 3 years after operative treatment, and, if results are normal, every 5 years thereafter. Our practice is to obtain a colonoscopy at 1 year after surgical resection in case the initial colonoscopic evaluation missed a lesion. A proctosigmoidoscopy should be undertaken every 6 months for 5 years for rectal cancer patients who have not received pelvic irradiation. Chest X-rays, complete blood counts and liver function tests are not recommended by ASCO, and molecular or cellular markers should not influence the surveillance strategy based on available evidence. The ASCO recommendations may be reviewed in detail at the ASCO home website<sup>85</sup>.

## CARCINOMA OF THE ANUS

Carcinoma of the anus is a rare disease, accounting for approximately 1.5% of all gastrointestinal cancers in the US. In 2005, there were an estimated 3990 cases of anal cancer and 620 deaths<sup>86</sup>. Approximately 90% of patients will present with locoregional disease and less than 20% will develop distant metastases. The therapy for anal cancer has undergone a dramatic evolution over the past 25–30 years. Traditionally, radical resection consisting of an APR was considered the standard of care for this disease. Over the past two decades, however, combined-modality therapy (CMT) with systemic chemotherapy and radiotherapy, particularly for squamous cell carcinoma (SCC), has demonstrated survival rates equivalent to radical surgery while preserving sphincter function. Surgery is generally currently reserved for residual disease, recurrent disease, or treatment complications. This review focuses on the etiology, presentation, diagnosis, work-up, and management of anal cancers with particular attention to SCC, the most common histological type.

### Epidemiology and etiology

Cancers of the anal region account for 1–2% of all large bowel cancers in the US with an annual incidence of

about 0.7–0.9 per 100 000<sup>87,88</sup>. Anal cancers can develop within the anal canal or in the anal margin (perianal skin). They usually occur between the ages of 35 and 90, but most commonly in the sixth or seventh decade<sup>87,88</sup>. There has been a steady rise in the incidence of anal cancer in the US particularly among homosexual males, particularly under 45 years of age<sup>88</sup>. The annual incidence in homosexual males is approximately 35 per 100 000 and rises to 70 per 100 000 among the HIV-positive population<sup>86,87</sup>.

The exact mechanisms by which anal cancer develops are still unclear; however, certain risk factors and associations have helped identify those populations at risk. Epidemiological and molecular studies have now implicated the presence of sexually transmitted infection with human papilloma virus (HPV) as a causal factor in the development of anal cancer<sup>87,88</sup>. Similar to cervical intraepithelial neoplasia, HPV has been shown to cause anal intraepithelial neoplasia which can subsequently progress from low- to high-grade dysplasia, and ultimately to invasive cancer. In addition, altered immune status, such as in HIV patients or transplant patients, can facilitate the establishment of chronic HPV infection and subsequent anal cancer<sup>87,88</sup>. HPV serotypes 16 and 18, two of the serotypes implicated in the pathogenesis of cervical cancer, have also been shown to be frequently associated with invasive SCC of the anus<sup>87,89</sup>. With the recent approval of the HPV vaccine (Gardasil®) for prevention of cervical dysplasia and perineal warts, studies are ongoing to test the possible efficacy of the vaccine in the prevention of HPV and subsequent anal cancer in men<sup>87,89</sup>. Other significant risk factors include other sexually transmitted diseases including HIV, herpes, syphilis, gonorrhea, and *Chlamydia* sp., and chronic immunosuppression<sup>88,90</sup>. Smoking has been reported to increase the risk up to 5-fold<sup>86,88</sup>, and an association between Crohn's disease and anal cancer has also been reported<sup>86</sup>. Benign anal lesions, such as anal fissures, fistulae and abscesses, have often been associated with anal cancers but have not been shown to be causal<sup>87</sup>.

## Anatomy

A thorough understanding of anal canal anatomy is essential for accurate diagnosis and treatment of anal cancer and there has been considerable controversy about the anatomic borders defining the anal canal and rectum as well as the anal canal and anal margin. In general, the anal margin is defined as the skin within 5 cm of the anal verge (see Figure 16.2). The anal canal extends from the anorectal ring (upper portion of the puborectalis/levator complex) to the anal verge and is usually 3.5–4 cm

in length<sup>88</sup>. The distal 2–2.5 cm of the anal canal is lined by stratified squamous epithelium and the upper end of this region is demarcated by the dentate line. Above the dentate line, there is a 6–12 mm segment termed the anal transition zone which is lined with basal, columnar, cuboidal, transitional, and squamous epithelium. The upper portion of the anal canal is lined with columnar epithelium similar to that of the rectum<sup>88</sup>.

## Pathology

Approximately 80% of anal cancers are SCC with adenocarcinomas making up 15%<sup>91,92</sup>. Similar to SCC of the cervix, anal SCC may be preceded by the development of anal intraepithelial neoplasia or premalignant dysplasia. Anal canal cancers usually exhibit aggressive local growth and if left untreated, will extend to the rectal mucosa/submucosa as well as perianal tissue, perineum, ischiorectal fat, and even the pelvic peritoneum. Traditionally, mesenteric metastases have been present in 30–50% of surgical specimens. Over 50% of patients will present with locally advanced disease. The most common sites of distant metastases include the liver, lung and abdominal cavity, although most cancer-related deaths are due to uncontrolled pelvic or peritoneal disease<sup>91,92</sup>.

Anal margin cancers, in contrast, rarely metastasize to mesenteric nodes and the rate of local recurrence is higher than the rate of distant metastases, which are rare. The most common metastases are the superficial inguinal nodes, occurring in approximately 15%<sup>91–94</sup>.

## Diagnosis and staging

The most common presenting symptoms of anal cancer include bleeding, pain, fullness, and change in bowel habits<sup>88</sup>. Unfortunately, these are often similar to those caused by common benign anal diseases. Furthermore, benign anal conditions are often concomitantly present and can obscure the diagnosis<sup>88</sup>. A detailed and complete history including previous anal pathology and sexual practices is important. A meticulous physical examination should focus on identifying the size, location of the lesion and its relationship to surrounding structures as well as characterizing the sphincter tone. Examination should also include anoscopy with biopsy as well as evaluation of inguinal nodal basins.

Once the diagnosis is made, the patient must be accurately staged to determine the extent of disease. The current AJCC staging system for anal canal and anal margin cancers is shown in Tables 16.6–16.9<sup>12</sup>. The extent of local invasion should be assessed with EUS or endorectal MRI while systemic staging can be performed

**Table 16.6** AJCC TNM classification for anal canal cancer*Primary tumor*

T0	No evidence of primary tumor
Tis	Carcinoma <i>in situ</i>
T1	Tumor ≤ 2 cm in greatest dimension
T2	Tumor 2–5 cm in greatest dimension
T3	Tumor >5 cm in greatest dimension
T4	Tumor of any size with invasion of adjacent organ(s)

*Lymph nodes*

N0	No regional lymph node metastases
N1	Metastases to perirectal lymph nodes
N2	Metastases to unilateral internal iliac and/or inguinal lymph nodes
N3	Metastases to perirectal and inguinal lymph nodes and/or bilateral internal iliac and/or inguinal nodes

*Distant metastases*

M0	No distant metastases
M1	Distant metastases

Adapted from reference 12.

**Table 16.7** Stage grouping for anal canal cancer

	<i>r</i>	<i>N</i>	<i>M</i>
0	Tis	N0	M0
I	T1	N0	M0
II	T2-3	N0	M0
IIIA	T1-3	N1	M0
	T4	N0	M0
IIIB	T4	N1	M0
	Any T	N2	M0
	Any T	N3	M0
IV	Any T	Any N	M1

Adapted from reference 12.

with CT or MRI<sup>87,88</sup>. Functional imaging modalities such as PET scanning can also have a role in the investigation of indeterminate lesions or in the assessment of residual or recurrent disease. Clinically suspicious inguinal nodes

**Table 16.8** AJCC TNM classification for anal margin cancer*Primary tumor*

T0	No evidence of primary tumor
Tis	Carcinoma <i>in situ</i>
T1	Tumor ≤ 2 cm in greatest dimension
T2	Tumor 2–5 cm in greatest dimension
T3	Tumor >5 cm in greatest dimension
T4	Tumor invades deep extradermal structures

*Lymph nodes*

N0	No regional lymph node metastases
N1	Regional lymph node metastases

*Distant metastasis*

M0	No distant metastasis
M1	Distant metastasis

Adapted from reference 12.

can be present in 10–20% of patients during initial presentation rising to 30–60% in tumors larger than 5 cm<sup>88</sup>. Suspicious nodes should be biopsied by fine needle aspiration or excisional biopsy.

**Table 16.9** Stage grouping for anal margin cancer

	<i>r</i>	<i>N</i>	<i>M</i>
0	Tis	N0	M0
I	T1	N0	M0
II	T2–3	N0	M0
III	T4	N0	M0
	Any T	N1	M0
IV	Any T	Any N	M1

Adapted from reference 12.

## Treatment

### *Anal margin cancer*

Regardless of the histological type – SCC of the anal margin, as well as basal cell carcinoma, verrucous carcinoma, Bowen's disease, or Paget's disease – the preferred treatment remains wide local excision (WLE) with at least 1 cm margins – similar to SCC elsewhere on the skin<sup>95,96</sup>. This is usually the treatment of choice for small (<5 cm), superficial (T1,T2) SCC of the anal margin that do not invade the sphincter complex. The 5-year survival rate for these lesions is greater than 80%. For larger or more invasive SCC including those with positive lymph nodes, multimodality therapy consisting of systemic chemotherapy and radiation is usually utilized either as primary therapy or in a neoadjuvant setting<sup>96</sup>. For patients with T3–4, N0 lesions, prophylactic radiation is usually given to the inguinal regions with higher doses for patients with positive nodal disease<sup>96</sup>. APR is generally reserved for treatment failures and salvage therapy. Five-year disease-specific survival ranges from 70 to 90% and sphincter preservation is possible in 65–84%<sup>96</sup>.

### *Anal canal cancer*

Until the 1980s, surgical resection was the recommended treatment for SCC of the anal canal. Local excision was reserved for the small number of patients with well-differentiated tumors smaller than 2 cm, for those confined to the mucosa and submucosa, and for patients with incidentally discovered lesions after anal procedures. Unfortunately, this constituted less than 10% of the cases and the more radical APR was the recommended treatment for all other anal canal SCCs<sup>88</sup>. Despite this aggressive surgical approach, local recurrence occurred in

up to 40% of patients and overall 5-year survival was 40–70%<sup>87,88,96</sup>.

The pioneering work of Nigro *et al.* introduced the use of CMT – radiation therapy with 5-FU and mitomycin C (MMC) as primary treatment for SCC of the anal canal<sup>97</sup>. Subsequently, multiple studies confirmed the effectiveness of 5-FU/MMC/radiotherapy CMT in providing complete regression in 80–100% of patients and 5-year survival rates as high as 94%<sup>98</sup>. Three subsequent randomized trials then established CMT using this regimen as the standard treatment of choice for SCC of the anal canal<sup>99,100</sup>. In the UK and EORTC trials, the combination was found to be superior to the same schedule of radiation alone, resulting in improved rates of primary tumor control and colostomy-free survival<sup>99,101</sup>. In the third trial, conducted in North America by the RTOG and ECOG, it was shown that the combination of 5-FU and MMC with radiotherapy was more effective than radiotherapy plus 5-FU alone, with significant improvements in colostomy survival and disease-free survival<sup>100</sup>.

In an attempt to reduce the toxicity associated with the use of MMC, as well as to add dual radiosensitizers, regimens containing 5-FU/cisplatin and radiotherapy were used and showed response rates comparable or even slightly better than MMC-containing regimens with a better overall side-effect profile<sup>102</sup>. An NCI-Intergroup phase III trial comparing induction cisplatin-based chemotherapy followed by cisplatin/5-FU/radiotherapy to upfront MMC/5-FU/radiotherapy has recently been completed. In this randomized study, there was no statistically significant difference in DFS, OS, time to local failure, or overall toxicity, but there was a significantly lower incidence rate of colostomies needed in the MMC group. Male gender, higher T-stage and positive nodes were also found independent predictors of poorer survival, regardless of the therapy<sup>103</sup>. This study suggested, therefore, that MMC should remain the standard of care in CMT of anal cancer<sup>103</sup>. The role of surgery has therefore shifted to salvage therapy after the failure of CMT or perhaps for very small lesions, as discussed earlier, with a low incidence of nodal metastases.

*Inguinal nodal disease* Metastatic spread to inguinal nodes occurs in 15–60% of patients with anal canal cancers during the course of their disease and is related to tumor size and location<sup>88</sup>. Pelvic radiation fields should therefore probably include the inguinal nodal basin whether metastatic disease is present or not, as was performed in both the UK and RTOG/ECOG trials discussed above<sup>100,101</sup>. For synchronous nodal disease, radiotherapy to the nodal basins as part of CMT provides initial disease control rates of up to 90%<sup>88</sup>. For patients who have persistent nodal disease, lymph node dissection



can be performed. In patients with metachronous or recurrent inguinal disease, lymph node dissection can lead to 5-year survival rates of over 50%<sup>88,104</sup>. In addition, if the nodal region has not reached its treatment tolerance, additional radiation therapy can be given. Unfortunately, inguinal node dissections in a radiated field are commonly associated with wound complications and consideration of a well-vascularized musculocutaneous flap should be considered.

*Treatment of persistent or recurrent disease* In evaluating patients after CMT, it is important to note that there may be a delayed effect of radiation for several months after treatment<sup>86,88</sup>. Patients therefore require close follow-up during this period and although routine biopsies are not necessary, if there are lesions that persist or progress, biopsy should be obtained to rule out persistent disease. Of patients treated with CMT, 10–15% will have persistent disease and an additional 10–30% will develop a recurrence<sup>88</sup>.

For these patients, additional CMT can be considered if tissue tolerance has not been reached. For those who cannot receive additional CMT and those who do not respond, radical salvage surgery remains the only choice and usually involves APR with wide perineal margins. This procedure, however, is associated with significant morbidity and problems with healing of the perineum occur in up to two-thirds of patients most likely secondary to the heavily radiotherapy treated area<sup>87,88</sup>. Reconstruction with well-vascularized musculocutaneous flaps should therefore be strongly considered, similar to the case in inguinal node dissections discussed above. Prior to attempting surgical salvage, a thorough diagnostic work-up including appropriate imaging is required to ascertain the feasibility of obtaining negative margins and to rule out distant disease. Overall 5-year survival after salvage APR ranges from 25 to 50% in multiple series<sup>105–107</sup> with positive margins, tumors >5 cm, age >55, adjacent organ

involvement, residual disease after salvage and node positive disease all being associated with poorer survival. Similar survival has been noted for patients having received salvage chemoradiation<sup>108</sup>. The most common pattern of failure after salvage therapy is local recurrence.

*Treatment of distant metastatic disease* Approximately 10–25% of patients with carcinoma of the anus will have or develop systemic metastases, the incidence correlating with the size and stage of their primary tumor. The most common sites of spread include the liver and the lung and treatment is palliative. Salvage chemotherapy regimens are often cisplatin-based and offer some response but overall prognosis is poor with median survival in the 9–12 month range<sup>109</sup>. Newer agents are being studied and consideration of enrollment in clinical trials should also be considered. Radiation therapy may also be used for palliative treatment of symptomatic metastases.

## CONCLUSIONS

Cancer of the anus including anal canal cancer and anal margin cancer remains an uncommon disease, although it is becoming much more prevalent in susceptible populations. Although the precise pathogenesis is still unclear, HPV infection does appear to play a causal role and recent development of the HPV vaccine may hold promise in the prevention of anal cancer in affected individuals. Anal margin cancers are usually treated similarly to other squamous cell cancers of the skin with WLE. In contrast, CMT with systemic chemotherapy and radiation has become the standard of care for the treatment of anal canal cancer and provides excellent long-term survival while preserving sphincter control. Surgical therapy nevertheless plays an important role in the diagnosis, and follow-up as well as for treatment of residual or recurrent disease.

## REFERENCES

1. Jemal A, Murray T, Ward E et al. Cancer statistics, 2005. *CA Cancer J Clin* 2005; 55: 10–30.
2. Lynch JP, Hoops TC. The genetic pathogenesis of colorectal cancer. *Hematol Oncol Clin North Am* 2002; 16: 775.
3. Winawer SJ, Zauber AG, Fletcher RH et al. Guidelines for colonoscopy surveillance after polypectomy: a consensus update by the US Multi-Society Task Force on Colorectal Cancer and the American Cancer Society. *Gastroenterology* 2006; 130: 1872–85.
4. Lynch HT, Smyrk TC, Watson P et al. Genetics, natural history, tumor spectrum, and pathology of hereditary nonpolyposis colorectal cancer: an updated review. *Gastroenterology* 1993; 104: 1535–49.
5. Raedle J, Trojan J, Brieger A et al. Bethesda guidelines: relation to microsatellite instability and MLH1 promoter methylation in patients with colorectal cancer. *Ann Intern Med* 2001; 135: 566–76.
6. Jenne DE, Reimann H, Nezu J et al. Peutz-Jeghers syndrome is caused by mutations in a novel serine threonine kinase. *Nat Genet* 1998; 18: 38–43.
7. [www.cancer.gov/](http://www.cancer.gov/)

8. Winawer SJ, Zauber AG, Ho MN et al. The National Polyp Study, Prevention of colorectal cancer by colonoscopic polypectomy. *N Engl J Med* 1993; 329: 1977–81.
9. Engstrom PF, Benson AB 3rd, Chen YJ. Colon cancer clinical practice guidelines in oncology. *J Natl Compr Canc Netw* 2005; 3: 468–91.
10. [www.cancer.org/docroot/stt/stt\\_0.asp](http://www.cancer.org/docroot/stt/stt_0.asp).
11. Rockey DC, Paulson E, Niedzwiecki D et al. Analysis of air contrast barium enema, computed tomographic colonography, and colonoscopy: prospective comparison. *Lancet* 2005; 365: 305–11.
12. AJCC Cancer Staging Handbook, 6th edn. Philadelphia: Springer, 2002.
13. [www.info.cancerresearchuk.org/cancerstats/types/bowel/survival/](http://www.info.cancerresearchuk.org/cancerstats/types/bowel/survival/).
14. Fuchshuber PR, Rodriguez-Bigaz M, Weber T, Petrelli NJ. Anal canal and perineal epidermoid cancers. *J Am Coll Surg* 1997; 185: 494–505.
15. McAndrew MR, Saba AK. Efficacy of routine preoperative computed tomography scans in colon cancer. *Am Surg* 1999; 65: 205–8.
16. van der Schouw YT, Verbeek AL, Wobbes T et al. Comparison of four serum tumour markers in the diagnosis of colorectal carcinoma. *Br J Cancer* 1992; 66: 148–54.
17. Clinical practice guidelines for the use of tumor markers in breast and colorectal cancer. Adopted on May 17, 1996 by the American Society of Clinical Oncology. *J Clin Oncol* 1996; 14: 2843–77.
18. Thaler W, Watzka S, Martin F et al. Preoperative staging of rectal cancer by endoluminal ultrasound vs. magnetic resonance imaging. Preliminary results of a prospective, comparative study. *Dis Colon Rectum* 1994; 37: 1189–93.
19. Morotomi M, Guillem JG, Pocsidio JG et al. Effect of polyethylene glycol-electrolyte lavage solution on intestinal microflora. *Appl Environ Microbiol* 1989; 55: 1026–8.
20. Platell C, Barwood N, Makin G. Randomized clinical trial of bowel preparation with a single phosphate enema or polyethylene glycol before elective colorectal surgery. *Br J Surg* 2006; 93: 427–33.
21. Bucher P, Gervaz P, Soravia C et al. Randomized clinical trial of mechanical bowel preparation versus no preparation before elective left-sided colorectal surgery. *Br J Surg* 2005; 92: 409–14.
22. Nelson H, Petrelli N, Carlin A et al. Guidelines 2000 for colon and rectal cancer surgery. *J Natl Cancer Inst* 2001; 93: 583–96.
23. Swanson RS, Compton CC, Stewart AK, Bland KI. The prognosis of T3N0 colon cancer is dependent on the number of lymph nodes examined. *Ann Surg Oncol* 2003; 10: 65–71.
24. Baxter NN, Virnig DJ, Rothenberger DA et al. Lymph node evaluation in colorectal cancer patients: a population-based study. *J Natl Cancer Inst* 2005; 97: 219–25.
25. Pocard M, Van den Eynde M, Goere D et al. Sentinel lymph node sampling and analysis in colon cancer: what is the question? *J Clin Oncol* 2006; 24: 3712–3; author reply 3713–4.
26. Tomita H, Marcello PW, Milsom JW. Laparoscopic surgery of the colon and rectum. *World J Surg* 1999; 23: 397–405.
27. Clinical Outcomes of Surgical Therapy Study Group. A comparison of laparoscopically assisted and open colectomy for colon cancer. *N Engl J Med* 2004; 350: 2050–9.
28. Veldkamp R, Kuhry E, Hop WC et al. Laparoscopic surgery versus open surgery for colon cancer: short-term outcomes of a randomised trial. *Lancet Oncol* 2005; 6: 477–84.
29. Pollett WG, Nicholls RJ. The relationship between the extent of distal clearance and survival and local recurrence rates after curative anterior resection for carcinoma of the rectum. *Ann Surg* 1983; 198: 159–63.
30. Smalley S, Benedetti J, Williamson S. Intergroup-0144-phase III trial of 5-FU based chemotherapy regimens plus radiotherapy (XRT) in postoperative adjuvant rectal cancer. Proceedings of the American Society of Clinical Oncology 2003; 22: 251a.
31. Wolmark N, Fisher B. An analysis of survival and treatment failure following abdominoperineal and sphincter-saving resection in Dukes' B and C rectal carcinoma. A report of the NSABP clinical trials. National Surgical Adjuvant Breast and Bowel Project. *Ann Surg* 1986; 204: 480–9.
32. Scott N, Jackson P, al-Jaberi T et al. Total mesorectal excision and local recurrence: a study of tumour spread in the mesorectum distal to rectal cancer. *Br J Surg* 1995; 82: 1031–3.
33. Nagtegaal ID, van de Velde CJ, van der WE et al. Macroscopic evaluation of rectal cancer resection specimen: clinical significance of the pathologist in quality control. *J Clin Oncol* 2002; 20: 1729–34.
34. Fick TE, Baeten CG, von Meyenfeldt MF, Obertop H. Recurrence and survival after abdominoperineal and low anterior resection for rectal cancer, without adjunctive therapy. *Eur J Surg Oncol* 1990; 16: 105–8.
35. McLeod RS. Comparison of quality of life in patients undergoing abdominoperineal extirpation or anterior resection for rectal cancer. *Ann Surg* 2001; 233: 157–8.
36. Minsky BD, Rich T, Recht A, Harvey W, Mies C. Selection criteria for local excision with or without adjuvant radiation therapy for rectal cancer. *Cancer* 1989; 63: 1421–9.
37. Neary P, Makin GB, White TJ et al. Transanal endoscopic microsurgery: a viable operative alternative in selected patients with rectal lesions. *Ann Surg Oncol* 2003; 10: 1106–11.
38. Parks AG. Per-anal anastomosis. *World J Surg* 1982; 6: 531–8.
39. Sauer R, Becker H, Hohenberger W et al. Preoperative versus postoperative chemoradiotherapy for rectal cancer. *N Engl J Med* 2004; 351: 1731–40.
40. Paty PB, Enker WE, Cohen AM et al. Long-term functional results of coloanal anastomosis for rectal cancer. *Am J Surg* 1994; 167: 90–4.
41. Prolongation of the disease-free interval in surgically treated rectal carcinoma. Gastrointestinal Tumor Study Group. *N Engl J Med* 1985; 312: 1465–72.
42. Krook JE, Moertel CG, Gunderson LL et al. Effective surgical adjuvant therapy for high-risk rectal carcinoma. *N Engl J Med* 1991; 324: 709–15.
43. Heald RJ, Husband EM, Ryall RD. The mesorectum in rectal cancer surgery—the clue to pelvic recurrence? *Br J Surg* 1982; 69: 613–6.
44. Heald RJ, Moran BJ, Ryall RD et al. Rectal cancer: the Basingstoke experience of total mesorectal excision, 1978–1997. *Arch Surg* 1998; 133: 894–9.
45. Enker WE. Total mesorectal excision—the new golden standard of surgery for rectal cancer. *Ann Med* 1997; 29: 127–33.
46. Nelson H, Sargent DJ. Refining multimodal therapy for rectal cancer. *N Engl J Med* 2001; 345: 690–2.
47. Arbmán G, Nilsson E, Hallbook O, Sjodahl R. Local recurrence following total mesorectal excision for rectal cancer [see comments]. *Br J Surg* 1996; 83: 375–9.
48. Kapiteijn E, Marijnen CA, Nagtegaal ID et al. Preoperative radiotherapy combined with total mesorectal excision for resectable rectal cancer. *N Engl J Med* 2001; 345: 638–46.

49. Schell SR, Zlotecki RA, Mendenhall WM et al. Transanal excision of locally advanced rectal cancers downstaged using neoadjuvant chemoradiotherapy. *J Am Coll Surg* 2002; 194: 584–90.
50. Baron TH, Dean PA, Yates MR 3rd et al. Expandable metal stents for the treatment of colonic obstruction: techniques and outcomes. *Gastrointest Endosc* 1998; 47: 277–86.
51. Buyse M, Zeleniuch-Jacquotte A, Chalmers TC. Adjuvant therapy of colorectal cancer. Why we still don't know. *Jama* 1988; 259: 3571–8.
52. Smith RE, Colangelo L, Wieand HS et al. Randomized trial of adjuvant therapy in colon carcinoma: 10-year results of NSABP protocol C-01. *J Natl Cancer Inst* 2004; 96: 1128–32.
53. O'Connell MJ, Mailliard JA, Kahn MJ et al. Controlled trial of fluorouracil and low-dose leucovorin given for 6 months as postoperative adjuvant therapy for colon cancer. *J Clin Oncol* 1997; 15: 246–50.
54. Wolmark N, Rockette H, Mamounas E et al. Clinical trial to assess the relative efficacy of fluorouracil and leucovorin, fluorouracil and levamisole, and fluorouracil, leucovorin, and levamisole in patients with Dukes' B and C carcinoma of the colon: results from National Surgical Adjuvant Breast and Bowel Project C-04. *J Clin Oncol* 1999; 17: 3553–9.
55. Poplin EA, Benedetti JK, Estes NC et al. Phase III Southwest Oncology Group 9415/Intergroup 0153 randomized trial of fluorouracil, leucovorin, and levamisole versus fluorouracil continuous infusion and levamisole for adjuvant treatment of stage III and high-risk stage II colon cancer. *J Clin Oncol* 2005; 23: 1819–25.
56. Twelves C, Wong A, Nowacki MP et al. Capecitabine as adjuvant treatment for stage III colon cancer. *N Engl J Med* 2005; 352: 2696–704.
57. Andre T, Boni C, Mounedji-Boudiaf L et al. Oxaliplatin, fluorouracil, and leucovorin as adjuvant treatment for colon cancer. *N Engl J Med* 2004; 350: 2343–51.
58. Wolmark N, Colangelo L, Wieand S. National Surgical Adjuvant Breast and Bowel Project trials in colon cancer. *Semin Oncol* 2001; 28(1 Suppl 1): 9–13.
59. Clinical Practice Guidelines in Oncology. National Comprehensive Cancer Network (NCCN) v2. 2006.
60. Van Cutsem E, Labianca R, Hossfeld D. Randomized phase III trial comparing infused irinotecan/5-fluorouracil/folinic acid versus 5-FU/FA in stage III colon cancer patients. *J Clin Oncol* 2005; 23: 1090.
61. Wolmark N, Wieand HS, Hyams DM et al. Randomized trial of postoperative adjuvant chemotherapy with or without radiotherapy for carcinoma of the rectum: National Surgical Adjuvant Breast and Bowel Project Protocol R-02. *J Natl Cancer Inst* 2000; 92: 388–96.
62. Efficacy of adjuvant fluorouracil and folinic acid in colon cancer. International Multicentre Pooled Analysis of Colon Cancer Trials (IMPACT) investigators. *Lancet* 1995; 345: 939–44.
63. Zaniboni A, Labianca R, Marsoni S et al. A randomized trial of adjuvant 5-fluorouracil and folinic acid administered to patients with colon carcinoma—long term results and evaluation of the indicators of health-related quality of life. Gruppo Italiano Valutazione Interventi in Oncologia. Studio Italiano Terapia Adjuvante Colon. *Cancer* 1998; 82: 2135–44.
64. Figueredo A, Charette ML, Maroun J et al. Adjuvant therapy for stage II colon cancer: a systematic review from the Cancer Care Ontario Program in evidence-based care's gastrointestinal cancer disease site group. *J Clin Oncol* 2004; 22: 3395–407.
65. Benson AB 3rd, Schrag D, Somerfield MR et al. American Society of Clinical Oncology recommendations on adjuvant chemotherapy for stage II colon cancer. *J Clin Oncol* 2004; 22: 3408–19.
66. Gryfe R, Kim H, Hsieh ET et al. Tumor microsatellite instability and clinical outcome in young patients with colorectal cancer. *N Engl J Med* 2000; 342: 69–77.
67. Kohonen-Corish MR, Daniel JJ, Chan C et al. Low microsatellite instability is associated with poor prognosis in stage C colon cancer. *J Clin Oncol* 2005; 23: 2318–24.
68. Watanabe T, Wu TT, Catalano PJ et al. Molecular predictors of survival after adjuvant chemotherapy for colon cancer. *N Engl J Med* 2001; 344: 1196–206.
69. Jen J, Kim H, Piantadosi S et al. Allelic loss of chromosome 18q and prognosis in colorectal cancer. *N Engl J Med* 1994; 331: 213–21.
70. Martenson JA Jr, Willett CG, Sargent DJ et al. Phase III study of adjuvant chemotherapy and radiation therapy compared with chemotherapy alone in the surgical adjuvant treatment of colon cancer: results of intergroup protocol 0130. *J Clin Oncol* 2004; 22: 3277–83.
71. Galandiuk S, Wieand HS, Moertel CG et al. Patterns of recurrence after curative resection of carcinoma of the colon and rectum. *Surg Gynecol Obstet* 1992; 174: 27–32.
72. Zaheer S, Pemberton JH, Farouk R et al. Surgical treatment of adenocarcinoma of the rectum. *Ann Surg* 1998; 227: 800–11.
73. Colorectal Cancer Collaborative Group. Adjuvant radiotherapy for rectal cancer: a systematic overview of 8,507 patients from 22 randomised trials. *Lancet* 2001; 358: 1291–304.
74. Douglass HO Jr, Moertel CG, Mayer RJ et al. Survival after postoperative combination treatment of rectal cancer. *N Engl J Med* 1986; 315: 1294–5.
75. NIH consensus conference. Adjuvant therapy for patients with colon and rectal cancer. *Jama* 1990; 264: 1444–50.
76. Kollmorgen CF, Meagher AP, Wolff BG et al. The long-term effect of adjuvant postoperative chemoradiotherapy for rectal carcinoma on bowel function. *Ann Surg* 1994; 220: 676–82.
77. Bujko K, Nowacki MP, Nasierowska-Guttmejer A et al. Sphincter preservation following preoperative radiotherapy for rectal cancer: report of a randomised trial comparing short-term radiotherapy vs. conventionally fractionated radiochemotherapy. *Radiother Oncol* 2004; 72: 15–24.
78. Improved survival with preoperative radiotherapy in resectable rectal cancer. Swedish Rectal Cancer Trial. *N Engl J Med* 1997; 336: 980–7.
79. The evaluation of low dose pre-operative X-ray therapy in the management of operable rectal cancer; results of a randomly controlled trial. *Br J Surg* 1984; 71: 21–5.
80. Gerard A, Buyse M, Nordlinger B et al. Preoperative radiotherapy as adjuvant treatment in rectal cancer. Final results of a randomized study of the European Organization for Research and Treatment of Cancer (EORTC). *Ann Surg* 1988; 208: 606–14.
81. Peeters KC, van de Velde CJ, Leer JW et al. Late side effects of short-course preoperative radiotherapy combined with total mesorectal excision for rectal cancer: increased bowel dysfunction in irradiated patients—a Dutch colorectal cancer group study. *J Clin Oncol* 2005; 23: 6199–206.
82. Camma C, Giunta M, Fiorica F et al. Preoperative radiotherapy for resectable rectal cancer: A meta-analysis. *Jama* 2000; 284: 1008–15.
83. Bosset JF, Collette L, Calais G et al. Chemotherapy with preoperative radiotherapy in rectal cancer. *N Engl J Med* 2006; 355: 1114–23.

84. [www.nccn.org/default.asp](http://www.nccn.org/default.asp).
85. [www.asco.org/portal/site/ASCO/menuitem.c543a013502b2a89de912310320041a0/?vgnextoid=9f882071d0658010VgnVCM100000ed730ad1RCRD](http://www.asco.org/portal/site/ASCO/menuitem.c543a013502b2a89de912310320041a0/?vgnextoid=9f882071d0658010VgnVCM100000ed730ad1RCRD)
86. Chang GJ, Feig BW. Cancer of the colon, rectum, and anus. In: Feig BW, Berger DH, Fuhrman GM, eds. *The M.D. Anderson Surgical Oncology Handbook*. Philadelphia: Lippincott Williams and Wilkins, 2006: 261–320.
87. Clark MA, Hartley A, Geh JI. Cancer of the anal canal. *Lancet Oncol* 2004; 5: 149–57.
88. Rousseau DL Jr, Thomas CR Jr, Petrelli NJ, Kahlenberg MS. Squamous cell carcinoma of the anal canal. *Surg Oncol* 2005; 14: 121–32.
89. Geipert N. Vaccinating men for HPV: new strategy for preventing cervical cancer in women? *J Natl Cancer Inst* 2005; 97: 630–1.
90. Ryan DP, Compton CC, Mayer RJ. Carcinoma of the anal canal. *N Engl J Med* 2000; 342: 792–800.
91. Old ref. 131
92. Old ref. 132
93. Old ref. 141
94. Old ref. 142
95. Berardi RS, Lee S, Chen HP. Perianal extramammary Paget's disease. *Surg Gynecol Obstet* 1988; 167: 359–6.
96. Moore HG, Guillem JG. Anal neoplasms. *Surg Clin North Am* 2002; 82: 1233–51.
97. Nigro ND, Vaitkevicius VK, Considine B Jr. Combined therapy for cancer of the anal canal: a preliminary report. *Dis Colon Rectum* 1974; 17: 354–6.
98. Sato H, Koh PK, Bartolo DC. Management of anal canal cancer. *Dis Colon Rectum* 2005; 48: 1301–15.
99. Bartelink H, Roelofs F, Eschwege F et al. Concomitant radiotherapy and chemotherapy is superior to radiotherapy alone in the treatment of locally advanced anal cancer: results of a phase III randomized trial of the European Organization for Research and Treatment of Cancer Radiotherapy and Gastrointestinal Cooperative Groups. *J Clin Oncol* 1997; 15: 2040–9.
100. Flam M, John M, Pajak TF et al. Role of mitomycin in combination with fluorouracil and radiotherapy, and of salvage chemoradiation in the definitive nonsurgical treatment of epidermoid carcinoma of the anal canal: results of a phase III randomized intergroup study. *J Clin Oncol* 1996; 14: 2527–39.
101. Epidermoid anal cancer: results from the UKCCCR randomised trial of radiotherapy alone versus radiotherapy, 5-fluorouracil, and mitomycin. UKCCCR Anal Cancer Trial Working Party. UK Co-ordinating Committee on Cancer Research. *Lancet* 1996; 348: 1049–54.
102. Hung A, Crane C, Delclos M et al. Cisplatin-based combined modality therapy for anal carcinoma: a wider therapeutic index. *Cancer* 2003; 97: 1195–202.
103. Ajani JA, W. KA, Gunderson LL et al. Intergroup RTOG 98-11: A phase III randomized study of 5-fluorouracil (5-FU), mitomycin, and radiotherapy versus 5-fluorouracil, cisplatin and radiotherapy in carcinoma of the anal canal. *Journal of Clinical Oncology*, 2006 ASCO Annual Meeting Proceedings Part I, 2006; 24(18S (June 20 Supplement)): 4009.
104. Skibber J, Rodriguez-Bigas MA, Gordon PH. Surgical considerations in anal cancer. *Surg Oncol Clin N Am* 2004; 13: 321–38.
105. Akbari RP, Paty PB, Guillem JG et al. Oncologic outcomes of salvage surgery for epidermoid carcinoma of the anus initially managed with combined modality therapy. *Dis Colon Rectum* 2004; 47: 1136–44.
106. Pocard M, Tiret E, Nugent K et al. Results of salvage abdominoperineal resection for anal cancer after radiotherapy. *Dis Colon Rectum* 1998; 41: 1488–93.
107. van der Wal BC, Cleffken BI, Gulec B et al. Results of salvage abdominoperineal resection for recurrent anal carcinoma following combined chemoradiation therapy. *J Gastrointest Surg* 2001; 5: 383–7.
108. Esiashvili N, Landry J, Matthews RH. Carcinoma of the anus: strategies in management. *Oncol* 2002; 7: 188–99.
109. Cummings BJ. Current management of anal cancer. *Semin Oncol*, 2005; 32(6 suppl 9): S123–8.



# Pancreatic cancer and ampullary carcinoma

17

Dirk J Gouma, W L Vervenne and O R C Busch

---

## INCIDENCE/PREVALENCE/ PREDISPOSING-RISK FACTORS

Pancreatic tumors are the eighth commonest cause of cancer related death in the Western world<sup>1,2</sup>. The incidence in Europe as well as the US is around 10–12 per 100 000 per year<sup>1,2</sup>. The majority of these tumors are pancreatic adenocarcinoma. Despite surgical treatment with or without radio- and chemotherapy, the overall 5-year survival is around 4% and has hardly improved during recent decades<sup>2–4</sup>. So the prevalence of these tumors is roughly the same as the incidence.

Carcinoma of the ampulla of Vater is relatively uncommon. The incidence is 1–2 per 100 000 per year. These tumors are associated with a better prognosis than pancreatic cancer; a high percentage can be resected and the 5-year survival is between 40 and 60% after resection<sup>5</sup>. The better survival rate is attributable to earlier presentation, generally with obstructive jaundice, and due to the location of the tumor in relation with the mesenteric and portal vessels. There is confusion about the terminology, in particular using the word periampullary as well as pancreatic head tumors. Both also include distal bile duct tumors as well as duodenal tumors. Using the term pancreatic cancer generally only refers to patients with ductal adenocarcinoma of the pancreas excluding neuroendocrine tumors and other lesions.

The etiology of pancreatic and ampullary carcinoma is still unknown. A model of genetic progression and accumulation of multiple genetic changes resulting in pancreatic intraepithelial neoplasia (PanIN)-1A (K-ras mutations), PanIN-2 (loss p16 expression), and PanIN-3 lesions (loss of SMAD4 expression), and subsequently invasive carcinoma is now generally accepted<sup>6,7</sup>. The most important predisposing risk factors are chronic pancreatitis, patients with hereditary pancreatitis and familial pancreatic cancer (5–10%) as well as the well known genetic syndromes such as Peutz-Jeghers syndrome (PJS), familial atypical multiple melanoma syndrome (FAMMM) and familial adenomatous polyposis (FAP) for patients with

ampullary tumors<sup>8,9</sup>. I MPT has also been considered as a premalignant lesion. Other suggested, non-evidence-based factors are cigarette smoking and adult-onset diabetes (probably the first symptom in 10% of patients)<sup>10</sup>.

## PRESENTATION

In the early phase patients are asymptomatic or will have relatively non-specific symptoms such as anorexia, nausea, abdominal discomfort, or pain, in particular if the tumor is located in the pancreatic corpus or tail area. Therefore, the majority of patients have advanced disease at the time of diagnosis. In the later phase most patients with a pancreatic head lesion (70% of the tumors) will have the well known symptoms of obstructive jaundice (in combination with dark urine and pale clay-colored stools, weight loss, itching, and an abdominal mass in the right upper abdomen (palpable gallbladder)). Painless jaundice with a palpable gallbladder at physical examination (Courvoisier's sign) is highly suspicious for a distal bile duct obstruction. In patients with ampullary lesions approximately 10% will present with cholangitis due to the incomplete obstruction of the biliary tract leading to infection and cholangitis. Patients with more advanced disease will often present with persistent upper abdominal pain radiated to the back (tumor invading retroperitoneal nerves), vomiting (due to duodenal obstruction in 15%) and ascites (due to portal vein obstruction). Late-onset diabetes mellitus is reported in 10% and a minority of patients will present with an unexplained acute pancreatitis.

Tumors located in the corpus and/or tail area, generally in an advanced stage, will present with long-lasting general malaise, weight loss and pain radiating to the back. Pancreatic exocrine insufficiency will lead to malabsorption and eventually to steatorrhea. Laboratory findings are not very specific. Liver function tests will confirm an extrahepatic cholestasis and serum glucose levels will confirm diabetes. Tumor markers are not very useful because of a relatively low diagnostic accuracy but CA 19-9 and carcinoembryonic antigen (CEA) might be raised and are

used now in some countries<sup>11</sup>. However, many centers do not use these tumor markers routinely.

## SCREENING AND DIAGNOSTIC STRATEGIES

The screening and diagnostic strategy can be divided in three main parts: first, the 'early' diagnostic strategy for asymptomatic high risk patients or screening; second, the diagnostic work-up for symptomatic patients to establish the diagnosis as well as the assessment of the patient's fitness for undergoing major surgery; and third, the staging procedures in terms of determining the extent of local disease (in particular relative to vascular structures) and metastasis.

Screening will become more important in the near future after identifying new (genetic) risk factors for development of pancreatic carcinoma, but currently the potential selection of the population for screening is not well defined, except for the generally accepted indications regarding pancreatic cancer families and patients with hereditary pancreatitis or IMPT<sup>9</sup>. The sensitivity and specificity of tumor markers and newly developed biomarkers in blood, pancreatic secretion, or duodenal fluid is too low and currently of limited value for screening tests. Even brush cytology with K-ras or p53 alterations has a relatively low sensitivity<sup>12</sup>. Other screening possibilities are dual computed tomography (CT) scan, magnetic resonance imaging (MRI), or endoscopic ultrasound. Currently CT scan and MRI are used most commonly.

The management of high risk patients with subsequent small detected lesions in the pancreas, without proven malignancy is still difficult. Is (subtotal) pancreatectomy as prevention justified in these patients? Complications as a result of this screening program and the subsequent surgical procedure without malignancy should be prevented.

## DIAGNOSTIC STRATEGIES

The aim of the current diagnostic strategies is to select patients for potential curative resections. Other authors with a more pessimistic view have suggested that the main goal of staging should be selection to obtain optimal palliation<sup>3</sup>. In this option staging is helpful to avoid unnecessary operations and select patients for non-surgical palliation.

Until the early 1970s in the last century the only diagnostic test was hypotonic duodenography and final staging was performed 'durante operation'. Currently diagnostic work-up and staging can be performed by many new modalities such as Doppler ultrasound, CT scan, magnetic resonance cholangiopancreatography (MRCP),

MRI/MRCP, endoscopic ultrasound, endoscopic retrograde cholangiopancreatography (ERCP) or percutaneous transhepatic cholangiography (PTC) with intra-ductal ultrasound, positron emission tomography (PET) scan, brush and fine needle biopsy, and, finally, diagnostic laparoscopy. The question remains which tests or combination of tests are necessary for screening to establish the diagnosis but in particular to obtain accurate staging.

The diagnostic work-up for symptomatic patients generally starts with an ultrasound to exclude benign disease, in particular common bile duct (CBD) stones (gallbladder stones). Ultrasound will nearly always show dilated bile ducts and sometimes a pancreatic mass and/or liver metastasis<sup>13,14</sup>. In the past in patients with obstructive jaundice ERCP was the next invasive test. In a study from The Netherlands we found that in 30% of patients with obstructive jaundice, ERCP and subsequent biliary drainage was still the next step before a CT scan was performed<sup>15</sup>. It is not clear whether the order was caused by a waiting time for the CT scan or by the wish of the gastroenterologist to obtain the definitive diagnosis and pathological proof and to conduct a therapeutical intervention.

Because of the improvement in the quality of spiral CT and MRCP during recent years, it is questioned whether ERCP should be used or if it is still justified as a diagnostic procedure. There is general agreement that there is no role for ERCP in the diagnostic work-up. Data about the accuracy of CT scans, endoscopic ultrasound and MRI/MRCP concerning detection of a pancreatic mass, showing the presence of liver metastases and local resectability are widely variable due to technical performance and patient selection<sup>16-19</sup>. A recent meta-analysis showed that CT scan, MRI and ultrasound are comparable to demonstrate pancreatic mass with an overall sensitivity of 76%, 91% and 84%, and a specificity of 75%, 85% and 82%, respectively<sup>18</sup>.

A difficult problem remains the differentiation between focal pancreatitis and pancreatic carcinoma which might also induce pancreatitis around the tumor area. In a previous study we found that about 5% of patients who underwent resection for a suspected lesion in the pancreatic head area suffered from chronic (focal) pancreatitis. On the other hand, in a group of 400 patients with chronic pancreatitis pancreatic cancer was diagnosed in more than 5% within 4 years, partly due to a missed diagnosis (recognized within 12 months) or development of pancreatic cancer in chronic pancreatitis<sup>20</sup>.

Endoscopic ultrasonography has a high sensitivity but also lower specificity regarding local inflammatory changes. An additional advantage is that endoscopic ultrasound during a puncture can confirm the diagnosis, unfortunately a negative biopsy does not exclude malignancy<sup>19</sup>.

## STAGING

The selection of patients for further staging is heavily dependent on local treatment philosophy, in particular considering the extent of local tumor growth in surrounding vessels and more recently regarding the indication to resect (solitary) metastasis. There are different criteria to define local resectability of pancreatic tumors. Should resectability include a resection of the portal/mesenteric vein in order to achieve a R0 resection or should ingrowth at the CT scan for more than 180° be considered as incurable and therefore not resectable<sup>21–23</sup>? Second, is a non-radical (R1) resection justified as optimal palliative treatment<sup>23–25</sup>? Others have suggested that resection should not be performed if a radical (R0) resection cannot be obtained because it does not provide survival benefits and increases morbidity<sup>3</sup>. Until recently there was a consensus that patients with metastases should not undergo resection and there is currently no evidence to change this policy. However, there are a few studies showing long-term survival after pancreatic resection combined with liver resection for limited metastatic disease, however, others have not shown survival benefit<sup>26,27</sup>.

Metastases can be found by endoscopic ultrasound, CT scan and MRI, and the specificity for metastases by MRI and CT are 92% and 82%, respectively<sup>18</sup>, considering the availability in general practice and the cost effectiveness, the CT scan is presently the most commonly used staging procedure but the role of MRI might increase in the near future<sup>17,18,22</sup>. Endoscopic ultrasound has a lower accuracy for liver metastasis, however, the detection of vascular infiltration is high<sup>19</sup>. The reported success rate (accuracy) of endoscopic ultrasound varies significantly and this could be strongly related to the experience of the endoscopist. PET has been introduced more recently and might be helpful in detection of metastases in the near future. Also, it shows the primary pancreatic lesion but false positive findings due to chronic (focal) pancreatitis are reported. So far its role in routine diagnostic work-up is limited<sup>28</sup>.

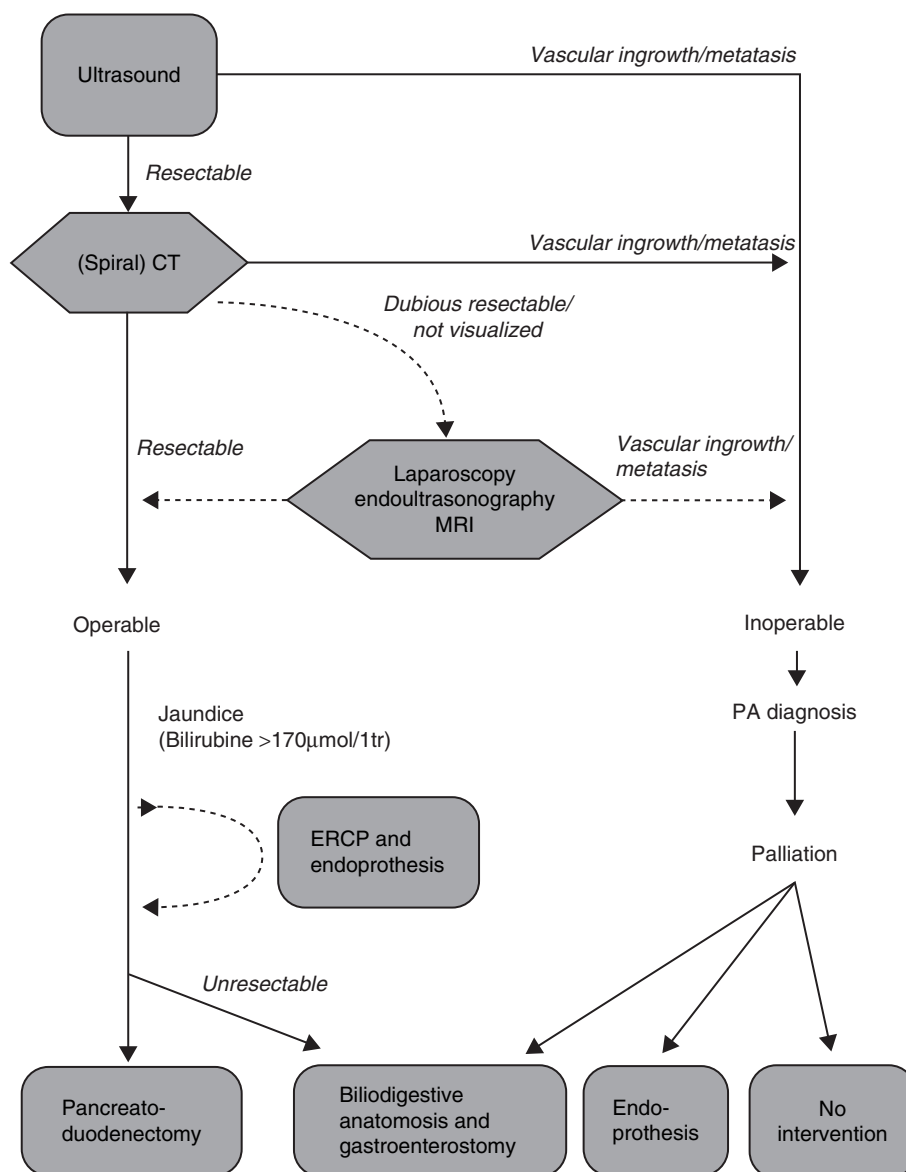
Unfortunately small liver metastases as well as peritoneal deposits will be missed by the above-mentioned techniques. Diagnostic laparoscopy has therefore been used routinely in the past to improve assessment of metastatic disease. It enables the detection of small superficial metastases at the liver surface and the peritoneum that are easily missed with radiological staging techniques and often first encountered during laparotomy. Diagnostic laparoscopy can be combined with laparoscopic ultrasound, which has been reported to be sensitive for the detection of intrahepatic metastases and for the evaluation of enlarged lymph nodes as well as tumor ingrowth in vascular structures surrounding peripancreatic tumors<sup>29–31</sup>.

As laparoscopy is the final staging procedure before surgery, the eventual benefits of laparoscopic staging apply to patients already selected for resection by radiological imaging techniques. In the early period, the additional value of diagnostic laparoscopy in patients with pancreatic head carcinoma varied widely between 18% and 82%<sup>29–31</sup>. In recent years new radiological imaging techniques have been improved, affecting patient selection for staging and increasing resectability rates even without adding laparoscopy. It is likely that the improved accuracy of radiological staging techniques will eventually limit the additional value of laparoscopic staging. In a review Pisters *et al.* stated that detection of occult metastatic disease should be around 10–15% at maximum during laparoscopy because otherwise the quality of prediagnostic imaging would be insufficient<sup>31</sup>. Recent studies from experienced centers in which the potential benefit of diagnostic laparoscopy in detection of metastases was evaluated during laparotomy after a high quality helical CT scan indeed showed a relative low percentage of liver metastasis<sup>31–33</sup>.

Since the evaluation of staging is incomplete without the assessment of the consequences for treatment in terms of improvement of outcome, we decided to investigate the additional value of diagnostic laparoscopy (after complete radiological staging) as well as the outcome of patients with pathology proven incurable carcinoma, who underwent subsequent palliative treatment by endoscopic stent placement or a surgical bypass procedure<sup>33</sup>. Patients with pathology proven metastases at diagnostic laparoscopy (13%) were randomized for both options and underwent subsequent palliative treatment. The average hospital-free survival in the endoscopically treated patients was 94 days compared with 164 days after surgical palliative treatment. This study showed again a limited benefit of diagnostic laparoscopy (13%) in preventing laparotomy but more importantly no improved hospital-free survival after subsequent non-surgical palliation. Therefore, diagnostic laparoscopy was abandoned as a routine diagnostic procedure in patients with periampullary and pancreatic tumors in our institute and in a more recent study this policy was confirmed<sup>34,35</sup>. The currently used diagnostic strategy in Academic Medical Center (AMC), Amsterdam is summarized in Figure 17.1.

Summarizing, a spiral CT scan (Figure 17.2) is currently the most important diagnostic tool for staging which might be changed for MRI in the future. The use of endoscopic ultrasound is dependent on local expertise but it should be used routinely if the tumor cannot be visualized in a patient with obstructive jaundice. There might be an indication to perform laparoscopy in a well-defined selected group of patients with a high risk of advanced disease. The additional value of PET scan to differentiate from chronic pancreatitis or to show metastases has so far limited additional value.





**Figure 17.1** The diagnostic strategy as used in the Academic Medical Center Amsterdam since 2003. CT, computed tomography; MRI, magnetic resonance imaging; ERCP, endoscopic retrograde cholangiopancreatography; PA.

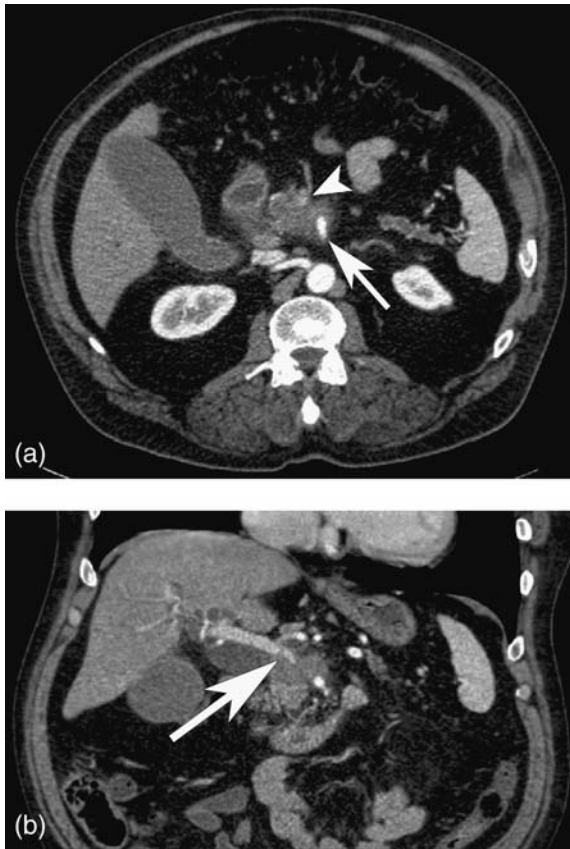
## SURGERY FOR CURE

Surgery and resection still offers the only possibility of cure; however, the majority of patients (approximately 80%) are not candidates for resection and even after resection patients (with pancreatic carcinoma) have a low chance for cure. Despite major improvement in operative mortality (less than 5% in centers), the morbidity is still substantial (40–60%), and careful evaluation of preoperative risk factors and preoperative preparation should be performed.

Preoperative biliary drainage before resection was introduced by Whipple in 1935. The surgical drainage procedure has more recently been replaced by endoscopic or percutaneous drainage. Preoperative drainage will lead to reversal of the pathophysiological disturbances seen in

jaundiced patients<sup>36</sup>. Obstructive jaundice induces endotoxemia due to translocation of bacteria from the bowel; endotoxemia leads to impaired immunological and renal function, and deterioration of the nutritional status. Experimental studies have shown benefits of preoperative biliary drainage in terms of reversal of these negative factors and a lower mortality rate<sup>36</sup>.

Clinical studies, however, have failed to show the same benefit of preoperative drainage, and recent studies have even reported a deleterious effect in terms of increased infection<sup>37–39</sup>. Therefore, a meta-analysis was performed to examine the effectiveness of preoperative biliary drainage in jaundiced patients with tumors. This study showed no difference in the overall death rate between patients who had preoperative biliary drainage and those who had



**Figure 17.2** A spiral CT scan of a patient with pancreatic cancer with encasement of (a) portal vein (coronal) (arrowhead) and mesenteric artery (arrow) and (b) the portal vein (axial) (arrow).

surgery without preoperative biliary drainage. The overall complication rate, however, was significantly adversely affected by preoperative biliary drainage compared with surgery without preoperative biliary drainage<sup>40</sup>. We concluded from this meta-analysis that preoperative biliary drainage should not be performed routinely.

The indication for preoperative biliary drainage is, however, also dependent on other factors such as the time needed for extra diagnostic tests, the severity of jaundice (serum bilirubin levels  $>300 \mu\text{mol/l}$ ), logistics such as waiting time for surgery or referral to centers, the use of preoperative chemoradiotherapy and, last but not least, the prevalence of the gastroenterologist<sup>37,41</sup>. A randomized controlled trial should be performed to define the role of preoperative endoscopic stenting.

### Surgical procedures

The standard procedure for pancreatic and ampullary cancer in the partial pancreaticoduodenectomy is shown in Figure 17.3. This can be performed by the classic so-called Kausch-Whipple resection, including a distal gastrectomy, or the pylorus preserving variant<sup>42–44</sup>.

Currently there is evidence from randomized controlled trials that the pylorus preserving partial

pancreaticoduodenectomy does not have a different outcome, in terms of early morbidity, mortality, recurrence and survival compared with the standard procedure<sup>45–48</sup>. A standard Whipple procedure is still preferred for tumors that might infiltrate in the area of the pylorus and gastric antrum or local lymph nodes.

### Extended resection

There is also discussion about the extent of resection in terms of extent of the lymphadenectomy with or without resection of the portal vein and/or mesenteric artery (regional resection). The different types of resection, the standard procedure, the extended lymph node dissection, and the regional en bloc pancreaticoduodenectomy have been defined and described after a consensus meeting in Europe<sup>44</sup>. After the initial study of Ishikawa *et al.* showing a 5-year survival of 28% after extended resection many (retrospective) studies suggested a potential benefit in terms of longer survival<sup>49</sup>.

Since then four randomized controlled trials have been published showing no benefit in survival but increased morbidity after extended lymph node dissection in terms of an increased rate of delayed gastric emptying and diarrhea<sup>50–55</sup>. This was confirmed in a recent meta-analysis comparing standard and extended lymphadenectomy.

Generally portal vein resection for extensive tumor encasement does not lead to prolonged survival and should therefore only be performed for local ingrowth to increase tumor-free margins<sup>56–58</sup>. The same principle can be followed for local extension in surrounding organs in particular limited ingrowth in the mesocolon leading to a segmental colon resection.

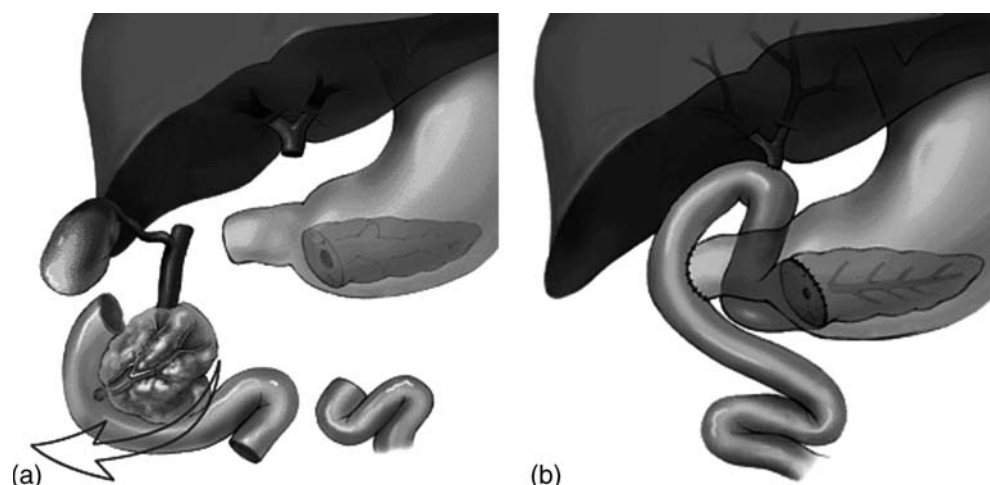
Resection of the portal or mesenteric vein for patients with limited unsuspected local tumor ingrowth, however, is now generally accepted and not associated with increased morbidity and mortality<sup>58</sup>.

In the past total pancreatectomy has been used because of the existence of multifocal tumors in the pancreas. This is very uncommon for pancreatic adenocarcinoma and no advantage was found in long-term survival. The procedure was also associated with more metabolic problems (diabetes). The current indication for total pancreatectomy is limited to patients with extensive IMPT<sup>59</sup>.

A pancreatic corpus and tail resection should be performed for lesions in the corpus and tail area. Most patients do not present with resectable lesions and, currently, there is discussion about extended tail resections, the so-called radical antegrade pancreatosplenectomy<sup>60,61</sup>.

### Perioperative somatostatin

The role of somatostatin and its analogs to reduce postoperative complications after pancreatic surgery is still



**Figure 17.3** A schematic drawing of pancreatoduodenectomy (a) and the reconstruction (b). Adapted from reference 42.

under discussion. Many trials have been performed with different outcomes ranging from reduction of overall complications as well as reduction in mortality to no difference in outcome<sup>62–64</sup>. It has been suggested that these differences might partly be due to patient selection (risk factors for leakage, for example inclusion of pancreatic versus ampullary tumors) and the experience of the participating centers (studies from high volume centers versus multicenter studies). In a recent meta-analysis, summarizing ten trials that met the inclusion criteria, somatostatin did not reduce overall morbidity and pancreatic-specific complications<sup>64</sup>. Currently, we are using somatostatin only in high-risk patients for leakage such as patients with a soft pancreas and patients without pancreatic duct dilatation (generally ampullary and duodenal tumors).

### Reconstruction after resection

An important complication after reconstruction is leakage of the pancreaticoenteric anastomosis. The reconstruction can be performed by a pancreaticojejunostomy or pancreaticogastrostomy (Figure 17.3b). The incidence of leakage of the pancreatic anastomosis and for pancreatic fistulas varies widely between 2% and 40%, and is related to not only the definition used but also, as mentioned above, to the type of tumor, ampullary and duodenal tumors versus pancreatic cancer, to the duct size, the pancreas consistency, and finally probably even more importantly the experience of the surgeon<sup>65–70</sup>. Recently the International Study Group on Pancreatic Fistula Definition introduced a well defined definition for pancreatic fistulas type A, B and C<sup>68</sup>. In retrospective studies it has been suggested that the leakage rate is lower after pancreaticogastrostomy compared with pancreaticojejunostomy<sup>71,72</sup>. Randomized controlled trials comparing pancreaticojejunostomy and pancreaticogastrostomy however, showed no difference in

mortality and leakage rate (12% and 10%, respectively)<sup>73–75</sup>. Experienced centers are generally reporting a mortality rate of 1–2% and overall complications between 30 and 50% after pancreatic resection (Table 17.1).

The most common severe postoperative complications after pancreaticoduodenectomy besides leakage of the pancreaticojejunostomy (pancreatic fistula) are leakage of the hepaticojejunostomy, bleeding and abscess formation<sup>63–75</sup>. There is an enormous discussion about the management of these complications ranging from completion pancreatectomy for severe leakage or bleeding to radiological intervention by percutaneous abscess drainage and percutaneous transhepatic biliary drainage for limited leakage and selected embolization for severe bleeding (Figure 17.4)<sup>65,66,69,70,76,77–78</sup>.

Delayed gastric emptying (DGE) is still a major clinical problem and it has been reported to occur at a rate of between 14% and 60%. It has been shown to be related to intra-abdominal infections, but not related to the type of resection (pylorus preserving or standard pancreatoduodenectomy)<sup>79</sup>. A recent randomized controlled trial showed that antecolic reconstruction might reduce DGE<sup>80</sup>.

### Volume–mortality relationship

Numerous studies have shown that several high-risk surgical procedures can be performed with a lower postoperative mortality rate in high-volume centers compared with low-volume centers<sup>65,70,81–84</sup>. This volume–outcome effect has underlined the importance of centralization. Although not generally accepted throughout the world, most states in the US do centralize successfully. In European countries centralization has been reported less frequently. Studies that plea for centralization are received with reluctance<sup>67</sup>. The scientific validity of these publications is questioned because they should reflect selection bias since

Table 17.1 Complications in patients who underwent pancreatoduodenectomy ( $n = 639$ ) between October 1992 and December 2005 at the Academic Medical Center, Amsterdam

Complication	<i>n</i>	%
Surgery-related	272	43
Pancreatic leakage/fistula	67	10.5
Bile leakage	19	3.0
Bleeding	48	7.5
Delayed gastric emptying	122	18.9
Relaparotomy	62	9.7
Mortality	9	1.4
Hospital stay	Median 16 days	

evidence of an inverse relationship between hospital volume and mortality, and reinforces the plea for centralization. A recent study, reporting on a 10-year plea for centralization among the surgical community, did not show a reduction of the mortality rate after pancreatic resection or change in the referral pattern in The Netherlands<sup>85</sup>.

Other methods such as interference by the government or health insurance companies have been introduced in some European countries and the US to change this pattern and to achieve a strong patient-driven action toward centralization. Recently, a first step has been made by the Dutch Government and Dutch Health Care Inspectorate introducing the so-called 'performance indicators' such as registration of volume and outcome of a few high-risk procedures.

## PALLIATIVE SURGERY

Unfortunately the majority of patients will have palliative treatment and therefore palliation of symptoms will still be the major focus to improve outcome of patients with pancreatic cancer. According to the World Health Organization, palliative care is aimed at improving the quality of life of patients who face a life-threatening illness and at the prevention or relief of pain and symptoms<sup>86</sup>. The three most important symptoms that should be treated in advanced pancreatic and periampullary cancer are obstructive jaundice, duodenal obstruction and pain.

The decision to aim for palliative treatment/surgery can be made at two different time points during the disease. The first decision is generally made after the staging procedures and a selection is made for potential curative surgery, palliative surgery, or non-surgical (endoscopic) palliation. A second step in the selection of treatment is made during surgery and can be an attempt for resection with curative intent (R0 resection), a resection for optimal palliation (R1 resection), or other surgical procedures for palliative treatment. Accurate initial staging remains, therefore, the crucial step for the selection of surgical and non-surgical (palliative) treatment and prevention of unnecessary laparotomies.

At the time of diagnosis up to 90% of the patients present with obstructive jaundice. Relief of the obstructive jaundice causes a dramatic increase of the quality of life of patients and should therefore always be accomplished<sup>87</sup>. Biliary drainage can be achieved non-surgically by placement of a biliary stent (endoscopic or percutaneous) or surgically by performing a biliary bypass. The success rate for short-term relief of biliary obstruction is comparable for both surgical and non-surgical drainage procedures and varies between 80 and 100%. In the past, endoscopic biliary drainage was widely performed using plastic (Teflon and polyethylene) stents. Plastic stents can give rise to

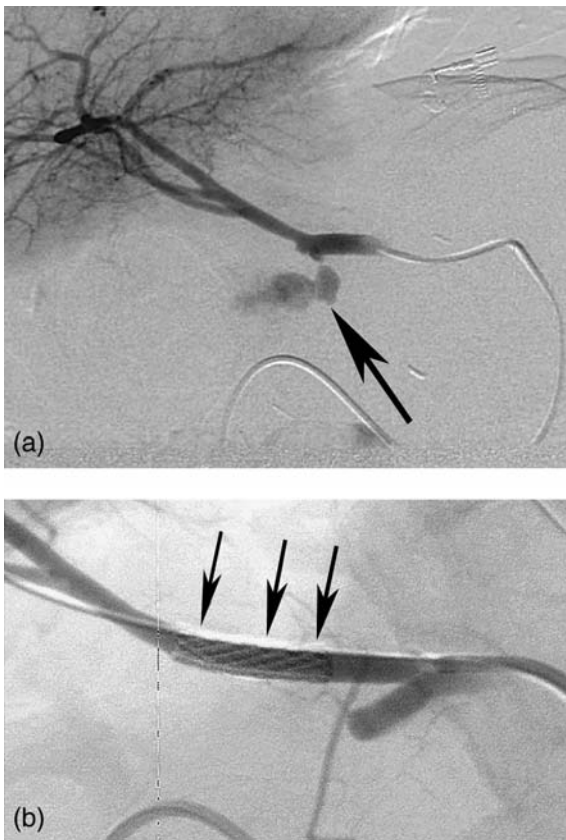


Figure 17.4 Postoperative bleeding after a pancreatoduodenectomy from the duodenal artery (a) and treatment by embolization and stenting (b). Adapted from reference 76.

they are based on data from large academic centers, single states, or selected patients<sup>81–85</sup>. Since randomization of patients between high- and low-volume hospitals is not feasible, a systematic review of the data from independent national routine health registries was performed<sup>85</sup>. The data on hospital volume and mortality show convincing

complications such as migration and occlusion, reported at rates of up to 40%. A new stent type for endoscopic treatment is the self-expandable (covered) metallic stent. Compared with plastic stents, expandable stents have a longer patency, but cannot be removed after placement<sup>88,89</sup>.

A surgical bypass can be performed by a hepaticojejunostomy alone or a double bypass, including a gastroenterostomy. In the past cholecystojejunostomy was preferred because it is a relatively simple procedure. However, in an extensive review the success rate of cholecystojejunostomy to relieve obstructive jaundice was lower compared with choledochojejunostomy. A choledochoduodenostomy is not recommended because it is generally thought that this drainage procedure frequently results in recurrent jaundice due to local tumor ingrowth into the hepatoduodenal ligament and the distal common bile duct, including the entrance of the cystic duct.

In our institution (AMC, Amsterdam) a site-to-site Roux Y choledochojejunostomy is routinely performed after removal of the gallbladder. According to the extension of dissection, in an attempt to demonstrate locally advanced disease by ingrowth at the proximal portal vein, the common bile duct may be transected in an early phase of the procedure and an end-to-site anastomosis is made by a one layer running suture.

Five prospective randomized controlled trials have been performed of which four compared surgical biliary drainage and endoscopic drainage<sup>33,90–93</sup>. In the first trial by Bornmann *et al.* percutaneous biliary drainage was used and no differences were found between percutaneous and surgical palliation. The other studies are relative old studies and were performed between 1988 and 1994 except for the study of Nieveen *et al.* in which patients underwent a diagnostic laparoscopy, and randomization for stent versus bypass was performed after pathology proven metastasis. There was no difference in procedure-related morbidity or number of re-admitted patients between the surgically and endoscopically palliated patients. The mean hospital-free survival was 164 days after surgical and 94 days after endoscopic palliation. The survival was 192 and 116 days in the surgical and endoscopic group, respectively ( $p = 0.05$ ). It must be kept in mind, however, that this concerns a selected group of patients who were thought to have a resectable tumor after conventional radiological staging<sup>33</sup>. Taylor *et al.* conducted a meta-analysis using the three earlier mentioned studies of endoscopic stenting and concluded that more treatment sessions were required after stent placement than after surgery, with a common odds ratio estimated to be 7.23. This indicates a more than 7-fold increased risk of additional treatment sessions after stenting<sup>94</sup>. No significant difference was found concerning 30-day mortality between the two treatment strategies.

So far a few general conclusions can be drawn from the available studies. Surgical treatment of biliary obstruction in unresectable pancreatic cancer is associated with higher early morbidity, longer hospital stay and probably higher initial mortality rate but long-term results are better. Endoscopic treatment is associated with a lower initial mortality and morbidity but more frequently leads to late biliary complications and reinterventions due to clotting of the stent, infection and gastric outlet obstruction (GOO). Therefore surgical palliation should be preferred in relatively fit patients with a suspected survival of more than 6 months.

### Gastric outlet obstruction

Symptoms of GOO such as nausea and vomiting are reported in 11–50% of patients with pancreatic cancer at the time of diagnosis. Surgical palliation should only be performed when GOO has a mechanical cause. When there is no mechanical cause of the GOO, pharmaceutical treatment options should be investigated. It is therefore important to radiologically or endoscopically confirm the mechanical GOO. In the patients who are found to have an unresectable tumor at laparotomy, a gastrojejunostomy (in addition to a biliary bypass) can easily be performed. On the other hand, endoscopic duodenal stenting has recently been introduced and accepted as a non-surgical palliative treatment of duodenal obstruction<sup>95</sup>. Therefore, even between surgeons debate remains about whether to perform a prophylactic gastrojejunostomy. From two recent trials it might be concluded that a prophylactic gastrojejunostomy is preferable to a biliary bypass alone, because of the significantly reduced risk of late GOO and the low morbidity and mortality rates<sup>96,97</sup>. None of the patients who received a gastrojejunostomy developed late GOO during follow-up, compared with 19% of patients who did not undergo a gastrojejunostomy in the initial procedure, which was significantly different<sup>97</sup>. However, it has to be realized that in these two studies endoscopic stenting of duodenal obstruction during follow-up was not attempted and this might influence the outcome in the near future.

### Pain management

At the time of diagnosis, approximately 40–80% of patients already report pain. According to the World Health Organization guidelines, the initial pain management should be pharmacological, and consist of analgesics such as non-steroidal anti-inflammatory drugs (NSAIDs) and oral or transdermic narcotic analgesics. The next step is a celiac plexus nerve block, which interrupts the innervation of the pancreas and prevents pain stimuli reaching the brain.

Currently the celiac plexus block can be performed percutaneously, by endoscopic ultrasound or during laparotomy. There are only a few randomized controlled trials on percutaneous neurolytic celiac plexus blockade (NCPB) and the best evidence is in terms of prevention of pain from the recent study by Wong *et al.*<sup>98</sup>.

Celiac plexus block during surgery has been performed for many years. Lillemoe *et al.* performed a double-blinded randomized controlled trial which compared a chemical splanchnicectomy during laparotomy with alcohol versus saline placebo. Chemical splanchnicectomy was performed intraoperatively by injection of 20 ml of either 50% alcohol or saline solution on each side of the aorta at the level of the celiac axis. Alcohol injection significantly reduced the mean pain score for surviving patients at 2, 4 and 6 months. Interestingly, actuarial survival was improved in the subgroup of patients who reported significant preoperative pain and underwent a splanchnicectomy with alcohol ( $p < 0.001$ )<sup>99</sup>. The authors suggested that the difference could be caused by the progressive physical deterioration due to persistent pain which eventually leads to impaired survival. These findings confirm other reports which state that the presence of pain is associated with a poor prognosis.

### Palliative resection

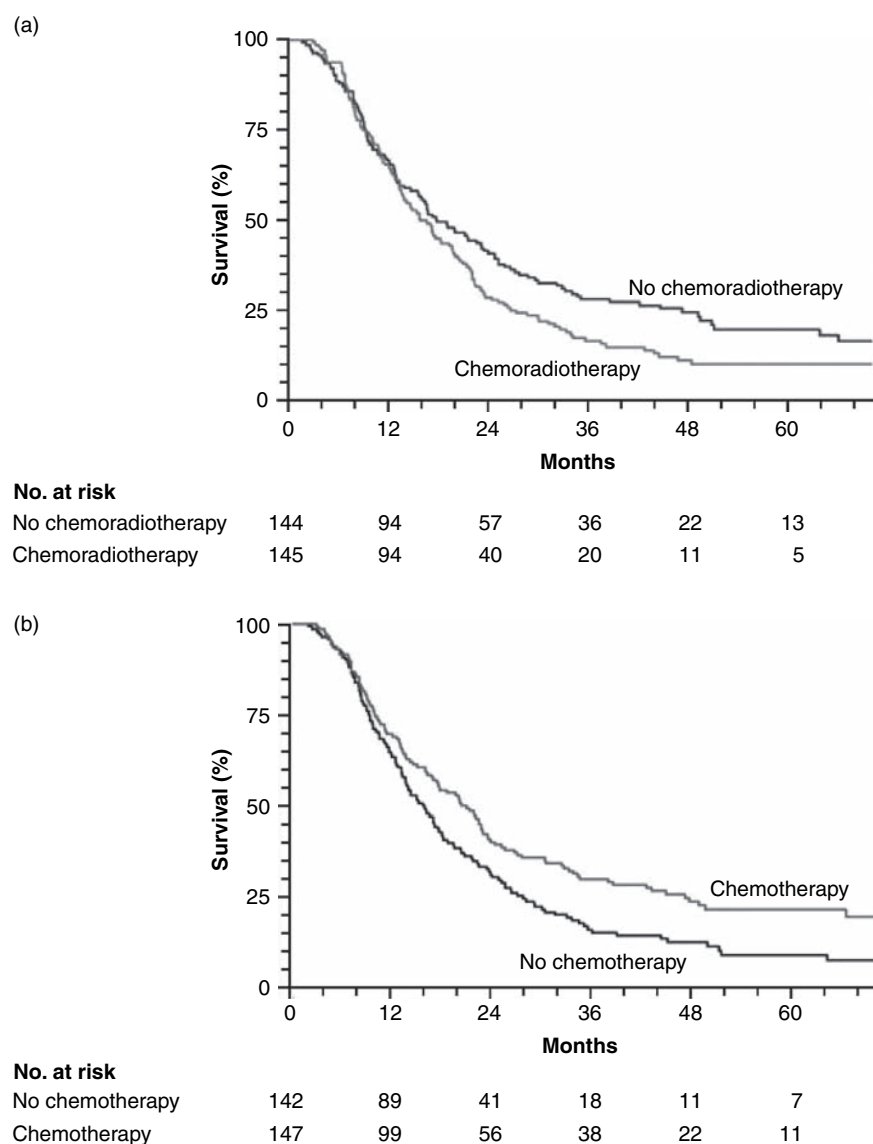
Several reports have appeared which discuss the indications to perform a pancreaticoduodenectomy as a palliative treatment option. This controversial question results from the observation in recent literature that morbidity and mortality rates after pancreaticoduodenectomy are decreasing. Three studies retrospectively investigated the role of a pancreaticoduodenectomy for palliation by comparing the outcome of non-radical resections with the outcome of patients who underwent a single or double bypass for a locally invasive tumor without metastases<sup>100–102</sup>. Results show that a pancreaticoduodenectomy can be performed with similar mortality and morbidity rates, and hospital stay, compared with a palliative bypass. Remarkably, the survival after a palliative resection is significantly longer than after bypass. This difference is probably due to patient selection and the limited comparability of the two groups. The available data confirm that, in the case of questionable radical resectability, a resection can offer relatively good palliation; so a more aggressive approach could be advocated in patients with a doubtful resectable tumor<sup>103</sup>. The use of diagnostic laparoscopy has also introduced the minimal invasive approach for subsequent palliation if metastases or local ingrowth of tumors are found. The procedures include palliation of obstructive jaundice by cholecystojejunostomy or choledochojejunostomy and

GOO by a gastroenterostomy. The available data show that the laparoscopic double bypass can be performed safely, with acceptable morbidity and low mortality. However, the long-term follow-up concerning recurrent jaundice and GOO is only highlighted briefly in these studies<sup>104</sup>.

### NEOADJUVANT AND ADJUVANT THERAPY

The prognosis of patients with pancreatic cancer is poor even in the selected group of patients who underwent resection. Adjuvant therapy by chemoradiotherapy has therefore been investigated in a number of clinical trials with conflicting results. In a study by the Gastrointestinal Tumor Study Group (GITSG) chemoradiotherapy after resection was compared with resection alone<sup>105</sup>. After inclusion of 32 patients this trial was closed because of a better survival observed in the arm with adjuvant chemoradiotherapy. Despite the fact that statistical significance was not reached, adjuvant chemoradiotherapy is considered standard after resection of pancreatic adenocarcinomas in the US. Furthermore, in a European (EORTC) study a non-significant advantage of postoperative chemoradiotherapy was found after subgroup analysis for pancreatic cancer<sup>106</sup>. In a critical review the authors suggested that chemoradiotherapy should be evaluated further. A Japanese study, however, did not show a survival benefit<sup>107</sup>. More recently the results of the European Study Group for Pancreatic Cancer (ESPAC)-1 trial were published<sup>108,109</sup>. In a two-by-two multifactorial design a survival benefit for patients treated with adjuvant chemotherapy (5-FU-leucovorin) versus no chemotherapy of 20.1 versus 15.5 months was shown (Figure 17.5). Besides this a detrimental effect on survival of chemoradiotherapy was found. Comments concerning this trial included the outdated split course radiotherapy used and poor quality control of the radiotherapy<sup>110,111</sup>.

After the controversial results of the ESPAC-1 trial, the CONKO-001 study finally brought more clarity about the role of chemotherapy in the adjuvant setting<sup>112</sup>. This study compared the effect of gemcitabine versus observation only on the duration of disease-free survival in 368 patients with resected pancreatic carcinoma. An improvement of median disease-free survival was observed (12.9 vs. 8.0 months). Improvement was seen in all subgroups including microscopic non-radical resection and tumor positive lymph nodes in the surgical specimen. Because of these relatively favorable results of adjuvant chemotherapy with gemcitabine this treatment option should be considered in patients with resected pancreatic adenocarcinoma, although long-term overall survival data still have to be published.



**Figure 17.5** Kaplan–Meier estimates of survival according to whether or not patients received (a) chemoradiotherapy or (b) chemotherapy for European Study Group for Pancreatic Cancer-1 two-by-two factorial design cohort. Adapted from reference 109.

## PALLIATIVE CHEMOTHERAPY AND RADIOTHERAPY

In non-metastatic locally advanced pancreatic cancer, several phase II studies have investigated the role of radiotherapy. With modern conformal radiotherapy high doses, up to 72 Gy, can be delivered without unacceptable toxicity<sup>113</sup>. Although pain relief is often achieved, overall results are usually disappointing. Median survival times are reported to be between 5.5 and 11 months. Whether radiotherapy is superior to an expectant policy is not clear. Pain relief may be the only advantage<sup>114</sup>. Combined chemoradiotherapy has also been investigated in locally advanced pancreatic cancer. Infusion of 5-FU in addition

to radiotherapy is the most commonly used multimodality treatment. Slightly better median survival times than those described with radiotherapy alone have been reported in literature (7–16 months). The GITSG performed a trial in which radiotherapy with 5-FU was superior to radiotherapy alone<sup>115</sup>. Recently the efficacy of gemcitabine, known to be a potent enhancer of tumor radioresponse *in vitro*, has been investigated<sup>116</sup>. A real improvement in the results with this combination has not been observed, however. Because of the only limited benefit for patients, the burden of treatment with chemoradiotherapy must be weighed against it.

In the setting of metastatic pancreatic cancer, gemcitabine is considered to be standard chemotherapy.



After intracellular conversion in active metabolites, it blocks DNA synthesis by interference with RNA-reductase. Besides this the incorporation in cellular DNA blocks further DNA synthesis. Gemcitabine was superior to 5-FU in a randomized trial<sup>112</sup>. It showed a modest gain in median overall survival (5.7 vs. 4.2 months). Moreover, the 1-year survival probability was 18% for gemcitabine versus 2% for 5-FU, and a clinical benefit response (score for improvement in cancer-related symptoms) of 24% was reported for gemcitabine versus 5% for 5-FU. After this, gemcitabine was combined with other cytotoxic drugs in clinical trials. Only the combination with oxaliplatin showed a significant improvement in progression-free survival and response rate; however, without a beneficial effect on median overall survival<sup>117</sup>.

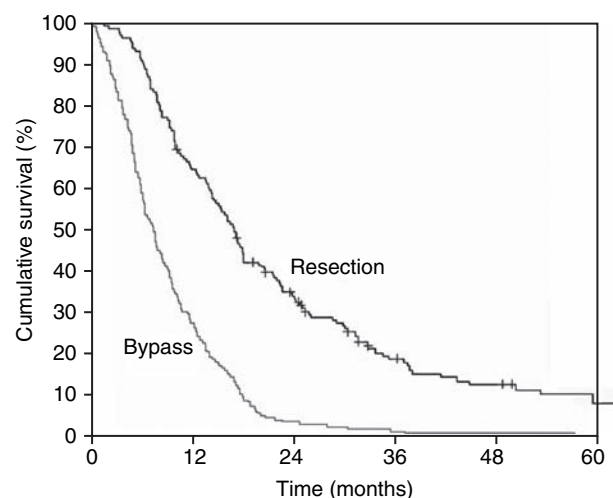
Recently, increasing knowledge of the molecular properties that characterize pancreatic cancer has created new opportunities for therapeutic intervention. Several molecular alterations, for example growth factor receptors, angiogenic factors and other signaling molecules that cause this disease have been identified and can now be exploited for therapy<sup>118</sup>. To date, it is unclear what will be the therapeutic gain of novel targeted drugs in pancreatic cancer. Their efficacy has been shown in several other forms of cancer<sup>119,120</sup>. Even in the setting of highly therapy-resistant pancreatic adenocarcinoma a very interesting observation has been made. In a randomized trial comparing gemcitabine with placebo and gemcitabine with the epidermal growth factor receptor (EGFR) blocking agent, erlotinib, a very modest gain in overall survival was found (5.9 vs 6.4 months) in favor of the combination of gemcitabine with the targeted drug erlotinib. However, when the patients treated with erlotinib who developed a significant form of skin rash, which is a well known side-effect of erlotinib, were compared with patients who did not experience this adverse event a striking difference in median survival was found: 10.5 months for patients with rash compared with 5.3 months for patients not experiencing this rash. Furthermore, a 1-year survival probability of 43% versus 11% in favor of patients with this side-effect was shown<sup>121</sup>. This observation supports the hypothesis that this new class of cancer drugs could earn a place in systemic pancreatic cancer treatment in the future<sup>118</sup>.

## OUTCOME

Survival has been the traditional endpoint after treatment for pancreatic and ampullary cancer in most studies. More recently clinical benefit response and quality of life have been generally accepted as other important endpoints in particular after palliative therapy. The survival rate after

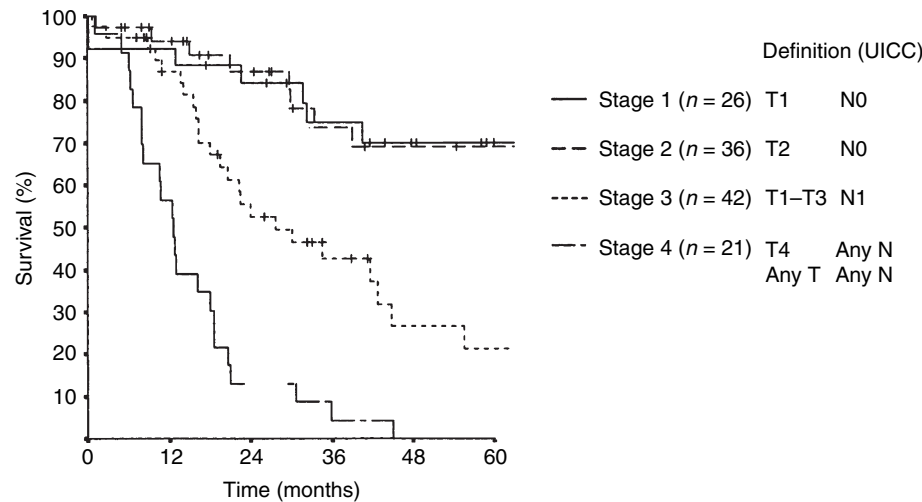
resection without adjuvant therapy has been reported to be between 8% and 35% for pancreatic cancer and between 25% and 50% after ampullary cancer mainly depending patient selection (inclusion criteria) and follow-up period<sup>4,5,105–111</sup>. The majority of patients will have recurrence or metastases within 5 years and the disappointing survival curve of the AMC series reporting an actuarial 5-year survival of only 8% is shown in Figure 17.6<sup>4</sup>. Prognostic factors for survival are radical (R0) resection, type of tumor ampullary lesions (Figure 17.7), lymph node involvement, and in a few studies blood transfusion, surgery in experienced center and higher socioeconomic status. The most important survival curves of the ESPAC-1 study reporting survival after adjuvant chemo- and chemoradiotherapy are shown in Figure 17.5<sup>108,109</sup>.

Another important outcome is the quality of life after resection as well as after palliative treatment and a recent study analyzed quality of life longitudinally after both procedures. Quality of life deteriorated temporarily after surgery but was restored to preoperative levels within 6 weeks (Figure 17.8). Even patients with palliative bypass surgery did well until the last 6 weeks before death as shown by weekbooks (Figure 17.9)<sup>122</sup>. Improvement of quality of life and clinical benefit response were also shown after palliative chemotherapy as well as prolonged survival. Despite recent improvements in survival and quality of life in patients with pancreatic and ampullary cancer after surgical treatment and/or chemotherapy, the overall prognosis for the majority of patients remains poor, and the challenge will be to find tools that help to select the patients that will benefit most from these new drugs in combination with surgical resection.

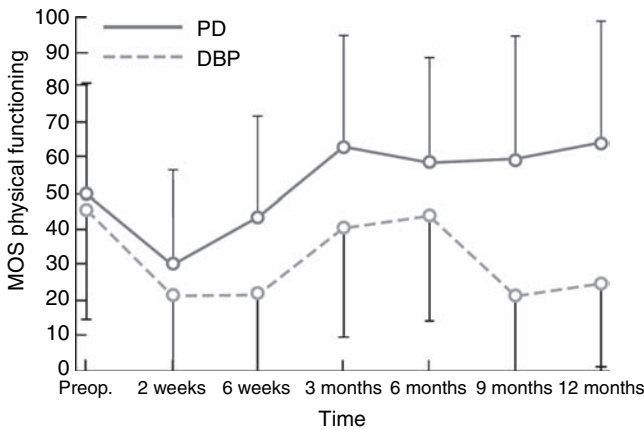


**Figure 17.6** Kaplan-Meier survival curves of patients who underwent a resection ( $n = 160$ ) or a palliative bypass ( $n = 183$ ) between 1992 and 2002. The median survival after resection and bypass was 17.0 and 7.5 months, respectively ( $p < 0.01$ ). Adapted from reference 4.

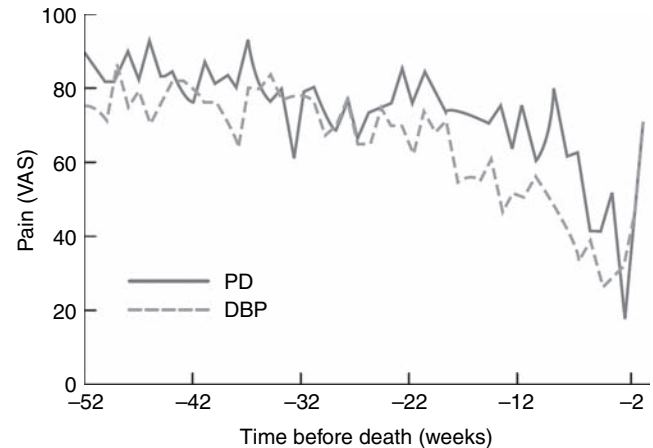




**Figure 17.7** Overall actuarial survival curve for patients with adenocarcinoma of the ampulla after resection according to the International Union Against Cancer (UICC) stage. Adapted from reference 5.



**Figure 17.8** Medical Outcomes Study (MOS) physical functioning scores after pylorus-preserving pancreatoduodenectomy (PD) and palliative double-bypass procedure (DBP) for pancreatic or periampullary carcinoma. Adapted from reference 122.



**Figure 17.9** Pain scores measured on a visual analog scale (VAS) in the terminal phase of illness after pancreatoduodenectomy (PD) and palliative double-bypass procedure (DBP) for pancreatic or periampullary carcinoma. Adapted from reference 122.

## REFERENCES

1. Parkin DM, Bray F, Ferlay J, Pisani P. Global cancer statistics 2002. *CA Cancer J Clin* 2005; 55: 74–108.
2. Lowenfels AB, Maisonneuve P. Epidemiology and risk factors for pancreatic cancer. *Best Pract Res Clin Gastroenterol* 2006; 20: 197–209.
3. Gudjonsson B. Carcinoma of the pancreas: critical analysis of costs, results of resections, and the need for standardized reporting. *J Am Coll Surg* 1995; 181: 483–503.
4. Kuhlmann KF, De Castro SM, Wessling JC et al. Surgical treatment of pancreatic adenocarcinoma; actual survival and prognostic factors in 343 patients. *Eur J Cancer* 2004; 40: 549–58.
5. De Castro SM, Van Heek NT, Kuhlmann KF et al. Surgical management of neoplasms of the ampulla of Vater: local resection or pancreatoduodenectomy and prognostic factors for survival. *Surgery* 2004; 136: 994–1002.
6. Klein WM, Hruban RH, Klein-Szanto AJ, Wilentz RE. Direct correlation between proliferative activity and dysplasia in pancreatic intraepithelial neoplasia (PanIN): additional evidence for a recently proposed model of progression. *Mod Pathol* 2002; 15: 441–7.
7. Maitra A, Kern SE, Hruban RH. Molecular pathogenesis of pancreatic cancer. *Best Pract Res Clin Gastroenterol* 2006; 20: 211–26.
8. Yan L, McFaul C, Howes N et al. Molecular analysis to detect pancreatic ductal adenocarcinoma in high-risk groups. *Gastroenterology* 2005; 128: 2124–30.

9. Vitone LJ, Greenhalf W, McFaul CD et al. The inherited genetics of pancreatic cancer and prospects for secondary screening. *Best Pract Res Clin Gastroenterol* 2006; 20: 253–83.
10. Huxley R, Ansary-Moghaddam A, Berrington DG et al. Type-II diabetes and pancreatic cancer: a meta-analysis of 36 studies. *Br J Cancer* 2005; 92: 2076–83.
11. Rosty C, Goggins M. Early detection of pancreatic carcinoma. *Hematol Oncol Clin North Am* 2002; 16: 37–52.
12. Sturm PD, Hruban RH, Ramsioek TB et al. The potential diagnostic use of K-ras codon 12 and p53 alterations in brush cytology from the pancreatic head region. *J Pathol* 1998; 186: 247–53.
13. Hohl C, Schmidt T, Haage P et al. Phase-inversion tissue harmonic imaging compared with conventional B-mode ultrasound in the evaluation of pancreatic lesions. *Eur Radiol* 2004; 14: 1109–17.
14. Kitano M, Kudo M, Maekawa K et al. Dynamic imaging of pancreatic diseases by contrast enhanced coded phase inversion harmonic ultrasonography. *Gut* 2004; 53: 854–9.
15. Tillemann EH, Benraadt J, Bossuyt PM et al. [Diagnosis and treatment of pancreatic carcinoma in the region of Amsterdam Comprehensive Cancer Care Center in 1997]. *Ned Tijdschr Geneesk* 2001; 145: 1358–62. [in Dutch]
16. Bronstein YL, Loyer EM, Kaur H et al. Detection of small pancreatic tumors with multiphasic helical CT. *AJR Am J Roentgenol* 2004.
17. Michl P, Pauls S, Gress T. Evidence-based diagnosis and staging of pancreatic cancer. *Best pract Res Clin Gastroenterol* 2006; 20: 227–51.
18. Bipat S, Phoa SS, Van Delden OM et al. Ultrasonography, computed tomography and magnetic resonance imaging for diagnosis and determining resectability of pancreatic adenocarcinoma: a meta-analysis. *J Comput Assist Tomogr* 2005; 29: 438–45.
19. Hunt GC, Faigel DO. Assessment of EUS for diagnosing, staging, and determining resectability of pancreatic cancer: a review. *Gastrointest Endosc* 2002; 55: 232–7.
20. Van Gulik TM, Reeders JW, Bosma A et al. Incidence and clinical findings of benign, inflammatory disease in patients resected for presumed pancreatic head cancer. *Gastrointest Endosc* 1997; 46: 417–23.
21. Phoa SS, Reeders JW, Stoker J et al. CT criteria for venous invasion in patients with pancreatic head carcinoma. *Br J Radiol* 2000; 73: 1159–64.
22. McMahon PM, Halpern EF, Fernandez-del Castillo C et al. Pancreatic cancer: cost-effectiveness of imaging technologies for assessing resectability. *Radiology* 2001; 221: 93–106.
23. Phoa SS, Tillemann EH, Van Delden OM et al. Value of CT criteria in predicting survival in patients with potentially resectable pancreatic head carcinoma. *J Surg Oncol* 2005; 91: 33–40.
24. Lillemoe KD, Cameron JL, Yeo CJ et al. Pancreaticoduodenectomy. Does it have a role in the palliation of pancreatic cancer? *Ann Surg* 1996; 223: 718–25 discussion 725–8.
25. Kuhlmann K, De Castro S, Van Heek T et al. Microscopically incomplete resection offers acceptable palliation in pancreatic cancer. *Surgery* 2006; 139: 188–96.
26. Shimada K, Kosuge T, Yamamoto J et al. Successful outcome after resection of pancreatic cancer with a solitary hepatic metastasis. *Hepatogastroenterology* 2004; 51: 603–5.
27. Takada T, Yasuda H, Amano H et al. Simultaneous hepatic resection with pancreaticoduodenectomy for metastatic pancreatic head carcinoma: does it improve survival? *Hepatogastroenterology* 1997; 44: 567–73.
28. Pakzad F, Groves AM, Ell PJ. The role of positron emission tomography in the management of pancreatic cancer. *Semin Nucl Med* 2006; 36: 248–56.
29. Warshaw AL, Tepper JE, Shipley WU. Laparoscopy in the staging and planning of therapy for pancreatic cancer. *Am J Surg* 1986; 151: 76–80.
30. Bemelman WA, De Wit LD, Van Delden OM et al. Diagnostic laparoscopy combined with laparoscopic ultrasonography in staging of cancer of the pancreatic head region. *Br J Surg* 1995; 82: 820–4.
31. Pisters PW, Lee JE, Vauthey JN et al. Laparoscopy in the staging of pancreatic cancer. *Br J Surg* 2001; 88: 325–37.
32. Friess H, Kleeff J, Silva JC et al. The role of diagnostic laparoscopy in pancreatic and periampullary malignancies. *J Am Coll Surg* 1998; 186: 675–82.
33. Nieveen van Dijkum EJ, Romijn MG, Terwee CB et al. Laparoscopic staging and subsequent palliation in patients with periampullary carcinoma. *Ann Surg* 2003; 237: 66–73.
34. Tillemann EH, Kuiken BW, Phoa SS et al. Limitation of diagnostic laparoscopy for patients with a periampullary carcinoma. *Eur J Surg* 2004; 30: 658–62.
35. Tillemann EH, Busch OR, Bemelman WA et al. Diagnostic laparoscopy in staging pancreatic carcinoma: developments during the past decade. *J Hepatobiliary Pancreat Surg* 2004; 11: 11–6.
36. Kimmings AN, Van Deventer SJ, Obertop H et al. Inflammatory and immunologic effects of obstructive jaundice: pathogenesis and treatment. *J Am Coll Surg* 1995; 181: 567–81.
37. Sewnath ME, Birjmohun RS, Rauws EA et al. The effect of preoperative biliary drainage on postoperative complications after pancreaticoduodenectomy. *J Am Coll Surg* 2001; 192: 726–34.
38. Sohn TA, Yeo CJ, Cameron JL et al. Do preoperative biliary stents increase postpancreaticoduodenectomy complications? *J Gastrointest Surg* 2000; 4: 258–67 discussion 267–8.
39. Povoski SP, Karpeh MS Jr, Conlon KC et al. Association of preoperative biliary drainage with postoperative outcome following pancreaticoduodenectomy. *Ann Surg* 1999; 230: 131–42.
40. Sewnath ME, Karsten ThM, Prins MH et al. A meta-analysis on the efficacy of preoperative biliary drainage for tumours causing obstructive jaundice. *Ann Surg* 2002; 236: 17–27 (review).
41. Isenberg G, Gouma DJ, Pisters PW. The on-going debate about perioperative biliary drainage in jaundiced patients undergoing pancreaticoduodenectomy. *Gastrointest Endosc* 2002; 56: 310–5.
42. www.hopkinsgi.
43. Lillemoe KD, Cameron JL. Pancreatic procedures. In: *Alimentary tract and abdomen. ACS Surgery: Principles and Practice*, 2002.
44. Pedrazzoli S, Beger H, Obertop H et al. A surgical and pathological based classification of resection of pancreatic cancer: summary of an international workshop on surgical procedures in pancreatic cancer. *Dig Surg* 1999; 16: 337–45.
45. Tran KT, Smeenk HG, Van Eijck CH et al. Pylorus preserving pancreaticoduodenectomy versus standard Whipple procedure: a prospective, randomized, multicenter analysis of 170 patients with pancreatic and periampullary tumors. *Ann Surg* 2004; 240: 738–45.
46. Seiler CA, Wagner M, Sadowski C et al. Randomized prospective trial of pylorus-preserving vs. Classic duodenopancreatectomy (Whipple procedure): initial clinical results. *J Gastrointest Surg* 2000; 4: 443–52.
47. Seiler CA, Wagner M, Bachmann T et al. Randomized clinical trial of pylorus-preserving duodenopancreatectomy versus

- classical Whipple resection-long term results. *Br J Surg* 2005; 92: 547–56.
48. Lin PW, Shan YS, Lin YJ, Hung CJ. Pancreaticoduodenectomy for pancreatic head cancer: PPPD versus Whipple procedure. *Hepatogastroenterology* 2005; 52: 1601–4.
  49. Ishikawa O, Ohhigashi H, Sasaki Y et al. Practical usefulness of lymphatic and connective tissue clearance for the carcinoma of the pancreas head. *Ann Surg* 1988; 208: 215–20.
  50. Pedrazzoli S, DiCarlo V, Dionigi R et al. Standard versus extended lymphadenectomy associated with pancreatoduodenectomy in the surgical treatment of adenocarcinoma of the head of the pancreas: a multicenter, prospective, randomized study. Lymphadenectomy Study Group. *Ann Surg* 1998; 228: 508–17.
  51. Farnell MB, Pearson RK, Sarr MG et al. A prospective randomized trial comparing standard pancreatoduodenectomy with pancreatoduodenectomy with extended lymphadenectomy in resectable pancreatic head adenocarcinoma. *Surgery* 2005; 138: 618–28 discussion 628–30.
  52. Yeo CJ, Cameron JL, Sohn TA et al. Pancreaticoduodenectomy with or without extended retroperitoneal lymphadenectomy for periaampullary adenocarcinoma: comparison of morbidity and mortality and short-term outcome. *Ann Surg* 1999; 229: 613–22 discussion 622–14.
  53. Yeo CJ, Cameron JL, Lillemoe KD et al. Pancreaticoduodenectomy with or without distal gastrectomy and extended retroperitoneal lymphadenectomy for periaampullary adenocarcinoma, part 2: randomized controlled trial evaluating survival, morbidity, and mortality. *Ann Surg* 2002; 236: 355–66 discussion 366–8.
  54. Riall TS, Cameron JL, Lillemoe KD et al. Pancreaticoduodenectomy with or without distal gastrectomy and extended retroperitoneal lymphadenectomy for periaampullary adenocarcinoma – part 3: update on 5-year survival. *J Gastrointest Surg* 2005; 9: 1191–204 discussion 1204–6.
  55. Nimura Y, Nagino M, Kato H et al. Regional versus extended lymph node dissection in radical pancreaticoduodenectomy for pancreatic cancer: a multicenter, randomized controlled trial. *HPB* 2004; 6: 2.
  56. Howard TJ, Villanustre N, Moore SA et al. Efficacy of venous reconstruction in patients with adenocarcinoma of the pancreatic head. *J Gastrointest Surg* 2003; 7: 1089–95.
  57. Van Geenen RC, Ten Kate FJ, De Wit LT et al. Segmental resection and wedge excision of the portal or superior mesenteric vein during pancreatoduodenectomy. *Surgery* 2001; 129: 158–63.
  58. Tseng JF, Tamm EP, Lee JE et al. Venous resection in pancreatic cancer surgery. *Best Pract Res Clin Gastroenterol* 2006; 20: 349–64.
  59. Fujino Y, Suzuki Y, Yoshikawa T et al. Outcomes of surgery for intraductal papillary mucinous neoplasms of the pancreas. *World J Surg* 2006; 30: 1909–14.
  60. Strasberg SM, Drebin JA, Linehan D. Radical antegrade modular pancreatosplenectomy. *Surgery* 2003; 133: 521–7.
  61. Shimada K, Sakamoto Y, Sano T, Kosuge T. Prognostic factors after distal pancreatectomy with extended lymphadenectomy for invasive pancreatic adenocarcinoma of the body and tail. *Surgery* 2006; 139: 288–95.
  62. Suc B, Msika S, Piccinini M et al. Octreotide in the prevention of intra-abdominal complications following elective pancreatic resection: a prospective multicenter randomized controlled trial. *Arch Surg* 2004; 139: 288–94.
  63. Yeo CJ, Cameron JL, Lillemoe KD et al. Does prophylactic octreotide decrease the rates of pancreatic fistula and other complications after pancreaticoduodenectomy? Results of a prospective randomized placebo-controlled trial. *Ann Surg* 2000; 232: 419–29.
  64. Connor S, Alexakis N, Garden OJ et al. Meta-analysis of the value of somatostatin and its analogues in reducing complications associated with pancreatic surgery. *Br J Surg* 2005; 92: 1059–67.
  65. Cameron JL, Pitt HA, Yeo CJ et al. One-hundred and forty-five consecutive pancreaticoduodenectomies without mortality. *Ann Surg* 1993; 217: 430–8.
  66. Cameron JL, Riall TS, Coleman JRN, Belcher KA. One thousand consecutive pancreaticoduodenectomies. *Ann Surg* 2006; 244: 10–5.
  67. Gouma DJ, Van Geenen RC, Van Gulik TM et al. Rates of complications and death after pancreaticoduodenectomy: risk factors and the impact of hospital volume. *Ann Surg* 2000; 232: 786–95.
  68. Bassi C, Dervenis C, Butcherini G et al. International Study Group on Pancreatic Fistula Definition. Postoperative pancreatic fistula: an international study group (ISGPF) definition. *Surgery* 2005; 138: 8–13.
  69. Langrehr JM, Bahra M, Jacob D et al. *World J Surg* 2005; 29: 1111–9 discussion 1120–21.
  70. Wagner M, Redaelli C, Lietz M et al. Curative resection is the single most important factor determining outcome in patients with pancreatic adenocarcinoma. *Br J Surg* 2004; 91: 586–94.
  71. Oussoultzoglou E, Bachellier P, Bigourdan JM et al. Pancreaticogastrostomy decreased relaparotomy caused by pancreatic fistula after pancreaticoduodenectomy compared with pancreaticojejunostomy. *Arch Surg* 2004; 139: 327–35.
  72. Takano S, Ito Y, Watanabe Y et al. Pancreaticojejunostomy versus pancreaticogastrostomy in reconstruction following pancreaticoduodenectomy. *Br J Surg* 2000; 87: 423–7.
  73. Yeo CJ, Cameron JL, Maher MM et al. A prospective randomized trial of pancreaticogastrostomy versus pancreaticojejunostomy after pancreaticoduodenectomy. *Ann Surg* 1995; 222: 580–8 discussion 771–73.
  74. Bassi C, Falconi M, Molinari E et al. Reconstruction by pancreaticojejunostomy versus pancreaticogastrostomy following pancreatectomy: results of a comparative study. *Ann Surg* 2005; 242: 767–71 discussion 771–73.
  75. Duffas JP, Suc B, Msika S et al. French Associations for Research in Surgery. *Am J Surg* 2005; 189: 720–9.
  76. De Castro SM, Kuhlmann KF, Busch OR et al. Delayed massive hemorrhage after pancreatic and biliary surgery: embolization or surgery? *Ann Surg* 2005; 241: 85–91. Comment in *Ann Surg* 2006; 243: 138–9; author reply 139.
  77. De Castro SM, Kuhlmann KF, Busch OR et al. Incidence and management of biliary leakage after hepaticojejunostomy. *J Gastrointest Surg* 2005; 9: 1163–71.
  78. De Castro SM, Busch OR, Van Gulik TM et al. Incidence and management of pancreatic leakage after pancreatoduodenectomy. *Br J Surg* 2005; 92: 1117–23.
  79. Van Berge Henegouwen MI, Van Gulik TM, De Wit LT et al. Delayed gastric emptying after standard pancreaticoduodenectomy versus pylorus-preserving pancreaticoduodenectomy: an analysis of 200 consecutive patients. *J Am Coll Surg* 1997; 185: 373–9.
  80. Tani M, Terasawa H, Kawai M et al. Improvement of delayed gastric emptying in pylorus-preserving pancreaticoduodenectomy: results of a prospective, randomized, controlled trial. *Ann Surg* 2006; 243: 316–20.
  81. Lieberman MD, Kilburn H, Lindsey M, Brennan MF. Relation of perioperative deaths to hospital volume among patients undergoing pancreatic resection for malignancy. *Ann Surg* 1995; 222: 638–45.

82. Gordon TA, Bowman HM, Tielsch JM et al. Statewide regionalization of pancreaticoduodenectomy and its effect on in-hospital mortality. *Ann Surg* 1998; 228: 71–8.
83. Birkmeyer JD, Siewers AE, Finlayson EV et al. Hospital volume and surgical mortality in the United States. *N Engl J Med* 2002; 346: 1128–37.
84. Birkmeyer JD, Finlayson SG, Tosteson AA et al. Effect of hospital volume on in-hospital mortality with pancreaticoduodenectomy. *Surgery* 1999; 125: 250–6.
85. Van Heek NT, Kuhlmann KF, Scholten RJ et al. Hospital volume and mortality after pancreatic resection: a systematic review and an evaluation of intervention in the Netherlands. *Ann Surg* 2005; 242: 781–8 discussion 788–90.
86. World Health Organization. National Cancer Control Programmes: policies and managerial guidelines. 2002.
87. Abraham NS, Barkun JS, Barkun AN. Palliation of malignant biliary obstruction: a prospective trial examining impact on quality of life. *Gastrointest Endosc* 2002; 56: 835–41.
88. Davids PH, Groen AK, Rauws EA et al. Randomised trial of self-expanding metal stents versus polyethylene stents for distal malignant biliary obstruction. *Lancet* 1992; 340: 1488–92.
89. Kaassis M, Boyer J, Dumas R et al. Plastic or metal stents for malignant stricture of the common bile duct? Results of a randomized prospective study. *Gastrointest Endosc* 2003; 57: 178–82.
90. Bornmann PC, Harries-Jones EP, Tobias R et al. Prospective controlled trial of transhepatic biliary endoprosthesis versus bypass surgery for incurable carcinoma of head of pancreas. *Lancet* 1986; 1: 69–71.
91. Shepherd HA, Royle G, Ross AP et al. Endoscopic biliary endoprosthesis in the palliation of malignant obstruction of the distal common bile duct: a randomized trial. *Br J Surg* 1988; 75: 1166–8.
92. Andersen JR, Sorensen SM, Kruse A et al. Randomised trial of endoscopic endoprosthesis versus operative bypass in malignant obstructive jaundice. *Gut* 1989; 30: 1132–5.
93. Smith AC, Dowsett JF, Russell RC et al. Randomised trial of endoscopic stenting versus surgical bypass in malignant low bile duct obstruction. *Lancet* 1994; 344: 1655–60.
94. Taylor MC, McLeod RS, Langer B. Biliary stenting versus bypass surgery for the palliation of malignant distal bile duct obstruction: a meta-analysis. *Liver Transpl* 2000; 6: 302–8.
95. Telford JJ, Carr-Locke DL, Baron TH et al. Palliation of patients with malignant gastric outlet obstruction with the enteral Wallstent: outcome from a multicenter study. *Gastrointest Endosc* 2004; 60: 916–20.
96. Lillemoe KD, Cameron JL, Hardacre JM et al. Is prophylactic gastrojejunostomy indicated for unresectable periampullary cancer? A prospective randomized trial. *Ann Surg* 1999; 230: 322–8.
97. Heek NT van, de Castro SM, van Eijck CH et al. The need for a prophylactic gastrojejunostomy for unresectable periampullary cancer: a prospective randomized multicenter trial with special focus on assessment of quality of life. *Ann Surg* 2003; 238: 894–902.
98. Wong GY, Schroeder DR, Corns PE et al. Effect of neurolytic celiac plexus block on pain relief, quality of life, and survival in patients with unresectable pancreatic cancer: a randomized controlled trial. *JAMA* 2004; 291: 1092–9.
99. Lillemoe KD, Cameron JL, Kaufman HS et al. Chemical splanchnicectomy in patients with unresectable pancreatic cancer. A prospective randomized trial. *Ann Surg* 1993; 217: 447–55.
100. Reinders ME, Allema JH, van Gulik TM et al. Outcome of microscopically nonradical, subtotal pancreaticoduodenectomy (Whipple's resection) for treatment of pancreatic head tumors. *World J Surg* 1995; 19: 410–4.
101. Gouma DJ, van Dijkum EJ, van Geenen RC et al. Are there indications for palliative resection in pancreatic cancer? *World J Surg* 1999; 23: 954–9.
102. Kuhlmann K, de Castro S, van Heek T et al. Microscopically incomplete resection offers acceptable palliation in pancreatic cancer. *Surgery* 2006; 139: 188–96.
103. Lillemoe KD, Cameron JL, Yeo CJ et al. Pancreaticoduodenectomy. Does it have a role in the palliation of pancreatic cancer? *Ann Surg* 1996; 223: 718–25.
104. Kuriansky J, Saenz A, Astudillo E et al. Simultaneous laparoscopic biliary and retrocolic gastric bypass in patients with unresectable carcinoma of the pancreas. *Surg Endosc* 2000; 14: 179–81.
105. Gastrointestinal Tumor Study Group. Further evidence of effective adjuvant combined radiation and chemotherapy following curative resection of pancreatic cancer. *Cancer* 1987; 59: 2006–10.
106. Klinkenbijl JH, Jeekel J, Sahmoud T et al. Adjuvant radiotherapy and 5-fluorouracil after curative resection of cancer of the pancreas and periampullary region. Phase III trial of the EORTC GITCCG. *Ann Surg* 1999; 230: 776–84.
107. Takada T, Amano H, Yasuda H et al. Is postoperative adjuvant chemotherapy useful for gall-bladder carcinoma? *Cancer* 2002; 95: 1658.
108. Neoptolemos JP, Dunn JA, Stocken DD et al. Adjuvant chemoradiotherapy and chemotherapy in resectable pancreatic cancer: a randomised controlled trial. *Lancet* 2001; 358: 1576–85.
109. Neoptolemos JP, Stocken DD, Friess H et al. A randomized trial of chemoradiotherapy and chemotherapy after resection of pancreatic cancer. *N Engl J Med* 2004; 350: 1200–10.
110. Stocken DD, Büchler MW, Dervenis C et al. Meta-analysis of randomised adjuvant therapy trials for pancreatic cancer. *Br J Cancer* 2005; 92: 1372–81.
111. Chua YJ, Cunningham D. Adjuvant treatment for respectable pancreatic cancer. *J Clin Oncol* 2005; 23: 4532–7.
112. Burris HA III, Moore MJ, Andersen J et al. Improvements in survival and clinical benefit with gemcitabine as first-line therapy for patients with advanced pancreas cancer: a randomized trial. *J Clin Oncol* 1997; 15: 2403–13.
113. Ceha HM, Van Tienhoven G, Gouma DJ et al. Feasibility and efficacy of high dose conformal radiotherapy for locally advanced pancreatic cancer. *Cancer* 2000; 89: 2222–9.
114. Van Geenen RC, Keyzer-Dekker CM, Van Tienhoven G et al. Pain management of patients with unresectable peripancreatic carcinoma. *World J Surg* 2002; 26: 715–20.
115. Moertel CG, Frytak S, Hahn RG et al. Therapy of locally unresectable pancreatic carcinoma: a randomised comparison of high dose (6000 rads) radiation alone, moderate dose radiation (4000 rads + 5 fluorouracil) and high dose radiation + 5 fluorouracil. The Gastrointestinal Tumor Studygroup. *Cancer* 1981; 48: 1705–10.
116. De Lange SM, Van Groeningen CJ, Meijer OW et al. Gemcitabine-radiotherapy in patients with locally advanced pancreatic cancer. *Eur J Cancer* 2002; 38: 1212–17.
117. Louvet C, Labianca R, Hammel P et al. Gemcitabine in combination with oxaliplatin compared with gemcitabine alone in locally advanced or metastatic pancreatic cancer: Results of a GERCOR and GISCAD phase III trial. *J Clin Oncol* 2005; 23: 3509–16.
118. Von Hoff DD. What's new in pancreatic cancer treatment pipeline? *Best Pract Res Clin Gastroenterol* 2006; 20: 315–26.

119. Hurwitz H, Fehrenbacher L, Novotny W et al. Bevacizumab plus irinotecan, fluorouracil and leucovorin for metastatic cancer. *N Engl J Med* 2004; 350: 2335–42.
120. Piccart-Gebhart MJ, Procter M, Leyland-Jones B et al. Trastuzumab after adjuvant chemotherapy in HER2-positive breast cancer. *N Engl J Med* 2005; 353: 1659–72.
121. Moore MJ, Goldstein D, Hamm J et al. Erlotinib plus gemcitabine compared to gemcitabine alone in patients with advanced pancreatic cancer. A phase III trial of the National Cancer Institute of Canada Clinical Trials Group (NCIC-CTG). NCIC-CTG. Proceedings ASCO 2005: abstr1.
122. Nieveen van Dijkum EJ, Kuhlmann KF, Terwee CB et al. Quality of life after curative or palliative surgical treatment of pancreatic and periampullary carcinoma. *Br J Surg* 2005; 92: 471–7.  
Neuhaus P, Oettle H, Post S et al. A randomised, prospective, multicenter, phase III trial of adjuvant chemotherapy with gemcitabine vs observation in patients with resected pancreatic cancer. 2005 ASCO Annual Meeting Proceedings. 2005: abstr LBA4013.

Dario Ribero, Eddie K Abdalla and Jean-Nicolas Vauthey

---

## INTRODUCTION

Hepatocellular carcinoma (HCC) is the fifth most common neoplasm worldwide; as many as 600 000 new cases are diagnosed annually. Although HCC is less prevalent in most parts of the developed Western world than in the East, recent epidemiological data indicate that the incidence is steadily rising. In the US, the incidence of HCC doubled between 1975 and 1998, coincident with the spread of hepatitis C virus (HCV) infection<sup>1</sup>.

HCC is associated with HCV and hepatitis B virus (HBV) infection in approximately 80% of cases. Most of the remaining cases in the West are related to other causes leading to liver cirrhosis, such as heavy alcohol intake, primary biliary cirrhosis, primary sclerosing cholangitis, autoimmune hepatitis, and metabolic liver diseases (e.g. hereditary hemochromatosis, Wilson's disease, hereditary tyrosinemia, type I glycogen storage disease, and  $\alpha_1$ -antitrypsin deficiency). Recently, non-alcoholic steatohepatitis-related cirrhosis has been recognized as an emerging problem. Indeed, cirrhosis is the strongest predisposing factor for HCC and, globally, 80–90% of HCC cases arise in severely fibrotic or cirrhotic livers. However, tumorigenesis of HCC probably differs between HBV infection versus other causes; HBV integrates its viral genome into the human host DNA, thus promoting malignant cell transformation regardless of the severity the liver parenchyma damage, whereas other causes, such as HCV and alcohol, induce cirrhosis, characterized by chronic necroinflammation which in turn can induce genomic mutations and eventually malignant cellular transformation. In Europe and the US, in patients with HCV-related cirrhosis, the incidence and 5-year cumulative risk for HCC are 3.7 cases per 100 person-years and 17%, respectively. In patients with HBV-related cirrhosis, the incidence and 5-year cumulative risk for HCC are 2.2 cases per 100 person-years and 10%, respectively.

This chapter provides an overview of the clinical presentation of HCC, discussion of strategies for diagnosis, and addresses issues of surgical and non-surgical treatment,

in the context of the interplay between cancer and chronic liver disease. Treatment outcomes are examined.

## CLINICAL PRESENTATION

The clinical presentation of HCC varies greatly depending on the stage of disease. When effective screening is performed, HCC can be detected at an early, asymptomatic stage. Conversely, in areas where systematic surveillance is lacking, up to 50% of cases are diagnosed at an advanced stage. Classic presenting symptoms include upper abdominal pain or discomfort, palpable right upper quadrant mass, weight loss, and symptoms of worsening liver function – jaundice, ascites, peripheral edema, or other sequelae of portal hypertension. In less than 5% of cases, patients present with acute abdominal catastrophe from tumor rupture with intra-abdominal bleeding.

Because of differences in the natural history of virus infection, patients with HBV-related HCC are usually younger than patients with HCV-related HCC and present with larger tumors arising in a field of moderate, asymptomatic liver disease (no or moderate fibrosis). In contrast, patients with HCV-related HCC generally present with smaller tumors arising in a field of more severe cirrhosis, probably a consequence of the fact that the latter patients are often screened because of known cirrhosis or because of symptoms related to cirrhosis itself.

## SCREENING AND DIAGNOSTIC STRATEGIES

The American Association for the Study of Liver Diseases recommends that patients with cirrhosis be enrolled in surveillance ultrasonography programs with the aim of identifying HCCs at an early stage when potentially effective treatment can be offered<sup>2</sup>. Screening is recommended every 6 months.

Serum  $\alpha$ -fetoprotein (AFP) can be detected in more than 80% of HCC cases, at levels ranging from within

the reference range up to  $10^7$  ng/ml. In addition, elevated AFP levels (up to 500 ng/ml and occasionally higher) may be seen in adult patients who have hepatitis or cirrhosis and high necroinflammatory activity but who do not have HCC. AFP levels more than 10 ng/ml have been reported in up to 40% of patients with cirrhosis. Thus, AFP alone is not sufficiently sensitive or specific for HCC screening. However, AFP levels more than 200 ng/ml associated with characteristic imaging findings are nearly 100% sensitive for the diagnosis of HCC.

Ultrasonography is a non-invasive imaging modality useful to detect very small liver lesions. Although various sonographic features ('mosaic' pattern, peripheral halo, lateral shadows, and posterior echo enhancement) have been described as typical for HCC, small nodules (<2 cm) generally appear simply as hypoechoic or, less frequently, hyperechoic. In cirrhotic livers, non-malignant regenerative and dysplastic nodules pose an important diagnostic dilemma since their ultrasound appearance is indistinguishable from that of small HCCs. As a rule, any new liver mass identified in a cirrhotic patient should be carefully investigated to determine whether it represents a new HCC.

Either multiphase computed tomography (CT) or magnetic resonance imaging (MRI) establish a reliable non-invasive diagnosis of HCC when a nodule more than 2 cm exhibits the specific radiographic characteristics of arterial enhancement followed by a contrast washout in the delayed venous phase. If the vascular profile on dynamic imaging is not characteristic and the AFP level is less than 200 ng/ml, a fine-needle aspiration (FNA) biopsy might be considered as an alternative to close follow-up with serial imaging.

In nodules measuring less than 1 cm, the typical pattern of contrast enhancement is seldom observed. Since a percutaneous biopsy of such minute lesions is technically challenging, close follow-up with repeat imaging every 3–4 months is generally indicated.

For nodules measuring 1–2 cm, a diagnosis of HCC is established when coincidental characteristic features are detected by two dynamic imaging studies (CT, MRI, or contrast-enhanced ultrasound). Almost half of HCCs measuring 1–2 cm do not exhibit a diagnostic contrast enhancement pattern. In these cases, an FNA biopsy may be necessary to establish the diagnosis. Negative findings on biopsy do not exclude the diagnosis of HCC, and if the biopsy findings are equivocal, options include imaging follow-up with CT or MRI at 3–6 months or repeat biopsy. The risk of tumor seeding along the biopsy needle track could argue against performing FNA, but with modern techniques this event is rare (occurring in <1% of cases), and the risk of bleeding is low. In cases in which the diagnosis is uncertain, the risks associated with major resection or transplantation for benign disease may be outweighed by

the potential benefits of FNA biopsy. Alternatively, serial imaging studies can be used to follow the evolution of suspicious nodules: an enlarging lesion with features typical of HCC can be confidently considered HCC.

## TREATMENT

Without treatment, the median survival duration for patients with HCC varies from 3 to 17 months, depending on tumor extent and the degree of underlying liver disease. Treatment options for HCC include potentially curative therapies, such as surgical resection, liver transplantation, and possibly ablation, and palliative therapy in the form of transarterial chemoembolization. Chemotherapy and radiation therapy are used in highly selected cases.

### Surgical resection

Surgical resection is an effective treatment for HCC, which can be offered to 15–30% of patients with HCC.

#### *Preoperative evaluation*

Optimal outcomes after surgical resection for HCC – minimal postoperative morbidity and mortality as well as optimal long-term survival – are contingent upon proper identification of candidates for safe, complete resection. Systematic assessment of tumor extent, general medical fitness and underlying liver function are used to identify candidates for surgery. The addition of remnant liver volume assessment is crucial to planning major hepatectomy.

Patient age *per se* does not preclude liver resection. However, co-morbidities increase the operative risk and should be carefully considered: patients with an American Society of Anesthesiology score of more than 1 have more than three times the mortality and twice the morbidity of patients with a score of 1<sup>3</sup>. Risk may be prohibitive in patients with congestive heart failure, severe chronic obstructive pulmonary disease, or significant chronic renal failure.

#### *Tumor extent*

The assessment of tumor extent is essential for determining resectability and the appropriate type of surgical resection. At the University of Texas M D Anderson Cancer Center, each patient is first staged with multiple-phase CT of the thorax and the abdomen because this study provides superior image resolution of extrahepatic sites and excellent liver anatomy detail. MRI is the imaging modality of choice when contrast agents are contraindicated or further lesion characterization is needed.

In recent years, eligibility criteria for resection have expanded to include selected patients with tumors once considered unresectable, such as large HCCs, multinodular and bilobar HCCs, and, in highly selected cases, HCCs with portal vein or hepatic vein involvement. Extrahepatic disease and tumor thrombus extending into the inferior vena cava generally remain contraindications for resection. On the basis of the preoperative staging, patients are considered for resection when all tumor nodules can be safely removed with negative margins and when the volume and function of the future liver remnant (FLR) is adequate.

### *Underlying liver function*

In the West, hepatic function has traditionally been evaluated with the Child-Pugh classification (Table 18.1). The Child-Pugh classification provides an estimate of the synthetic and detoxification capacity of the liver. Postoperative mortality increases with each successive Child-Pugh class, therefore major liver resection is considered only in patients with Child-Pugh class A disease. Minor resection can be considered in Child-Pugh class B patients, whereas patients with Child-Pugh class C disease are generally not candidates for even minor resection.

The Child-Pugh classification may underestimate the surgical risk because it does not assess the hemodynamic status of the patient. Undiagnosed or latent portal hypertension has been shown to increase the risk of hepatic

decompensation following hepatic resection<sup>4</sup>. Thus, preoperative clinical or radiological signs of portal hypertension, including splenomegaly, thrombocytopenia (platelet count  $<100\,000/\text{mm}^3$ ), and esophagogastric varices, represent contraindications for major resection.

In addition, evidence of ongoing hepatocellular injury indicated by aspartate aminotransferase (AST) and alanine aminotransferase (ALT) levels exceeding twice the upper limit of normality, is a contraindication to major resection. Adequate treatment of active hepatitis may permit some patients to undergo subsequent safe major resection.

In the East, global functional liver tests, such as indocyanine green (ICG) clearance, galactose elimination capacity and aminopyrine clearance, have been employed for preoperative selection. The most widely used and validated test is ICG clearance<sup>5</sup>, which has been used to select patients with cirrhosis mainly for minor resection.

### *Future liver remnant volume*

Although useful for patient selection, the Child-Pugh classification, ICG clearance and the other aforementioned tests estimate the overall liver function, and do not provide specific information regarding the function of the portion of the liver that will remain after resection, the future liver remnant (FLR), which may vary in size as a result of individual intrahepatic variation<sup>6</sup> or compensatory hypertrophy. Recent studies have emphasized the critical link between volume and function of the FLR and the increased postoperative risks associated with small liver remnant<sup>7,8</sup>. Therefore, in patients selected for major hepatic resection, attention has focused on the FLR volume, along with consideration of the extent of underlying liver disease.

In general, to avoid cholestasis, fluid retention and postoperative hepatic insufficiency, an FLR volume of 20% of the estimated total liver volume (TLV) is required in patients with normal underlying liver<sup>7</sup>; 40% is required in patients with compensated cirrhosis or hepatitis<sup>9</sup>. Three-dimensional CT volumetry, derived from the staging/planning CT, provides accurate preoperative measurement of the FLR.

Although direct measurement of the TLV is possible, it may not be relevant for surgical planning<sup>10</sup>, since cirrhotic patients often have enlarged or shrunken livers, thereby reducing the utility of the measured TLV to standardize the FLR volume.

The estimated TLV, which is calculated using a mathematical formula derived from the linear correlation between liver size and body surface area (BSA) ( $\text{TLV (cm}^3\text{)} = -794.41 + 1267.28 \times \text{BSA (m}^2\text{)}$ )<sup>11</sup>, provides a standardized estimation of the TLV. The ratio of the measured FLR volume to the estimated TLV is termed the 'standardized FLR volume' and indicates the percentage of the TLV remaining

**Table 18.1** Child-Pugh classification of hepatic functional reserve

<i>Clinical and biochemical parameters</i>	<i>1 point</i>	<i>2 points</i>	<i>3 points</i>
Albumin (g/dl)	>3.5	2.8–3.5	<2.8
Bilirubin (mg/dl)	<2	2–3	>3
Prothrombin time			
prolonged (seconds)	<4	4–6	>6
percentage	>60	40–60	<60
international normalized ratio	<1.7	1.7–2.3	>2.3
Encephalopathy	Absent	Moderate (stage I–II)	Severe (stage III–IV)
Ascites	Absent	Moderate	Refractory

Each parameter is assigned 1, 2, or 3 points as indicated in the column headings. Child-Pugh class is assigned as follows: 5–6 points, class A; 7–9 points, class B; 10–15 points, class C.



after resection. Calculating the standardized FLR volume corrects the actual liver volume to the individual patient's size and provides a validated, individualized estimate of that patient's postresection liver function.

In patients who are otherwise candidates for hepatic resection, an inadequate standardized FLR volume may be the only obstacle to curative resection. Portal vein embolization can safely be used to increase the volume and function of the FLR<sup>12</sup>. Embolization of the portal branches of the segments to be resected, using a percutaneous transhepatic technique, results in hypertrophy of the non-embolized segments<sup>12</sup>. The FLR hypertrophy after portal vein embolization correlates with an improvement in FLR function and ability of the liver to tolerate a surgical stress<sup>10</sup>. Moreover, a recent prospective study corroborated the benefit of portal vein embolization prior to right hepatectomy in patients with chronic liver disease: portal vein embolization was associated with a significant decrease in pulmonary complications, hepatic decompensation and the lengths of intensive care unit and hospital stays<sup>13</sup>.

### *Surgical principle and short-term results*

Principles guiding resection of HCC include anatomic resection, the use of vascular inflow occlusion, and low central venous pressure anesthesia.

HCC has a propensity to invade the portal and hepatic veins; thus, tumor spread is essentially through the bloodstream – first via the portal vein to cause intrahepatic metastasis, and later, to extrahepatic organs. On this basis, Makuuchi *et al.*<sup>14</sup> championed the concept of anatomic resection, which includes systematic removal of the entire tumor-bearing hepatic segment to include resection of the portal territories that might contain venous metastases or daughter micronodules. The outcome advantage of anatomic over non-anatomic resection has been demonstrated<sup>15,16</sup>, and a segment-oriented anatomic resection should be considered the standard approach for any HCC whenever technically and functionally possible. Further evidence supporting use of the anatomic approach is the fact that when negative resection margins are attained, the rate of postoperative tumor recurrence is related not to margin width but rather to microvascular invasion or the presence of microsattellites<sup>17</sup>.

One of the most powerful independent predictors of major morbidity and death from hepatectomy is the amount of intraoperative blood loss. Maintenance of low central venous pressure, usually less than 5 cm H<sub>2</sub>O, has been shown to reduce blood loss from hepatic veins and hepatic parenchyma during liver transection<sup>18</sup>. Different techniques of temporary vascular occlusion have also been developed to reduce intraoperative hemorrhage, such as

hepatic pedicle clamping (Pringle's maneuver) and total vascular exclusion. Total vascular exclusion, however, is poorly tolerated in patients with cirrhosis. Generally, most elective resections can be performed safely with intermittent pedicle clamping<sup>19</sup> or selective 'unilateral' pedicle clamping.

Improved patient selection and surgical techniques have resulted in a remarkable decrease in perioperative mortality rates after resection of HCC. Currently, the overall mortality rate for resection in cirrhotic patients is approximately 5%, with some centers reporting near zero mortality<sup>20,21</sup>. In recent large series, morbidity rates ranged from 25 to 50%.

### *Staging and impact of disease features on long-term outcomes*

Several clinical and pathological factors dictate the prognosis after liver resection for HCC<sup>22,23</sup>. However, studies from different centers suggest different predictors of survival, and numerous staging or classification systems have been proposed. In 2003, the American Hepato-Pancreato-Biliary Association and American Joint Committee on Cancer (AJCC) consensus conference on staging for HCC recommended the use of the TNM staging system to stratify the prognosis in resected patients<sup>24</sup>. Thus, in this section of the chapter the current (6th) edition of the AJCC/International Union Against Cancer (UICC) staging system<sup>25</sup> is used, and the impact on prognosis of HCC features and underlying liver disease is discussed.

In 2002, the International Cooperative Study Group for HCC reported on a cohort of 557 patients treated with radical resection in centers in the US, Europe and Asia. They found that invasion of a main branch of the portal or hepatic vein, microscopic vascular invasion, severe fibrosis/cirrhosis, multiple nodules, and tumor size more than 5 cm were independent predictors of survival<sup>22</sup>. Consistent with other studies<sup>26</sup>, vascular invasion was identified as the most powerful tumor-related determinant of survival. These data were used to define the simplified, revised TNM staging system, which was adopted in the 6th edition of the unified AJCC/UICC TNM staging manual (Table 18.2).

Patients with a solitary tumor without vascular invasion were found to have similar survival irrespective of tumor size (Figure 18.1) and thus comprise the T1 category (5-year survival rate, 55%). The prognosis of patients with multiple tumors, none larger than 5 cm, was similar to that of patients with a single tumor with microscopic vascular invasion. These two groups were combined to form the new T2 category (5-year survival rate, 37%; Figure 18.2). Patients with multiple tumors, any of which is greater than 5 cm, and those with major vascular invasion were

**Table 18.2** Current (6th) edition of the American Joint Committee on Cancer/International Union Against Cancer TNM, histological grade and fibrosis score classification scheme for hepatocellular carcinoma

<i>Primary tumor (T)</i>				
TX	Primary tumor cannot be assessed			
T0	No evidence of primary tumor			
T1	Solitary tumor without vascular invasion			
T2	Solitary tumor with vascular invasion or multiple tumors none more than 5 cm			
T3	Multiple tumors more than 5 cm or tumor involving a major branch of the portal or hepatic vein(s)			
T4	Tumor(s) with direct invasion of adjacent organs other than the gallbladder or with perforation of visceral peritoneum			
<i>Regional lymph nodes (N)</i>				
NX	Regional lymph nodes cannot be assessed			
N0	No regional lymph node metastasis			
N1	Regional lymph node metastasis			
<i>Distant metastasis (M)</i>				
MX	Distant metastasis cannot be assessed			
M0	No distant metastasis			
M1	Distant metastasis			
<i>Stage Groupings</i>				
Stage I	T1	N0	M0	
Stage II	T2	N0	M0	
Stage IIIA	T3	N0	M0	
Stage IIIB	T4	N0	M0	
Stage IIIC	Any T	N1	M0	
Stage IV	Any T	Any N	M1	
<i>Histological grade (G)</i>				
GX	Grade cannot be assessed			
G1	Well differentiated			
G2	Moderately differentiated			
G3	Poorly differentiated			
G4	Undifferentiated			
<i>Fibrosis score (F)</i>				
F0	Fibrosis score 0–4 (no fibrosis to moderate fibrosis)			
F1	Fibrosis score 5–6 (severe fibrosis to cirrhosis)			

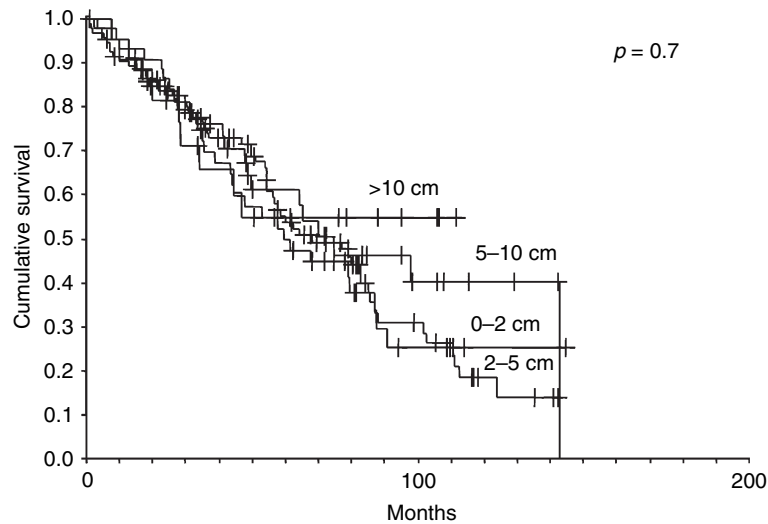
Adapted from reference 25.

categorized as T3 (5-year survival rate, 15%; Figure 18.2). Since adoption of the current TNM staging system, several authors have independently validated and confirmed its prognostic accuracy in separate patient cohorts.

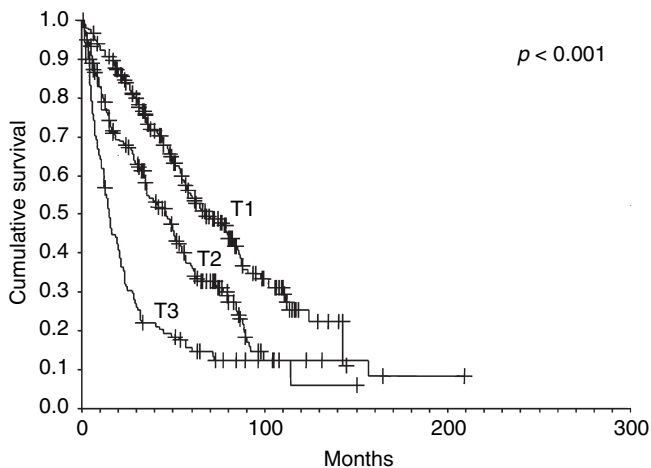
Although tumor size, vascular invasion and multiple nodules are associated with shorter survival, recent studies have emphasized that these factors should be regarded as

prognostic factors rather than as criteria for patient selection for surgical treatment.

Tumor size as a prognostic factor must be considered carefully. First, although large tumor size is associated with an increased incidence of microscopic vascular invasion, large tumors without vascular invasion have a prognosis similar to that of small tumors without vascular invasion.



**Figure 18.1** Effect of tumor size on survival in patients with solitary hepatocellular carcinoma without vascular invasion. Reprinted from reference 22, with permission.



**Figure 18.2** Survival of 557 patients with hepatocellular carcinoma (HCC) treated with surgical resection, according to T category in the current American Joint Committee on Cancer/International Union Against Cancer TNM staging system for HCC. Reprinted from reference 22, with permission.

Unfortunately, microscopic vascular invasion cannot be reliably determined prior to resection. Second, high histological grade is associated with increased incidence of microscopic vascular invasion. Together these findings may help to determine the probability of microscopic vascular invasion, however, tumor size and grade alone should not be used to exclude patients from potentially curative surgery<sup>27</sup>. While some authors consider a single tumor larger than 5 cm inappropriate for resection<sup>28</sup>, resection of solitary HCCs yields 5-year survival rates of 37–55%. Furthermore, analysis of outcomes in 300 patients who underwent partial hepatectomy for HCCs larger than 10 cm revealed a 5-year survival rate of 27%<sup>29</sup>.

Unlike microvascular invasion, tumor invasion of the major branches of the hepatic (Vv2) veins or the

first–second order branches of the portal (Vp2–3) vein can be detected preoperatively. For patients with such invasion, some ‘treatment guidelines’<sup>28</sup> indicate that the only appropriate therapies are new antitumoral agents in the setting of clinical trial. However, despite the technical and oncological challenges, hepatic resection may be justified in selected patients. In a series of 102 patients with Vp3 or Vv2, the 5-year survival rate was 23% in patients without cirrhosis, and median survival duration exceeded the historic survival durations in similar patients treated non-surgically<sup>30</sup>.

Multinodular HCCs present another treatment challenge. Multiple nodules may represent independent tumors derived from multiple foci of hepatocarcinogenesis or may be a manifestation of advanced disease with intrahepatic metastasis. Bilobar tumor location further increases the technical challenge. Indeed, major resections are often required in such patients because of substantial tumor volume or wide geographic distribution of tumors throughout the liver. Patients with more than three nodules, regardless of size, or two or three nodules, one of which exceeds 3 cm, have been considered unsuitable for resection by some groups<sup>28</sup>. However, Ng *et al.*<sup>31</sup> recently reported results that challenged the relegation of these patients to palliative therapies: in 380 patients with such tumor features who underwent resection, the treatment-related mortality rate was 2.4%, and the 5-year survival rate was 39%. Extensive resection is, of course, limited to patients without cirrhosis.

Chronic hepatitis and cirrhosis are, along with vascular invasion, the strongest predictors of tumor recurrence that occurs in 70–100% of patients. Recurrence can occur early, from vascular invasion with microsatellite tumors in the adjacent parenchyma (intrahepatic metastases) or late,

as possibly 'second' primary tumors in the remnant liver, that result from the field of cancerization from hepatitis and cirrhosis<sup>32</sup>.

Data from Vauthey *et al.* reveal that moderate to severe fibrosis stratifies patient survival within each T category (Table 18.3). Thus, for example, T1 class with severe fibrosis/cirrhosis is associated with a distinct reduced survival compared with T1 class without fibrosis. The AJCC/UICC staging manual recommends notation of fibrosis in every resected case of HCC using the fibrosis classification proposed by Ishak *et al.*<sup>33</sup> but has not yet formally incorporated the fibrosis classification into the staging system.

Although surgical resection of intrahepatic tumor recurrence can be technically challenging, repeat hepatectomy has been proven to be safe and effective when feasible<sup>34,35</sup>. Treatment-related mortality rates are 0–8%, and 5-year survival rates are 50–69%. However, only 10–31% of patients with intrahepatic tumor recurrence can be treated with a second hepatectomy.

Finally, underlying liver disease often limits resection options even in patients who present with solitary or anatomically resectable disease. Thus, other treatment strategies are necessary for such patients.

## Liver transplantation

Advanced cirrhosis with impaired liver function (Child-Pugh class B and C) limits the surgical treatment options

**Table 18.3** Prognosis of patients with hepatocellular carcinoma according to the main T categories of the new American Joint Committee on Cancer/International Union Against Cancer classification and fibrosis score

<i>T Category</i>	<i>Fibrosis score</i>	<i>5-Year survival (%)</i>	<i>p Value</i>
T1 – Solitary tumor without vascular invasion	F0	64	0.01
	F1	49	
T2 – Solitary tumor with vascular invasion or multiple tumors ≤5 cm	F0	46	0.01
	F1	30	
T3 – Major vascular invasion or multiple tumors >5 cm	F0	17	0.005
	F1	9	

F0 indicates fibrosis grade of 0–4 and F1 indicates fibrosis grade of 5–6 according to Ishak *et al.*<sup>33</sup>.

Adapted from reference 22, with permission.

to liver transplantation. Generally accepted indications for liver transplantation are guided by the seminal proposal of Bismuth *et al.*<sup>36</sup>, subsequently formalized by Mazzaferro *et al.*<sup>37</sup> to include patients with a solitary HCC less than 5 cm or a maximum of three tumors, each less than 3 cm, without macroscopic vascular involvement or distant disease. These selection criteria, known as the Milan criteria, have resulted in 5-year survival rates of 71–75% in some centers and of about 60% in registry data from Europe and USA.

Liver transplantation removes the 'field at risk' for development of *de novo* cancer<sup>38</sup>, restores the hepatic function and completely extirpates the liver tumors, advantages counterbalanced by the 13% 1-year mortality rate in adults, the severe shortage of organ donors and the cost and morbidity of life-long immunosuppression. Waiting for a suitable donor organ, on the list for transplantation, increases the probability of tumor growth beyond the listing criteria; 'dropout', i.e. loss of opportunity for transplantation, because of tumor progression is reported to be 15–33% of patients waiting for liver transplantation. Progression and dropout while waiting worsen the outcomes of liver transplantation: the 2-year intention-to-treat survival rate is 84% for patients with 62 days of waiting time but only 54% for patients with 162 days of waiting time<sup>39</sup>. Recent intention-to treat analyses of a large cohort of patients found 5-year survival rates of 47–62%, far below the 70% or more survival rates reported by Mazzaferro and other authors.

Expansion of the limits of the actual morphological selection criteria for liver transplantation has been considered, while some have suggested incorporating biological factors such as grading and genotyping. A detailed discussion of the pros and cons of these controversial approaches is beyond the scope of this chapter, but encouraging results of early studies are balanced by the difficulties in identifying good prognosis tumor among patients with HCC beyond the Milan criteria.

Whether liver resection or liver transplantation is the optimal initial treatment for patients with preserved liver function and HCCs within the Milan criteria remains controversial<sup>40–42</sup>. In view of the discrepancy between organ supply and demand, and the problems associated with liver transplantation, such as graft rejection, recurrent viral hepatitis, immunosuppression-related opportunistic infections, and long-term medical complications, the potential value of liver resection followed by 'salvage' transplantation for tumor recurrence or deterioration of the hepatic function is hotly debated. Majno *et al.*'s Markov-based decision analytic model, which showed a life expectancy of 8.8 years for patients undergoing primary liver transplantation versus 7.8 years for patients undergoing primary resection and salvage transplantation, added fuel to

the controversy<sup>43</sup>. In practice, liver resection and liver transplantation are complementary, not competing treatments. Patients with preserved hepatic function are generally considered for liver resection as first-line treatment. Conversely, those with poor liver function and early HCCs are eligible for liver transplantation. The problem of more advanced HCCs arising in the setting of advanced cirrhosis remains unsolved by liver resection or liver transplantation.

Few data exist regarding which staging system should be used to best estimate the prognosis of patients treated with liver transplantation. We have recently investigated this issue by comparing the ability of the most widely used staging systems to predict survival in a cohort of 490 patients who underwent liver transplantation for HCC and found that among all major staging systems or treatment schemes, including the Japan Integrated Staging (JIS) score, the Japanese TNM, the CLIP (Cancer of the Liver Italian Program) score, the UNOS (United Network for Organ Sharing) classification, the Pittsburgh classification, and the Barcelona Clinic Liver Cancer (BCLC) staging classification, the AJCC/UICC staging system provides the best stratification of both overall and recurrence-free survival (unpublished data). Thus, the AJCC/UICC staging system is likely to be considered the optimal staging system for prediction of outcome after surgery (liver resection or liver transplantation) for HCC.

### Ablative therapies

In some patients not eligible for surgical resection or liver transplantation, ablative therapies can be considered. Although these therapies may also be used to treat resectable HCC, their efficacy has not been established as equivalent to that of resection or transplantation. The major disadvantages of any ablation technique are the limited ability to evaluate treatment margins and the need to obtain negative treatment margins in three dimensions. Indeed, all ablation techniques are associated with higher local recurrence rates than resection.

Percutaneous ethanol injection (PEI) is the best-known and best-studied ablative therapy<sup>44</sup>. Absolute ethanol induces cellular dehydration, necrosis and vascular thrombosis, causing tumor cell death. PEI results in complete ablation of 90–100% of HCCs smaller than 2 cm, but complete ablation rates fall to 70% for tumors between 2 and 3 cm and 50% for tumors between 3 and 5 cm. Cases of incomplete ablation are due to incomplete ethanol infiltration related to inadequate placement of the needle and/or the presence of intratumoral septae. Severe complications of PEI are rare, and the treatment-related mortality rate has been reported to be 0.09–0.1%.

Radiofrequency ablation (RFA) is the most utilized alternative mode of ablative therapy. RFA uses heat to

destroy tumors: a needle electrode inserted into the tumor delivers a high-frequency alternating current, which generates rapid vibration of ions, frictional heat and, ultimately, coagulative necrosis. The efficacy of RFA is similar to that of PEI in tumors smaller than 2 cm, and the efficacy of RFA is better than that of PEI in larger tumors<sup>45</sup>. However, studies that report pathological analysis of explanted livers after RFA consistently show tumor persistence after RFA in 45–53% of cases (37–38% for HCCs <3 cm); the cumulative probability of HCC persistence 18 months after treatment is 70%<sup>46</sup>. The main drawbacks of RFA are its relatively high costs; higher rate of complications compared with PEI (0–12%), which can include pneumothorax, pleural effusion, hemorrhage, subcapsular hematoma, hemobilia, biliary stricture, and liver abscess; and the treatment-related mortality rate of up to 1%. However, this technique remains an important and effective treatment for unresectable small HCCs. For patients who have a tumor recurrence after surgical treatment and who are not candidates for resection, RFA is probably the best ‘salvage technique’ and may enable remission. RFA is also used in some cases as a bridge to liver transplantation to prevent tumor progression while awaiting the transplant.

### Transcatheter arterial embolization and transarterial chemoembolization

HCC is a vascular tumor that derives most of its blood supply from the hepatic artery. Therefore, selective injection into the hepatic artery of particulate embolic agents such as gelatin sponges and polyvinyl alcohol particles, a procedure referred to as transcatheter arterial embolization (TAE), results in ischemic tumor necrosis. Transarterial chemoembolization (TACE) combines the hepatic artery occlusion with intra-arterial chemotherapy. In TACE, the aim is to increase the selective delivery of chemotherapy into the tumor. Drugs – most commonly doxorubicin and cisplatin – are impregnated in the gelatin sponges used for embolization or suspended in lipiodol, an oily contrast agent selectively retained within the tumor for an extended period.

Randomized studies have established the utility, safety and efficacy of TAE and TACE. TACE has been shown to prolong patient survival when compared with the best supportive care<sup>47,48</sup>. A recent meta-analysis of seven randomized studies comparing TACE or TAE with a control arm of conservative management or suboptimal therapy, showed a significant improvement in 2-year survival, ranging from 20% to 60%, favoring TAE or TACE<sup>48</sup>. Sensitivity analyses confirmed a significant survival benefit after TACE with cisplatin or doxorubicin but not after TAE.

TAE and TACE are contraindicated in patients with serum bilirubin level greater than 5 mg/dl, refractory ascites,

platelet count less than 50 000/mm<sup>3</sup>, prothrombin activity less than 50%, renal failure, or encephalopathy. Overall, in patients with Child-Pugh class C disease, the postembolization risk of liver failure and death is unacceptably high. Patients with main portal vein thrombosis are poor candidates for TACE because of the risk of necrosis of the non-tumorous liver deprived of blood supply, while those with cavernous transformation or segmental portal vein thrombosis can be treated selectively. Postembolization syndrome, including fever, nausea, pain, and a moderate degree of ileus, appears in more than 50% of patients. Other adverse events, including hepatic abscess, cholecystitis, fatal hepatic necrosis, and liver failure, have also been reported.

Due to the proven survival advantage in properly selected patients not eligible for percutaneous ablation or resection, and without extrahepatic tumor spread, TACE is considered the standard of care.

### Chemotherapy

Systemic chemotherapy has marginal antitumor activity against HCC. Various clinical trials investigating the role of single agents, such as 5-fluorouracil, doxorubicin, cisplatin, vinblastine, and etoposide, in the treatment of unresectable HCCs have reported short-lasting, modest responses in 0–20% of patients. Doxorubicin is considered the most active single agent, with an overall response rate of 19%. However, neither doxorubicin nor any other chemotherapeutic agent or combination has produced improved patient survival rates.

Recently, in the setting of a phase II trial, a combination of cisplatin, interferon  $\alpha$ -2b, doxorubicin, and fluorouracil (PIAF) yielded promising results in patients with preserved liver function and extensive HCC: an overall response rate of 26% and a complete pathological response rate of 8%. Although a subsequent randomized phase III study failed to demonstrate an improved survival duration or a significantly higher response rate for PIAF (8.7 months and 21%) versus doxorubicin alone (6.8 months and 11%)<sup>49</sup>, an important finding of Lau *et al.*<sup>50</sup> did emerge from the analysis of patients with extensive liver-only disease and preserved liver function: 28% of patients with unresectable HCCs treated with PIAF underwent salvage resection made possible because of significant tumor downsizing, versus only 12% of patients with unresectable disease treated with doxorubicin.

### Radiation therapy

External-beam radiation therapy has limited utility in the treatment of HCC. Whole-liver radiation is not effective and may be associated with radiation hepatitis. However, newer methods using conformal, 'four-dimensional' planning techniques and the proton therapy are promising

and radiation therapy can provide palliative, symptomatic relief in selected patients with HCC. Interest is increasing in selective internal radiation therapy through intra-arterial injection of lipiodol-iodine-131- or yttrium-90-labeled microspheres. The impact of these therapies on survival has not been established, and they are considered investigational.

### SUMMARY

HCC remains a major health issue worldwide. Effective screening programs are advised to increase the frequency of tumor diagnosis at a stage at which potentially curative treatment can be offered. Liver resection is the optimal initial treatment in cirrhotic patients with preserved liver function (Child-Pugh A) when complete resection of the tumor can be obtained. Therefore, liver resection is no longer limited to early stage disease. Large and multinodular tumors do not represent a contraindication to liver resection; HCC with macroscopic vascular invasion and bilobar tumors may be resected with acceptable outcome in carefully selected patients (usually without cirrhosis). The extent of liver resection must be planned with particular attention to hepatic function and underlying liver disease to reduce postoperative complications and hepatic insufficiency. Minor hepatectomy can be safely performed in patients with normal liver function tests (serum bilirubin levels  $\leq 1.0$  mg/dl, AST and ALT levels less than twice the upper limit of normal), no ascites and platelets counts  $> 100\,000/\text{mm}^3$ . Additional criteria, for patients considered for major hepatectomy, are the absence of clinical portal hypertension (determined based on the absence of splenomegaly), and/or thrombocytopenia, and/or esophagogastric varices, and an FLR volume equal or greater than 40% of the estimated TLV. Portal vein embolization is indicated in patients with an FLR less than 40% of the TLV to induce hypertrophy of the FLR in order to reduce the morbidity and mortality of major hepatectomy. Liver transplantation is indicated in patients with impaired liver function (Child-Pugh B and C) and early HCC (i.e. solitary HCC  $< 5$  cm or a maximum of three tumors, each  $< 3$  cm). In patients with small-volume tumors, unsuitable for surgery, ablative therapies represent potentially curative treatments. TACE is an alternative for patients not eligible for other treatment, especially when multiple tumors are present with a background of compensated cirrhosis. Systemic chemotherapy and radiotherapy have a limited role for treatment of HCC. Advances in the treatment of HCC will come from effective strategies for early diagnosis, refinements in integration of liver function and volume, and better definition of biological factors to guide select first-line treatments and adjuvant therapies.

## REFERENCES

1. El-Serag HB. Hepatocellular carcinoma: an epidemiologic view. *J Clin Gastroenterol* 2002; 35: S72–8.
2. Bruix J, Sherman M. Management of hepatocellular carcinoma. *Hepatology* 2005; 42: 1208–36.
3. Belghiti J, Hiramatsu K, Benoist S et al. Seven hundred forty-seven hepatectomies in the 1990s: an update to evaluate the actual risk of liver resection. *J Am Coll Surg* 2000; 191: 38–46.
4. Bruix J, Castells A, Bosch J et al. Surgical resection of hepatocellular carcinoma in cirrhotic patients: prognostic value of preoperative portal pressure. *Gastroenterology* 1996; 111: 1018–22.
5. Torzilli G, Makuuchi M, Inoue K et al. No-mortality liver resection for hepatocellular carcinoma in cirrhotic and noncirrhotic patients: is there a way? A prospective analysis of our approach. *Arch Surg* 1999; 134: 984–92.
6. Abdalla EK, Denys A, Chevalier P et al. Total and segmental liver volume variations: implications for liver surgery. *Surgery* 2004; 135: 404–10.
7. Abdalla EK, Barnett CC, Doherty D et al. Extended hepatectomy in patients with hepatobiliary malignancies with and without preoperative portal vein embolization. *Arch Surg* 2002; 137: 675–80.
8. Shirabe K, Shimada M, Gion T et al. Postoperative liver failure after major hepatic resection for hepatocellular carcinoma in the modern era with special reference to remnant liver volume. *J Am Coll Surg* 1999; 188: 304–9.
9. Kubota K, Makuuchi M, Kusaka K et al. Measurement of liver volume and hepatic functional reserve as a guide to decision-making in resectional surgery for hepatic tumors. *Hepatology* 1997; 26: 1176–81.
10. Vauthey JN, Chaoui A, Do KA et al. Standardized measurement of the future liver remnant prior to extended liver resection: methodology and clinical associations. *Surgery* 2000; 127: 512–9.
11. Vauthey JN, Abdalla EK, Doherty DA et al. Body surface area and body weight predict total liver volume in Western adults. *Liver Transpl* 2002; 8: 233–40.
12. Abdalla EK, Hicks ME, Vauthey JN. Portal vein embolization: rationale, technique and future prospects. *Br J Surg* 2001; 88: 165–75.
13. Farges O, Belghiti J, Kianmanesh R et al. Portal vein embolization before right hepatectomy: prospective clinical trial. *Ann Surg* 2003; 237: 208–17.
14. Makuuchi M, Hasegawa H, Yamazaki S. Ultrasonically guided subsegmentectomy. *Surg Gynecol Obstet* 1985; 161: 346–50.
15. Hasegawa K, Kokudo N, Imamura H et al. Prognostic impact of anatomic resection for hepatocellular carcinoma. *Ann Surg* 2005; 242: 252–9.
16. Regimbeau JM, Kianmanesh R, Farges O et al. Extent of liver resection influences the outcome in patients with cirrhosis and small hepatocellular carcinoma. *Surgery* 2002; 131: 311–7.
17. Poon RT, Fan ST, Ng IO, Wong J. Significance of resection margin in hepatectomy for hepatocellular carcinoma: a critical reappraisal. *Ann Surg* 2000; 231: 544–51.
18. Johnson M, Mannar R, Wu AV. Correlation between blood loss and inferior vena caval pressure during liver resection. *Br J Surg* 1998; 85: 188–90.
19. Belghiti J, Noun R, Malafosse R et al. Continuous versus intermittent portal triad clamping for liver resection: a controlled study. *Ann Surg* 1999; 229: 369–75.
20. Fan ST, Lo CM, Liu CL et al. Hepatectomy for hepatocellular carcinoma: toward zero hospital deaths. *Ann Surg* 1999; 229: 322–30.
21. Imamura H, Seyama Y, Kokudo N et al. One thousand fifty-six hepatectomies without mortality in 8 years. *Arch Surg* 2003; 138: 1198–206.
22. Vauthey JN, Lauwers GY, Esnaola NF et al. Simplified staging for hepatocellular carcinoma. *J Clin Oncol* 2002; 20: 1527–36.
23. Predictive factors for long term prognosis after partial hepatectomy for patients with hepatocellular carcinoma in Japan. The Liver Cancer Study Group of Japan. *Cancer* 1994; 74: 2772–80.
24. Henderson JM, Sherman M, Tavill A et al. AHPBA/AJCC consensus conference on staging of hepatocellular carcinoma: consensus statement. *HPB Surg* 2003; 5: 243–50.
25. Liver (including intrahepatic bile ducts). In: Greene FL, Page DL, Fleming ID, eds. *American Joint Committee on Cancer Staging Manual*, 6th edn. New York: Springer-Verlag, 2002: 133–44.
26. Tsai TJ, Chau GY, Lui WY et al. Clinical significance of microscopic tumor venous invasion in patients with resectable hepatocellular carcinoma. *Surgery* 2000; 127: 603–8.
27. Pawlik TM, Delman KA, Vauthey JN et al. Tumor size predicts vascular invasion and histologic grade: Implications for selection of surgical treatment for hepatocellular carcinoma. *Liver Transpl* 2005; 11: 1086–92.
28. Bruix J, Llovet JM. Prognostic prediction and treatment strategy in hepatocellular carcinoma. *Hepatology* 2002; 35: 519–24.
29. Pawlik TM, Poon RT, Abdalla EK et al. Critical appraisal of the clinical and pathologic predictors of survival after resection of large hepatocellular carcinoma. *Arch Surg* 2005; 140: 450–7.
30. Pawlik TM, Poon RT, Abdalla EK et al. Hepatectomy for hepatocellular carcinoma with major portal or hepatic vein invasion: results of a multicenter study. *Surgery* 2005; 137: 403–10.
31. Ng KK, Vauthey JN, Pawlik TM et al. Is hepatic resection for large or multinodular hepatocellular carcinoma justified? Results from a multi-institutional database. *Ann Surg Oncol* 2005; 12: 364–73.
32. Imamura H, Matsuyama Y, Tanaka E et al. Risk factors contributing to early and late phase intrahepatic recurrence of hepatocellular carcinoma after hepatectomy. *J Hepatol* 2003; 38: 200–7.
33. Ishak K, Baptista A, Bianchi L et al. Histological grading and staging of chronic hepatitis. *J Hepatol* 1995; 22: 696–9.
34. Minagawa M, Makuuchi M, Takayama T, Kokudo N. Selection criteria for repeat hepatectomy in patients with recurrent hepatocellular carcinoma. *Ann Surg* 2003; 238: 703–10.
35. Poon RT, Fan ST, Lo CM et al. Intrahepatic recurrence after curative resection of hepatocellular carcinoma: long-term results of treatment and prognostic factors. *Ann Surg* 1999; 229: 216–22.
36. Bismuth H, Chiche L, Adam R et al. Liver resection versus transplantation for hepatocellular carcinoma in cirrhotic patients. *Ann Surg* 1993; 218: 145–51.
37. Mazzaferro V, Regalia E, Doci R et al. Liver transplantation for the treatment of small hepatocellular carcinomas in patients with cirrhosis. *N Engl J Med* 1996; 334: 693–9.
38. Bilimoria MM, Lauwers GY, Doherty DA et al. Underlying liver disease, not tumor factors, predicts long-term survival after resection of hepatocellular carcinoma. *Arch Surg* 2001; 136: 528–35.
39. Llovet JM, Fuster J, Bruix J. Intention-to-treat analysis of surgical treatment for early hepatocellular carcinoma: resection versus transplantation. *Hepatology* 1999; 30: 1434–40.
40. Poon RT, Fan ST, Lo CM et al. Long-term survival and pattern of recurrence after resection of small hepatocellular carcinoma in

- patients with preserved liver function: implications for a strategy of salvage transplantation. *Ann Surg* 2002; 235: 373–82.
41. Adam R, Azoulay D, Castaing D et al. Liver resection as a bridge to transplantation for hepatocellular carcinoma on cirrhosis: a reasonable strategy? *Ann Surg* 2003; 238: 508–18; discussion 518–9.
42. Belghiti J, Cortes A, Abdalla EK et al. Resection prior to liver transplantation for hepatocellular carcinoma. *Ann Surg* 2003; 238: 885–92; discussion 892–3.
43. Majno PE, Sarasin FP, Mentha G, Hadengue A. Primary liver resection and salvage transplantation or primary liver transplantation in patients with single, small hepatocellular carcinoma and preserved liver function: an outcome-oriented decision analysis. *Hepatology* 2000; 31: 899–906.
44. Livraghi T, Giorgio A, Marin G et al. Hepatocellular carcinoma and cirrhosis in 746 patients: long-term results of percutaneous ethanol injection. *Radiology* 1995; 197: 101–8.
45. Lin SM, Lin CJ, Lin CC et al. Radiofrequency ablation improves prognosis compared with ethanol injection for hepatocellular carcinoma  $\leq 4$  cm. *Gastroenterology* 2004; 127: 1714–23.
46. Mazzaferro V, Battiston C, Perrone S et al. Radiofrequency ablation of small hepatocellular carcinoma in cirrhotic patients awaiting liver transplantation: a prospective study. *Ann Surg* 2004; 240: 900–9.
47. Lo CM, Ngan H, Tso WK et al. Randomized controlled trial of transarterial lipiodol chemoembolization for unresectable hepatocellular carcinoma. *Hepatology* 2002; 35: 1164–71.
48. Llovet JM, Bruix J. Systematic review of randomized trials for unresectable hepatocellular carcinoma: chemoembolization improves survival. *Hepatology* 2003; 37: 429–42.
49. Yeo W, Mok TS, Zee B et al. A randomized phase III study of doxorubicin versus cisplatin/interferon  $\alpha$ -2b/doxorubicin/fluorouracil (PIAF) combination chemotherapy for unresectable hepatocellular carcinoma. *J Natl Cancer Inst* 2005; 97: 1532–8.
50. Lau WY, Ho SK, Yu SC et al. Salvage surgery following downstaging of unresectable hepatocellular carcinoma. *Ann Surg* 2004; 240: 299–305.





# Carcinoma of the biliary tree and gallbladder

19

George Miller and William Jarnagin

## CARCINOMA OF THE BILIARY TRACT

### Classification and epidemiology

Adenocarcinoma of the biliary tree, or cholangiocarcinoma, is subclassified according to the anatomic site of origin (Figure 19.1). Tumors arising from the extrahepatic bile ducts are the most common. Those involving the biliary confluence, also known as hilar cholangiocarcinoma, account for approximately 60% of all cases. Tumors originating in the mid- or lower bile duct account for 20–30% of all cases and are referred to as distal cholangiocarcinomas. Cholangiocarcinoma arising from biliary radicles within the liver, or intrahepatic cholangiocarcinoma, are the least common, accounting for approximately 10% of cases, although the incidence of this type is increasing. Less than 10% of patients will present with multifocal or diffuse involvement of the biliary tree.

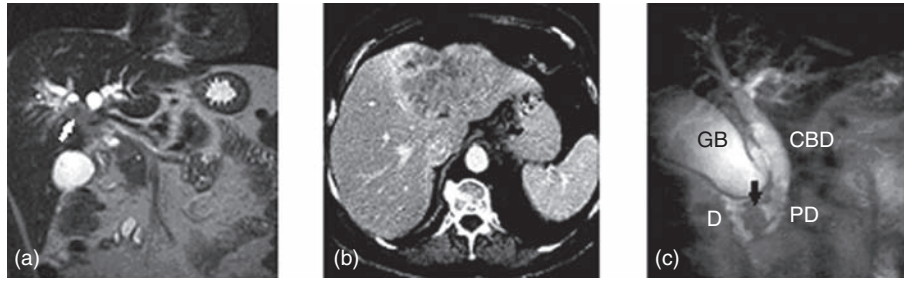
Altogether, cholangiocarcinoma accounts for approximately 3% of gastrointestinal malignancies worldwide. However, incidence varies widely between geographic regions and is likely related to the distribution of risk factors for this disease. The highest incidence of intrahepatic cholangiocarcinoma worldwide is in northeast Thailand where 96 per 100 000 men and 38 per 100 000 women are affected. In contrast, the incidence rates among Australian men and women are 0.2 and 0.1 per 100 000, respectively. In the US, approximately 5000 new cases of cholangiocarcinoma are diagnosed each year. Overall, men are affected 1.5 times more commonly than women and Asians have twice the incidence of whites and blacks. Cholangiocarcinoma is rare before the age of 40 and most cases are diagnosed in individuals older than 65. Recent data show that the incidence of intrahepatic cholangiocarcinoma is increasing worldwide, while the incidence of extrahepatic cholangiocarcinoma is declining. For example, in the US, the age-adjusted incidence of intrahepatic cholangiocarcinoma increased by 165% from the late 1970s to the late 1990s, while the incidence of extrahepatic cholangiocarcinoma declined by 14% over this period<sup>1</sup>.

### Etiology

Most cases of cholangiocarcinoma in the US and Europe occur in patients without any known predisposing risk factors. However, a number of conditions have been found to predispose to the development of cholangiocarcinoma. Primary sclerosing cholangitis (PSC), an inflammatory condition characterized by destruction and fibrosis of the intrahepatic and extrahepatic bile ducts and often complicated by biliary stricture, recurrent bacterial cholangitis and hepatic parenchymal dysfunction, is a strong risk factor for the development of cholangiocarcinoma. In a Swedish study of 305 patients with PSC, 8% eventually developed cholangiocarcinoma<sup>2</sup>. Moreover, in autopsy studies, up to 40% of individuals with PSC harbored foci of cholangiocarcinoma<sup>3</sup>. Approximately 75% of patients with PSC also suffer from ulcerative colitis. Nevertheless, only approximately 5% of the total cohort of ulcerative colitis patients ever develop PSC. For patients with PSC who go on to develop cholangiocarcinoma, the prognosis is worse than for the general cholangiocarcinoma population because the disease tends to be multifocal at presentation. In addition, resection is usually not possible because of underlying liver parenchymal disease.

Congenital biliary cystic disease (i.e. choledochal cysts, Caroli's disease), an uncommon heterogeneous condition characterized by cystic dilatation of the intrahepatic and/or extrahepatic bile ducts, is strongly associated with the development of cholangiocarcinoma<sup>4</sup>. The incidence of cholangiocarcinoma is as high as 20% in patients with choledochal cysts left *in situ*. Carcinogenesis in these patients is thought to be related to reflux of pancreatic secretions into the biliary tree resulting in chronic inflammation and bacterial contamination. Reflux is likely to be the result of an abnormal pancreaticobiliary duct union<sup>5</sup>.

Intrahepatic gallstone disease, or hepatolithiasis, an entity more commonly seen in Japan and Southeast Asia, is associated with cholangiocarcinoma in approximately 10% of cases. In a Taiwanese review of 48 patients who underwent hepatic resection for peripheral cholangiocarcinoma, 67% of patients had associated intrahepatic stones<sup>6</sup>.



**Figure 19.1** Three types of cholangiocarcinoma based on anatomic location. (a) Hilar cholangiocarcinoma. A coronal magnetic resonance (MR) image through the upper abdomen shows a mass (arrow) at the confluence of the left and right hepatic ducts causing proximal intrahepatic biliary ductal dilatation. (b) Intrahepatic cholangiocarcinoma. An axial computed tomography (CT) image shows a large heterogeneous mass occupying most of the left liver and causing umbilication of the liver surface. (c) Distal cholangiocarcinoma. A magnetic resonance cholangiopancreatography (MRCP) coronal image shows a mass (arrow) at the distal common bile duct (CBD) near its confluence with the pancreatic duct (PD) before entry into the duodenum (D). The proximal bile duct and gallbladder (GB) are distended.

It is likely that recurrent bacterial cholangitis secondary to bile stasis from obstructing stones contributes to cholangiocarcinogenesis. Parasitic infestations of the biliary tract (*Clonorchis sinensis*, *Opisthorchis viverrini*) are endemic in parts of Asia and are also associated with the development of cholangiocarcinoma. A case-control study in northeast Thailand showed that at least two-thirds of cases of cholangiocarcinoma in that region were attributable to *Opisthorchis viverrini* infection<sup>7</sup>. Recently, it has been suggested that hepatitis C virus (HCV) infection may also be associated with the development of cholangiocarcinoma. In a Japanese case-control study, HCV seropositivity was detected in 36% of intrahepatic cholangiocarcinoma patients compared with just 3% of controls. The odds ratio for the association of anti-HCV antibodies with the development of cholangiocarcinoma was 16.9<sup>8</sup>. Furthermore, the cumulative rates of newly diagnosed cases of cholangiocarcinoma in patients with HCV-associated cirrhosis was about 1000 times higher than the incidence of cholangiocarcinoma in the general Japanese population<sup>9</sup>. Smoking, alcohol consumption and exposure to toxins such as thorostat have also been implicated in cholangiocarcinogenesis.

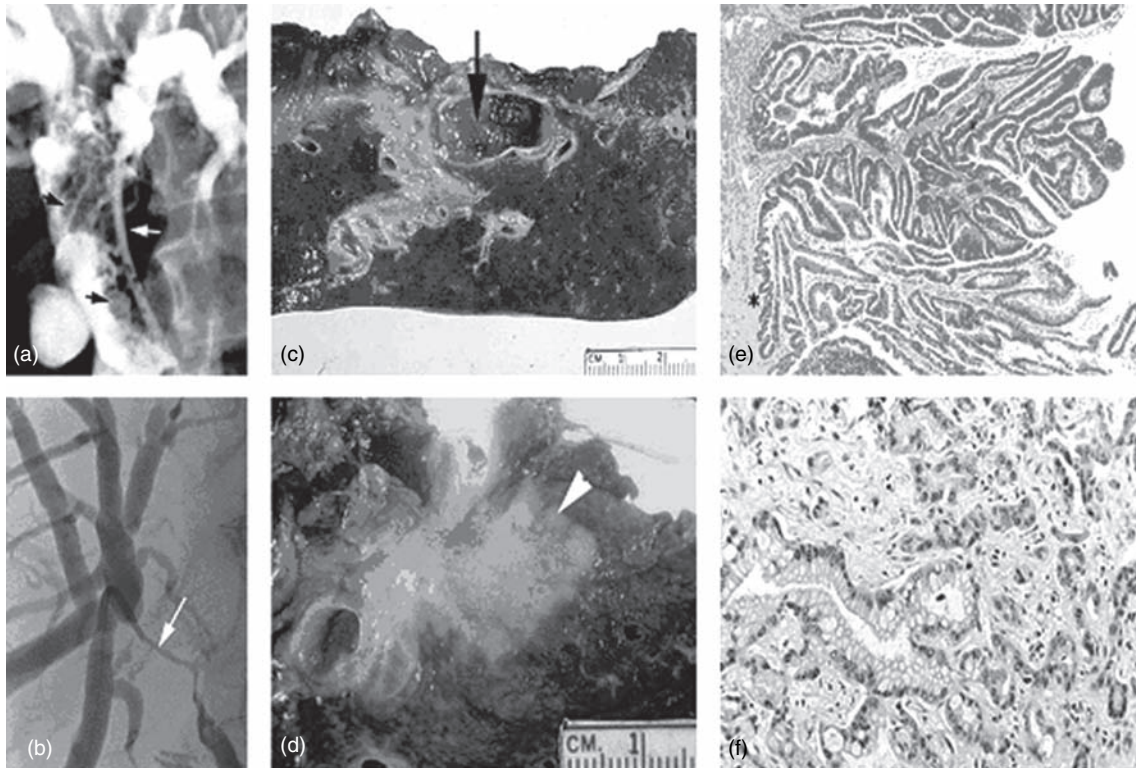
Recent sobering evidence has suggested that surgical manipulation or reconstruction of the biliary tree may also predispose to the development of cholangiocarcinoma. In a follow-up of 108 patients who underwent transduodenal sphincteroplasty for benign conditions, Hakamada *et al.*<sup>10</sup> found a 7.4% incidence of cholangiocarcinoma at an interval of 1–20 years after the procedure. Tocchi *et al.*<sup>11</sup> followed 1003 patients who underwent either transduodenal sphincteroplasty, choledochoduodenostomy, or hepaticojejunostomy between 1967 and 1997, and noted that 55 patients (5.5%) eventually developed cholangiocarcinoma. The mechanism of carcinogenesis after a biliary-enteric procedure is uncertain, but appears

to be related to reflux of pancreatic secretions into the biliary tree, resulting in chronic inflammation and bacterial contamination.

### Histopathology

The overwhelming majority of extrahepatic cholangiocarcinomas are adenocarcinomas. Most are firm, sclerotic tumors containing a paucity of cellular components within a dense fibrotic, desmoplastic background (Figure 19.2). As a consequence, non-diagnostic preoperative biopsies are common. In contrast to the sclerotic type, papillary tumors represent a less common morphological variant, accounting for approximately 10% of tumors arising from the extrahepatic biliary tree<sup>13</sup>. Papillary tumors are soft and friable. They may be associated with little transmural invasion and are characterized by a mass that expands rather than contracts the duct (Figure 19.2). Although papillary tumors may grow to a significant size, they often arise from a well-defined stalk, with the bulk of the tumor mobile within the ductal lumen. Recognition of this variant is important since they are more often resectable and have a more favorable prognosis than the sclerotic tumors<sup>12</sup>.

In considering intrahepatic cholangiocarcinoma, gross examination usually reveals a gray scirrhous mass, which is usually infiltrative with a poorly defined tumor edge. Histopathologically, these tumors are also adenocarcinomas and the diagnosis of intrahepatic cholangiocarcinoma should be considered in patients presenting with a presumptive diagnosis of metastatic adenocarcinoma in which a primary lesion cannot be found, particularly if they have a single, solitary hepatic mass. A small number of intrahepatic cholangiocarcinomas contain focal areas of papillary carcinoma with mucus production, signet ring cell, squamous cell, mucoepidermoid, and spindle cell variants.



**Figure 19.2** Cholangiographic, gross and microscopic appearance of a papillary cholangiocarcinoma (a) (c) and (e), and a nodular-sclerosing tumor (b) (d) and (f), respectively. Transhepatic cholangiogram of a papillary hilar cholangiocarcinoma (a) showing multiple filling defects that expand the bile duct (black arrows; the biliary drainage catheter is indicated by the white arrow). This is in contrast to the cholangiographic features of nodular-sclerosing tumors characterized by an irregular stricture that constricts the bile duct lumen (b) (arrow); a transhepatic catheter is seen traversing the stricture. On examination of the cut gross specimens, note the papillary tumor within the bile duct lumen (c) (arrow) and the nodular-sclerosing tumor invading the hepatic parenchyma (d) (arrowhead). A histological section of a papillary cholangiocarcinoma is shown with no invasive component (e) (asterisk) and an invasive nodular-sclerosing tumor associated with a desmoplastic stroma (f). From reference 12, with permission.

## HILAR CHOLANGIOCARCINOMA

### Clinical presentation and diagnosis

In more than 90% of cases, patients harboring a hilar cholangiocarcinoma present to medical attention because of jaundice. The jaundice is typically progressive but can be intermittent in cases where the tumor is mobile within the lumen of the biliary tree and causes a ball-valve-like obstructive effect at the hepatic duct confluence. Patients with unilateral duct obstruction or segmental obstruction may not become jaundice early in their disease course but may eventually present with abnormal liver function tests and correlative imaging findings of ipsilateral lobar atrophy without overt jaundice.

Associated symptoms include purities (30%), weight loss (29%) and abdominal pain (20%). Fever (9%) is less common and frank cholangitis is actually rare at initial presentation. However, patients who have undergone endoscopic or percutaneous instrumentation of their

biliary tree more commonly present with cholangitis early in their disease course. In fact, the rate of *bacteribilia* is nearly 100% in patients with hilar cholangiocarcinoma who have been instrumented compared with 30% for those who have not<sup>14</sup>. Physical examination generally does not contribute a great deal to the diagnosis of cholangiocarcinoma. In fact, besides jaundice, physical findings are few. The liver edge may occasionally be palpable as a result of hepatic enlargement from biliary obstruction. The gallbladder is usually decompressed in hilar cholangiocarcinoma and a palpable gallbladder suggests a more distal obstruction. Rarely, patients with long-standing biliary obstruction and/or portal vein involvement may have physical findings consistent with portal hypertension.

Laboratory tests usually reveal elevated serum levels of alkaline phosphatase,  $\gamma$ -glutamyl transpeptidase and bilirubin. The total level of bilirubin may help distinguish cholangiocarcinoma from choledocholithiasis. In the latter scenario, bilirubin levels are typically in the 2–4 mg/dl

range, while patients with an obstructing hilar cholangiocarcinoma usually have total bilirubin levels greater than 10 mg/dl and average 18 mg/dl. Approximately 70% of cholangiocarcinomas overexpress carcinoembryonic antigen (CEA) and carbohydrate antigen (CA) 19-9<sup>15</sup>. However, the lack of specificity of these tests makes them of limited diagnostic utility.

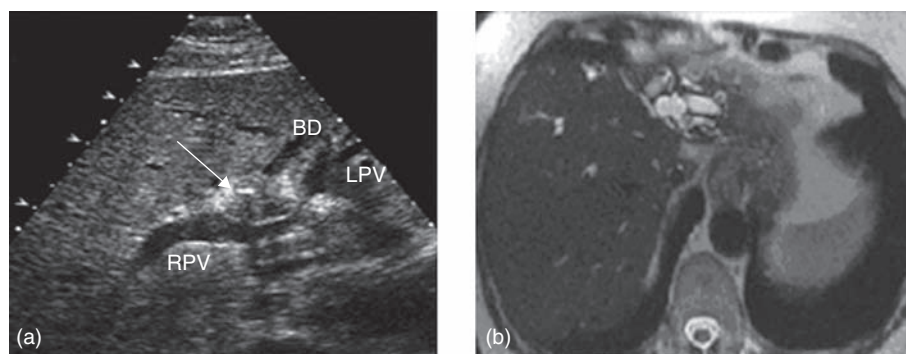
### Radiological investigations

While clinical signs and symptoms, physical examination and laboratory studies may suggest hilar cholangiocarcinoma, definitive diagnosis requires in depth radiographic investigation. In addition, imaging studies also serve as the primary modality to evaluate surgical resectability. However, it must be cautioned that other conditions may mimic hilar cholangiocarcinoma on imaging studies including benign focal stenosis of the hepatic ducts, Mirizzi's syndrome resulting from a large stone impacted in the neck of the gallbladder, and gallbladder cancer<sup>16</sup>. The basic imaging algorithm for the diagnosis of hilar cholangiocarcinoma has been revolutionized in the past decade. Until recently, invasive techniques such as transhepatic percutaneous cholangiography (PTC) and celiac and mesenteric angiography, combined with computed tomography (CT) were required to make the diagnosis and determine resectability. However, besides being invasive in nature, recent studies have found that preoperative biliary instrumentation, particularly when combined with biliary stenting, increases perioperative infection complications<sup>14,17</sup>. This, combined with the rapid technological developments that have resulted in improvements in the quality of magnetic resonance cholangiography, have led to the authors' current practice of utilizing non-invasive imaging (duplex ultrasound combined with magnetic resonance (MR) cholangiopancreatography

(MRCP)) with good determination of the disease extent and the potential resectability.

Ultrasound is the least expensive and often the initial imaging modality used in the jaundiced patient. At a minimum, ultrasound will provide accurate information regarding the level of biliary obstruction. The major limitation of ultrasound is in delineating the precise extent of tumor infiltration. Furthermore, ultrasound is entirely operator dependent and requires a skilled technician. Nevertheless, in experienced hands, ultrasonography with color spectral Doppler technique has been shown to be equivalent to angiography and CT portography in diagnosing lobar atrophy, level of biliary obstruction, hepatic parenchymal involvement, and venous invasion (Figure 19.3). In a series of 63 consecutive patients, duplex ultrasonography predicted portal vein involvement with a 93% sensitivity, 99% specificity and 97% positive predictive value<sup>18</sup>.

Because of its intrinsic high tissue contrast and multiplanar capability, MRI can accurately investigate all relevant structures such as bile ducts, vessels and hepatic parenchyma (Figure 19.3). On MRCP images, hilar cholangiocarcinoma appears as an irregular thickening of the bile duct wall with symmetric upstream dilatation of the intrahepatic bile ducts. MRCP has been shown to be equivalent to invasive endoscopic or percutaneous cholangiography in the evaluation of the level of biliary obstruction and the anatomy of the biliary tree<sup>19,20</sup>. Furthermore, MRCP provides the best available information on the extent of intrahepatic tumor spread, the degree of hilar vascular involvement, the presence of lobar atrophy, and the possibility of nodal or distant spread. In the authors' view, in patients with appropriate non-invasive imaging and in the proper clinical setting, histological confirmation of malignancy is not mandatory prior to exploration. In fact, biopsies or brushings which are taken at



**Figure 19.3** Hilar tumors obstructing portal venous flow result in ipsilateral hepatic lobar atrophy. (a) Sonogram illustrating a hilar cholangiocarcinoma (arrow) causing obstruction of the left portal vein (LPV) and involving the left hepatic duct (BD) with a patent right portal vein (RPV). (b) An axial magnetic resonance image from the same patient shows a small atrophic left hepatic lobe with crowded dilated ducts (arrow).



the time of endoscopic or percutaneous cholangiography are often non-diagnostic.

Cholangiography effectively demonstrates both the location of the tumor and the extent of disease within the bile ducts. Although endoscopic retrograde cholangiography (ERCP) may provide some helpful information, percutaneous transhepatic cholangiography (PTC) displays the intrahepatic bile ducts more reliably and has been the preferred approach. However, because cholangiography only provides data on disease within the biliary tree, information regarding extraductal hepatic or vascular invasion, lobar atrophy, and distant or nodal disease cannot be obtained without complementary imaging. Similarly, direct cholangiography alone may not be able to distinguish hilar cholangiocarcinoma from other causes of biliary obstruction such as benign stricture, metastases to periportal lymph nodes, or gallbladder cancer invading the hepatoduodenal ligament.

CT scans are often obtained in patients with hilar cholangiocarcinoma before referral to specialty units. While it had been difficult to diagnose cholangiocarcinoma with conventional CT imaging, modern spiral CT scanners can supply valuable information regarding the level of obstruction, vascular involvement and lobar atrophy. However, CT imaging tends to underestimate the proximal extent of tumor within the bile duct and is not ideal for the determination of resectability<sup>21</sup>.

### Assessment of resectability

Complete surgical resection is the only potentially curative option in patients with hilar cholangiocarcinoma. In general terms, determination of surgical resectability is made by examining patient-related factors, local disease-related factors and distant disease-related factors (Table 19.1).

In terms of patient-related factors, since the vast majority of complete resections of hilar cholangiocarcinoma will require a partial hepatectomy, the treating surgeon must determine the patient's fitness to undergo this operation. The presence of significant cardiopulmonary disease, Child's B or C liver cirrhosis, or portal hypertension precludes resection. In patients who present with biliary sepsis from prior intubation of their biliary tree, fluid resuscitation and control of the infectious process are required before embarking on surgery.

Determination of resectability based on local disease-related factors requires considerable experience and judgment. In the most basic terms, resectable tumors must be amenable to complete extirpation while preserving a well-perfused hepatic remnant with adequate biliary drainage. Assessment of the feasibility of this goal requires evaluation of three crucial determinants resectability: extent of tumor

progression within the biliary tree, extent of portal venous invasion, and the presence of hepatic lobar atrophy (Table 19.1). In terms of tumor progression within the biliary tree, involvement of secondary biliary radicles on imaging studies mandates hepatic resection, while progression into secondary biliary radicles bilaterally defines unresectability. Similarly, ipsilateral portal venous involvement also necessitates hepatectomy for complete resection, while encasement of either both portal veins, or the main portal venous trunk, generally precludes resection. Furthermore, any combination of ipsilateral portal venous encasement and contralateral involvement of secondary biliary radicals prohibits resection. Another indicator of portal venous involvement with tumor, besides obvious vascular encasement, is hepatic lobar atrophy. This finding implies portal venous involvement, but occasionally can be seen with complete, prolonged unilateral biliary obstruction, and mandates a partial hepatectomy as part of the surgical approach. Atrophy is considered to be present if cross-sectional imaging demonstrates a small, often hypoperfused lobe with crowding of the dilated intrahepatic ducts (Figure 19.3). In contrast to the importance of portal venous involvement, hepatic arterial invasion is less commonly a critical factor in determining resectability.

Determination of distant spread requires assessment of the presence of metastatic or distant nodal deposits. Cholangiocarcinoma has a propensity to spread to regional

**Table 19.1** Criteria of unresectability in patients with hilar cholangiocarcinoma

#### *Patient factors*

Medically unfit or otherwise unable to tolerate a major operation

Hepatic cirrhosis

#### *Local tumor-related factors*

Tumor extension to secondary biliary radicles bilaterally

Encasement or occlusion of the main portal vein proximal to its bifurcation

Atrophy of one hepatic lobe with contralateral portal vein branch encasement or occlusion

Atrophy of one hepatic lobe with contralateral tumor extension to secondary biliary radicles

Unilateral tumor extension to secondary biliary radicles with contralateral portal vein branch encasement or occlusion

#### *Metastatic disease*

Histologically proven metastases to distant lymph nodes

Lung, liver, or peritoneal metastases

From reference 22, with permission.

lymph nodes and the liver, but other sites, including lung and peritoneum are also potential sites. Resection is generally not indicated in the presence of peritoneal or solid organ metastases. Likewise, involvement of peripancreatic, paraduodenal, celiac, superior mesenteric, and posterior pancreaticoduodenal lymph nodes often denotes advanced disease that is not amenable to complete resection, although long-term survival has been reported<sup>23,24</sup>. Enlarged lymph nodes can be found on preoperative MRI or CT. Suspicious lymph nodes may then be biopsied percutaneously, using endoscopic ultrasound guidance, or intraoperatively before proceeding with resection, provided that the finding of metastatic disease would change the treatment plan. The role of laparoscopy in determining the presence of distant disease in hilar cholangiocarcinoma has recently been evaluated. In a series of 56 patients thought to be resectable by conventional imaging studies, 14 (25%) were found to have peritoneal, distant solid organ, or distant nodal disease on diagnostic laparoscopy, sparing these patients an unnecessary laparotomy<sup>25</sup>. However, positive cytology from peritoneal washings in the absence of visible metastases was not predictive of occult metastatic disease<sup>26</sup>.

In many centers, primarily in Japan, a very detailed approach to definition of resectability is often used and is based on direct cholangiography of segmental ducts and cholangioscopy<sup>27</sup>. This approach generally involves placement of multiple percutaneous biliary drainage catheters in order to allow complete access to the biliary tree and is often combined with preoperative portal vein embolization in an effort to lower the risk of postoperative hepatic failure. Such an aggressive diagnostic evaluation appears to increase the resectability but requires a prolonged hospital stay and its ultimate value is unclear<sup>27,28</sup>.

## Staging

The most commonly cited staging systems for cholangiocarcinoma are the American Joint Committee on Cancer (AJCC) system and the modified Bismuth-Corlette

classification. The AJCC system is based largely on pathological criteria and has little clinical utility for preoperative decision-making. The modified Bismuth-Corlette classification merely describes the extent of tumor progression within the biliary tree but fails to include portal venous invasion and lobar atrophy, which are of considerable importance in determining resectability. Moreover, the above-mentioned staging systems correlate poorly with survival. The ideal staging system should accurately predict resectability and correlate with patient survival. Such a system would assist the surgeon in formulating a treatment plan and help the patient to understand the treatment options and outcome. Based on these principles, the hepatobiliary disease management group at Memorial Sloan-Kettering Cancer Center has proposed a T staging system that takes into account data from preoperative imaging studies including biliary ductal involvement, portal venous invasion, and lobar atrophy (Table 19.2). This system correlates well with resectability and survival (Table 19.3). In addition, the likelihood of metastatic

**Table 19.2** Proposed T stage criteria for hilar cholangiocarcinoma

T1	Tumor involving biliary confluence ± unilateral extension to 2° biliary radicles
T2	Tumor involving biliary confluence ± unilateral extension to 2° biliary radicles And <i>ipsilateral</i> portal vein involvement ± <i>ipsilateral</i> hepatic lobar atrophy
T3	Tumor involving biliary confluence + bilateral extension to 2° biliary radicles Or unilateral extension to 2° biliary radicles with <i>contralateral</i> portal vein involvement Or unilateral extension to 2° biliary radicles with <i>contralateral</i> hepatic lobar atrophy Or main or bilateral portal venous involvement

From reference 22, with permission.

**Table 19.3** Association between T stage and resectability and survival post-resection in hilar cholangiocarcinoma

T stage	n	Explored with curative intent	Resected	Negative margins	Median survival (months)
1	87	73 (84%)	51 (59%)	38 (75%)	20
2	95	79 (83%)	29 (31%)	24 (83%)	13
3	37	8 (22%)	0	0	8
Total	219	160 (71%)	80 (37%)	62 (77%)	16

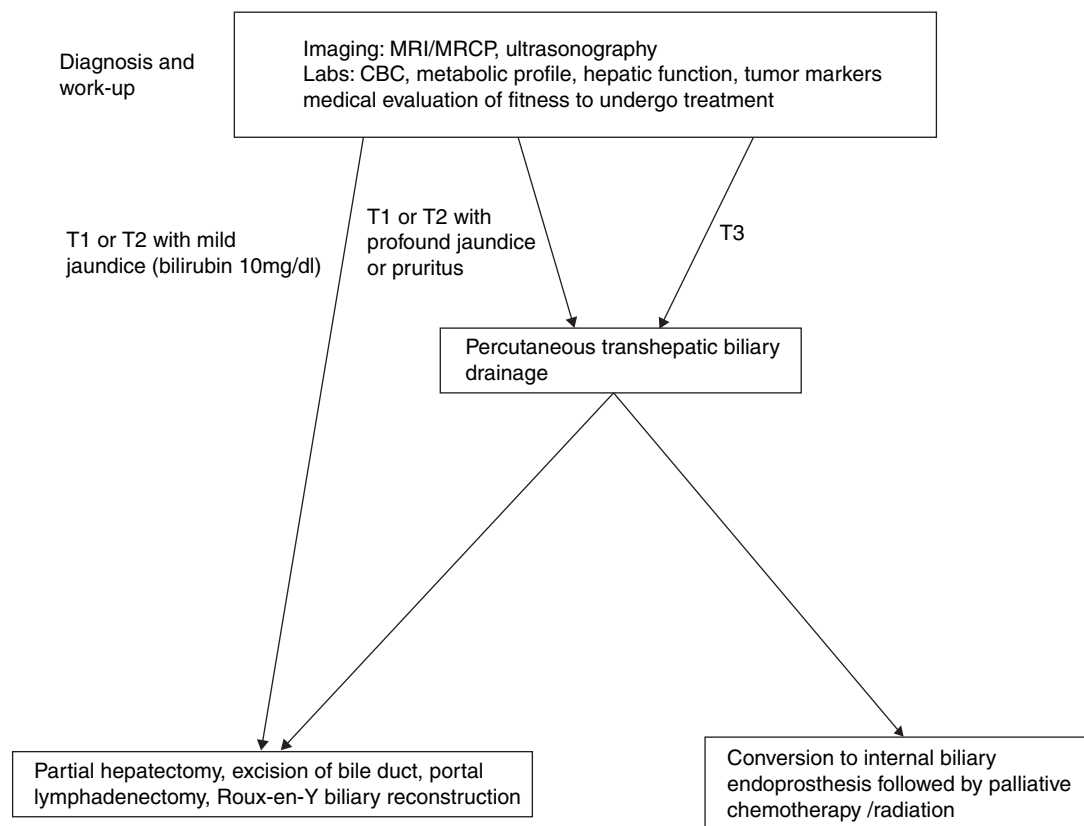
From reference 22, with permission.

disease increases with higher clinical T stage<sup>22</sup>. An algorithm for the management of patients with hilar cholangiocarcinoma by T stage is shown in Figure 19.4.

### Surgical technique

The principal objective in operation for hilar cholangiocarcinoma is complete resection with negative histological margins. The latter almost invariably requires an en bloc hepatectomy. In fact, a number of studies have shown good correlation between the performance of a partial hepatectomy and negative histological margins (Table 19.4). As discussed above, for patients who undergo operation for potentially resectable disease, surgery should commence with a diagnostic laparoscopy, looking for evidence of distant or locally advanced unresectable disease, especially in more locally advanced tumors. If laparoscopy fails to reveal any suspicious findings, open operation is begun and includes an exploration for low volume peritoneal metastases and celiac nodal disease, bimanual palpation of the liver, and a generous Kocher maneuver to expose the retropancreatic lymph

nodes. If these maneuvers fail to reveal unresectable disease, definitive resection is begun. The general approach to hepatic resection is low central venous pressure anesthetic management with inflow and outflow control before hepatic parenchymal transection. The hilus is exposed by resecting the gallbladder and lowering the hilar plate by incising the peritoneum at the base of segment IV. This allows palpation of the tumor and gross determination of its extension in the bile duct. The distal common bile duct is then divided above the second portion of the duodenum and the divided bile duct along with all overlying lymphatic tissues of the hepatoduodenal ligament is dissected cephalad so as to skeletonize the hepatic artery and portal vein. A frozen section of the distal bile duct is sent to pathology to confirm negative distal margins. The involvement of vascular structures by tumor and the proximal extent of tumor are then assessed, which will provide some guidance regarding the extent of hepatectomy required. Caudate resection is additionally performed for all tumors extending into the left hepatic duct or if there is otherwise concern regarding involvement of the caudate ducts. A dilated caudate duct on



**Figure 19.4** Algorithm for the work-up and management of patients with hilar cholangiocarcinoma. Patient with T3 tumors without pruritus who do not desire palliative chemotherapy may forgo biliary drainage. MRI, magnetic resonance imaging; MRCP, magnetic resonance cholangiopancreatography; CBC, complete blood count.



**Table 19.4** Summary of selected series of hilar cholangiocarcinoma showing the relationship between the rate of partial hepatectomy and proportion of negative histological margins achieved

<i>Author</i>	<i>Complete gross resection (n)</i>	<i>Partial Hepatectomy (%)</i>	<i>Negative Margin (%)</i>
Cameron (1990) <sup>29</sup>	39	20	15
Hadjis (1990) <sup>30</sup>	27	60	56
Nimura (1990) <sup>31</sup>	55	98	83
Klempnauer (1997) <sup>32</sup>	147	79	79
Gerhards (2000) <sup>33</sup>	112	29	14
Neuhaus (1999) <sup>34</sup>	95	85	61
Tsao (2000) <sup>36</sup>	25	16	28
Jarnagin (2001) <sup>22</sup>	80	78	78
Dinant (2006) <sup>36</sup>	99	31	38

cross-sectional imaging implies caudate lobe involvement with tumor and generally mandates caudate lobectomy.

### Outcomes after resection

Following resection with curative intent, the median survival in patients with hilar cholangiocarcinoma ranges from 20 to 35 months. The reported 5-year survival rate ranges from 8 to 40%<sup>37</sup>. Again, there is again a strong correlation between concomitant partial hepatectomy, associated negative margins and extended survival. This point is emphasized by the recently reported Dutch series of 99 consecutive resections for hilar cholangiocarcinoma accumulated over a 15-year interval. In this study, there was a progressive increase over time in the proportion of patients subjected to partial hepatectomy, with a corresponding increase in the incidence of negative histological margins and in survival<sup>36</sup>. Another study from Memorial Sloan Kettering Cancer Center reported results of resection in 106 patients and showed a median survival of 43 months in patients who underwent an R0 resection compared with 24 months in those with positive resection margins<sup>12</sup>. Multivariate analysis showed that an R0 resection, a concomitant hepatic resection, well differentiated histology, and papillary tumor phenotype were independent predictors of long-term survival in patients with hilar tumors.

### Treatment alternatives and adjuvant therapy

Orthotopic liver transplantation has been attempted for hilar cholangiocarcinoma with mixed results. Klempnauer *et al.*<sup>32</sup> reported only a 12% 5-year survival rate among 32 patients who underwent liver transplant

for unresectable disease. Pichlmayr *et al.*<sup>38</sup> reported a 17% 5-year survival rate after transplantation, but this was tempered by a 12% perioperative mortality rate. More recently, using a protocol involving neoadjuvant chemotherapy, Rea *et al.*<sup>39</sup> reported a 5-year survival rate of 82% after orthotopic liver transplantation for patients with unresectable hilar cholangiocarcinoma. This was superior to their reported 48% 5-year survival rate in patients undergoing surgical resection which included a partial hepatectomy. These results, however, should be viewed with caution as the impressive outcomes were achieved in highly selected patients with low volume unresectable disease, often in the setting of PSC. Given the shortage of available organs for transplantation, further evidence is necessary before recommending the widespread use of transplantation as a first-line option in the treatment of cholangiocarcinoma:

Several studies have reported on the use of adjuvant or neoadjuvant chemotherapy and radiation therapy in patients with resectable hilar cholangiocarcinoma<sup>40,41</sup>. However, many reports combine patients with both intrahepatic and extrahepatic cholangiocarcinoma and gallbladder cancer into the same analysis which obscures the results. Furthermore, because of lack of patient randomization into different treatment arms, definitive conclusions cannot be drawn. At the present time, there is no good evidence to support the routine use of adjuvant therapy for resectable hilar cholangiocarcinoma outside the context of a controlled clinical trial.

### Palliation

The majority of patients with hilar cholangiocarcinoma are not suitable for resection. In this setting, the

management options include supportive care or some form of palliative therapy. Palliative measures may include chemotherapy, radiation therapy, photodynamic therapy, or biliary decompression. The most common indications for palliative biliary decompression include intractable pruritus or cholangitis. Jaundice alone, however, is not necessarily an indication for biliary decompression, unless required for chemotherapy treatment. Methods of biliary decompression include endoscopic stent placement, percutaneous transhepatic biliary puncture, or the surgical creation of a biliary-enteric bypass. However, hilar tumors can be difficult to transverse by endoscopic techniques and the failure rates of endoscopic stent placement and the incidence of subsequent cholangitis in these patients are high<sup>42</sup>. Therefore, of the nonoperative methods of biliary decompression, percutaneous transhepatic biliary drainage is usually preferred.

### *Percutaneous biliary drainage*

Percutaneous transhepatic biliary drainage and the subsequent placement of a self-expandable metallic endoprosthesis can be successfully performed in most patients with hilar obstruction. However, specific challenges exist in patients with hilar tumors. Frequently, all three major hilar ducts (left hepatic, right anterior sectoral hepatic and right posterior sectoral hepatic) are obstructed, and multiple stents may be required for adequate drainage. One must also consider that jaundice in these patients may result from hepatic dysfunction secondary to portal vein occlusion and not biliary obstruction. Jaundice in this setting, without intrahepatic biliary dilatation, is not correctable with biliary stents. The median patency of metallic endoprostheses at the hilus is approximately 6 months, significantly lower than that reported for similar stents placed in the distal bile duct<sup>43</sup>. Becker *et al.*<sup>44</sup> reported 1-year patency rates of 46% and 89% for stents placed at the hilus and the distal bile duct, respectively. Similarly, Stoker *et al.*<sup>45</sup> documented occlusion in 36% of patients with stents at the hilus compared with 6% of patients with stents in the distal bile duct. In most series of biliary endoprostheses placed for hilar obstruction, documented stent occlusion requiring re-intervention occurs in 25% of patients<sup>43–46</sup>.

### *Intrahepatic biliary-enteric bypass*

Patients found to be unresectable at operation after transection of the bile duct may be candidates for intrahepatic biliary-enteric bypass. The segment III duct is usually the most accessible, but the right anterior or posterior sectoral hepatic ducts can also be used<sup>47</sup>. Segment III bypass provides excellent biliary drainage and is

generally not prone to occlusion by tumor since the anastomosis can be placed at some distance away from the tumor. Relief of jaundice will be achieved if at least one-third of the functioning hepatic parenchyma is adequately drained. In a report of 20 consecutive segment III bypasses in patients with malignant hilar obstruction, the 1-year patency rate was 80% and there were no perioperative deaths<sup>47</sup>. However, patients known to have unresectable disease before operation or before division of the bile duct are probably best served with percutaneous drainage procedures.

### *Palliative radiation therapy and photodynamic therapy*

Patients with unresectable, locally advanced tumors but without evidence of widespread disease may be candidates for palliative radiation therapy. A combination of external beam radiation (5000–6000 cGy) and intraluminal iridium-192 (2000 cGy) is typically used. Several authors have demonstrated the feasibility of this approach, but improved survival compared with biliary decompression alone has not been documented in a controlled study<sup>29,48,49</sup>.

Photodynamic therapy has recently been tested in patients with unresectable hilar cholangiocarcinoma<sup>50</sup>. This method has previously been used in the treatment of carcinomas of the esophagus, colon, stomach, bronchus, bladder, and brain. Its application entails a two-step procedure. First, a photosensitizer is injected intravenously, and then 48 hours later, direct illumination of the biliary tree via cholangioscopy activates the compound leading to tumor cell death. In a randomized prospective trial of 49 patients, Ortner *et al.* showed that patients treated with either percutaneous or endoscopic stenting and photodynamic therapy had a significant survival advantage over those treated with stenting alone<sup>50</sup>.

### *Palliative chemotherapy*

In cases of advanced biliary tract cancers where curative surgical resection is impossible, palliative chemotherapy has been used with the aims of potentially improving quality of life, diminishing symptoms and prolonging survival. Only one randomized study has tested the efficacy of chemotherapy in patients with advanced biliary tract tumors<sup>51</sup>. This study included 37 patients who were randomized to receive chemotherapy (5-FU/leucovorin with or without etoposide) or best supportive care. Short-term improvements in survival (6.5 versus 2.5 months) were noted among the chemotherapy group. In addition, the treatment group also demonstrated improvement in quality of life as measured by a standard quality of life questionnaire.

Many agents (5-FU, gemcitabine, capecitabine, cisplatin, oxaliplatin, and interferon) alone or in combination have been evaluated in multiple phase I and II trials. Partial disease responses consistently range from 10 to 30%. Although no consensus has been reached regarding the standard use of chemotherapy in cases of advanced biliary tract cancer, gemcitabine as a single agent has emerged given its more favorable profile in both toxicity and disease response<sup>52</sup>. However, given the paucity of level I evidence to support the use of palliative chemotherapy in cases of advanced cholangiocarcinoma, it is best employed in the context of a clinical trial.

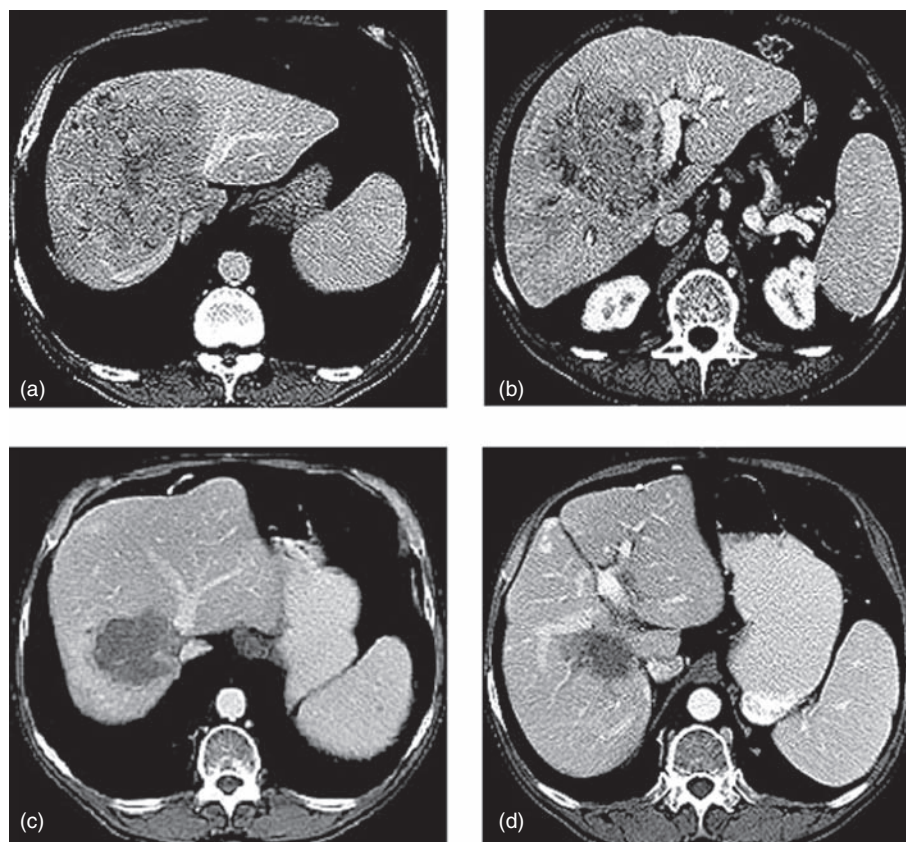
## INTRAHEPATIC CHOLANGIOCARCINOMA

### Presentation and diagnosis

In the US and western Europe intrahepatic cholangiocarcinoma is infrequently encountered and represents only 10% of biliary cancers. Of the approximately 4000 patients with primary or metastatic liver cancer seen at Memorial Sloan Kettering Cancer Center in New York

City from 1995 to 2001, only 1% had intrahepatic cholangiocarcinoma. However, in parts of Asia where parasitic infections of the biliary tree are common, intrahepatic cholangiocarcinoma accounts for up to 30% of primary hepatic malignancies<sup>53</sup>. Patients harboring an intrahepatic cholangiocarcinoma are frequently asymptomatic with the hepatic lesion discovered incidentally in the evaluation of an unrelated condition. Of patients with symptoms, abdominal pain is the most common complaint reported in 35–71% of cases. Jaundice and prurities are seen in approximately 25% of patients and their presence usually indicates compression or invasion of the biliary confluence. Weight loss, generalized malaise and non-specific gastrointestinal complaints are also frequently seen. An elevation in liver enzymes, without associated symptoms, may be the initial finding in some cases<sup>54</sup>.

Imaging of intrahepatic cholangiocarcinoma is best done with either CT scanning or MRI. On CT imaging intrahepatic cholangiocarcinoma typically appears as hypovascular lesions with central necrosis (Figure 19.5). There is frequently capsular retraction of the surrounding liver surface adjacent to the tumor. CT also provides



**Figure 19.5** Hepatic arterial infusion chemotherapy for intrahepatic cholangiocarcinoma. (a) and (b) Axial computed tomography (CT) images with intravenous contrast show a large predominantly right-sided intrahepatic cholangiocarcinoma at presentation. (c) and (d) After hepatic arterial infusion chemotherapy with floxuridine dramatic tumor shrinkage was observed.

essential information regarding tumor extension within the liver, satellite nodules, possible vascular or central biliary invasion, and presence or absence of distant disease. On MRI, intrahepatic cholangiocarcinomas are hypodense or isodense on T1-weighted images and hyperdense on T2-weighted images. The distinction of between intrahepatic cholangiocarcinoma and hepatocellular carcinoma or even metastatic liver disease preoperatively can be challenging. In comparison with hepatocellular carcinoma, intrahepatic cholangiocarcinoma is less commonly associated with chronic liver parenchymal disease. Therefore, the presence of underlying cirrhosis would suggest hepatocellular carcinoma. Liver serologies, a history of alcoholic liver disease and  $\alpha$ -fetoprotein (AFP) levels are also helpful in this regard; AFP levels are more likely to be normal in patients with intrahepatic cholangiocarcinoma. Percutaneous biopsy of intrahepatic cholangiocarcinoma will reveal adenocarcinoma, often leading to the presumptive diagnosis of metastatic cancer to the liver. However, an experienced pathologist can confirm the diagnosis of intrahepatic cholangiocarcinoma based on immunohistochemical staining of the biopsy specimen. In cases of uncertainty, a full evaluation should be carried out to exclude metastatic disease including upper and lower endoscopy, CT or MR imaging of the chest, abdomen, and pelvis and mammography in women.

### Staging and determination of resectability

The AJCC TNM classification for primary liver cancers such as hepatocellular carcinoma also applies for intrahepatic cholangiocarcinoma. However, as the biological behavior of intrahepatic cholangiocarcinoma and hepatocellular carcinoma are distinct, this staging system provides little clinical utility either in terms of preoperative assessment of resectability or in terms of prediction of outcome. The Liver Cancer Study Group of Japan established a useful classification based on the macroscopic appearance of intrahepatic cholangiocarcinoma<sup>55</sup>. Three distinct types were established: mass-forming type, periductal-infiltrating type and intraductal growth type. The mass-forming type is typically an encapsulated mass, is located within the liver parenchyma, and does not invade a major portal branch. Nearly 80% of intrahepatic cholangiocarcinomas are of the mass-forming type and this type is believed to be associated with the best overall survival. The periductal-infiltrating type is defined as a tumor which extends mainly longitudinally along the outside of a bile duct, often resulting in dilatation of the peripheral bile duct. The intraductal growth type proliferates within the lumen of the bile duct like a tumor thrombus. Combinations of the three macroscopic categories have also been described.

Besides macroscopic descriptive categories, a TNM classification of intrahepatic cholangiocarcinoma was also designed by the Liver Cancer Study Group of Japan based on analysis of 136 cases of the mass-forming type that were completely resected between 1990 and 1996<sup>55</sup>. Multivariate analyses showed that three factors had positive prognostic value in terms of survival: tumor size less than 2 cm, the presence of a single nodule and the absence of vascular or serous membrane invasion. T stages were thus defined as follows: T1 tumors contain all three positive prognostic factors, T2 tumors contain two factors, T3 tumors have one positive prognostic factor, and T4 tumors have none of the positive predictive elements. N stages were defined as N0 had no lymph node metastasis and N1 denotes metastases to any nodal basin. No distinction was made between hepatoduodenal lymph nodes and distant lymph nodes based on the data. Thus, the stages of intrahepatic cholangiocarcinoma were defined as stage I, T1N0M0; stage II, T2N0M0; stage III, T3N0M0; stage IVA, T4N0M0 or any TN1M0; and stage IVB, any T any NM1. Approximate 4-year survival rates after complete resection were 100% for stage I, 70% for stage II, 45% for stage III, and 10% for stage IV<sup>55</sup>.

The reported resectability rate of patients presenting with intrahepatic cholangiocarcinoma has varied from 46 to 90%<sup>56,57</sup>. Even after extensive preoperative work-up, patients deemed resectable are often found to have unresectable disease in the operating room. A report from Memorial Sloan Kettering Cancer Center found that approximately two-thirds of patients with intrahepatic cholangiocarcinoma who were thought to be resectable on preoperative imaging were actually resectable at operation<sup>58</sup>. Laparoscopy may be used to assess resectability before proceeding with laparotomy. Determinants of lack of resectability include vascular invasion of the main portal vein or the contralateral lobar portal vein, distant metastases, peritoneal spread, metastatic disease to celiac or retropancreatic lymph nodes, or multiple intrahepatic metastasis. Satellite hepatic lesions are considered surrogate markers for vascular invasion. It is unclear if resecting tumors with a limited number of satellite lesions offers a survival advantage but the authors tend to favor resection in such cases. Likewise, the question of proceeding with resection in the presence of regional nodal metastases remains unsettled. Long-term survival in a small number of patients with metastatic disease to hepatoduodenal lymph nodes has been reported but is rare. However, metastatic disease to celiac or retroperitoneal lymph nodes is likely a contraindication to resection. Additionally, underlying liver cirrhosis and significant medical co-morbidities may also preclude resection.

## Treatment options and outcomes

The only currently available potentially curative modalities for the treatment of intrahepatic cholangiocarcinoma are hepatic resection and orthotopic liver transplantation. Hepatic resection requires negative margins. The extent of resection required is dictated by both the location and extent of the tumor. Most patients with intrahepatic cholangiocarcinoma present with large tumors and a major partial hepatectomy is usually required to achieve an R0 resection. However, a more limited resection may suffice in some patients with smaller tumors. Patients with tumor involvement of the biliary confluence will also require a bile duct resection and reconstruction. The benefits of subhilar lymphadenectomy in these cases in terms of survival are uncertain. However, at a minimum, this provides useful staging information.

The reported median survival after resection of intrahepatic cholangiocarcinoma ranges from 8 to 50 months<sup>59,60</sup>. The reported 5-year survival rate after complete resection is as high as 48% (Table 19.5). In a report from Memorial Sloan Kettering Cancer Center, the actuarial 3-year survival rate after complete resection was 55% compared with 21% for patients undergoing biopsy only<sup>58</sup>. However, disease recurrence is very common, even after an R0 resection. The median time to recurrence ranges from 12 to 20 months. The most common site of recurrence is the liver remnant, which is seen in up to 70% of patients with recurrent disease. Recurrent disease in regional lymph nodes, lung and bone is also seen with some frequency, ranging from 4 to 30%<sup>54</sup>. In the report from Weber *et al.*<sup>58</sup>, three significant predictors of local recurrence were identified: the presence of multiple tumors, vascular invasion, and tumor size.

Orthotopic liver transplantation has been utilized in the management of some patients. The largest series of patients undergoing transplantation for intrahepatic cholangiocarcinoma ( $n = 186$ ) was reported by the European Liver Transplant Registry and showed 1-, 3-, 5-, 8-, and 10-year survival rates of 58%, 38%, 29%, 23%, and 21%, respectively<sup>65</sup>. Large tumor size, lymph node involvement and contiguous organ infiltration were predictors of poor outcome after transplantation. Highly selected patients with small early stage node negative tumors are most likely to achieve long-term survival after transplantation. Furthermore, data from the Mayo clinic suggest that pre-operative chemoradiation may further improve results<sup>39</sup>. However, given the critical shortage of liver grafts and the uncertain benefits of transplantation over resection, transplantation for intrahepatic cholangiocarcinoma is not performed in most centers, unless it is done in the context of a clinical trial.

## Adjuvant therapy

The very high recurrence rate after resection represents a major limitation of surgery. Clearly, effective adjuvant therapy is necessary if further improvements in mortality related to this disease are to be made. However, the use of chemotherapy, including 5-FU or other agents, has not been shown to improve survival, either as adjuvant therapy following resection or in patients with unresectable lesions<sup>66</sup>. External beam radiation therapy, intraoperative radiation and intraluminal radiation therapy have all been evaluated in patients with intrahepatic cholangiocarcinoma. However, most studies are not well controlled and involve small numbers of patients. Furthermore, no prospective trial or retrospective review has shown a significant survival benefit in patients with unresectable disease. In an effort to target the radiation dose within

**Table 19.5** Resectability rates and outcomes postresection in selected recent series of intrahepatic cholangiocarcinoma

Author	<i>n</i>	Resectability	Survival rate
Roayaie (1998) <sup>60</sup>	26	62%	44% (5 year)
Leister (1998) <sup>57</sup>	61	46%	60% (3 year)
Valverde (1999) <sup>61</sup>	42	71%	22% (3 year)
Isaji (1999) <sup>62</sup>	48	75%	24% (5 year)
El Rassi (1999) <sup>56</sup>	21	90%	16% (3 year)
Weber (2001) <sup>58</sup>	53	62%	31% (5 year)
Giuliantie (2005) <sup>63</sup>	35	43%	49% (3 year)
Lang (2006) <sup>64</sup>	120	25%	48% (5 year)

the tumor,  $^{31}\text{I}$ -labelled anti-CEA in conjunction with systemic chemotherapy has been used in patients with unresectable tumors<sup>67</sup>. While a significant reduction in tumor volume was noted on CT scan in 27% of patients, there was no improvement in survival. Recently, regional chemotherapy administered via a surgically placed hepatic artery infusion pump has been explored. This approach, which uses continuous arterial infusion of floxuridine at high doses, has been shown to significantly reduce the incidence of hepatic recurrence after partial hepatectomy for metastatic colorectal cancer<sup>68</sup>. Recent clinical observations suggest that this may be a useful approach for patients with unresectable intrahepatic cholangiocarcinoma or perhaps as an adjuvant after resection (Figure 19.5).

## DISTAL CHOLANGIOCARCINOMA

There has been some confusion and debate regarding the classification of tumors of the common bile duct. Traditionally, cholangiocarcinomas located between the cystic duct–hepatic duct junction and the upper border of the duodenum were known as mid-bile duct tumors, while cholangiocarcinomas located between the upper border of the duodenum and the papilla of Vater were classified as distal bile duct tumors. The logic behind this classification scheme was that mid-bile duct tumors were potentially amenable to curative resection by extirpation of the bile duct alone, while tumors below the upper border of the duodenum required pancreaticoduodenectomy. However, this dichotomy was clinically impractical as tumors often overlap both regions. In addition, true mid-bile duct tumors are distinctly uncommon. A more practical classification system was proposed by Nakeeb *et al.*<sup>69</sup> who designated tumors above the cystic duct–hepatic duct confluence as perihilar cholangiocarcinomas and tumors below the confluence as distal cholangiocarcinomas. These tumors represent 20–30% of all cholangiocarcinoma and 5–10% of periampullary tumors. There are approximately 2000 new cases of distal cholangiocarcinoma diagnosed each year in the US.

### Clinical presentation and diagnosis

The typical presentation of patients with distal cholangiocarcinoma is similar to that of patients with either hilar or other periampullary tumors. Jaundice is present in approximately 80% of cases. Abdominal pain, weight loss, purities, and fever associated with cholangitis may also be present. The most important diagnostic dilemma is distinguishing a malignancy from more common

choledocholithiasis-related obstruction. As, with perihilar tumors, the level of serum bilirubin may be helpful in elucidating the etiology of obstruction as benign stone disease rarely results in elevations of serum bilirubin above 10 mg/dl.

Cross-sectional imaging such as CT scan will show a dilated proximal bile duct but may fail to show a distinct mass. Endoscopic ultrasound may be used to try to identify a mass lesion in equivocal cases. ERCP remains a vital test to exclude choledocholithiasis and delineate the level of obstruction. However, it may be difficult to definitively distinguish a benign distal bile duct stricture from carcinoma preoperatively. Brush biopsies obtained during ERCP are notoriously insensitive in detecting malignancy and should not be relied upon. The use of PET scans to distinguish cholangiocarcinoma from benign strictures is promising but remains experimental<sup>70</sup>. Furthermore, it may be difficult to distinguish a distal cholangiocarcinoma from a pancreatic head mass or a duodenal based malignancy before operation. In a series of 119 patients submitted to operation for a periampullary mass, the site of origin of the malignancy was incorrectly diagnosed preoperatively in 28% of cases<sup>71</sup>. However, histological confirmation is not essential before proceeding with surgery so long as the patient understands that the diagnosis of a benign biliary stricture is a possibility.

Preoperative imaging also serves the critical role of helping to determine the resectability of distal cholangiocarcinoma. The principal reasons for unresectability are either the presence of distant disease or invasion of the mesenteric vessels or portal vein. While superior mesenteric arterial invasion is an absolute contraindication for resection, short segment portal vein or superior mesenteric vein involvement may be resected with the specimen followed by vascular reconstruction. Metastatic disease in distant lymph nodes including celiac, periportal and superior mesenteric nodes is also considered distant disease and should be viewed as a contraindication to resection. In a series of 104 patients with distal bile duct cancer treated at Memorial Sloan Kettering Cancer Center, 20 patients (19%) were deemed inoperable based on preoperative imaging while an additional 39 patients (38%) were found to have advanced disease upon operative exploration<sup>72</sup>. In a report from the US Veteran Affairs Hospitals, over a 5-year period, only 34 of 156 patients (22%) who presented with distal cholangiocarcinoma were candidates for resection<sup>73</sup>.

### Treatment options and outcomes

Complete surgical resection is the only potential curative treatment modality in distal cholangiocarcinoma. In most cases, this requires a pancreaticoduodenectomy.

However, in selected cases of tumors of the mid-bile duct, resection of the bile duct alone may suffice. In reported series, 8–13% of patients were amenable to complete resection with bile duct resection alone without pancreaticoduodenectomy<sup>72,73</sup>. Five-year survival rates after complete resection range from 14 to 50%<sup>72,73</sup>. Besides complete resection, factors that have been associated with outcome include lymph node involvement and tumor differentiation<sup>69</sup>. Fong *et al.*<sup>72</sup> found that patients with tumor in regional nodes had a 6.7-fold greater likelihood of disease recurrence and death. As is the case with intrahepatic and hilar cholangiocarcinoma, adjuvant chemotherapy or radiation have not been proven to extend survival. However, prospective studies are lacking.

As suggested above, most patients with distal cholangiocarcinoma are not candidates for resection with curative intent because of the presence of locally advanced or distant disease. For these patients, the primary therapeutic goal is palliation of the biliary obstruction. This can be achieved with either a surgical bypass (hepaticojejunostomy or choledochojejunostomy) or a biliary endoprosthesis. While a surgically created bypass provides durable relief of jaundice and can be done with acceptably low morbidity, endobiliary stenting is usually favored in patients who are discovered preoperatively to have unresectable disease.

## GALLBLADDER CARCINOMA

### Epidemiology and risk factors

Gallbladder cancer is a relatively rare disease, but it has a distinctly higher incidence in certain population groups and geographic areas. Women are affected approximately three times more commonly than men and most patients stricken with this disease are older than 50 years of age. The highest incidence in the world is reported in women in Delhi, India (21.5 per 100 000). Other high risk areas include parts of Pakistan, Korea, Japan, Poland, Slovakia, Spain, Ecuador, and Colombia<sup>74</sup>. In the US and in the UK the incidence rates are less than two per 100 000. However, certain subgroups may be at higher risk. For example, Native American females in New Mexico have an annual incidence of 14.5 per 100 000<sup>75</sup>.

A primary risk factor for the development of gallbladder cancer is cholelithiasis. In a cohort study conducted in the US, the relative risk of developing gallbladder cancer in patients with gallstone disease was 8.3 compared with the general population<sup>76</sup>. Case-control studies have also confirmed the association between cholelithiasis and gallbladder cancer with relative risks ranging widely from 2.3 to 34.4 between different studies<sup>74</sup>. Three studies

have analyzed the association between gallstone size and the risk of developing gallbladder cancer. Two of these studies found a strong correlation between larger gallstones (>3 cm) and the risk of cancer<sup>77,78</sup>. However, in the third study, the relative size of the gallstone was not a significant prognostic factor<sup>79</sup>.

A high body mass index is also correlated with an increased risk of developing gallbladder cancer. A Norwegian cohort study including over 2 million people and 1715 cases of gallbladder cancer showed that the relative risk of developing gallbladder cancer was 2.53 for women aged 20–44 with a body mass index greater than 30<sup>80</sup>. Increased numbers of pregnancies is also a risk factor for the development of gallbladder cancer. However, it is uncertain if there is a direct association between obesity or high parity and gallbladder cancer or whether the association is secondary to the predisposition to cholelithiasis in these patients.

As is the case with other gastrointestinal malignancies, a progression from adenoma to carcinoma has been demonstrated within adenomatous polyps of the gallbladder<sup>81</sup>. Gallbladder polyps have been noted in 3–6% of the population on sonographic examination. The vast majority of gallbladder polyps, however, are cholesterol polyps and have no malignant potential. Adenomatous polyps are found in approximately 1% of cholecystectomy specimens<sup>82</sup>. Yang *et al.*<sup>83</sup> reviewed a series of 182 gallbladder polyps found in cholecystectomy specimens. Preoperative ultrasound was 93% sensitive in diagnosing a polypoid lesion in the wall of the gallbladder. Most of the polyps were benign cholesterol polyps, however, 13 (7%) were discovered to harbor a malignancy. Yeh *et al.*<sup>84</sup>, in a series of 123 patients with polypoid lesions of the gallbladder, found that the likelihood of an associated malignancy correlated with polyp size greater than 1 cm and patient age greater than 50 years. The presence of a gallbladder polyp alone on imaging studies is not an indication for cholecystectomy. However, single, sessile polyps that measure more than 1 cm should be an indication for cholecystectomy. Polyps that appear less suspicious can be followed with serial imaging for a defined length of time to assure stability.

### Pathology and staging

Nearly all gallbladder cancers are adenocarcinomas. Papillary, mucinous, squamous and adenosquamous subtypes have been described, with papillary tumors having a somewhat better prognosis than the others. The AJCC staging system for gallbladder cancer is based on the TMN paradigm (Table 19.6). T stage describes the relative invasion of tumor through the layers of the gallbladder wall and into adjacent structures and is a primary

factor in determining appropriate treatment. The wall of the gallbladder consists of a mucosa, lamina propria, thin muscular layer, perimuscular connective tissue, and a serosa. However, a unique feature of clinical importance is that the portion of the gallbladder adjacent to the liver lacks a serosal covering and the perimuscular connective tissue of the gallbladder is continuous with hepatic connective tissue. In general, tumors confined to the gallbladder wall are classified as either T1 or T2, while T3 and T4 tumors have extended beyond the gallbladder. Importantly, T3 tumors are still potentially resectable while T4 tumors are usually regarded as unresectable. Accurate N staging requires that a minimum of three

regional lymph nodes are histologically examined. Regional lymph nodes include hilar, celiac, periduodenal, peripancreatic, and superior mesenteric nodes as well as nodes along the pancreatic head. Cancer in lymph nodes outside of the hepatoduodenal ligament are considered M1 disease. The most common sites of distant metastasis in gallbladder cancer are the peritoneum and the liver. Occasionally, spread to the lung and pleura are also seen. The incidence of distant and nodal metastases appears to be related to T stage. In a study from Memorial Sloan-Kettering Cancer Center, distant and nodal metastases increased progressively from 16 to 79% and from 33 to 69%, respectively, in going from T2 to T4 tumors<sup>85</sup>.

**Table 19.6** AJCC 2002 TNM classification for gallbladder cancer

<i>Tumor (T)</i>	
TX	Primary tumor cannot be assessed
T0	No evidence of primary tumor
Tis	Carcinoma <i>in situ</i>
T1	Tumor invades lamina propria or muscle layer
T1a	Tumor invades lamina propria
T1b	Tumor invades the muscle layer
T2	Tumor invades the perimuscular connective tissue; no extension beyond the serosa or into the liver
T3	Tumor perforates the serosa (visceral peritoneum) and/or directly invades the liver and/or one other adjacent organ or structure, such as the stomach, duodenum, colon, or pancreas, omentum or extrahepatic bile ducts
T4	Tumor invades main portal vein or hepatic artery or invades multiple extrahepatic organs or structures
<i>Nodes (N)</i>	
NX	Regional lymph nodes cannot be assessed
N0	No regional lymph node metastasis
N1	Regional lymph node metastasis
<i>Metastasis (M)</i>	
MX	Distant metastasis cannot be assessed
M0	No distant metastasis
M1	Distant metastasis
<i>Stage Groupings</i>	
Stage 0	TisN0M0
Stage IA	T1N0M0
Stage IB	T2N0M0
Stage IIA	T3N0M0
Stage IIB	T1N1M0, T2N1M0, T3N1M0
Stage III	T4 any NM0
Stage IV	Any T any NM1



The current AJCC stage groupings for gallbladder cancer reflect the clinical treatment status of the disease. Cancers categorized as stages I or II are resectable with curative intent, whereas stage III signifies locally unresectable disease and stage IV represents unresectability as a consequence of distant metastases (Table 19.6).

### Presentation and diagnosis

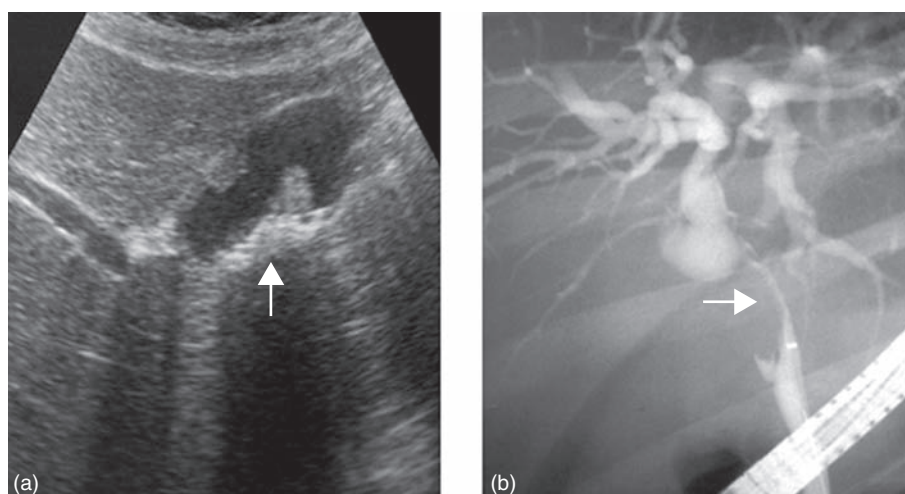
Most cases of gallbladder cancer are discovered when the disease is at an advanced stage. In fact, 75% of patients are diagnosed when the disease is beyond the limits of resection. The most common symptoms at presentation are abdominal pain or biliary colic. Patients with advanced disease may also present with jaundice from tumor invasion of the biliary tree or with systemic signs such as malaise and weight loss. The diagnosis is often suspected on an ultrasound done to evaluate presumed gallstone disease. Echogenic or discontinuous gallbladder mucosa, submucosal echolucency, or a mass should lead one to suspect gallbladder cancer (Figure 19.6). An inhomogeneous mass replacing most of the gallbladder is nearly diagnostic of gallbladder carcinoma. Doppler ultrasound can also define the extent of biliary tree involvement as well as confirm the presence of hepatic arterial or portal venous invasion. Cholangiography may show stricture of the bile duct in locally advanced cases (Figure 19.6). In addition, abdominal cross-sectional imaging (CT or MRI) should be performed to evaluate for nodal or metastatic disease as well as to further define the local extent of disease. Recent studies have shown that PET scans

reliably detect primary and metastatic gallbladder cancer but have a low accuracy in detecting nodal disease<sup>86</sup>. The role of PET scan in the multimodality work-up of patients with suspected gallbladder cancer is still being defined and its use should be individualized.

Patients with gallbladder cancer present to the surgeon in three different clinical scenarios: malignancy suspected preoperatively, malignancy found at the time of exploration for presumed benign disease, and malignancy diagnosed incidentally on pathological examination after simple cholecystectomy. The last scenario is the most common mode of presentation of early stage gallbladder cancer<sup>87</sup>. For this reason, it should be customary to inspect the gallbladder mucosa after simple cholecystectomy. Suspicious lesions should be sent immediately for frozen section. The goal of resection in cases of malignancy should always be complete tumor extirpation with negative histological margins. However, surgical procedures will vary by T stage.

### Surgical therapy by T stage

Before proceeding with laparotomy for gallbladder cancer, staging laparoscopy is helpful to assess the abdomen for evidence of peritoneal spread or discontinuous liver disease; however, laparoscopic cholecystectomy should be avoided when a preoperative cancer is suspected because of the risk of port site seeding. Nevertheless, in suspicious cases, it is not unreasonable to proceed with open cholecystectomy and obtain frozen section histology to prove malignancy before proceeding with hepatic resection.



**Figure 19.6** Sonographic and cholangiographic appearance of gallbladder cancer. (a) A coronal ultrasound image through the gallbladder shows asymmetric thickening of the gallbladder wall (arrow) with a mass projecting into the gallbladder lumen. (b) An endoscopic retrograde cholangiogram of locally advanced gallbladder cancer shows narrowing of the mid-bile duct, non-filling of the cystic duct, and proximal bile duct dilatation.

T1a tumors are most often discovered after laparoscopic cholecystectomy. The cure rate after simple cholecystectomy is 85–100% if negative margins are attained as the potential for nodal metastasis is small<sup>88,89</sup>. T1b tumors, in theory, should also be cured by simple cholecystectomy; however, there have been reports of tumor recurrence and death following a simple cholecystectomy for T1b tumors<sup>90</sup>. Given the limited data regarding T1b gallbladder cancers in the literature, the decision to perform a simple cholecystectomy versus a more radical procedure should be individualized.

Tumors that extend into the perimuscular connective tissues should be treated by aggressive resection, which includes en bloc resection of the adjacent liver as well as a lymphadenectomy of the hepatoduodenal ligament. The reason for this requirement is that the normal plane of dissection during simple cholecystectomy is actually within the perimuscular connective tissue which is in continuity with the liver. Thus, a simple cholecystectomy will not achieve tumor clearance with certainty. The utility of radical surgery for T2 tumors is supported by studies which show 20–40% 5-year survival rates after simple cholecystectomy compared with upward of an 80% 5-year survival rate after en bloc hepatic resection<sup>91–94</sup>. The extent of hepatectomy required depends upon whether there is tumor involvement of major hepatic arterial or portal venous structures. In the absence of such involvement, the authors prefer to perform a segmental resection of segments IVb and V. Similarly, a resection and reconstruction of the bile duct is performed only if necessary to clear tumor. In this regard, determination of the margin status of the cystic duct stump is critical. A lymphadenectomy is also performed for T2 tumors given that approximately one-third of these lesions have associated lymph node metastases and long-term survivors have been reported in patients with N1 disease<sup>94,95</sup>. The extent of lymphadenectomy is controversial. It is the authors' practice to include extirpation of lymph nodes within the hepatoduodenal ligament.

T3 tumors are rarely cured by simple cholecystectomy. These tumors require hepatic resection and porta hepatis lymphadenectomy at a minimum. This often includes a major hepatectomy with bile duct resection and reconstruction. The principals that apply to T2 tumors also apply to T3 tumors. In addition, if direct invasion into adjacent organs is suspected, en bloc resection is required. In patients who present after prior cholecystectomy for presumed gallstone disease, postoperative inflammatory changes and adhesions of surrounding structures to the gallbladder fossa make precise determination of the extent of cancer invasion difficult. In these cases, en bloc resection of adherent tissues along with hepatectomy is most prudent. When a complete resection is attained, 5-year

survival rates of 30–50% can be achieved in patients with T3 tumors<sup>85,91,96</sup>.

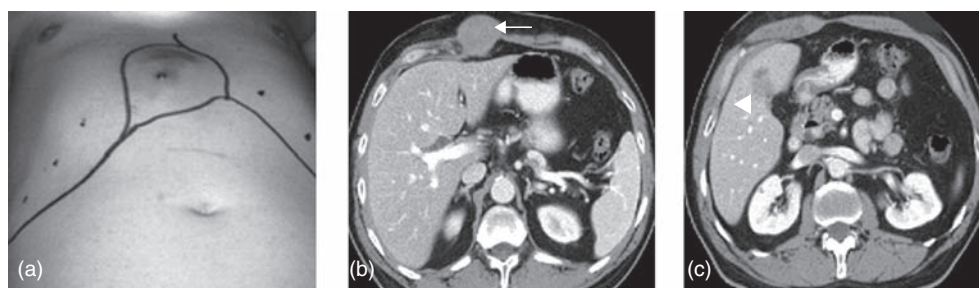
According to the new AJCC definition of T4 disease, these lesions are nearly always unresectable and palliative therapies should be sought.

In cases where the diagnosis of gallbladder cancer is made at the time of exploration for what had been presumed to be benign disease, if the treating surgeon is not prepared to perform a hepatic resection, the patient would be best served by transfer to a center with experience in performing the appropriate operation. Such an approach is reasonable and does not negatively impact on the patient's prognosis, provided that the definitive procedure is subsequently performed. Fong *et al.*<sup>85</sup> showed that a prior non-curative cholecystectomy does not influence survival in patients who subsequently undergo re-operation and appropriate resection.

Patients with gallbladder cancer that was diagnosed after an unsuspecting laparoscopic cholecystectomy may be predisposed to early peritoneal spread or port site seeding, especially if bile or stone spillage occurred<sup>97</sup>. Because inadvertent cholecystotomy during cholecystectomy is rarely documented, it is difficult to predict which patients are at increased risk. Some surgeons recommend routine full thickness resection of all laparoscopic port sites in an effort to ensure clearance of microscopic disease that may have been implanted. However, there is little evidence to support the efficacy of routine resection of all port sites at re-operation<sup>98</sup>. In the authors' experience, recurrence at the port sites is a harbinger of generalized peritoneal recurrence that would not have been prevented with resection of these areas (Figure 19.7).

## Outcomes

Historically, clinical attitudes towards gallbladder cancer were pervaded with pessimism and nihilism. These sentiments are reflected in a quote from the American surgeon Alfred Blalock in 1924 in which he states, 'in malignancy of the gallbladder, when a diagnosis can be made without exploration, no operation should be performed, inasmuch as it only shortens the patient's life.' This viewpoint gained further acceptance when a review of all cases of gallbladder cancer reported in the English language literature ( $n = 6222$ ) was undertaken by Peilher and Crichlow in 1978, demonstrating a cumulative median survival of 5–8 months and 5-year survival rate of only 4%<sup>99</sup>. In recent years, however, an improved understanding of this disease and the extensive surgical resection required, has led to less nihilistic attitudes and improved outcomes. In particular the realization that all cases beyond T1 require radical resection to best ensure



**Figure 19.7** Port site recurrence in gallbladder carcinoma. (a) This patient developed a clinically obvious port site recurrence of gallbladder cancer at his midline subxiphoid laparoscopic port. (b) The metastatic subcutaneous mass (arrow) is also seen on axial computed tomography imaging. (c) Unfortunately, port site recurrence, while technically resectable, is usually a harbinger for disseminated disease. This patient developed a left hepatic metastatic deposit (arrowhead).

negative margins, has led to prolonged survival and cure in selected patients. Furthermore, over the past three decades, decreasing morbidity and mortality associated with major hepatectomy, bile duct resection and hilar lymphadenectomy have allowed for safer application of surgical therapy<sup>91,100</sup>. In a contemporary series from Memorial Sloan-Kettering Cancer Center, Bartlett *et al.*<sup>91</sup> reported on 149 cases in which radical surgical resection yielded an actuarial 5-year survival of 83% for stage II disease and 63% for stage III. Further evidence supporting an aggressive surgical approach was recently offered in a Canadian study which analyzed cohorts from two time periods that spanned a 12-year interval<sup>101</sup>. The latter half of the 12-year period included significantly more liver and bile duct resections indicative of the more aggressive surgical approach. In comparing outcomes from the later with the earlier period, median survival doubled from 9 to 17 months and 5-year survival rates increased from 7 to 35%.

A number of factors have been shown to be predictive of survival after radical resection. T stage is an important prognostic factor. In a study by Fong *et al.*<sup>85</sup>, patients with T2 disease had a 59% 5-year survival rate compared with 21% for those with T3 disease. Nodal disease is also associated with poor prognosis. In the same study, of the 36 patients with node-positive disease treated by resection with curative intent, only two patients survived beyond 5 years. In addition, overall AJCC stage has correlated well with outcome. Of the physical findings, the presence of jaundice is an ominous sign in patients with gallbladder cancer. The most common finding in jaundiced patients is obstruction of the distal common hepatic duct or proximal common bile duct. Because of the proximity of the gallbladder to the major extrahepatic biliary ductal structures, concomitant biliary involvement can take the form of direct extension or metastatic disease to the hepatoduodenal ligament. Coexisting jaundice very frequently signifies advanced disease that is beyond resectability. In an analysis of 240 patients with gallbladder cancer over a

7-year period, Hawkins *et al.*<sup>102</sup> reported the presence of jaundice in 82 (34%), of which only six (7%) had disease amenable to a complete resection, and all of these patients had either recurred or died of disease by 2 years.

### Adjuvant therapy

Most data for the use of adjuvant or neoadjuvant therapy in patients with gallbladder cancer are derived from phase II trials in which treated patients were compared with historical controls. Definitive conclusions from these trials are limited by the small numbers of patients and the inclusion of patients undergoing less than an R0 resection<sup>103,104</sup>. In addition, patients with gallbladder cancer are often lumped together with patients with other biliary tract malignancies. Many of the phase II studies used some combination of chemoradiation. The use of radiotherapy plus 5-FU in the neoadjuvant setting has not been shown to provide a major benefit in terms of survival. However, in cases of locally advanced gallbladder cancer, this therapy may reduce local recurrence and potentially improve resectability<sup>105</sup>. A recent phase III multi-institutional trial of adjuvant chemotherapy was performed in Japan which included 508 patients with bile duct cancer, gallbladder cancer, carcinoma of the ampulla of Vater, or pancreatic cancer. On subset analysis, the gallbladder cancer patients ( $n = 140$ ) who were randomized to receive surgical resection plus adjuvant mitomycin and 5-FU had an actuarial 5-year disease-free survival of 20.3% compared with 11.6% for patients treated by surgical resection alone<sup>106</sup>. Based on these data it is reasonable to offer adjuvant chemotherapy with 5-FU and mitomycin to resected gallbladder patients.

### Palliation

Most patients with gallbladder cancer present with advanced, incurable disease and only approximately one in four patients will actually be a candidate for surgical

resection. For this majority of patients, as well as for those who experience local or distant recurrence after resection, median survival ranges between 2 and 4 months and palliation is the primary goal. Symptoms and conditions associated with incurable gallbladder cancer include jaundice, pain and gastrointestinal obstruction. In general, chemotherapy and radiation therapy have yielded poor results in the treatment of unresectable gallbladder cancer. Multiple regimens have been tested including combinations of 5-FU, leucovorin, mitomycin, adriamycin, and nitrosoureas. However, the effects have been mostly disappointing with poor response rates and limited duration of response.

Occasionally, palliative interventions may be necessary but should be selected to minimize morbidity. Palliative procedures may be required to relieve biliary or intestinal obstruction. If unresectable disease is discovered at the time of exploration, a segment III bypass is can be performed to relieve jaundice, but most patients are best served by avoiding a major operative procedure and proceeding with percutaneous biliary drainage postoperatively<sup>107</sup>. Intestinal bypass should be performed only in patients who have symptomatic obstruction. However, as in cases of biliary obstruction, performing a less invasive endoscopic gastrointestinal drainage procedure may be the preferred option.

## REFERENCES

1. Shaib Y, El-Serag HB. The epidemiology of cholangiocarcinoma. *Semin Liver Dis* 2004; 24: 115–25.
2. Broome U, Olsson R, Loof L et al. Natural history and prognostic factors in 305 Swedish patients with primary sclerosing cholangitis. *Gut* 1996; 38: 610–5.
3. Pitt HA, Dooley WC, Yeo CJ et al. Malignancies of the biliary tree. *Curr Probl Surg* 1995; 32: 1–90.
4. Lipsett PA, Pitt HA, Colombani PM et al. Choledochal cyst disease. A changing pattern of presentation. *Ann Surg* 1994; 220: 644–52.
5. Tanaka K, Ikoma A, Hamada N et al. Biliary tract cancer accompanied by anomalous junction of pancreaticobiliary ductal system in adults. *Am J Surg* 1998; 175: 218–20.
6. Chen MF, Jan YY, Jeng LB et al. Intrahepatic cholangiocarcinoma in Taiwan. *J Hepatobiliary Pancreat Surg* 1999; 6: 136–41.
7. Parkin DM, Srivatanakul P, Khlai M et al. Liver cancer in Thailand. I. A case-control study of cholangiocarcinoma. *Int J Cancer* 1991; 48: 323–8.
8. Yamamoto S, Kubo S, Hai S et al. Hepatitis C virus infection as a likely etiology of intrahepatic cholangiocarcinoma. *Cancer Sci* 2004; 95: 592–5.
9. Kobayashi M, Ikeda K, Saitoh S et al. Incidence of primary cholangiocellular carcinoma of the liver in Japanese patients with hepatitis C virus-related cirrhosis. *Cancer* 2000; 88: 2471–7.
10. Hakamada K, Sasaki M, Endoh M et al. Late development of bile duct cancer after sphincteroplasty: a ten- to twenty-two-year follow-up study. *Surgery* 1997; 121: 488–92.
11. Tocchi A, Mazzoni G, Liotta G et al. Late development of bile duct cancer in patients who had biliary-enteric drainage for benign disease: a follow-up study of more than 1,000 patients. *Ann Surg* 2001; 234: 210–4.
12. Jarnagin WR, Bowne W, Klimstra DS et al. Papillary phenotype confers improved survival after resection of hilar cholangiocarcinoma. *Ann Surg* 2005; 241: 703–12.
13. Weinbren K, Mutum SS. Pathological aspects of cholangiocarcinoma. *J Pathol* 1983; 139: 217–38.
14. Hochwald SN, Burke EC, Jarnagin WR et al. Association of preoperative biliary stenting with increased postoperative infectious complications in proximal cholangiocarcinoma. *Arch Surg* 1999; 134: 261–6.
15. Qin XL, Wang ZR, Shi JS et al. Utility of serum CA19-9 in diagnosis of cholangiocarcinoma: in comparison with CEA. *World J Gastroenterol* 2004; 10: 427–32.
16. Corvera CU, Blumgart LH, Darvishian F et al. Clinical and pathologic features of proximal biliary strictures masquerading as hilar cholangiocarcinoma. *J Am Coll Surg* 2005; 201: 862–9.
17. Heslin MJ, Brooks AD, Hochwald SN et al. A preoperative biliary stent is associated with increased complications after pancreatoduodenectomy. *Arch Surg* 1998; 133: 149–54.
18. Bach AM, Hann LE, Brown KT et al. Portal vein evaluation with US: comparison to angiography combined with CT arterial portography. *Radiology* 1996; 201: 149–54.
19. Lee MG, Lee HJ, Kim MH et al. Extrahepatic biliary diseases: 3D MR cholangiopancreatography compared with endoscopic retrograde cholangiopancreatography. *Radiology* 1997; 202: 663–9.
20. Park MS, Kim TK, Kim KW et al. Differentiation of extrahepatic bile duct cholangiocarcinoma from benign stricture: findings at MRCP versus ERCP. *Radiology* 2004; 233: 234–40.
21. Tillich M, Mischinger HJ, Preisegger KH et al. Multiphasic helical CT in diagnosis and staging of hilar cholangiocarcinoma. *AJR Am J Roentgenol* 1998; 171: 651–8.
22. Jarnagin WR, Fong Y, Dematteo RP et al. Staging, resectability, and outcome in 225 patients with hilar cholangiocarcinoma. *Ann Surg* 2001; 234: 507–17.
23. Kitagawa Y, Nagino M, Kamiya J et al. Lymph node metastasis from hilar cholangiocarcinoma: audit of 110 patients who underwent regional and paraaortic node dissection. *Ann Surg* 2001; 233: 385–92.
24. Tojima Y, Nagino M, Ebata T et al. Immunohistochemically demonstrated lymph node micrometastasis and prognosis in patients with otherwise node-negative hilar cholangiocarcinoma. *Ann Surg* 2003; 237: 201–7.
25. Weber SM, Dematteo RP, Fong Y et al. Staging laparoscopy in patients with extrahepatic biliary carcinoma. Analysis of 100 patients. *Ann Surg* 2002; 235: 392–9.

26. Martin RC, Fong Y, Dematteo RP et al. Peritoneal washings are not predictive of occult peritoneal disease in patients with hilar cholangiocarcinoma. *J Am Coll Surg* 2001; 193: 620–5.
27. Nimura Y, Kamiya J, Kondo S et al. Aggressive preoperative management and extended surgery for hilar cholangiocarcinoma: Nagoya experience. *J Hepatobiliary Pancreat Surg* 2000; 7: 155–62.
28. Kondo S, Hirano S, Ambo Y et al. Forty Consecutive resections of hilar cholangiocarcinoma with no postoperative mortality and no positive ductal margins: results of a prospective study. *Ann Surg* 2004; 240: 95–101.
29. Cameron JL, Pitt HA, Zinner MJ et al. Management of proximal cholangiocarcinomas by surgical resection and radiotherapy. *Am J Surg* 1990; 159: 91–7.
30. Hadjis NS, Blenkharn JL, Alexander N et al. Outcome of radical surgery in hilar cholangiocarcinoma. *Surgery*. 1990; 107: 597–604.
31. Nimura Y, Hayakawa N, Kamiya J et al. Hepatic segmentectomy with caudate lobe resection for bile duct carcinoma of the hepatic hilus. *World J Surg* 1990; 14: 535–43.
32. Klempnauer J, Ridder GJ, Werner M et al. What constitutes long-term survival after surgery for hilar cholangiocarcinoma? *Cancer* 1997; 79: 26–34.
33. Gerhards MF, van Gulik TM, de Wit LT, Obertop H, Gauma DJ. Evaluation of morbidity and mortality after resection for hilar cholangiocarcinoma – a single center experience. *Surgery* 2000; 127: 395–404.
34. Neuhaus P, Jonas S, Bechstein WO et al. Extended resections for hilar cholangiocarcinoma. *Ann Surg* 1999; 230: 808–18.
35. Tsao JL, Nimura Y, Kamiya J et al. Management of hilar cholangiocarcinoma: comparison of an American and Japanese experience. *Ann Surg* 2000; 232: 166–74.
36. Dinant S, Gerhards MF, Rauws EA et al. Improved outcome of resection of hilar cholangiocarcinoma (Klatskin tumor). *Ann Surg Oncol* 2006; 13: 872–80.
37. Jarnagin WR, Shoup M. Surgical management of cholangiocarcinoma. *Semin Liver Dis* 2004; 24: 189–99.
38. Pichlmayr R, Weimann A, Klempnauer J et al. Surgical treatment in proximal bile duct cancer. A single-center experience. *Ann Surg* 1996; 224: 628–38.
39. Rea DJ, Heimbach JK, Rosen CB et al. Liver transplantation with neoadjuvant chemoradiation is more effective than resection for hilar cholangiocarcinoma. *Ann Surg* 2005; 242: 451–8.
40. Olnes MJ, Erlich R. A review and update on cholangiocarcinoma. *Oncology* 2004; 66: 167–79.
41. Price P. Cholangiocarcinoma and the role of radiation and chemotherapy. *Hepatogastroenterology* 2001; 48: 51–2.
42. Liu CL, Lo CM, Lai EC et al. Endoscopic retrograde cholangiopancreatography and endoscopic endoprosthesis insertion in patients with Klatskin tumors. *Arch Surg* 1998; 133: 293–6.
43. Glatli A, Stain SC, Baer HU et al. Unresectable malignant biliary obstruction: treatment by self-expandable biliary endoprotheses. *HPB Surg* 1993; 6: 175–84.
44. Becker CD, Glatli A, Maibach R et al. Percutaneous palliation of malignant obstructive jaundice with the Wallstent endoprosthesis: follow-up and reintervention in patients with hilar and non-hilar obstruction. *J Vasc Interv Radiol* 1993; 4: 597–604.
45. Stoker J, Lameris JS. Complications of percutaneously inserted biliary Wallstents. *J Vasc Interv Radiol* 1993; 4: 767–72.
46. Rossi M, Salvatori FM, Ingianna D et al. Nonvascular interventional radiology in the treatment of post-liver transplant complications. The clinico-radiological correlations and technical considerations. *Radiol Med (Torino)* 1995; 90: 291–7. [in Italian]
47. Jarnagin WR, Burke E, Powers C et al. Intrahepatic biliary enteric bypass provides effective palliation in selected patients with malignant obstruction at the hepatic duct confluence. *Am J Surg* 1998; 175: 453–60.
48. Kuvshinov BW, Armstrong JG, Fong Y et al. Palliation of irresectable hilar cholangiocarcinoma with biliary drainage and radiotherapy. *Br J Surg* 1995; 82: 1522–5.
49. Vallis KA, Benjamin IS, Munro AJ et al. External beam and intraluminal radiotherapy for locally advanced bile duct cancer: role and tolerability. *Radiother Oncol* 1996; 41: 61–6.
50. Ortner ME, Caca K, Berr F et al. Successful photodynamic therapy for nonresectable cholangiocarcinoma: a randomized prospective study. *Gastroenterology* 2003; 125: 1355–63.
51. Glimelius B, Hoffman K, Sjoden PO et al. Chemotherapy improves survival and quality of life in advanced pancreatic and biliary cancer. *Ann Oncol* 1996; 7: 593–600.
52. Daines WP, Rajagopalan V, Grossbard ML et al. Gallbladder and biliary tract carcinoma: a comprehensive update, Part 2. *Oncology (Williston Park)* 2004; 18: 1049–59.
53. Primary liver cancer in Japan. Clinicopathologic features and results of surgical treatment. Liver Cancer Study Group of Japan. *Ann Surg* 1990; 211: 277–87.
54. Martin R, Jarnagin W. Intrahepatic cholangiocarcinoma. Current management. *Minerva Chir* 2003; 58: 469–78.
55. Yamasaki S. Intrahepatic cholangiocarcinoma: macroscopic type and stage classification. *J Hepatobiliary Pancreat Surg* 2003; 10: 288–91.
56. El Rassi ZE, Partensky C, Scoazec JY et al. Peripheral cholangiocarcinoma: presentation, diagnosis, pathology and management. *Eur J Surg Oncol* 1999; 25: 375–80.
57. Lieser MJ, Barry MK, Rowland C et al. Surgical management of intrahepatic cholangiocarcinoma: a 31-year experience. *J Hepatobiliary Pancreat Surg* 1998; 5: 41–7.
58. Weber SM, Jarnagin WR, Klimstra D et al. Intrahepatic cholangiocarcinoma: resectability, recurrence pattern, and outcomes. *J Am Coll Surg* 2001; 193: 384–91.
59. Chou FF, Sheen-Chen SM, Chen YS et al. Surgical treatment of cholangiocarcinoma. *Hepatogastroenterology* 1997; 44: 760–5.
60. Roayaie S, Guarrera JV, Ye MQ et al. Aggressive surgical treatment of intrahepatic cholangiocarcinoma: predictors of outcomes. *J Am Coll Surg* 1998; 187: 365–72.
61. Valverde A, Bonhomme N, Farges O et al. Resection of intrahepatic cholangiocarcinoma: a Western experience. *J Hepatobiliary Pancreat Surg* 1999; 6: 122–7.
62. Isaji S, Kwarada Y, Taoka H et al. Clinicopathological features and outcome of hepatic resection for intrahepatic cholangiocarcinoma in Japan. *J Hepatobiliary Pancreat Surg* 1999; 6: 108–16.
63. Giuliani F, Gauzolino R, Vellone M et al. Liver resection for intrahepatic cholangiocarcinoma. *Tumor* 2005; 91: 487–92.
64. Lang H, Sotiropoulos GC, Brokalaki E et al. [Surgical therapy of intrahepatic cholangiocellular carcinoma]. *Chirurg* 2006; 77: 53–60. German.
65. Pascher A, Jonas S, Neuhaus P. Intrahepatic cholangiocarcinoma: indication for transplantation. *J Hepatobiliary Pancreat Surg* 2003; 10: 282–7.
66. Falkson G, Macintyre JM, Moertel CG. Eastern Cooperative Oncology Group experience with chemotherapy for inoperable gallbladder and bile duct cancer. *Cancer* 1984; 54: 965–9.

67. Stillwagon GB, Order SE, Haulk T et al. Variable low dose rate irradiation (131I-anti-CEA) and integrated low dose chemotherapy in the treatment of nonresectable primary intrahepatic cholangiocarcinoma. *Int J Radiat Oncol Biol Phys* 1991; 21: 1601–5.
68. Kemeny N, Huang Y, Cohen AM et al. Hepatic arterial infusion of chemotherapy after resection of hepatic metastases from colorectal cancer. *N Engl J Med* 1999; 341: 2039–48.
69. Nakeeb A, Pitt HA, Sohn TA et al. Cholangiocarcinoma. A spectrum of intrahepatic, perihilar, and distal tumors. *Ann Surg* 1996; 224: 463–73.
70. Wakabayashi H, Akamoto S, Yachida S et al. Significance of fluorodeoxyglucose PET imaging in the diagnosis of malignancies in patients with biliary stricture. *Eur J Surg Oncol* 2005; 31: 1175–9.
71. Jones BA, Langer B, Taylor BR et al. Periampullary tumors: which ones should be resected? *Am J Surg* 1985; 149: 46–52.
72. Fong Y, Blumgart LH, Lin E et al. Outcome of treatment for distal bile duct cancer. *Br J Surg* 1996; 83: 1712–5.
73. Wade TP, Prasad CN, Virgo KS et al. Experience with distal bile duct cancers in U.S. Veterans Affairs hospitals: 1987–1991. *J Surg Oncol* 1997; 64: 242–5.
74. Randi G, Franceschi S, La VC. Gallbladder cancer worldwide: geographical distribution and risk factors. *Int J Cancer* 2006; 118: 1591–602.
75. Barakat J, Dunkelberg JC, Ma TY. Changing patterns of gallbladder carcinoma in New Mexico. *Cancer* 2006; 106: 434–40.
76. Maringhini A, Moreau JA, Melton LJ III et al. Gallstones, gallbladder cancer, and other gastrointestinal malignancies. An epidemiologic study in Rochester, Minnesota. *Ann Intern Med* 1987; 107: 30–5.
77. Diehl AK. Gallstone size and the risk of gallbladder cancer. *JAMA* 1983; 250: 2323–6.
78. Lowenfels AB, Walker AM, Althaus DP et al. Gallstone growth, size, and risk of gallbladder cancer: an interracial study. *Int J Epidemiol* 1989; 18: 50–4.
79. Moerman CJ, Lagerwaard FJ, Bueno de Mesquita HB et al. Gallstone size and the risk of gallbladder cancer. *Scand J Gastroenterol* 1993; 28: 482–6.
80. Engeland A, Tretli S, Austad G et al. Height and body mass index in relation to colorectal and gallbladder cancer in two million Norwegian men and women. *Cancer Causes Control* 2005; 16: 987–96.
81. Fong Y, Malhotra S. Gallbladder cancer: recent advances and current guidelines for surgical therapy. *Adv Surg* 2001; 35: 1–20.
82. Kozuka S, Tsubone N, Yasui A et al. Relation of adenoma to carcinoma in the gallbladder. *Cancer* 1982; 50: 2226–34.
83. Yang HL, Sun YG, Wang Z. Polypoid lesions of the gallbladder: diagnosis and indications for surgery. *Br J Surg* 1992; 79: 227–9.
84. Yeh CN, Jan YY, Chao TC et al. Laparoscopic cholecystectomy for polypoid lesions of the gallbladder: a clinicopathologic study. *Surg Laparosc Endosc Percutan Tech* 2001; 11: 176–81.
85. Fong Y, Jarnagin W, Blumgart LH. Gallbladder cancer: comparison of patients presenting initially for definitive operation with those presenting after prior noncurative intervention. *Ann Surg* 2000; 232: 557–69.
86. Petrowsky H, Wildbrett P, Husarik DB et al. Impact of integrated positron emission tomography and computed tomography on staging and management of gallbladder cancer and cholangiocarcinoma. *J Hepatol* 2006.
87. de A X, Roa I, Burgos L et al. Gallbladder cancer: an analysis of a series of 139 patients with invasion restricted to the subserosal layer. *J Gastrointest Surg* 2006; 10: 186–92.
88. Yamaguchi K, Tsuneyoshi M. Subclinical gallbladder carcinoma. *Am J Surg* 1992; 163: 382–6.
89. Shirai Y, Yoshida K, Tsukada K et al. Inapparent carcinoma of the gallbladder. An appraisal of a radical second operation after simple cholecystectomy. *Ann Surg* 1992; 215: 326–31.
90. Kimura W, Shimada H. A case of gallbladder carcinoma with infiltration into the muscular layer that resulted in relapse and death from metastasis to the liver and lymph nodes. *Hepatogastroenterology* 1990; 37: 86–9.
91. Bartlett DL, Fong Y, Fortner JG et al. Long-term results after resection for gallbladder cancer. Implications for staging and management. *Ann Surg* 1996; 224: 639–46.
92. de A X, Roa IS, Burgos LA et al. Curative resection in potentially resectable tumours of the gallbladder. *Eur J Surg* 1997; 163: 419–26.
93. Oertli D, Herzog U, Tondelli P. Primary carcinoma of the gallbladder: operative experience during a 16 year period. *Eur J Surg* 1993; 159: 415–20.
94. Shirai Y, Yoshida K, Tsukada K et al. Radical surgery for gallbladder carcinoma. Long-term results. *Ann Surg* 1992; 216: 565–8.
95. Onoyama H, Yamamoto M, Tseng A et al. Extended cholecystectomy for carcinoma of the gallbladder. *World J Surg* 1995; 19: 758–63.
96. Chijiwa K, Tanaka M. Carcinoma of the gallbladder: an appraisal of surgical resection. *Surgery* 1994; 115: 751–6.
97. Fong Y, Brennan MF, Turnbull A et al. Gallbladder cancer discovered during laparoscopic surgery. Potential for iatrogenic tumor dissemination. *Arch Surg* 1993; 128: 1054–6.
98. Shoup M, Fong Y. Surgical indications and extent of resection in gallbladder cancer. *Surg Oncol Clin N Am* 2002; 11: 985–94.
99. Piehler JM, Crichlow RW. Primary carcinoma of the gallbladder. *Surg Gynecol Obstet* 1978; 147: 929–42.
100. Nakamura S, Sakaguchi S, Suzuki S et al. Aggressive surgery for carcinoma of the gallbladder. *Surgery* 1989; 106: 467–73.
101. Dixon E, Vollmer CM Jr, Sahajpal A et al. An aggressive surgical approach leads to improved survival in patients with gallbladder cancer: a 12-year study at a North American Center. *Ann Surg* 2005; 241: 385–94.
102. Hawkins WG, DeMatteo RP, Jarnagin WR et al. Jaundice predicts advanced disease and early mortality in patients with gallbladder cancer. *Ann Surg Oncol* 2004; 11: 310–5.
103. Kresl JJ, Schild SE, Henning GT et al. Adjuvant external beam radiation therapy with concurrent chemotherapy in the management of gallbladder carcinoma. *Int J Radiat Oncol Biol Phys* 2002; 52: 167–75.
104. Mahe M, Stampfli C, Romestaing P et al. Primary carcinoma of the gall-bladder: potential for external radiation therapy. *Radiother Oncol* 1994; 33: 204–8.
105. de A X, Roa I, Burgos L et al. Preoperative chemoradiotherapy in the treatment of gallbladder cancer. *Am Surg* 1999; 65: 241–6.
106. Takada T, Amano H, Yasuda H et al. Is postoperative adjuvant chemotherapy useful for gallbladder carcinoma? A phase III multicenter prospective randomized controlled trial in patients with resected pancreaticobiliary carcinoma. *Cancer* 2002; 95: 1685–95.
107. Kapoor VK, Pradeep R, Haribhakti SP et al. Intrahepatic segment III cholangiojejunostomy in advanced carcinoma of the gallbladder. *Br J Surg* 1996; 83: 1709–11.



Theo JM Ruers

---

The liver is a common site for the development of metastases from primary tumors of various histology. The site of the primary tumor is the main determinant of the management of patients with liver metastases. In general we recognize liver metastases from colorectal cancer, from neuroendocrine tumors and from non-colorectal/non-neuroendocrine primary tumors. This chapter deals with the management of patients with liver metastases of colorectal origin and liver metastases from non-colorectal/non-neuroendocrine origin. Management of liver metastases of neuroendocrine tumors is discussed in the specific chapter on neuroendocrine tumors.

## LIVER METASTASES FROM COLORECTAL CANCER

### Incidence

Colorectal cancer ranks second as cause of death due to cancer in the Western world. The cumulative lifetime risk is approximately 5%, the incidence rate in the Western world is 50/100 000. Liver metastases form the main cause of death in patients with colorectal cancer. Already at the time of detection of the primary tumor 15–25% of the patients present with liver metastases, another 20% will develop metastases following treatment of the colorectal primary. Unfortunately only a minority of patients (10–15%) with liver metastases are considered to be candidates for surgery. The majority of patients with liver metastases prove to be unresectable, for these patients systemic chemotherapy is the standard care.

Without any treatment the median survival after detection of liver metastases is approximately 9 months, depending on the extent of the disease at the time of diagnosis<sup>1</sup>. Generally, colorectal liver metastases do not cause any signs or symptoms. Only in advanced stages may patients suffer from cachexia, fatigue, icterus, or sometimes pain due to stretching of the liver capsula.

### Screening

To detect liver metastases in an early curable stage, patients with primary colorectal cancer should be actively screened for the presence of liver metastases at the time of diagnosis of the primary tumor as well as during follow-up after curative resection of the primary.

Patients at the time of diagnosis of primary colorectal carcinoma can be screened for the presence of liver involvement by abdominal ultrasound. In case liver metastases are detected, intraoperative ultrasound should be planned to judge resectability of the metastases. Currently, there is wide variation in follow-up after resection of the colorectal primary. Some authors have postulated that intensive follow-up would lead to early detection of metachronous tumors and thus improved survival, while others have questioned the need for follow-up at all. A recent systemic review and meta-analysis of several randomized trials demonstrated that intensive follow-up by regular measurements of serum carcinoembryonic antigen (CEA) and computed tomography (CT) after curative resection of colorectal cancer can lead to earlier detection of recurrences and is associated with improved survival<sup>2</sup>. In patients who are fit enough to undergo liver surgery regular CEA measurements (every 3 months) and intermittent liver imaging, e.g. by abdominal ultrasound, should be regarded as a minimum during the first 3 years after colorectal resection. Recent guidelines by the American Society of Clinical Oncology even mention annual CT of the chest and abdomen for the first 3 years after surgery in high risk patients (stage II and III) who are eligible for surgery with curative intent<sup>3</sup>.

### Patient selection

When liver metastases are detected, patients should be carefully evaluated for the possibility of surgical resection of the liver metastases. In order to decide whether surgical resection can lead to meaningful prolongation of survival,



it is important to review carefully the prognostic factors that have been defined to determine clinical outcome. The variables most consistently associated with poor prognosis and tumor recurrence are tumor positive resection margin of the removed specimen and extrahepatic disease at the time of surgery for liver metastases (Table 20.1)<sup>4–13</sup>.

### Radical resection

Tumor positive resection margins should be avoided at any time, since survival under such circumstances hardly differs from natural history. This understanding should force every surgeon to make the critical judgment before surgery about whether there is a fair chance that all tumor tissue can be adequately removed.

### Extrahepatic disease

The presence of extrahepatic disease is generally considered a contraindication to resection. An exception can be made for resectable lung metastases or locally invasive disease that can be resected together with the liver lesions (e.g. involvement of the diaphragm of the adrenal). After combined resection of liver and lung metastases several series report a 5-year survival rate of more than 20% and some even close to 30%<sup>14</sup>. In patients with peritoneal metastases or intra-abdominal lymph node metastases surgical treatment does not seem to prolong survival, although some series argue that an exception may be made for isolated nodes in the hepatoduodenal ligament<sup>15</sup>. In these cases, hepatic resection in combination with lymphadenectomy of the hepatoduodenal ligament can result in long-term survival.

### Other factors

Other factors that are related to survival after resection are the number of metastases, the size of the metastases, the time interval between the primary tumor and metastases, the original staging of the primary tumor, and high preoperative CEA levels. Each of these factors has only a limited impact

on survival and should not be considered an absolute contraindication to resection. However, summation of all these factors may clearly influence definite outcome. To direct clinical decision making several clinical risk scores have been formulated based on these prognostic factors<sup>6,8,12</sup>. In a clinical scoring system by Fong *et al.* the following five prognostic variables are assigned one point: disease-free interval from primary disease to metastases less than 12 months, node-positive primary tumor, more than one tumor, largest tumor size more than 5 cm, and CEA less than 200 ng/ml. The total score ranging from 0 to 5 has been proven to be highly prognostic for long-term outcome. Patients with a score equal to or lower than 2 showed a 5-year survival rate after resection of more than 40% compared with a 5 year survival of less than 25% for those patients with a score of 3 or more.

Today, the main guidelines for patient selection, and hence preoperative staging for hepatic surgery, are to exclude extrahepatic disease and to judge whether negative resection margins can be obtained. Synchronous metastases, multiple metastases, or bilobar disease, which all were considered contraindications to resection in the past, are no longer an obstacle to resection as long as the remnant liver after resection is large enough (>30%) to prevent liver failure<sup>16,17</sup>.

### Preoperative staging

Preoperative staging of patients with colorectal liver metastases should concentrate on the accurate imaging of the number, size and location of the metastatic lesions within the liver as well as on the detection of possible extrahepatic disease.

### Liver

Multislice CT scan with intravenous contrast is currently regarded as the standard method for evaluating the anatomy and resectability of colorectal liver metastases<sup>16</sup>. The sensitivity of multislice CT scan for the detection of

**Table 20.1** Prognostic factors after hepatic resection of colorectal cancer liver metastases

<i>Author/year</i>	<i>Number of patients</i>	<i>Size lesions</i>	<i>Synchronous metachronous</i>	<i>Stage primary tumor</i>	<i>Number of metastases</i>	<i>Extrahepatic disease</i>	<i>Resection margin</i>
Hughes 1988 <sup>7</sup>	859	Yes	Yes	Yes	Yes	Yes	Yes
Scheele 1995 <sup>13</sup>	350	No	Yes	Yes	No	Yes	Yes
Jaeck 1997 <sup>9</sup>	747	Yes	No	Yes	Yes	Yes	Yes
Jamison 1997 <sup>10</sup>	280	No	No	No	No	Yes	Yes
Fong 1997 <sup>5</sup>	456	Yes	Yes	Yes	Yes	Yes	Yes
Elias 1998 <sup>4</sup>	270	No	No	No	No	Yes	Yes

colorectal liver metastases larger than 1 cm is around 75%, and increases to over 95% for lesions larger than 2 cm<sup>18</sup>. For lesions smaller than 1 cm this percentage is below 50%. For optimal imaging, slice thickness should be less than 5 mm, with adequate amounts of contrast and scanning particularly in the portal phase. Alternatively magnetic resonance imaging (MRI) scanning can be used with gadolinium or liver-specific contrast agents. As the performance of multislice CT scanning and MRI for detection of liver metastases is comparable, the selection of either technique will be determined mainly by local availability and preferences. Recently, metabolic imaging by positron emission tomography (PET) scan and PET-CT scan has been introduced for the detection of liver metastases. Results thus far show that the sensitivity of fluorodeoxyglucose (FDG) PET for the detection of liver metastases is comparable with that of CT<sup>19</sup>. Although the sensitivity of the metabolic imaging by FDG-PET and the anatomic imaging by CT or MRI seems comparable, FDG-PET by itself will not become a substitute for the excellent anatomical imaging provided by CT or MRI. Precise delineation of the liver metastases to anatomical structures, as depicted by CT or MRI, is essential for the surgeon to decide whether resection of the liver metastases is possible.

Further development of combined modalities of CT and PET imaging, thereby presenting overlays of anatomical (CT) and functional (PET) information, may, however, still lead to significant improvement of preoperative liver staging and preoperative judgment regarding resectability.

With the present imaging techniques there is no place for liver biopsies to confirm the diagnosis. Liver biopsies may lead to metastatic seeding and hence may interfere with curative resection afterwards.

### *Extrahepatic imaging*

CT scan of the chest, abdomen and pelvis is generally standard practice to exclude extrahepatic disease. Specificity of multislice CT for lung metastases, however, is low and prudence is required not to overestimate the significance of small non-specific nodules. Whole body survey and analysis by metabolic activity, as performed during FDG-PET, may substantially add to the conventional anatomic imaging by CT. In most series, FDG-PET led to clinical relevant extrahepatic findings different from conventional imaging in 20–30% of the cases<sup>19,20</sup>. To exclude large bowel recurrence or any new primary colon malignancy, X-ray or colonoscopy can be performed.

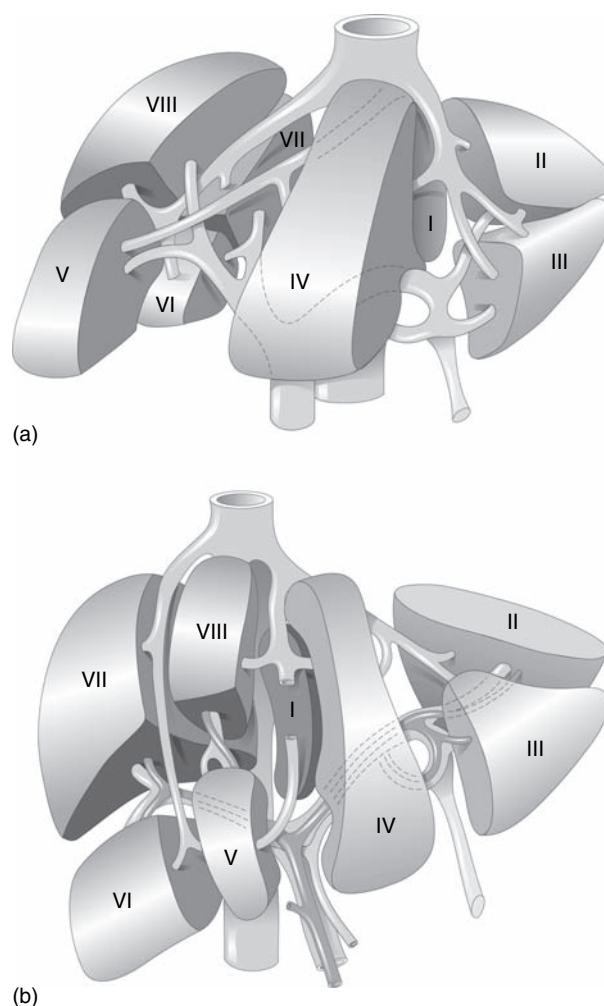
### **Resection**

Resection is the gold standard for the surgical treatment of colorectal liver metastases<sup>6,8,12,16,17,21</sup>. It should be considered

in all patients with metastatic disease confined to the liver, irrespective of size, number, or multilobar localization of the lesions, as long as all lesions can be removed adequately while leaving enough functional liver reserve.

### *Operative procedure*

At laparotomy the abdomen is carefully inspected for extrahepatic disease. Intraoperative ultrasound is performed in order to determine the number of metastatic lesions and to assess the localization of the metastases in relation to the vascular structures and main bile ducts. Detailed knowledge of the segmental structure of the liver is essential for a safe surgical procedure (Figure 20.1). A large variety of resections can be undertaken, following the distribution of the metastases. With an increasing tendency to perform hepatic resection for a second or even third time in case of liver recurrence, there is a trend to avoid extensive



**Figure 20.1** Functional division of the liver and liver segments according to Couinaud's nomenclature (a) as seen in the patient and (b) in *ex vivo* position. Reproduced from reference 22, with permission.

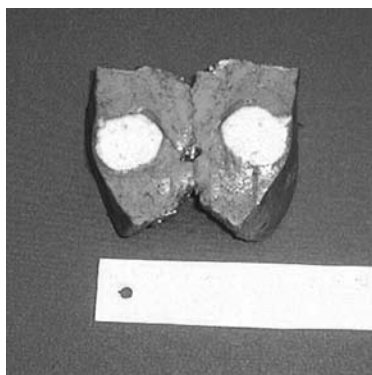
resections when not absolutely indicated to obtain adequate margins. A liver-sparing approach offers significant better opportunities for secondary liver surgery and facilitates postoperative recovery. Surface oriented metastases can be excised by non-anatomic wedge resections, whereas deeper solitary lesions can be treated by segmentectomy or bisegmentectomy. (Figure 20.2). Large lesions or multiple lesions are treated by right or left hepatectomy or multiple segmentectomies in case of bilobar disease.

To control intraoperative hemorrhage, several methods of vascular clamping can be applied such as: non-selective intermittent clamping of the portal triad (Pringle maneuver); complete vascular exclusion of the liver, including clamping of the hepatic pedicle, infra- and suprahepatic vena cava; and selective vascular occlusion or ligation of the hepatic artery, portal vein and hepatic vein of the depending site of the parenchymal resection. The venous pressure within the inferior vena cava should be maintained at a low level (<5 mmHg) to minimize blood loss during parenchymal dissection, especially in those cases where hepatic veins are not controlled.

Parenchymal division can be performed in several ways. The easiest way is to crush small portions of liver tissue with a small forceps. Smaller vessels that are encountered are coagulated, while larger vessels and biliary structures are ligated. Several instruments are available on the market to facilitate parenchymal dissection such as ultrasonic dissectors and waterjet dissectors. More recently, coagulation equipment has been developed to transect the liver tissue, e.g. by sealing the vascular structures or by coagulation of liver tissue with the help of radiofrequency energy. The choice of transection method is mainly based on the preference and expertise of the surgeon.

### Perioperative mortality and morbidity

Hepatic resection has become an increasingly safe procedure during the past two decades. Mortality in recent



**Figure 20.2** Resection specimen after local wedge resection of solitary colorectal liver metastasis.

series is below 5% despite an increasing aggressive approach to treat patients at an older age and patients with more extensive liver involvement<sup>5,6,10–13,23–26</sup>. In most series mortality is related to the extent of liver resection. For example in a series of 456 patients mortality after local and segment resections was 0.5% compared with 4.6% after more extensive resections<sup>5</sup>.

Reported morbidity in most series of liver resections varies from 20 to 40% and is strongly influenced by operative blood loss and preoperative liver function. Pulmonary complications, which are often related to upper abdominal surgery, such as pneumonia and atelectasis, are observed in 5–10% of the patients, and cardiac complications are encountered in 3–5% of the cases. Pleural effusion is often encountered after hepatic surgery but treatment is seldom necessary. Wound problems occur in about 5%, while abscesses, bile fistula and biloma are described in 2–5 % of the patients. Liver failure and hemorrhage also vary between 1 and 5% depending on the extent of hepatic resection.

Patients are generally discharged from the hospital within 7–10 days, depending on the extent of the resection. Health-related quality of life is generally fully restored within 3 months after of the procedure.

### Survival

Many studies over the past two decades have demonstrated long-term survival after liver resection for colorectal liver metastases (Table 20.2). Five-year survival rates after resection in these series varies from 27 to 59%<sup>6,10–13,23–26</sup>. Ten-year overall survival has been reported to be between 20 and 28%, indicating that liver resection can cure patients with colorectal liver metastases.

**Table 20.2** Results of hepatic resection of colorectal cancer liver metastases

<i>Author/Year</i>	<i>Number of patients</i>	<i>Operative mortality (%)</i>	<i>5-Year survival (%)</i>	<i>10-Year survival (%)</i>
Scheele 1995 <sup>13</sup>	350	4.4	38	23
Nordlinger 1996 <sup>12</sup>	1568	2.3	28	
Jamison 1997 <sup>10</sup>	280	4	27	20
Fong 1999 <sup>6</sup>	1001	2.8	37	22
Minagawa 2000 <sup>11</sup>	235	0	38	26
Sugawara 2001 <sup>25</sup>	331	0	46	
Choti 2002 <sup>23</sup>	226	0.9	40	26
Fernandez 2004 <sup>24</sup>	100	1	59	
Wei 2006 <sup>26</sup>	395	1.7	47	28

Differences in survival are mainly related to patient selection. Moreover, multicenter studies often report lower survival data compared with single center studies, emphasizing the importance of experience in high-volume centers. Survival differences according to the clinical risk score of Fong *et al.* are shown in Figure 20.3<sup>6</sup>. According to preoperative criteria, this scoring system enables the clinician to predict the results after curative resection.

There is still some uncertainty about the best timing of hepatic resection in patients with liver metastases at the time of presentation of the primary tumor. Some reports suggest delaying hepatic surgery by 3 months in order to judge the biological behavior of the metastatic disease. In case of explosive growth an unnecessary resection is prevented. However, most centers favor immediate resection, especially when the number of metastatic lesions is limited. In these circumstances waiting for resection may result in larger lesions which need more extensive resections and hence more morbidity.

### Resection margins and survival

It should be stressed that the above results apply only for those patients in whom resection margins of the resected specimen are negative for tumor. As stated earlier patients with positive resection margins hardly benefit from resection,

for these patients the 5-year survival rates vary in different studies between 0 and 17%<sup>4,5,7,9,13</sup>.

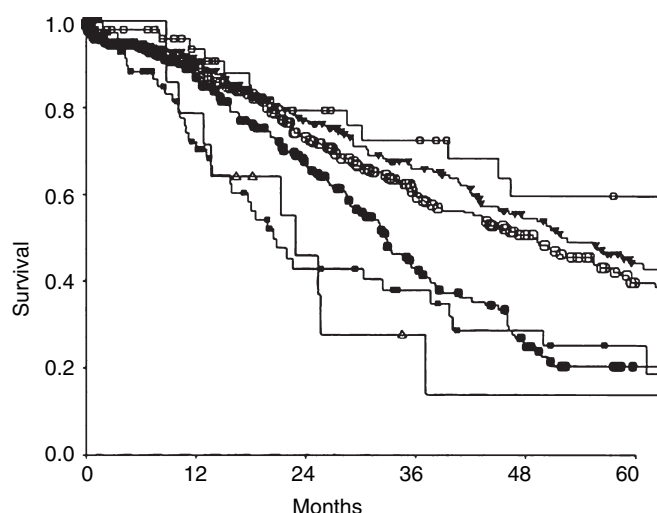
Although in general a resection margin of 1 cm or more is aimed for, the location of the metastases does not always allow such a margin. Many studies indicate, however, that the resection specimen can still be considered adequate as long as the resection margins are microscopically free of tumor. For example, in a multicenter report there was no difference in survival or local rate of tumor recurrence in the liver regardless the extent of the tumor-free resection margin<sup>27</sup>.

### Disease-free survival and tumor recurrence

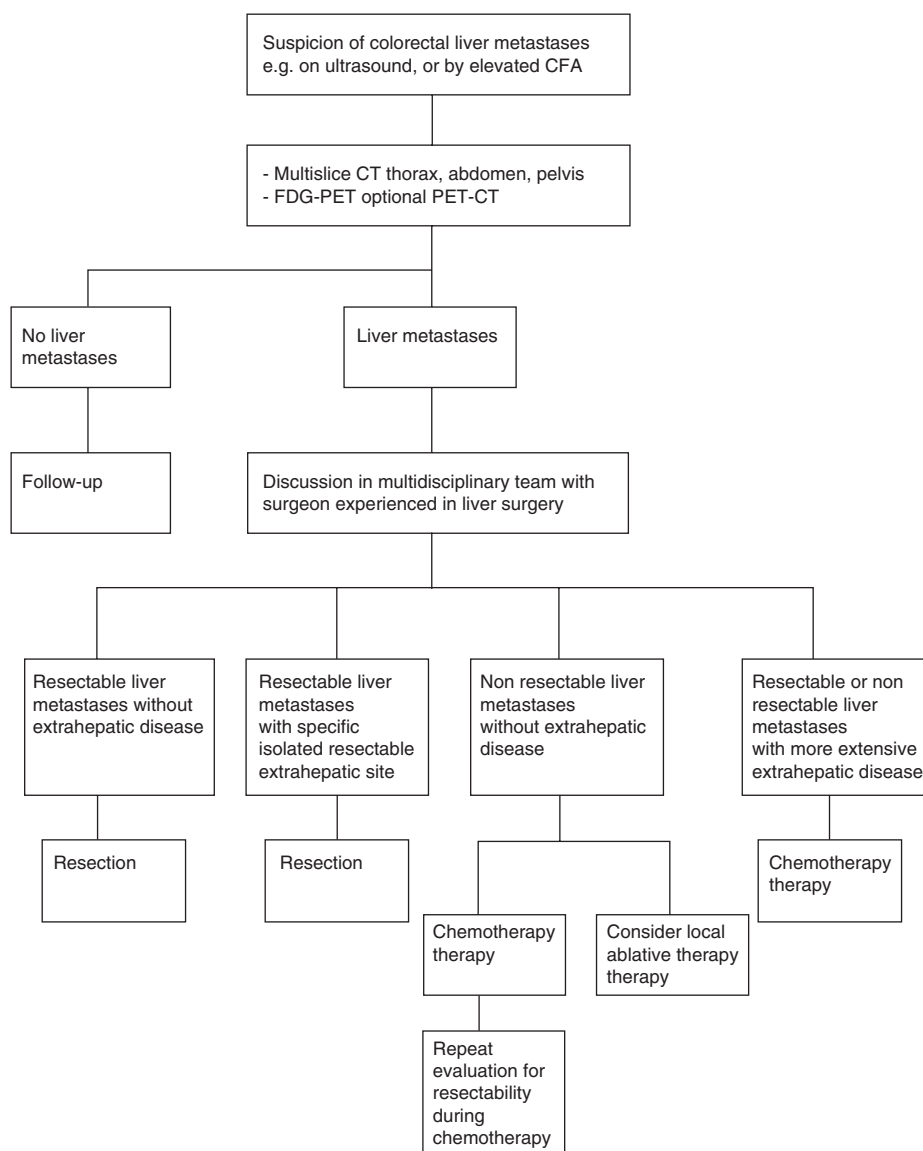
In about two-thirds of patients tumor recurrence will occur<sup>4,6,10–13,23–26,28</sup>. Median disease-free survival after hepatic resection varies between 15 and 22 months<sup>5,12,23,24,26</sup>. In half of these cases the first site of recurrence is within the remaining liver. The other half shows extrahepatic recurrence in the lungs and at intraabdominal sites. Local recurrence at the resection site is low and generally reported below 5%. In patients with isolated liver recurrence as well as in those who only show lung metastases surgery should be considered. Several studies show a 5-year survival rate close to 30% after secondary resection of liver metastases from colorectal cancer<sup>29</sup>.

### Adjuvant treatment

Whether the use of adjuvant chemotherapy after resection of the metastases can decrease the recurrence rate is still a matter of dispute. Several retrospective and prospective studies have investigated the effectiveness of adjuvant chemotherapy after resection of colorectal liver metastases<sup>21</sup>. Results from retrospective studies are conflicting, with two studies demonstrating no benefit and two suggesting some advantage. Since the remnant liver is often the primary site of recurrence, the use of adjuvant chemotherapy by hepatic artery infusion was also extensively tested. A multicenter prospective German study failed to show any benefit on survival of adjuvant postoperative intra-arterial treatment using fluorouracil (5-FU) and folinic acid<sup>30</sup>. Another study demonstrated a significant improvement in 4-year recurrence-free survival of hepatic artery infusion plus systemic chemotherapy compared with surgery alone (46% vs. 25%,  $p = 0.04$ )<sup>31</sup>. Median overall survival, however, did not reach statistical difference. Furthermore, a recent meta-analysis failed to show any significant advantage of adjuvant intrahepatic chemotherapy, although there was a trend towards better survival after adjuvant treatment<sup>32</sup>. More recently, however, a multicentre randomised trial was completed, that studied the added value of adjuvant systemic chemotherapy after liver resection compared



**Figure 20.3** Survival after resection of colorectal liver metastases according to the prognostic scoring system of Fong *et al.* Five prognostic variables are assigned one point: disease-free interval from primary disease to metastases <12 months, node-positive primary tumor, >1 tumor, largest tumor size >5 cm, carcinoembryonic antigen (CEA) >200 ng/ml. The total score ranging from 0 to 5 has been proven to be highly prognostic for long-term outcome. Open box, score 0 ( $n = 52$ ); filled triangle, score = 1 ( $n = 262$ ); open circle, score = 2 ( $n = 350$ ); filled circle, score = 3 ( $n = 243$ ); filled box, score = 4 ( $n = 80$ ); open triangle, score = 5 ( $n = 14$ ). Reproduced from reference 6, with permission.



**Figure 20.4** Algorithm for the management of colorectal liver metastases. CEA, carcinoembryonic antigen; CT, computed tomography; FDE-PET, fluorodeoxyglucose-positron emission tomography.

to surgery and observation alone. {Portier,} Despite a sub-optimal chemotherapy regimen, which was the standard at the beginning of the study, adjuvant intravenous chemotherapy provided a significant disease-free survival benefit, with a 5-year disease-free survival rate of 33.5% for the adjuvant chemotherapy group and 26.7% for patients in the control group. A trend towards increased overall survival was observed, however, the study failed to detect a statistically significant benefit (5-year overall survival 51% versus 41%). Very recently the results of an EORTC phase III study became available {Nordlinger,} investigating the benefit of combining perioperative chemotherapy (FOLFOX4: oxaliplatin, leucovorin, folinic acid and 5-fluorouracil) with surgery versus surgery alone for

patients with initially resectable liver metastases. Perioperative chemotherapy improved progression free survival over surgery alone in patients whose metastases were actually resected. These studies indicate that adjuvant chemotherapy after resection of colorectal liver metastases should become standard<sup>33,34</sup>.

### Local tumor ablation

In many patients with colorectal liver metastases confined to the liver, resection of the metastases cannot result in adequate clearance of all tumor tissue from the liver. This may be the case either because of the number of metastatic liver lesions or because of the location of the metastases.

Examples are patients with more diffuse bilobar disease or with unresectable recurrence after previous liver surgery. It is in this group of patients with unresectable colorectal liver metastases that local ablative techniques, such as radiofrequency, microwave, or laser, can be used to clear the liver of all metastatic tumor lesions<sup>21</sup>. The basic idea behind local tumor ablation is to selectively destruct tumor tissue (including a rim of normal tissue around the tumor) without causing any significant damage to vascular structures in the remaining liver and hence any consequent loss of large areas of normal liver tissue.

Of the different techniques available, radiofrequency is most widely used. During radiofrequency a small electrode is placed within the tumor and used to deliver radiofrequency energy to the tissue resulting in heat and tissue destruction. For radiofrequency, adequate local tumor control has been described for tumors up to 4–5 cm<sup>27, 35–38</sup>. The accuracy of the techniques is mainly determined by adequate imaging of the procedure by ultrasound.

Radiofrequency ablation can be performed percutaneously, laparoscopically and by laparotomy. In a recent review by Mulier *et al.* the open and laparoscopic approach seemed to be more reliable and resulted in lower local recurrence rates compared with the percutaneous approach<sup>37</sup>. For tumors less than 3 cm, the local recurrence rate after open or laparoscopic approach was zero versus 19% for the percutaneous approach. For lesions larger than 3 cm, the local recurrence rate after the open or laparoscopic approach was 20% versus 51% for the percutaneous approach. Although the results of radiofrequency for small liver metastases are promising, there are no data available yet showing that local tumor ablative techniques are equally efficient as resection. Hence, for the moment local tumor ablation should not be considered as a substitute for resection.

Also, in patients with unresectable metastases the precise impact of local tumor ablative therapy on survival in colorectal liver metastases is still unclear. No randomized studies have been performed investigating local aggressive treatment of liver metastases in combination with chemotherapy versus chemotherapy alone. From the uncontrolled studies performed in patients with unresectable colorectal liver metastases, the ultimate effect of radiofrequency on overall survival is still difficult to judge. Altogether several studies have shown median overall survival times of more than 30 months after radiofrequency treatment. These results have been claimed to be superior to standard treatment by chemotherapy, which nowadays can result in a median survival of 20 months. The superior results of local ablative therapy compared with chemotherapy may certainly be due to patient selection. Controlled clinical trials are urgently needed in order to prove whether indeed local tumor destruction is of any value in patients with unresectable colorectal liver metastases.

## Ways to increasing resectability rates

### *Portal vein embolization and staged resection*

Resection of liver metastases may lead to severe postoperative liver failure if the functional reserve of the remaining liver remnant is too small. To overcome this problem preoperative portal vein embolization (PVE) or staged resection of liver metastases can be considered<sup>38</sup>.

Portal vein occlusion of one side of the liver leads to atrophy of the homolateral liver lobe and compensatory hypertrophy of the contralateral liver lobe. By portal vein embolization of the liver lobe that is harboring the tumor mass, the remnant liver lobe will show hypertrophy within 2 weeks after the procedure due to hepatocyte regeneration. The increase in volume of the remnant liver ranges from 7 to 27% after PVE. In this way the functional reserve of the liver can be increased within 2–4 weeks allowing more extensive resections. Several studies show that overall survival after portal vein embolization is comparable with metastasectomy without portal vein embolization.

In patients with diffuse multinodular metastases staged liver resection can also be an alternative for conservative treatment<sup>40</sup>. During the first operation the highest possible number of metastases are resected. After operation the liver remnant regenerates accompanied by an increase of the functional capacity of the liver. During this period, systemic chemotherapy is given to hamper outgrowth of metastases. At a later stage, when the functional capacity has been restored, a second stage curative resection of the residual liver metastases is performed. In patients with diffuse metastases in the liver, a two-stage hepatectomy can offer a chance of long-term remission.

### *Resection after chemotherapy in patients with initially unresectable disease*

Chemotherapy of colorectal cancer has improved substantially over the past 10 years with currently reported response rates up to 70–80%<sup>41–44</sup>. These results have prompted reports on the resection of initially unresectable liver metastases that were converted to resectable disease after chemotherapy. The benefit in survival after combined treatment of preoperative chemotherapy and subsequent resection is shown to be comparable with that obtained with primary liver resection. For example, in a study by Bismuth *et al.*, performed in patients with initially unresectable liver metastases, the 5-year overall-survival rate after combined treatment with neoadjuvant chemotherapy and subsequent resection was 40%<sup>45</sup>. The number of patients that may benefit from such an approach varies significantly according to the efficacy of the different chemotherapy regimens and the initial selection criteria for

unresectable disease<sup>41</sup>. In patients with initially unresectable metastatic disease confined to the liver more than 25% of the patients may become resectable compared with approximately 10% in series of non-selected patients with metastatic colorectal cancer. Most studies evaluating the results of secondary resections after chemotherapy used modulated 5-FU regimens combined with oxaliplatin or irinotecan, which all produce response rates over 50%. Liver resection after neoadjuvant chemotherapy is safe and can be performed with a mortality rate comparable with primary resection. Some precautions should be taken, however, with regard to the extent of resection after long-term use of oxaliplatin which is associated with signs of hepatic veno-occlusive disease<sup>46</sup>.

## Chemotherapy

For the past few decades, chemotherapy for metastatic colorectal cancer was only of limited benefit due to the lack of effective chemotherapeutic drugs<sup>42–44</sup>. For a long period of time, fluoropyrimidines (e.g. 5-FU) in combination with leucovorin (LV) formed the mainstay of chemotherapy for metastatic colorectal cancer. Many types of schedules were tested, all leading to response rates of around 25% and a median overall survival of 10–12 months. The results of chemotherapy have changed markedly with the introduction of new drugs like irinotecan, oxaliplatin and, more recently, the biological agents such as monoclonal antibodies that target vascular endothelial growth factor (bevacizumab) and the epidermal growth factor receptor (cetuximab)<sup>47–50</sup>.

Combination chemotherapy incorporating oxaliplatin or irinotecan with infusional 5-FU/LV or recently with orally active fluoropyrimidines such as capecitabine results in a median overall survival that consistently approaches 20 months<sup>42–44</sup>.

Chemotherapy should generally be started at the time of diagnosis of metastatic disease when most patients are still asymptomatic. There is still debate concerning the optimal treatment regimen that should be given as first-line treatment and the place of biologicals in first-line treatment. Within this context it is important to note that overall survival is mainly dependent on the exposure to all active drugs, instead of the exact time point or sequence of administration<sup>42–44</sup>.

Despite all the recent advances in new agents, 5-year overall-survival rates with chemotherapy remain limited. For this reason, the possibility for resection should always be considered in those patients in which upfront unresectable liver metastases are converted to resectable disease during the course of chemotherapy. Such decisions should be taken in close collaboration between surgeons, medical oncologists, gastroenterologists, and radiologists. This

also illustrates that optimal treatment of colorectal liver metastases is only possible within a multidisciplinary team. Such a team should be in place in every hospital dealing with liver surgery of colorectal liver metastases.

## LIVER METASTASES FROM NON-COLORECTAL AND NON-NEUROENDOCRINE PRIMARY TUMORS

The role of hepatic resection for patients with non-colorectal, non-neuroendocrine (NCNN) liver metastases is far less defined. Isolated liver metastases of NCNN origin are relatively rare since generally liver metastases in NCNN disease reflect systemic metastatic disease. The literature does not provide clear indications or contraindications to resection of these NCNN metastases. Only a limited number of series have been reported on resection of NCNN metastases<sup>51–53</sup>. Patient selection in these series is very diverse and it is impossible to give evidence-based guidelines. Series that describe a collection of all types of non-colorectal liver metastases report a 3-year survival rate after resection between 30 and 45%, and a 5-year survival between 10 and 37%. The best results are achieved with liver metastases from genitourinary tumors. In a heterogeneous group of 34 genitourinary tract tumors (kidney, adrenal, testis, ovary, cervix, uterus), Harrison *et al.* describe a 5-year survival rate of 60%<sup>51</sup>. In several of these cases hepatic resection was performed to remove residual disease after chemotherapy. For liver metastases of sarcomas 5-year survival rates after resection vary between 15 and 20%. Even in patients with extrahepatic tumor at the time of liver resection surgery may be considered provided that complete removal of both liver and extrahepatic tumor is judged possible.

Resection of liver metastases from non-colorectal gastrointestinal tumors (pancreas, esophagus, gallbladder) is generally not advised because results are disappointing. Only in very selected cases may resection result in long-term survival. For gastric cancer several Japanese series describe more favorable results. In a small selected group of patients with liver metastases from gastric cancer, 3-year survival after resection of the metastases was 34%. Patients with solitary and metachronous metastases showed even better survival. In melanoma patients liver metastases are usually a marker of systemic disseminated disease and long-term survival after resection is rare. Ocular melanoma often selectively metastasizes to the liver. Solitary liver lesions in ocular melanoma are, however, rare. A solitary liver lesion diagnosed in a patient with ocular melanoma often appears to be a precursor of more widespread liver disease in the near future.



Also, for breast cancer isolated liver metastases are rare and generally reflect disseminated disease. Several studies, however, report promising results of resection of these metastases in a highly selected group of patients. In such patients 5-year survival rates have been achieved of over 25%, even up to 50% in very selected studies. A long interval between primary tumor and liver recurrence as well as a negative lymph node status at time of the primary tumor are particularly related to long-term survival. Although these data seem promising, the reported survival rates are estimated survival rates obtained in a very limited number of patients. Moreover, it should be realized that it only concerns a very small percentage of the total amount of metastatic breast cancer patients. With the present available literature it is impossible to give an honest estimate

of the real value of hepatic resection in metastatic breast cancer. For these reasons a conservative approach seems still most appropriate.

In conclusion, NCNN liver metastases generally indicate disseminated disease. Only in a very selected group of patients, may surgery be indicated and improve survival. Especially in patients with genitourinary tract tumors resection should be considered in order to remove residual disease after chemotherapy. For patients with other forms of primary tumors, resection seems indicated only in a very limited number of cases. In selected cases with isolated disease to the liver and a long disease-free interval after resection of the primary tumor, hepatic resection of the liver metastases may result in prolonged survival.

## REFERENCES

1. Stangl R, Altendorf-Hofmann A, Charnley RM, Scheele J. Factors influencing the natural history of colorectal liver metastases. *Lancet* 1994; 343: 1405–10.
2. Renehan AG, Egger M, Saunders MP, O'Dwyer ST. Impact on survival of intensive follow up after curative resection for colorectal cancer: systematic review and meta-analysis of randomised trials. *BMJ* 2002; 324: 813.
3. Desch CE, Benson AB III, Somerfield MR et al. Colorectal cancer surveillance: 2005 update of an American Society of Clinical Oncology practice guideline. *J Clin Oncol* 2005; 23: 8512–9.
4. Elias D, Cavalcanti A, Sabourin JC et al. Resection of liver metastases from colorectal cancer: the real impact of the surgical margin. *Eur J Surg Oncol* 1998; 24: 174–9.
5. Fong Y, Cohen AM, Fortner JG et al. Liver resection for colorectal metastases. *J Clin Oncol* 1997; 15: 938–46.
6. Fong Y, Fortner J, Sun RL et al. Clinical score for predicting recurrence after hepatic resection for metastatic colorectal cancer: analysis of 1001 consecutive cases. *Ann Surg* 1999; 230: 309–18.
7. Hughes KS, Rosenstein RB, Songhorabodi S et al. Resection of the liver for colorectal carcinoma metastases. A multi-institutional study of long-term survivors. *Dis Colon Rectum* 1988; 31: 1–4.
8. Iwatsuki S, Dvorchik I, Madariaga JR et al. Hepatic resection for metastatic colorectal adenocarcinoma: a proposal of a prognostic scoring system. *J Am Coll Surg* 1999; 189: 291–9.
9. Jaeck D, Bachellier P, Guiguet M et al. Long-term survival following resection of colorectal hepatic metastases. *Association Francaise de Chirurgie. Br J Surg* 1997; 84: 977–80.
10. Jamison RL, Donohue JH, Nagorney DM et al. Hepatic resection for metastatic colorectal cancer results in cure for some patients. *Arch Surg* 1997; 132: 505–10.
11. Minagawa M, Makuuchi M, Torzilli G et al. Extension of the frontiers of surgical indications in the treatment of liver metastases from colorectal cancer: long-term results. *Ann Surg* 2000; 231: 487–99.
12. Nordlinger B, Guiguet M, Vaillant JC et al. Surgical resection of colorectal carcinoma metastases to the liver. A prognostic scoring system to improve case selection, based on 1568 patients. *Association Francaise de Chirurgie. Cancer* 1996; 77: 1254–62.
13. Scheele J, Stang R, Altendorf-Hofmann A, Paul M. Resection of colorectal liver metastases. *World J Surg* 1995; 19: 59–71.
14. Kobayashi K, Kawamura M, Ishihara T. Surgical treatment for both pulmonary and hepatic metastases from colorectal cancer. *J Thorac Cardiovasc Surg* 1999; 118: 1090–6.
15. Jaeck D, Nakano H, Bachellier P et al. Significance of hepatic pedicle lymph node involvement in patients with colorectal liver metastases: a prospective study. *Ann Surg Oncol* 2002; 9: 430–8.
16. Garden OJ, Rees M, Poston GJ et al. Guidelines for resection of colorectal cancer liver metastases. *Gut* 2006; 55 (Suppl 3): iii1–8.
17. Poston GJ, Adam R, Alberts S et al. OncoSurge: a strategy for improving resectability with curative intent in metastatic colorectal cancer. *J Clin Oncol* 2005; 23: 7125–34.
18. Bipat S, van Leeuwen MS, Comans EF et al. Colorectal liver metastases: CT, MR imaging, and PET for diagnosis—meta-analysis. *Radiology* 2005; 237: 123–31.
19. Wiering B, Ruers TJ, Oyen WJ. Role of FDG-PET in the diagnosis and treatment of colorectal liver metastases. *Expert Rev Anticancer Ther* 2004; 4: 607–13.
20. Ruers TJ, Langenhoff BS, Neeleman N et al. Value of positron emission tomography with [F-18]fluorodeoxyglucose in patients with colorectal liver metastases: a prospective study. *J Clin Oncol* 2002; 20: 388–95.
21. Ruers T, Bleichrodt RP. Treatment of liver metastases, an update on the possibilities and results. *Eur J Cancer* 2002; 38: 1023–33.
22. Poston Blumgart. *Surgical Management of Hepatobiliary and Pancreatic Disorders*. Martin Dunitz, :4.
23. Choti MA, Sitzmann JV, Tiburi MF et al. Trends in long-term survival following liver resection for hepatic colorectal metastases. *Ann Surg* 2002; 235: 759–66.
24. Fernandez FG, Drebin JA, Linehan DC et al. Five-year survival after resection of hepatic metastases from colorectal cancer in patients screened by positron emission tomography with F-18 fluorodeoxyglucose (FDG-PET). *Ann Surg* 2004; 240: 438–47.
25. Sugawara Y, Yamamoto J, Yamasaki S et al. Estimating the prognosis of hepatic resection in patients with metastatic liver tumors



- from colorectal cancer with special concern for the timing of hepatectomy. *Surgery* 2001; 129: 408–13.
26. Wei AC, Greig PD, Grant D et al. Survival after hepatic resection for colorectal metastases: a 10-year experience. *Ann Surg Oncol* 2006; 13: 668–76.
  27. Pawlik TM, Scoggins CR, Zorzi D et al. Effect of surgical margin status on survival and site of recurrence after hepatic resection for colorectal metastases. *Ann Surg* 2005; 241: 715–22.
  28. Abdalla EK, Vauthey JN, Ellis LM et al. Recurrence and outcomes following hepatic resection, radiofrequency ablation, and combined resection/ablation for colorectal liver metastases. *Ann Surg* 2004; 239: 818–25.
  29. Neeleman N, Andersson R. Repeated liver resection for recurrent liver cancer. *Br J Surg* 1996; 83: 893–901.
  30. Lorenz M, Muller HH, Schramm H et al. Randomized trial of surgery versus surgery followed by adjuvant hepatic arterial infusion with 5-fluorouracil and folinic acid for liver metastases of colorectal cancer. German Cooperative on Liver Metastases (Arbeitsgruppe Lebermetastasen). *Ann Surg* 1998; 228: 756–62.
  31. Kemeny MM, Adak S, Gray B et al. Combined-modality treatment for resectable metastatic colorectal carcinoma to the liver: surgical resection of hepatic metastases in combination with continuous infusion of chemotherapy—an intergroup study. *J Clin Oncol* 2002; 20: 1499–505.
  32. Clancy TE, Dixon E, Perlis R et al. Hepatic arterial infusion after curative resection of colorectal cancer metastases: a meta-analysis of prospective clinical trials. *J Gastrointest Surg* 2005; 9: 198–206.
  33. Portier G, Elias D, Bouche O et al. Multicenter randomized trial of adjuvant fluorouracil and folinic acid compared with surgery alone after resection of colorectal liver metastases: FFCD ACHBTH AURC 9002 trial. *J Clin Oncol* 2006; 24: 4976–82.
  34. Nordlinger B. Final results of the EORTC Intergroup randomized phase III study 40983 [EPOC] evaluating the benefit of peri-operative FOLFOX4 chemotherapy for patients with potentially resectable colorectal cancer liver metastases. Abstract - No. LBA5 2007 ASCO Annual Meeting.
  35. Bilchik AJ, Wood TF, Allegra DP. Radiofrequency ablation of unresectable hepatic malignancies: lessons learned. *Oncologist* 2001; 6: 24–33.
  36. Bleicher RJ, Allegra DP, Nora DT et al. Radiofrequency ablation in 447 complex unresectable liver tumors: lessons learned. *Ann Surg Oncol* 2003; 10: 52–8.
  37. Mulier S, Ni Y, Jamart J et al. Local recurrence after hepatic radiofrequency coagulation: multivariate meta-analysis and review of contributing factors. *Ann Surg* 2005; 242: 158–71.
  38. Ruers TJ, de Jong KP, Ijzermans JN. Radiofrequency for the treatment of liver tumors. *Dig Surg* 2005; 22: 245–53.
  39. Azoulay D, Castaing D, Smail A et al. Resection of nonresectable liver metastases from colorectal cancer after percutaneous portal vein embolization. *Ann Surg* 2000; 231: 480–6.
  40. Adam R, Laurent A, Azoulay D et al. Two-stage hepatectomy: a planned strategy to treat irresectable liver tumors. *Ann Surg* 2000; 232: 777–85.
  41. Folprecht G, Grothey A, Alberts S et al. Neoadjuvant treatment of unresectable colorectal liver metastases: correlation between tumor response and resection rates. *Ann Oncol* 2005; 16: 1311–9.
  42. Goyle S, Maraveyas A. Chemotherapy for colorectal cancer. *Dig Surg* 2005; 22: 401–14.
  43. Lawes D, Taylor I. Chemotherapy for colorectal cancer—an overview of current management for surgeons. *Eur J Surg Oncol* 2005; 31: 932–41.
  44. Patiyl S, Alberts SR. Metastatic colorectal cancer: therapeutic options. *Curr Treat Options Oncol* 2006; 7: 389–98.
  45. Bismuth H, Adam R, Levi F et al. Resection of nonresectable liver metastases from colorectal cancer after neoadjuvant chemotherapy. *Ann Surg* 1996; 224: 509–20.
  46. Bilchik AJ, Poston G, Curley SA et al. Neoadjuvant chemotherapy for metastatic colon cancer: a cautionary note. *J Clin Oncol* 2005; 23: 9073–8.
  47. Cunningham D, Humblet Y, Siena S et al. Cetuximab monotherapy and cetuximab plus irinotecan in irinotecan-refractory metastatic colorectal cancer. *N Engl J Med* 2004; 351: 337–45.
  48. de Gramont A, Figer A, Seymour M et al. Leucovorin and fluorouracil with or without oxaliplatin as first-line treatment in advanced colorectal cancer. *J Clin Oncol* 2000; 18: 2938–47.
  49. Douillard JY, Cunningham D, Roth AD et al. Irinotecan combined with fluorouracil compared with fluorouracil alone as first-line treatment for metastatic colorectal cancer: a multicentre randomised trial. *Lancet* 2000; 355: 1041–7.
  50. Hurwitz H, Fehrenbacher L, Novotny W et al. Bevacizumab plus irinotecan, fluorouracil, and leucovorin for metastatic colorectal cancer. *N Engl J Med* 2004; 350: 2335–42.
  51. Harrison LE, Brennan MF, Newman E et al. Hepatic resection for noncolorectal, nonneuroendocrine metastases: a fifteen-year experience with ninety-six patients. *Surgery* 1997; 121: 625–32.
  52. Weitz J, Blumgart LH, Fong Y et al. Partial hepatectomy for metastases from noncolorectal, nonneuroendocrine carcinoma. *Ann Surg* 2005; 241: 269–76.
  53. Yedibela S, Gohl J, Graz V et al. Changes in indication and results after resection of hepatic metastases from noncolorectal primary tumors: a single-institutional review. *Ann Surg Oncol* 2005; 12: 778–85.

## RELEVANT WEBSITES

<http://www.uptodate.com>  
<http://www.evidis.com/oncosurge>  
[http://www.umcn.nl/userfiles/other/Met\\_Assist.xls](http://www.umcn.nl/userfiles/other/Met_Assist.xls)  
<http://www.cancer.gov>

# Kidney: renal cell carcinoma

21

Melissa R Kaufman, Michael S Cookson and Sam S Chang

---

## INTRODUCTION

Despite intensive study for well over a century, renal cell carcinoma (RCC) continues to rank as one of the most enigmatic malignancies. Our understanding of the molecular genetics of RCC remains in its infancy and, although surgical interventions for localized disease are often successful, definitive therapeutics for advanced disease remains elusive. As witnessed by several recent reviews on RCC, the significance of management of this difficult cancer remains at the forefront of modern medicine<sup>1-4</sup>. Herein we examine the fundamental information concerning RCC with an emphasis on its surgical management.

## INCIDENCE AND PREVALENCE

Although accounting for only 2.6% of adult malignancies, RCC has the ominous distinction of being the 6th leading cause of cancer deaths in the US<sup>5,6</sup>. RCC is the predominant neoplasm of the kidney, encompassing approximately 90% of all solid renal masses, and is distinguished as one of the most lethal of the urological cancers with an overall disease-specific mortality of 40%<sup>4,7,8</sup>. In 2005, 36 160 cases of RCC were predicted to occur in the US with 12 660 deaths. The widespread use of computed tomography (CT) and ultrasonography since the 1970s has contributed to a dramatic increase in the diagnosis of RCC by up to 4% per year with an estimated 126% rise in prevalence of the disease in the US over the past five decades<sup>9,10</sup>. Several studies suggest that incidental diagnosis of RCC which occurs during evaluation for general abdominal complaints may increase survival by decreasing the stage at presentation<sup>11-13</sup>. However, other data dispute the favorability of this 'lead time' bias and reveal a steadily increasing mortality rate for RCC, implying intrinsic biological changes in disease have occurred<sup>9</sup>. Large scale analysis of the Surveillance, Epidemiology, and End Results (SEER) National Cancer Institute registry database demonstrated no significant difference in the

stage of presentation of RCC diagnosed in 1973-1985 as compared with that diagnosed from 1986 to 1988<sup>14</sup>.

RCC more commonly afflicts males with a 1.6 : 1 predominance. Typically patients present during their sixth or seventh decade with RCC. Only a small percentage of renal tumors in children are of this histopathology<sup>15</sup>.

Curiously, RCC displays a racial disparity with a higher incidence in the African-American population as compared with Caucasians<sup>9,16</sup>.

## PREDISPOSING RISK FACTORS

The vast majority of cases of RCC are suspected to be sporadic with approximately 4% related to hereditary conditions<sup>8</sup>. Although numerous risk factors have been implicated in sporadic RCC, the exact etiology of the disease remains mysterious<sup>17</sup>. Several environmental and occupational exposures have been implicated as causative agents for RCC such as trichloroethylene, perchloroethylene and asbestos, with the most acknowledged and robust data supporting a relationship between tobacco use and RCC<sup>18,19</sup>. Recent meta-analysis of over 40 published studies substantiates the link between tobacco exposure and RCC, revealing a strong dose-dependent increase in relative risk of 1.38 for smokers as compared with non-smokers<sup>19</sup>. Multiple forms of tobacco use have been implicated, and cumulative tobacco dose as a causal agent is strengthened by the demonstration of an elevated risk for RCC associated with simultaneous use of several types of tobacco<sup>20</sup>.

Predisposing health issues including obesity and hypertension have additionally been linked to risk for RCC<sup>21-23</sup>. A number of other items, although designated as possible risk factors, have not yet demonstrated a causal link to RCC. These instigators include a history of kidney injury, exposure to analgesics, use of thiazide diuretics, occupational exposures in the iron, steel and petroleum industries, low socioeconomic status, and a history of hysterectomy. In addition, no definitive link between dietary factors and RCC has been demonstrated.

In end-stage renal disease (ESRD), up to 90% of dialysis patients will develop acquired cystic kidney disease (ACKD) after 5–10 years with 1–2% of this population developing RCC, representing a 5- to 100-fold increased risk of RCC<sup>8,24–26</sup>. As discussed in a following section, for screening purposes it is important to recognize that ACKD occurs in up to 13% of ESRD patients not receiving dialysis<sup>27</sup>.

Four major hereditary cancer syndromes have a proven relationship with RCC: von Hippel-Lindau syndrome (VHL), hereditary renal carcinoma, hereditary papillary renal carcinoma, and the Birt-Hogg-Dube syndrome (BHD)<sup>2,8</sup>. Hereditary papillary RCC has autosomal dominant inheritance and the genetic defect has been localized to the receptor tyrosine kinase MET on chromosome 7<sup>28</sup>. BHD is a rare autosomal dominant disorder distinguished by fibrofolliculomas and multiple renal tumors of chromophobe or oncocytoma histology<sup>29</sup>. Although less dramatic than the aforementioned cancer syndromes, other genetic conditions are likewise associated with RCC. Approximately 2% of patients with tuberous sclerosis (TS) develop RCC, although controversy exists concerning whether there is an increased incidence from that of the general population for the TS patient<sup>8,30,31</sup>. Additionally, renal medullary carcinoma is a rare subtype of RCC that arises in patients with sickle cell trait.

Prominent among the familial RCC syndromes is VHL, a rare, autosomal dominant disorder manifesting with pheochromocytomas, retinal angiomas, hemangioblastomas of the central nervous system, pancreatic cysts, pancreatic adenocarcinoma, epididymal cysts, and the clear cell variant of RCC<sup>8,32</sup>. Approximately half of patients with VHL develop RCC, with RCC now the most prevalent cause of mortality in VHL patients. RCC in VHL patients is often bilateral, multifocal and strikes patients at an early age in comparison to sporadic RCC. In 1993, the von Hippel-Lindau tumor suppressor gene was identified on chromosome 3p<sup>33</sup>. The product of the *VHL* gene, the VHL protein, behaves as a tumor suppressor, inhibiting hypoxia-inducible proteins involved in angiogenesis, cell growth, glucose uptake, and acid–base balance<sup>3,34,35</sup>. Loss of the VHL protein results in overexpression of molecules such as vascular endothelial growth factor (VEGF), creating an environment ripe for cell proliferation. Disruption of the *VHL* locus is also seen in 60–75% of non-hereditary renal carcinomas<sup>36,37</sup>. As discussed in a subsequent section, the molecular characterization of these genes and the signaling pathways they regulate will be a crucial key to defining therapeutic agents specific for RCC.

## PRESENTATION

Historically, RCC presented with a classic triad of hematuria, flank pain and an abdominal mass. Currently, only

about 10% present with the archetypal symptoms and it is estimated that approximately 50% of RCC is actually detected incidentally during radiological evaluation<sup>8,38,39</sup>. This incidental finding of renal lesions on imaging studies has increased dramatically with routine use of sonography and CT scanning for evaluation of abdominal complaints. The likelihood of incidental diagnosis was 13% between 1961 and 1973, increasing to up to 61% from 1989 to 1993<sup>40,41</sup>. The fact that almost half of all RCC is found in asymptomatic patients verifies the insidious nature of tumor growth and progression seen in the majority of patients. The retroperitoneal location of RCC allows for substantial advancement of disease prior to manifestation of clinical sequelae. Unfortunately, the first symptoms of RCC are often from local extension, metastases, or paraneoplastic syndromes<sup>42</sup>. Over 20% of patients with RCC are afflicted with paraneoplastic symptoms including hypercalcemia, hypertension, polycythemia, anemia, and non-metastatic hepatic dysfunction classified as ‘Stauffer’s syndrome’. The hepatic dysfunction associated with RCC, which can include elevated alkaline phosphatase, prothrombin time, bilirubin, and transaminases as well as hypoalbuminemia, will normalize after nephrectomy in the majority of patients<sup>8</sup>. Other constitutional symptoms include weight loss, fever, neuromyopathy, and amyloidosis. Physical examination findings of a palpable flank mass, lymphadenopathy, a non-reducing varicocele, and lower extremity edema are concerning for advanced RCC.

## SCREENING AND DIAGNOSTIC STRATEGIES

Screening for RCC with imaging and urinalysis is currently focused on the high risk patients with familial RCC and ESRD<sup>8</sup>. The incidence of RCC in the general population does not support widespread screening due to an unacceptably elevated false positive rate. Currently, there are no specific serum or urinary markers to identify patients with RCC and the primary diagnostic modality is radiographic.

Between 83% and 90% of all solid renal masses identified by imaging are RCCs<sup>43</sup>. Accordingly, the diagnosis of RCC should be considered in all patients with a suspected solid renal mass. A renal mass detected on either intravenous pyelography or ultrasound is usually confirmed by CT<sup>44</sup>. Typically, RCCs are characterized on CT by a solid parenchymal mass with a heterogeneous density and enhancement with intravenous contrast injection (average of 115 Hounsfield units in the corticomedullary phase)<sup>45</sup>. Up to 7% of RCCs are cystic and a classification system designed by Bosniak is utilized

to distinguish benign and malignant lesions<sup>46,47</sup>. Despite sophisticated modern imaging, some benign tumors and complex cysts may be indistinguishable from cancer and confirmed only after surgical excision. Additionally, metastatic deposits from a variety of malignancies including breast, lung and gastrointestinal cancers may involve the kidney and percutaneous biopsy may be considered in patients with known or suspected extrarenal disease<sup>48</sup>; however, some authors indicate biopsy is unwarranted even in these circumstances<sup>49</sup>. Biopsy is additionally indicated for differentiation of renal abscess or in the diagnosis of suspected lymphoma<sup>50</sup>. The role of percutaneous biopsy or needle aspiration in discriminating an indeterminate renal mass remains controversial, and the absence of malignant cells on biopsy does not rule out the possibility of a neoplasm. Complications of renal biopsy include bleeding, infection, arteriovenous fistula, pneumothorax, and potential seeding of the biopsy tract with cancer. For these reasons, percutaneous renal biopsy for diagnostic purposes should be used selectively.

Surgical excision remains the only effective and potentially curative therapy for clinically localized RCC and can play a role in advanced disease. Preoperative evaluation, in addition to a thorough history and physical examination, generally includes a complete metabolic panel which incorporates a serum creatinine, alkaline phosphatase and liver function studies. As mentioned above, clinical staging in patients suspected of RCC usually includes a contrast-enhanced CT of the abdomen, often with three-dimensional reconstructions; however, magnetic resonance imaging (MRI) is occasionally employed and is particularly useful in patients with a history of an intravenous iodinated contrast allergy, renal insufficiency, or a suspected vena caval thrombus<sup>51</sup>. From these imaging modalities, a number of factors can be determined, including the size and potential resectability of the primary lesion, the presence or absence of lymphadenopathy and/or metastasis, involvement of adjacent structures and the status of the contralateral kidney. A chest radiograph is routinely obtained to rule out lung metastasis. Bone scans are performed in any patients with symptoms referable to the bone, as well as an elevation in serum alkaline phosphatase or hypercalcemia. In cases of suspected vena caval involvement, Doppler ultrasound is a useful screening tool. However, if results are equivocal or if a vena caval thrombus is confirmed, a vascular phase MRI is usually able to determine the level of extension of the tumor thrombus allowing the surgeon to properly plan an operative strategy. Other technologies that may benefit in preoperative planning for excision of tumors extending into the vena cava and the right atrium include CT angiography and transesophageal echocardiography.

## STAGING

Pathological staging remains the pre-eminent prognostic variable in terms of patient survival, and the two most commonly utilized staging systems are the Robson classification and the currently recommended tumor, nodes and metastasis (TNM) staging system of the International Union Against Cancer and the American Joint Committee on Cancer<sup>52-54</sup>. Both staging systems have demonstrated an inverse relationship between survival and increasing stage, but the TNM is generally considered more accurate because it precisely defines the extent of disease<sup>55-57</sup> (Table 21.1).

**Table 21.1** Renal cell carcinoma staging

### *Primary tumor (T)*

TX	Primary tumor can not be assessed
T0	No evidence of primary tumor
T1	Tumor $\leq 7$ cm, limited to kidney
T1a	Tumor $\leq 4$ cm, limited to kidney
T1b	Tumor $>4$ cm and $<7$ cm, limited to kidney
T2	Tumor $>7$ cm, limited to kidney
T3	Tumor extends into major veins or invades adrenal gland or perinephric tissues but not beyond Gerota's fascia
T3a	Tumor invades adrenal gland or perinephric tissues but not beyond Gerota's fascia
T3b	Tumor grossly extends into renal vein or vena cava below diaphragm
T3c	Tumor extends into vena cava above diaphragm
T4	Tumor invades beyond Gerota's fascia

### *Regional lymph nodes (N)*

NX	Regional lymph nodes cannot be assessed
N0	No regional lymph node metastasis
N1	Metastasis in a single regional lymph node
N2	Metastasis in more than one regional lymph node

### *Distant metastases (M)*

MX	Distant metastases cannot be assessed
M0	No distant metastasis
M1	Distant metastasis

### *Stage groupings*

Stage I	T1	N0	M0
Stage II	T2	N0	M0
Stage III	T1 or T2	N1	M0
	T3	N0 or N1	M0
Stage IV	T4	Any N	M0
	Any T	N2	M0
	Any T	Any N	M1

In patients treated with radical nephrectomy and found to have tumors confined to the kidney (Robson stage I, TNM stage I and II), the 5-year survival is between 66% and 93% compared with 47–77% in patients whose RCC invades perinephric fat (Robson stage II, TNM stage III)<sup>8,58</sup>. Survival for patients with distant metastases (Robson stage IVb, TNM stage IV) is poor with a 10-year survival of between 0% and 5%<sup>59</sup>. More specifically, under the current TNM staging system, the 5-year survival for patients with organ-confined tumors treated with radical nephrectomy for T1aN0M0 tumors ( $\leq 4$  cm) is 97%, whereas that for T1bN0M0 (4–7 cm) falls dramatically to 87%<sup>57</sup>. Larger organ confined tumors classified as T2N0M0 ( $> 7$  cm) reveal a 5-year cancer-specific survival of 71%. For those patients with carcinomas staged as T3aN0M0 (tumor invading into the adrenal gland), T3bN0M0 (tumor invading into the renal vein), and T3cN0M0 (vena caval involvement above diaphragm) the 5-year survival is 53%, 44% and 37%, respectively. Extension beyond Gerota's fascia defined as T4N0M0 shows a 20% 5-year survival. Finally, patients with node-positive disease (N1–3M0) show a 5-year survival between 5% and 30%.

## TUMOR TYPES AND MOLECULAR BIOLOGY

Although pathological staging is the major determinant of prognosis with RCC, histological subtype and nuclear grade, as classified by Fuhrman, can additionally portend tumor behavior<sup>60</sup>. Recent series reveal the 5-year survival decreased from 76% for grade 1 tumors (nuclear size 10 mm, round and uniform, absent or inconspicuous nucleoli) to 35% for those classified Fuhrman grade 4 (nuclear size  $> 20$  mm, bizarre, multilobed nuclei, prominent nucleoli with chromatin clumps)<sup>61</sup>. There are six major histological types of renal cancer classified as conventional, papillary, chromophobic, collecting duct, medullary cell, and the benign oncocytoma<sup>62</sup>. Conventional or clear cell RCC encompasses 75% of tumors and is postulated to arise from the proximal convoluted tubule. Most other histological types arise from the more distal aspects of the nephron<sup>2</sup>. Histological subtypes that herald an ominous prognosis include collecting duct carcinoma, renal medullary carcinoma, and sarcomatoid variants of clear cell RCC.

As outlined previously, the majority of patients with familial or sporadic RCC have an inactivation of the tumor suppressor gene *VHL* on chromosome 3, resulting in dysregulation of the hypoxia inducible transcription factor HIF- $\alpha$ <sup>3</sup>. Accumulation of HIF- $\alpha$  results in expression of transforming growth factors TGF- $\alpha$  and TGF- $\beta$ , vascular endothelial growth factor (VEGF), and platelet derived

growth factor B chain (PDGF-B). These hypoxia inducible proteins promote angiogenesis and tumor cell growth, and have recently proven to be exciting novel therapeutic targets for treatment of systemic renal cell carcinoma.

## NATURAL HISTORY OF SMALL RENAL MASSES

With the dramatic increase in the diagnosis of small ( $< 3$  cm) renal masses with widespread use of abdominal imaging, several recent series have investigated the natural history of these incidentally discovered masses<sup>63–66</sup>. Up to 30% of these incidentally discovered masses may not represent a malignancy, thus alternative strategies to surgical therapy were evaluated. Generally, these small, asymptomatic masses were not managed surgically due to patient preference or poor performance status. The growth rate during surveillance varied dramatically between patients and studies, but by and large a slow growth rate was demonstrated and no patient in these published series developed metastatic disease. These results indicate that for select patients with significant medical co-morbidities expectant management of small renal masses may be the most appropriate therapy.

## SURGERY: RADICAL NEPHRECTOMY

The primary curative intervention for RCC is radical nephrectomy<sup>67</sup>. The indication for radical nephrectomy is a unilateral, localized solid renal mass in a patient with a normal contralateral kidney. As discussed below, patients with solitary kidneys, renal insufficiency and bilateral renal masses should be considered candidates for nephron-sparing surgery (NSS). A thorough preoperative history and physical examination should be performed before the procedure. If significant co-morbidities are suspected, preoperative consultation with the appropriate physician is recommended. In an elective radical nephrectomy, the patient should be expected to physically withstand the operation, have a reasonable overall performance status and a 5-year life expectancy.

Although local extension of primary RCC into the perinephric fat, vena cava, or ipsilateral adrenal gland may portend a worse prognosis, in the absence of metastatic disease these factors alone should not dissuade the surgeon from attempting a radical nephrectomy. Additionally, radical nephrectomy has been successfully performed in the setting of direct extension of the tumor into adjacent organs such as the liver, colon, spleen, pancreas, or psoas muscle. However, surgical removal in this setting is technically difficult, associated with a higher morbidity and a potentially

poor prognosis. Therefore, it should be attempted only after careful preparation and in cooperation with appropriate surgical consultants.

The general principles of classic radical nephrectomy include early ligation of the renal vasculature, removal of the kidney outside of Gerota's fascia including the ipsilateral adrenal gland, and an extensive regional lymphadenectomy. The role of regional lymphadenectomy and ipsilateral adrenalectomy at the time of radical nephrectomy remains controversial, and currently most patients should undergo only a limited lymphadenectomy for the purpose of staging<sup>68,69</sup>.

There are a variety of factors that influence the choice of incision during open radical nephrectomy. These include location of the affected kidney, tumor size and characteristics, body habitus, and physician preference. There are advantages and disadvantages to each incision, and it is important to be familiar with several approaches to the kidney, as no one incision is appropriate in all settings. The most commonly used incisions for open radical nephrectomy are the flank, thoracoabdominal and transabdominal (subcostal or chevron), and have been extensively reviewed elsewhere<sup>70</sup>.

Since laparoscopic radical nephrectomy was first reported by Clayman in 1991, the minimally invasive surgical approach to nephrectomy has emerged as a major treatment modality for localized RCC<sup>71,72</sup>. Several series demonstrate that the laparoscopic approach, whether performed via a transperitoneal, retroperitoneal, or hand-assisted approach, equals open radical nephrectomy in terms of oncological effectiveness for lesions as advanced as T3aN0M0<sup>72-75</sup>. Significant advantages of the laparoscopic approach are measured in terms of reduced pain, shorter hospital stays and convalescence, and improvements in cosmesis<sup>76</sup>.

Although radical nephrectomy remains the standard of care for unilateral renal cell carcinoma, as discussed in following sections, more conservative surgical options are emerging on the forefront of RCC management. The eventual choice of surgical treatment in patients with clinically localized renal masses will ultimately stem from a variety of issues including patient factors and desires, tumor characteristics and surgeon access to and comfort with the variety of techniques. Currently, open radical nephrectomy remains a gold standard in patients with clinically localized and locally advanced renal cell carcinoma and a benchmark against which future alternative surgical strategies will be measured.

Surgical treatment of hypervascular RCC tumors can be challenging due to the potential for significant intraoperative bleeding. Thus, extensive RCCs may be candidates for preoperative renal embolization to reduce blood transfusion requirements and possibly enhance survival<sup>77,78</sup>.

Embolization is commonly performed by interventional radiology on the day prior to nephrectomy. Recent studies have described a combined intraoperative approach with the assistance of vascular surgery that reduces postinfarction syndrome commonly seen following preoperative embolization<sup>79</sup>.

## SURGERY: NEPHRON-SPARING SURGERY

Radical surgery remains the standard therapy for primary RCC, but for an increasing number of patients, nephron-sparing surgery (NSS) is appropriate. Historically, partial nephrectomy was indicated in patients with a solitary kidney, significant renal insufficiency and bilateral disease. Excellent results have been seen in patients treated with NSS, with 10-year cancer-specific survivals of greater than 90% for small (<4 cm), stage I tumors<sup>80</sup>. Although at a higher risk for local recurrence, cancer-specific survival rates for NSS are comparable with those for radical nephrectomy<sup>81-83</sup>.

Elective partial nephrectomy, enucleation and wedge resection may afford potential advantages in terms of preserved renal function and quality of life in properly selected patients. The criteria for NSS have expanded dramatically in recent years to include a cohort of patients in whom it is not essential to spare functioning renal tissue. The cohort of patients is expanding because of the oncological efficiency of NSS combined with increasing awareness of the long-term deleterious effects of nephrectomy on renal function<sup>81,84</sup>.

Since its feasibility was first demonstrated by Winfield in 1992, laparoscopic partial nephrectomy (LPN) has emerged as an additional tool in the urologist's armamentarium for localized RCC<sup>85-87</sup>. This approach has a steep learning curve due to the technically challenging aspects of intracorporeal suturing, often during the time constraint of warm ischemia, although numerous studies report the safety of performing LPN without vascular clamping<sup>88</sup>. Most importantly, early oncological outcomes for LPN are equivalent to those with the open procedure<sup>89,90</sup>.

Despite these competing approaches, open radical nephrectomy will continue to play an important role in the management of RCC and it is essential that any surgeon who employs a minimally invasive technique be well versed in its performance and potential drawbacks.

## ABLATIVE NEPHRON-SPARING THERAPIES

Detection of small renal masses by widespread abdominal imaging has ushered in a new age of minimally invasive techniques for management of these incidental, often

asymptomatic, lesions. Current interest is focused on the promising technologies of cryoablation, radiofrequency ablation and high-intensity focused ultrasound<sup>91,92</sup>. Other modalities such as microwave ablation and interstitial laser coagulation are additionally under development. Encouraging clinical results have been documented in multiple studies for each of these minimally invasive modalities, but long-term outcomes are still unknown.

## BIOLOGICAL THERAPIES

Up to 30% of patients presenting with RCC have metastatic disease at initial diagnosis and approximately 40% of the remaining patients will eventually develop metastasis<sup>8,93</sup>. Unfortunately, no traditional chemotherapeutic agents have shown durable efficacy for treatment of RCC<sup>94</sup>. Likewise, RCC is not a radiation sensitive tumor and radiotherapy is reserved for palliation of metastatic lesions<sup>95,96</sup>. Hormonal manipulation has similarly shown little effect with RCC<sup>4,97</sup>. Thus, for the past decades, systemic therapy has focused on immune modulators and targets of the molecular mechanisms driving development of RCC. High dose interleukin-2 (IL-2), a T-cell growth factor, is the current standard therapy for advanced RCC with a 15% total response rate and a 7% rate of absolute remission<sup>98,99</sup>. Complete responses with IL-2 appear durable, with 80% of patients benefiting from a total response alive at 15 years.

Novel therapies for RCC are emerging at an exciting pace with immunomodulators, vaccines, stem cell transplants, and targeted molecular therapeutics such as antiangiogenic drugs at the forefront<sup>3,4,100–102</sup>. Indeed, the Food and Drug Administration recently approved a tyrosine kinase inhibitor, sorafenib tosylate, as a second-line chemotherapy for advanced RCC<sup>103</sup>. A plethora of other clinical trials for similar targeted agents are also ongoing for application either primarily or in the adjuvant setting<sup>104</sup>.

## ROLE OF SURGERY IN TREATMENT OF METASTATIC DISEASE

A significant paradigm shift has occurred based on two randomized trials that demonstrated radical nephrectomy prior to immunotherapy improved survival from 3 to 10 months among patients with metastatic RCC versus immunotherapy alone<sup>105–108</sup>. Accordingly, radical nephrectomy is being offered to an increasing number of patients with a resectable primary tumor in the setting of metastatic disease. Patient selection for cytoreductive therapy is paramount, as certain series have demonstrated that only 20–62% were subsequently eligible for IL-2 therapy<sup>109,110</sup>.

Radical nephrectomy among patients with a solitary metastatic site has a 5-year survival rate of 30% in selected patients, with best results reported in patients with solitary pulmonary metastases that are resected<sup>111,112</sup>.

The mechanism of cytoreductive nephrectomy is poorly understood but theoretically involves a combination of debulking, removal of metastatic focus, improvement of performance status, and improved immunological function. No clear predictors of success exist in these patients, but good performance status is essential prior to nephrectomy.

## PALLIATIVE INTERVENTIONS

Radical nephrectomy may also be performed for palliation, such as for those patients with intractable pain, life-threatening hemorrhage, or to ameliorate paraneoplastic sequelae that have not responded to medical therapies such as treatment with hydrocortisone or progesterone<sup>113,114</sup>. In this patient population with advanced disease and poor performance status, less invasive approaches such as tumor infarction via renal artery embolization can also be considered for symptom management<sup>115</sup>. Surgery for relief of the complications of metastases, such as spinal cord compression or pathological fractures, is also a mainstay of symptom control for diffusely metastatic disease<sup>112</sup>.

## OUTCOMES: PREDICTION

A variety of prognostic algorithms have been developed to predict the course of RCC<sup>116</sup>. The most prominent predictive factors remain the presence of symptoms at presentation and pathological stage. Recent addition of molecular markers for the disrupted signaling pathways in RCC will provide new forecasting tools that will be incorporated into existing algorithms. An interesting note concerning RCC is the capacity for spontaneous regression in a small (less than 1%) proportion of patients<sup>117</sup>.

## CONCLUSIONS

Despite remarkable advancement in the molecular mechanisms underlying RCC, the mainstay of treatment remains surgical excision of the tumor, either alone or in combination with immunomodulators. An impressive range of surgical options are now available to the urologist, with an increasing number of minimally invasive approaches being developed. Immense anticipation exists for future systemic therapeutics against RCC.

## REFERENCES

- Motzer RJ, Bander NH, Nanus DM. Renal-cell carcinoma. *N Engl J Med* 1996; 335: 865–75.
- Curti BD. Renal cell carcinoma. *JAMA* 2004; 292: 97–100.
- Cohen HT, McGovern FJ. Renal-cell carcinoma. *N Engl J Med* 2005; 353: 2477–90.
- Drucker BJ. Renal cell carcinoma: current status and future prospects. *Cancer Treat Rev* 2005; 31: 536–45.
- Jemal A, Murray T, Ward E et al. Cancer statistics, 2005. *CA Cancer J Clin* 2005; 55: 10–30.
- McLaughlin JK, Lipworth L. Epidemiologic aspects of renal cell cancer. *Semin Oncol* 2000; 27: 115–23.
- Landis SH, Murray T, Bolden S et al. Cancer statistics, 1999. *CA Cancer J Clin* 1999; 49: 8–31.
- Novick AC, Campbell SC. Renal tumors. In: Walsh PC, ed. *Campbell's Urology*, 8th edn. Philadelphia: WB Saunders, 2002: 2672–731.
- Chow WH, Devesa SS, Warren JL et al. Rising incidence of renal cell cancer in the United States. *JAMA* 1999; 281: 1628–31.
- Pantuck AJ, Zisman A, Beldegrun AS. The changing natural history of renal cell carcinoma. *J Urol* 2001; 166: 1611–23.
- Thompson IM, Peek M. Improvement in survival of patients with renal cell carcinoma—the role of the serendipitously detected tumor. *J Urol* 1988; 140: 487–90.
- Gudbjartsson T, Thoroddsen A, Petursdottir V et al. Effect of incidental detection for survival of patients with renal cell carcinoma: results of population-based study of 701 patients. *Urology* 2005; 66: 1186–91.
- Leslie JA, Prihoda T, Thompson IM. Serendipitous renal cell carcinoma in the post-CT era: continued evidence in improved outcomes. *Urol Oncol* 2003; 21: 39–44.
- Hock LM, Lynch J, Balaji KC. Increasing incidence of all stages of kidney cancer in the last 2 decades in the United States: an analysis of surveillance, epidemiology and end results program data. *J Urol* 2002; 167: 57–60.
- Estrada CR, Suthar AM, Eaton SH et al. Renal cell carcinoma: children's Hospital Boston experience. *Urology* 2005; 66: 1296–300.
- Vaishampayan UN, Do H, Hussain M et al. Racial disparity in incidence patterns and outcome of kidney cancer. *Urology* 2003; 62: 1012–7.
- Dhote R, Thiounn N, Debre B et al. Risk factors for adult renal cell carcinoma. *Urol Clin North Am* 2004; 31: 237–47.
- McLaughlin JK, Lindblad P, Møller A et al. International renal-cell cancer study. I. Tobacco use. *Int J Cancer* 1995; 60: 194–8.
- Hunt JD, van der Hel OL, McMillan GP et al. Renal cell carcinoma in relation to cigarette smoking: meta-analysis of 24 studies. *Int J Cancer* 2005; 114: 101–8.
- Goodman MT, Morgenstern H, Wynder EL. A case-control study of factors affecting the development of renal cell cancer. *Am J Epidemiol* 1986; 124: 926–41.
- Amling CL. The association between obesity and the progression of prostate and renal cell carcinoma. *Urol Oncol* 2004; 22: 478–84.
- Chow WH, Gridley G, Fraumeni JF Jr et al. Obesity, hypertension, and the risk of kidney cancer in men. *N Engl J Med* 2000; 343: 1305–11.
- Shapiro JA, Williams MA, Weiss NS et al. Hypertension, anti-hypertensive medication use, and risk of renal cell carcinoma. *Am J Epidemiol* 1999; 149: 521–30.
- Ishikawa I, Saito Y, Onouchi Z et al. Development of acquired cystic disease and adenocarcinoma of the kidney in glomerulonephritic chronic hemodialysis patients. *Clin Nephrol* 1980; 14: 1–6.
- Levine E, Hartman DS, Meilstrup JW et al. Current concepts and controversies in imaging of renal cystic diseases. *Urol Clin North Am* 1997; 24: 523–43.
- Stewart JH, Buccianti G, Agodoa L et al. Cancers of the kidney and urinary tract in patients on dialysis for end-stage renal disease: analysis of data from the United States, Europe, and Australia and New Zealand. *J Am Soc Nephrol* 2003; 14: 197–207.
- Matson MA, Cohen EP. Acquired cystic kidney disease: occurrence, prevalence, and renal cancers. *Medicine (Baltimore)* 1990; 69: 217–26.
- Schmidt L, Duh FM, Chen F et al. Germline and somatic mutations in the tyrosine kinase domain of the met proto-oncogene in papillary renal carcinomas. *Nat Genet* 1997; 16: 68–73.
- Welsch MJ, Kronic A, Medenica MM. Birt-Hogg-Dube syndrome. *Int J Dermatol* 2005; 44: 668–73.
- Lendvay TS, Marshall FF. The tuberous sclerosis complex and its highly variable manifestations. *J Urol* 2003; 169: 1635–42.
- Tello R, Blickman JG, Buonomo C et al. Meta analysis of the relationship between tuberous sclerosis complex and renal cell carcinoma. *Eur J Radiol* 1998; 27: 131–8.
- Friedrich CA. Von Hippel-Lindau syndrome. A pleomorphic condition. *Cancer* 1999; 86: 2478–82.
- Latif F, Tory K, Gnarr J et al. Identification of the von Hippel-Lindau disease tumor suppressor gene. *Science* 1993; 260: 1317–20.
- Iliopoulos O, Kibel A, Gray S et al. Tumour suppression by the human von Hippel-Lindau gene product. *Nat Med* 1995; 1: 822–6.
- Chen F, Kishida T, Duh FM et al. Suppression of growth of renal carcinoma cells by the von Hippel-Lindau tumor suppressor gene. *Cancer Res* 1995; 55: 4804–7.
- Clifford SC, Prowse AH, Affara NA et al. Inactivation of the von Hippel-Lindau (VHL) tumour suppressor gene and allelic losses at chromosome arm 3p in primary renal cell carcinoma: evidence for a VHL-independent pathway in clear cell renal tumorigenesis. *Genes Chromosomes Cancer* 1998; 22: 200–9.
- Kim WY, Kaelin WG. Role of VHL gene mutation in human cancer. *J Clin Oncol* 2004; 22: 4991–5004.
- Brethauer D, Lechevallier E, Eghazarian C et al. Prognostic significance of incidental renal cell carcinoma. *Eur Urol* 1995; 27: 319–23.
- Lee CT, Katz J, Fearn PA et al. Mode of presentation of renal cell carcinoma provides prognostic information. *Urol Oncol* 2002; 7: 135–40.
- Konnak JW, Grossman HB. Renal cell carcinoma as an incidental finding. *J Urol* 1985; 134: 1094–6.
- Jayson M, Sanders H. Increased incidence of serendipitously discovered renal cell carcinoma. *Urology* 1998; 51: 203–5.
- Gold PJ, Fefer A, Thompson JA. Paraneoplastic manifestations of renal cell carcinoma. *Semin Urol Oncol* 1996; 14: 216–22.
- Silver DA, Morash C, Brenner P et al. Pathologic findings at the time of nephrectomy for renal mass. *Ann Surg Oncol* 1997; 4: 570–4.
- Bechtold RE, Zagoria RJ. Imaging approach to staging of renal cell carcinoma. *Urol Clin North Am* 1997; 24: 507–22.



45. Heidenreich A, Ravery V. Preoperative imaging in renal cell cancer. *World J Urol* 2004; 22: 307–15.
46. Bosniak MA. The current radiological approach to renal cysts. *Radiology* 1986; 158: 1–10.
47. Warren KS, McFarlane J. The Bosniak classification of renal cystic masses. *BJU Int* 2005; 95: 939–42.
48. Gattuso P, Ramzy I, Truong LD et al. Utilization of fine-needle aspiration in the diagnosis of metastatic tumors to the kidney. *Diagn Cytopathol* 1999; 21: 35–8.
49. Sanchez-Ortiz RF, Madsen LT, Bermejo CE et al. A renal mass in the setting of a nonrenal malignancy: when is a renal tumor biopsy appropriate? *Cancer* 2004; 101: 2195–201.
50. Herts BR, Baker ME. The current role of percutaneous biopsy in the evaluation of renal masses. *Semin Urol Oncol* 1995; 13: 254–61.
51. Choyke PL. Detection and staging of renal cancer. *Magn Reson Imaging Clin N Am* 1997; 5: 29–47.
52. Robson CJ. Radical nephrectomy for renal cell carcinoma. *J Urol* 1963; 89: 37–42.
53. Guinan P, Sobin LH, Algaba F et al. TNM staging of renal cell carcinoma: workgroup no. 3. Union International Contre le Cancer (UICC) and the American Joint Committee on Cancer (AJCC). *Cancer* 1997; 80: 992–3.
54. Greene FL, Page DL, Fleming ID et al. *AJCC Cancer Staging Manual*, 6th edn. New York: Springer Press, 2002.
55. Guinan P, Saffrin R, Stuhldreher D et al. Renal cell carcinoma: comparison of the TNM and Robson stage groupings. *J Surg Oncol* 1995; 59: 186–9.
56. Gettman MT, Blute ML, Spotts B et al. Pathologic staging of renal cell carcinoma: significance of tumor classification with the 1997 TNM staging system. *Cancer* 2001; 91: 354–61.
57. Frank I, Blute ML, Leibovich BC et al. Independent validation of the 2002 American Joint Committee on Cancer primary tumor classification for renal cell carcinoma using a large, single institution cohort. *J Urol* 2005; 173: 1889–92.
58. Thrasher JB, Paulson DF. Prognostic factors in renal cancer. *Urol Clin North Am* 1993; 20: 247–62.
59. Motzer RJ, Russo P. Systemic therapy for renal cell carcinoma. *J Urol* 2000; 163: 408–17.
60. Fuhrman SA, Lasky LC, Limas C. Prognostic significance of morphologic parameters in renal cell carcinoma. *Am J Surg Pathol* 1982; 6: 655–63.
61. Bretheau D, Lechevallier E, de Fromont M et al. Prognostic value of nuclear grade of renal cell carcinoma. *Cancer* 1995; 76: 2543–9.
62. Storkel S, Eble JN, Adlakha K et al. Classification of renal cell carcinoma: workgroup no. 1. Union Internationale Contre le Cancer (UICC) and the American Joint Committee on Cancer (AJCC). *Cancer* 1997; 80: 987–9.
63. Rathmell WK, Godley PA, Rini BI. Renal cell carcinoma. *Curr Opin Oncol* 2005; 17: 261–7.
64. Volpe A, Panzarella T, Rendon RA et al. The natural history of incidentally detected small renal masses. *Cancer* 2004; 100: 738–45.
65. Kassouf W, Aprikian AG, Laplante M et al. Natural history of renal masses followed expectantly. *J Urol* 2004; 171: 111–3.
66. Kato M, Suzuki T, Suzuki Y et al. Natural history of small renal cell carcinoma: evaluation of growth rate, histological grade, cell proliferation and apoptosis. *J Urol* 2004; 172: 863–6.
67. Robson CJ, Churchill BM, Anderson W. The results of radical nephrectomy for renal cell carcinoma. *J Urol* 1969; 101: 297–301.
68. Blom JH, van Poppel H, Marechal JM et al. Radical nephrectomy with and without lymph node dissection: preliminary results of the EORTC randomized phase III protocol 30881. EORTC genitourinary group. *Eur Urol* 1999; 36: 570–5.
69. Dave DS, Lam JS, Leppert JT et al. Open surgical management of renal cell carcinoma in the era of minimally invasive kidney surgery. *BJU Int* 2005; 96: 1268–74.
70. Cookson MS, Chang SS. Radical nephrectomy. In: Graham SD, Keane TE, Glenn JF, eds. *Glenn's Urologic Surgery*, 6th edn. Philadelphia: Lippincott Williams & Wilkins, 2004: 39–50.
71. Clayman RV, Kavoussi LR, Soper NJ et al. Laparoscopic nephrectomy: initial case report. *J Urol* 1991; 146: 278–82.
72. Permpongsosol S, Chan DY, Link RE et al. Laparoscopic radical nephrectomy: long-term outcomes. *J Endourol* 2005; 19: 628–33.
73. Ono Y, Kinukawa T, Hattori R et al. Laparoscopic radical nephrectomy for renal cell carcinoma: a five-year experience. *Urology* 1999; 53: 280–6.
74. Chan DY, Cadeddu JA, Jarrett TW et al. Laparoscopic radical nephrectomy: cancer control for renal cell carcinoma. *J Urol* 2001; 166: 2095–9.
75. Novick AC. Laparoscopic and partial nephrectomy. *Clin Cancer Res* 2004; 10: 6322S–7S.
76. Allan JD, Tolley DA, Kaouk JH et al. Laparoscopic radical nephrectomy. *Eur Urol* 2001; 40: 17–23.
77. Bakal CW, Cynamon J, Lakritz PS et al. Value of preoperative renal artery embolization in reducing blood transfusion requirements during nephrectomy for renal cell carcinoma. *J Vasc Interv Radiol* 1993; 4: 727–31.
78. Zielinski H, Szmigielski S, Petrovich Z. Comparison of preoperative embolization followed by radical nephrectomy with radical nephrectomy alone for renal cell carcinoma. *Am J Clin Oncol* 2000; 23: 6–12.
79. Lin PH, Terramani TT, Bush RL et al. Concomitant intraoperative renal artery embolization and resection of complex renal carcinoma. *J Vasc Surg* 2003; 38: 446–50.
80. Uzzo RG, Novick AC. Nephron sparing surgery for renal tumors: indications, techniques and outcomes. *J Urol* 2001; 166: 6–18.
81. Lau WK, Blute ML, Weaver AL et al. Matched comparison of radical nephrectomy vs nephron-sparing surgery in patients with unilateral renal cell carcinoma and a normal contralateral kidney. *Mayo Clin Proc* 2000; 75: 1236–42.
82. Lerner SE, Hawkins CA, Blute ML et al. Disease outcome in patients with low stage renal cell carcinoma treated with nephron sparing or radical surgery. *J Urol* 1996; 155: 1868–73.
83. Dunn MD, Portis AJ, Shalhav AL et al. Laparoscopic versus open radical nephrectomy: a 9-year experience. *J Urol* 2000; 164: 1153–9.
84. McKiernan J, Simmons R, Katz J et al. Natural history of chronic renal insufficiency after partial and radical nephrectomy. *Urology* 2002; 59: 816–20.
85. Winfield HN, Donovan JF, Godet AS et al. Laparoscopic partial nephrectomy: initial case report for benign disease. *J Endourol* 1993; 7: 521–6.
86. McDougall EM, Clayman RV, Anderson K. Laparoscopic wedge resection of a renal tumor: initial experience. *J Laparoendosc Surg* 1993; 3: 577–81.
87. Weise ES, Winfield HN. Laparoscopic partial nephrectomy. *J Endourol* 2005; 19: 634–42.
88. Albqami N, Janetschek G. Laparoscopic partial nephrectomy. *Curr Opin Urol* 2005; 15: 306–11.
89. Gill IS, Matin SF, Desai MM et al. Comparative analysis of laparoscopic versus open partial nephrectomy for renal tumors in 200 patients. *J Urol* 2003; 170: 64–8.

90. Allaf ME, Bhayani SB, Rogers C et al. Laparoscopic partial nephrectomy: evaluation of long-term oncological outcome. *J Urol* 2004; 172: 871–3.
91. Weld KJ, Landman J. Comparison of cryoablation, radiofrequency ablation and high-intensity focused ultrasound for treating small renal tumours. *BJU Int* 2005; 96: 1224–9.
92. Marberger M, Mauermann J. Energy ablation nephron-sparing treatment of renal tumors AUA Update Series 2004; 23; Lesson 23.
93. Maldazys JD, deKernion JB. Prognostic factors in metastatic renal carcinoma. *J Urol* 1986; 136: 376–9.
94. Amato RJ. Chemotherapy for renal cell carcinoma. *Semin Oncol* 2000; 27: 177–86.
95. Halperin EC, Harisiadis L. The role of radiation therapy in the management of metastatic renal cell carcinoma. *Cancer* 1983; 51: 614–7.
96. Cutuli BF, Methlin A, Teissier E et al. Radiation therapy in the treatment of metastatic renal-cell carcinoma. *Prog Clin Biol Res* 1990; 348: 179–86.
97. Harris DT. Hormonal therapy and chemotherapy of renal-cell carcinoma. *Semin Oncol* 1983; 10: 422–30.
98. Fisher RI, Rosenberg SA, Sznol M et al. High-dose aldesleukin in renal cell carcinoma: long-term survival update. *Cancer J Sci Am* 1997; 3 (Suppl 1): S70–2.
99. Fisher RI, Rosenberg SA, Fyfe G. Long-term survival update for high-dose recombinant interleukin-2 in patients with renal cell carcinoma. *Cancer J Sci Am* 2000; 6: S55–7.
100. Van Spronsen DJ, Mulders PF, De Mulder PH. Novel treatments for metastatic renal cell carcinoma. *Crit Rev Oncol Hematol* 2005; 55: 177–91.
101. Sokoloff MH, Daneshmand S, Ryan CW. Current clinical trials in renal cell carcinoma. *Urol Oncol* 2005; 23: 289–92.
102. Mancuso A, Sternberg CN. What's new in the treatment of metastatic kidney cancer? *BJU Int* 2005; 95: 1171–80.
103. Schoffski P, Dumez H, Clement P et al. Emerging role of tyrosine kinase inhibitors in the treatment of advanced renal cell cancer: a review. *Ann Oncol* 2006; 17: 1185–96.
104. Bellmunt J. Current treatment in advanced renal cell carcinoma (RCC): impact of targeted therapies in the management of RCC. *Eur Urol* 2007; (Suppl 6): 484–91.
105. Flanigan RC, Salmon SE, Blumenstein BA et al. Nephrectomy followed by interferon alfa-2b compared with interferon alfa-2b alone for metastatic renal-cell cancer. *N Engl J Med* 2001; 345: 1655–9.
106. Mickisch GH, Garin A, van Poppel H et al. Radical nephrectomy plus interferon-alfa-based immunotherapy compared with interferon alfa alone in metastatic renal-cell carcinoma: a randomised trial. *Lancet* 2001; 358: 966–70.
107. Flanigan RC, Mickisch G, Sylvester R et al. Cytoreductive nephrectomy in patients with metastatic renal cancer: a combined analysis. *J Urol* 2004; 171: 1071–6.
108. Hafez KS, Montie JE. Indications and limitations of cytoreductive nephrectomy for metastatic renal cell carcinoma AUA Update Series 2004; 23; Lesson 31.
109. Bromwich E, Hendry D, Aitchison M. Cytoreductive nephrectomy: is it a realistic option in patients with renal cancer? *BJU Int* 2002; 89: 523–5.
110. Walther MM, Yang JC, Pass HI et al. Cytoreductive surgery before high dose interleukin-2 based therapy in patients with metastatic renal cell carcinoma. *J Urol* 1997; 158: 1675–8.
111. Kuczyk MA, Anastasiadis AG, Zimmermann R et al. Current aspects of the surgical management of organ-confined, metastatic, and recurrent renal cell cancer. *BJU Int* 2005; 96: 721–7.
112. Sengupta S, Leibovich BC, Blute ML et al. Surgery for metastatic renal cell cancer. *World J Urol* 2005; 23: 155–60.
113. Wood CG. The role of cytoreductive nephrectomy in the management of metastatic renal cell carcinoma. *Urol Clin North Am* 2003; 30: 581–8.
114. Ok JH, Meyers FJ, Evans CP. Medical and surgical palliative care of patients with urological malignancies. *J Urol* 2005; 174: 1177–82.
115. Munro NP, Woodhams S, Nawrocki JD et al. The role of transarterial embolization in the treatment of renal cell carcinoma. *BJU Int* 2003; 92: 240–4.
116. Lane BR, Kattan MW. Predicting outcomes in renal cell carcinoma. *Curr Opin Urol* 2005; 15: 289–97.
117. Lokich J. Spontaneous regression of metastatic renal cancer. Case report and literature review. *Am J Clin Oncol* 1997; 20: 416–8.

## RELEVANT WEBSITES

Kidney Cancer Association: [www.kidneycancer.org](http://www.kidneycancer.org)  
 National Cancer Institute: [www.cancer.gov/cancertopics/types/kidney](http://www.cancer.gov/cancertopics/types/kidney)  
 American Cancer Society: [www.cancer.org](http://www.cancer.org)



# Urothelial carcinoma of the bladder and upper tracts

22

William T Lowrance, Sam S Chang and Michael S Cookson

---

## INTRODUCTION

Urothelial carcinoma (UC), known also as transitional cell carcinoma (TCC), can affect any portion of the urothelium, which includes the renal pelvis, the ureter, the bladder, and the prostatic and penile urethra. The normal uroepithelium is composed of several different cell subtypes and is usually three to seven layers thick. Basal cells attach to the lamina propria basement membrane; a few intermediate cell layers separate the basal cells from apical cells known as umbrella cells. Umbrella cells project into the lumen of the urinary tract and serve a key role in providing a barrier against solutes and waste products in the urine.

The exact etiology of urothelial carcinoma is unknown, but clearly it is multifactorial. Certain genetic predispositions and exposure of urothelium to chemical carcinogens and/or other irritating stimuli (infection, inflammation, radiation) probably lead to alterations in DNA which cause the normal cell cycle to go awry, promoting the development of a malignancy. Not surprisingly, UC is often a field change disease with the entire urothelium susceptible to malignancy.

Classically, urothelial carcinoma is divided into carcinoma arising within the bladder and that developing in the upper tracts (kidney and ureter). Bladder cancer is far more common than upper tract malignancies. Although the most common, urothelial carcinoma is not the only primary malignancy affecting the urinary tract. Pure squamous cell carcinoma accounts for around 3–5% of all bladder tumors in western countries<sup>1</sup>. Primary adenocarcinoma is the third most common epithelial tumor of the bladder; it represents 1–2% of all bladder tumors. Other rare primary bladder tumors include sarcomas, carcinosarcomas, small cell carcinomas, pheochromocytomas, lymphomas, and melanomas. Similarly, squamous cell carcinomas, adenocarcinoma, sarcomas, and small cell carcinomas can involve the upper urinary tract. Of upper tract tumors 1–7% are squamous cell carcinomas<sup>1</sup>. The focus of this chapter is on urothelial carcinomas, and distinctions are made between those tumors arising primarily within the bladder and those of the upper tracts.

## INCIDENCE AND PREVALENCE

Bladder cancer is the fourth most common incident cancer among men after prostate, lung and colorectal cancers, and the ninth most common in women. However, it is the second most prevalent cancer among American men<sup>2</sup>. The high prevalence rate for bladder cancer reflects the fact that many patients are diagnosed with low grade, low stage disease and are at significant risk for multiple recurrences. Over 61 000 new cases of bladder cancer (44 690 in men and 16 730 in women) were projected to be diagnosed in the US in 2006, with over 13 000 deaths attributable to the disease<sup>2</sup>. Bladder cancer accounts for approximately 6% of all new cancer diagnoses in men and approximately 3% of all cancer deaths in men<sup>2</sup>. The highest incidence of bladder cancer is found in industrialized countries such as the US, UK, France, Canada, Italy, Spain, and Denmark. The incidence of bladder cancer increases significantly with age, and in all countries its incidence is two to three times higher in men than women<sup>2</sup>. Urothelial cancers comprise nearly 90% of all primary bladder tumors.

Upper tract UC, although much less common than bladder cancer, does make up approximately 5% of all urothelial neoplasms. The majority of these arise in the kidney/renal pelvis, while only about 1% are ureteral in origin. Of all primary renal tumors, UC of the renal pelvis accounts for about 10%<sup>1</sup>. Upper tract UC occurs in 2–4% of patients with a history of bladder cancer, but this number is higher in contemporary series and may be as high as 25% for those with associated carcinoma *in situ* treated with Bacillus Calmette-Guerin (BCG)<sup>3</sup>. Anywhere from 15 to 50% of all cases of upper tract UC occur in patients with a history of bladder cancer. UC of the ureter occurs more commonly in the distal ureter (75%) than in the middle (20%) or proximal ureter (5%)<sup>3</sup>.

## PREDISPOSING/RISK FACTORS

Risk factors for UC of the upper and lower urinary tract are similar, and both are more common with increasing age.

Cigarette smoking causes a three- to four-fold increase in the incidence of UC, and approximately 50% of urothelial cancers in men and 30% in women are attributed to smoking<sup>4</sup>. Interestingly, other forms of tobacco only slightly increase an individual's risk of UC. The exact mechanism of how smoking leads to UC is not known, but it most certainly involves a chemical carcinogen excreted in the urine that initiates tumorigenesis. With smoking cessation, patients' risk for developing UC begins to decline after 2–4 years but can take up to 20 years to reach baseline<sup>3,5</sup>.

Historically, occupational exposures may have accounted for up to a quarter of all urothelial cancers. Exposure to industrial chemicals known as arylamines is primarily responsible for this risk, and these carcinogens are commonly found in the dye, leather, rubber, aluminum, and petroleum industries<sup>3</sup>. Because of their strong association with UC, many arylamines have been eliminated from the work environment. Cyclophosphamide and other closely related chemotherapy agents can greatly increase the risk of developing UC. Acrolein, a metabolite of cyclophosphamide, is excreted in the urine and is thought to be responsible for inducing UC.

Chronic irritation of the bladder caused by stones, foreign bodies, or infections can increase the risk of UC. Schistosomiasis, long-term foley catheters, and calculus disease more frequently are associated with squamous cell carcinoma of the urinary tract, but they also increase the risk of UC. Not surprisingly, radiation therapy for other malignancies can increase the risk of UC. Chinese herb nephropathy and Blackfoot disease have also been linked to UC. Chinese herbs with *Aristolochia fangchi* form aristolochic acid, which is thought to be the causative agent<sup>3</sup>. The increased incidence of UC with Blackfoot disease seen in Taiwan is related to arsenic exposure in well water. Analgesic abuse and Balkan nephropathy both impart a significant risk for upper tract urothelial tumors but are not associated with bladder tumors<sup>3</sup>. Although experimental studies have suggested artificial sweeteners may also contribute to the development of UC, clinical evidence for this has thus far been lacking.

## PRESENTATION

Approximately 80% of patients with UC initially present with either gross or microscopic hematuria<sup>3</sup>. Some patients with bladder cancer may first experience irritative voiding symptoms. Hematuria and irritative voiding symptoms must be aggressively evaluated and not just assumed to be secondary to urinary tract infections. In addition to hematuria, patients with upper tract tumors may experience flank pain, have hydronephrosis, and possibly have a palpable flank mass. The hydronephrosis and/or flank

pain can result from ureteral obstruction caused by blood clots or the tumor itself. Although uncommon, constitutional symptoms such as weight loss, fatigue, or bone pain may be a sign of advanced disease.

The mean age at presentation of upper tract urothelial cancers is 65 years and is slightly older than for bladder tumors<sup>3</sup>. On initial presentation, approximately 70–80% of patients with bladder cancer have disease that does not invade the muscle, which has historically been referred to as superficial bladder cancer. Among these patients, approximately 20–40% may progress to muscle invasion, underscoring the need for effective treatment of the initial and recurrent disease. The remaining 20–30% will present with *de novo* muscle invasive bladder cancer, and if left untreated, only about 15% will survive 2 years<sup>6,7</sup>. Thus, 80% of patients with muscle invasive disease harbor this potentially lethal tumor at the time of initial diagnosis. Unlike bladder tumors, 50–60% of urothelial tumors of the renal pelvis are invasive at presentation<sup>3</sup>.

## SCREENING

The goal of cancer screening is to detect asymptomatic malignancies at an early stage and to allow for effective treatment that will decrease disease-specific mortality. Most patients who present with or eventually develop distant metastases have organ-confined muscle invasive disease. Since these tumors can progress to invasive and often metastatic lesions, early detection is paramount in successfully treating epithelial malignancies such as UC<sup>8</sup>. In order for a screening test to be useful, it must be highly sensitive, specific, safe, and cost effective. Since hematuria is the most common presenting sign of UC, it would make sense that hematuria testing and urine cytology are the most widely used screening studies for urothelial cancers. Depending on age, sex and risk level, the rates of asymptomatic hematuria in the general population can range from 0.2 to 16%<sup>9</sup>. Two prospective studies have both shown that using home dipstick hematuria testing in a generalized population of older males may detect high grade urothelial tumors at an earlier stage and therefore reduce mortality rates<sup>8,10</sup>. Unfortunately, there have been no prospective, randomized, controlled screening trials for urothelial cancers. Therefore, it remains controversial as to whether screening low risk populations is indeed efficacious and cost effective.

Urine cytology, flow cytometry and various other UC marker tests have lacked sensitivity and specificity therefore limiting their use as screening tools for the general public. Urine cytology, which is often used for evaluating patients with hematuria or following those with a history of bladder cancer may be falsely negative over 20% of

the time. As a screening tool, urine cytology is really only useful in high-risk patient populations. Many different biological markers for UC and combinations of these markers have been tested, but most lack sensitivity and/or specificity. The search is being undertaken to find the ideal screening marker for UC and then to demonstrate its utility in a randomized, controlled trial.

## DIAGNOSTIC STRATEGIES

As defined by the American Urological Association's clinical guidelines, a complete hematuria evaluation includes a thorough history and physical examination, laboratory analysis (urinalysis, urine culture and urine cytology), upper urinary tract imaging, and cystoscopy of the bladder<sup>11</sup>. Urothelial tract tumors are generally discovered as part of a hematuria evaluation or are incidentally noted on radiographic studies. Bladder tumors are typically found during cystoscopy and many escape radiographic detection. Nevertheless, they may be discovered on ultrasound, computed tomography (CT) scans, magnetic resonance imaging (MRI), or as filling defects within the bladder on intravenous pyelography (IVP). Cystoscopy is considered the gold standard for diagnosing tumors within the urinary bladder. Once a bladder lesion is visualized, the best way to evaluate it further is to perform a transurethral resection; this helps determine the grade of the tumor and its depth of invasion. A bimanual examination also adds important diagnostic information about the tumor's depth of invasion and ultimate resectability.

Upper urinary tract tumors are commonly discovered as filling defects or areas of obstruction on retrograde pyelography, CT scans, or IVP studies. Selected ureteral cytological washings can also be diagnostically helpful. As with bladder tumors, the accepted standard for diagnosing upper tract lesions is direct visualization with biopsy. This is accomplished with either a flexible or semirigid ureteroscopy. It has been shown that the addition of ureteropyeloscopy with tissue sampling significantly improved diagnostic accuracy.

## GRADING AND STAGING

The degree of cytological atypia helps determine the grade of urothelial lesions. Traditionally urothelial tumors were graded 1 through 3, with grade 3 lesions being the most poorly differentiated and having the most nuclear pleomorphism. In 1998 the World Health Organization and the International Society of Urologic Pathologists (WHO/ISUP) published a new consensus classification system for urothelial neoplasms of the bladder<sup>12</sup>. New terminology

was included in this classification system, and papillary lesions were no longer considered grade 1 through 3. Instead, they were labeled as either papillary urothelial neoplasms of low malignant potential or as low- or high-grade urothelial carcinomas (Table 22.1).

Several different staging systems exist for both upper and lower tract urothelial neoplasms, but the most widely accepted one is the tumor, node, metastasis (TNM) staging system (Tables 22.2 and 22.3) by the American Joint Committee on Cancer (AJCC)<sup>13</sup>. Multiple studies have shown that there is close correlation between tumor grade, stage and disease-specific survival for bladder and upper tract tumors. When considering all variables, tumor (T) stage is the most accurate predictor of patient outcome. The T stage of a urothelial neoplasm is based on its depth of invasion. Ta and Tis (carcinoma *in situ*) lesions are confined to the mucosa, and T1 tumors invade the lamina propria but do not involve the true detrusor muscle. In clinical practice, Ta, Tis and T1 are all grouped as 'non-muscle invasive' tumors. However, this terminology has been criticized due to the very heterogeneous nature of these tumors. T2–T4 lesions are all muscle-invasive tumors with increasing depth of penetration. The differentiation of non-muscle invasive disease from muscle-invasive disease is an important point since it will help guide treatment decisions.

The clinical T stage is determined by a biopsy or transurethral resection (TUR) of the urothelial lesion. For neoplasms of the bladder, it is important that muscularis propria be present in the TUR specimen so that the depth of tumor invasion can be accurately assessed and clinical understaging can be minimized. Between 30 and 60% of non-muscle invasive tumors that invade the lamina propria (stage T1) are understaged after a single TUR<sup>14,15</sup>. The presence of muscularis propria and a repeat TUR 4–6 weeks after the original resection significantly improve clinical staging accuracy as well as ensure complete tumor resection. In a patient series from Memorial Sloan-Kettering Cancer Center, 96 patients with superficial bladder cancer underwent repeat TUR, and 29% were upstaged, thus affecting treatment decisions<sup>16</sup>. In addition, findings at the time of a re-staging TUR among patients with non-muscle invasive tumors may predict outcomes and should be strongly considered, particularly among those with high-grade and lamina propria invasive disease<sup>17</sup>.

**Table 22.1** WHO grading system

Urothelial papilloma
Papillary urothelial neoplasm of low malignant potential (PUNLMP)
Low-grade papillary urothelial carcinoma
High-grade papillary urothelial carcinoma

**Table 22.2** Urothelial carcinoma of the bladder staging

<i>Primary tumor (T)</i>			
TX	Primary tumor cannot be assessed		
T0	No evidence of primary tumor		
Ta	Non-invasive papillary carcinoma		
Tis	Carcinoma <i>in situ</i> : ‘flat tumor’		
T1	Tumor invades subepithelial connective tissue		
T2	Tumor invades muscle		
T2a	Tumor invades superficial muscle (inner half)		
T2b	Tumor invades deep muscle (outer half)		
T3	Tumor invades perivesical tissue		
T3a	Microscopically		
T3b	Macroscopically (extravesical mass)		
T4	Tumor invades any of the following: prostate, uterus, vagina, pelvic wall, abdominal wall		
T4a	Tumor invades prostate, uterus, vagina		
T4b	Tumor invades pelvic wall, abdominal wall		
<i>Regional lymph nodes (N)</i>			
NX	Regional lymph nodes cannot be assessed		
N0	No regional lymph node metastasis		
N1	Metastasis in a single lymph node, $\geq 2$ cm in greatest dimension		
N2	Metastasis in a single lymph node, $>2$ cm but $\leq 5$ cm in greatest dimension; or multiple lymph nodes, none $>5$ cm in greatest dimension		
N3	Metastasis in a lymph node, $>5$ cm in greatest dimension		
<i>Distant metastasis (M)</i>			
MX	Distant metastasis cannot be assessed		
M0	No distant metastasis		
M1	Distant metastasis		
<i>Stage groupings</i>			
Stage 0a	Ta	N0	M0
Stage 0is	Tis	N0	M0
Stage I	T1	N0	N0
Stage II	T2a	N0	M0
	T2b	N0	M0
Stage III	T3a	N0	M0
	T3b	N0	M0
	T4a	N0	M0
Stage IV	T4b	N0	M0
	Any T	N1	M0
	Any T	N2	M0
	Any T	N3	M0
	Any T	Any N	M1

**Table 22.3** Urothelial carcinoma of renal pelvis and ureter staging

<i>Primary tumor (T)</i>			
TX	Primary tumor cannot be assessed		
T0	No evidence of primary tumor		
Ta	Papillary non-invasive carcinoma		
Tis	Carcinoma <i>in situ</i>		
T1	Tumor invades subepithelial connective tissue		
T2	Tumor invades the muscularis		
T3	(For renal pelvis only) Tumor invades beyond muscularis into peripelvic fat or the renal parenchyma		
T3	(For ureter only) Tumor invades beyond muscularis into periureteric fat		
T4	Tumor invades adjacent organs, or through the kidney into the perinephric fat		
<i>Regional lymph nodes (N)</i>			
NX	Regional lymph nodes cannot be assessed		
N0	No regional lymph node metastasis		
N1	Metastasis in a single lymph node, ≤2 cm in greatest dimension		
N2	Metastasis in a single lymph node, >2 cm but ≤5 cm in greatest dimension; or multiple lymph nodes, none >5 cm in greatest dimension		
N3	Metastasis in a lymph node, >5 cm in greatest dimension		
 *Note: Laterality does not affect the N classification			
<i>Distant metastasis (M)</i>			
MX	Distant metastasis cannot be assessed		
M0	No distant metastasis		
M1	Distant metastasis		
 <i>Stage groupings</i>			
Stage 0a	Ta	N0	M0
Stage 0is	Tis	N0	M0
Stage I	T1	N0	M0
Stage II	T2	N0	M0
Stage III	T3	N0	M0
Stage IV	T4	N0	M0
	Any T	N1	M0
	Any T	N2	M0
	Any T	N3	M0
	Any T	Any N	M1

For patients with non-muscle invasive UC, assessment of the upper tracts is performed to exclude a synchronous tumor which can be present in approximately 3% of patients. Once an invasive urothelial tumor has been identified, a complete staging evaluation must be undertaken. For most invasive urothelial cancers this includes a complete history and physical examination, a complete metabolic panel, chest X-ray, and CT scan or MRI of the abdomen and pelvis. For patients suspected of having advanced disease, a bone scan or CT of the head may be indicated. Once the clinical disease stage is ascertained, the physician and patient together can formulate a treatment plan.

## SURGERY FOR CURE

Non-muscle invasive bladder tumors (Ta, Tis and T1) are typically treated endoscopically with complete TUR. As mentioned, these 'non-invasive' bladder tumors are a heterogeneous group with a wide variation in tumor biology and differing rates of recurrence and progression. Ta tumors rarely progress to muscle invasive disease, yet over 50% of patients will experience recurrence if treated only with TUR. However, patients with high-grade T1 disease or Tis are at a significant risk for stage progression and/or recurrence. Risk factors for recurrence and/or progression include presence of carcinoma *in situ*, multifocality, high grade or stage of tumor, prior episode of recurrence, and initial large size of tumor.

The addition of adjuvant intravesical immunotherapy or chemotherapy is indicated for certain high-risk superficial lesions and can significantly reduce the UC recurrence and progression rates. First popularized in Europe, it is increasingly common to incorporate a single dose of perioperative intravesical chemotherapy to reduce bladder cancer recurrence. Currently, the most commonly used perioperative chemotherapeutic agent is mitomycin C, and it can generally be instilled immediately following the TUR and left indwelling for 1 hour<sup>18</sup>. In addition to mitomycin C, thiotepa, epirubicin and adriamycin are all options for intravesical chemotherapy and may be administered as a single instillation within 24 hours of complete TUR<sup>18</sup>. BCG is the most commonly used intravesical immunotherapy and is typically given approximately 2–4 weeks after complete TUR of high grade T1 tumors or carcinoma *in situ*. Unlike intravesical chemotherapy, BCG is never administered in the immediate postoperative period. The Southwest Oncology Group (SWOG) recommends a 6-week induction course, followed by a 3-week maintenance dose at months 3, 6, 12, 18, 24, 30, and 36<sup>19</sup>. Effectiveness of the treatment is closely monitored with surveillance cystoscopy every 3 months. Although most non-muscle invasive bladder tumors can be treated without removing the bladder, radical cystectomy remains

an important treatment option for patients with high-risk or recurrent non-muscle invasive UC who have failed intravesical therapy or other conservative measures<sup>20</sup>.

Open radical cystectomy with en bloc pelvic lymph node dissection and urinary diversion is considered the gold standard of treatment for patients with muscle-invasive bladder cancer<sup>7</sup>. Although there are various surgical approaches (open, laparoscopic, or robotic), most radical cystectomies have three major portions: extirpation of the bladder, pelvic lymphadenectomy, and urinary diversion. Each of these parts will be discussed separately.

Obtaining negative surgical margins in cystectomy specimens is of paramount importance for achieving local cancer control and improving survival<sup>21</sup>. In men, the prostate is traditionally removed with the cystectomy specimen, as it can be involved with the urothelial tumor or harbor a secondary malignancy. The incidence of prostatic involvement varies with individual tumor characteristics as well as the technique used to assess the prostate specimen. In a study by Revelo *et al.*, UC or dysplasia was found within the prostate in up to 50% of specimens when analyzed using whole mount step sections<sup>22</sup>. Also in that study, incidental adenocarcinoma of the prostate was detected in about half of the specimens as well. However, select patients can be considered for sparing of the prostate, and in properly selected patients the oncological safety and functional outcomes have been demonstrated<sup>23</sup>. In addition, nerve sparing techniques similar to those described by Walsh *et al.* for radical prostatectomy can be applied to radical cystectomy with improvements in functional outcome<sup>24</sup>. If the urethra is involved with UC, urethrectomy is generally performed at the time of cystectomy or as a separate procedure.

Classically the standard of treatment for invasive bladder UC in women was an anterior exenteration, which included removal of the bladder, urethra, uterus, ovaries, fallopian tubes, and a portion of the anterior vaginal wall. With the refinement of surgical techniques and careful patient selection, certain gynecological organs, urethra, and/or the anterior vaginal wall can be spared<sup>25</sup>. In fact, there is a low incidence of secondary gynecological malignancies incidentally found at cystectomy, and direct extension of urothelial tumors into adjacent organs, if present, is usually suspected preoperatively or determined intraoperatively<sup>25,26</sup>.

The importance of a complete pelvic lymphadenectomy at the time of cystectomy cannot be overstated. Nearly one-quarter of patients undergoing radical cystectomy will pathologically have lymph node metastases<sup>7,27</sup>. In treating invasive bladder cancer, the lymphadenectomy is certainly diagnostic and may be therapeutic. Among patients with positive nodes treated with radical cystectomy and lymphadenectomy, approximately 20–30% will be rendered disease-free at follow-up beyond 5 years<sup>7</sup>.



In addition, survival improves with the completeness of the lymphadenectomy, even among node-negative patients, further underscoring the importance of a thorough dissection<sup>28</sup>.

A standard pelvic lymphadenectomy generally extends distally from the node of Cloquet to the bifurcation of the common iliac vessels cephalad; it extends from the genitofemoral nerve anterolaterally to the internal iliac vessels posteriorly, including the obturator nodes. Through lymph node mapping of cystectomy patients, Smith and Whitmore demonstrated that 19% of patients had metastases to their common iliac nodes, and were among the first to suggest the importance of an extended pelvic lymph node dissection<sup>29</sup>. Several series have shown that extending the lymph node dissection proximally to the aortic bifurcation and including the presacral nodes will increase the total number of nodes removed and likely improve patient survival<sup>30,31</sup>. In addition, radical cystectomy positive surgical margin rates may be decreased with extended lymph node dissections<sup>32</sup>.

A major portion of any cystectomy procedure is the lower urinary tract reconstruction. The ureters are typically connected to a segment of bowel which functions as a reservoir, and then allows urine to empty out of an ostomy or through the native urethra. The three most common types of lower urinary tract diversion are the ileal or colon conduit, orthotopic urinary diversion ('neobladder'), and continent cutaneous reservoir. Overall ileal conduits are the most commonly performed urinary diversions, owing to their relative ease of construction and lower complication rates, but orthotopic neobladders have become a popular alternative for properly selected patients over the past decade. At some institutions over 50% of patients receive an orthotopic neobladder, as many different series have shown they can be performed with minimal morbidity and often improve patient self image and quality of life. Neobladder construction involves detubularizing a segment (approximately 55 cm) of ileum and fashioning it into either a U-shaped (Studer) or a W-shaped (Hautman) reservoir<sup>33,34</sup>. This reservoir is then sutured to the patient's native urethra, thus obviating the need for an ostomy. Not all patients are candidates or desire a neobladder, and therefore their urinary system is reconstructed with an ileal conduit or continent cutaneous reservoir. Absolute contraindications to an orthotopic neobladder include failure to achieve a negative tumor margin in the proximal urethra, significant renal or hepatic impairment, inability to perform self-catheterization, and poor patient motivation/compliance.

An ileal conduit consists of a length of distal ileum (approximately 15 cm) that has the ureters anastomosed to its proximal end and then the distal portion of the tube is brought through the skin as an ostomy. An ileal conduit

is an incontinent diversion, and therefore an ostomy appliance bag must be worn at all times. In patients in whom the ileum is not suitable, a sigmoid colon conduit may be performed. Additionally, in patients with a prior history of pelvic radiation, a transverse colon conduit may be desirable to allow for selection of a suitable portion of non-irradiated bowel.

A continent cutaneous diversion allows the patient to pass a catheter through an abdominal stoma and drain urine from an internal reservoir formed from a segment of bowel, usually the right colon. While there are various types of continent cutaneous diversions, one of the most popular is the Indiana pouch in which the right colon is used as the reservoir and the ileocecal valve functions to maintain continence through a catheterizable stoma of terminal ileum<sup>35</sup>.

The gold standard of treatment for patients with upper tract transitional cell carcinoma is complete nephroureterectomy, assuming the patient has a normal contralateral renal unit. In special circumstances, such as in patients with bilateral upper tract tumors, renal insufficiency, or a solitary kidney, renal sparing surgery may be considered including endoscopic or segmental resections although recurrence rates are high and vigilant surveillance of the upper tract is necessary to evaluate for recurrent tumors.

Classically, open nephroureterectomies are performed through two incisions, but some surgeons prefer a single midline incision. The two incision approach usually involves a flank incision for the nephrectomy and upper ureterectomy, and then a lower midline or Gibson incision for the distal ureterectomy and excision of bladder cuff. Complete excision of the distal ureter and bladder cuff is important, since recurrence rates in the ureteral stump can range from 30 to 75%<sup>3</sup>. With the popularity and proven efficacy of many minimally invasive surgical techniques, pure laparoscopic and hand-assisted nephroureterectomies have become commonplace over the past decade. The first laparoscopic nephroureterectomy was performed about 15 years ago, and since then many institutions have adopted this technique<sup>36</sup>. With laparoscopic nephroureterectomy, there is considerable debate about how to best manage the distal ureter and bladder cuff. Methods ranging from open excision to complete transurethral resection of the ipsilateral ureteral orifice and surrounding bladder mucosa exist as options. Currently, at many high volume centers laparoscopic nephroureterectomy has replaced open surgical approaches with reduced morbidity, faster recovery and equivalent oncological efficacy<sup>37</sup>. Still, the use of open nephroureterectomy should remain a viable option for patients with locally advanced tumors or those patients who are not candidates for minimally invasive surgery.

## PALLIATIVE SURGERY

Ideally radical cystectomies and nephroureterectomies are performed with curative intent. Patients with locally advanced or metastatic UC are clearly not candidates for curative surgery. Chemotherapy is a much better option for these patients, but occasionally local symptoms dictate that palliative surgery must be considered. Advanced UC can cause intractable hematuria necessitating surgical intervention and may sometimes require palliative cystectomy or nephroureterectomy. Likewise, invasive UC can cause ureteral obstruction requiring urinary diversion; placement of a percutaneous nephrostomy tube or an ileal conduit diversion may be needed. As with any type of palliative procedure, patient symptoms must be weighed against the risk of morbidity and/or mortality induced by the procedure.

## ADJUVANT AND NEOADJUVANT CHEMOTHERAPY

Tumor (T) and node (N) stage are key prognostic indicators for bladder and upper tract urothelial carcinoma. Five-year survival rates for patients with node negative pT3b and T4 bladder cancer are 62% and 50%, respectively; for patients with positive lymph nodes, 5-year survival drops to 35%<sup>7</sup>. Historically radical cystectomy or nephroureterectomy has been the mainstay of treatment for organ-confined UC, and chemotherapy was generally reserved for the treatment of metastatic or locally recurrent disease. The vast majority of data on the use of perioperative chemotherapy for urothelial neoplasms involve bladder tumors, and there are few studies concerning upper tract disease.

Urothelial cancers are sensitive to chemotherapy with greater than 50% showing response to combination therapies containing cisplatin<sup>38</sup>. Although the response rate is impressive, the overall cure rate for metastatic UC is quite disappointing, and at best is 15%<sup>38</sup>. Since the development of the methotrexate, vinblastine, doxorubicin, and cisplatin (MVAC) regimen, chemotherapy has come to play a major role in the neoadjuvant and adjuvant treatment of locally advanced bladder cancer while remaining the mainstay of treatment for metastatic UC. MVAC is not a benign regimen, as it can cause significant myelosuppression and mucositis, and it is not an option for patients with renal insufficiency. Newer agents, such as gemcitabine, in combination with cisplatin may be just as effective as MVAC but have less toxicity and can be used carefully in patients with renal insufficiency.

The debate continues as to whether chemotherapy for advanced disease should be given in the adjuvant or

neoadjuvant setting. Several randomized trials and subsequent meta-analyses have demonstrated a modest improvement in survival with perioperative chemotherapy and possibly a slight survival advantage (around 5%) for those patients receiving neoadjuvant MVAC as compared with adjuvant therapy<sup>39,40</sup>. Proponents of neoadjuvant chemotherapy argue that in appropriately selected patients it can help 'downstage' the disease, therefore aiding complete surgical excision. Rarely are the neoadjuvant toxicities such that they preclude patients from moving on to cystectomy, if needed, but postoperative morbidity can delay or prevent adjuvant therapy. Administering chemotherapy initially also gives an *in vivo* assessment as to whether the tumor is responsive to these cytotoxic drugs. However, overstaging may occur in 20–30% of patients, and in the event that the chemotherapy is ineffective it may inadvertently delay treatment.

Those who favor adjuvant chemotherapy argue that there is a delay in definitive treatment via radical cystectomy if neoadjuvant therapy is given. Numerous studies have shown delaying radical cystectomy by more than 3 months can lead to a worse outcome, both in terms of worse pathological stage and more importantly survival<sup>41,42</sup>. When chemotherapy is given postoperatively, it can be based on accurate pathological staging and patients can be appropriately counseled as to their risk of recurrence. Thus the over-treatment of certain patients based on clinical staging alone can be avoided. Although most experts believe there is a slight survival advantage obtained by administering neoadjuvant therapy in patients with locally advanced disease as shown by several randomized trials, only a small percentage of patients currently receive neoadjuvant therapy<sup>43</sup>. In clinical practice, the majority of patients receiving perioperative chemotherapy are receiving treatment in the adjuvant setting. Perhaps most importantly, clinical trials are ongoing to identify more efficacious chemotherapy for patients with locally advanced and metastatic UC which can then be incorporated into the perioperative management of patients at high risk for recurrence.

## COMBINATION CHEMOTHERAPY AND RADIATION THERAPY

Currently adjuvant radiation therapy is not typically used for upper or lower tract urothelial tumors. Several small, non-randomized studies found that adjuvant radiation therapy to locally advanced upper tract UCs did not improve survival above surgery alone<sup>44</sup>. Radiation therapy does have a role in bladder-sparing protocols for the treatment of muscle-invasive bladder cancer. In an effort to enhance patient quality of life, eliminate the morbidity associated with cystectomy, and provide early treatment

for micrometastatic disease some carefully selected patients may opt for a bladder-sparing treatment approach. Bladder preservation using multimodality treatment involving complete transurethral resection, systemic chemotherapy, and radiotherapy has been reported<sup>45</sup>. Almost all of the patients included in these trials are selected based on the caveat that the tumor is completely resected, and the patients undergo close surveillance to exclude recurrence indicative of need for radical cystectomy. Various series have shown overall survival rates around 50% at 5 years of follow-up, similar to many radical cystectomy series<sup>45,46</sup>. Of note, one-third or more of patients undergoing bladder-conserving treatment eventually require cystectomy for disease recurrence or an incomplete initial tumor response<sup>46</sup>. Although not the gold standard, bladder-preserving protocols do have a role in the treatment of muscle-invasive UC in certain patients. In summary, this strategy is best suited for small, muscle-invasive bladder cancers amenable to complete resection followed by combined chemoradiation therapy. These patients require vigilant surveillance, and if the bladder cancer recurs they should be strongly considered for exenterative surgery. In the best of situations, only about one-third of selected patients will remain disease-free with an intact bladder at 5 years.

## PALLIATIVE CARE

Invasive UC is a formidable disease, and unfortunately a significant number of patients recur and die from the disease each year. In one series, over 1000 patients underwent radical cystectomy at the University of Southern California and had a disease-free survival rate of 68% at 5 years<sup>7</sup>. In another series involving upper tract tumors, patients with T3 lesions of the renal pelvis had a 5-year survival of 54%, while those with T3 lesions of the ureter had a 24% survival rate at 5 years<sup>47</sup>. At some point attention must be

directed toward palliative care in patients who have exhausted surgical and chemotherapeutic options in an attempt at curative treatment. Pain control and other comfort measures take precedence.

Urothelial tumors can commonly metastasize to regional lymph nodes, lungs, liver, and bones. The presence or absence of pain should always be ascertained during patient encounters. Aggressive pain management utilizing non-steroidal anti-inflammatory drugs and various narcotic preparations is often necessary. Doses should be escalated as needed to achieve adequate pain control. Painful metastatic bone lesions can be treated with focal radiation therapy with excellent palliative results. Bowel or urinary obstruction secondary to recurrent or progressive UC may necessitate surgical diversion. Effective palliative care typically results when a multidisciplinary team consisting of the urologist, medical and radiation oncologist, pain management specialist, nurses, and hospice personnel are involved.

## OUTCOMES

The long-term efficacy of multimodality treatment of both upper and lower urinary tract UC has been shown in terms of local control and disease-free survival. Multiple series have shown excellent 5- and 10-year survival rates for patients with muscle-invasive bladder UC treated with radical cystectomy<sup>7,24,48,49</sup>. Disease-free survival is closely correlated with the grade and stage of the urothelial tumor. Overall TMN stage (I–IV) (Table 22.2) is one of the best prognostic indicators for survival. The National Cancer Data Base has 5-year survival data reported from over 1200 US hospitals showing a wide survival range depending on disease stage (Figure 22.1 and Table 22.4). Patients with organ-confined disease have better long-term survival than those with advanced local disease or lymph

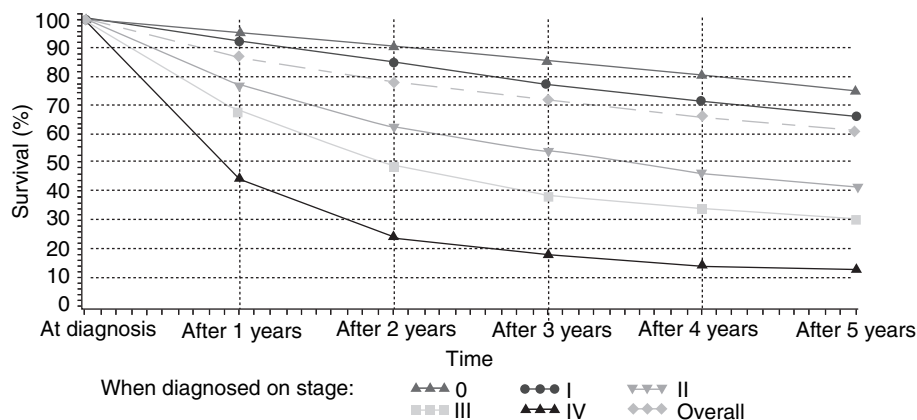
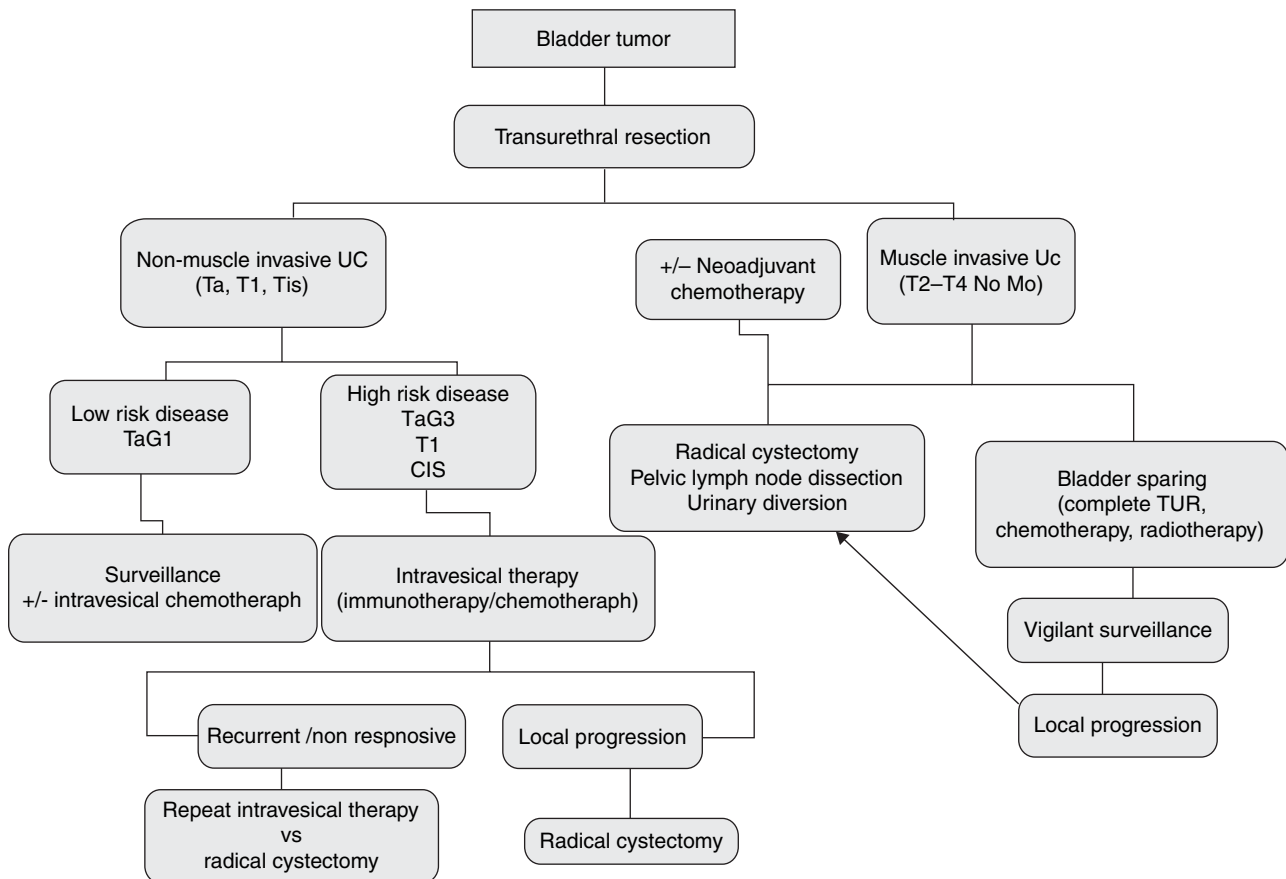


Figure 22.1 Five-year survival rates for bladder cancer cases diagnosed in 1998 reported from 1278 US hospitals. From reference 50.

**Table 22.4** Five-year survival for bladder cancer cases diagnosed in 1998 from 1278 US hospitals. From reference 50

Stage	Cases	At diagnosis	Survival					95% Confidence interval
			1 year	2 year	3 year	4 year	5 year	
0	13080	100	95.61	90.71	86.09	80.90	75.12	74.30–75.94
I	7278	100	92.50	84.73	77.12	71.46	65.63	64.43–66.83
II	3543	100	76.42	61.21	53.28	45.99	41.10	39.34–42.86
III	1854	100	67.50	48.42	38.11	33.74	29.64	27.40–31.88
IV	1935	100	44.29	24.11	17.60	14.27	12.65	11.03–14.27
Overall	27690	100	86.82	77.80	71.46	66.06	60.78	60.16–61.40

**Figure 22.2**

node involvement, and neoadjuvant or adjuvant chemotherapy can improve survival in patients with advanced disease.

Investigators at the University of Southern California have reported their extensive experience with radical

cystectomy in the literature; it involves over 1000 patients with a median follow-up of over 10 years<sup>7</sup>. In their series, the overall disease-free survival at 5 years was 68% and at 10 years was 66%. Patients without lymph node involvement who had pT2a and pT3a had 5- and 10-year

disease-free survivals of 89% and 87%, and 78% and 76%, respectively. Approximately 24% of patients in their series had lymph node involvement, and regardless of T stage, the 5- and 10-year recurrence-free survival was 35% and 34%, respectively. Patients with no lymph node involvement and pT3b disease had a 5- and 10-year disease-free recurrence rate of 62% and 61%; those with pT4 disease had recurrence-free survival rates of 50% and 45% at 5 and 10 years. Bladder cancer recurred in about 30% of their patients within 1 year, and most of those recurrences were distant metastases. Similar studies have shown good long-term results for patients with upper tract UC. In one large series,

5-year disease-free survival in patients undergoing complete nephroureterectomy with excision of bladder cuff was 45%<sup>51</sup>.

UC is a heterogeneous disease, behaving differently depending on tumor location, grade and stage. Therefore the treatment of upper and lower tract UC must be individually tailored for patients, and often requires a multidisciplinary approach (see Figure 22.2 for generalized algorithm of treating bladder UC). Clearly long-term survival with good functional outcomes can be achieved with aggressive surgical management and appropriate neoadjuvant or adjuvant therapy.

## REFERENCES

- Bostwick DG, Eble JN. *Urologic Surgical Pathology*. St. Louis: Mosby-Year Book, 1997.
- Jemal A, Siegel R, Ward E et al. Cancer statistics, 2006. *CA Cancer J Clin* 2006; 56: 106–30.
- Campbell MF, Walsh PC, Retik AB. *Campbell's Urology*, 8th edn. Philadelphia, PA: Saunders, 2002; 2732–84.
- Burch JD, Rohan TE, Howe GR et al. Risk of bladder cancer by source and type of tobacco exposure: a case-control study. *Int J Cancer* 1989; 44: 622–8.
- Fleshner N, Garland J, Moadel A et al. Influence of smoking status on the disease-related outcomes of patients with tobacco-associated superficial transitional cell carcinoma of the bladder. *Cancer* 1999; 86: 2337–45.
- Prout GR, Marshall VF. The prognosis with untreated bladder tumors. *Cancer* 1956; 9: 551–8.
- Stein JP, Lieskovsky G, Cote R et al. Radical cystectomy in the treatment of invasive bladder cancer: long-term results in 1,054 patients. *J Clin Oncol* 2001; 19: 666–75.
- Messing EM, Young TB, Hunt VB et al. Comparison of bladder cancer outcome in men undergoing hematuria home screening versus those with standard clinical presentations. *Urology* 1995; 45: 387–96.
- Woolhandler S, Pels RJ, Bor DH et al. Dipstick urinalysis screening of asymptomatic adults for urinary tract disorders. I. Hematuria and proteinuria. *JAMA* 1989; 262: 1214–9.
- Messing EM, Young TB, Hunt VB et al. Hematuria home screening: repeat testing results. *J Urol* 1995; 154: 57–61.
- Grossfeld GD, Litwin MS, Wolf JS Jr et al. Evaluation of asymptomatic microscopic hematuria in adults: the American Urological Association best practice policy—part II: patient evaluation, cytology, voided markers, imaging, cystoscopy, nephrology evaluation, and follow-up. *Urology* 2001; 57: 604–10.
- Epstein JI, Amin MB, Reuter VR et al. The World Health Organization/International Society of Urological Pathology consensus classification of urothelial (transitional cell) neoplasms of the urinary bladder. Bladder Consensus Conference Committee. *Am J Surg Pathol* 1998; 22: 1435–48.
- Sobin LH, Fleming ID. *TNM Classification of Malignant Tumors*, fifth edition (1997). Union Internationale Contre le Cancer and the American Joint Committee on Cancer. *Cancer* 1997; 80: 1803–4.
- Dutta SC, Smith JA Jr, Shappell SB et al. Clinical under staging of high risk nonmuscle invasive urothelial carcinoma treated with radical cystectomy. *J Urol* 2001; 166: 490–3.
- Stein JP. Indications for early cystectomy. *Semin Urol Oncol* 2000; 18: 289–95.
- Herr HW. The value of a second transurethral resection in evaluating patients with bladder tumors. *J Urol* 1999; 162: 74–6.
- Herr HW, Donat SM. A re-staging transurethral resection predicts early progression of superficial bladder cancer. *BJU Int* 2006; 97: 1194–8.
- van der Meijden AP, Sylvester R, Oosterlinck W et al. EAU guidelines on the diagnosis and treatment of urothelial carcinoma in situ. *Eur Urol* 2005; 48: 363–71.
- Lamm DL, Blumenstein BA, Crissman JD et al. Maintenance bacillus Calmette-Guerin immunotherapy for recurrent TA, T1 and carcinoma in situ transitional cell carcinoma of the bladder: a randomized Southwest Oncology Group Study. *J Urol* 2000; 163: 1124–9.
- Smith JA Jr, Labasky RF, Cockett AT et al. Bladder cancer clinical guidelines panel summary report on the management of non-muscle invasive bladder cancer (stages Ta, T1 and TIS). The American Urological Association. *J Urol* 1999; 162: 1697–701.
- Herr HW. Extent of surgery and pathology evaluation has an impact on bladder cancer outcomes after radical cystectomy. *Urology* 2003; 61: 105–8.
- Revelo MP, Cookson MS, Chang SS et al. Incidence and location of prostate and urothelial carcinoma in prostates from cystoprostatectomies: implications for possible apical sparing surgery. *J Urol* 2004; 171: 646–51.
- Nieuwenhuijzen JA, Meinhardt W, Horenblas S. Clinical outcomes after sexuality preserving cystectomy and neobladder (prostate sparing cystectomy) in 44 patients. *J Urol* 2005; 173: 1314–7.
- Schoenberg MP, Walsh PC, Breazeale DR et al. Local recurrence and survival following nerve sparing radical cystoprostatectomy for bladder cancer: 10-year followup. *J Urol* 1996; 155: 490–4.
- Ali-el-Dein B, Abdel-Latif M, Ashamallah A et al. Local urethral recurrence after radical cystectomy and orthotopic bladder substitution in women: a prospective study. *J Urol* 2004; 171: 275–8.

26. Chang SS, Cole E, Smith JA Jr et al. Pathological findings of gynecologic organs obtained at female radical cystectomy. *J Urol* 2002; 168: 147–9.
27. Leissner J, Ghoneim MA, Abol-Enein H et al. Extended radical lymphadenectomy in patients with urothelial bladder cancer: results of a prospective multicenter study. *J Urol* 2004; 171: 139–44.
28. Konety BR, Joslyn SA, O'Donnell MA. Extent of pelvic lymphadenectomy and its impact on outcome in patients diagnosed with bladder cancer: analysis of data from the Surveillance, Epidemiology and End Results Program data base. *J Urol* 2003; 169: 946–50.
29. Smith JA Jr, Whitmore WF Jr. Regional lymph node metastasis from bladder cancer. *J Urol* 1981; 126: 591–3.
30. Herr HW, Bochner BH, Dalbagni G et al. Impact of the number of lymph nodes retrieved on outcome in patients with muscle invasive bladder cancer. *J Urol* 2002; 167: 1295–8.
31. Leissner J, Hohenfellner R, Thuroff JW et al. Lymphadenectomy in patients with transitional cell carcinoma of the urinary bladder: significance for staging and prognosis. *BJU Int* 2000; 85: 817–23.
32. Herr H, Lee C, Chang S et al. Standardization of radical cystectomy and pelvic lymph node dissection for bladder cancer: a collaborative group report. *J Urol* 2004; 171: 1823–8.
33. Hautmann RE. 15 years experience with the ileal neobladder. What have we learned? *Urologe A* 2001; 40: 360–7. [in German]
34. Studer UE, Zingg EJ. Ileal orthotopic bladder substitutes. What we have learned from 12 years' experience with 200 patients. *Urol Clin North Am* 1997; 24: 781–93.
35. Rowland RG. Continent cutaneous urinary diversion. *Semin Urol Oncol* 1997; 15: 179–83.
36. Clayman RV, Kavoussi LR, Figenschau RS et al. Laparoscopic nephroureterectomy: initial clinical case report. *J Laparoendosc Surg* 1991; 1: 343–9.
37. Gill IS, Sung GT, Hobart MG et al. Laparoscopic radical nephroureterectomy for upper tract transitional cell carcinoma: the Cleveland Clinic experience. *J Urol* 2000; 164: 1513–22.
38. Aparicio AM, Elkhouchy AB, Quinn DI. The current and future application of adjuvant systemic chemotherapy in patients with bladder cancer following cystectomy. *Urol Clin North Am* 2005; 32: 217–30, vii.
39. Grossman HB, Natale RB, Tangen CM et al. Neoadjuvant chemotherapy plus cystectomy compared with cystectomy alone for locally advanced bladder cancer. *N Engl J Med* 2003; 349: 859–66.
40. Winquist E, Kirchner TS, Segal R et al. Neoadjuvant chemotherapy for transitional cell carcinoma of the bladder: a systematic review and meta-analysis. *J Urol* 2004; 171: 561–9.
41. Chang SS, Hassan JM, Cookson MS et al. Delaying radical cystectomy for muscle invasive bladder cancer results in worse pathological stage. *J Urol* 2003; 170: 1085–7.
42. Herr HW, Sogani PC. Does early cystectomy improve the survival of patients with high risk superficial bladder tumors? *J Urol* 2001; 166: 1296–9.
43. Millikan R, Dinney C, Swanson D et al. Integrated therapy for locally advanced bladder cancer: final report of a randomized trial of cystectomy plus adjuvant M-VAC versus cystectomy with both preoperative and postoperative M-VAC. *J Clin Oncol* 2001; 19: 4005–13.
44. Maulard-Durdux C, Dufour B, Hennequin C et al. Postoperative radiation therapy in 26 patients with invasive transitional cell carcinoma of the upper urinary tract: no impact on survival? *J Urol* 1996; 155: 115–7.
45. Shipley WU, Kaufman DS, Zehr E et al. Selective bladder preservation by combined modality protocol treatment: long-term outcomes of 190 patients with invasive bladder cancer. *Urology* 2002; 60: 62–7.
46. Zietman AL, Grocela J, Zehr E et al. Selective bladder conservation using transurethral resection, chemotherapy, and radiation: management and consequences of Ta, T1, and Tis recurrence within the retained bladder. *Urology* 2001; 58: 380–5.
47. Guinan P, Vogelzang NJ, Randazzo R et al. Renal pelvic cancer: a review of 611 patients treated in Illinois 1975–1985. Cancer Incidence and End Results Committee. *Urology* 1992; 40: 393–9.
48. Dalbagni G, Genega E, Hashibe M et al. Cystectomy for bladder cancer: a contemporary series. *J Urol* 2001; 165: 1111–6.
49. Gschwend JE, Dahm P, Fair WR. Disease specific survival as endpoint of outcome for bladder cancer patients following radical cystectomy. *Eur Urol* 2002; 41: 440–8.
50. National Cancer Data Base, Commission on Cancer, Survival Reports 2006.
51. Hall MC, Womack S, Sagalowsky AI et al. Prognostic factors, recurrence, and survival in transitional cell carcinoma of the upper urinary tract: a 30-year experience in 252 patients. *Urology* 1998; 52: 594–601.

## RELEVANT WEBSITES

<http://www.auanet.org/guidelines/>  
[http://www.nccn.org/patients/patient\\_gls.asp](http://www.nccn.org/patients/patient_gls.asp)  
[http://www.uroweb.org/index.php?structure\\_id=140](http://www.uroweb.org/index.php?structure_id=140)  
<http://www.cancer.org/docroot/home/index.asp>  
[http://seer.cancer.gov/statfacts/html/urinb.html?statfacts\\_page=urinb.html;#x00026;x=13;#x00026;y=13](http://seer.cancer.gov/statfacts/html/urinb.html?statfacts_page=urinb.html;#x00026;x=13;#x00026;y=13)  
<http://web.facs.org/ncdabbmr/>



Philip A Cornford and Daniel M Burke

---

## INTRODUCTION

In the UK in 2002 there were nearly 32 000 new cases of prostate cancer recorded, accounting for 12% of all cancers diagnosed, resulting in the condition being the most commonly diagnosed male malignancy<sup>1</sup>. Across the Western world the incidence has increased dramatically over the past 50 years, initially as a consequence of an increase in the number of men under going transurethral resection of the prostate (TURP) for lower urinary tract symptoms and since 1989 following the introduction of prostate specific antigen (PSA) screening programs. However, prostate cancer represents a unique problem amongst the solid tumors as it essentially exists in two forms: a histological or latent form which can be identified in autopsy specimens in approximately 30% of men over the age of 50 years and 70% of men over the age of 80<sup>2</sup>, and the clinically evident form which affects approximately one in six men in their lifetimes<sup>3</sup>. Indeed the risk of dying of prostate cancer is small with it only accounting for approximately 5% of all male cancer deaths<sup>4</sup>. Separating those who need treatment from those whose disease will remain indolent and then initiating appropriate intervention is the conundrum that most vexes urology today.

## DEFINITIVE RISK FACTORS

### Age

Both the incidence and mortality increase with age and after the age of 50 years at a near exponential rate<sup>5</sup>.

### Race

The age-adjusted incidence and death rates from prostate cancer vary dramatically from country to country as well as between racial-ethnic groups (Figure 23.1)<sup>6</sup>. The incidence rates are highest in American blacks (149/100 000 person-years), intermediate in UK (107/100 000 person-years),

and lowest in Chinese men (28/100 000 person-years)<sup>6</sup>. Interestingly the frequency of autopsy-detected cancers is roughly the same in different parts of the world<sup>7</sup>. This is in sharp contrast with the incidence of clinical prostate cancer, which differs widely between different geographical areas, being high in the USA and Northern Europe and low in South-East Asia<sup>8,9</sup>. However, if Japanese men move from Japan to Hawaii their risk of clinical prostate cancer increases and if they move further on to California their risk approaches that of American men<sup>10</sup>.

### Family history

Several studies have shown that the incidence of prostate cancer is higher in male relatives of prostate cancer patients<sup>11–16</sup>. These studies have revealed that the risk of a man's developing prostate cancer is associated with the number of affected relatives (Table 23.1), the closeness of their genetic relationship (Table 23.2), and the age at diagnosis (Table 23.3). Studies looking at the frequency of prostate cancer in twin brothers have also suggested a strong genetic influence<sup>17</sup>. The genetic make up of prostate cancer is complex and multifactorial; research has, however, pointed to important genetic changes on chromosome 1 and chromosome X<sup>18</sup>.

## PROBABLE RISK FACTORS

### Dietary fat

A number of studies have shown that the level of dietary fat is an important risk factor for prostate cancer<sup>19–21</sup>. Furthermore, in international comparisons, a strong correlation has been shown between dietary fat intake and prostate cancer mortality<sup>22</sup>. Body mass index has also been related to prostate cancer risk (relative risk 1.4)<sup>23</sup>, but at present there is insufficient evidence to conclude that specific fatty acids are associated with prostate cancer development.



**Table 23.1** Age-adjusted relative risk estimates for prostate cancer by number of additional affected family members

<i>Affected relatives (beside proband)</i>	<i>Odds ratio (95% CI)</i>
1	2.2 (1.4–3.5)
2	4.9 (2.0–12.3)
3	10.9 (2.7–43.1)

From Steinberg *et al.*<sup>14</sup>

**Table 23.2** Relative risk for prostate carcinoma in relatives of prostate carcinoma cases by degree of relationship

<i>Affected relatives</i>	<i>Relative risk (95% CI)</i>
First-degree	2.0 (1.2–3.3)
Second-degree	1.7 (1.0–2.9)
Both first- and second-degree	8.8 (2.8–28.1)

From Steinberg *et al.*<sup>14</sup>

**Table 23.3** Relative odds for prostate cancer in brothers of prostate carcinoma cases by age

<i>Age of affected case (years)</i>	<i>Age of brother (years)</i>		
	<65	65–79	80+
<65	5.97	2.77	2.29
65–79	2.77	2.04	2.52
80+	2.29	2.52	1.14

From Cannon *et al.*<sup>12</sup>

## Hormone levels

Testosterone is necessary for normal prostate epithelium development and early prostate cancer has been shown to be endocrine dependent. It has been suggested that altered hormone metabolism may play a role in the progression of prostate cancer from histological to clinically significant<sup>24</sup>. Indeed Zumoff *et al.*<sup>25</sup> and Drafta *et al.*<sup>26</sup> showed testosterone levels to be higher in patients with prostate cancer than in controls, although, other studies have been unable to confirm this<sup>27,28</sup>. It is clear, however, that young black men have serum testosterone levels that are approximately 15% higher than their white counterparts, and this difference may be enough to explain the increased risk of

prostate cancer in black men<sup>29</sup>. It has also been shown that testosterone metabolism is different in American/European men when compared with Japanese men<sup>30</sup>. Japanese men have a lower 5 $\alpha$ -reductase activity, which may help explain their lower incidence of clinical prostate cancer.

## POTENTIAL RISK FACTORS

### Occupation and chemical exposure

Men involved in welding and electroplating are exposed to high levels of cadmium. Several studies have shown a weak association between cadmium exposure and prostate cancer risk<sup>31–33</sup>. The exact mechanism is unclear but it may be interfering with zinc, which acts as a cofactor in multiple metabolic pathways.

Farmers have an increased incidence of prostate cancer despite prostate cancer being generally rarer in the rural population<sup>34</sup>. In a study on 20 025 farmers Wiklund *et al.*<sup>35</sup> showed it was mainly those employed as pesticide users that are at risk (relative risk 2.03). Interestingly cadmium is a common if minor ingredient in fertilizers.

### Ultraviolet radiation

Data from Schwartz *et al.*<sup>36,37</sup> have shown a close inverse relationship between the geographical variation of ultraviolet (UV) radiation and the incidence of prostate cancer. Even within the USA prostate cancer mortality rates are inversely proportional to UV exposure<sup>6</sup>. It is argued that this is related to increased vitamin D production in the skin. M'Buyamba-Kabangu *et al.*<sup>38</sup> showed that vitamin D levels fell in Africans moving to Europe and 1,25-dihydroxyvitamin D is known to inhibit cell growth both *in vitro* and *in vivo*<sup>39,40</sup>. Vitamin D and its analogs have also been shown to be capable of inducing differentiation as well as to slow the growth of prostate cancer cells<sup>41</sup>, and in other systems to inhibit expression of the oncogene *c-myc*<sup>42</sup>. It has been proposed that differences in vitamin D levels might explain the low incidence of prostate cancer in men in central Africa (4–10 per 100 000 men)<sup>43</sup>. Traditionally this group have done very little to protect themselves from the sun unlike their genetic counterparts in North America, who have a much higher incidence of prostate cancer.

### Vitamin A

Vitamin A or retinol is a fat-soluble vitamin that is essential for normal differentiation of epithelial cells, physiological growth, visual function, and reproduction. Deficiency of this vitamin has been associated with prostate cancer

(relative risk 1.94)<sup>44</sup>. However, confusingly, men with a high intake of vitamin A are also at increased risk<sup>45</sup>, perhaps as a result of associated high dietary fat intake.

## Selenium and vitamin E

Following two trials which, although they were not set to look at prostate cancer as a primary endpoint, suggested the possible benefit of the trace metal selenium<sup>46</sup> and vitamin E<sup>47</sup> in decreasing the incidence of prostate cancer, a large multicenter study has been commenced (the SELECT study) to look specifically at the relationship of these dietary factors and prostate cancer.

## RISK FACTOR SUMMARY

After the age of 50, both the incidence and the mortality rates from prostate cancer rise almost exponentially causing significant curtailment of life expectancy<sup>48</sup>. Prostate cancer develops as a result of interplay between genetic and environmental factors. Understanding how these factors interact will allow the investigation of prevention strategies as well as defining those patients who will benefit from treatment.

## PRESENTING SYMPTOMS

Advanced prostate cancer may present with bone pain from metastases, anemia and renal failure, due to obstructive changes or rarely spinal cord compression. Early prostate cancer, however, is mainly asymptomatic with its detection often being the result of an elevated PSA test. PSA was first described in 1979<sup>49</sup> and later proposed as a marker for prostate cancer<sup>50</sup>. It is a kallikrein-like serine protease and is produced almost exclusively by the epithelial cells of the prostate<sup>51</sup>. It is organ specific but not disease specific being raised secondary to any condition causing leakage of cell contents across the basement membrane into the circulation, i.e. prostate cancer, benign prostatic hyperplasia, prostatitis, and prostatic manipulation. The half-life of PSA is between 2.2 and 3.2 days<sup>50,52</sup> and therefore the clinician must take into account any condition or investigation that might result in a transient rise in the PSA. It is advisable to leave between 4 and 6 weeks after a TURP or prostate biopsy before repeating a PSA<sup>53</sup>. Minimal PSA rises are seen following both rigid and flexible cystoscopy<sup>53</sup>; however, there is good evidence that a digital rectal examination (DRE) results in no clinically significant rise in PSA<sup>54</sup>. Although men are often told to present to their general practitioner if they have bladder outflow symptoms; i.e. hesitancy, poor flow, terminal dribbling,

nocturia, etc. there is no increase in the incidence of prostate cancer in this group of men compared with that seen in the asymptomatic population<sup>55</sup>. Because of its relatively low positive predictability, alternative derived values have been proposed, these include evaluating rate of PSA change (PSA velocity (PSAV) and PSA doubling time), correcting for prostate gland size (PSA density (PSAD) and age-related PSA) (Table 23.4), and calculating the free to total PSA ratio in the serum<sup>56–60</sup>.

## CLASSIFICATION

### Grading

Grading follows the Gleason system established in 1974<sup>61</sup>. The Gleason grade is achieved by looking at the histological architecture of the prostate (Table 23.5). The two most commonly seen patterns are added together to give the patient a final Gleason score. A final score will therefore be between 2 and 10 with 2 being the least and 10 the most aggressive type of cancer. For a pathologist to be able to give a diagnosis of prostate cancer the abnormal tissue must occupy at least 5% of the biopsy specimen. Histological material is obtained either by a prostate biopsy or from prostate chippings from a patient undergoing a TURP.

Gleason grade has been shown to correlate with the risk of tumor progression and ultimately death from prostate cancer<sup>62</sup> (Table 23.6).

### Staging

Staging of prostate cancer is important when determining not only the prognosis of the condition but also the most suitable treatment. Controversy still remains as to the most appropriate way to stage a patient from the investigations available to the clinician. These are discussed below. The most commonly used staging system is the International Union Against Cancer (UICC) 2002 Tumor node metastasis (TNM) classification (Table 23.7).

Table 23.4

Age (years)	Normal PSA Range (ng/ml)
40–49	0.0–2.5
50–59	0.0–3.5
60–65	0.0–4.5
70–79	0.0–6.5

Adapted from reference 58.

Table 23.5

Pattern	Tumor border	Stromal invasion	Gland			
			Appearance	Size	Architecture	Cytoplasm
1	Circumscribed pushing	Minimal	Round, monotonous replicated	Medium regular	Closely packed rounded masses	Similar to benign epithelium
2	Early infiltration	Mild with definite separation of glands by stroma	Round, with some variation	Medium less regular	Loosely packed, rounded masses	Similar to benign epithelium
3	Infiltration	Marked	Angular with variation	Irregular	Variably packed, irregular masses	More basophilic than patterns 1 and 2
4	Ragged infiltration	Marked	Microacinar, papillary and cribriform	Irregular	Fused with chains and cords	Dark
5	Ragged infiltration	Marked	Difficult to identify lumina	Sheets of glands	Fused sheets and masses	Variable

**Table 23.6** The 15-year risk of dying from cancer of the prostate in relation to Gleason score at diagnosis in patients with localized disease aged 55–74 years

Gleason score	Risk of cancer death (%)	Cancer specific mortality (%)
2–4	4–7	8
5	6–11	14
6	18–30	44
7	42–70	76
8–10	60–87	93

### Rectal examination

It is well established that rectal examination is a subjective investigation and even in experienced hands there is variability in its findings<sup>63</sup>. The sensitivity and specificity of determining organ-confined disease, however, is limited with values of 52% and 81%, respectively<sup>64</sup>. However, when used in combination with other parameters it is more effective in predicting the final pathological stage. The presence of an abnormality on DRE signifies cancer in 15–40% of cases, and for any given PSA value approximately doubles the risk that cancer is present. The most common position to perform a rectal examination is in the left lateral position, although a number of centers advocate the knee elbow position.

### Transrectal ultrasound scan

This is principally used as a mapping device in order to obtain systematic biopsies and is insensitive at detecting capsular extension or organ-confined disease. The standard approach to prostatic biopsy is to biopsy each sextant of the prostate and in addition to sampling the peripheral zone at apex laterally and the base<sup>65</sup>. Biopsy cores obtained in this way include the peripheral zone which is the most common location for early prostate cancer. If the first set of biopsies are negative, repeated biopsies can be recommended. A detection rate of about 20% has been reported in cases with 'persistent indication' and a negative first set of biopsies<sup>66,67</sup>. Detection rate is even higher (50–100%) if atypical small acinar proliferation or prostatic intraepithelial neoplasia is present<sup>68,69</sup>. Transrectal ultrasound scanning has a similar sensitivity to rectal examination when predicting stage of disease<sup>70,71</sup>. It can, however, add information as to the size of the prostate which is useful when planning treatment and when calculating the PSA density. Color Doppler sonography is still under evaluation and its routine use has not yet been shown to improve detection rate or staging<sup>72,73</sup>.

### Partin's tables

Partin's tables use a combination of the clinical stage, the patient's PSA and the Gleason grade at biopsy to predict the probability of organ-confined disease, extracapsular spread,

**Table 23.7** Tumor node metastasis (TNM) classification of prostate cancer

<i>Primary tumor (T)</i>	
Tx	Primary tumor cannot be assessed
T0	No evidence of primary tumor
T1	Clinically inapparent tumor not palpable or visible by imaging
T1a	Tumor incidental histological finding in $\leq 5\%$ of tissue resected
T1b	Tumor incidental histological finding in $> 5\%$ of tissue resected
T1c	Tumor identified by needle biopsy
T2	Tumor confined within the prostate
T2a	Tumor involves one lobe
T2b	Tumor involves both lobes
T3	Tumor extends through the prostatic capsule
T3a	Extracapsular extension (unilateral or bilateral)
T3b	Tumor invades seminal vesicle(s)
T4	Tumor is fixed or invades adjacent structures other than seminal vesicles
<i>Regional lymph nodes (N)</i>	
Nx	Regional lymph nodes cannot be assessed
N0	No regional metastasis
N1	Regional lymph node metastasis
<i>Distant metastasis (M)</i>	
Mx	Distant metastasis cannot be assessed
M0	No distant metastasis
M1	Distant metastasis
M1a	Non-regional lymph node(s)
M1b	Bone(s)
M1c	Other site(s)

seminal vesicle involvement, or lymphatic nodal involvement<sup>74,75</sup>. These tables have been reviewed subsequent to their first publication and have been validated in different populations. They are widely used by urologists as indicators of clinical stage and help inform discussion with patients about appropriate treatment.

### *Magnetic resonance imaging and computed tomography*

Magnetic resonance imaging (MRI) is often used to assess capsular penetration and seminal vesicle involvement but the routine use of MRI remains controversial; endorectal coil as opposed to whole body MRI gives greater accuracy

in staging<sup>76</sup>, but is more invasive and not widely available. Neither computed tomography (CT) nor MRI are sensitive enough to advocate their routine use in staging.

### *Lymph node staging*

No preoperative investigation is sufficient to detect reliably the presence of lymph node involvement and therefore lymph node status is often only determined at the time of surgery. The decision to perform a lymphadenectomy is surgeon dependent but preoperative PSA, rectal examination and histology are all used as indicators<sup>77,78</sup>.

For those rare cases in which the lymph node status is important in determining the definitive treatment plan, then laparoscopic lymphadenectomy is a viable option.

Recent developments in the use of nanoparticles containing iron oxide injected intravenously 24 hours prior to performing an MRI are giving exciting and encouraging results in detecting early lymphatic involvement. Early studies give sensitivity values of 91% for detecting lymphatic disease<sup>79</sup>.

### *Bone scan*

Radionuclide bone scans using technetium are used for assessing bone metastasis, ideally performed prior to the commencement of any treatment. This is more sensitive than skeletal radiography, however, skeletal X-rays are useful in clarifying ambiguous results from other skeletal pathology, for example Paget's disease, healing fractures, or osteoarthritis.

Bone scans can be avoided in groups of men when the risk of metastatic disease is low. This would include asymptomatic patients with a PSA level less than 20 ng/ml, stage less than T4 and Gleason score less than 8, and should be omitted unless the major Gleason pattern is 4<sup>80</sup>.

## SCREENING

It is thought that the earlier detection of prostate cancer by screening techniques could lead to a reduction in the mortality rate<sup>81</sup>. However, there is the concern, that with some papers suggesting an incidence rate of up to 24%<sup>82</sup> and a risk of mortality from prostate cancer of only 3–4%<sup>4</sup>, that a screening program could lead to over diagnosis and subsequent over treatment. Ongoing studies such as the Prostate, Lung, Colorectal and Ovarian Cancer Screening Trial (PLCO) and the European randomized study of screening for prostate cancer have been set up to look at the role of screening. The earliest results of these studies are due for publication in 2008 and should go some way to answering the debate. In addition, the PROTEC study is evaluating the effect of prostate cancer screening.

## DIAGNOSIS

Once the suspicion of prostate cancer has been raised then histological diagnosis is achieved by transrectal ultrasound-guided prostatic biopsies. The biopsies are performed under local anesthetic, with antibiotic cover using a 10 Hz ultrasound rectal probe and a trucut needle. The biopsies are targeted to the peripheral zone in a systematic fashion. With increasing number of biopsies the detection rate increases but so does the morbidity and it is therefore accepted that between ten and 12 cores should be taken.

In more advanced cases (T3 and T4) fewer biopsies can be taken especially if the PSA is significantly raised<sup>2</sup>. Patients can also be diagnosed following a TURP, where the pre-operative PSA and DRE failed to raise any suspicion of cancer (stage T1b and T1c). Depending on the volume and grade of prostate cancer present, the patient's age and co-morbidity these patients may or may not require any further treatment<sup>1</sup>.

## TREATMENT

Treatment principally depends on whether the prostate cancer is deemed curative or not, i.e. localized as opposed to locally advanced or metastatic. In a localized prostate cancer (preoperative staging T2NXM0 or less) radical treatment should be considered if the patient has a life-expectancy of greater than 10 years. The management of locally advanced prostate cancer is more controversial, radical surgery or radical radiotherapy alone is not justified.

Combination therapy is therefore often adopted with the use of surgery, radiotherapy and hormone manipulation playing the primary roles. All of the treatment options will be discussed below, however, it is important before deciding on a definitive management plan that a patient's age, co-morbidity, stage, and grade of the disease are all taken in to account.

### Localized prostate cancer

There are no randomized studies comparing the different treatment options for localized prostate cancer (T2N0M0 or less). All of the options are discussed below and the final decision for treatment is agreed between physician and patient once appropriate counselling has taken place.

### Active monitoring

Active monitoring is an attempt to delay the consequences of treatment until evidence of tumor activity suggests progression of disease. It is suitable for patients with T1a well and moderately differentiated disease, or higher staged

localized disease with a life expectancy of less than 10 years. It can also be appropriate in more advanced and higher grade disease in patients who have a short life expectancy, or in patients who are well informed and are unwilling to accept the side-effects of alternative treatment.

Although active monitoring avoids the side-effects experienced by some patients undergoing radical treatment, patients should be aware of recent studies indicating a decreased survival time when compared with radical prostatectomy<sup>88</sup>.

Active monitoring involves regular clinic review assessing the patient's clinical status and PSA levels. In some schemes regular repeat prostate biopsy has been suggested to ensure that the grade of tumor does not progress<sup>89</sup>. There is no definitive PSA level where treatment is recommended but rather an arbitrarily figure decided on individual merit. Active monitoring can be used as a treatment option in its own right but can also be used to assess the characteristics of the tumor prior to considering radical treatment. This does, however, run the risk of missing the opportunity of treating organ-confined disease.

### Radical prostatectomy

This involves the removal of the entire prostate gland and the seminal vesicles. This can be performed open, laparoscopic, or robotically assisted. The advantage of the latter two is decreased blood loss, shorter hospital stay and quicker return to full activity; however, there are no randomized controlled studies comparing the different methods<sup>90</sup>. It is also felt that due to the superior vision experienced the continence and potency rates will be higher, although again evidence of this is currently lacking.

Open removal can be via the retropubic or the perineal approach. Tumor progression and patient survival appear to be similar whichever technique is adopted and the final decision is dependent on the surgeon's experience and preference. Whichever technique is adopted, if the final histology shows clear margins and organ-confined disease, then the patient can expect a good prognosis even with high grade disease<sup>91</sup>. Work by D'Amico *et al.* has allowed urologists to predict a patient's chances of being disease free at 10 years depending on their final stage, grade and preoperative PSA<sup>92</sup>. A summary of this can be seen in Table 23.8.

Should the final histology indicate T3 disease and no lymph node involvement then adjuvant radiotherapy has been shown to increase the PSA-free and disease-free survival with data due to be published on overall survival<sup>93</sup>.

Although the use of neoadjuvant hormone therapy has been shown to decrease the size of the prostate and reduce the incidence of positive surgical margins<sup>94–97</sup>. The long-term follow-up of these patients has shown no

Table 23.8

Risk group	PSA (ng/ml)	Pathological stage (1997)	Grade	10-year PSA survival (%)
Low	0–10	T1c–T2a	≤6	83
Intermediate	10–20	T2b	7	46
High	>20	T2c	≥8	29

Adapted from reference 92.

benefit in terms of PSA-free survival when compared with radical prostatectomy alone<sup>98,99</sup>. The use of neoadjuvant hormonal treatment in conjunction with surgery can therefore not be supported at this stage.

Follow-up after radical prostatectomy is based around PSA readings with levels <0.1 ng/ml being deemed a success. Failure following radical surgery is defined as two PSA readings of 0.2 ng/ml or above. If this is discovered during follow-up then additional treatment is almost certainly required. The mortality and morbidity of radical surgery have improved with surgical experience, recording of complications can often be difficult and hence the wide variation in figures quoted in Table 23.9.

## Radiotherapy

External beam radiotherapy can be considered for the same group of patients as radical prostatectomy. Unlike surgery radiotherapy does not remove the prostate and therefore grading and staging is limited to preoperative investigations and therefore can lead to either under- or over-staging/grading the disease.

Three-dimensional conformal radiotherapy is now considered the gold standard for radiotherapy treatment. This technique allows greater accuracy and therefore higher doses can be administered with a reduced side-effect profile. However, the dose administered is still controversial with doses above 75 Gy giving greater PSA-free survival but is associated with greater morbidity. Side-effects are similar to those experienced by patients undergoing radical surgery.

Follow-up of the condition is also open to variation. In surgery an operation is only considered a success if the PSA is unrecordable, in radiotherapy there is variation amongst clinicians as to what value PSA nadir is considered a success. Generally if the PSA is <1.0 ng/ml then no additional treatment is required. Once the nadir has been reached, recurrence is assumed if there are three consecutive rises in the PSA<sup>100</sup>.

Table 23.9 Complications following radical prostatectomy

Complication	Incidence (%)
Mortality	0.0–2.1
Major bleeding	1.0–11.5
Rectal Injury	0.0–5.4
Impotence	29.0–100.0
Severe stress incontinence	0.0–15.4
Slight stress incontinence	4.0–50.0
Bladder neck obstruction	0.5–14.6
DVT	0.0–8.3

Adapted from European Association of Urology Guidelines 2006, Prostate Cancer

## Interstitial radiotherapy (brachytherapy)

This involves the placement of radiation sources, most commonly palladium-103 or iodine-125 within the prostate carried out generally as a day-case procedure. Because of the half-life of the isotopes, 17 days for palladium and 60 days for iodine, the isotopes will give off most of their radiation over the following 3–10 months.

Brachytherapy is not suitable for all types of localized prostate cancer and therefore patient selection is important. In general it does well for low grade, low volume disease in men who have small prostates and minimal urinary symptoms.

## Cryotherapy

Cryotherapy involves the rapid freezing and slow thawing of prostatic tissue via multiple small cryoneedles that produce small iceballs. To achieve the best results this is performed as repetitive cycles to temperatures of less than –40°C. High-pressure argon gas is used to reduce the temperature, while high-pressure helium is used as a warming material. The needles are placed using transrectal ultrasound which remains *in situ* throughout the procedure. The urethra is protected by passing warm fluid down a catheter during the treatment this prevents urethral sloughing and protects the external urethral sphincter. A suprapubic catheter is inserted at the start of the procedure and generally remains in for at least a week postoperatively.

Long-term results for cryotherapy are not available at this stage and until they are, although an option for localized and locally advanced prostate cancer, it should be considered experimental at this stage. However, it is establishing a role as salvage treatment after PSA recurrence following radiotherapy.

## Lymph node positive

The lymph node status as previously alluded to is often not known; however, it can be predicted by using Partin tables or discovered following a radical prostatectomy or lymph node sampling.

If a patient is unexpectedly found to be lymph node positive following histology then there is evidence that they will benefit from adjuvant hormone treatment<sup>101,102</sup>. At a median follow-up of 10 years the overall survival has been shown to be 72% versus 49% in favor of immediate hormone treatment. Men should therefore be commenced on appropriate hormone therapy immediately following radical prostatectomy if lymph nodes are found to be positive.

## Locally advanced prostate cancer

Locally advanced prostate cancer (T3N0/XM0) has invaded into extraprostatic tissue but with no evidence of metastatic spread. The lymph node status is often unknown but assumed to be clear.

Despite it being considered by many as incurable, radical surgery and radiotherapy have been the subjects of a number of trials for the treatment of clinically T3 disease. The results have not been encouraging. Surgery alone will result in a PSA-free survival at 5 years of between 20 and 30%<sup>103,104</sup>, and although local control may be achieved most men will die from disseminated disease<sup>105</sup>.

Radiotherapy alone gives similar results with overall survival at 5 years of around 65% and 10 years of approximately 35–42%; disease-free survival is understandably less with figures of 44–58% and 28–44%, respectively, being quoted<sup>106–108</sup>.

These disappointing results lead to the belief that combining surgery or radiotherapy with hormone treatment would improve results. While neoadjuvant hormone therapy has been proven to reduce the size of the prostate its use prior to surgical treatment has not altered PSA progression<sup>96,109,110</sup>. Anecdotally surgeons have reported the operation to be technically more difficult following hormone manipulation; however, some complications such as blood loss and transfusion rates appear equal in the two groups<sup>111</sup>.

More recent studies have focused on the role of radiotherapy following radical surgery for pathological T3 disease. Work carried out by Bolla *et al.* showed an improvement in biochemical and clinical progression in a group of men treated with a 6-week course of radiotherapy 16 weeks after their surgery<sup>93</sup>.

Greater emphasis in this group of patients is placed on radiotherapy with neoadjuvant hormone therapy. Randomized studies have demonstrated an improvement

in local control and survival in patients treated with combination therapy as opposed to radiotherapy alone. The length of time patients need to be on androgen deprivation is still to be established<sup>112,113</sup>. Trials are currently ongoing to evaluate whether this benefit can be seen with just hormonal treatment.

## Alternative treatment

### *High intensity focused ultrasound*

High intensity focused ultrasound (HIFU) can be considered as an alternative form of treatment for either primary or salvage therapy for prostate cancer. It works by coagulative necrosis of tissue at a frequency of between 3 and 4 MHz with the advantage of not damaging the structures that it passes through or increasing the risk of metastases<sup>114,115</sup>. Temperatures reach 80–90°C at the point of the ultrasound focus; however, due to the steep temperature gradient at the focal point there is obvious demarcation between necrotic and normal tissue<sup>116,117</sup>. Prostatic tissue of up to 40 g can be treated in one sitting and the time taken normally varies between 1 and 3 hours. A suprapubic catheter is sited prior to commencement of the procedure and left for approximately 14 days afterwards.

Work performed by Chaussy *et al.*<sup>118</sup> demonstrated that a TURP done in conjunction with HIFU resulted in not only debulking the prostate and therefore reducing the operating time, but also lowered some of the associated morbidity, mean catheter time reduced from 40 to 7 days, incontinence reduced from 15.4% to 6.9%, urinary infection rate 47.9% to 11.4%, and IPSS improved from 8.91 to 3.37. A combination of TURP and HIFU is now considered standard practice in Europe<sup>119</sup>. Follow-up data are limited with early results of localized prostate cancer showing that PSA nadir is reached at 3 months and 93.4% of patients had a PSA of below 1.0 ng/ml at a mean follow-up of 22 months; all patients had a negative control biopsy<sup>120</sup>. The role of HIFU will be determined once the long-term results are published and there are randomized trials conducted against current accepted treatments.

## Advanced prostate cancer

Advanced prostate cancer implies lymphatic involvement with or without distant metastases and is also therefore incurable. Treatment options available aim at palliation from the known complications of prostate cancer, maintaining quality of life and potentially prolonging the patients survival time.

Since the dependency of prostate cancer on androgen stimulation was first described by Huggins and Hodges in 1941<sup>121</sup>, the mainstay of treatment for advanced prostate

cancer has remained prevention of androgen stimulation of the prostate. This can be achieved through either surgical castration or medical manipulation. The different types of hormonal treatment and time scale to achieve therapeutic levels of testosterone can be seen in Table 23.10.

Most testosterone (approximately 90%) comes from the Leydig cells of the testis with the remainder arising from the adrenal glands. Medical or surgical castration results in prevention of androgen production from the testicle; however, adrenal androgens can potentially have an effect on the prostate. Numerous studies have therefore looked at the role of maximal androgen blockade with conflicting results. Maximal androgen blockade involves the addition of a steroidal or non-steroidal anti-androgen to initial castration therapy. If benefit is present then it is of little clinical significance with a 5-year survival advantage of less than 5%<sup>122,123</sup>.

Because of the side-effects of castration (Table 23.11) intermittent and delayed androgen deprivation has been advocated in certain cases. Intermittent therapy will result in periods off medical castration once an acceptable PSA nadir has been reached. The resultant rise in testosterone has been shown to improve the quality of life of some patients and it is thought that it may have a role in delaying the time to progression to hormone refractory prostate cancer; however, this remains to be proven.

Controversy is still present over the role of immediate or deferred androgen ablation. The Veterans Administration Cooperative Urological Research Group published a series of papers in the 1960s and 1970s comparing these

two groups of patients<sup>124–126</sup>. These studies showed comparable survival between initial and deferred treatment groups for prostate cancer but an increase in the complications seen in the estrogen therapy group. Later studies showed that a reduced dose of estrogen 1.0 mg/day compared with 5.0 mg/day had equal effect on prostate cancer and a reduced cardiotoxicity profile. This study was unable to answer the question of immediate versus delayed treatment as many patients in the deferred arm failed to receive any treatment for their prostate cancer. Later studies by the Medical Research Council<sup>127,128</sup> looking at metastatic and non-metastatic disease showed an improvement in the complications, but no increase in survival in the immediate treatment group for known metastatic disease. Again in the non-metastatic group a survival benefit is seen in the immediate treatment group but no definitive conclusions could be drawn as many patients in the placebo arm failed to receive any treatment.

### Treatment options after initial treatment has relapsed

#### *Hormone refractory prostate cancer*

Prostate cancer is said to become hormone refractory when there is a rise in serum PSA following the PSA nadir encountered after initiation of androgen deprivation therapy. The mechanism of hormone refractory prostate cancer (HRPC) is not fully understood and is multifactorial with the progression of androgen independent cells, androgen

**Table 23.10**

<i>Treatment</i>	<i>Time to castration levels of testosterone</i>	<i>Mechanism of action</i>
Bilateral orchidectomy		Stop testosterone production from testicles
Estrogens		Decrease in LHRH production Androgen inactivation Suppression of Leydig cell function
LHRH agonists (buserelin, goserelin, leuprorelin, triptorelin)	2–4 weeks 10% fail to achieve castration levels	Downregulation of LHRH receptors following initial testosterone surge
LHRH antagonists (abarelix)		Competitively binds to LHRH receptors
Non-steroidal antiandrogens (bicalutamide, flutamide, nilutamide)	Testosterone levels remain normal	Competitively binds to androgen receptors in prostate
Steroidal antiandrogens (cyproterone acetate)	Testosterone levels remain normal	Competitively binds to androgen receptors in prostate Inhibition of pituitary gland

LHRH, luteinizing hormone releasing hormone.



**Table 23.11** Principal effects of castration*Principal side-effects of castration*


---

Loss of libido
Erectile dysfunction
Hot flushes
Gynecomastia
Increase in body fat
Muscle wasting
Anemia
Osteopenia and osteoporosis

---

receptor gene mutations, deregulation of apoptosis and peptide growth factors all playing a role<sup>129–132</sup>. HRPC can be further divided into androgen-independent, but hormone sensitive carcinoma or true HRPC; the former still responds to secondary hormone manipulation whereas the latter is resistant to all hormone measures.

For the disease to become androgen-independent adequate levels of castration must first be demonstrated by performing serum testosterone levels. Any additional treatment should be given in conjunction with continued luteinizing hormone releasing hormone (LHRH) therapy as survival may be compromised if castration therapy is stopped<sup>133</sup>. Additional therapy includes antiandrogen therapy (steroidal or non-steroidal), withdrawal of antiandrogen, steroids, estrogen, non-hormonal chemotherapy, and active monitoring.

### Chemotherapy in prostate cancer

Docetaxel was the first treatment to show an increase in survival<sup>134</sup>. Prior to this, chemotherapy was available in the form of mitoxantrone and prednisolone which significantly improved the patients' bone pain and quality of life but had no effect on survival<sup>135</sup>. Docetaxel is an antineoplastic drug belonging to the taxane group, it disrupts the microtubular network that is essential for the mitotic and interphase cell functions resulting in failure of division and cell death. It should be administered with prednisolone, as a 1 hour infusion every 3 weeks for a maximum of 10 weeks. Side-effects include hypersensitivity reactions, bone marrow suppression, fluid retention, peripheral neuropathy and alopecia. In suitable patients, Karnofsky performance status 60% or above the patient can expect a median survival benefit of approximately 3 months when compared with mitoxantrone and prednisolone. There is also an improvement in quality of life, bone pain and PSA response<sup>135</sup>.

## COMPLICATIONS

### Skeletal complications

The formation of bone metastases is a complex interaction between tumor cells and bone microenvironment which results in a disruption of the normal bone remodeling process. Prostate skeletal metastases are principally osteoblastic, but are also associated with an increase in osteolytic activity resulting in marked bone turnover and significant morbidity<sup>136,137</sup>.

Complications commonly arise from skeletal metastases and/or osteoporosis, these can result in pain, vertebral collapse, pathological fractures, and spinal cord compression. Bone metastases will occur in patients with advanced prostate cancer in 65–75% of cases<sup>138–140</sup>. These patients have a median survival time of between 12–53 months, and 30–50% of these men will experience at least one skeletal and related event<sup>137,138,141–143</sup>. Treatment of skeletal complications should primarily be preventative thus avoiding nasty complications; treatment involves a combination of radiotherapy, bisphosphonates, analgesia, and radionuclids.

### Bisphosphonates and skeletal complications

Bisphosphonates inhibit osteoclast activity and therefore reduce bone resorption. Zoledronic acid is the first bisphosphonates to show a reduction in skeletal complications from prostatic bone metastases<sup>143,144</sup>. It has been shown to decrease the incidence of pathological fractures and improve the quality of life of patients with evidence of metastatic disease.

As the role of zoledronic acid develops, support is being gained for its use in for prevention against androgen deprivation-induced osteoporosis<sup>145</sup>. Androgens play an important role in skeletal integrity<sup>146</sup> and as men reach the age of 40–50 their androgen production goes down resulting in a bone loss of 0.3–0.5% per year. If androgen ablation is induced then that rate will increase up to 10-fold<sup>147</sup>. Early use of zoledronic acid may help to prevent some of the complications seen with long-term use. It was the first bisphosphonate to demonstrate an increase in bone mineral density<sup>145</sup>.

### Urinary tract obstruction

Renal obstruction and subsequent renal failure can occur either by direct compression of the ureteric orifices by growth of the prostate or by ureteric compression from enlarged lymph nodes. Patients generally tend to present in a chronic fashion, however, acute renal obstruction with resulting renal colic can be seen<sup>148,149</sup>. The decision to proceed with decompression with nephrostomies is often a complex one and depends on the patient's co-morbidity

and suitability for further treatment. Although the placement of nephrostomies can lead to prolonged survival this can be at the expense of quality of life<sup>149</sup>. Nephrotomies are best considered in hormone naïve patients or those likely to benefit from chemotherapy, in these cases intervention decreases morbidity as well as prolonging life<sup>150,151</sup>.

## Spinal cord compression

Spinal metastases occur most commonly in the thoracic and lumbar vertebral bodies<sup>152,153</sup>. Patients at risk of spinal

cord compression from their prostatic metastases are most likely to present with one or a combination of the symptoms of back pain, weakness, autonomic and/or sensory loss<sup>154</sup>. If spinal cord compression is suspected after clinical history and examination then MRI is the examination of choice and should be performed on an urgent basis<sup>154</sup>. Prostatic spinal cord metastases respond well to radiotherapy<sup>155,156</sup> and this is established as the 'gold-standard' for acute treatment. Other options available include surgery, steroids, chemotherapy, and hormone deprivation therapy.

## REFERENCES

1. <http://www.info.cancerresearchuk.org/cancerstats/types/prostate/>
2. Mettlin C, Jones GW, Murphy GP. Trends in prostate care in the United States 1974-1990; observations from the care evaluation studies of the American College of Surgeons Commissions of Cancer. *CA Cancer J Clin* 1993; 48: 83-91.
3. Carter HB, Coffey DS. The prostate: an increasing medical problem. *Prostate* 1990; 16: 39-48.
4. Parkin DM, Bray F, Ferlay J, Pisani P. Global cancer statistics, 2002. *CA Cancer J Clin* 2005; 55: 74-108.
5. Wingo PA, Tong T, Bolden S. Cancer statistics, 1995. *CA Cancer J Clin* 1995; 45: 8-31.
6. Landis SH, Murray T, Bolden S, Wingo PA. Cancer Statistics 1998. *CA Cancer J Clin* 1998; 48: 6-29.
7. Breslow N, Chan CW, Dhon G et al. Latent carcinoma of the prostate at autopsy in seven areas. *The International Agency for Research on Cancer, Lyons, France. Int J Cancer* 1977; 20: 680-8.
8. Zaridze DG, Boyle P. Cancer of the prostate: epidemiology and aetiology. *Br J Urol* 1987; 59: 493-502.
9. Carter HB, Piantadosi S, Issacs JT. Clinical evidence for and implications of the multistep development of prostate cancer. *J Urol* 1990; 143: 742-6.
10. Zaridze DG, Boyle P, Smans M. International trends in prostate cancer. *Int J Cancer* 1984; 33: 223-30.
11. Woolf CM. An investigation of familial aspects of carcinoma of the prostate. *Cancer* 1960; 13: 739-44.
12. Spitz MR, Currier RD, Fugger JJ et al. Familial patterns of prostate cancer: a case control analysis. *J Urol* 1991; 146: 1305-7.
13. Carter BS, Beaty TH, Steinberg GD et al. Mendelian inheritance of familial prostate cancer. *Proc Natl Acad Sci* 1993; 89: 3367-71.
14. Cannon L, Bishop DT, Skolnick M et al. Genetic epidemiology of prostate cancer in the Utah Mormon genealogy. *Cancer Surv* 1982; 1: 47-69.
15. Carter BS, Bova GS, Beaty TH et al. Hereditary prostate cancer: epidemiologic and clinical features. *J Urol* 1993; 150: 797-802.
16. Steinberg GD, Carter BS, Beaty TH et al. Family history and the risk of prostate cancer. *Prostate* 1990; 17: 337-47.
17. Page WF, Braun MM, Partin AW et al. Heredity and prostate cancer: a study of World War II veteran twins. *Prostate* 1997; 33: 240-5.
18. Smith JR, Freije D, Carpten JD et al. Major susceptibility locus for prostate cancer on chromosome 1 suggested by a genome-wide search. *Science* 1996; 274: 1371.
19. Giovannucci E, Rimm EB, Colditz GA et al. A prospective study of dietary fat and prostate cancer. *J Natl Cancer Inst* 1993; 85: 1571-9.
20. West DW, Slattery ML, Robinson LM et al. Adult dietary intake and prostate cancer risk in Utah: a case-control study with special emphasis on aggressive tumours. *Cancer Causes Control* 1991; 2: 84-94.
21. Whittemore AS, Kolonel LN, Wu AH et al. Prostate cancer in relation to diet, physical activity, and body size in blacks, whites, and Asians in the United States and Canada. *J Natl Cancer Inst* 1995; 87: 652-61.
22. Rose DP, Boyar AP, Wynder EL. International comparisons of mortality rates for cancer of the breast, ovary, prostate and colon, and per capita food consumption. *Cancer* 1986; 58: 2363-71.
23. Andersson SO, Wolk A, Bergstrom R et al. Body size and prostate cancer: a 20-year follow up study among 135006 Swedish construction workers. *J Natl Cancer Inst* 1997; 89: 385-9.
24. Hamalainen E, Adlercreutz H, Puska P, Pietinen P. Diet and serum hormones in healthy men. *J Steroid Biochem* 1984; 20: 459-64.
25. Zumoff B, Levin J, Strain GW et al. Abnormal levels of plasma hormones in men with prostate cancer: evidence towards a "two-disease" theory. *Prostate* 1982; 3: 579-88.
26. Drafta D, Proca E, Zamfir V et al. Plasma steroid levels in benign prostatic hypertrophy and carcinoma of the prostate. *Journal of Steroid Biochemistry* 1982; 17: 689-93.
27. Harper ME, Peeling WB, Cowley T et al. Plasma steroids and protein hormone concentrations in patients with prostatic carcinoma before and during oestrogen therapy. *Acta Endocrinol* 1976; 81: 409-26.
28. Habib FK, Lee IR, Stich SR, Smith PH. Androgen levels in the plasma and prostatic tissues of patients with benign hypertrophy and carcinoma of the prostate. *J Endocrinol* 1976; 71: 99-107.
29. Ross R, Bernstein L, Judd H et al. Serum testosterone levels in healthy young black and white men. *J Natl Cancer Inst* 1986; 76: 45-8.
30. Ross RK, Bernstein L, Lobo RA et al. 5-alpha-reductase activity and risk of prostate cancer among Japanese and US white and black males. *Lancet* 1992; 339: 887-9.
31. Elghany NA, Schumacher MC, Slattery ML, West DW. Occupation, cadmium exposure and prostate cancer. *Epidemiology* 1990; 1: 107-15.

32. Delzell E, Macaluso M, Honda Y, Austin H. Mortality patterns among men in the motor vehicle manufacturing industry. *Am J Ind Med* 1993; 24: 471–84.
33. Tola S, Kalliomaki PL, Pukkala E et al. Incidence of cancer among welders, platers machinists and pipe fitters in shipyards and machine shops. *Br J Ind Med* 1988; 45: 209–18.
34. Morrison H, Savitz D, Semenciw R et al. Farming and prostate cancer mortality. *Am J Epidemiol* 1993; 137: 270–80.
35. Wiklund K, Dich J, Holm LE, Eklund G. Risk of cancer in pesticide applicators in Swedish agriculture. *Br J Ind Med* 1989; 46: 809–14.
36. Schwartz GC, Hulka BS. Is vitamin D deficiency a risk factor for prostate cancer? *Anticancer Res* 1990; 10: 1307–12.
37. Hanchette CI, Schwartz GC. Geographic patterns of prostate cancer mortality. *Cancer* 1992; 70: 2861–9.
38. M'Buyamba-Kabangu JR, Fagard R, Lijnen P et al. Calcium, vitamin D-endocrine system, and parathyroid hormone in black and white males. *Calcif Tissue Int* 1987; 41: 70–4.
39. Eisman JA, Barkla DH, Tutton PJ. Suppression of in vivo growth of human solid tumour xenografts by 1 $\alpha$  25-dihydroxyvitamin D<sub>3</sub>. *Cancer Res* 1987; 47: 21–5.
40. Abe E, Miyaura C, Sakagami H et al. Differentiation of mouse myeloid leukemia cells induced by 1 $\alpha$  25-dihydroxyvitamin D<sub>3</sub>. *Proc Natl Acad Sci USA* 1981; 78: 4990–4.
41. Skowronski RJ, Peehl DM, Feldman D. Actions of vitamin D<sub>3</sub> analogs on human prostate cancer cell lines: comparison with 1,25-dihydroxyvitamin D<sub>3</sub>. *Endocrinology* 1995; 136: 20–6.
42. Reitsma PH, Rothberg PG, Astrin SM et al. Regulation of myc gene expression in HL-60 leukaemia cells by a vitamin D metabolite. *Nature* 1983; 306: 492–4.
43. Kovi J, Heshmat MY. Incidence of cancer in negroes in Washington DC, and selected African cities. *Am J Epidemiol* 1972; 96: 401–13.
44. Oishi K, Okada K, Yoshida O et al. A case control study of prostatic cancer with reference to dietary habits. *Prostate* 1988; 12: 179–90.
45. Kolonel LN, Hankin JH, Yoshawa CN. Vitamin A and prostate cancer in elderly men: enhancement of risk. *Cancer Res* 1987; 47: 2982–5.
46. Clark LC, Combs GF Jr, Turnbull BW et al. Effects of selenium supplementation for cancer prevention in patients with carcinoma of the skin. A randomized controlled trial. Nutritional Prevention of Cancer Study Group. *JAMA* 1996; 276: 1957–1963.
47. Heinonen OP, Albanes D, Huttunen JK et al. Prostate cancer and supplementation with alpha-tocopherol and beta-carotene: incidence and mortality in a controlled trial. *J Natl Cancer Inst* 1998; 90: 440–6.
48. Pienta KJ, Dempers R, Hoff M et al. Effect of age and race on the survival of men with prostate cancer in the metropolitan Detroit tricounty area, 1973 to 1987. *Urology* 1995; 45: 93–101.
49. Wang MC, Valenzuela LA, Murphy GP et al. Purification of a human prostate specific antigen. *Invest Urol* 1979; 17: 159–63.
50. Stamey TA, Yang N, Hay AR et al. Prostate-specific antigen as a serum marker for adenocarcinoma of the prostate. *N Engl J Med* 1987; 317: 909–16.
51. Lilja H, Christensson A, Dahlen U et al. Prostate-specific antigen in serum occurs predominantly in complex with  $\alpha$ 1-antichymotrypsin. *Clin Chem* 1991; 37: 1618–25.
52. Oesterling JE, Chan DW, Epstein JI et al. Prostate specific antigen in the preoperative and postoperative evaluation of localized prostatic cancer treated with radical prostatectomy. *J Urol* 1988; 139: 766–72.
53. Oesterling JE, Rice DC, Glenski WJ et al. Effect of cystoscopy, prostate biopsy and transurethral resection of prostate on serum prostate-specific antigen concentration. *Urology* 1993; 42: 276–82.
54. Crawford ED, Schultz MJ, Clejan S et al. The effect of digital rectal examination on prostate-specific antigen levels. *JAMA* 1992; 267: 2227–8.
55. Young JM, Muscatello DJ, Ward JE. Are men with lower urinary tract symptoms at increased risk of prostate cancer? A systematic review and critique of the available evidence. *BJU Int* 2000; 85: 1037–48.
56. Benson MC, Whang IS, Pantuck A et al. Prostate specific antigen density: a means of distinguishing benign prostatic hypertrophy and prostate cancer. *J Urol* 1992; 147: 815–6.
57. Zlotta AR, Djavan B, Marberger M et al. Prostate specific antigen of the transition zone: a new parameter for prostate cancer prediction. *J Urol* 1997; 157: 1315–21.
58. Oesterling JE, Jacobsen SJ, Chute CG et al. Serum prostatespecific antigen in a community-based population of healthy men. Establishment of age-specific reference ranges. *JAMA* 1993; 270: 860–4.
59. Carter HB, Pearson JD, Metter EJ et al. Longitudinal evaluation of prostate-specific antigen levels in men with and without prostate disease. *JAMA* 1992; 267: 2215–20.
60. Schmid H-P, McNeal JE, Stamey TA. Observations on the doubling time of prostate cancer. The use of serial prostate-specific antigen in patients with untreated disease as a measure of increasing cancer volume. *Cancer* 1993; 71: 2031–40.
61. Gleason DF, Mellinger GT. Prediction of prognosis for prostatic adenocarcinoma by combined histological grading and clinical staging. *J Urol* 1974; 111: 58–64.
62. Albertsen P, Hanley JA, Gleason DF et al. Competing risk analysis of men 55 to 74 years at diagnosis managed conservatively for clinically localized prostate cancer. *JAMA* 1998; 280: 975–80.
63. Smith DS, Catalona WJ. Interexaminer variability of digital rectal examination in detecting prostate cancer. *Urology* 1995; 45: 70.
64. Partin AW, Borland RN, Epstein JI et al. Influence of established capsular penetration on prognosis in men with clinically localized prostate cancer. *J Urol* 1993a; 150: 135.
65. Aus G, Bergdahl S, Hugosson J et al. Outcome of laterally directed sextant biopsies of the prostate in screened males aged 50–66 years. Implications for sampling order. *Eur Urol* 2001; 139: 655–60.
66. Djavan B, Ravery V, Zlotta A et al. Prospective evaluation of prostate cancer detection on biopsies 1,2,3 and 4; when should we stop? *J Urol* 2001; 166: 1679–83.
67. Applewhite JC, Matlaga BR, McCullough DL. Results of the 5 region prostate biopsy method: the repeat biopsy population. *J Urol* 2002; 168: 500–3.
68. Zlotta AR, Raviv G, Schulman CC. Clinical prognostic criteria for later diagnosis of prostate carcinoma patients with initial isolated prostatic intraepithelial neoplasia. *Eur Urol* 1996; 30: 249–55.
69. Haggman MJ, Macoska JA, Wojno KJ et al. The relationship between prostatic intraepithelial neoplasia and prostate cancer: critical issues. *J Urol* 1997; 158: 12–22.
70. Smith JA Jr, Scardino PT, Resnick MI et al. Transrectal ultrasound versus digital rectal examination for the staging of carcinoma of the prostate: results of a prospective multi-institutional trial. *J Urol* 1997; 157: 902–6.
71. Liebrass RH, Pollack A, Lankford SP et al. Transrectal ultrasound for staging prostate carcinoma prior to radiation therapy: an evaluation based on disease outcome. *Cancer* 1999; 85: 1577–85.

72. Kravchick S, Cytron S, Peled R et al. Optimal combinations for detection of prostate cancer: systematic sextant and laterally directed biopsies versus sextant and color dopler-targeted biopsies. *Urology* 2004; 63: 301–5.
73. Frauscher F, Klausner A, Volgger H et al. Comparison of contrast enhanced color Doppler targeted biopsy with conventional systematic biopsy: impact on prostate cancer detection. *J Urol* 2002; 167: 1648–52.
74. Partin AW, Yoo J, Carter HB et al. The use of prostate-specific antigen, clinical stage and Gleason score to predict pathological stage in men with localised prostate cancer. *J Urol* 1993; 150: 110–4.
75. Partin AW, Subong ENP, Walsh PC et al. Combination of prostate-specific antigen, clinical stage and Gleason score to predict pathological stage of prostate cancer. A multi-institutional update. *JAMA* 1997; 277: 1445–51.
76. Schnall MD, Imai Y, Tomaszewski J et al. Prostate cancer: local staging with endorectal surface coil MR imaging. *Radiology* 1991; 178: 797–802.
77. Partin AW, Mangold LA, Lamm DM et al. Contemporary update of the prostate cancer staging nomograms (Partin Tables) for the new millennium. *Urology* 2001; 58: 843–8.
78. Stone NN, Stock RG, Parikh D et al. Perineural invasion and seminal vesicle involvement predict pelvic lymph node metastasis in men with localised carcinoma of the prostate. *J Urol* 1998; 160: 1722–36.
79. Harisingham MG, Barentsz J, Hahn PF et al. Noninvasive detection of clinically occult lymph-node metastases in prostate cancer. *N Engl J Med* 2003; 348: 2491–9.
80. O'Sullivan JM, Norman AR, Cook GJ et al. Broadening the criteria for avoiding staging bone scans in prostate cancer: a retrospective study of patients at the Royal Marsden Hospital. *BJU Int* 2003; 92: 685–9.
81. Reissigl A, Horninger W, Fink K et al. Prostate carcinoma screening in the county of Tyrol, Austria: experience and results. *Cancer* 1997; 80: 1818–29.
82. Thompson IM, Goodman PJ, Tangen CM et al. The influence of finasteride on the development of prostate cancer? *N Engl J Med* 2003; 349: 215–24.
83. Brnic Z, Gasparov S, Lozo PV et al. Is quadrant biopsy sufficient in men likely to have advanced prostate cancer? Comparison with extended biopsy. *Pathol Oncol Res* 2005; 11: 40–4.
84. Lowe BA, Listrom MB. Incidental carcinoma of the prostate: an analysis of the predictors of progression. *J Urol* 1988; 140: 1340–4.
88. Holmberg L, Bill-Axelsson A, Helgesen F et al. A randomized trial comparing radical prostatectomy with watchful waiting in early prostate cancer. *N Engl J Med* 2002; 347: 781–9.
89. Klotz L. Active surveillance for prostate cancer, for whom? *J Clin Oncol* 2005; 23: 8165–9. Review.
90. Toohar R, Swindle P, Woo H et al. Laparoscopic radical prostatectomy for localized prostate cancer; a systematic review of comparative studies. *J Urol* 2006; 175: 2011–7.
91. Ohori M, Goad JR, Wheeler TM et al. Can radical prostatectomy alter the progression of poorly differentiated prostate cancer? *J Urol* 1994; 152: 1843–9.
92. D'Amico AV, Whittington R, Malkowicz SB et al. Predicting prostate specific antigen outcome preoperatively in the prostate specific era. *J Urol* 2001; 166: 2185–8.
93. Bolla M, van Poppel H, Collett L et al. Postoperative radiotherapy after radical prostatectomy: a randomized controlled trial. (EORTC trial 22911). *Lancet* 2005; 366: 572–8.
94. Fair WR, Aprikian A, Sogani P et al. The role of neoadjuvant hormonal manipulation in localised prostate cancer. *Cancer* 1993; 71(3 Suppl): 1031–8.
95. Hugosson J, Abrahamson PA, Ahlgren G et al. The risk of malignancy in the surgical margin at radical prostatectomy reduced almost three-fold in patients given neo-adjuvant hormone treatment. *Eur Urol* 1996; 29: 413–9.
96. Soloway MS, Sharifi R, Wajzman et al. Randomised prospective study comparing radical prostatectomy alone versus radical prostatectomy preceded by androgen blockade in clinical stage B2 (T2bNxM0) prostate cancer. The Lupron Depot Neoadjuvant Prostate Cancer Study Group. *J Urol* 1995; 154: 424–8.
97. Van Poppel H, De Ridder D, Elgamel AA et al. Neoadjuvant hormonal therapy before radical prostatectomy decrease the number of positive surgical margins in stage T2 prostate cancer: interim results of a prospective randomised trial. The Belgian Uro-Oncological Study group. *J Urol* 1995; 154: 429–34.
98. Soloway MS, Pareek K, Sharifi R et al. Neoadjuvant androgen ablation before radical prostatectomy in cT2bNxM0 prostate cancer: 5-year results. The Lupron Depot Neoadjuvant Prostate Study Group. *J Urol* 2002; 167: 112–6.
99. Van Poppel H, Goethuys H, De Ridder D et al. Neoadjuvant therapy before radical prostatectomy: impact on progression free survival. *Uro-Oncology* 2001; 1: 301–7.
100. American Society of therapeutic radiology and Oncology Consensus Panel. Consensus statement: guidelines for PSA following radiation therapy. *Int J Radiat Oncol Bio Phys* 1997; 37: 1035–41.
101. Messing E, Manola J, Sarosdy M et al. Immediate hormonal therapy compared with observation after radical prostatectomy and pelvic lymphadenectomy in men with node positive prostate cancer: results at 10 years of EST 3886. *J Urol* 2003; 169: 396–1480.
102. Tunn UW, Eckart O, Kienle E et al. Can intermittent androgen deprivation be an alternative to continuous androgen withdrawal in patients with PSA relapse. First results of the randomised prospective Phase III clinical trial EC 507. Abstract presented at American Urological Association AUA Annual Meeting, Chicago, 2003; 1481.
103. Aus G, Addou CC, Heindenreich A et al. Guidelines on prostate cancer complications. *Eur Assoc Urol* 2003; 24.
104. Eastham JA, Scardino PT. Radical prostatectomy. In: Walsh PC, Retik AB, Vaughan ED Jr et al., eds. *Campbell's Urology*, Philadelphia: WB Saunders, 1998; 3: 2547–64.
105. Morgan WR, Bergstrahl EJ, Zinke H. Long term evaluation of radical prostatectomy as treatment for clinical stage C (T3) prostate cancer. *Urology* 1993; 41: 113–20.
106. Hahn P, Baral E, Cheang M et al. Long-term outcome of radical radiation therapy for prostate carcinoma: 1967–1987. *Int J Radiat Oncol Biol Phys* 1996; 34: 41–7.
107. Perez CA, Hanks GE, Leibel SA et al. Localised carcinoma of the prostate (stages T1B, T1C, T2 and T3). Review of management with external beam radiation therapy. *Cancer* 1993; 72: 3156–73.
108. Aus G, Abrahamsson PA, Ahlgren G et al. Three-month neoadjuvant hormonal therapy before radical prostatectomy; a 7-year follow-up of a randomized controlled trial. *BJU Int* 2002; 90: 561–6.
109. Schulman CC, Debruyne FM, Forster G et al. 4-year follow-up results of a European prospective randomised study on neoadjuvant hormonal therapy prior to radical prostatectomy in T2-T3N0M0 prostate cancer. European Study Group on neoadjuvant Treatment of Prostate Cancer. *Eur Urol* 2000; 38: 706–13.
110. Van Poppel H, Goethuys H, De Ridder D et al. Neoadjuvant therapy before radical prostatectomy: impact on progression free survival. *Uro-Oncology* 2001; 1: 301–7.

111. Van Poppel H, Ameye F, Oyen R et al. Neo-adjuvant hormone-therapy does not facilitate radical prostatectomy. *Acta Urol Belg* 1992; 60: 73–82.
112. Denham JW, Steigler Lamb DS et al. Short-term androgen deprivation and radiotherapy for locally advanced prostate cancer: results from the Trans-Tasman radiation Oncology Group 96.01 randomised controlled trial. *Lancet Oncol* 2005; 6: 819–21.
113. Bolla M, Gonzalez D, Warde P et al. Improved survival in patients with locally advanced prostate cancer treated with radiotherapy and goserelin. *N Engl J Med* 1997; 337: 295–300.
114. Chapelon JY, Margonari J, Vernier et al. In vivo effects of high-intensity ultrasound on prostatic adenocarcinoma Dunning R3327. *Cancer Res* 1992; 52: 6353–7.
115. Oosterhof GON, Cornel EB, Smits GAHJ et al. Influence of high-intensity focused ultrasound on the development of metastases. *Eur Urol* 1997; 32: 91–5.
116. ter Haar GR, Clarke RL, Vaughan MG et al. Trackless surgery using focused ultrasound: technique and case report. *Minim Invasive Ther* 1991; 1: 13–5.
117. Chen L, Rivens I, ter Haar GR et al. Histological changes in rat liver tumours treated with high-intensity focused ultrasound. *Ultrasound Med Biol* 1993; 19: 67–74.
118. Chaussy C, Thuroff S. The status of high-intensity focused ultrasound in the treatment of localized prostate cancer and the impact of a combined resection. *Curr Urol Rep* 2003; 4: 248–52.
119. Azzouz H, de la Rosette JJ. HIFU: local treatment of prostate cancer. *EAU-EBU Update series* 2006; 4: 62–9.
120. Blana A, Walter B, Rogenhofer S et al. High-intensity focused ultrasound for the treatment of localized prostate cancer: 5 year experience. *Urology* 2004; 63: 297–300.
121. Huggins C, Hodges CV. Studies on prostate cancer: 1. The effect of castration, of estrogen and of androgen injection on serum phosphatases in metastatic carcinoma of the prostate. *Cancer Res* 1941; 1: 293–7.
122. Prostate Cancer Trialists' Collaborative Group. Maximum androgen blockade in advanced prostate cancer: an overview of the randomized trials. *Lancet* 2000; 355: 1491–8.
123. Samson DJ, Seidenfeld J, Schmitt B et al. Systemic review and meta-analysis of monotherapy compared with combined androgen blockade for patients with advanced prostate carcinoma. *Cancer* 2002; 95: 361–76.
124. Mellinger GT. Veterans Administration Cooperative Urological Research Group. Carcinoma of the prostate; a continuing co-operative study. *J Urol* 1964; 91: 590–4.
125. Byer DP. Veterans Administration Cooperative Urological Research Groups studies of cancer of the prostate. *Cancer* 1973; 32: 1126–30.
126. Veterans Administration Cooperative Urological Research Group. Factors in the prognosis of carcinoma of the prostate: A cooperative study. *J Urol* 1968; 100: 59–65.
127. Medical Research Council Prostate Cancer Working Party Investigators Group. Immediate versus deferred treatment for advanced prostate cancer: initial results of the Medical Research Council trial. *Br J Urol* 1997; 79: 235–46.
128. AHCPR report No.99-E012. <http://www.ahcpr.gov/clinic/index.html>.
129. Taplin ME, Bubley GJ, Shuster TD et al. Mutation of the androgen-receptor gene in metastatic androgen-independent prostate cancer. *N Engl J Med* 1995; 332: 1393–8.
130. Horoszewicz JS, Leong SS, Kawinski E et al. LNCaP model of human prostatic carcinoma. *Cancer Res* 1983; 4: 1809–18.
131. Stapleton AM, Timme TL, Gousse AE et al. Primary human prostate cancer cells harbouring p53 mutations are clonally expanded in metastases. *Clin Cancer Res* 1997; 3: 1389–97.
132. Kim IY, Ahn HJ, Zelner DJ et al. Loss of expression of transforming growth factor beta type I and type II receptors correlates with tumour grade in human prostate cancer tissues. *Clin Cancer Res* 1996; 2: 1255–61.
133. Manni A, Bartholomew M, Caplan R et al. Androgen priming and chemotherapy in advanced prostate cancer evaluation of determinants of clinical outcome. *J Clin Oncol* 1988; 6: 1456–66.
134. Petrylak DP, Tangen CM, Hussian P et al. Docetaxel and estramustine compared with mitoxantrone and prednisone for advanced refractory prostate cancer. *N Engl J Med* 2004; 351: 1513–20.
135. Tannock IF, Osoba D, Stockler MR et al. Chemotherapy with mitoxantrone plus prednisone or prednisone alone for symptomatic hormone-resistant prostate cancer: a Canadian randomized trial with palliative end points. *J Clin Oncol* 1996; 14: 1756–64.
136. Nomura S, Takano-Yamamoto T. Molecular events caused by mechanical stress in bone. *Matrix Biol* 2000; 19: 91–6.
137. Abrahamsson PA. Pathophysiology of bone metastases in prostate cancer. *Eur Urol (Suppl)* 2004; 3: 3–9.
138. Coleman RE. Metastatic bone disease. Clinical features, pathophysiology and treatment strategies. *Cancer Treat Rev* 2001; 27: 165–76.
139. Mundy GR. Mechanisms of bone metastasis. *Cancer* 1997; 80 (Suppl): 1546–56.
140. McMurty CT, McMurty JM. Metastatic prostate cancer: complications and treatment. *J Am Geriatr Soc* 2003; 51: 1136–42.
141. Morris MJ, Scher HI. Clinical approaches to osseous metastases in prostate cancer. *Oncologist* 2003; 8: 161–73.
142. Berruti A, Dogliotti L, Bitossi R et al. Incidence of skeletal complications in patients with bone metastatic prostate cancer and hormone refractory disease: predictive role of bone resorption and formation markers evaluated at baseline. *J Urol* 2000; 164: 1248–53.
143. Saad F, Gleason DM, Murray R et al. for the Zoledronic Acid Prostate Cancer Study Group. Long-term efficacy of zoledronic acid for the prevention of skeletal complications in patients with metastatic hormone-refractory prostate cancer. *J Natl Cancer Inst* 2004; 96: 879–82.
144. Saad F, Gleason DM, Murray R et al. A randomized, placebo-controlled trial of zoledronic acid in patients with hormone-refractory metastatic prostate carcinoma. *J Natl Cancer Inst* 2002; 94: 1458–68.
145. Smith MR, Eastham J, Gleason DM et al. Randomized controlled trial of zoledronic acid to prevent bone loss in men receiving androgen deprivation therapy for nonmetastatic prostate cancer. *J Urol* 2003; 169: 2008–12.
146. Hofbauer LC, Khosla S. Androgen effects on bone metabolism: recent progress and controversies. *Eur J Endocrinol* 1999; 140: 271–86.
147. Manolagas SC, Jilka RL. Bone marrow, cytokines and bone remodeling: emerging insights into the pathophysiology of osteoporosis. *N Engl J Med* 1995; 332: 305–11.
148. Villavicencio H. Quality of life of patients with advanced and metastatic prostate carcinoma. *Eur Urol* 1993; 24: 118–21.
149. Russo P. Urologic emergencies in the cancer patient. *Semin Oncol* 2000; 27: 282–98.
150. Paul AB, Love C, Chisholm . The management of bilateral ureteric obstruction and renal failure in advanced prostate cancer. *Br J Urol* 1994; 74: 642–5.
151. Ortlip SA, Fraley SE. Indications for palliative urinary diversion in patients with cancer. *Urol Clin North Am* 1982; 9: 79–84.

- 
152. Schiff D. Spinal cord compression. *Neuro Clin N Am* 2003; 21: 67–86.
  153. Jacobs SC. Spread of prostatic cancer to bone. *Urology* 1983; 21: 337–44.
  154. Osborn JL, Getzenberg RH, Trump DL. Spinal cord compression in prostate cancer. *J Neurooncol* 1995; 23: 135–47.
  155. Martenson JA, Evans RG, Lie MR et al. Treatment outcome and complications in patients treated for malignant epidural spinal cord compression (SCC). *J Neurooncol* 1985; 3: 77–84.
  156. Greenberg HS, Kim JH, Posner JB. Epidural spinal cord compression from metastatic tumor: results with a new treatment protocol. *Ann Neurol* 1980; 8: 361–6.



Mark Fordham and Peter Clark

---

## INTRODUCTION

The majority of solid neoplasms that develop within the testis are malignant and 95% of these are germ cell tumors (GCT). These GCTs are classified by their histological appearance into seminomas (60–70% incidence, age range 20–40 years) and non-seminomatous germ cell tumors (NSGCTs), which in the UK are often referred to as teratomas (incidence 30–40%, age range 15–30 years). Tumors with mixed elements (15–30%) are managed as for NSGCTs. This histological classification correlates well with the natural history of the tumor types and also their response rates to modern treatment modalities. Seminomas are radiosensitive but both seminomas and NSGCTs respond well to cisplatin-based chemotherapy regimens with 5-year survival rates of 90% for all GCTs and >95% for all seminomas. Prognosis is most favorable in low volume disease with a 99% 5-year survival rate for all stage I tumors but less favorable rates (~60%) for the rarer cases of advanced tumors with visceral metastases. Although testicular tumors are rare with an incidence of about 3/100 000 in the UK and account for only 1% of all male cancers, it is the commonest solid malignancy in men in the age range 15–35 years.

No specific etiological factors have been identified but there is an increased relative risk in first-degree relatives (father/brother)<sup>1</sup>, in patients with a history of testicular maldevelopment<sup>2</sup>, and patients with primary infertility<sup>3</sup>. In addition, men who have been successfully treated for testis cancer have a 2–5% incidence of developing a further tumor in the remaining testis, in some cases many years later<sup>4</sup>.

The remaining 5% of non-germ cell tumors comprise mainly lymphoma presenting in adult men (age range 50–70 years); other tumors include sex cord tumors (Sertoli cell tumors, Leydig cell tumors) in adults and paratesticular tumors (rhabdomyosarcoma in infants and leiomyosarcoma in adults). A particular feature of some GCTs is the presence of the serum tumor markers  $\beta$ -human chorionic gonadotropin ( $\beta$ -hCG),  $\alpha$ -fetoprotein

(AFP) and lactate dehydrogenase (LDH). Although not uniquely specific for GCT they provide important information when they are present about tumor burden, tumor type and response to treatment and possible relapse. The presence of a raised serum AFP indicates a teratomatous element within the tumor even if this is not identified on histology. Although  $\beta$ -hCG may be moderately raised in seminoma, high values are associated with NSGCT and indicate tumor burden and activity. The serum marker LDH is non-specific but can indicate tumor burden and be a sign of tumor relapse. The postorchidectomy rate of fall of  $\beta$ -hCG (half-life ~1 day) and AFP (half-life ~6 days) will indicate whether the tumor has been removed or if metastases are present. Because most patients presenting with a testicular tumor are young adults often at the stage of considering starting a family, the potential effects on their fertility of both surgery and chemotherapy need to inform the planning of any management regimen.

## CLINICAL PRESENTATION AND ASSESSMENT

Like all cases of malignancy, patients with a testicular tumor may present with symptoms from the primary, from metastases and from non-specific general symptoms. The majority of patients present with a swelling in the scrotum. Many men carry out self examination as a result of increased public awareness about testicular cancer, and many such cases reveal epididymal cysts, a hydrocele, or normal anatomy. The important step in clinical examination is to establish whether the mass is intratesticular indicating a high risk that it is a malignant growth. The examination of the testis may be restricted by the presence of a hydrocele which can develop secondary to a testicular tumor or by the presence of incidental epididymal cysts. If the mass lies at the junction of the testis and the epididymis it may be difficult clinically to establish whether the mass is intra-testicular. In any case



of clinical uncertainty a scrotal ultrasound scan offers a reliable method of establishing the location of the mass and in the majority of cases will confirm if the mass is intra- or extratesticular. Ultrasound is unreliable at differentiating the type of malignant tumor, although seminoma usually has a solid homogeneous appearance while a teratoma will often have a mixed solid/cystic appearance. In such cases an abdominal ultrasound scan can also be used to assess for evidence of enlarged para-aortic lymph nodes suggestive of metastatic disease. In a few cases (~10%) hemorrhage within the tumor may produce acute pain and swelling in the testis<sup>5</sup>.

The presence of pain associated with a testicular swelling is a clinical finding that has to be interpreted with care. Men who have identified a testicular swelling and have presented to a doctor may be anxious not to seem overly concerned and may minimize their symptoms while others may overplay any discomfort they have noticed. In some cases they may have noticed the lump initially after relatively minor trauma and assumed the lump was caused by the trauma. The importance of pain associated with a scrotal swelling is in establishing the differential diagnosis of epididymo-orchitis, where the swelling develops over 24–48 hours commonly associated with severe pain in the scrotum together with pyrexia and general constitutional symptoms. The clinical findings in the scrotum, however, may be indistinguishable, except by ultrasound scanning, from a testicular tumor. Testicular torsion, another cause of a painful testis in a young adult, can be suspected from the history and examination, and, where necessary, confirmed at operation.

Lymphatic metastatic spread of the testicular tumor is to the para-aortic glands and can give rise to the presenting symptom of backache. Metastases to the lungs can present as hemoptysis and to the brain as a cerebrovascular accident (CVA). In patients with high values of  $\beta$ -hCG breast plate enlargement may be noticed together with nipple tingling. This can lead to the occasional case being diagnosed by a positive pregnancy test performed on the man's urine sample. In cases of advanced disease, weight loss, anorexia and anemia are all possible features.

Rarely a patient may present with an abdominal mass which is found to be a GCT on histological analysis but no tumor or lesion is identified clinically or radiologically within either testis. Under these circumstances such a tumor is described as of extragonadal in origin. However, in some cases subsequently a tumor develops within the testis or at histological examination of the testis a healed scar is identified which is thought to be the remnant of the involuted primary tumor, the so-called Azzopardi scar<sup>6,7</sup>.

## MANAGEMENT OF THE PRIMARY TUMOR

In the majority of cases, when the intratesticular mass has been confirmed, management consists of a radical orchidectomy performed via the groin and dividing and transfixing the spermatic cord at the deep inguinal ring.

Clearly the patient needs to understand that the operation is being performed to remove what is suspected to be a malignant tumor, but this will not be confirmed until the testis has been examined histologically (unless the tumor markers are raised or there is evidence of metastatic disease).

As part of the preoperative preparation it is essential for serum tumor markers to be measured. If they are elevated then sequential postoperative measurements will indicate whether they fall to normal, indicating a stage I tumor that has been completely removed, or they remain elevated indicating metastatic disease even if the computed tomography (CT) scan is normal.

Some men will express anxiety at the change in their body image when an orchidectomy is discussed. The use of a silicone testicular implant placed at the time of the surgery produces a satisfactory prosthesis in most patients but some find that there is an unnatural feel or appearance which they can find difficult to accept.

In the rare cases where a patient presents with a testicular tumor in a solitary testis, plans should be made for an opportunity for sperm banking before any surgery is performed and, if possible, to consider performing a testis-sparing excision of the tumor. Although testis-sparing surgery runs the risk of incompletely removing any tumor, there is evidence to suggest that in some cases chemotherapy may eradicate any remaining malignant cells within the testis<sup>7,8</sup>.

In cases where the patient has presented with advanced GCT and extensive distant metastases, surgery for the primary may be regarded of secondary importance to commencing urgent chemotherapy treatment. In cases of patients with heavy tumor burden and high levels of tumor markers it is important to exclude cerebral metastases, as neurosurgical treatment may be indicated prior to starting chemotherapy.

## HISTOPATHOLOGY OF TESTICULAR TUMORS

Histopathological examination of the radical orchidectomy specimen assesses the primary for the type of testicular tumor, evidence of lymphovascular invasion and the extent of spread of the tumor within the scrotum, i.e. the pT stage. Where a tumor exhibits both seminoma and

teratoma elements the tumor is managed according to the teratoma element.

## Types of germ cell tumor

### *Seminoma*

The majority of seminoma (~85%) are 'classical' in their appearance with approximately 10% demonstrating anaplastic features. A small number are described as spermatocytic seminomas which are recognized as benign tumors and not GCT.

### *Non-seminomatous germ cell tumors (teratoma)*

These tumors are characterized by exhibiting cellular elements from all three primitive developmental layers, endoderm, mesoderm and ectoderm. Cellular elements may include glandular tissue, respiratory or gastrointestinal morphology, neurological tissue and bone or cartilaginous or skin structures. In addition embryological tissues such as trophoblastic cells, yolk cell elements and choriocarcinoma may be seen.

The American classification lists each element, whereas the UK classification subdivides into four main categories:

- Teratoma differentiated (TD) containing both mature and immature elements
- Malignant teratoma intermediate (MTI) containing teratoma with malignant transformation and can include embryonal carcinoma
- Malignant teratoma undifferentiated (MTU) describing embryonal carcinoma
- Malignant teratoma trophoblastic describing choriocarcinoma which may contain other malignant elements.

## Extent of spread

From the histological examination of the radical orchidectomy specimen the pathologist can stage the primary tumor by the TNM system.

- pT1 tumor limited to the testis and epididymis, no vascular or lymphatic involvement
- pT2 tumor limited to the testis and epididymis with vascular/lymphatic invasion, or tumor extending through the tunica albuginea
- pT3 tumor invading the spermatic cord with or without lymphovascular invasion
- pT4 tumor invading the scrotum with or without lymphovascular invasion.

## STAGING THE SPREAD OF THE TUMOR

A chest, abdomen and pelvis CT scan is needed to assess for evidence of lymph node, mediastinal and lung and liver metastases. If there is significant tumor burden or multiple pulmonary secondaries a brain CT may be needed to exclude cerebral metastatic disease.

In the USA and some European countries it is usual for patients with radiological stage I GCT to undergo retroperitoneal para-aortic lymph node dissection (RPLND). To avoid division of all sympathetic para-aortic autonomic nerves leading to retrograde ejaculation a template dissection of lymph nodes is performed depending on the side of the primary tumor<sup>10</sup>. Patients free of micro-metastases clearly have proven stage I disease. For those with lymph node metastases, removing them means the patient may be spared chemotherapy.

A prognostic classification combines the histological type, the tumor stage and the level of tumor serum markers to generate good, intermediate and poor prognosis groups (Table 24.1)<sup>11</sup>.

For management purposes the extent of tumor spread is conveniently divided into four stages as shown in (Table 24.2)<sup>12</sup>.

## TREATMENT REGIMENS

### Pretreatment preparation of the patient

For all patients who are to have chemotherapy, a full explanation is needed regarding any side-effects both reversible and irreversible, possible complications and actions that may need to be taken, and a description of the routine of the hospital which is being attended regarding undergoing chemotherapy and the facilities that are available to help with consequences of the disease and its treatment. The timing of chemotherapy cycles is important and arrangements and expectations for time off work, support from social services and arrangements for transport to and from the hospital are important.

Standard chemotherapy for testicular tumors consists of four cycles (three cycles for good prognosis groups), each of 5 days at 3-week intervals, of combination treatment using cisplatin, etoposide and bleomycin (BEP). The cisplatin is nephrotoxic and adequate baseline renal function is needed for safe administration, with the dose based on the patient's weight and height. The drug is given intravenously with a crystalloid infusion to maintain good renal perfusion. It can induce significant nausea and vomiting.

In addition cisplatin is neurotoxic and can result in both peripheral neuropathy affecting the fingers and toes,

**Table 24.1** Prognostic classification of testicular germ cell tumors.

<i>Good prognosis group (proportion of patients 56%, 5-year survival 90%)</i>	
	<i>NSGCT</i>
	testis or retroperitoneal primary site
	no non-pulmonary visceral metastases
	AFP <1000 ng/ml, $\beta$ -hCG <5000 IU/l, LDH <1.5 times upper limit of normal
	<i>Seminoma</i>
	any primary site
	no non-pulmonary visceral metastases
	normal AFP, any $\beta$ -hCG, or LDH
<i>Intermediate prognosis group (proportion of patients 28%, 5-year survival 80%)</i>	
	<i>NSGCT</i>
	testis or retroperitoneal primary site
	no non-pulmonary visceral metastases
	any of AFP 1000–10 000 ng/ml, $\beta$ -hCG 5000–50 000 IU/l, or LDH 1.5–10 times upper limit of normal
	<i>Seminoma</i>
	testis or retroperitoneal primary site
	non-pulmonary visceral metastases
	normal AFP, any $\beta$ -hCG, or LDH
<i>Poor prognosis group (Proportion of patients 16%, 5-year survival 50%)</i>	
	<i>NSGCT</i>
	any of the following criteria:
	mediastinal primary site
	non-pulmonary visceral metastases
	AFP >10 000 ng/ml, $\beta$ -hCG >50 000 IU/L, or LDH >10 times upper limit of normal

NSGCT, non-seminomatous germ cell tumor; AFP,  $\alpha$ -fetoprotein;  $\beta$ -hCG,  $\beta$ -human chorionic gonadotropin; LDH, lactate dehydrogenase.

**Table 24.2** Staging classification of testicular germ cell tumors.

<i>Stage</i>	<i>Anatomical extent</i>
Stage I	Tumor confined to the testis. No evidence of distant spread
Stage II	Abdominal lymph node involvement
A	diameter <2 cm
B	diameter 2–5 cm
C	diameter >5 cm
Stage III	Supra- and infradiaphragmatic lymph node involvement
A	diameter <2 cm
B	diameter 2–5 cm
C	diameter >5 cm
Stage IV	Extralymphatic (non-pulmonary) visceral metastases

and ototoxicity causing loss of high frequency hearing. Although often reversible, the recovery process can take up to 2 years. Bleomycin has the rare but fatal complication of progressive pulmonary fibrosis causing irreversible damage to the lung resulting in progressive and ultimately fatal hypoxia. Etoposide can induce marrow suppression resulting in a reduction in the number of white blood cells and platelets. Cases of secondary leukemia have been described. Any sign of infection or abnormal bruising requires prompt attendance at the hospital. Hair loss (alopecia) is usual.

Of particular importance is the effect of the chemotherapeutic agents on the germinal epithelium of the remaining testis. Spermatogenesis is eradicated by the chemotherapy but generally returns to normal after about 12 months. For this reason all patients are offered sperm banking before starting chemotherapy. If for some reason spermatogenesis did not return, *in vitro* fertilization

would be an option for the couple. There is no evidence to suggest that a pregnancy may be abnormal if it occurs while spermatogenesis is undergoing recovery, and so contraception is not required.

Long-term late complications remain an area of investigation but secondary malignancies and cardiovascular disease have both been associated with GCT chemotherapy<sup>13,14</sup>.

For those teratoma patients with abdominal or thoracic metastases, chemotherapy may eradicate them completely. However, where residual masses remain it is usually appropriate to excise them surgically, and informing the patient at an early stage that treatment is a combination of chemotherapy and surgery allows the patient to understand the treatment plan.

## Seminoma

### Stage I

This is a very good prognosis tumor which is sensitive to both radiotherapy and chemotherapy. Studies have looked at placing patients on surveillance following radical orchidectomy but recurrences occur late (up to 2–5 years) necessitating long-term CT-based follow-up. Treatment options include radiotherapy to the abdominal lymph nodes to deal with micrometastases or a single infusion of carboplatin as monotherapy<sup>15</sup>. Following treatment recurrence is very rare.

### Stage II

Although abdominal radiotherapy remains an option, combination cisplatin-based chemotherapy is commonly used.

### Stage III and IV

Full dose combination cisplatin chemotherapy is used.

## Non-seminomatous germ cell tumors

### Stage I

This stage is subdivided into low risk and high risk groups. Peckham *et al.*<sup>16,17</sup> have shown that many patients were cured by radical orchidectomy alone with only 30% of stage I teratoma patients going on to develop relapse after radical orchidectomy. The majority of the relapses occur within the first 12 months and high risk patients demonstrate specific features, in particular

lymphovascular invasion within the testis and have a 50% chance of relapse.

For the high risk group stage I, two cycles of combination cisplatin-based chemotherapy are used.

Patients in the low risk group have a 15–20% chance of relapse and are offered surveillance after the radical orchidectomy. The follow-up is intense and it is important that they have a high level of compliance (see Table 24.3). Previously CT scans were performed twice in each of the first 2 years but now are performed at 3 and 12 only.

### Stages II–IV

Combination cisplatin-based chemotherapy over three or four cycles depending on the prognostic group.

## POSTCHEMOTHERAPY MANAGEMENT

Following successful treatment with chemotherapy a further CT scan is required about 4 weeks later to assess the metastatic disease. In patients with teratoma where residual masses remain (usually >1 cm) surgical excision is required<sup>18</sup>. For patients with seminoma primary tumors, residual masses have been shown to be nearly always necrotic and due to the intense fibrosis that occurs adjacent to them surgical excision is not regarded as necessary or wise.

Surgery for retroperitoneal para-aortic masses requires the patient to be prepared with considerable care. The surgery is usually performed through a long midline abdominal incision or via a thoraco-abdominal incision. Residual masses usually lie adjacent to the aorta and often close to the renal artery. To perform complete excision of these masses it is sometimes necessary to include a nephrectomy to remove the masses en bloc. For this

**Table 24.3** Surveillance follow up regime for low risk stage I NSGCT patients.

Year	Outpatient visit	Tumor markers
1	Monthly	Monthly
2	2 monthly	2 monthly
3	3 monthly	3 monthly
4	6 monthly	6 monthly
5	Annually	Annually
6	Annually	Annually

reason, the patient requires a preoperative intravenous urogram to confirm both kidneys function normally and to help define the location of the para-aortic masses. During the dissection within the standard template along the aorta the sympathetic nerves may be divided which can lead to retrograde ejaculation. The patient needs to be informed of this.

Although pulmonary function tests, including the transfer factor, are often normal in patients following bleomycin chemotherapy, there is evidence that these patients are at a higher risk of developing reduced gas transfer intraoperatively due to either oxygen sensitivity or relative pulmonary edema if over-transfused with crystalloid<sup>19</sup>. Experienced anesthetic support is required for such surgical procedures, together with a high level of postoperative pain control allowing the patient to perform regular pulmonary physiotherapy exercises.

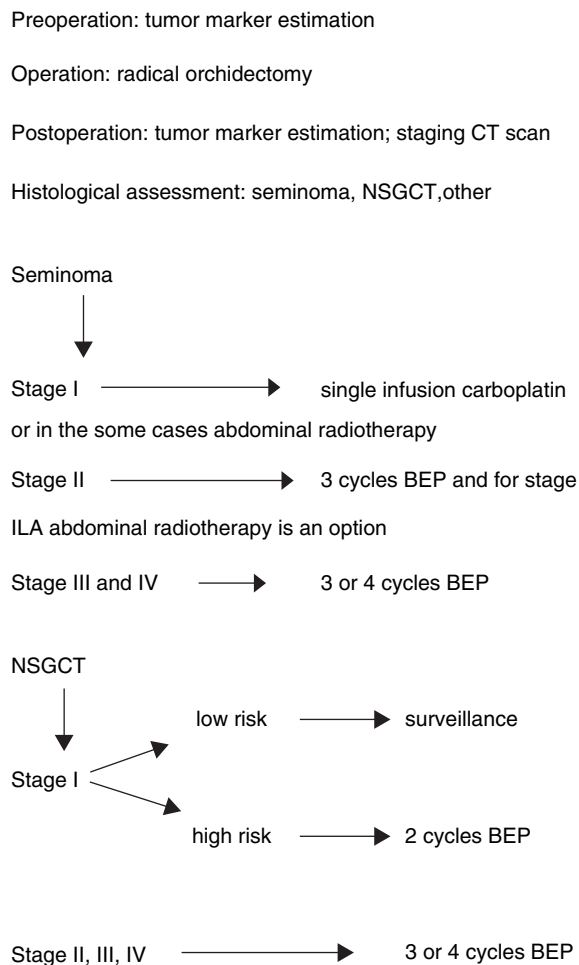
All tissue following such surgery is examined histologically. About 40% of cases show necrotic tissue resulting from tumor death following the chemotherapy. About 40–50% show mature or differentiated teratoma. This tissue has responded to the chemotherapy by differentiating, but has the potential to de-differentiate at a later time. Such tissue may develop back into teratoma or squamous or sarcomatoid differentiation can be seen. It is for this reason that complete excision of residual masses is important. In 10–15%, there is residual malignant teratoma present within the excised mass. Depending on the extent of the disease and the patient's tumor marker status further chemotherapy or surveillance may be recommended<sup>20</sup>.

## POST-TREATMENT FOLLOW-UP AND THE MANAGEMENT OF RELAPSED DISEASE

The intensity of post-treatment follow-up is determined by the prognostic group the patient was in at presentation and how well they have responded to treatment. Most early stage seminoma patients are more at risk of developing a metachronous tumor than relapse from their primary. Late stage seminoma patients equally have a very good prognosis. Early stage teratoma patients on surveillance are monitored for at least the first 6 years. Those patients who have been cured with chemotherapy require a similar follow-up period. Teratoma patients who have required postchemotherapy node dissection will require long-term follow-up and CT scanning if the histology showed differentiated teratoma or active tumor was found.

For patients who develop post-treatment relapse the outcome is less good. Second-line chemotherapy has about a 40% complete remission rate, probably because of the development of multiple drug resistant tumor differentiation<sup>21</sup>. Response to chemotherapy, however, is not always durable and the surgical resection of any residual masses remains an integral part of the patient's management.

The risk of testis tumor patients developing a tumor of the remaining testis is between 2 and 5%. Work by Skakkebaek<sup>22</sup> has shown that histological changes within the testis may precede the development of a clinically evident testis tumor. Such changes are described as testicular intraepithelial neoplasia (TIN) or carcinoma *in situ* (CIS), and have been identified in high risk groups such as men with primary infertility or small atrophic testes. Some research groups believe that a biopsy of the contralateral testis should be performed to exclude TIN



**Figure 24.1** Treatment algorithm for testicular tumors. CT, computed tomography; NSGCT, non-seminomatous germ cell tumor; BEP, cisplatin, etoposide and bleomycin.

at the same time as the radical orchidectomy, although this is not universally supported<sup>23</sup>. The finding of testicular microcalcification on ultrasound scanning was previously thought to be associated with an increased risk of TIN but subsequent research has not supported this<sup>24,25</sup>.

For patients who have been cured and then go on to father children the published evidence shows there is no

increase in fetal or developmental abnormalities in the children<sup>26</sup>.

## TREATMENT ALGORITHM

Figure 24.1 shows the treatment algorithm for testicular tumors.

## REFERENCES

1. Forman D, Oliver RT, Brett AR et al. Familial testicular cancer: a report of the UK family register, estimation of risk and an HLA class 1 sib-pair analysis. *Br J Cancer* 1992; 65: 255–62.
2. Stone JM, Cruickshank DG, Sandeman TF et al. Laterality, maldescent, trauma and other clinical factors in the epidemiology of testis cancer in Victoria, Australia. *Br J Cancer* 1991; 64: 132–8.
3. Pryor JP, Cameron KM, Chilton CP et al. Carcinoma in situ in testicular biopsies from men presenting with infertility. *Br J Urol* 1983; 55: 780–4.
4. Wanderas EH, Fossa SD, Tretli S. Risk of a second germ cell cancer after treatment of a primary germ cell cancer in 2201 Norwegian male patients. *Eur J Cancer* 1997; 33: 244–52.
5. Richie JP. Advances in the diagnosis and treatment of testicular cancer. *Cancer Invest* 1993; 11: 670–5.
6. Azzopardi JG, Hoffbrand AV. Retrogression in testicular seminoma with viable metastases. *J Clin Pathol* 1965; 18: 135–41.
7. Scholz M, Zehender M, Thalmann GN et al. Extragonadal retroperitoneal germ cell tumor: evidence of origin in the testis. *Ann Oncol* 2002; 13: 121–4.
8. Huyghe E, Soulie M, Escourrou G et al. Conservative management of small testicular tumors relative to carcinoma in situ prevalence. *J Urol* 2005; 173: 820–3.
9. Geldart TR, Simmonds PD, Mead GM. Orchidectomy after chemotherapy for patients with metastatic testicular germ cell cancer. *BJU Int* 2002; 90: 451–5.
10. Donohue JP, Zachary JM, Maynard BR. Distribution of nodal metastases in nonseminomatous testis cancer. *J Urol* 1982; 128: 315–20.
11. Schmoll HJ, Souchon R, Krege S et al. European consensus on diagnosis and treatment of germ cell cancer: a report of the European Germ Cell Cancer Consensus Group (EGCCCG). *Ann Oncol* 2004; 15: 1377–99.
12. Horwich A. Testicular cancer. In: Horwich A, ed. *Oncology – a Multidisciplinary Textbook*. London: Chapman and Hall, 1995: 485–98.
13. Huddart RA, Norman A, Shahidi M et al. Cardiovascular disease as a long-term complication of treatment for testicular cancer. *J Clin Oncol* 2003; 21: 1513–23.
14. Zagars GK, Ballo MT, Lee AK, Strom SS. Mortality after cure of testicular seminoma. *J Clin Oncol* 2004; 22: 640–7.
15. Oliver RT, Mason MD, Mead GM et al. Radiotherapy versus single-dose carboplatin in adjuvant treatment of stage I seminoma: a randomised trial. *Lancet* 2005; 366: 293–300.
16. Horwich A, Peckham MJ. Surveillance after orchidectomy for clinical stage I germ-cell tumors of the testis. *Prog Clin Biol Res* 1988; 269: 471–9.
17. Freedman LS, Parkinson MC, Jones WG et al. Histopathology in the prediction of relapse of patients with stage I testicular teratoma treated by orchidectomy alone. *Lancet* 1987; 2: 294–8.
18. Hendry WF, A'Hern RP, Hetherington JW et al. Para-aortic lymphadenectomy after chemotherapy for metastatic non-seminomatous germ cell tumors: prognostic value and therapeutic benefit. *Br J Urol* 1993; 71: 208–13.
19. Donat SM, Levy DA. Bleomycin associated pulmonary toxicity: is perioperative oxygen restriction necessary? *J Urol* 1998; 160: 1347–52.
20. Steyerberg EW, Keizer HJ, Fossa SD et al. Prediction of residual retroperitoneal mass histology after chemotherapy for metastatic nonseminomatous germ cell tumor: multivariate analysis of individual patient data from six study groups. *J Clin Oncol* 1995; 13: 1177–87.
21. Loehrer PJ Sr, Gonin R, Nichols CR et al. Vinblastine plus ifosfamide plus cisplatin as initial salvage therapy in recurrent germ cell tumor. *J Clin Oncol* 1998; 16: 2500–4.
22. Skakkebaek NE. Carcinoma in situ of the testis: frequency and relationship to invasive germ cell tumors in infertile men. *Histopathology* 1978; 2: 157–70.
23. Pamentier B, De Bono JS, Brown IL et al. Bilateral testicular cancer: a preventable problem? Experience from a large cancer centre. *BJU Int* 2003; 92: 43–6.
24. Peterson AC, Bauman JM, Light DE et al. The prevalence of testicular microlithiasis in an asymptomatic population of men 18 to 35 years old. *J Urol* 2001; 166: 2061–4.
25. Fossa SD, Chen J, Schonfeld SJ et al. Risk of contralateral testicular cancer: a population-based study of 29,515 U.S. men. *J Natl Cancer Inst* 2005; 97: 1056–66.
26. Senturia YD, Peckham CS, Peckham MJ. Children fathered by men treated for testicular cancer. *Lancet* 1985; 2: 766–9.



# General principles of gynecological oncology for the general surgeon

25

Robert E Kingston

---

For the purpose of this summary, gynecological cancers can be considered in relation to four main anatomical sites, the vulva, cervix, uterus, and ovary. Cancers of the fallopian tube and primary peritoneal cancers are best regarded, for the purposes of clinical management, as variants of ovarian cancer. Primary cancers of the vagina, which are very uncommon, are broadly treated like cervical cancers when they arise in the upper two-thirds of the vagina, or like vulval cancers arising in the lower third. Gestational trophoblastic neoplasia, although important, is exceedingly rare in Europe, and is not considered further in this review.

## INCIDENCE/PREVALENCE/PREDISPOSING RISK FACTORS

Vulval cancer is uncommon. In the year 2000 there were 996 new cases, and in 2002 there were 364 deaths, in the UK<sup>1</sup>. Vulval cancer is very rare in premenopausal women. Most are squamous cell carcinomas. Most of the remainder comprise melanoma, Paget's disease, Bartholin's gland carcinoma, adenocarcinoma, and basal cell carcinoma. Predisposing factors include vulval intra-epithelial neoplasia (VIN), which is human papillomavirus (HPV) related, and non-neoplastic maturation disorders such as lichen sclerosis (LS)<sup>2</sup>.

In the UK in 2002 there were 2841 new cases of cervical cancer diagnosed. In 2004 there were 1093 deaths. Infection with one of the oncogenic HPV types is a requisite cause, as HPV DNA is found in virtually all cervical cancers. Other risk factors include age at first coitus, number of sexual partners, history of other sexually transmitted diseases, smoking, oral contraceptive use, and parity<sup>3</sup>.

In the UK endometrial cancer is the second most common gynecological cancer, with 5600 new cases per annum and 1135 deaths<sup>1</sup>. Some risk factors are related to ovarian function, such as early age at menarche, late age at menopause, nulliparity, and conditions such as the polycystic ovarian syndrome. Unopposed estrogen replacement

therapy increases the risk, but the combined oral contraceptive pill is protective. A causative relationship between tamoxifen and endometrial cancer has not been established. Obesity, diabetes and hypertension increase the risk. Endometrial cancer is therefore frequently associated with cardiac or vascular disease which when severe may compromise ideal treatment. Endometrial cancer mostly affects women in the postmenopausal age group. Rates vary worldwide and are highest in white women in Western populations. Given its association with age and obesity, current population trends suggest its incidence will continue to increase. A small number of uterine cancers are sarcomas or carcinosarcomas, or uterine serous papillary carcinomas. These are uncommon, poor prognosis variants.

In the UK approximately 6900 women are diagnosed with ovarian cancer each year, and there are 4400 deaths. Among gynecological cancers, ovarian cancer ranks as the leading cause of death, due to an absence of early symptoms and a disproportionate number of late-stage presentations. Most ovarian cancers occur in postmenopausal women. The incidence of ovarian cancer in British women has been steadily increasing for the past 25–30 years from around 15 per 100 000 women in 1975 to around 18 per 100 000 women in 2002, an increase of 20%<sup>1</sup>. Ovarian cancer is a generic term including many histologically individual neoplasms, grouped as epithelial, germ cell, stromal, or secondary tumors. The germ cell group includes cancers which morphologically and clinically are identical to their testicular counterparts. The majority of ovarian cancers are epithelial, and these are considered further in this chapter. The etiology of ovarian cancer remains speculative.

## PRESENTATION

Vulval cancer usually presents symptomatically, with vulval pain, bleeding, or pruritus. On clinical examination 90% have a visible lump. A history of vulval cancer is a risk factor for the development of cervical cancer, and vice versa.



Cancer of the cervix presents clinically with persistent postcoital bleeding, postmenopausal bleeding (PMB), or persistent infective vaginal discharge. More advanced disease may present with lower abdominal or pelvic pain often radiating to the low back, disturbances of bowel habit or micturition, sometimes associated with lower limb lymphedema or thromboembolism. Very late presentations with malignant urinary or fecal fistula, or obstructive uropathy, are rare in modern UK practice. Some invasive cervical cancers are identified via the screening process when they are often microinvasive and non-symptomatic.

Endometrial cancers classically present with PMB. Approximately 7–10% of cases of PMB will prove to be neoplastic in origin<sup>4</sup>. The likelihood of cancer is not proportional to the severity of the symptoms, and any patient who experiences such an episode, irrespective of how trivial, should be referred for further investigation.

The presentation of ovarian cancer is notoriously vague, and tends to arise insidiously in the guise of a gastroenterological problem, with implications for delayed diagnosis. This is probably the most important single interface between gynecological oncology and general surgery. Specific gynecological symptoms are unusual, and the condition is much more likely to present with a gradual history over a few months of vague abdominal distension, alteration of bowel habit, abdominal pain, or anorexia. New onset of features of irritable bowel syndrome in a middle-aged or postmenopausal woman should prompt investigation of organic causes, including ovarian cancer.

## SCREENING

There is no screening test for vulval cancer available for the well woman population. Patients Presenting symptomatically with VIN should receive appropriate local treatment and be followed up in a vulvoscopy clinic. Patients who are found to have LS are usually treated medically, and are then discharged back to primary care. Because LS is relatively common it is not practical to maintain long-term follow-up for all patients, but patients should be encouraged to return for review in the event of new symptoms or signs<sup>5</sup>.

Screening for cervical cancer by exfoliative cytology has been available for over 60 years. In 1988 the UK moved from a policy of haphazard opportunistic screening to call and recall screening of the well woman female population between the ages of 20 and 65. Since then there has been a significant fall in the incidence and mortality of invasive cervical cancer, most noticeably in younger women, in whom there had been a three-fold rising mortality trend in the preceding 20 years. Although there is not complete consensus on the success of cervical cancer screening,

evidence suggests that the most intensively screened cohorts show the biggest drop in mortality, and epidemiological analysis suggests that approximately 4500 deaths are currently being prevented per year in the UK, with birth cohort trends suggesting that the death rate throughout life is lower in women first screened when they were younger<sup>6</sup>. Cytology screening has evolved from glass slide preparations to liquid-based techniques, which sample the cellular preparation much more efficiently, resulting in fewer inadequate samples. Exfoliative screening identifying carcinogenic HPV is being evaluated as an adjunct or replacement for the traditional Papanicolaou cytological technique<sup>7</sup>. Immunosuppressed women should undergo more frequent screening than the general population. Primary prevention of cervical cancer is now a practical possibility with the advent of prophylactic HPV vaccines<sup>8</sup>.

There is currently no well woman screening program for endometrial cancer. However, patients from hereditary non-polyposis colonic cancer (HNPCC) families who may have a high genetic predisposition to numerous neoplasms, including endometrial cancer, may be offered endometrial testing in the form of diagnostic hysteroscopy if they are premenopausal or transvaginal scanning postmenopausally. Gene carriers of HNPCC should report to the doctor any abnormal vaginal bleeding.

Similarly, there is currently no national screening program for cancer of the ovary. The value of well woman screening is currently the subject of a large UK prospective trial investigating the combination of ultrasound and estimation of the tumor marker CA125. Patients from ovarian or breast-ovarian cancer families account for 5–10% of the ovarian cancer population. They may be at significantly elevated risk for contracting the disease and may therefore be offered screening, or prophylactic oophorectomy if they have completed their families<sup>9</sup>.

## DIAGNOSTIC STRATEGIES

Patients who present with vulval symptoms may be initially treated by a policy of treat, watch and wait in primary care. Specialist referral should be made if symptoms persist for more than a few weeks. For an unexplained vulval lump, referral should be urgent. Viral warts are rare in postmenopausal women and should be biopsied. Biopsy confirmation is always required to establish the diagnosis of cancer. If multifocal disease is suspected, a mapping procedure, utilizing multiple vulvoscopically directed diagnostic biopsies, may be advisable.

Cervical cancer may be suspected from symptoms, or an abnormal looking cervix on speculum examination. A smear test is not required, and a previous negative result should not delay referral. Colposcopy may be helpful in

making the assessment, but it should be remembered that small punch biopsies are often superficial, and may under-diagnose invasive cancer. If in doubt, loop diathermy excision or a cone biopsy is carried out to provide a specimen which can be easily orientated by the pathologist, and where stromal invasion can be confidently assessed.

Endometrial cancer is normally confirmed following diagnostic assessment of PMB. Currently, the first-line investigation is transvaginal ultrasound. Current consensus identifies a cut-off point at 4 mm endometrial thickness. Endometrial thickness below this level is associated with probability of cancer of about 1% or less<sup>10</sup>. No further investigation is required. In the presence of ultrasound findings outside these limits, or where there are persisting symptoms, an immediate aspiration biopsy of the endometrium can be undertaken in the clinic, or if necessary the patient may be referred for urgent hysteroscopy. Very occasionally, in spite of this level of investigation, small endometrial cancers may still be missed, and persistent PMB of unknown cause may on occasions justify diagnostic hysterectomy.

Patients presenting with symptoms or signs suggestive of ovarian cancer should have abdominopelvic imaging. Ultrasound is often more convenient and is the investigation of choice for ovarian morphology, but computed tomography (CT) scanning is an appropriate alternative. Where imaging confirms a suspicion of ovarian cancer, the serum CA125 should be measured, and risk of malignancy index (RMI) calculated<sup>11</sup>. The RMI is calculated as  $U \times M \times CA125$ , where U is the ultrasound score, and scores 0 for an ultrasound score of zero, 1 for a score of 1, and 3 for a score of 2–5. Ultrasound scans are scored one point for each of the following characteristics, multilocular cyst, evidence of solid areas, evidence of metastases, presence of ascites, and bilateral lesions. The menopause score is 1 for premenopausal patients and 3 for postmenopausal. An RMI of greater than 200 suggests a 75–87% risk of ovarian cancer being present<sup>12</sup>. The patient should be referred to a network gynecological oncology center for further management. It should be remembered, however, that this test, although helpful, is not perfect. As well as underdiagnosing ovarian cancer, false positive results may occur with numerous non-gynecological conditions, including diverticular abscess, and carcinomas of the pancreas, cecum and rectum. The test should always be interpreted in the context of the clinical presentation.

## STAGING

The staging systems for gynecological cancers are defined by the International Federation of Gynecology and Obstetrics (FIGO), and are based on the characteristic spread patterns of each cancer<sup>13</sup>.

Vulval cancer spreads by direct extension to adjacent structures, including the anus, the rectum, and lower urinary tract, and by nodal metastasis, usually to the regional lymph nodes in the groin followed in untreated cases by iliac and para-aortic nodal disease.

Cervical cancer spreads by direct extension to adjacent structures, including the bladder, terminal ureter and the cardinal ligaments to the pelvic side wall. Increasing volume of the primary tumor is closely correlated with nodal metastases, usually to the regional lymph nodes in the pelvis. This is followed by more distant para-aortic nodal disease.

Endometrial cancer spreads by direct extension to the cervix and para-uterine connective tissues, the regional pelvic and para-aortic lymph nodes, the ovaries, and transcelomic spread to the peritoneal surfaces and omentum.

Ovarian cancer spreads by direct extension to other pelvic organs, transcelomic spread to the peritoneal surfaces and omentum, and metastasis to the pelvic and para-aortic lymph nodes. Malignant ascites is a common presenting feature with malignant pleural effusions less so.

For all the common gynecological cancers, hematogenous spread is an uncommon and late manifestation, the lungs being the most likely to be affected. Bony metastases are rare, and are most likely to occur via direct infiltration from adjacent soft tissue disease.

## SURGERY FOR CURE

Gynecological cancers often require complex multimodality treatment decisions, and the management of every patient should be discussed by the multidisciplinary team.

The treatment of vulval cancer is primarily surgical, and is based on the principle of radical extension of the primary lesion, backed up by groin lymphadenectomy in selected cases. More conservative and individualized treatment is possible in stage 1 presentations. With proper attention to staging and preoperative evaluation, radical vulvectomy and bilateral groin node dissection, with its associated physical and psychological morbidity, is often avoidable, whilst the intent remains curative. Stage 1a lesions, which are less than 2 cm and in diameter and confined to the vulva with stromal invasion of 1 mm or less, can be safely managed by radical local excision only because the risk of nodal metastases is exceedingly low<sup>14</sup>. Small cancers which are well lateralized on the vulva may be managed in the first instance by radical local excision and ipsilateral groin dissection only<sup>15</sup>, although subsequent treatment of the other groin may prove necessary if nodal metastases are confirmed in the first specimen. Radical excision should aim for a minimum margin of 10 mm of disease-free tissue in all planes around the lesion<sup>16</sup>. The reliability of more conservative groin node management is currently

being addressed, using sentinel node identification techniques with dye and technetium, or groin node ultrasound and fine needle aspiration cytology<sup>17</sup>.

Early stage cancer of the cervix is treated surgically. Microinvasive, stage 1a, cancers may be treated by local excision biopsy of the cervix itself, often by outpatient loop diathermy excision under local anesthetic. Overt stage 1 (stage 1b) carcinomas of the cervix are classically treated by radical hysterectomy, in the course of which the pelvic ureters are fully dissected and mobilized to allow removal of a wide cuff of paracervical tissue. A systematic pelvic lymphadenectomy is also undertaken<sup>18</sup>. In recent years radical trachelectomy<sup>19</sup> has become available for nulliparous patients with small stage 1 cancers as a fertility conserving option. In this operation radical excision of the cervix and paracervical tissue is undertaken vaginally, at the conclusion of which a permanent cerclage suture is placed at the conserved uterine isthmus to prevent cervical incompetence complicating subsequent pregnancies. Lymphadenectomy is also carried out, usually laparoscopically<sup>20</sup>. Results to date are encouraging. No reduction in survival is seen and high fertility rates can be maintained. Although this operation will not supplant radical hysterectomy as a definitive procedure, it is now being recommended with increasing confidence for very carefully selected patients.

Exenterative surgery is recommended with curative intent for selected patients with isolated central pelvic recurrences following radical pelvic radiotherapy for cervical cancer. The surgery is individualized according to the precise presentation of the recurrent disease. The most usual variation is a radical excision of the uterus and upper vagina together with the bladder, followed by the formation of an ileal conduit, or a continent urinary diversion. Less frequently a rectosigmoid resection will be required to effect adequate margins posteriorly, and in some cases a perineal as well as an abdominal dissection is required. These operations carry considerable risk, with an immediate 3% operative mortality, but are justified by long-term remission rates of 30–50% in properly selected patients<sup>21</sup>.

In endometrial cancer, primary surgery is the preferred modality for stage 1 and 2 disease<sup>22</sup>, and may be appropriate for local control of more advanced disease, assuming the uterus is mobile on clinical examination and the patient is fit for operation. The precise extent of surgery is more controversial. The procedure in all cases should include assessment of the peritoneal cavity, washings for cytology, total abdominal hysterectomy, and bilateral salpingo-oophorectomy. Recently published randomized trial data<sup>23</sup> suggest that therapeutic lymphadenectomy is not advantageous for survival, but knowledge of the node status may be helpful in planning postoperative adjuvant therapy. Laparoscopically assisted vaginal hysterectomy is

becoming an increasingly popular alternative to the traditional open operation and is of benefit in this cancer population with its extensive associated co-morbidity. In patients where there are particular concerns regarding postoperative complications, simple vaginal hysterectomy may be an appropriate compromise<sup>24</sup>.

Cancer of the ovary is usually suspected preoperatively but often only finally diagnosed at laparotomy. The indications for primary surgery for ovarian cancer are establishment of the diagnosis, surgical staging and primary cytoreduction (debulking). The current clinical consensus is based on the concept of radical cytoreductive surgery. This followed the observation that patients with minimal or no residual disease after primary surgery had a better survival than those with gross residual disease. Although some question the evidence to support the use of radical surgery, and it remains debatable whether the survival figures are consequent on the completeness of the surgery or the inherent biology of the tumor, there is no doubt that surgery plays a central role in the management of ovarian cancer<sup>25</sup>. An adequate staging laparotomy should be carried out through a vertical incision, peritoneal washings or ascites if present should be sent for cytology, and the abdominal contents and retroperitoneal spaces should then be carefully and systematically examined. Standard primary surgery comprises total abdominal hysterectomy, bilateral salpingo-oophorectomy, omentectomy, and tumor debulking. Complete debulking of all macroscopic disease is desirable<sup>26</sup>. Optimal debulking to tumor deposits of 1 cm or less in diameter is an appropriate surgical endpoint if total excision of the tumor masses is not possible. Systematic retroperitoneal lymphadenectomy is now known not to provide a survival advantage<sup>27</sup>, but examination and selective biopsy of the retroperitoneal nodes is important for the staging assessment.

When primary cytoreduction is likely to be unsuccessful, immediate chemotherapy may be considered with the option of interval debulking surgery half way through the chemotherapy program, and the definitive place of this strategy is currently being addressed by clinical trials<sup>28</sup>.

## PALLIATIVE SURGERY

Palliative surgery may be employed in recurrent and metastatic gynecological cancer to excise symptomatic tumor nodules from the vagina and vulva, and for symptomatic groin nodes if they are not deeply fixed. It may be reasonable to consider more aggressive palliation such as hysterectomy for bleeding or malignant discharge, even if extending remission is not a realistic possibility, as long as the patient is fit for the procedure and has a clear understanding of its limitations. Malignant fistulas, rectovaginal and

vesicovaginal, are associated with extremely distressing symptoms, and surgical treatment may be appropriate even in the terminally ill patient with limited life expectancy, as long as she remains fit for the operation. Correction of the symptoms is often almost instantaneous and transforms the quality of the patient's remaining life. Simple diversions into stomas are usually appropriate under these circumstances. Surgery to relieve intestinal obstruction may be considered in the palliative setting, but the most frequent presentation gynecologically is in association with progressive ovarian cancer. Obstruction under these circumstances is often at multiple sites, and is frequently associated with extensive malignant infiltration and fixation of the mesentery. Surgical correction is therefore difficult, and, balancing prolonged postoperative recovery against limited life expectancy, conservative management of the obstruction may be more appropriate<sup>29</sup>.

## ADJUVANT RADIOTHERAPY

As well as adjuvant radiation, it is important to note that within the field of gynecological cancer there are indications for primary radical radiotherapy with curative intent. For instance, for patients with early stage cervical cancers either radical radiotherapy or radical hysterectomy are equally effective treatments, and although surgery is usually preferable, decisions regarding the most appropriate treatment will be finalized on the likely morbidity from each modality. More advanced cervical cancers carry a more guarded prognosis, but curative radiation-based treatment remains appropriate. Patients with bulky stage 1B and 2A disease and stages 2b–4 are treated with a radical course of radiotherapy consisting of external beam followed by intracavitary treatment. Chemoradiation utilizing concurrent weekly cisplatin chemotherapy is now recommended in all patients with good performance status with bulky or locally advanced cervical cancer<sup>30</sup>. Meta-analysis<sup>31</sup> has demonstrated both an improvement in overall survival and also improved local and distant control rates. The acute and late morbidity is greater with concurrent chemotherapy.

Chemoradiation has also received considerable interest in regard to vulval cancer but has never been compared with radiation alone in the preoperative setting. Unlike anal carcinoma, there is currently insufficient evidence to advocate chemoradiation as the sole treatment of vulval cancer. Morbidity is considerable. Ideal patients are those who are young and fit with large tumors where surgery would need to be exenterative<sup>32</sup>. Patients who have a partial response to chemoradiation resulting in downstaging of the tumor may be suitable for sphincter-saving adjuvant surgery<sup>33</sup>.

Some endometrial carcinoma patients who are deemed unfit for surgery may be treated with radiotherapy alone. With radical radiotherapy local control rates are high in patients with stage 1 and 2 disease<sup>34</sup>.

Postoperative adjuvant radiotherapy is used in cervical, vulval and endometrial cancer, and has been extensively researched in the last, where prospective trial data<sup>35</sup> indicate that it is useful for local control, but has no effect on overall survival. Retrospective data for cervical cancer suggest a similar conclusion<sup>36</sup>.

In vulval cancer patients with positive nodes after radical surgery, adjuvant radiotherapy significantly improves survival. Trial data show significant improvement in survival for radiotherapy compared with extended surgery<sup>37</sup>.

Postoperative radiotherapy is not routinely used in ovarian cancer, but may be occasionally indicated to treat the pelvis postoperatively in stage 2 disease where small volume disease remains in the pelvis.

## ADJUVANT CHEMOTHERAPY

Cytotoxic chemotherapy is not regarded as standard treatment in the management of vulval cancers but can be used in otherwise fit patients with metastatic disease. The drugs used most extensively have been 5-fluorouracil (5-FU) usually as a single agent, cisplatin, or mitomycin C. The response rate to chemotherapy is low and the duration of response of the order of 3–6 months.

Cervical cancer chemotherapy with drugs including mitomycin C, cisplatin, 5-FU, and bleomycin has been employed in the management of advanced disease for several years<sup>38</sup>. The most active drug is cisplatin, which therefore restricts the eligible patient group to those without renal impairment. There is little evidence in favor of the activity of carboplatin. Problems such as prior radiation treatment, extensive surgical procedures and often poor general performance status in elderly patients have contributed to the low expectation of efficacy of this modality in the past.

In early ovarian cancer, trials have confirmed the survival gain of adjuvant chemotherapy. The combined data<sup>39</sup> have effectively shown an 8% survival benefit at 6 years in favor of adjuvant platinum-based chemotherapy, and a meta-analysis with two additional trials showed an overall hazard ratio of 0.72 in favor of adjuvant chemotherapy. The benefits of the treatment have to be viewed against the good survival of the overall group following surgery alone (80% at 10 years). Degree of differentiation is the most powerful prognostic indicator in stage I ovarian cancer. In stage 1a and 1b grade 1 tumors, where the risk of relapse is slight, an observation policy may be appropriate.

The choice of treatment should be made after the woman and her doctor have discussed the potential risks and benefits of the treatment options available, but there is general agreement that this should be platinum based.

For patients with advanced ovarian cancer who are medically fit, the combination of a platinum compound and paclitaxel is considered the standard first-line chemotherapy<sup>40</sup>. The platinum agents remain the most effective in the treatment of this disease, with a survival benefit estimated at 6 months to 2 years, and some evidence that this benefit is greater in stage III than in stage IV patients.

Overall survival of 40% at 5 years can be expected in stages II–IV. Other randomized trials, however, have shown that there is no advantage to the addition of paclitaxel over single agent platinum. The National Institute for Clinical Excellence (NICE) guidelines (January 2003) quote meta-analysis data carried out both by the Medical Research Council (MRC) and industry, which show a non-significant disease-free benefit for the paclitaxel/platinum combination, but a hazard ratio of 1.0 for survival in advanced disease (stages III/IV) population<sup>41</sup>.

Route of administration is being recognized as an important prognostic criterion, and intraperitoneal chemotherapy is now advocated as appropriate for patients with advanced ovarian cancer who have had optimal surgical cytoreduction<sup>42</sup>.

The benefits of alkylating agents (e.g. chlorambucil or cyclophosphamide) have been recognized for over 40 years in terms of producing a response rate in advanced disease, and while category A evidence of a survival benefit is lacking, they have now become useful second-line agents, particularly in elderly patients or those intolerant of parenteral therapy.

## PALLIATIVE CHEMORADIO THERAPY

Palliative radiotherapy is considered for vulval and cervical cancer patients with advanced, recurrent, or metastatic cancer, or for unfit patients with any stage of disease. Palliative local radiotherapy is particularly effective for bleeding, discharge, or pain. Depending on the performance status of the patient external beam or intracavitary or combinations of both can be used.

For the palliation of ovarian cancer, patients who relapse more than 6 months after platinum response may benefit from a further trial of the same drug in the first instance. Where there is a platinum-free interval of 12 months or more, it may be appropriate to offer combined treatment (paclitaxel and carboplatin) to this patient group. Retreatment with paclitaxel is associated with a 20% incidence of grade 3/4 neuropathy. Patients who relapse within 6 months of completing platinum-based chemotherapy have a low probability of response.

Liposomal doxorubicin or topotecan may be considered as options for the second-line (or subsequent) treatment of women with advanced ovarian cancer, but response rates are modest.

High dose progestogens can be used successfully to palliate advanced and recurrent endometrial cancer, but available evidence does not show that there is a role for the use of hormones in early stage disease<sup>43</sup>. In advanced or recurrent disease up to 30% of patients may respond to hormonal therapy.

## PALLIATIVE CARE

Palliative care issues in gynecological cancer are complex, and are best considered as a component of symptomatic and supportive care which begins at diagnosis and continues through all the milestones of the disease. Even for patients who have been fully cured there may be intense psychosexual issues which necessitate years of support. Input from highly trained specialist nurses is a vital component of this aspect of the clinical service, and there are advantages in utilizing an organizational model which combines the gynecological nurse specialist and palliative care functions, to enable seamless continuity of care from diagnosis to death<sup>44</sup>. A palliative care physician should be a member of the core multidisciplinary team and be encouraged to advise on matters of symptomatic and supportive management from diagnosis onwards.

Characteristic problems requiring conservative palliative care input in the terminal phase are pain, nausea, vomiting, dehydration, thromboembolism, and bowel obstruction and fistula unsuitable for surgical correction. One specific problem, which poses clinical and ethical dilemmas, is the management of bilateral obstructive uropathy in the gynecological cancer patient. Where there remain options for actively treating the cancer, the condition should be aggressively corrected prior to instituting appropriate treatment aimed at establishing remission. However, in the terminally ill patient with progressive cancer whose active treatment is no longer possible, a non-interventional policy may be more appropriate, since the traumatic experience of the intervention is highly unlikely to be outweighed by improvement in the patient's remaining quality of life<sup>45</sup>.

## OUTCOMES

Stage for stage, survival outcomes for the common gynecological cancers are broadly similar<sup>13</sup>, with 5-year survival of 77–93% for stage 1, 55–79% for stage 2, 29–52% for stage 3, and 13–19% for stage 4. Overall survival for ovarian cancer is much poorer because of the excessive

number of late stage presentations, and in cases of disease presenting with large volume metastases to the general peritoneal cavity (stage 3c) 5-year survival is approximately 30%. Lymph node status is a powerful prognostic indicator for cervical and vulvar cancer, and stage 1 node negative disease is associated with overall 5-year survival of 87–98% and 77%, respectively. Node negative cervical cancer (all stages) is associated with 5-year survival of 88%, dropping to 60% when there is node positivity. Other specific 5-year survival outcomes of importance include stage 2b cervical cancer treated by chemoradiation

(64%) and stage 1 endometrial cancer treated by surgery plus or minus postoperative radiotherapy (88%). For endometrial cancer patients unfit for surgery who are treated by primary radiotherapy, 5-year disease-specific survival rates are reported as 70% in patients with stage I/II disease and 33% in stage III/IV disease. However, 5-year overall survival rates in these patients are generally only 30–50% as a consequence of their medical problems.

For all the common gynecological cancers the long-term attrition rate is low, and 5-year survival can be assumed to approximate to the eventual cure rate.

## REFERENCES

1. Cancer Research UK. Cancer Statistics: 2006 [www.info.cancer-researchuk.org](http://www.info.cancer-researchuk.org).
2. Fox H, Wells M. Recent advances in the pathology of the vulva. *Histopathology* 2003; 42: 209–16.
3. Kirwan MJ, Herrington CS. Human papillomavirus and cervical cancer: where are we now? *Br J Obstet Gynaecol* 2001; 108: 1204–13.
4. Gredmark T, Kvint S, Havel G, Mattson LA. Histopathological findings in women with postmenopausal bleeding. *Br J Obstet Gynaecol* 1995; 102: 133–6.
5. RCOG working party. Clinical Recommendations for the Management of Vulvar Cancer. London: Royal College of Obstetricians and Gynaecologists, 1999.
6. Peto J, Gilham C, Fletcher O, Matthews FE. The cervical cancer epidemic that screening has prevented in the UK. *Lancet* 2004; 364: 249–56.
7. Cuzick J, Beverley E, Ho L et al. HPV testing in primary screening of older women. *Br J Cancer* 1999; 81: 554–8.
8. Tjalma WAA, Arbyn M, Paavonen J et al. Prophylactic human papillomavirus vaccines: the beginning of the end of cervical cancer. *Int J Gynecol Cancer* 2004; 14: 751–61.
9. Menon U, Jacobs IJ. Recent developments in ovarian cancer screening. *Curr Opin Obstet Gynecol* 2000; 12: 39–42.
10. Gull B, Carlsson S, Karlsson B et al. Transvaginal ultrasonography of the endometrium in women with postmenopausal bleeding. *Am J Obstet Gynecol* 2000; 182: 509–15.
11. Manjunath AP, Pratapkumar SK, Vani R. Comparison of three risk of malignancy indices in evaluation of pelvic masses. *Gynecol Oncol* 2001; 81: 225–9.
12. Bailey J, Tailor A, Naik R et al. Risk of malignancy index for referral of ovarian cancer cases to a tertiary center: does it identify the correct cases? *Int J Gynecol Cancer* 2006; 16: 30–4.
13. FIGO (International Federation of Gynecology and Obstetrics) annual report on the results of treatment in gynecological cancer. *Int J Gynecol Obstet* 2003; 83 (Suppl 1): 1–229.
14. Sedlis A, Homesley H, Bundy BN et al. Positive groin nodes in superficial squamous cell vulvar cancer. *Am J Obstet Gynecol* 1987; 156: 1159–64.
15. Stehman FB, Bundy BN, Dvoretzky PM, Creasman WT. Early stage 1 carcinoma of the vulva treated with ipsilateral superficial inguinal lymphadenectomy and modified radical hemivulvectomy. *Obstet Gynecol* 1992; 79: 490–7.
16. Hacker NF, van der Velden J. Conservative management of early vulvar cancer. *Cancer* 1993; 71: 1673–7.
17. Dhar KK, Woolas RP. Lymphatic mapping and sentinel node biopsy in early vulvar cancer. *Br J Obstet Gynaecol* 2005; 112: 696–702.
18. Shepherd JH. Cervical cancer: the surgical management of early stage disease. In: Shepherd JH, Monaghan JM, eds. *Clinical Gynaecological Oncology*, 2nd edn. Oxford: Blackwell Scientific Publications, 1990: 64–97.
19. Plante M, Renaud MC, Francois H, Roy M. Vaginal radical trachelectomy: an oncologically safe fertility-preserving surgery. An updated series of 72 cases and review of the literature *Gynecol Oncol* 2004; 94: 611–3.
20. Childers JM. The virtues and pitfalls of minimally invasive surgery for gynecological malignancies: an update. *Curr Opin Obstet Gynecol* 1999; 11: 51–9.
21. Robertson G, Lopes A, Beynon G, Monaghan JM. Pelvic exenteration: a review of the Gateshead experience 1974–1992. *Br J Obstet Gynaecol* 1994; 101: 529–31.
22. Creasman WT, Morrow CP, Bundy BN et al. Surgical pathologic spread patterns of endometrial cancer. *Cancer* 1987; 60: 2035–41.
23. Kitchener H, on behalf of the ASTEC study group. ASTEC – a study of the treatment of endometrial carcinoma. *Gynecol Oncol* 2006; 101 (Suppl 1): 21–2.
24. Chan JK, Lin YG, Monk BJ et al. Vaginal hysterectomy as primary treatment of endometrial cancer in medically compromised women. *Obstet Gynecol* 2001; 97: 707–11.
25. van der Burg MEL. Advanced ovarian cancer. *Curr Treat Options Oncol* 2001; 2: 109–18.
26. Hacker N. Surgical management of advanced ovarian cancer. In: Lawton FG, Neijt JP, Swenerton KD, eds. *Epithelial Cancer of the Ovary*. London: BMJ Publishing Group, 1995: 144–71.
27. Panici PB, Maggioni A, Hacker N et al. Systematic aortic and pelvic lymphadenectomy versus resection of bulky nodes only in optimally debulked advanced ovarian cancer: a randomized clinical trial. *J Natl Cancer Inst* 2005; 97: 560–6.
28. Van der Burg MEL, Coens C, van Lent M et al. After ten years follow-up interval debulking surgery remains a significant prognostic factor for survival and progression free survival for advanced ovarian cancer. *Int J Gynecol Cancer* 2004; 14 (Suppl 1): 3.
29. Ripamonti C, Twycross R, Baines M et al. Clinical-practice recommendations for the management of bowel obstruction in patients with end-stage cancer. *Support Care Cancer* 2001; 9: 223–33.
30. Rose PG, Bundy BN, Watkins EB et al. Concurrent cisplatin-based radiotherapy and chemotherapy for locally advanced cervical cancer. *N Engl J Med* 1999; 340: 1144–53.

31. Green JA, Kirwan JM, Tierney JF et al. Survival and recurrence after concomitant chemotherapy and radiotherapy for cancer of the uterine cervix: a systemic review and meta-analysis. *Lancet* 2001; 358: 781–6.
32. Moore D, Thomas G, Montana G. Preoperative chemoradiation for advanced vulvar cancer: a phase II study of the Gynaecologic Oncology group. *Int J Radiat Oncol Biol Phys* 1998; 42: 79–85.
33. Rotmensch J, Rubin SJ, Sutton HG et al. Pre-operative radiotherapy followed by radical vulvectomy with inguinal lymphadenectomy for advanced vulvar carcinomas. *Gynecol Oncol* 1990; 36: 181–4.
34. Churn M, Jones B. Primary radiotherapy for carcinoma of the endometrium using external beam radiotherapy and single line source brachytherapy. *Clin Oncol (R Coll Radiol)* 1999; 11: 255–62.
35. Scholten AN, van-Putten WLJ, Beerman H et al. Postoperative radiotherapy for Stage 1 endometrial carcinoma: long-term outcome of the randomized PORTEC trial with central pathology review. *Int J Radiat Oncol Biol Phys* 2005; 63: 834–8.
36. Thomas GM. Adjuvant therapy after primary surgery for stage I-IIA carcinoma of the cervix. *J Natl Cancer Inst Monogr* 1996; 21: 77–83.
37. Homsley HD, Bundy LN, Sedlis A, Adcock L. Radiation therapy versus pelvic node resection for carcinoma of the vulva with positive groin nodes. *Obstet Gynecol* 1986; 68: 733–40.
38. Smith HO, Stringer CA, Kavanagh JJ et al. Treatment of advanced or recurrent squamous cell carcinoma of the uterine cervix with mitomycin-C, bleomycin and cisplatin chemotherapy. *Gynecol Oncol* 1993; 48: 11–5.
39. Trimbos JB, Parmar M, Guthrie D et al. International collaboration ovarian neoplasm trial 1 and adjuvant chemotherapy in ovarian neoplasm trial: two parallel randomized phase III trials of adjuvant chemotherapy in patients with early-stage ovarian carcinoma. *J Natl Cancer Inst* 2003; 95: 105–12.
40. Piccart MJ, Bertelsen K, James K et al. Randomized intergroup trial of cisplatin–paclitaxel versus cisplatin–cyclophosphamide in women with advanced epithelial ovarian cancer: three-year results. *J Natl Cancer Inst* 2000; 92: 699–708.
41. Guidance on the use of paclitaxel in the treatment of ovarian cancer. Technology appraisal guidance no. 55. London: National Institute for Clinical Excellence. [www.nice.org.uk](http://www.nice.org.uk) 2003.
42. Armstrong DK, Bundy B, Wenzel L et al. Intraperitoneal cisplatin and paclitaxel in ovarian cancer. *N Engl J Med* 2006; 354: 34–43.
43. COSA-NZ-UK Endometrial Cancer Study Group. Adjuvant medroxyprogesterone acetate in high-risk endometrial cancer. *Int J Gynecol Cancer* 1998; 8: 387–91.
44. Skilbeck J, Corner J, Bath P et al. Clinical Nurse specialists in palliative care. *Palliat Med* 2002; 16: 285–96.
45. Harrington KJ, Pandha HS, Kelly SA et al. Palliation of obstructive nephropathy due to malignancy. *Br J Urol* 1995; 76: 101–7.

# Squamous cell carcinoma and basal cell carcinoma of the skin

26

J J Bonenkamp

---

## INCIDENCE/PREVALENCE

Skin cancers are typically divided into melanoma and non-melanoma skin cancers. Non-melanoma skin cancers, mainly basal cell carcinoma and squamous cell carcinoma, are the most common human malignancies. Squamous cell carcinoma can originate in virtually any organ and etiology and pathogenesis vary accordingly. Squamous cell carcinoma of the skin originates in the superficial cells of the stratum germinativum of the skin, which consists of a stratum basale and a stratum spinosum. It is composed of keratinocytes, which can be more or less differentiated. Often used synonyms for squamous cell carcinoma are spinocellular carcinoma and spinolioma. Basal cell carcinoma originates in the basal layers of the epidermis. This tumor behaves locally aggressive and sometimes invasive, but its metastatic potential is low. It is sometimes inappropriately called epithelioma because of this non-aggressive behavior.

It is often stated that basal cell carcinomas are more common than squamous cell carcinomas, but this is partly a matter of definition. If premalignant lesions (mainly Bowen's disease and actinic keratosis) are included in the definition, the incidence of squamous cell carcinoma might be much higher than that of basal cell carcinoma<sup>1</sup>. The main argument to do so is the fact that the distinction between actinic keratosis and squamous cell carcinoma is difficult. Furthermore, in the majority of squamous cell carcinomas, adjacent areas of actinic keratosis are found. Both share the etiology of excessive sun exposure and both lesions are identical under the microscope. It is therefore plausible to regard actinic keratosis as a precursor of squamous cell carcinoma. In fact, more than 60% of squamous cell carcinomas will develop out of actinic keratosis<sup>1</sup>. However, in spite of the similarities between actinic keratosis and squamous cell carcinoma, it is not justifiable to group them together. First and most importantly,

most actinic keratosis will never develop into squamous cell carcinoma<sup>2</sup>. The incidence that this will happen is estimated to be between 0.1 and 10%<sup>3</sup>. Second, the practical implications would be enormous. Most actinic keratoses are treated by non-invasive, locally destructive methods (coagulation, freezing, simple scraping off), whereas proven squamous cell carcinomas require resection, cryosurgery, or radiation therapy. If pathologists were to express doubt over the malignant potential of actinic keratosis, it is likely that this would result in overtreatment.

Most non-melanoma skin cancers will grow slowly and not behave aggressively, and a substantial number of these will not even be presented to a doctor. Precise incidence rates for squamous cell carcinoma and basal cell carcinoma are therefore difficult to obtain. Moreover, most countries do not register skin cancers separately in their cancer statistics, and if they do so usually basal cell carcinoma and squamous cell carcinoma are grouped together. Not surprisingly, the World Health Organization (WHO) reports age-adjusted incidence rates varying from 1.1 per 100 000 inhabitants in the USA Michigan region to 95 per 100 000 inhabitants in the Oxford region in the UK, although it is unlikely that such a dramatic difference would be explained by differences in race distribution, sun exposure, or other prognostic variables<sup>4</sup>. In the Dutch cancer registry squamous cell carcinoma is separately coded under 'Skin, other than melanoma' (ICD-O 173). In the years 1989–1991 the incidence of squamous cell carcinoma was 21.5/100 000 males and 11.7/100 000 females.

Basal cell carcinoma is not registered separately in The Netherlands, but based on a dermatologist survey approximately 30 000 cases each year present themselves for treatment (200/100 000). In total, more than 1 million cases of basal and squamous cell carcinoma are seen annually in the US which accounts for an age-adjusted incidence rate of approximately 200/100 000 inhabitants<sup>5</sup>.



## SQUAMOUS CELL CARCINOMA

### Predisposing factors

There are a number of risk factors for squamous cell carcinoma, all of which at some level impact the DNA damage and repair mechanism.

- Early exposure to ultraviolet (UV) irradiation
- Skin burn early in life or skin freezing
- Immunosuppression
- Ionizing radiation
- Psoralene and psoralen UVA (PUVA) for psoriasis
- Oral corticosteroids
- Chronic ulcer or scars (Marjolin ulcer)
- Contact with toxic material (arsenicum, nitrates).

### *Ultraviolet radiation*

Squamous cell carcinoma of the skin is seen much more frequently in whites (70 : 1 compared with non-whites) and in males (2 : 1 compared with females). It is a disease of the elderly, 75% of the cases occur in patients over 65 years of age. The head and neck region are most commonly involved (80%) and the remaining 20% occur in parts of the body that are exposed to sunlight. Chronic damage by UV radiation is thought to be the most important risk factor for squamous cell carcinoma of the skin<sup>6</sup>. This is probably different from the development of melanoma and basal cell carcinoma, which seem to be associated with intermittent sun damage occurring during overexposure to sun for instance on the beach. Although UVB radiation is the most toxic part for the skin, the wide and often long-time use of artificial UVA in sunbeds clearly contributes to skin damage and the development of actinic changes.

Skin cancers develop as a result of a sequence of biochemical events caused by and promoted by UV radiation. All wavelengths of UV (UVB 280–320 nm, UVA 320–400 nm), including even visible light, cause direct and sun-damage specific DNA damage. If this damage is not repaired (nucleotide excision repair) mutations are seen in proto-oncogenes (ras pathway) and tumor suppression genes (p53 mutation)<sup>7</sup>. In addition to this direct DNA damage, UV radiation causes down-regulation of the skin immune response by depletion of Langerhans cells, the antigen presenting cells of the epidermis<sup>8</sup>.

Certain groups of whites have an increased risk for the development of squamous cell carcinoma of the skin. It is

well known that patients with fair, white skin (type I or II, see Table 26.1) who almost never tan and who will easily develop sunburn after sun exposure are at increased risk. People with excessive sun exposure (farmers, road workers), with a history of or currently working in tropical areas, and people with excessive usage of sunbeds are also at increased risk of development of squamous cell carcinoma.

Patients with hereditary diseases such as xeroderma pigmentosum and epidermodysplasia verruciformis will almost all develop squamous cell carcinoma, because they lack the ability to repair existing DNA damage which makes them extremely sensitive for sun damage. They develop skin cancers at a very young age.

### *Renal transplant recipients*

On average 6% of renal transplant recipients develop cancer after transplantation, most commonly skin and lip cancer, which accounts for one-third of cancers in this group. In a long-term follow-up study in Australia, the skin cancer risk 11 years after transplantation was 45%, and after 20 years 70% of the patients had developed skin cancer<sup>9</sup>. There is still a relationship with sun exposure, as the incidence in countries on lower latitudes (Australia) appears to be higher than the incidence in countries such as The Netherlands (10–15%). Of the skin cancers detected after transplantation, squamous cell carcinoma incidence is more than 250 times that of the general population, whereas basal cell carcinoma incidence is only ten times higher<sup>10</sup>. Also, the distribution of squamous cell carcinomas is different in renal transplant recipients from the normal population, with a preference for the back of the hands and the face. These skin cancers tend to be multiple and they behave more aggressively which leads to difficulties in clinical assessment and often multiple biopsies<sup>11</sup>. The exact reason why skin cancers develop in immunosuppressed patients is not known. Lesions associated with cutaneous viral human papilloma virus (HPV) infections (warts) occur more often in patients with suppressed immunoresponses, and many of the pathways HPV uses for its duplication are recognized in cancer development as well. However, a clear relationship with cutaneous viral infections is hard to detect in spite of overexpression of p14, p15 and p53 in these lesions<sup>12</sup>.

### *Ionizing radiation*

Not only ultraviolet radiation but also ionizing radiation induces skin cancer. This has been an underreported hazard because of the insufficient non-melanoma skin cancer registration and the notion that most of these skin

cancers do not affect survival. In the childhood cancer survivor study, 213 of 13 000 analyzed patients had developed non-melanoma skin cancer at a median age of 31 years. Location of these skin cancers was predominantly on the head and neck, back and chest, and in more than 90% within an earlier radiation field. The skin cancers were often multiple and recurred in half of the patients<sup>13</sup>.

#### *Psoralene and psoralen ultraviolet A for psoriasis*

Psoriasis is a chronic skin disorder triggered by an immune response of T lymphocytes in the skin leading to local inflammation with a characteristic white scaling aspect. It is most often treated with topical corticosteroids on an outpatient basis, but phototherapy has long been used as well. Short courses of UVB, which induce a local inflammatory response, have been shown to be beneficial. Alternatively, UVA radiation combined with psoralene has been used, because of the reduced burning effect of UVA radiation. However, phototherapy is mutagenic and may lead to secondary skin tumors, notably melanoma and squamous cell carcinoma. In a PUVA follow-up study, after long-term follow-up (more than 20 years) the incidence of melanoma increased five-fold compared with a normal population<sup>14</sup>. This effect was more pronounced in patients with more than 250 PUVA treatments. A Swedish study showed a dose-dependent increase in the risk of squamous cell cancer of the skin. Male patients who had received more than 200 treatments had over 30 times the incidence of squamous cell cancer than that found in the general population<sup>15</sup>. The mutagenic effect occurred after a lag time of approximately 20 years. Patients with squamous cell carcinoma after PUVA often

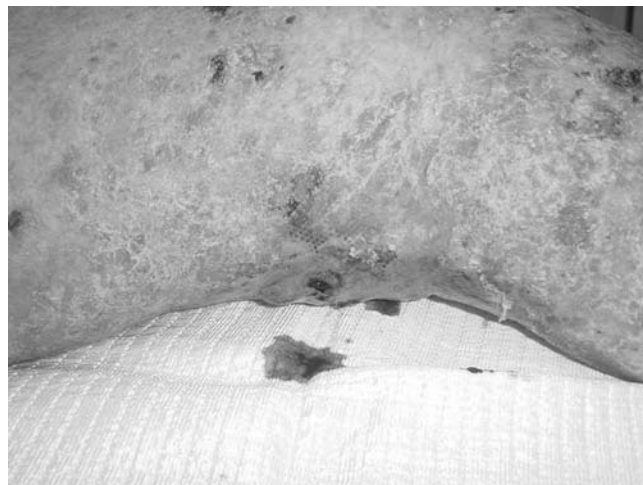present with multiple tumors with a tendency for a more aggressive behavior and increased metastatic potential. Continuous surveillance and early resection of suspected lesions in these patients is needed in order to prevent uncontrollable disease (Figure 26.1).

#### *Oral corticosteroids*

The use of corticosteroids has long been associated with skin problems (thinner skin, delayed healing of wounds). Non-melanoma skin cancers are seen in renal transplant recipients more often, partly because of the use of oral corticosteroids. Also, in otherwise non-immunosuppressed patients, use of oral corticosteroids may induce skin cancers. In a population-based American study, the risk of squamous cell carcinoma was increased among users of oral glucocorticoids (adjusted odds ratio = 2.31; 95% confidence interval (CI) = 1.27, 4.18), and risk of basal cell carcinoma was elevated modestly (adjusted odds ratio = 1.49; 95% CI = 0.90, 2.47). The risk of developing squamous cell carcinoma or basal cell carcinoma was unrelated to the use of inhaled steroids<sup>16</sup>.

#### *Chronic ulcer*

Marjolin ulcer is a malignant transformation in a long-standing ulcer and/or scar tissue. This is seen in 1–2% of all burns but can also develop from previously otherwise scarred tissue. The malignant transformation has a lag time after injury of 20–40 years. Malignant transformation presents as squamous cell carcinoma in 75–96% of the cases. The exact pathophysiological mechanism is unknown, but it is generally thought that a cancerous environment is formed by the lack of blood supply and



**Figure 26.1** Multiple skin lesions and nodal metastases (arrow) in the popliteal area of a squamous cell carcinoma on the leg of a patient who was treated with psoralen (P) UVA 20 years before.

decreased immunity in the scar tissue. The epithelium is destroyed by repeated local trauma, healing with increased difficulty each time. The regenerated epithelium is progressively inferior and the persistent stimulation to the marginal epithelium may lead to a loss of tissue restraint and neoplastic changes<sup>17</sup>.

## Precursor lesions

### *Actinic keratosis*

Most squamous cell carcinomas arise from actinic keratosis and many actually regard actinic keratosis as an *in situ* or superficial squamous cell carcinoma<sup>1</sup>. As stated earlier, because of the natural behavior of actinic keratosis and for practical reasons this is probably not correct.

Actinic keratosis are often multiple, small (<10 mm), hyperkeratotic lesions on sun-exposed skin. They often regress spontaneously, but in 0.1–10% they will develop into squamous cell carcinoma<sup>3</sup>. Like squamous cell carcinoma, development of actinic keratosis is linked to certain subtypes of HPV, although the etiological relationship remains unclear<sup>18</sup>. Because of its spontaneous regression, actinic keratosis does not always need treatment, in fact, many of these lesions will never be medically evaluated or treated at all. If any treatment is sought, cryotherapy seems to be most effective with low morbidity and negligible recurrence rates. Alternatively, simple scraping off seems to be as effective and, of course, substantially less expensive. A number of drugs (topical retinoid, beta carotene) have been advocated in order to prevent sun damage to the skin, particularly actinic keratosis. Only constant application of sunscreen when outdoors has been proven to reduce the risk of development of actinic keratosis<sup>19</sup>.

### *Bowen's disease*

This is also and appropriately known as *in situ* squamous cell carcinoma. It is an often sharply bordered, 10–50 mm

red-brown skin lesion, sometimes pigmented, on sun-exposed skin. There is no induration into the skin. Although there is a well known anogenital variant which is caused by HPV, such a relationship is less clear for the cutaneous variants. Of these lesions 20–30% will develop into squamous cell carcinoma and resection has therefore been the main treatment. Recently, imiquimod, a topical immune response modifier has come under increasing attention because it is a non-invasive and apparently effective treatment for Bowen's disease<sup>20</sup>. Randomized trials of resection compared with imiquimod treatment are now being conducted.

## Prognosis

Death from non-melanoma skin cancer is rare. As reported in the Dutch Cancer Registry, mortality from 'Skin, other than melanoma' (ICD-O 173) in 1991 was 3%, which is 0.2% of all cancer mortality. Given the fact that primary therapy (wide excision) of squamous cell carcinoma has not changed over the years and that no systemic therapy has been developed it is not surprising that the 5- and 10-year survival rates remain stable (Figure 26.2).

The occurrence of metastasis is the most important prognostic variable for death. Skin cancers preferentially metastasize through the lymphatics, but hematogenic metastases (lung, liver, bone) do occur. Metastases are seen in long-standing tumors, larger tumors, tumors with increasing T stage, and decreasing tumor differentiation. Squamous cell carcinomas in sun-damaged skin tend to behave less malignantly than *de novo* squamous cell carcinoma in normal skin. On the other hand, skin cancer developing in chronic ulcer or scar tissue (irradiation) has a far more malignant behavior; more than 20% of these ultimately metastasize.

A number of risk factors seem to be associated with dying from a squamous cell carcinoma of the skin<sup>21</sup>. These factors are tumor diameter 4 cm or more, the presence of perineural invasion, and depth of invasion beyond

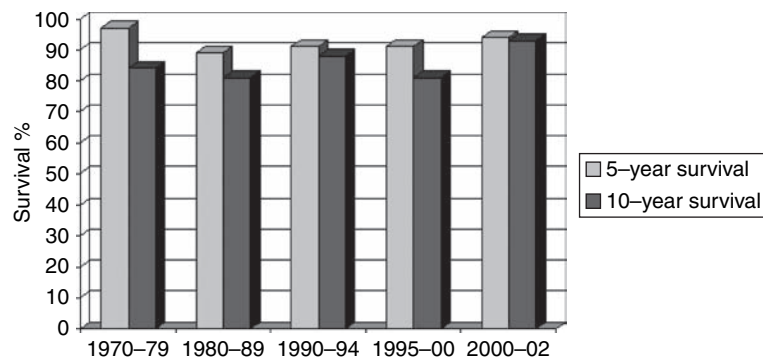


Figure 26.2

subcutaneous tissue. Presence of these factors can help identify patients who may benefit from more aggressive management and closer monitoring.

## Diagnosis

Clinical diagnosis of squamous cell carcinoma of the skin is difficult and there are numerous differential diagnoses, so histopathological examination of suspected skin lesions is mandatory. An excision biopsy is usually indicated. This can be done using field block analgesia, taking care not to infiltrate anesthetic in the lesion because increased tissue pressure might theoretically cause spread of tumor cells. A 2 mm margin of macroscopically normal skin should be taken. Most defects can easily be closed with intracutaneous running resorbable sutures.

In cases where primary excision is technically not feasible or where esthetics are a drawback (face), a 3 mm core biopsy may be taken. The biopsy should be sufficiently deep in order to enable the pathologist to determine the invasion depth and any vascular or lymphatic invasion.

## Treatment

### *Local treatment*

The vast majority of squamous cell carcinomas remain localized and require local treatment only. In routine practice, resection, cryosurgery, or radiotherapy are the most commonly used modalities. Tumor-related factors (size, location, growth pattern, primary, or recurrent lesion), patient-related factors (esthetics, age, preferences), and physician-related factors (experience, availability) all require attention to choose the appropriate treatment and it is therefore not surprising that outcomes of different treatments are not easily comparable.

Cryosurgery is simple, fast and often repeatable and it does not interfere with other treatment options. It is, however, impossible to assess histological radicality and it leads to strong wound reactions with long-term pigmentation of scars.

Resection is also simple, fast and has the advantage of histological examination. It may require general anesthesia and sometimes, large defects require skin reconstructions. It is the preferred treatment option in younger patients, for diffuse growing or recurrent lesions and for lesions on eyelids and in the nasolabial fold.

Mohs' surgery or micrographic surgery is performed by specialized surgeons, who use special resection techniques and immediate frozen section analysis of all margins in order to obtain free margins with minimal skin defects. It is increasingly being used for skin cancers but the availability of Mohs' surgeons is limited and the

procedure requires prolonged operation times. Five-year cure rates are as high as 95%<sup>22</sup>.

Radiation therapy can be used for all types of squamous cell carcinoma. It is the preferred treatment option for larger lesions where mutilation as a result of surgery would be substantial. Five-year cure rates are more than 90%, although this decreases substantially with increasing diameter of the lesion. For recurrent lesions the success rate is less than 50%<sup>23</sup>. Radiation therapy lacks histological confirmation and the treatment may take many weeks. Postradiation skin ulceration may occur in 6% of patients<sup>24</sup>. Its further disadvantage is that subsequent evaluation and treatment of irradiated skin areas is impaired and there is a long-term risk of development of secondary (skin, soft tissue) cancers.

A treatment algorithm is not easily composed. The variety of primary treatment options and the availability of these makes any choice tenable. In view of the arguments mentioned above and for rather practical reasons resection of malignant skin tumors is the preferred treatment option. A treatment algorithm would then be as shown in Figure 26.3.

### *Regional treatment*

Between 5 and 10% of squamous cell carcinomas present with synchronous or metachronous nodal metastases and clinical examination of the regional lymph node stations is mandatory. Suspected nodes require fine needle aspiration and cytological examination; when metastases are detected regional lymph node dissection should be performed. Sentinel lymph node biopsy has proven value for individual melanoma patients, where regional lymph node metastases occur in 15–20% of all patients<sup>25</sup>. However, performing sentinel node biopsy and subsequent regional lymph node dissection if a clinically unsuspected lymph node is identified as positive has not resulted in overall survival for melanoma patients. In view of the lower incidence of nodal metastases it seems unlikely that early treatment of subclinical disease in squamous cell carcinoma will be beneficial, and as long as factors predicting nodal metastases have not been identified, sentinel lymph node biopsy in squamous cell carcinoma should only be undertaken in studies<sup>26</sup>.

### *Adjuvant treatment*

Adjuvant radiation therapy for squamous cell carcinoma may be indicated for selected patients. These include high risk histological findings ( $\geq 4$  cm, perineural invasion, invasion beyond the subcutaneous tissue<sup>21</sup>) and patients with irradiated resected tumors, where additional resection would result in impaired wound healing.

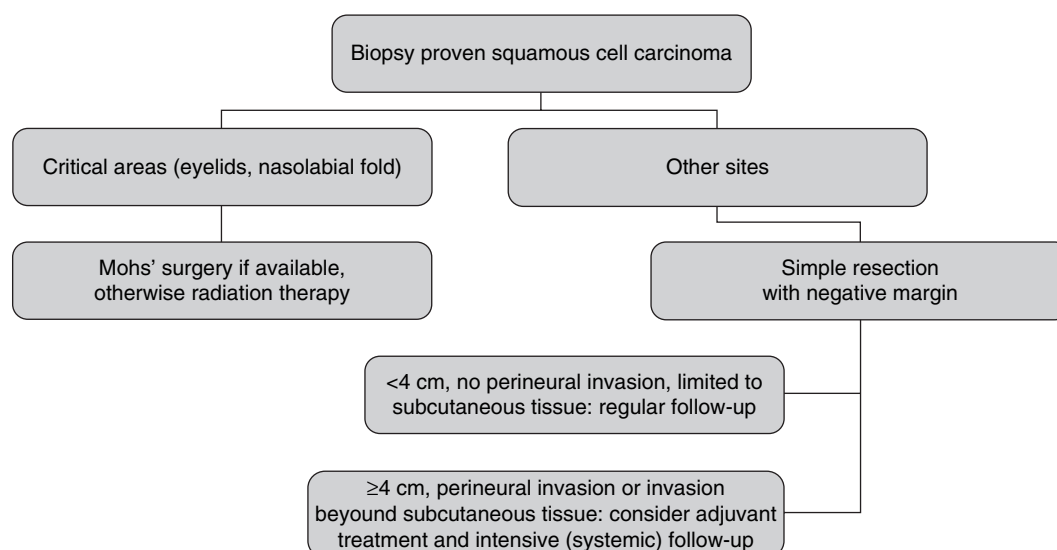


Figure 26.3

Adjuvant radiation therapy has also been used for nodal metastases, especially in the head and neck area. However, prospective data to evaluate the impact of adjuvant radiation treatment are lacking and some have even reported no benefit of adjuvant therapy at all.

### Follow up

Most (>85%) local recurrences after intentionally curative treatment of squamous cell carcinoma are seen within 5 years of treatment, although even 10 years later recurrences have been reported. The risk of a second primary depends on the risk factors of an individual patient, but this may be as high as 80%. Also, the risk of development of another skin cancer (basal cell carcinoma and melanoma) is increased. An effective follow-up scheme aimed at identifying recurrence should incorporate the individual risk and the speed of growth but half-yearly visits for the first 2 years and yearly visits until the 5th year should be sufficient. High risk patients should be followed for the rest of their life.

### TNM Classification

Because of its metastatic potential, TNM staging has more practical value for squamous cell carcinoma than for basal cell carcinoma. For malignancies arising in the eyelids, the vulva and the penis separate staging systems are being used. The staging of the American Joint Committee on Cancer (AJCC 1992) and the Union

Table 26.2 Classification for squamous cell carcinoma

#### Primary tumor (T)

Tx	Insufficient information for T staging
T1	Primary tumor <2 cm
T2	Primary tumor >2 cm and <5 cm
T3	Primary tumor >5 cm
T4	Invasion in deep structures (muscle, cartilage, or bone)

#### Lymphnodes (N)

Nx	Regional lymph nodes not assessed
N0	No regional lymph node involvement
N1	Regional lymph node involvement

#### Distant Metastases (M)

Mx	Distant metastases not assessed
M0	No distant metastases
M1	Distant metastases

#### Grade (G)

Gx	Histological differentiation not assessed
G1	Well differentiated
G2	Intermediate differentiated
G3	Poorly differentiated
G4	Undifferentiated

Internationale Contre le Cancer (UICC 1992) are the same Table 26.1<sup>27</sup>.

## BASAL CELL CARCINOMA

Basal cell carcinomas usually grow slowly. Infiltration into adjacent structures is rare, although this occurs more often in the area of the embryonic fusion planes of the face (temporal, nose and surroundings). The incidence of metastases is less than 0.03%<sup>28</sup>.

Because of the low risk of metastases, TNM staging is not applicable for basal cell carcinoma. They may be divided according to the risk of recurrence into low risk and high risk (Table 26.3)<sup>28</sup>.

The clinical diagnosis of basal cell carcinoma is confirmed by an excision biopsy. The histological growth pattern can be divided into three subtypes:

- Superficial (often multifocal, almost no stromal reaction)
- Nodular (clear margins, large cell nests)
- Spindle shaped (small cell nests with spindle shaped cells, unclear margins).

Treatment of basal cell carcinoma requires an individual approach where age, prognostic factors, preferences of the patient and physician, and availability of treatment options all have to be taken into account. These options are the same as for the treatment of squamous cell carcinoma. Outcome of surgery and radiotherapy seem to be comparable, with recurrences occurring in less than 5%. One prospective study could not detect a difference between radiotherapy and surgery, although the follow-up was less than 5 years<sup>29</sup>. On the basis of its efficacy, histological confirmation of radicality and its simplicity, resection seems the preferred treatment for primary and recurrent, well defined lesions smaller than 2 cm. If tissue sparing is essential (face), Mohs' micrographic surgery should be considered<sup>30</sup>. Electrosurgery (curettage and electrodesiccation) and cryosurgery are easily performed, rapid techniques with recurrence rates slightly higher than for resection (5–10%)<sup>31</sup>. They should be reserved for small (<0.5 cm) lesions where the results of treatment are easily investigated.

Treatment of multiple basal cell carcinomas has been much less investigated and thus remains mostly experimental. Options include photodynamic therapy<sup>32</sup> and immunotherapy with imiquimod<sup>33</sup>.

## REFERENCES

1. Brand D, Ackerman AB. Squamous cell carcinoma, not basal cell carcinoma is the most common cancer in humans. *J Am Acad Dermatol* 2000; 42: 523–6.
2. Smoller BR. Squamous cell carcinoma: from precursor lesions to high-risk variants. *Mod Pathol* 2006; 19: S88–92.
3. Marks R, Rennie G, Selwood TS. Malignant transformation of solar keratosis to squamous cell carcinoma. *Lancet* 1988; 1: 795–7.
4. WHO Cancer Incidence in Five Continents. [www-dep.iarc.fr](http://www-dep.iarc.fr). Accessed September 2006.
5. [www.cancer.org](http://www.cancer.org). 2005.
6. Zanetti R, Rosso S, Martinez C et al. Comparison of risk patterns in carcinoma and melanoma of the skin in men: a multi-center case-control study. *Br J Cancer* 2006; 94: 743–51.
7. Hussein MR. Ultraviolet radiation and skin cancer: molecular mechanisms. *J Cutan Pathol* 2005; 32: 191–205.
8. Meunier L. Ultraviolet light and dendritic cells. *Eur J Dermatol* 1999; 9: 269–75.
9. Bouwes Bavinck JN, Hardie DR, Green A et al. The risk of skin cancer in renal transplant recipients in Queensland, Australia. A follow-up study. *Transplantation* 1996; 61: 715–21.
10. Hartevelt MM, Bouwes Bavinck JN, Kootte AM et al. Incidence of skin cancer after renal transplantation in The Netherlands. *Transplantation* 1990; 49: 506–9.
11. Euvrard S, Kanitakis J, Pouteil-Noble C et al. Comparative epidemiologic study of premalignant and malignant epithelial cutaneous lesions developing after kidney and heart transplantation. *J Am Acad Dermatol* 1995; 33: 222–9.
12. Blokx WA, De Jong EM, De Wilde PC et al. P16 and p53 expression in (pre)malignant epidermal tumors of renal transplant recipients and immunocompetent individuals. *Mod Pathol* 2003; 16: 869–78.
13. Perkins JL, Liu Y, Mitby PA et al. Nonmelanoma skin cancer in survivors of childhood and adolescent cancer: a report from the childhood cancer survivor study. *J Clin Oncol* 2005; 23: 3733–41.
14. Stern RS, Nichols KT, Vakeva LH. Malignant melanoma in patients treated for psoriasis with methoxsalen (psoralen) and ultraviolet A radiation (PUVA). The PUVA Follow-Up Study. *N Engl J Med* 1997; 336: 1041–5.
15. Lindelöf B, Sigurgeirsson B, Tegner E et al. PUVA and cancer: a large-scale epidemiological study. *Lancet* 1991; 338: 91–3.
16. Karagas MR, Cushing GL Jr, Greenberg ER et al. Non-melanoma skin cancers and glucocorticoid therapy. *Br J Cancer* 2001; 85: 683–6.
17. Copcu E, Aktas A, Sismant N et al. Thirty-one cases of Marjolin's ulcer. *Clin Exp Dermatol* 2003; 28: 138–141.
18. Karagas MR, Nelson HH, Sehr P et al. Human papillomavirus infection and incidence of squamous cell and basal cell carcinomas of the skin. *J Natl Cancer Inst* 2006; 98: 389–95.
19. Darlington S, Williams G, Neale R et al. A randomized controlled trial to assess sunscreen application and beta carotene supplementation in the prevention of solar keratoses. *Arch Dermatol* 2003; 139: 451–5.
20. Peris K, Micantonio T, Farqnoli MC et al. Imiquimod 5% cream in the treatment of Bowen's disease and invasive squamous cell carcinoma. *J Am Acad Dermatol* 2006; 55: 324–7.

21. Clayman GL, Lee JJ, Holsinger FC et al. Mortality risk from squamous cell skin cancer. *J Clin Oncol* 2005; 23: 759–65.
22. Drake LA, Dinehart SM, Goltz RW et al. Guidelines of care for Mohs micrographic surgery. *American Academy of Dermatology. J Am Acad Dermatol* 1995; 33: 271.
23. Kwan W, Wilson D, Moravan V. Radiotherapy for locally advanced basal cell and squamous cell carcinoma of the skin. *Int J Radiat Oncol Biol Phys* 2004; 60: 406–11.
24. Schulte KW, Lippold A, Auras C et al. Soft x-ray therapy for cutaneous basal cell and squamous cell carcinomas. *J Am Acad Dermatol* 2005; 53: 993–1001.
25. Morton D, Thomson J, Cochran A et al. Sentinel node biopsy or nodal observation in melanoma. *N Engl J Med* 2006; 355: 1307–17.
26. Weisberg NK, Bertagnolli MM, Becker DS. Combined sentinel lymphadenectomy and Mohs' micrographic surgery for high-risk cutaneous squamous cell carcinoma. *J Am Acad Dermatol* 2000; 43: 483–8.
27. Wittekind C, Meyer HJ, Bootz F. *TNM Klassifikation maligner Tumoren*, 6th edn. Berlin: Springer, 2002.
28. Lo JS, Snow SN, Reitzner GT et al. Metastatic basal cell carcinoma; report of twelve cases with a review of the literature. *J Am Acad Dermatol* 1991; 24: 715–9.
29. Avril MF, Auperin A, Margulis A et al. Basal cell carcinoma of the face. Surgery or radiotherapy? Results of a randomised study. *Br J Cancer* 1997; 76: 100–6.
30. Wennberg A-M, Larkö O, Stenquist B. Five-year results of Mohs' micrographic surgery for aggressive facial basal cell carcinoma in Sweden. *Acta Derm Venereol* 1999; 79: 370–2.
31. Silverman MK, Kopf AW, Grin CN et al. Recurrence rate of treated basal cell carcinoma. Part 2: curettage and electrodesiccation. *J Dermatol Surg Oncol* 1991; 17: 720–6.
32. Dijkstra AT, Majoie IM, van Dongen JW et al. Photodynamic therapy with violet light and topical delta-aminolaevulinic acid in the treatment of actinic keratosis, Bowen's disease and basal cell carcinoma. *J Eur Acad Dermatol Venereol* 2001; 15: 550–4.
33. Marks R, Gebauer K, Schumack S et al. Imiquimod 5% cream in the treatment of superficial basal cell carcinoma. Results of a multicenter 6-week dose-response trial. *J Am Acad Dermatol* 2001; 44: 807–13.

Charles R Scoggins and Kelly M McMasters

---

## INTRODUCTION

Although less prevalent than squamous cell carcinoma and basal cell carcinoma, melanoma is the most serious and potentially lethal form of skin cancer. Melanoma represents the endpoint of malignant transformation of the melanocyte, the cell that contains the pigment, melanin. Embryologically, melanocytes are derived from neural crest cells, which migrate throughout the fetus to the developing gastrointestinal tract, eyes, meninges, and skin. As a result of the widespread distribution of these neural crest-derived cells, melanoma may arise in any of these locations; however, cutaneous melanoma is by far the most common form. This may be due to a combination of factors, including cutaneous exposure to ultraviolet (UV) radiation and the huge number of melanocytes distributed throughout the skin.

Melanoma has a propensity for early metastasis, and the usual pattern first involves the regional lymph nodes. Some patients' disease will progress further to include systemic metastases. The treatment of melanoma has radically changed over the past decade with the advent of a minimally invasive technique for nodal staging, known as sentinel lymph node biopsy. Concomitantly, the literature on melanoma has exploded, further refining the general understanding of this disease. Yet, despite these advances, outcomes for melanoma remain largely unchanged, in part due to a paucity of effective adjuvant therapies.

## INCIDENCE AND PREVALENCE

Melanoma is a relatively uncommon disease, representing only 5% of skin cancers. The American Cancer Society estimated that approximately 55 000 Americans would be diagnosed with melanoma in 2004, and this number continues to rise each year<sup>1</sup>. In fact, the incidence of melanoma is increasing faster than that of any other cancer. Additionally, an estimated 7900 patients with melanoma died in 2004<sup>1</sup>. The cumulative lifetime risk of developing melanoma also continues to rise, and for white

men the risk is 1 : 55 and for women the lifetime risk is 1 : 82. Melanoma is a disease that affects people during their productive years, with the peak incidence in the 4th and 5th decades of life. It is rare to diagnose melanoma in a person younger than 15 years old. Certainly, the incidence of melanoma is related to race. There appears to be a 20 : 1 risk of melanoma for whites when compared with African-Americans<sup>2</sup>. Additionally, race affects survival for patients afflicted with melanoma. White patients have a better survival than stage-matched African-Americans<sup>1</sup>.

The most common risk factors for the development of melanoma are fair complexion and sun exposure (especially with a history of blistering sunburn). Patients of northern European descent have the highest rates of melanoma, and this incidence increases with migration to regions of the world with greater sun exposure. Light hair and red-headed patients, those with pale skin, patients with blue or light-colored eyes, and those with particularly sun-sensitive skin are at increased risk for melanoma. As an environmental carcinogenic agent, UV radiation (UVA and UVB) exposure is directly related to sunburns. These burns, especially blistering sunburns early in life, appear to be related to malignant transformation of melanocytes, resulting in the formation of melanoma tumors. As such, methods to decrease skin exposure to UV radiation impact an individual patient's risk for melanoma, such as regular use of topical sunscreens and proper clothing that provide protection from prolonged sun exposure. In addition, some patients have genetic predispositions for the development of melanoma, including those with a strong family history and patients with dysplastic nevus syndrome. Patients with a prior history of skin cancer, including a prior melanoma, have an increased risk of subsequent melanoma development.

## PRESENTATION

Melanoma typically presents as a changing pigmented lesion. Most melanomas are darkly pigmented, but may

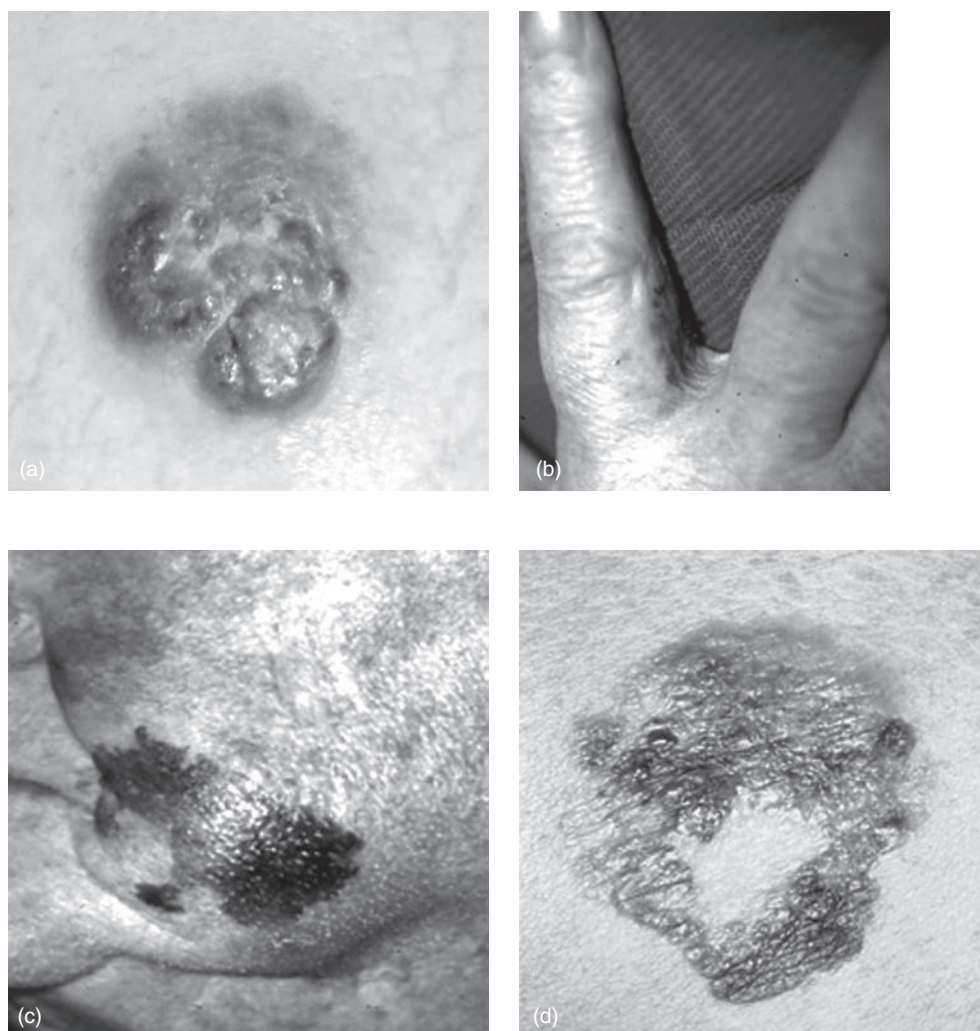


range in color from pink (amelanotic melanoma) to black (Figure 27.1). Many patients report expansion of a pigmented lesion in a radial pattern, often followed by a period of vertical growth forming a raised lesion or a 'bump'. Additionally, a lesion might cause pain, itching, or bleeding, or have a clear drainage. Dry, scaly skin overlying a lesion might prompt the patient to seek medical attention, and ulceration might result in drainage onto the patient's clothing. Occasionally, a patient will present with enlarged lymph nodes. Lymphadenopathy should prompt a thorough search for a primary lesion; however, occasionally a patient will present with an enlarged lymph node containing melanoma metastasis without an identifiable primary lesion. A truly occult primary melanoma with nodal metastasis probably represents an immunological phenomenon in which the immune system is activated by primary melanoma

antigens and activated T cell lymphocytes participate in tumor regression to the point of clinical regression and disappearance of the pigmented lesion. An alternative hypothesis is that, in some cases, primary melanomas can develop from pigmented nevus cells that reside within lymph nodes.

### Biopsy of primary lesions

Often, patients have multiple pigmented skin lesions, and the overwhelming majority of these are benign. However, there are some properties of pigmented lesions that should raise a clinician's suspicion, thus prompting a biopsy (Table 27.1). A change in the size and/or shape of a pigmented lesion should raise the possibility of malignant transformation. Additionally, an asymmetric border or a diameter that is 5 mm or greater is suspicious. Growth of



**Figure 27.1** (a) Nodular melanoma arising from a pre-existing nevus. Note focal ulceration. (b) Acral lentiginous melanoma arising between fingers. (c) Lento-malignant melanoma. (d) Superficial spreading melanoma with irregular borders and variegated pigmentation.

**Table 27.1** ABCDs of melanoma

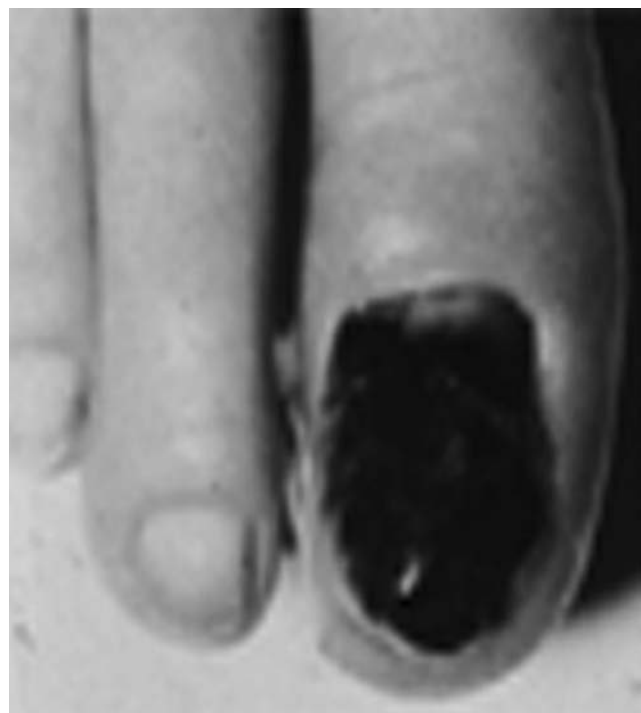---

Asymmetry
Irregular Borders
Color change
Large or changing
Diameter

---

a pigmented skin lesion should also be considered abnormal. Itching, bleeding, or drainage from a pigmented lesion might indicate ulceration and prompt a biopsy. A darkly colored nail without a history of injury is suspicious for a subungual melanoma.

Selecting the proper biopsy technique is critical for patients suspected to have melanoma. Since therapy is based on histological assessment of prognostic factors known to influence outcome, especially tumor thickness, any biopsy must accurately reflect the depth of the lesion in question. In general, shave biopsy or curettage biopsy should be avoided, as these techniques may not allow for complete assessment of tumor thickness. However, many dermatologists perform 'deep' shave biopsy of pigmented lesions that are relatively bland in appearance, only to find the pathology report documents melanoma. If the deep margin of these shave biopsies is negative, and the entire lesion has been adequately sampled, then this may be an accurate assessment of the tumor's thickness. It is uncommon for the excisional specimen that is resultant from these lesions to contain residual melanoma, thus suggesting that deep shave biopsy, especially for thin melanomas, may not be as 'bad' as once thought. In general, however, any lesion that is suspected of being a melanoma should be biopsied with either an incisional (including punch) or excisional biopsy, including a 1–2 mm margin. This biopsy should be full thickness, with attached subcutaneous fat to permit complete assessment of thickness. The choice of biopsy technique does not influence recurrence or survival following therapy for melanoma<sup>3</sup>, so long as an accurate determination of tumor thickness can be made from the biopsy specimen. These data highlight the fact that the most important aspect of any biopsy technique is obtaining an accurate determination of the tumor thickness, not the actual technique itself. For cutaneous and mucosal lesions, a punch or excisional biopsy under local anesthesia is safe and effective, and can easily be done in the office setting for most patients. For very large lesions, an incisional biopsy may be performed in the office, thus allowing for establishment of pathology prior to proceeding to the

**Figure 27.2** Large subungual melanoma.

operating room. For pigmented lesions of the nail bed, (Figure 27.2) a good digital block should be performed followed by removal of the nail itself. Biopsy of the underlying nail bed or nail matrix should then be performed, and both the biopsy and the nail itself should be sent for pathological analysis. Alternatively, a punch biopsy can be performed directly through the nail.

Some patients require special attention with regard to possible melanoma formation. An aggressive program of scheduled dermatological surveillance is mandatory for patients with a personal history of melanoma, as the risk of multiple primary melanomas is about 8% in these patients, and seems to increase further with each subsequent primary tumor. Additionally, patients with dysplastic nevus syndrome or a positive family history of melanoma should also be routinely screened, and any suspicious lesion biopsied. Generally, these patients are followed at least twice a year with a thorough head-to-toe skin examination and palpation of nodal basins.

## PROGNOSTIC FACTORS AND STAGING

The outcome of patients afflicted with melanoma is influenced by a multitude of factors (Table 27.2). Some of these prognostic factors are clinical in nature, while

**Table 27.2** Clinical and pathological factors that influence outcome for melanoma

<i>Clinical factors</i>	<i>Pathological factors</i>
Gender	Breslow thickness
Age	Clark level of invasion
Primary tumor site	Ulceration
	Regression
	Growth phase
	Histological subtype
	Metastasis*
	Lymphovascular invasion
	Mitoses

\*Includes nodal as well as distant metastasis.

others are pathological. Gender is known to be an important prognostic factor for melanoma; it is well established that not only do men have a higher risk of developing melanoma than women, but also women with melanoma have a better outcome<sup>4</sup>. This inequality in survival is not related to a difference in the incidence of nodal disease, as several studies have shown that gender does not predict nodal status<sup>5,6</sup>. Additionally, male patients may present to the physician's office with a longer duration of symptoms, and this delay in diagnosis also impacts survival.

Another significant clinical prognostic factor for patients afflicted with melanoma is age at diagnosis. Advanced age is an independent prognostic factor that directly correlates with mortality<sup>4</sup>. Data demonstrate that as age increases, there is an increase in tumor Breslow thickness and Clark level of invasion<sup>7</sup>, indicating that older patients have worse primary tumor characteristics than younger patients. In addition, the incidence of other clinicopathological factors known to adversely affect outcome, including tumor ulceration and regression, also increase with age. These data, however, occur in the context of a paradoxical decrease in the incidence of nodal metastasis with increasing age<sup>7,8</sup>. Worse survival rates among elderly melanoma patients in the face of fewer nodal metastases are indicative of a higher rate of hematogenous metastases, presumably as a result of the adverse primary tumor characteristics. As the skin ages, there are changes in the supportive collagen, and generalized thinning of the dermis. The effect of these structural changes on the ability of a melanoma cell to gain access to the bloodstream is unknown, but may play

a role in the higher rate of distant metastases in elderly patients.

The prognostic factors that have the greatest impact on patient outcome are pathological in nature. In the largest study evaluating the pathological factors influencing survival in melanoma, Breslow tumor thickness, Clark's level of invasion (for melanomas  $\leq 1$  mm), nodal status, the number of nodes involved, primary tumor ulceration, and distant metastasis were all found to influence outcome<sup>4</sup>. Of these factors, tumor thickness and ulceration are the most powerful primary tumor-related factors affecting recurrence and survival<sup>4,9</sup>. Interestingly, these same factors are associated with nodal spread, and the status of the regional lymph nodes is the single most important prognostic factor in early-stage melanoma<sup>10</sup>. Other factors that may impact survival to a lesser extent include evidence of tumor regression and tumor-infiltrating lymphocytes (possibly indicating immune activation), vertical growth phase, mitotic index (as an indicator of actively proliferating cells), and lymphovascular invasion.

**Histological subtypes of cutaneous melanoma**

Cutaneous melanoma has been categorized into four main histological subtypes: lentigo maligna melanoma, nodular melanoma, superficial spreading melanoma, and acral lentiginous melanoma. Lentigo maligna melanoma usually arises in middle-aged patients (50–70 years old) and is characterized by the majority of the melanoma cells being junctional. In addition, histological evidence of sun-induced skin damage, such as solar elastosis is usually seen in conjunction with lentigo maligna melanoma. Many of these lesions present as thin melanomas, and therefore have a relatively good outcome. Indeed, this form of melanoma has the best prognosis.

Nodular melanoma is characterized by the absence of a radial growth phase and the formation of a polypoid or nodular lesion early in the course of disease. As the early vertical growth phase results in thicker tumors, nodular melanoma may have a relatively poor prognosis. Superficial spreading melanoma represents the most common type of melanoma, and often is identified by its tendency for irregular margins and variegated pigmentation. Histologically, pagetoid cells without significant solar elastosis and a hyperplastic dermis are the predominant features. Acral lentiginous melanoma usually arises in the hands or feet, including below the nail, as well as mucosal tissues. Acral lentiginous melanoma is the most common type of melanoma diagnosed in patients of African descent. Histologically, it is characterized by a lack of pagetoid cells, and significant junctional components. In addition to these major types of melanoma, a less common form is

desmoplastic melanoma. This type, which may carry a worse prognosis than the other types, seems to have a propensity for neurotropism, and may be associated with a higher frequency of lack of pigment (amelanotic melanoma).

### Staging for melanoma

The American Joint Committee on Cancer (AJCC) has published the most widely accepted staging system for melanoma<sup>11</sup> (Table 27.3). This system uses pathological factors to place patients in stages (I–IV), each with prognostic significance. Since tumor thickness and ulceration are critically important primary tumor determinants of survival, both of these factors are accounted for in the current staging system. The T (primary tumor) stage of disease determines the surgical management of melanoma, not only by determining the margin necessary for adequate management of the primary tumor, but also by ascertaining the patient's risk of nodal metastasis. Ulceration plays an important role in determining the T stage. The finding of ulceration 'up-stages' a tumor's behavior, and is reflective of a more aggressive biology. For example, an ulcerated 1.9 mm thick melanoma is classified as a T2b lesion, but has a survival rate similar to a T3a lesion. Thus, these two lesions would be grouped together in the final disease stage.

Additionally, the metastatic burden is critically important, and the N stage reflects this. Previously, the AJCC staging system reflected the size, not the number of nodal metastasis; however, evidence that the number of positive nodes impacts outcome led to revision of the staging system. All patients with nodal metastasis are at least stage III disease (those also having distant metastasis are stage IV). Distant metastasis places a patient in stage IV melanoma. Studies analyzing the predictors of outcome for patients with metastatic melanoma demonstrate that patients with distant metastases to the lungs have a worse survival than those with metastases to distant skin and/or distant nodal basins, while those with metastases to other visceral organs have the worst survival<sup>12</sup>. Interestingly, an elevated lactate dehydrogenase (LDH) level in a patient diagnosed with metastatic melanoma places them in the worst category, with poor outcomes (Figure 27.3).

### SURGICAL THERAPY OF MELANOMA

Clinical decision-making in melanoma is based on a thorough understanding of each individual patient's primary tumor characteristics as well as his or her nodal status and general medical condition. Since the primary determinant of therapy is the thickness of the tumor, it is helpful to

**Table 27.3** TNM staging system for melanoma

<i>Primary tumor (T)</i>			
T0	No evidence of primary tumor		
Tis	Melanoma <i>in situ</i>		
T1	Melanoma ≤1 mm thickness		
T1a	Clark level II/III and without ulceration		
T1b	Clark level IV/V or with ulceration		
T2	Melanoma 1.01–2.0 mm thickness		
T2a	Without ulceration		
T2b	Ulceration		
T3	Melanoma 2.01–4.0 mm thickness		
T3a	Without ulceration		
T3b	Ulceration		
T4	Melanoma >4.0 mm thickness		
T4a	Without ulceration		
T4b	Ulceration		
<i>Regional lymph nodes (N)</i>			
N0	No regional nodal metastases		
N1	Metastasis in one lymph node		
N1a	Clinically occult (microscopic) metastasis		
N1b	Clinically apparent (macroscopic) metastasis		
N2	Metastases in 2–3 lymph nodes or regional intralymphatic metastases		
N2a	Microscopic metastases		
N2b	Macroscopic metastases		
N2c	Satellite or in-transit metastases without nodal metastases		
N3	Metastases in >3 nodes, matted metastatic nodes, or intralymphatic metastases with nodal metastases		
<i>Distant metastasis (M)</i>			
M0	No distant metastasis		
M1	Distant metastasis		
M1a	Metastasis to skin, subcutaneous tissues or distant lymph nodes		
M1b	Metastasis to lung		
M1c	Metastasis to all other viscera, or distant metastasis with an elevated lactate dehydrogenase (LDH) level		
<i>Staging</i>			
Stage 0	Tis	N0	M0
Stage IA	T1a	N0	M0
Stage IB	T1b, T2a	N0	M0

*Continued*

Table 27.3 Continued

Stage IIA	T2b, T3a	N0	M0
Stage IIB	T3b, T4a	N0	M0
Stage IIC	T4b	N0	M0
Stage IIIA	T1–4a	N1a, N2a	M0
Stage IIIB	T1–4b	N1a, N2a	M0
	T1–4a	N1b, N2b	M0
Stage IIIC	T1–4b	N1b, N2b, N3	M0
Stage IV	Any T	Any N	M1

From reference 11 with permission.

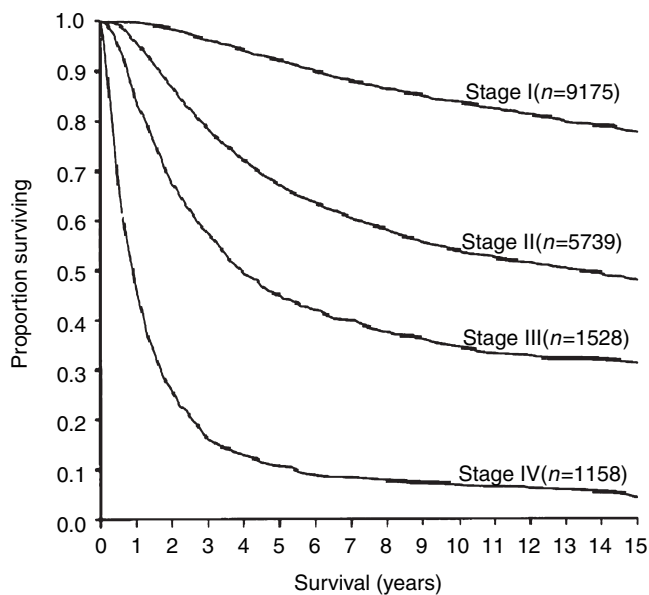


Figure 27.3 Survival for patients with melanoma based on stage. From reference 13, with permission.

consider surgical management based on tumor thickness. In a patient diagnosed with metastatic disease (stage IV), careful consideration to management of the primary tumor and nodal basin must be made. In general, excision of a primary lesion in this setting may prevent ongoing tumor growth and wound formation, while a sentinel lymph node biopsy would not be necessary. Palliative surgery for metastatic melanoma is discussed below.

Borderline melanoma-like lesions

By definition, this collection of premalignant lesions does not represent true melanomas, but it is helpful

to categorize them as borderline malignant tumors. Collectively, they are a conundrum, and pose diagnostic challenges to even the most experienced dermatopathologists. These lesions share a common characteristic: the presence of cytologic dysplasia. The true biological behavior of these lesions is poorly understood, including dysplastic nevi, but in general, these lesions should be treated with a margin-negative excision. This approach eliminates the concern for residual dysplastic cells, and results in elimination of the lesion as a potential source of malignant transformation.

Melanoma *in situ*

Melanoma *in situ* represents the earliest form of melanoma. By definition, the melanoma has not invaded beyond the basement membrane, and thus has not gained access to the lymphatic or vascular channels. Therefore, there is no risk of metastatic disease. Given this, there is no role for nodal evaluation beyond physical examination. Melanoma *in situ* is best treated with wide local excision with 0.5 cm radial margins. This approach eliminates the entire tumor, minimizes the risk of residual melanoma cells within the operative field, and is easily performed under local anesthesia. Many borderline lesions (atypical melanocytic proliferation) are best treated as melanoma *in situ*.

Invasive melanoma: principles of management

The management of patients with invasive melanoma involves wide local excision of the primary tumor as well as nodal evaluation (Table 27.4). Melanoma patients with palpable lymphadenopathy do not need a sentinel lymph node biopsy, but instead should undergo a needle biopsy (fine needle aspiration or core needle biopsy) of the nodal mass to establish tumor involvement, then undergo a thorough metastatic evaluation with computed tomography (CT) of the chest, abdomen and pelvis, and possibly a positron emission tomogram (PET). Additionally, neurological symptoms should be evaluated with a head CT or magnetic resonance imaging (MRI), and a bone scan may be obtained to evaluate any bone pain if present. It is easiest to consider invasive melanoma according to the primary tumor thickness, since this drives the therapy, and to classify them into thin, intermediate and thick melanomas.

The sentinel lymph node concept

When melanoma metastasizes, the regional lymph nodes are usually the initial site of spread. Additionally, it is rare

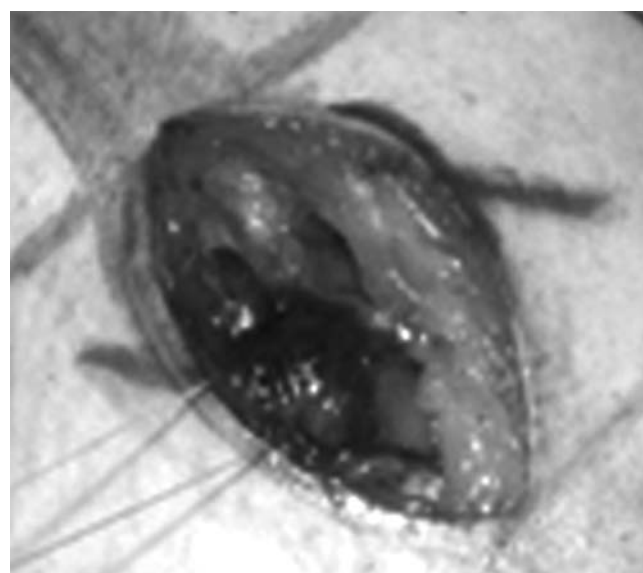
**Table 27.4** Management of melanoma by tumor thickness

	<i>Tumor thickness</i>			
	<i>In situ</i>	<i>Thin (<math>\leq 1</math> mm)</i>	<i>Intermediate (1.01–3.99 mm)*</i>	<i>Thick (<math>\geq 4</math> mm)</i>
Wide local excision	0.5 cm	1 cm	2 cm	2 cm
Node	None	$\pm$ SLN biopsy	SLN biopsy	SLN biopsy

\*For melanomas 1.0–2.0 mm thick, a 1 cm wide local excision is also acceptable. SLN, sentinel lymph node.

for patients who develop distant metastatic melanoma to never manifest nodal metastasis, although nodal metastasis is not always the first-detected site of metastatic disease. Of course, many patients with melanoma nodal metastasis will subsequently develop distant disease. Not long ago, patients with intermediate or thick melanomas ( $>1$  mm Breslow thickness) that had clinically negative (non-palpable) regional nodes were offered either elective lymph node dissection (ELND) or nodal observation. Several prospective randomized trials comparing ELND with nodal observation have failed to demonstrate a survival advantage in favor of ELND<sup>14–18</sup>. Additionally, complete lymphadenectomy carries a significant risk of morbidity, mostly from wound complications and chronic lymphedema. The lack of survival benefit and the risk of significant morbidity from ELND led investigators to pursue other methods to assess the regional nodal basins. These efforts resulted in the description of lymphatic mapping and sentinel lymph node biopsy in the early 1990s by Morton *et al.*<sup>19,20</sup>.

Conceptually, sentinel lymph node biopsy involves injection of a traceable substance near the tumor that then travels via the afferent lymphatic channel to the first draining lymph node – the lymph node most likely to contain metastatic disease. This node is termed the sentinel lymph node, as it accurately reflects the metastatic status of the entire nodal basin<sup>20,21</sup>. If the sentinel lymph node does not contain metastatic tumor cells, then the other nodes in the basin have a very low risk of harboring occult metastatic disease. From a practical standpoint, lymphatic mapping and sentinel lymph node biopsy for melanoma involves peritumoral intradermal injection of a radiotracer, such as technetium-99 sulfur colloid, usually in combination with intradermal injection of a vital-blue dye (isosulfan blue), followed by transcutaneous localization of the sentinel node with a hand-held gamma probe. A small incision is then made over this node, and the combination of a blue lymph



**Figure 27.4** Blue, radioactive inguinal lymph node mapped as the sentinel lymph node.

node and radioactivity allow precise localization of the sentinel node (Figure 27.4). These techniques are accurate and result in identification of the sentinel node in over 95% of cases with a very low false-negative rate<sup>7,10</sup>. Use of both the radiotracer and the vital-blue dye can be especially useful in identifying sentinel lymph nodes in unusual sites (those other than cervical, axillary and inguinal nodal basins) and in patients whose melanoma drains to multiple basins. Melanomas located on the trunk and distal extremities may drain to multiple basins, therefore, it is useful to obtain a preoperative lymphoscintigram (nuclear medicine scan) to identify the lymphatic drainage patterns prior to sentinel lymph node biopsy.

In addition to enhancing the identification of the lymph node most likely to harbor metastatic melanoma



cells, sentinel lymph node biopsy also involves a more thorough pathological assessment of the lymph node. Standard histopathological techniques for lymph node analysis involve cutting the node in half, or 'bi-valving' the node. Then one or two sections from the center of the node are stained and analyzed for metastatic disease. With this technique, a small volume of nodal tissue is examined, thus a very small tumor metastasis could be missed. This would result in the node being falsely diagnosed as benign. Sentinel lymph node processing differs significantly as it includes serial sectioning of the sentinel node (thus increasing the volume of nodal tissue examined) and staining with hematoxylin and eosin, as well as immunohistochemistry (usually with antibodies for the S-100 protein and/or HMB-45 antigen). By combining these advanced staining techniques with serial sectioning, the sensitivity for detection of nodal micrometastasis is increased (Figure 27.5).

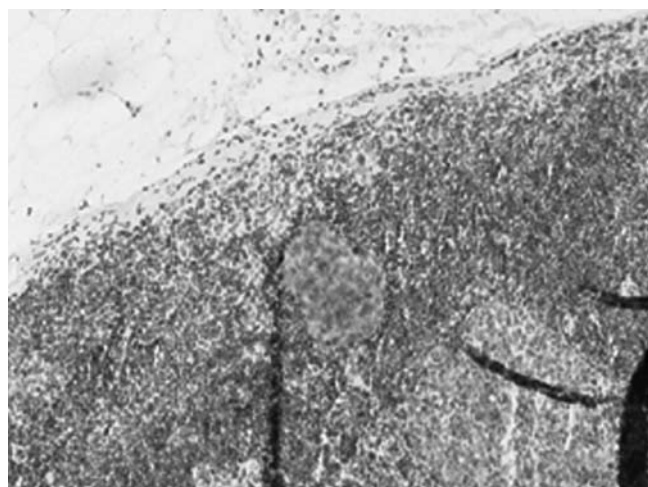
Management of the nodal basin following a sentinel lymph node biopsy is dependent upon the sentinel node status. Certainly, a negative sentinel lymph node (no metastatic cells identified) needs no further therapy with regard to the nodal basin. Currently, a positive sentinel lymph node (one that contains metastatic melanoma cells) should be considered for a completion lymphadenectomy. Following a positive sentinel node biopsy, however, approximately 80–85% of patients will not have further nodal involvement<sup>20,22</sup>. These data have led some to question the utility of completion lymphadenectomy in all patients, and to seek to identify a subset of melanoma patients that will not develop regional nodal recurrence if a completion lymphadenectomy is not performed. This is a subject of controversy, as well as the

subject of the ongoing Multicenter Selective Lymphadenectomy Trial II, conducted by Morton *et al.*

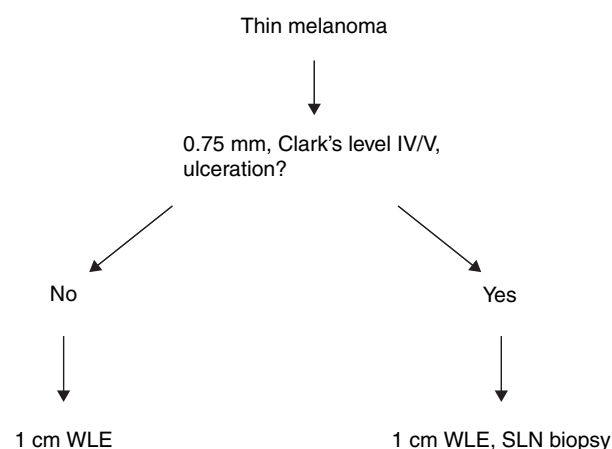
### Thin melanoma

Thin melanoma is defined as invasive melanoma that is less than 1 mm Breslow tumor thickness. These lesions have the best prognosis for invasive melanomas, with over 90% disease-specific survival at 10 years<sup>13</sup>. The treating clinician must consider several factors when deciding on the proper management of a patient with thin melanoma. The primary tumor in this group of patients is best managed with a 1 cm radial margin of excision. This margin results in a very low rate of local failure while permitting primary closure in most cases (Figure 27.6).

The indications for sentinel lymph node biopsy among patients with thin melanoma continue to evolve as more data become available. Certainly, the vast majority of patients with thin melanomas have an excellent prognosis and do not require sentinel node biopsy. Collectively, the risk of sentinel node metastasis in patients with thin melanoma is approximately 4%<sup>8,10</sup>. However, some authors advocate sentinel node biopsy for thin melanomas of around 0.75 mm thickness with Clark's level of more than III, and those with ulceration (although this is very uncommon in thin melanomas)<sup>23</sup>. Additionally, other tumor characteristics may prompt consideration for sentinel node biopsy. Evidence of tumor regression and vertical growth phase have been suggested as factors associated with an increased risk of nodal metastasis, and when combined with a tumor thickness of 0.75 mm or more, might lead a clinician to consider sentinel node analysis<sup>24</sup>. The latest evidence suggests



**Figure 27.5** Sentinel lymph node micrometastasis identified by immunohistochemistry.



**Figure 27.6** Treatment algorithm for patients with thin melanoma.

that mitotic rate and vertical growth phase, as well as age and gender, may be used to identify poor prognosis thin melanoma patients who may benefit from sentinel lymph node biopsy<sup>25</sup>.

Careful measurement of the margin at the time of surgery allows for accurate excision, and attention to the stress lines of the skin and mechanics of stress and motion will allow for optimal orientation of the surgical incision. Most melanoma excisions can be closed primarily; closure of the surgical wound also may be accomplished with local advancement flaps or with skin grafting (in cases of primary melanomas arising in an area with relatively fixed skin, such as the foot).

### Intermediate thickness melanoma

Tumors between 1 and 4 mm thick are termed intermediate thickness melanomas. These tumors are often associated with multiple adverse prognostic features, including ulceration, regression, high mitotic index, and vertical growth phase. Intermediate thickness melanomas have a risk of nodal metastasis of approximately 20–35%; therefore, sentinel lymph node biopsy has gained wide acceptance in this population<sup>8,10</sup>. Management of the primary tumor involves 2 cm radial margins, although for patients in the 1–2 mm thick category, a 1 cm margin is also acceptable (Figure 27.7). These recommendations are based on data from the Intergroup Trial, a multi-institutional trial with nearly 500 patients which demonstrated a risk of local failure of 2.1% for intermediate thickness melanomas treated with 2 cm margins compared with nearly identical risk for local recurrence for those treated with a 4 cm margin<sup>26</sup>. In addition, the 2 cm margin permits

closure of most wounds, and local advancement flaps may aid with closure.

### Thick melanoma

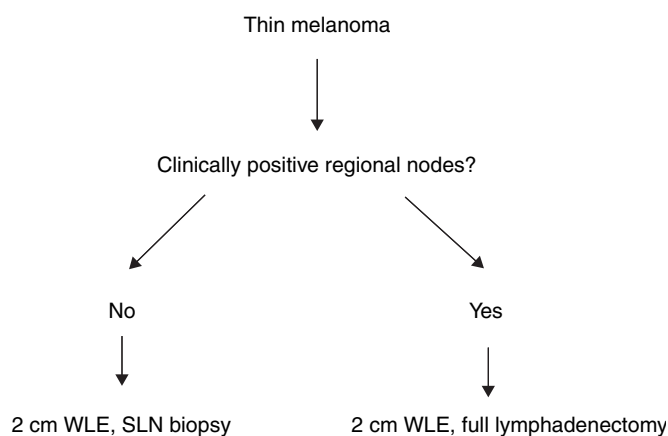
Thick melanoma (4 mm or greater) represents an advanced lesion, and as such, is frequently associated with adverse prognostic factors, such as ulceration and nodal disease. Indeed, the risk of sentinel node metastasis in patients with thick melanoma is 35–63%<sup>10</sup>. As in intermediate thickness melanoma, in the absence of clinically apparent nodal metastases, sentinel lymph node biopsy should be performed (Figure 27.7). Sentinel lymph node biopsy is accurate in this population, and since a significant number of patients with thick melanoma will not have nodal metastasis, this approach limits the number of patients subjected to complete lymphadenectomy. Evidence from clinical trials suggests that a 2 cm margin is adequate even for thick melanomas, while limiting the number of skin grafts required for closure. Nonetheless, some melanoma experts will obtain a wider margin (3 cm) for thick melanomas in locations (i.e. on the trunk) that will allow primary closure.

### Subungual melanoma

Melanomas arising in the nail matrix or nail bed have a high risk of nodal metastasis and should be considered for sentinel lymph node biopsy. For control of the primary tumor, digital amputation just proximal to the nearest interphalangeal joint provides adequate local control while preserving function.

### Mucosal melanoma

Mucosal melanoma requires special attention. This form of melanoma is often difficult to diagnose, as it may arise in difficult locations, thus making prompt diagnosis challenging. Most patients with mucosal melanoma present with extensive disease, and the risk of death approaches 100% at 5 years. Local control remains a significant problem, especially when considering that these patients gain little survival benefit from more radical surgery. For patients with anorectal melanoma without evidence of metastatic disease, abdominoperineal resection (APR) provides adequate local tumor control, but as with more radical surgery for cutaneous melanoma, is not accompanied by a survival benefit<sup>27</sup>. In addition, data demonstrate similar local control rates for patients treated with wide local excision and those treated with APR, leading some authorities to treat these unfortunate patients with wide local excision, when possible. In general, APR should be reserved for local failure following



**Figure 27.7** Treatment algorithm for patients with intermediate thickness melanoma.



wide local excision, or those cases where local excision is not possible.

### Ocular melanoma

Ocular melanoma represents the most common non-cutaneous form of melanoma. These unusual lesions arise from neural crest cells in the uveal tract (iris, ciliary body and choroid) in addition to the retina. There are several treatment approaches to ocular melanoma, including external beam radiotherapy, which has a reasonable rate of local control, partial ocular resection, and, finally, enucleation. Since there is no lymphatic drainage for the uveal tract, lymphatic metastasis is not a concern for patients with ocular melanoma. Instead, the liver is the most common site for metastasis.

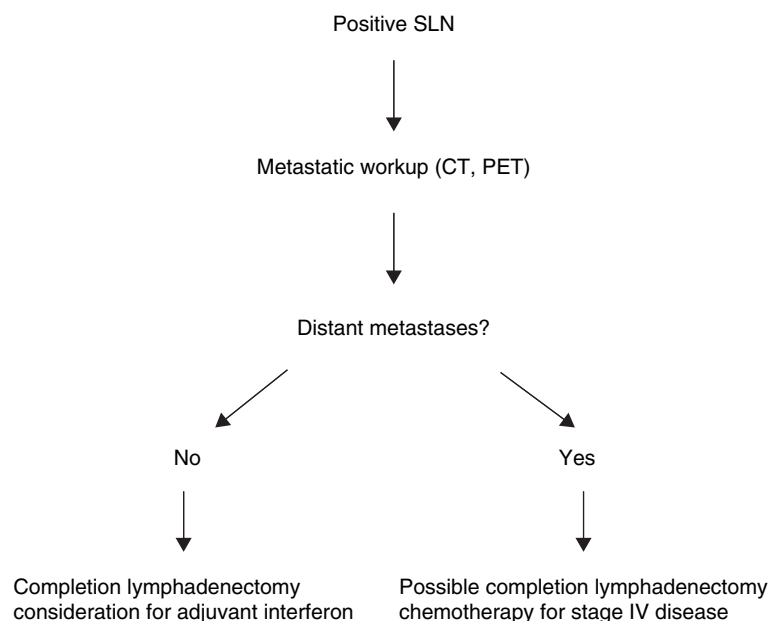
### Management of the regional nodal basin

When melanoma metastasizes, regional lymph nodes are usually the first-detected site of spread. In fact, it is relatively rare for patients who develop distant metastatic melanoma to never manifest nodal metastasis at some point in time, although nodal metastasis is not always the first-detected site of disease<sup>28</sup>. Of course, many patients with nodal metastasis will develop distant metastatic disease in time. Yet there is a significant and reproducible fraction of patients with positive nodes (palpable or microscopic) who never develop distant

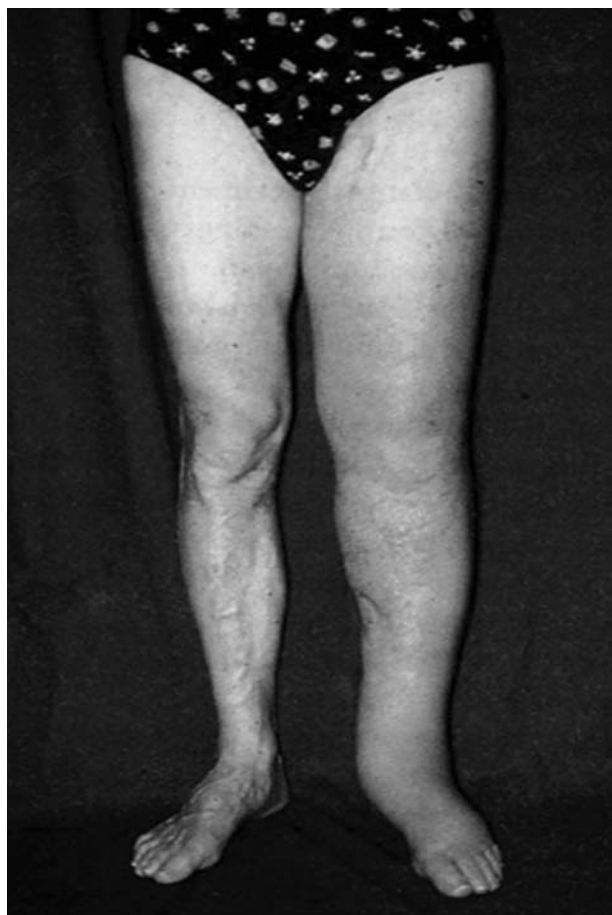metastatic disease after regional lymph node dissection. The population of patients presumably cured by regional lymphadenectomy is generally in the range of 25–35% in older studies in which predominantly patients with palpable nodal metastases were evaluated<sup>15,29</sup>. In more contemporary data in which early nodal metastases are detected by sentinel lymph node biopsy, the 5-year survival rate for patients who have undergone lymph node dissection for a single positive sentinel node exceeds 70%.

As stated previously, patients found to harbor metastatic melanoma within a sentinel node should be considered for completion lymphadenectomy (Figure 27.8). To date, there are no definitive predictive factors that permit the identification of a patient population that may safely avoid completion lymphadenectomy following a positive sentinel node biopsy. Full lymphadenectomy is not without risk. The most common complications associated with lymphadenectomy include wound infection, seroma formation, pain, and lymphedema. Chronic lymphedema is a significant problem, as it is not only cosmetically disturbing, but it may impair the patient's function (Figure 27.9).

Axillary lymphadenectomy for melanoma differs from that for breast cancer; a full level I–III node dissection is required and should include all of the node-bearing fatty tissue proximal to Halstead's ligament. For bulky disease, dividing the pectoralis minor muscle just below the clavicle may facilitate the proximal extent of this operation. The operative technique for iliofemoral lymphadenectomy



**Figure 27.8** Treatment algorithm for patients metastatic melanoma in a sentinel lymph node.



**Figure 27.9** Chronic lymphedema following an inguinal lymphadenectomy for metastatic melanoma.

includes removal of the fatty tissue within the femoral triangle, which is bordered by the sartorius muscle, the adductor longus, and the inguinal ligament. Careful dissection of the femoral vessels will permit complete lymphadenectomy. A transverse, or oblique incision across the upper thigh or inguinal region heals better with fewer wound complications than a longitudinal incision down the thigh. Cloquet's node<sup>9</sup> which is the lymph node just behind the inguinal ligament and medial to the femoral vein, should be removed. Some surgeons routinely evaluate Cloquet's node by frozen section histopathology, and if positive for cancer, will perform iliac and obturator node dissection. Since Cloquet's node may be considered the 'sentinel node to the iliac chain', a full iliac and obturator lymphadenectomy should be performed when it contains metastatic melanoma. Additionally, when these nodes contain clinically palpable disease, a lymphadenectomy often leads to reasonable palliation, as bulky nodal disease is difficult to treat without surgical clearance of the nodes. The exposed femoral vessels should be covered with a sartorius

rotational flap for additional safety and coverage; this simple maneuver greatly facilitates wound healing in the event of infection.

Iliac and obturator lymphadenectomy is best accomplished by extending the incision up to the anterior-superior iliac spine and dividing the muscles and fascia while reflecting the peritoneum medially. Alternatively, a separate retroperitoneal incision may be used (similar to that performed during a renal transplant) to expose the iliac and obturator nodes. For obese patients, sometimes a midline laparotomy incision may give better exposure and vascular control than a retroperitoneal incision. The nodal tissues are located medially along the iliac vessels, and along the obturator nerve, which is deep between the internal and external iliac veins. Melanoma metastases to neck nodes are managed with standard lymphadenectomy operations used for management for head and neck primary cancers.

Some patients will develop multiple in-transit or satellite melanoma tumors following definitive surgical treatment. Although not considered a curable situation, these patients may derive excellent palliation and regional control with an isolated limb perfusion. This is a technique that uses hyperthermic cytotoxic chemotherapy perfused via the inflow arterial system, collected by the venous outflow vessels, and recirculated through a roller-pump machine (such as one used during cardiac surgery). The most common agents used for isolated hyperthermic limb perfusion include melphalan and tumor necrosis factor. In appropriately selected patients without vascular disease and melanoma isolated to the limb, perfusion can give excellent control. This technique represents advanced palliative surgery, and as such, should be approached with great care. An alternative is isolated limb infusion, which differs in approach to the vessels; perfusion involves surgical access to the vessels with direct cannulation, while infusion involves percutaneous access to the vessels. There have been no controlled studies comparing the two techniques, but infusion may be associated with fewer wound complications.

## ADJUVANT SYSTEMIC THERAPY

While the surgical therapy for melanoma has improved over the past few decades with improvements in surgical techniques and the advent of sentinel lymph node biopsy as a minimally invasive staging procedure, adjuvant therapy remains somewhat limited. Interferon  $\alpha$ -2b is the only agent that has been approved by the US Food and Drug Administration for adjuvant therapy of high-risk melanoma. Interferons are naturally occurring immunostimulants that have been studied for over two decades as a

potential therapeutic option for patients with melanoma. Three randomized trials have shown that high dose interferon  $\alpha$ -2b given to patients with nodal metastases improves disease-free survival, and overall survival was improved in two of the three studies<sup>30–32</sup>. However, toxicity associated with this treatment is significant, and the magnitude of the benefit small. Despite these data, other trials of adjuvant interferon have found little or no benefit<sup>33</sup>. High-dose interferon  $\alpha$ -2b is given as an infusion 5 days per week for the first 4 weeks, followed by subcutaneous injections three times per week for the next 11 months; patients frequently report significant malaise and fatigue, and these toxicities often result in either dose-reduction or termination of therapy. Additionally, patients with significant co-morbidities and elderly patients may not be eligible for high dose interferon therapy.

Occasional spontaneous tumor regression and other immune-modulated phenomena observed in melanoma have led researchers to investigate techniques of immune modulation as a form of adjuvant therapy. As a form of immune therapy, vaccines directed against melanoma-associated antigens have been evaluated. Strategies to develop an effective melanoma vaccine have included allogeneic melanoma cell lysates, whole-cell melanoma vaccines, anti-idiotypic antibody vaccines, specific peptide or ganglioside vaccines, and autologous vaccines. Vaccines are attractive as a form of therapy, as they are better tolerated when compared with traditional cytotoxic chemotherapy, and some preliminary data have suggested dramatic responses in some patients. To date, completed adjuvant vaccine studies, using a ganglioside vaccine (GM2-KLH) and allogeneic melanoma cell lysates have demonstrated mixed results<sup>32,34</sup>. The field of tumor immunology and vaccine therapy continues to be an area of active research, and hopefully will lead to the development of an effective adjuvant therapy for patients afflicted with melanoma. At the present time, however, no vaccine therapy has been shown to be effective, either for treatment of stage IV disease or as adjuvant therapy. Further research is clearly needed.

## ADJUVANT RADIOTHERAPY

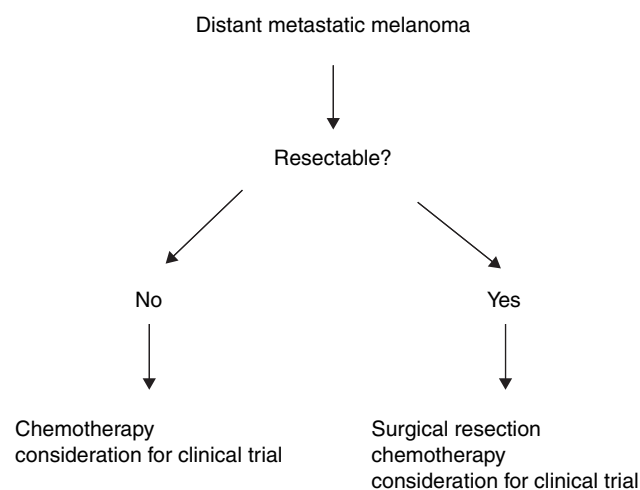
Adjuvant radiotherapy for cutaneous melanoma has been investigated for several decades. The early studies of radiotherapy demonstrated mixed results, with high local failures and disappointing rates of disease control. Modern series, however, have been more promising. Adjuvant radiotherapy may be used to aid with local control following resection of primary melanoma tumors in certain instances. In cases of extensive facial lentigo maligna

melanoma, especially in elderly patients, where radical resection would either be severely deforming or when medical co-morbidities are prohibitive, definitive external beam radiation therapy provides good local control. Additionally, desmoplastic melanoma, a histological subtype with a high risk of local recurrence following radical resection, has worse primary tumor characteristics, and thus may be at increased risk of local failure<sup>35</sup>. These melanomas may benefit from adjuvant radiotherapy following resection, although this has recently been questioned<sup>36</sup>.

In addition to selected use of adjuvant radiation therapy for primary tumors, some regional nodal metastases may benefit from postoperative external beam radiotherapy. Patients with multiple metastatic lymph nodes (more than four), macrometastatic nodal disease (>2 cm), evidence of extracapsular nodal extension, or those with head and neck melanoma may benefit from adjuvant radiotherapy to the affected nodal basin<sup>37,38</sup>. The addition of adjuvant radiation to a nodal basin with a heavy tumor burden (one or more of these factors) may decrease the risk of recurrent disease within the basin itself. However, the evidence to support adjuvant radiation therapy for melanoma is weak and inconclusive. Morbidity from the adjuvant radiation, namely lymphedema, appears to be manageable.

## Radiation for metastatic melanoma

Since patients with metastatic melanoma are rarely cured with surgery, non-operative methods of palliation for distant metastatic disease are attractive. Radiation therapy has been used to treat metastatic melanoma in multiple settings. External beam radiotherapy is



**Figure 27.10** Treatment algorithm for patients with distant metastatic melanoma.

quite effective in treating dermal and subcutaneous metastases<sup>39</sup>, as well as controlling clinically evident nodal disease in patients with distant metastases, especially when given before the nodal disease reaches massive size<sup>40</sup>. In addition, brain metastases may be treated with external beam radiation<sup>41</sup>. Stereotactic radiation for brain metastases may prolong life, and this technique seems to be well tolerated<sup>42</sup>. In addition, symptomatic bone metastases are amenable to a short-course of external beam radiotherapy, with good palliation of pain.

## CHEMOTHERAPY FOR METASTATIC MELANOMA

Unfortunately, many patients afflicted with melanoma will develop distant metastases. Stage IV melanoma is associated with a poor prognosis, with 5- and 10-year survival rates of 7–19% and 2–16%, respectively<sup>13</sup>. These unfortunate patients are best managed with systemic chemotherapy, as stage IV melanoma truly represents widely disseminated disease. Currently, dacarbazine is recognized as standard therapy for metastatic melanoma, either as a single agent or in combination therapy. Additionally, investigators have tried to exploit the gender-related differences in outcome, and have studied the effect of hormonal manipulation for patients with advanced melanoma. Early data reported increased response rates when tamoxifen was combined with cytotoxic chemotherapy<sup>43,44</sup>. These phase II data, however, have not been replicated in randomized phase III trials<sup>45,46</sup> or by a

recent meta-analysis<sup>47</sup>. To date, the most widely accepted therapy for metastatic melanoma remains dacarbazine-based chemotherapy, as no definitive evidence exists to support the use of hormonal therapy for treatment of melanoma.

In addition to traditional cytotoxic chemotherapy, strategies to combine immune modulators with chemotherapeutic agents have been employed in patients with metastatic melanoma. So called 'biochemotherapy' regimens, which typically involve an aggressive combination of interleukin-2, interferon and standard chemotherapeutic agents, have demonstrated reasonable response rates in selected patients with stage IV disease. Furthermore, a minority of patients with distant metastases ( $\leq 10\%$ ) has achieved durable long-term complete responses with this approach.

## SURGERY FOR METASTATIC MELANOMA

Given the lack of effective systemic therapy for stage IV melanoma, one should never overlook the opportunity to render a patient surgically free of disease when possible (Figure 27.10). Some patients will have a remarkably long disease-free interval after resection, and others are potentially cured by resection of even visceral organ metastases<sup>48</sup>. Patients with widely disseminated disease are best treated on clinical trials of novel therapy. Patients with liver, lung, bowel, brain, and other sites of metastasis should be considered for resection. Careful patient selection may permit reasonable survival for these patients<sup>49,50</sup>.

## REFERENCES

1. American Cancer Society. Cancer Facts and Figures, 2004. 1–58. 2004.
2. Reintgen DS, McCarty KS Jr, Cox E, Seigler HF. Malignant melanoma in the American black. *Curr Surg* 1983; 40: 215–7.
3. Martin RC, Scoggins CR, Ross MI et al. Is incisional biopsy of melanoma harmful? *Am J Surg* 2005; 190: 913–7.
4. Balch CM, Soong SJ, Gershenwald JE et al. Prognostic factors analysis of 17,600 melanoma patients: validation of the American Joint Committee on Cancer melanoma staging system. *J Clin Oncol* 2001; 19: 3622–34.
5. Essner R, Conforti A, Kelley MC et al. Efficacy of lymphatic mapping, sentinel lymphadenectomy, and selective complete lymph node dissection as a therapeutic procedure for early-stage melanoma. *Ann Surg Oncol* 1999; 6: 442–9.
6. McMasters KM, Noyes RD, Reintgen DS et al. Lessons learned from the Sunbelt Melanoma Trial. *J Surg Oncol* 2004; 86: 212–3.
7. Chao C, Martin RC, Ross MI et al. Correlation between prognostic factors and increasing age in melanoma. *Ann Surg Oncol* 2004; 11: 259–64.
8. Statius Muller MG, van Leeuwen PA, de Lange-De Klerk ES et al. The sentinel lymph node status is an important factor for predicting clinical outcome in patients with stage I or II cutaneous melanoma. *Cancer* 2001; 91: 2401–8.
9. Balch CM. Cutaneous melanoma: prognosis and treatment results worldwide. *Semin Surg Oncol* 1992; 8: 400–14.
10. Gershenwald JE, Thompson W, Mansfield PF et al. Multi-institutional melanoma lymphatic mapping experience: the prognostic value of sentinel lymph node status in 612 stage I or II melanoma patients. *J Clin Oncol* 1999; 17: 976–83.
11. Greene FL, Page DL, Fleming ID et al. *AJCC Cancer Staging Manual*, 6th edn. New York: Verlang-Springer 2002.
12. Barth A, Wanek LA, Morton DL. Prognostic factors in 1,521 melanoma patients with distant metastases. *J Am Coll Surg* 1995; 181: 193–201.

13. Balch CM, Buzaid AC, Soong SJ et al. Final version of the American Joint Committee on Cancer staging system for cutaneous melanoma. *J Clin Oncol* 2001; 19: 3635–48.
14. Balch CM, Murad TM, Soong SJ et al. Tumor thickness as a guide to surgical management of clinical stage I melanoma patients. *Cancer* 1979; 43: 883–8.
15. Balch CM, Soong SJ, Milton GW et al. A comparison of prognostic factors and surgical results in 1,786 patients with localized (stage I) melanoma treated in Alabama, USA, and New South Wales, Australia. *Ann Surg* 1982; 196: 677–84.
16. Balch CM, Soong SJ, Bartolucci AA et al. Efficacy of an elective regional lymph node dissection of 1 to 4 mm thick melanomas for patients 60 years of age and younger. *Ann Surg* 1996; 224: 255–63.
17. Reintgen DS, Cox EB, McCarty KS Jr et al. Efficacy of elective lymph node dissection in patients with intermediate thickness primary melanoma. *Ann Surg* 1983; 198: 379–85.
18. Veronesi U, Adamus J, Bandiera DC et al. Delayed regional lymph node dissection in stage I melanoma of the skin of the lower extremities. *Cancer* 1982; 49: 2420–30.
19. Morton DL, Wen DR, Wong JH et al. Technical details of intraoperative lymphatic mapping for early stage melanoma. *Arch Surg* 1992; 127: 392–9.
20. Ross MI, Reintgen D, Balch CM. Selective lymphadenectomy: emerging role for lymphatic mapping and sentinel node biopsy in the management of early stage melanoma. *Semin Surg Oncol* 1993; 9: 219–23.
21. Reintgen D, Cruse CW, Wells K et al. The orderly progression of melanoma nodal metastases. *Ann Surg* 1994; 220: 759–67.
22. McMasters KM, Wong SL, Edwards MJ et al. Frequency of nonsentinel lymph node metastasis in melanoma. *Ann Surg Oncol* 2002; 9: 137–41.
23. Stitzenberg KB, Groben PA, Stern SL et al. Indications for lymphatic mapping and sentinel lymphadenectomy in patients with thin melanoma (Breslow thickness  $\leq$  1.0 mm). *Ann Surg Oncol* 2004; 11: 900–6.
24. McMasters KM, Wong SL, Edwards MJ et al. Factors that predict the presence of sentinel lymph node metastasis in patients with melanoma. *Surgery* 2001; 130: 151–6.
25. Sondak VK, Taylor JM, Sabel MS et al. Mitotic rate and younger age are predictors of sentinel lymph node positivity: lessons learned from the generation of a probabilistic model. *Ann Surg Oncol* 2004; 11: 247–58.
26. Karakousis CP, Balch CM, Urist MM et al. Local recurrence in malignant melanoma: long-term results of the multiinstitutional randomized surgical trial. *Ann Surg Oncol* 1996; 3: 446–52.
27. Slingluff CL Jr, Vollmer RT, Seigler HF. Anorectal melanoma: clinical characteristics and results of surgical management in twenty-four patients. *Surgery* 1990; 107: 1–9.
28. Gershenwald JE, Colome MI, Lee JE et al. Patterns of recurrence following a negative sentinel lymph node biopsy in 243 patients with stage I or II melanoma. *J Clin Oncol* 1998; 16: 2253–60.
29. Balch CM, Soong S, Ross MI et al. Long-term results of a multi-institutional randomized trial comparing prognostic factors and surgical results for intermediate thickness melanomas (1.0 to 4.0 mm). Intergroup Melanoma Surgical Trial. *Ann Surg Oncol* 2000; 7: 87–97.
30. Kirkwood JM, Strawderman MH, Ernstoff MS et al. Interferon alfa-2b adjuvant therapy of high-risk resected cutaneous melanoma: the Eastern Cooperative Oncology Group Trial EST 1684. *J Clin Oncol* 1996; 14: 7–17.
31. Kirkwood JM, Ibrahim JG, Sondak VK et al. High- and low-dose interferon alfa-2b in high-risk melanoma: first analysis of intergroup trial E1690/S9111/C9190. *J Clin Oncol* 2000; 18: 2444–58.
32. Kirkwood JM, Ibrahim JG, Sosman JA et al. High-dose interferon alfa-2b significantly prolongs relapse-free and overall survival compared with the GM2-KLH/QS-21 vaccine in patients with resected stage IIB–III melanoma: results of intergroup trial E1694/S9512/C509801. *J Clin Oncol* 2001; 19: 2370–80.
33. Hancock BW, Wheatley K, Harris S et al. Adjuvant interferon in high-risk melanoma: the AIM HIGH Study – United Kingdom Coordinating Committee on Cancer Research randomized study of adjuvant low-dose extended-duration interferon Alfa-2a in high-risk resected malignant melanoma. *J Clin Oncol* 2004; 22: 53–61.
34. Sondak VK, Liu PY, Tuthill RJ et al. Adjuvant immunotherapy of resected, intermediate-thickness, node-negative melanoma with an allogeneic tumor vaccine: overall results of a randomized trial of the Southwest Oncology Group. *J Clin Oncol* 2002; 20: 2058–66.
35. Livestro DP, Muzikansky A, Kaine EM et al. Biology of desmoplastic melanoma: a case-control comparison with other melanomas. *J Clin Oncol* 2005; 23: 6739–46.
36. Arora A, Lowe L, Su L et al. Wide excision without radiation for desmoplastic melanoma. *Cancer* 2005; 104: 1462–7.
37. Ross M, Meyer JL. Management of the regional lymph nodes in malignant melanoma: surgery, radiotherapy or observation. *Front Radiat Ther Oncol* 1994; 28: 226–34.
38. Ballo MT, Zagars GK, Gershenwald JE et al. A critical assessment of adjuvant radiotherapy for inguinal lymph node metastases from melanoma. *Ann Surg Oncol* 2004; 11: 1079–84.
39. Bentzen SM, Overgaard J, Thames HD et al. Clinical radiobiology of malignant melanoma. *Radiother Oncol* 1989; 16: 169–82.
40. Overgaard J, Overgaard M, Hansen PV, von der MH. Some factors of importance in the radiation treatment of malignant melanoma. *Radiother Oncol* 1986; 5: 183–92.
41. Carella RJ, Gelber R, Hendrickson F et al. Value of radiation therapy in the management of patients with cerebral metastases from malignant melanoma: Radiation Therapy Oncology Group Brain Metastases Study I and II. *Cancer* 1980; 45: 679–83.
42. Bhatnagar AK, Flickinger JC, Kondziolka D, Lunsford LD. Stereotactic radiosurgery for four or more intracranial metastases. *Int J Radiat Oncol Biol Phys* 2005.
43. Rumke P, Kleeberg UR, MacKie RM et al. Tamoxifen as a single agent for advanced melanoma in postmenopausal women. A phase II study of the EORTC Malignant Melanoma Cooperative Group. *Melanoma Res* 1992; 2: 153–6.
44. Cocconi G, Bella M, Calabresi F et al. Treatment of metastatic malignant melanoma with dacarbazine plus tamoxifen. *N Engl J Med* 1992; 327: 516–23.
45. Agarwala SS, Ferri W, Gooding W, Kirkwood JM. A phase III randomized trial of dacarbazine and carboplatin with and without tamoxifen in the treatment of patients with metastatic melanoma. *Cancer* 1999; 85: 1979–84.
46. Chapman PB, Einhorn LH, Meyers ML et al. Phase III multicenter randomized trial of the Dartmouth regimen versus dacarbazine in patients with metastatic melanoma. *J Clin Oncol* 1999; 17: 2745–51.

47. Lens MB, Reiman T, Husain AF. Use of tamoxifen in the treatment of malignant melanoma. *Cancer* 2003; 98: 1355–61.
48. Essner R, Lee JH, Wanek LA et al. Contemporary surgical treatment of advanced-stage melanoma. *Arch Surg* 2004; 139: 961–6.
49. Weitz J, Blumgart LH, Fong Y et al. Partial hepatectomy for metastases from noncolorectal, nonneuroendocrine carcinoma. *Ann Surg* 2005; 241: 269–76.
50. Crook TB, Jones OM, John TG, Rees M. Hepatic resection for malignant melanoma. *Eur J Surg Oncol* 2005.

## RELEVANT WEBSITES

General facts regarding melanoma:

[www.melanoma.com](http://www.melanoma.com)

[www.mpip.org](http://www.mpip.org)

Latest research updates and clinical trials available for melanoma patients:

[www.melanoma.org](http://www.melanoma.org)

<http://www.cancer.gov/cancertopics/wyntk/melanoma>



Barney Harrison and Sabapathy P Balasubramanian

---

## ANATOMY AND PHYSIOLOGY OF THE ADRENAL GLAND

The adrenal glands are situated within a compartment of the renal fascia in relation to the upper poles of the kidneys. The right is smaller and triangular, and the left larger and crescentic. The right adrenal gland is located partially behind the inferior vena cava and superior to the right kidney, whereas the left adrenal is anteromedial to the left kidney. The arterial blood supply for both glands arises from the abdominal aorta and the respective inferior phrenic and renal arteries. The venous drainage is chiefly via the main adrenal vein that drains into the inferior vena cava on the right and the renal vein on the left side. Histologically, the adrenal gland is comprised of an outer cortex derived from mesoderm and an inner medulla derived from the neural crest, i.e. the ectoderm. Table 28.1 shows the hormones secreted by the various layers of the adrenal gland and their key regulatory mechanisms.

This chapter focuses chiefly on adrenal malignancies with a brief mention of functioning adenomas and incidentalomas. The medical management of patients with functioning tumors, adrenal hyperplasia and pediatric adrenal tumors are beyond the scope of this chapter.

## EPIDEMIOLOGY

Adrenal gland tumors arise from the cortex or the medulla and can be benign or malignant; the latter being either primary or secondary. Tumors may be functioning or non-functioning (Table 28.2). Functioning tumors secrete hormones which may either present as specific clinical syndromes or are diagnosed on biochemical testing (sub-clinical tumors).

Adrenal tumors are relatively rare in comparison with tumors in other organs. Incidentally detected tumors of the adrenal gland (incidentalomas) are on the increase in parallel with the increased use of cross-sectional imaging techniques including computed tomography (CT) and magnetic resonance imaging (MRI). Incidentalomas are

present in approximately 2.1% of individuals from autopsy series and the incidence rises with age<sup>1</sup>.

Cushing's syndrome (all causes) affects mainly adults aged 20–50 years with an incidence of 2.5 per million population per year<sup>2</sup>. The incidence of Conn's syndrome is around 0.8 per million per year<sup>3</sup> and the incidence of pheochromocytomas ranges from 1.55 to 1.9 per million per year<sup>3,4</sup>.

Adrenocortical carcinomas (ACC) also occur infrequently with reported age-adjusted incidence rates of 1.5 per million per year<sup>5</sup>. As a proportion of cases may go undetected, these figures are likely to underestimate the true incidence. ACC typically has a bimodal age distribution in the first and fourth decades of life<sup>6</sup>. Adrenal tumors can be sporadic or familial. Although no environmental risk factors have been identified, genetic predisposition may underlie a significant proportion of them. Familial syndromes associated with an increased risk of cortical and medullary tumors are shown in Table 28.3.

## PRESENTATION

### Hormonal effects

Clinical effects of hormones secreted by the tumor include hyperaldosteronism, hypercortisolism, pheochromocytoma, and virilizing or feminizing features. Around 60% of adrenocortical malignancies present with evidence of steroid hormone excess<sup>7</sup>.

Primary hyperaldosteronism results from excess secretion of aldosterone from the adrenal cortex. This usually arises either from an adenoma (Conn's syndrome) or from bilateral adrenal hyperplasia. Rare causes include unilateral adrenal hyperplasia, ACC and glucocorticoid-suppressible hyperaldosteronism. In patients with hypertension, careful screening will reveal primary hyperaldosteronism occurs in 5–13%, of which aldosterone producing adenoma is the cause in about 28%<sup>8</sup>. The only specific clinical feature is hypertension. Biochemical findings include hypokalemia, hypernatremia, alkalosis, raised plasma aldosterone, and low plasma renin activity.



**Table 28.1** Hormones secreted by the various layers of the adrenal gland and their principal regulatory mechanisms

<i>Adrenal gland</i>	<i>Hormones</i>	<i>Regulation</i>
<i>Cortex</i>		
Zona glomerulosa (15%)	Aldosterone	Renin–angiotensin system
Zona reticularis (70%)	Cortisol, sex steroids	ACTH (negative feedback mechanism)
Zona fasciculata (15%)	Sex steroids	ACTH (negative feedback mechanism)
<i>Medulla</i>	Catecholamines and metabolites	As part of the autonomic nervous system

ACTH, adrenocorticotrophic hormone.

**Table 28.2** Adrenal tumors or tumor-like lesions

<i>Adrenal cortex</i>	
Adenomas – functioning and non-functioning	
Adrenocortical carcinoma – functioning and non-functioning	
<i>Adrenal medulla</i>	
Pheochromocytoma – benign and malignant	
Ganglioneuroma, ganglioneuroblastoma and neuroblastoma	
<i>Miscellaneous</i>	
Adrenal metastases	
Cysts	
Hematomas	
Myelolipomas	
Other rare tumors	

Hypercortisolism results from excess secretion of cortisol from the adrenal cortex. The excess secretion can be adrenocorticotrophic hormone (ACTH) dependent (excess ACTH secretion from the pituitary (in 70%) when it is referred to as Cushing's disease) or ectopic sites (in 15%) or ACTH independent (in 15%). The latter are usually due to adrenal adenomas or carcinomas but can rarely be due to bilateral hyperplasia, primary pigmented nodular adrenal disease (Carney's complex), or McCune-Albright syndrome<sup>9</sup>. Clinical features include abnormal fat deposition, myopathy, fragile skin with easy bruising and poor healing, osteopenia, hypertension, diabetes, psychological symptoms, reduced libido, menstrual irregularities and hirsutism in women, and growth retardation in children.

Pheochromocytoma arises from the adrenal medulla or extra-adrenal chromaffin tissue resulting in the

hypersecretion of catecholamines and their metabolites. They may be asymptomatic or present as cardiovascular syndromes (such as myocardial infarction, arrhythmias and uncontrolled hypertension), cerebrovascular accidents, hyperglycemia, panic attacks, and anxiety. Previously undiagnosed pheochromocytoma may be incidentally detected at abdominal surgery. No attempt should be made to excise the pheochromocytoma in a pharmacologically unprepared patient. Pheochromocytoma is rarely encountered in pregnancy or labor when it may be confused with other hypertensive syndromes related to pregnancy. Delayed diagnosis can adversely affect both mother and fetus<sup>9</sup>.

Virilizing and feminizing tumors of the adrenal gland are extremely uncommon and often associated with raised levels of other hormones such as cortisol. They are almost always symptomatic and malignant.

### Local symptoms

Malignant non-functioning adrenal tumors can infiltrate the retroperitoneum and adjacent organs and present with local pressure symptoms such as pain and hemorrhage or organ-specific symptoms from metastases.

### Incidental lesions

Adrenal lesions (Table 28.2) are often detected as an incidental finding during investigation of other abdominal pathology (incidentalomas). The prevalence of such lesions ranges from 0.1% during general health screening with ultrasound to 4.3% in cancer patients. These lesions become increasingly common with age, with a prevalence of 7% in patients aged 70 and above<sup>1</sup>. The reported incidence of functioning tumors in adrenal incidentalomas varies widely due to variation in the extent of biochemical screening. A prospective audit of patients from 33 hospitals in Sweden showed that 5% of lesions in 381 patients were hormonally active<sup>10</sup>.

Table 28.3 Familial syndromes associated with adrenal lesions

<i>Adrenal tumors</i>	<i>Syndrome</i>	<i>Chromosomal defects</i>	<i>Key clinical features</i>
Adrenocortical tumors	Carney's complex	Heterogenous disease with defects localized to 2p16 and the PRKARIA gene in 17q22	Primary pigmented, nodular adrenocortical disease (PPNAD), lentigenes, ephelides, blue nevi of skin and mucosa, various non-endocrine and endocrine tumors
	Congenital adrenal hyperplasia	Defect in the 21-hydroxylase gene in chromosome 6p21.3	Classical form is early onset virilization of external genitalia in females, hypocortisolism, precocious puberty in both sexes. Late onset can also occur
	Li-Fraumeni syndrome	Defect in TP53 gene in chromosome 17q13	Soft tissue sarcoma, breast cancer, leukemia, brain tumors, adrenocortical carcinoma
	McCune-Albright syndrome	Defect in GNAS1 gene in chromosome 20q13	Polyostotic fibrous dysplasia, precocious puberty, café au lait spots, hyperfunction of thyroid, pituitary and adrenal glands
	Multiple endocrine neoplasia type 1	Defect in Menin gene in chromosome 11q13	Pituitary, parathyroid and pancreatic tumors. Adrenocortical tumors are usually adenomas and hyperplasia and rarely carcinoma
Pheochromocytoma	Beckwith-Wiedemann syndrome	Several genetic and epigenetic defects localized to chromosome 11p15	Omphalocele, macroglossia, macrosomia, hemihypertrophy, Wilm's tumor, adrenocortical carcinoma
	Von Hippel Lindau type II	Defect in the VHL gene in chromosome 3p25-26	Associated anomalies in this syndrome include retinal and central nervous system hemangioblastomas, endolymphatic sac tumors, epididymal cystadenomas, renal-cell cysts and carcinomas, pancreatic neoplasms and cysts
	Multiple endocrine neoplasia type II	Defect in the RET gene in chromosome 10q11.2	Associated conditions in MEN IIa include medullary thyroid carcinoma, hyperparathyroidism and cutaneous lichen amyloidosis and in MEN IIb include mucosal ganglioneuromas and marfanoid habitus
	Neurofibromatosis type I	Defect in NF1 gene in chromosome 17q11.2	Associated conditions include multiple fibromas on skin and mucosae and café au lait skin spots
	Paraganglioma syndromes	Defects in mitochondrial genes SDHB (in chromosome 1p36.13) and SDHD (in chromosome 11q23)	Associated conditions include head and neck tumors, abdominal and thoracic paragangliomas

## SCREENING AND DIAGNOSTIC STRATEGIES

### Screening

The rarity of adrenal malignancies and the relative abundance of incidental benign lesions make adrenal cancer and pheochromocytoma unsuitable diseases for general population screening. Screening by abdominal CT and biochemical testing may be appropriate for those proven to be gene carriers of familial syndromes described in Table 28.3.

### Diagnosis

An important principle in the investigation of functioning adrenal lesions is the need for biochemical confirmation of a suspected clinical syndrome before anatomical localization of the tumor by imaging. Patients with incidentalomas and those presenting with local symptoms must undergo initial biochemical testing, even if apparently asymptomatic.

Biochemical testing is mandatory in the evaluation of all adrenal masses to confirm a suspected clinical diagnosis, to detect subclinical hormonal syndromes, to obtain baseline hormonal levels in patients with functioning tumors, and, after treatment, to confirm biochemical cure and detect recurrence.

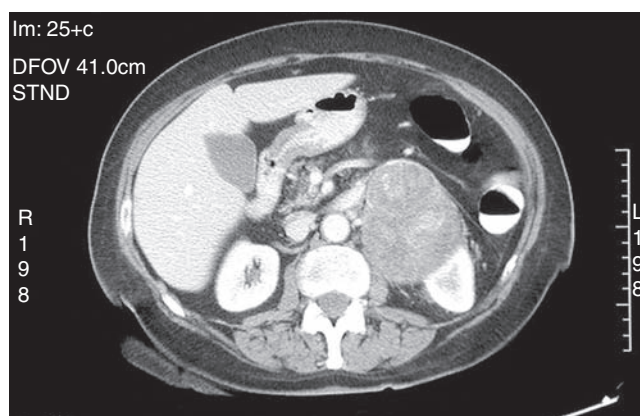
- (1) *Cushing's syndrome* Confirmation of hypercortisolism by measurement of urinary free cortisol, midnight plasma or late night salivary cortisol and low dose (overnight and 48-hour) dexamethasone suppression test. The cause of hypercortisolism is determined by measuring plasma ACTH, corticotropin releasing hormone (CRH) test and sometimes a high dose dexamethasone suppression test<sup>8</sup>.
- (2) *Pheochromocytoma* Urine and plasma catecholamines (epinephrine and norepinephrine) and their metabolites (metanephrine, normetanephrine and vanillylmandelic acid) are commonly measured. Plasma free metanephrines have been shown to be a highly accurate test for the diagnosis of pheochromocytoma<sup>12</sup>.
- (3) *Conn's syndrome* In patients with hypertension, serum potassium, plasma aldosterone levels and renin activity are measured to diagnose hyperaldosteronism. A raised plasma aldosterone concentration to plasma renin activity ratio is a sensitive test for autonomous aldosterone production.<sup>7</sup>
- (4) *Sex hormone secreting tumors* Serum levels of dehydroepiandrosterone (DHEA), 17-OH-progesterone,

androstenedione, testosterone, and 17- $\beta$ -estradiol are measured in patients with feminizing or virilizing syndromes.

Many of these tests have a normal range, a borderline range and a clearly abnormal range. The tests have differing sensitivities and specificities depending on the threshold level chosen. A combination of tests may often provide more information than a single one. It is important to keep in mind that several variables such as drugs and dietary factors influence the results of these tests and that repeat measurements are often of value in borderline scenarios. Interested readers are referred to other sources for detailed information on these and additional tests<sup>1,8,9,12-14</sup>.

*Cross-sectional imaging* is essential to confirm the adrenal abnormality, the laterality and size, to identify obvious malignant features, and to monitor for recurrence. In patients with an incidentaloma, adrenal cancer accounts for 2% of tumors that are 4 cm or less, 6% of tumors 4.1–6 cm, and 25% of tumors greater than 6 cm<sup>1</sup>. CT scan is the currently preferred modality for the diagnosis and characterization of adrenal tumors (Figure 28.1). Density measurements on non-contrast CT, enhancement patterns on contrast and delayed washout images are all important in the characterization of adrenal tumors. MRI is as effective as CT scan and can be used to evaluate lesions that are indeterminate on CT.

Findings suggestive of malignancy include invasion into adjacent structures, associated lymphadenopathy, presence of metastases, irregular tumor margins, heterogeneity, and more than 10 Hounsfield units on CT scan. MRI features of malignancy also include reduced fat content, isointensity to liver on T1 images, intermediate to



**Figure 28.1** A cross-sectional CT image showing a heterogeneous adrenal tumor on the left side. Histology confirmed adrenocortical cancer.

moderate intensity on T2 images, and enhancement after gadolinium contrast with slow washout<sup>7</sup>.

**Functional imaging** using iodine-123 metaiodobenzylguanidine (MIBG) scanning is useful in the detection of pheochromocytomas (Figure 28.2) with a reported sensitivity and specificity of 91% and 100%, respectively<sup>15</sup>. It is strongly recommended in those at high risk of extra-adrenal disease. This includes those with a family history of pheochromocytoma, history suggestive of familial syndromes associated with pheochromocytoma and a large adrenal tumor (>5 cm)<sup>14</sup>. The use of adrenal scintigraphy with iodocholesterol analogs is not in widespread use in the UK.

*Localization tests* include the following:

- (1) Selective venous catheterization of the adrenal veins for differential determination of the aldosterone–cortisol ratio can help in differentiating between unilateral and bilateral Conn's disease. This is useful in patients with a high probability of an aldosterone

producing adenoma but with equivocal findings of unilateral disease on CT scan<sup>8</sup>.

- (2) Biopsy of adrenal tumors is rarely indicated in the management of adrenal tumors and should never be undertaken on retroperitoneal lesions in the region of the adrenal gland without ruling out a pheochromocytoma by biochemical testing. Comprehensive biochemical and imaging evaluation without need for a tissue diagnosis gives sufficient information for appropriate management in the vast majority of cases. Functioning tumors and those with a high risk of malignancy (>4 cm) need surgical excision and small non-functioning tumors can be observed safely. Relative indications for percutaneous biopsy, however, include large retroperitoneal tumors of uncertain origin, a non-functioning adrenal mass in a patient previously treated for cancer, and therapeutic aspiration of cysts<sup>16</sup>.

A pragmatic algorithm for the initial investigation and treatment of the adrenal mass is shown in Figure 28.3. This algorithm is only a guide that needs to be tailored to local facilities and expertise. Interpretation of the results of diagnostic tests and planning appropriate treatment requires multi-disciplinary input from a team comprising surgeons, endocrinologists, biochemists and radiologists.

## SURGERY

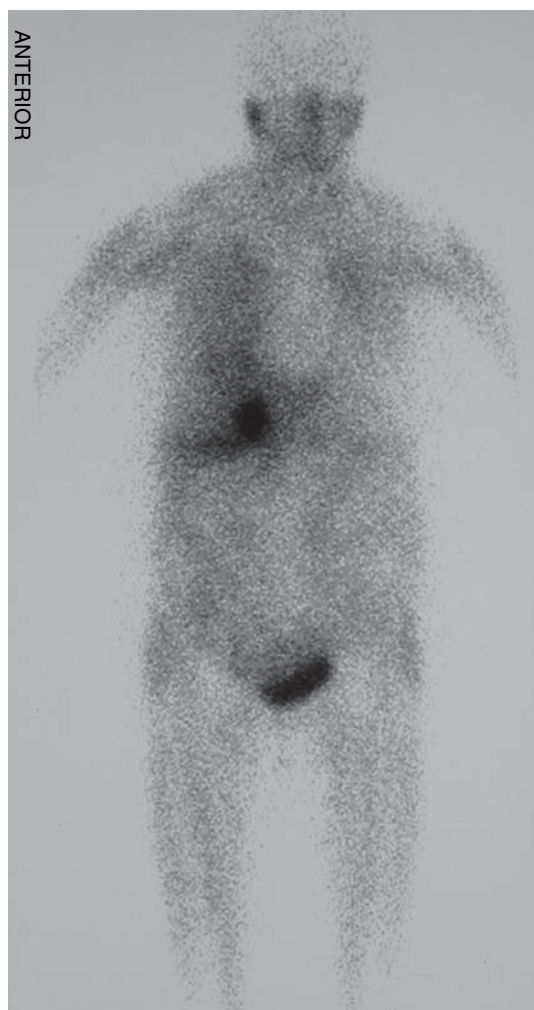
### Indications

Adrenalectomy is clearly indicated for masses with biochemical and/or radiological features suggestive of malignancy, in masses of more than 4 cm in diameter and in functioning tumors. Long-term cost benefits over medical therapy have also been demonstrated for patients with Conn's syndrome<sup>20</sup>, where the main objective is control of blood pressure and avoidance of side-effects of medication. The indications for surgery are less certain in patients with subclinical Cushing's syndrome with small tumors and Conn's syndrome with well controlled blood pressure. Small non-functioning lesions, asymptomatic adrenal cysts and myelolipomas can be managed conservatively.

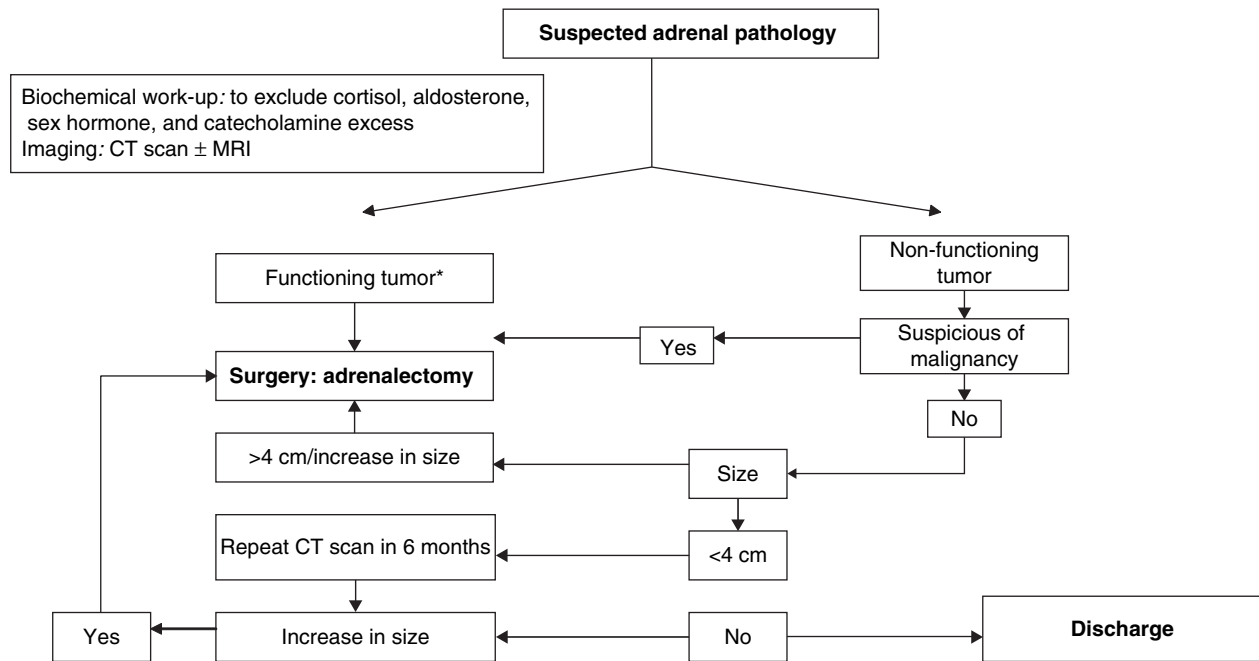
### Perioperative management

Adequate perioperative medical management of these patients in collaboration with medical endocrinologists and anesthetists is essential for a good outcome. Table 28.4 outlines the issues for consideration for any patient undergoing adrenalectomy.

Informed written consent prior to surgery should include the risk of conversion to open surgery, injury to



**Figure 28.2** Metaiodobenzylguanidine (MIBG) scan showing increased uptake on the right side in a patient with right adrenal pheochromocytoma.



**Figure 28.3** A suggested approach for diagnosis and treatment of adrenal gland tumours. \*The management of subclinical Cushing's syndrome and medically treated Conn's adenomas is controversial. Some of these patients may need further studies such as adrenal venous sampling to differentiate between single gland and bilateral diseases. CT, computed tomography; MRI, magnetic resonance imaging.

adjacent intra-abdominal viscera, the risk of residual and recurrent disease, major bleeding, wound and intra-abdominal infection, and general complications associated with major surgery such as chest infection, cardio-respiratory problems and deep venous thrombosis.

### Laparoscopic versus open adrenalectomy

Various surgical approaches are available for adrenalectomy (Table 28.5). The choice of operation depends on several factors including unilateral versus bilateral disease, likelihood of malignancy, tumor size, other abdominal disease or previous surgery, body habitus and the surgeon's familiarity with the various procedures.

Several observational studies have demonstrated the safety and efficacy of the laparoscopic approach, in addition to immediate benefits such as reduction in postoperative pain, blood loss and wound infection, reduced hospitalization, and early return to normal activity. The laparoscopic approach is now the preferred approach for all benign adrenal tumors<sup>13</sup> and can be considered suitable for tumors up to 10 cm in size. For tumors with a high likelihood of being malignant, the open approach is recommended due to oncological concerns regarding clearance and the risk of tumor seeding due to capsular rupture and tumor spillage during the laparoscopic approach. The laparoscopic approach for malignant tumors may thus be associated with a high risk of local recurrence<sup>21</sup>. A hand-assisted laparoscopic approach enables direct handling of the tumor and excision of larger tumors.

A thoracoabdominal approach may sometimes be required for excision of large lesions<sup>6</sup>.

### Transperitoneal and retroperitoneal approaches

The transperitoneal approach may be anterior or lateral; the retroperitoneal approach may be posterior or lateral. The transperitoneal approach with the patient in lateral position is most commonly used<sup>20</sup> with advantages of a larger working space and easily identifiable landmarks. The retroperitoneal approach, however, is said to be associated with shorter hospital stay and earlier recovery. This is especially true when the procedure is performed by experienced surgeons in large volume centers<sup>21</sup>. Two randomized controlled trials comparing the retroperitoneal and transperitoneal laparoscopic approaches did not find any significant difference in important clinical outcomes<sup>23,24</sup>. The transperitoneal approach may, however, be suitable in patients with previous retroperitoneal surgery and in those with large tumors; the retroperitoneal approach is used in those with previous intra-abdominal surgery, bilateral disease and those who are morbidly obese.

The key steps in laparoscopic adrenalectomy include correct positioning of the patient and port placement. In the transperitoneal approach, careful mobilisation of the liver on the right side and the spleen with the tail of the pancreas on the left side is important. In the retroperitoneal approach, high insufflation pressures (20 to 28 mm Hg) are considered crucial not only to improve exposure but

**Table 28.4** Issues to consider in patients undergoing adrenal-ectomy*General considerations*

Perioperative thromboprophylaxis (especially in those with hypercortisolism)  
 Critical care facilities in the early postoperative period  
 Availability of cross-matched blood  
 Appropriate postoperative tests to confirm biochemical cure and gradual steroid withdrawal or supplementation if necessary

*Pheochromocytoma*

Gradual increase of alfa-blockers to ensure maximum preoperative alfa-blockade  
 Avoid beta-blockers prior to adequate prior alfa-blockade  
 Adequate preoperative hydration to prevent postoperative hypotension  
 Intensive intra- and postoperative monitoring of blood pressure  
 Monitoring and treatment of postoperative hypoglycemia  
 Vaginal delivery is contraindicated when pheochromocytoma is diagnosed in the third trimester of pregnancy

*Cushing's syndrome*

Perioperative steroid supplementation to prevent relative adrenal insufficiency  
 Ensure adequate function by the other adrenal gland (by basal cortisol or synacthen test) before stopping steroids postoperatively

*Conn's syndrome*

Stop aldosterone antagonists postoperatively

also to minimize bleeding from small vessels<sup>21</sup>. Early identification and division of the major vessels facilitates further dissection and safe mobilization of the gland. Key principles of the operation are to avoid grasping the tumor or adrenal gland and the avoidance of incomplete resection of adrenal tissue particularly in patients undergoing bilateral surgery for Cushing's disease.

## MALIGNANT TUMORS OF THE ADRENAL GLAND: ADRENOCORTICAL CANCER, MALIGNANT PHEOCHROMOCYTOMA AND ADRENAL METASTASES

### Adrenocortical cancer

Most patients with ACC (~70%) present with clinical and/or biochemical evidence of hormonal excess<sup>24</sup>, often mixed. Non-functioning cancers may present with abdominal or back pain, with or without systemic symptoms of fever,

**Table 28.5** Surgical approaches to the adrenal gland*Laparoscopic approach*

Transperitoneal

Anterior

Lateral

Retroperitoneal

Lateral

Posterior

*Open approach*

Anterior

Posterior

Thoracoabdominal

**Table 28.6** Histological criteria of malignancy in adrenocortical lesions

High nuclear grade

High mitotic rate (>5/50 high power fields)

Atypical mitoses

Clear cells comprising  $\leq 25\%$  of the tumor

Diffuse architecture ( $\geq 33\%$  of tumor)

Microscopic necrosis

Venous invasion

Sinusoidal invasion

Capsular invasion

weight loss and anorexia. The diagnosis of ACC is usually confirmed by histology following an adrenalectomy. The distinction of benign from malignant adrenal tumors on histology may be difficult. Malignant potential is indicated by the presence of three or more<sup>25,26</sup> of nine histological features (Table 28.6). Broad fibrous bands are also a characteristic feature of malignant adrenocortical tumors<sup>7</sup>.

### Staging

For adrenocortical cancers, the Macfarlane staging system, initially proposed in 1958 and later modified by Sullivan *et al.*<sup>27</sup> along with a proposed TNM system<sup>24</sup>, is generally used (Table 28.7). Table 28.8 compares the two systems.

### Treatment

Adrenalectomy is the recommended treatment for stage I and II tumors. For patients with a clear preoperative diagnosis of malignancy, open surgery with en bloc resection of the adrenal gland and any enlarged lymph nodes offers the best chance of achieving R0 resection and thereby cure. Concomitant lymphadenectomy, nephrectomy and rarely



**Table 28.7** TNM system

<i>Tumor (T)</i>	
T1	Tumor ≤5 cm in size, invasion absent
T2	Tumor >5 cm in size, invasion absent
T3	Tumor locally invasive not involving adjacent organs
T4	Tumor invading adjacent organs
<i>Nodes (N)</i>	
N0	No nodal involvement
N1	Involvement of regional lymph nodes
<i>Metastases (M)</i>	
M0	No metastases
M1	Metastases present

**Table 28.8** Comparison of the TNM and Macfarlane staging for adrenocortical cancer

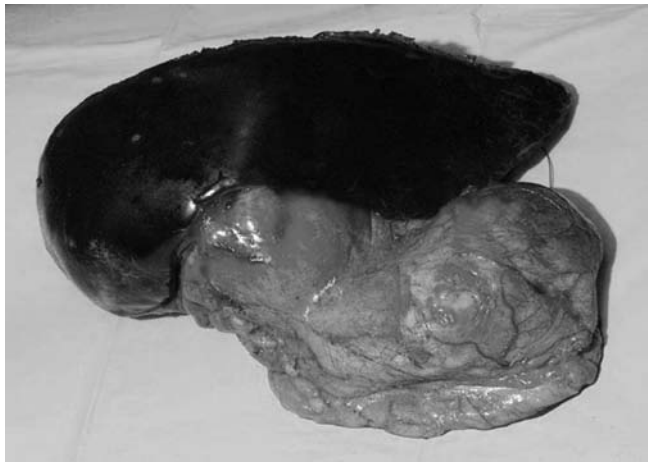<i>Macfarlane staging</i>	<i>Description of the Macfarlane staging</i>	<i>TNM</i>
I	<5 cm, confined to the adrenal gland	T1N0M0
II	>5 cm, confined to the adrenal gland	T2N0M0
III	Involvement of lymph nodes or tumor extending beyond the adrenal gland but without metastases	T1N1M0
		T2N1M0
		T3N0M0
IV	Tumor extending beyond the adrenal gland with lymph node involvement or distant metastases	T3N1M0
		T4N1M0
		anyT, anyN,M1

liver resection may sometimes be necessary (Figure 28.4). Rupture of the tumor capsule during surgery is associated with local recurrence. Extension of tumor into the inferior vena cava (Figure 28.5) is not considered to be metastatic disease and complete removal should be attempted<sup>28</sup>. The value of surgical treatment in stage III or IV disease remains controversial<sup>6</sup>. R0 resection in stage III patients may confer some survival benefit; however, debulking or palliative resection does not influence survival<sup>30</sup>. For patients with

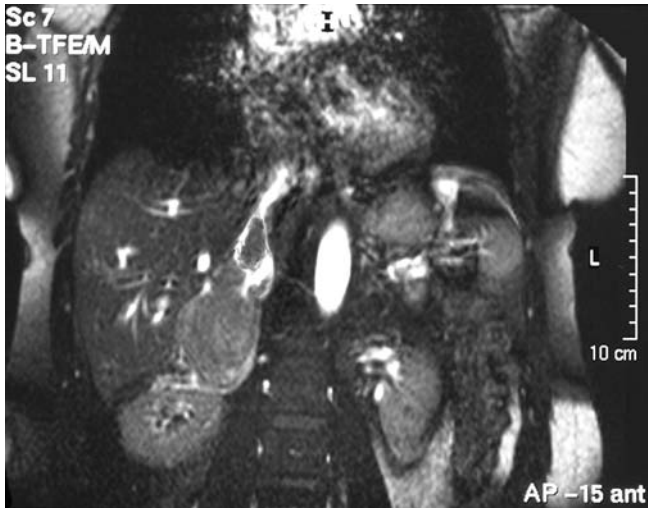
local recurrence, there is evidence that repeat resection (if complete) may improve survival<sup>30</sup>. Resection of solitary metastasis may be indicated in the absence of diffuse metastatic disease or major vessel involvement<sup>31</sup>.

Adrenocortical tumors are generally considered resistant to radiotherapy. Radiotherapy, however, can result in an objective reduction in tumor bulk in unresectable disease, and is effective in the palliation of symptoms<sup>6</sup>. Adjuvant radiotherapy in patients with stage III or high risk stage II patients has been shown in small case series to improve local control<sup>7,32</sup>.

The only organ-specific chemotherapeutic drug in adrenocortical cancer is mitotane (o,p'-DDD), which suppresses adrenal steroid secretion and causes necrosis of adrenal tissue. Although mitotane controls excess tumoral hormone secretion in the majority of patients, reduction in tumor bulk occurs in only 25%<sup>33</sup>. Optimal response



**Figure 28.4** En bloc resection of the adrenal gland, kidney and segments 5, 6 and 7 of the liver for locally advanced adrenocortical cancer on the right side.



**Figure 28.5** Magnetic resonance imaging (MRI) (coronal section) showing right adrenocortical cancer invading into the inferior vena cava.

occurs at blood mitotane concentrations above 14 mg/ml<sup>34</sup>, but this is tempered by significant gastrointestinal (nausea, vomiting, anorexia, and diarrhea) and neurological side-effects (lethargy, depression and somnolence). Supraphysiological doses of glucocorticoid replacement are necessary as mitotane induces steroid insufficiency and increases metabolic clearance of exogenous steroids<sup>7</sup>. Although mitotane is often used in metastatic disease in an attempt to control the syndrome of hormone excess<sup>33</sup> and to prolong survival<sup>35</sup>, its efficacy as an adjuvant agent is doubtful, although a recent retrospective review of 177 patients suggested an improvement in recurrence – free survival<sup>36</sup>.

The use of single agents (cisplatin, suramin and gossypol) and combined chemotherapy regimens with or without mitotane have been reported in small case series. Phase II studies of two combination regimens (etoposide, doxorubicin, cisplatin, and mitotane in one and streptozocin and mitotane in another) in unresectable adrenocortical cancer showed measurable reduction in tumor bulk in 48.6%<sup>37</sup> and 36%<sup>38</sup>, respectively.

Patients with advanced disease under consideration for chemotherapy should be enrolled in clinical trials for objective assessment of response and effectiveness. A multinational phase III randomized control trial (FIRM-ACT) is now recruiting patients with locally advanced and metastatic adrenocortical cancer to compare mitotane, doxorubicin, etoposide, and cisplatin in one arm to mitotane and streptozotocin in the other<sup>39</sup>. Adrenostatic drugs such as ketoconazole, metyrapone or etomidate are occasionally used in patients symptomatic from hormone excess uncontrolled by mitotane treatment alone<sup>7</sup>.

An algorithm for the management of adrenocortical cancer is shown in Figure 28.6.

### Outcomes

For adrenocortical cancer, large series have quoted overall 5-year survival rates of between 22 and 23%<sup>40,41</sup> in the late 1980s, and 37–38% more recently<sup>42,43</sup>. Although the exact reason for this improvement is unclear, this may be due to the increasing use of mitotane or due to the increasing proportion of smaller tumors in the more recent series.

### Prognostic factors

Early stage and curative resection of adrenocortical cancer influence survival<sup>5</sup>. However, at the time of diagnosis, only 35% of ACC are confined to the adrenal. Metastases commonly occur in the liver, lungs, bone, and retroperitoneal lymph nodes. Most patients with metastases at diagnosis die within 1 year<sup>6</sup>. Tumor size and age are other prognostic factors; smaller tumors<sup>44</sup> and young age<sup>6</sup> favor a better outcome. A short duration between onset of symptoms and diagnosis<sup>6</sup> and a low mitotic rate<sup>40</sup> are also associated with good prognosis.

### Malignant pheochromocytoma

Malignancy in pheochromocytoma ranges from 11.6 to 23%<sup>45–47</sup> in large series. There are no absolute histological criteria to differentiate between benign and malignant

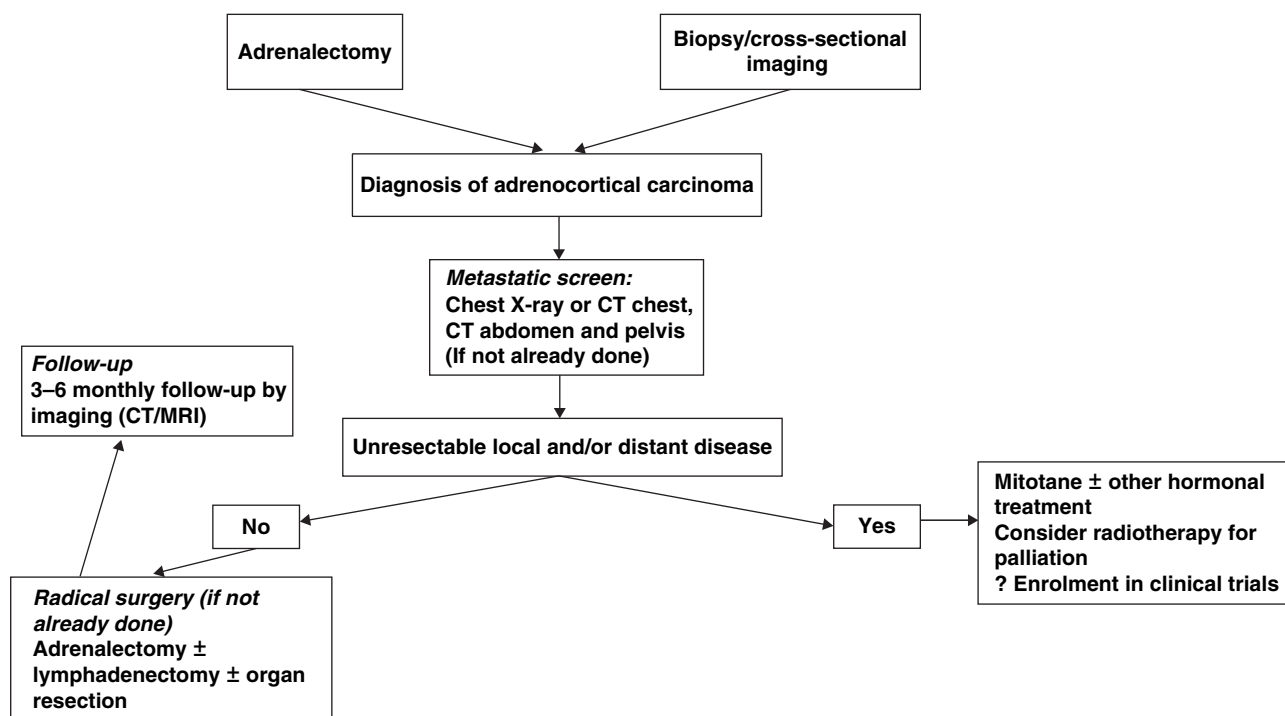


Figure 28.6 An algorithm for the management of adrenocortical carcinoma. CT, computed tomography; MRI magnetic resonance imaging.



pheochromocytomas. Malignancy is diagnosed when there is clear evidence of local invasion into perirenal tissues or metastatic spread in non-chromaffin tissue. The common sites of metastases include bone, lung, liver, and lymph nodes. Clinical features associated with an increased risk of malignancy are abdominal pain, a short history, large (>5 cm) tumors, extra-adrenal location, patients with succinate dehydrogenase complex subunit B (SDHB) mutations, persistent postoperative hypertension, and raised plasma and urinary dopamine and dihydroxyphenylalanine<sup>12,45,46</sup>. Histological features associated with malignancy include confluent tumor necrosis, presence of vascular invasion, intracytoplasmic hyaline globules<sup>48</sup> and S100 positive sustentacular cells<sup>49</sup>. It is important to note that local capsular or vascular invasion do not in isolation predict malignant behavior. All patients with pheochromocytomas require life-long surveillance due to the difficulty in differentiating between benign and malignant tumors. There are no staging classifications for malignant pheochromocytomas.

### *Treatment and outcomes*

Radical surgery is the mainstay of treatment and due to the rarity of the condition; there are few large studies on other forms of treatment. Alfa-blockers and alfa-methyl-paratyrosine can be used for symptomatic relief. In a review of 116 patients with malignant pheochromocytomas treated

in 24 different centers, treatment with iodine-131-MIBG was found to result in symptomatic improvement in 76% of patients and objective reduction in tumor bulk in 30%. A survival benefit was seen in responders<sup>50</sup>.

Combination chemotherapy with cyclophosphamide, vincristine and dacarbazine is associated with complete and partial response rates of 57%<sup>51</sup> but the benefit on survival is unclear. The 5-year survival rate for malignant pheochromocytomas after surgery was 20% in a small series of ten patients<sup>45</sup>.

### **Adrenal metastases**

In a series of 1000 consecutive autopsies in patients with cancer, adrenal metastases were demonstrated present in 27% of cases<sup>52</sup>. Clinical presentation occurs usually in three different ways: during staging investigations for cancer, incidentalomas and local pressure effects. The latter group is rare and only accounted for 4% in a series of 464 patients<sup>53</sup>. In a series of patients who underwent surgery for incidentalomas, a past history of cancer increases the likelihood of the lesion being metastatic to 52%<sup>54</sup>.

The commonest primary cancers that metastasize to the adrenal gland are lung cancer, followed by stomach, esophagus and liver/bile ducts cancers<sup>53,55</sup>. Usually, the primary site is apparent and the disease is widespread. Retrospective observational data suggest that adrenalectomy may benefit some patients with an isolated metastasis<sup>56,57</sup>.

## **REFERENCES**

1. Grumbach MM, Biller BM, Braunstein GD et al. Management of the clinically inapparent adrenal mass ("incidentaloma"). *Ann Intern Med* 2003; 138: 424–9.
2. Lindholm J, Juul S, Jorgensen JO et al. Incidence and late prognosis of Cushing's syndrome: a population-based study. *J Clin Endocrinol Metab* 2001; 86: 117–23.
3. Andersen GS, Toftdahl DB, Lund JO et al. The incidence rate of pheochromocytoma and Conn's syndrome in Denmark, 1977–1981. *J Hum Hypertens* 1988; 2: 187–9.
4. Hartley L, Perry-Keene D. Pheochromocytoma in Queensland—1970–83. *Aust N Z J Surg* 1985; 55: 471–5.
5. Soreide JA, Brabrand K, Thoresen SO. Adrenal cortical carcinoma in Norway, 1970–1984. *World J Surg* 1992; 16: 663–7.
6. Wajchenberg BL, Albergaria Pereira MA, Medonca BB et al. Adrenocortical carcinoma: clinical and laboratory observations. *Cancer* 2000; 88: 711–36.
7. Allolio B, Fassnacht M. Adrenocortical Carcinoma: Clinical Update. *J Clin Endocrinol Metab* 2006; 91: 2027–37.
8. Young WF Jr. Minireview: primary aldosteronism—changing concepts in diagnosis and treatment. *Endocrinology* 2003; 144: 2208–13.
9. Newell-Price J, Bertagna X, Grossman AB, Nieman LK. Cushing's syndrome. *Lancet* 2006; 367: 1605–17.
10. Potts JM, Larrimer J. Pheochromocytoma in a pregnant patient. *J Fam Pract* 1994; 38: 289–93.
11. Bulow B, Ahren B. Adrenal incidentaloma—experience of a standardized diagnostic programme in the Swedish prospective study. *J Intern Med* 2002; 252: 239–46.
12. Lenders JW, Pacak K, Walther MM et al. Biochemical diagnosis of pheochromocytoma: which test is best? *JAMA* 2002; 287: 1427–34.
13. Nieman LK, Ilias I. Evaluation and treatment of Cushing's syndrome. *Am J Med* 2005; 118: 1340–6.
14. Lenders JW, Eisenhofer G, Mannelli M, Pacak K. Pheochromocytoma. *Lancet* 2005; 366: 665–75.
15. Lumachi F, Tregnagh A, Zucchetta P et al. Sensitivity and positive predictive value of CT, MRI and 123I-MIBG scintigraphy in localizing pheochromocytomas: A prospective study. *Nucl Med Commun* 2006; 27: 583–7.
16. Neri LM, Nance FC. Management of adrenal cysts. *Am Surg* 1999; 65: 151–63.
17. Sywak M, Pasieka JL. Long-term follow-up and cost benefit of adrenalectomy in patients with primary hyperaldosteronism. *Br J Surg* 2002; 89: 1587–93.
18. Shen WT, Sturgeon C, Duh QY. From incidentaloma to adrenocortical carcinoma: the surgical management of adrenal tumors. *J Surg Oncol* 2005; 89: 186–92.

19. Gonzalez RJ, Shapiro S, Sarlis N et al. Laparoscopic resection of adrenal cortical carcinoma: a cautionary note. *Surgery* 2005; 138: 1078–85.
20. Assalia A, Gagner M. Laparoscopic adrenalectomy. *Br J Surg* 2004; 91: 1259–74.
21. Walz MK, Alesina PF, Wenger FA et al. Posterior retroperitoneoscopic adrenalectomy—result of 560 procedures in 520 patients. *Surgery*, 2000. 140(6): p 943–8; discussion 948–50.
22. Fernandez-Cruz L, Saenz A, Benarroch G et al. Laparoscopic unilateral and bilateral adrenalectomy for Cushing's syndrome. Transperitoneal and retroperitoneal approaches. *Ann Surg* 1996; 224: 727–34.
23. Rubinstein M, Gill TS, Aron M et al. Prospective, randomized comparison of transperitoneal versus retroperitoneal laparoscopic adrenalectomy. *J Urol* 2005; 174: 442–5.
24. Norton JA. Adrenal Tumors. In: DeVita VTJ, Hellman S, Rosenberg SA, eds. *Cancer: Principles and Practice of Oncology*, 7th edn. Philadelphia: Lippincott Williams and Wilkins 2005; 1528–39.
25. Weiss LM. Comparative histologic study of 43 metastasizing and nonmetastasizing adrenocortical tumors. *Am J Surg Pathol* 1984; 8: 163–9.
26. Medeiros LJ, Weiss LM. New developments in the pathologic diagnosis of adrenal cortical neoplasms. A review. *Am J Clin Pathol* 1992; 97: 73–83.
27. Sullivan M, Boileau M, Hodges CV. Adrenal cortical carcinoma. *J Urol* 1978; 120: 660–5.
28. Chiche L, Douset B, Kieffer E, Chapuis Y. Adrenocortical carcinoma extending into the inferior vena cava: presentation of a 15-patient series and review of the literature. *Surgery* 2006; 139: 15–27.
29. Henley DJ, van Heerden JA, Grant CS et al. Adrenal cortical carcinoma – a continuing challenge. *Surgery* 1983; 94: 926–31.
30. Causeret S, Monneuse O, Mabrut JY et al. [Adrenocortical carcinoma: prognostic factors for local recurrence and indications for reoperation. A report on a series of 22 patients]. *Ann Chir* 2002; 127: 370–7. [in French].
31. Schulick RD, Brennan MF. Long-term survival after complete resection and repeat resection in patients with adrenocortical carcinoma. *Ann Surg Oncol* 1999; 6: 719–26.
32. Markoe AM, Serber W, Micaily B et al. Radiation therapy for adjunctive treatment of adrenal cortical carcinoma. *Am J Clin Oncol* 1991; 14: 170–4.
33. Hahner S, Fassnacht M. Mitotane for adrenocortical carcinoma treatment. *Curr Opin Investig Drug* 2005; 6: 386–94.
34. Haak HR, Hermans J, van de Velde CJ et al. Optimal treatment of adrenocortical carcinoma with mitotane: results in a consecutive series of 96 patients. *Br J Cancer* 1994; 69: 947–51.
35. Ilias I, Alevizaki M, Philippou G et al. Sustained remission of metastatic adrenal carcinoma during long-term administration of low-dose mitotane. *J Endocrinol Invest* 2001; 24: 532–5.
36. Terzolo M, Angeli A, Fassnacht M et al. Adjuvant mitotane treatment for adrenocortical carcinoma. *N Engl J Med*, 2007.
37. Berruti A, Terzolo M, Sperone P et al. Etoposide, doxorubicin and cisplatin plus mitotane in the treatment of advanced adrenocortical carcinoma: a large prospective phase II trial. *Endocr Relat Cancer* 2005; 12: 657–66.
38. Khan TS, Imam H, Juhlin C et al. Streptozocin and o,p'DDD in the treatment of adrenocortical cancer patients: long-term survival in its adjuvant use. *Ann Oncol* 2000; 11: 1281–7.
39. [www.firm-act.org/](http://www.firm-act.org/), June 2007.
40. Venkatesh S, Hickey RC, Selin RV et al. Adrenal cortical carcinoma. *Cancer* 1989; 64: 765–9.
41. Luton JP, Cerdas S, Billaud L et al. Clinical features of adrenocortical carcinoma, prognostic factors, and the effect of mitotane therapy. *N Engl J Med* 1990; 322: 1195–201.
42. Icard P, Goudet P, Charpenay C et al. Adrenocortical carcinomas: surgical trends and results of a 253-patient series from the French Association of Endocrine Surgeons study group. *World J Surg* 2001; 25: 891–7.
43. Abiven G, Coste J, Groussin L et al. Clinical and biological features in the prognosis of adrenocortical cancer: poor outcome of cortisol-secreting tumors in a series of 202 consecutive patients. *J Clin Endocrinol Metab* 2006; 91: 2650–5.
44. Harrison LE, Gaudin PB, Brennan MF. Pathologic features of prognostic significance for adrenocortical carcinoma after curative resection. *Arch Surg* 1999; 134: 181–5.
45. John H, Ziegler WH, Hauri D, Jaeger P. Pheochromocytomas: can malignant potential be predicted? *Urology* 1999; 53: 679–83.
46. Glodny B, Winde G, Herwig R et al. Clinical differences between benign and malignant pheochromocytomas. *Endocr J* 2001; 48: 151–9.
47. Goldstein RE, O'Neill JA, Holcomb GW et al. Clinical experience over 48 years with pheochromocytoma. *Ann Surg* 1999; 229: 755–64.
48. Linnoila RI, Keiser HR, Steinberg SM, Lack EE. Histopathology of benign versus malignant sympathoadrenal paragangliomas: clinicopathologic study of 120 cases including unusual histologic features. *Hum Pathol* 1990; 21: 1168–80.
49. Unger P, Hoffman K, Pertsemliadis D et al. S100 protein-positive sustentacular cells in malignant and locally aggressive adrenal pheochromocytomas. *Arch Pathol Lab Med* 1991; 115: 484–7.
50. Loh KC, Fitzgerald PA, Matthay KK et al. The treatment of malignant pheochromocytoma with iodine-131 metaiodobenzylguanidine (131I-MIBG): a comprehensive review of 116 reported patients. *J Endocrinol Invest* 1997; 20: 648–58.
51. Averbuch SD, Steakley CS, Young RC et al. Malignant pheochromocytoma: effective treatment with a combination of cyclophosphamide, vincristine, and dacarbazine. *Ann Intern Med* 1988; 109: 267–73.
52. Abrams HL, Spiro R, Goldstein N. Metastases in carcinoma; analysis of 1000 autopsied cases. *Cancer* 1950; 3: 74–85.
53. Lam KY, Lo CY. Metastatic tumors of the adrenal glands: a 30-year experience in a teaching hospital. *Clin Endocrinol (Oxf)* 2002; 56: 95–101.
54. Lenert JT, Barnett CC, Kudelka AP et al. Evaluation and surgical resection of adrenal masses in patients with a history of extra-adrenal malignancy. *Surgery* 2001; 130: 1060–7.
55. Hess KR, Varadhachary GR, Taylor SH et al. Metastatic patterns in adenocarcinoma. *Cancer* 2006; 106: 1624–33.
56. Sarela AI, Murphy I, Coit DG, Conlon KC. Metastasis to the adrenal gland: the emerging role of laparoscopic surgery. *Ann Surg Oncol* 2003; 10: 1191–6.
57. Sebag F, Calzolari F, Harding J et al. Isolated adrenal metastasis: the role of laparoscopic surgery. *World J Surg* 2006; 30: 888–92.

## RELEVANT WEBSITES

Information on Adrenal cancer at the Dana Farber Cancer Institute: <http://www.dfci.harvard.edu/can/cancer/View.aspx?lang=en&audience=1=doc=520>

Surgical treatment of diseases of the adrenal gland: <http://www.baes.info/Adrenal.htm>



# Thyroid cancer

29

Douglas Fraker

Thyroid cancer is by far the most common malignancy of endocrine glands with a recent increase of incidence over the past decade. In 1995 there were approximately 17 000 new cases of thyroid cancer in the US and in 2007 it is estimated that there will be 33 550 new cases of thyroid cancer<sup>1</sup>. The reason for this increase is not clear but since the overall mortality rate from thyroid cancer has been relatively stable over that time period (Figure 29.1), it is thought to be due to better detection. The primary etiology for well-differentiated thyroid cancer which comprises the majority of this increased incidence is radiation exposure and, if anything, there is less radiation exposure due to external beam treatment for benign disease which stopped in the 1950s and environmental catastrophes. Furthermore, the majority of these lesions are small and can be detected by increased use of ultrasound screening and attention to and biopsy of smaller lesions<sup>2</sup>.

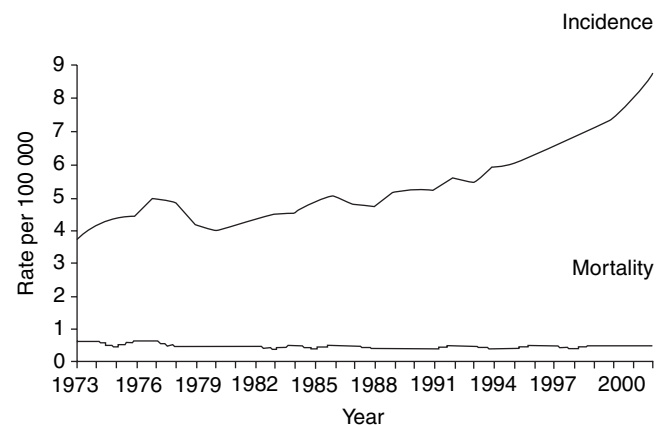
Thyroid cancer differs from other solid neoplasms in a variety of important ways. First, the vast majority of these tumors are quite indolent or are markedly curable leading to a very low proportion of deaths due to thyroid cancer. There will be an estimated death rate of 1530 deaths due to thyroid cancer in 2007 which is only 4.6% of the estimated incidence of 33 550<sup>1</sup>. Even though thyroid cancer comprises the vast majority of endocrine tumors, being 94.5% of overall endocrine malignancies, thyroid cancer only counts for 66% of the deaths again reflecting a high cure rate<sup>1</sup>. Second, the most common types of thyroid cancers are treated by radioactive iodine and not by chemotherapy or external beam radiation therapy. Third, the key groups of specialists managing thyroid cancer are endocrine surgeons, endocrinologists and nuclear medicine physicians as opposed to surgical oncologists, medical oncologists and radiation oncologists.

Within the broad category of thyroid cancer, there are four distinct clinical tumor types based on cell of origin, natural history, treatment, and prognosis (Table 29.1). Each of these types will be discussed in a separate section as they are quite distinct from each other. By far, the most overwhelmingly common type of thyroid cancer is categorized as well differentiated tumors of the thyroid.

These tumors arise from the follicular cells lining the colloid nodules and include papillary thyroid cancer and follicular thyroid cancer, and their variants. The second most common type of thyroid malignancy is medullary thyroid cancer which arises from the parafollicular cells of the thyroid and has a completely different natural history, epidemiology and treatment than well differentiated thyroid cancer. The third type of thyroid cancer is anaplastic thyroid carcinoma which almost certainly arises from the follicular cells but is quite rare and a much more aggressive disease than well differentiated thyroid cancer. The final category is thyroid lymphoma, and there are other very unusual tumors including thyroid sarcoma and metastatic disease to the thyroid gland. Of the new cases of thyroid cancer each year, approximately 90% are well differentiated thyroid cancers, 5–7% medullary thyroid cancers, 1–2% lymphoma, and 1% anaplastic thyroid cancer (Table 29.1).

## THYROID NODULES

Thyroid cancer uniformly presents as a thyroid nodule detected in one of several ways. The nodule may be



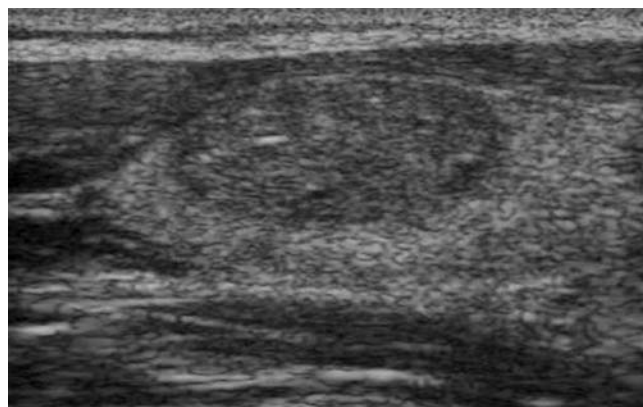
**Figure 29.1** Thyroid cancer incidence and mortality from 1973 to 2002. Note the recent increase in incidence over the past decade with a completely stable mortality. Reproduced from reference 2, with permission.

**Table 29.1** Distribution of thyroid cancers

<i>Well differentiated thyroid cancer</i>	90%
Papillary (80%)	
classic	
follicular variant	
tall cell	
Follicular (10%)	
Hurthle cell	
<i>Medullary</i>	6%
Familial	
MEN-2a	
MEN-2b	
Non-MEN familial	
Sporadic	
<i>Anaplastic</i>	1%
<i>Lymphoma</i>	3%

noticed by the patient, family, or friends observing that individual. The neck mass can be noted on routine physical screening examination. Due to the prevalence of radiological tests of the cervical region for other indications, thyroid nodules can be an incidental finding on imaging studies such as carotid ultrasound, cervical spine magnetic resonance imaging (MRI) scans, or chest computed tomography (CT) scans. A newer imaging technique which may identify incidental thyroid nodules is the positron emission tomography (PET) scan done for staging of other malignancies. The vast majority of thyroid nodules and thyroid cancers cause no symptoms for the patient at the time of presentation. More advanced tumors such as anaplastic thyroid cancer may cause dysphagia by compression of the esophagus, dyspnea by compression of the trachea, and hoarseness by invasion and subsequent destruction of the recurrent laryngeal nerve. However, the incidence of local symptoms due to thyroid nodules is under 5% in most series.

The optimal imaging technique for evaluating thyroid nodules is neck ultrasound. This technique not only can define the number and precise size of thyroid nodules, but also can characterize them in a variety of other ways including the presence of fluid in either completely or partially cystic lesions, indistinct borders of the thyroid nodule relative to the surrounding thyroid, microcalcifications within the thyroid nodule, and level of vascularity by Doppler imaging technique in the thyroid nodule<sup>3</sup>. Microcalcifications, indistinct borders and increased



**Figure 29.2** Ultrasound appearance of a thyroid cancer. Ultrasound demonstrates an irregular border microcalcifications that is more indicative of thyroid malignancy.

vascularity are more likely associated with malignancy but these features are suggestive and not definitive<sup>4</sup> (Figure 29.2).

Other tests that can be utilized to evaluate thyroid nodules include radioactive nuclear scan and thyroid function blood tests. The primary piece of information gathered from a nuclear scan is whether a nodule is cold, warm, or hot meaning that the nodule takes up less iodine than the surrounding thyroid, equivalent iodine to the surrounding thyroid, or more iodine than the surrounding iodine, respectively<sup>5</sup>. The one problem with the nuclear medicine scan is that exophytic nodules which lie either lateral, inferior, or superior to the normal contour of the thyroid that are cold may be invisible with this technique leaving an unaltered normal thyroid contour. The primary role of nuclear medicine scan is to identify the functional status of thyroid nodules that are identified on biopsy as follicular neoplasm as this particular tumor type with a warm or hot nodule is virtually never malignant and may not require surgery. Another role for nuclear medicine scan is in a multinodular gland that identifies non-functional or cold thyroid nodules which have the potential to be malignant and identifies them as lesions to be targeted for fine needle aspiration biopsy.

Thyroid function tests, although universally obtained by primary physicians and endocrinologists, contribute little to the work-up and evaluation of thyroid nodules. Functional thyroid disease, either hyperthyroidism or hypothyroidism, is for the most part distinct from nodular disease of the thyroid. One rare exception would be a toxic thyroid adenoma in which the nodule is the only site of uptake on radioiodine scan and the patient would have a suppressed thyroid stimulating hormone (TSH) and elevated thyroxine. For virtually all tumor types that are discussed in this chapter, there is no impact on thyroid function and none of these nodules make excess

hormone for well differentiated thyroid cancers. In terms of functional status, two other comments need to be made. First, medullary thyroid cancer from the parafollicular cells virtually always produces calcitonin and this hormone is elevated even in the most aggressive forms of medullary thyroid cancer. Second, the non-functional status of well differentiated thyroid cancer is in contradistinction to a variety of other endocrine tumors such as parathyroid carcinoma which has extreme hyperfunction and other tumors of the neuroendocrine system of the gut as well as adrenal tumors which are often functional.

The mainstay and primary diagnostic test for a thyroid nodule is fine needle aspiration cytology. This technique was developed in Scandinavia over 30 years ago and is utilized widely as the primary guide for management of thyroid nodules. The technique of fine needle aspiration of thyroid nodules is similar to that used at other sites of the body where a small gauge needle between 23 and 27 gauge is placed through several points of the nodule with constant suction and a microscopic slide is prepared. There are very good data that for nodules that are non-diagnostic or for partially cystic nodules in which acellular fluid may be aspirated with a percutaneous attempt, aspiration of thyroid nodules under ultrasound guidance leads to a much greater proportion of significant results.

The results of fine needle aspiration biopsy of thyroid nodules can be grouped into four broad categories<sup>6</sup>. These categories are malignant lesions, indeterminate lesions, benign lesions, and insufficient material to make a diagnosis<sup>7</sup>. Figure 29.3 shows the algorithm for what each of these diagnostic categories may identify and what

further steps are needed. The malignant category of fine needle aspiration includes papillary thyroid cancer and its variants, medullary thyroid cancer, anaplastic thyroid cancer, and in most cases lymphoma of the thyroid. Papillary thyroid cancer which is the most common type of thyroid cancer is identified on fine needle aspiration by distinct nuclear changes. Specifically, central chromatin clearing, large nuclei and nuclear grooves including 'Orphan Annie' eye nucleus are pathognomonic for papillary thyroid cancer (Figure 29.4a). This is why this particular tumor type is very easy to identify with a good cellular specimen on cytology as no tissue architecture diagnosis is needed if appropriate nuclear characteristics are present. The other tumor types that can be identified reliably as malignant are medullary thyroid cancer and anaplastic thyroid cancer. Medullary thyroid cancer from the parafollicular cells has a neuroendocrine appearance and may be confused with follicular cells, however, immunocytochemistry with calcitonin very often leads to positive staining and serum calcitonin levels can confirm the diagnosis when suggested by aspiration cytology (Figure 29.4b). Anaplastic thyroid cancer is a very poorly differentiated tumor and may be confused with thyroid lymphoma both in terms of its rapid growth characteristics and on aspiration cytology. Appropriate immunocytochemistry for lymphoid tumor markers or epithelioid tumor markers can distinguish these two diseases reliably. For these three tumor types (papillary, medullary and anaplastic), there are no benign tumors. In other words, all of these lesions when identified make the diagnosis of a thyroid carcinoma of that subtype.

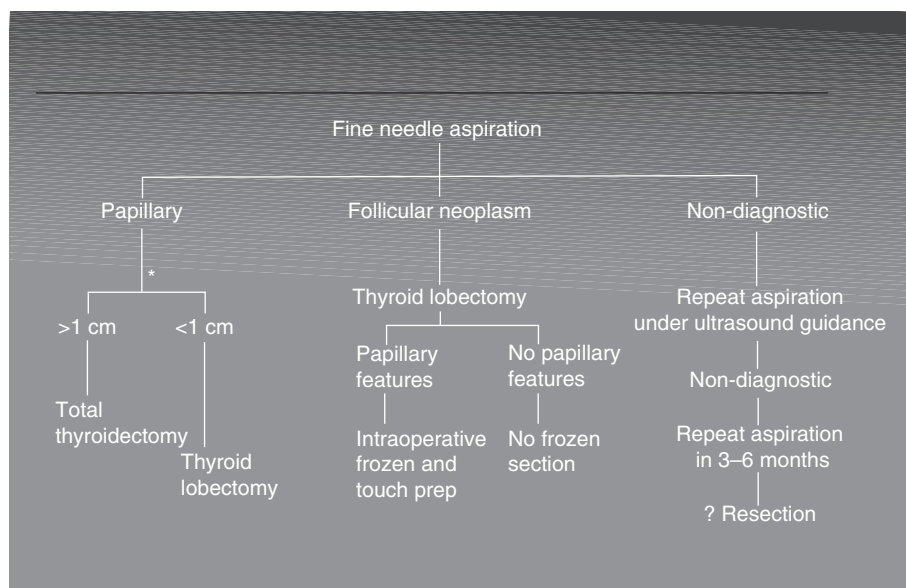
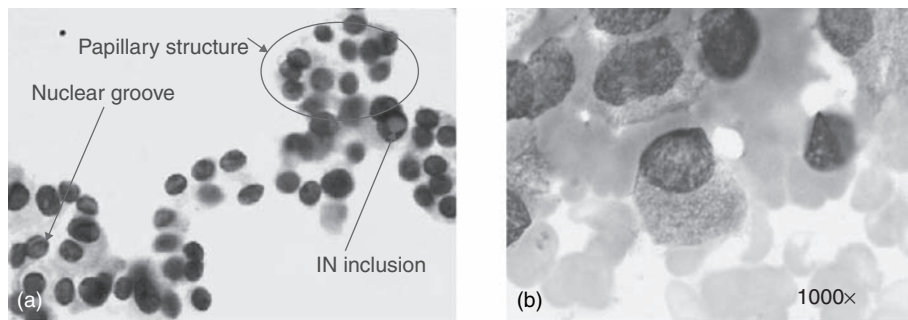


Figure 29.3 Algorithm of decision-making for fine needle aspiration biopsies for thyroid nodules. \*Controversial.



**Figure 29.4** (a) Fine needle aspiration of papillary thyroid cancer demonstrating nuclei and central lymph node clearing. (b) Fine needle aspiration of medullary thyroid cancer.

The indeterminate biopsy is really a misnomer as it is not a biopsy result that gives no information as patients often perceive<sup>8</sup>. Rather, it is a biopsy result that identifies the nodule as a follicular neoplasm. As opposed to papillary, medullary and anaplastic thyroid cancer, follicular neoplasms are most commonly benign follicular adenomas. In most large series, the proportion of follicular neoplasms that are benign ranges between 80 and 85%, with 15–20% being follicular carcinomas. The cell morphology of a follicular adenoma and a follicular carcinoma are not distinguishable by aspiration cytology. A follicular carcinoma is defined by the microscopic tumor growth characteristics of either capsular invasion or vascular invasion<sup>9</sup>. Virtually all follicular neoplasms have a fibrous capsule that separates them from the surrounding thyroid tissue, and any follicular cell growth and penetration into the capsule is identified as minimal capsular invasion and growth through the capsule into the surrounding thyroid is gross capsular invasion; both of these define one subtype of follicular carcinoma<sup>9,10</sup>. Growth of follicular cells into the blood vessels that run within the thyroid nodule is classified as vascular or angioinvasion and is another category of follicular carcinoma. A variant of follicular neoplasms are Hurthle cell neoplasms named for a 19th century German pathologist who identified a specific cell type<sup>11</sup>. Hurthle actually identified parafollicular cells but these were incorrectly associated with this subcategory of follicular neoplasms. The alternative term used today is follicular neoplasm with oncocytic features. Like follicular neoplasms, Hurthle cell neoplasms can be benign adenomas or malignant carcinomas, with carcinomas defined by capsular or vascular invasion and this distinction is impossible on cytology.

The third category which is by far the most common result of fine needle aspiration of a thyroid nodule is a benign reading. The vast majority of thyroid nodules are non-neoplastic nodules which are primary storage deposits of colloid. An aspiration biopsy that produces abundant colloid often associated with macrophages and

Hurthle cell changes in association with bland follicular cells is diagnostic of a colloid nodule. Alternative names for this benign condition include hyperplastic focus in a nodular goiter or adenomatous nodule. In most series, 80–90% of biopsies result in a colloid nodule and for lesions that are asymptomatic in terms of mass effects from the nodule, no surgical referral is necessary. A second less common category of benign nodules is a lymphocytic focus in chronic autoimmune thyroiditis. This aspiration result demonstrates fairly abundant lymphocytes mixed with thyroid follicular cells and can be substantiated by biochemical diagnosis of autoimmune thyroiditis measuring circulating antithyroid peroxidase and antithyroglobulin antibodies. This lesion may be incorrectly interpreted as papillary thyroid cancer.

The final category of results obtained from fine needle aspiration biopsy of a thyroid nodule is a non-diagnostic specimen. This result occurs when the slide prepared from the biopsy shows very little material with scant colloid and scant cellular material. It is often associated with an aspiration of blood or in completely cystic nodules containing acellular cystic fluid. The result of a non-diagnostic fine needle aspiration is not equivalent to benign as a subset of these nodules on repeat biopsy and subsequent excision turn out to be malignant carcinomas. For some reason, these cancers do not release cellular material during the aspiration biopsy procedure. If a repeat biopsy is still non-diagnostic, surgical excision is indicated.

The incidence of thyroid nodules in the general population is quite high and is increased in women compared with men<sup>12</sup>. The incidence of clinically detected nodules in women over age 50 is as high as 6% and in men at the same age is 1.5%. The incidence of nodules that are detected by either ultrasound evaluation or autopsy series in elderly patients can be as high as 70–90% for women and 40–60% for men over age 70<sup>13</sup>. The vast majority of these nodules are benign colloid nodules and the majority of these nodules are smaller than 1 cm when identified

**Table 29.2** Classification of thyroid nodules*Benign non-neoplastic*

Hyperplastic nodule (colloid nodule)

Thyroid cyst

Lymphocytic thyroiditis nodule

*Benign neoplastic*

Follicular adenoma

Hurthle cell adenoma

*Malignant*

Papillary

Follicular

Hurthle cell

Medullary

Anaplastic

Lymphoma

ultrasound or autopsy. Because of the high prevalence of nodules, guidelines have been identified to define which lesions need to be biopsied<sup>3</sup>. For nodules with no worrisome characteristics such as increased vascularity, microcalcifications and indistinct borders, nodules smaller than 1.5 cm in maximum dimension do not require biopsy. For nodules that have worrisome characteristics, only lesions larger than 1.0 × 1.0 cm should undergo fine needle aspiration biopsy. Unfortunately, the technology to allow ultrasound-guided biopsy has made it possible to reliably sample lesions as small as 0.5 cm, and these guidelines are not being followed putting surgical practitioners in situations in which they have biopsy results on nodules that should not be biopsied based on size criteria.

## WELL DIFFERENTIATED THYROID CANCER

Well differentiated thyroid malignancies are by far the most common type of thyroid cancer. These include papillary thyroid cancer and its variants as well as follicular thyroid cancer. Twenty years ago, there was a separate third category called mixed which indicated a combined papillary/follicular lesion. Patients with this tumor category when followed had a natural history that is much more similar to papillary thyroid cancer and has been renamed follicular variant of papillary thyroid cancer<sup>14</sup>. Types of papillary thyroid cancer include classic type, follicular variant, tall cell variant, and diffuse sclerosing papillary thyroid cancer. The tall variant of papillary thyroid cancer is a more aggressive tumor type in which

the length of the cells is twice the width<sup>15</sup>. This tumor tends to occur in older patients and has a much more aggressive characteristic than the classic or follicular variant of papillary thyroid cancer. Diffuse sclerosing papillary thyroid cancer is more common in adolescents or young adults and essentially mimics a rock-hard goiter as the thyroid does not appear nodular but rather diffusely enlarged and firm. This is the result of complete tumor replacement of the thyroid lymphatics. These tumors are universally associated with very extensive lymph node metastases.

Follicular thyroid cancers also include the variant of Hurthle cell as well as insular tumors. Because of a somewhat different biology, some investigators consider Hurthle cell neoplasms as a distinct variety of well differentiated thyroid cancer. However, similar to the most common follicular carcinomas they are malignant on the basis of capsular or vascular invasion and tend to metastasize hematogenously. One difference is that there is an increased incidence of lymph node metastasis with Hurthle cell carcinomas as opposed to follicular carcinomas, but this incidence is nowhere near that seen with papillary thyroid cancer and medullary thyroid cancer. Within the spectrum of well differentiated thyroid cancer, in most series 80–90% are papillary thyroid cancers and 10–20% are follicular carcinomas. Approximately 5% of the total lesions tend to be Hurthle cell carcinomas.

The American Joint Committee on Cancer (AJCC) staging system for papillary thyroid cancer is shown in Table 29.3. This is a standard TNM classification system in which T4 lesions are characterized by direct invasion outside the thyroid. The peculiarity is that in addition to the standard TNM definition, age plays a predominant role. For example, any T lesion or any N lesion in a patient under age 45 is considered stage I disease. Even a patient with hematogenous metastases under the age of 45 is considered to have stage II disease. Patients over age 45 are more typically classified in a stepwise manner based on tumor size, lymph node extent, tumor extension into surrounding tissue, and hematogenous metastases as demonstrated in Table 29.3.

Prior to the TNM staging system of the AJCC, there were a variety of other staging systems developed from large institutional retrospective databases that emphasized the peculiar features of prognosis in well differentiated thyroid cancer<sup>16–19</sup>. The Lahey Clinic group used a system categorized as AMES (age, metastatic disease, extrathyroidal extension, and size). A group from Canada modified this with the addition of DNA content and flow cytometry to the AMES categorization so-called DAMES. The Mayo Clinic system has the AGES which stands for age, tumor grade, tumor extension, and tumor



**Table 29.3** AJCC staging for well differentiated thyroid cancer

<i>Tumor (T)</i>		
T1	Tumor diameter <2 cm	
T2	Primary tumor diameter 2–4 cm	
T3	Primary tumor diameter >4 cm limited to the thyroid or with minimal extrathyroidal extension	
T4a	Tumor of any size extending beyond the thyroid capsule to invade subcutaneous soft tissues, larynx, trachea, esophagus, or recurrent laryngeal nerve	
T4b	Tumor invades prevertebral fascia or encases carotid artery or mediastinal vessels	
TX	Primary tumor size unknown, but without extrathyroidal invasion	
<i>Nodes (N)</i>		
N0	No metastatic nodes	
N1a	Metastases to level VI (pretracheal, paratracheal, and prelaryngeal/Delphian lymph nodes)	
N1b	Metastases to unilateral, bilateral, contralateral cervical or superior mediastinal node metastases	
NX	Nodes not assessed at surgery	
<i>Metastases (M)</i>		
M0	No distant metastases	
M1	Distant metastases	
MX	Distant metastases not assessed	
<i>Staging</i>		
	<i>Patient age &lt;45 years</i>	<i>Patient age ≥45 years</i>
Stage I	Any T, any N, M0	T1N0M0
Stage II	Any T, any N, M1	T2N0M0
Stage III		T3N0M0
		T1N1aM0
		T2N1aM0
		T3N1aM0
Stage IVA		T4aN0M0
		T4aN1aM0
		T1N1bM0
		T2N1bM0
		T3N1bN0
		T4aN1bM0
Stage IVB		T4b, any N, M0
Stage IVC		Any T, any N, M1

**Table 29.4** Schema for categorizing patients with well differentiated thyroid cancer prognostic risk categories*Low risk : high risk*

Age – males <41 years, females <51 years : males >40 years, females >50 years

Metastases – no distant metastases : distant metastases

Extent – intrathyroidal papillary or follicular with minor capsule inversion : extrathyroidal papillary or follicular with major invasion

Size – <5 cm : >5 cm

Low risk patients are (A) any low risk age group without metastases or (B) high risk age without metastases and with low risk extent and size. Overall survival 95%

High risk patients are (A) any patient with metastases or (B) high risk age with either high risk extent or size. Overall survival 54%

*DAMES (AMES system modified by tumor cell DNA content measured by flow cytometry)*

Low risk AMES + euploid = low risk. Overall survival 92%

Low risk AMES + aneuploid = intermediate risk. Overall survival 45%

High risk AMES + aneuploid = high risk. Overall survival 0%

*AGES (age, tumor grade, tumor extent, tumor size)*

PS =  $0.05 \times \text{age in years}$  (except patients <40 years = 0), +1 (grade 2) or +3 (grade 3/4), +1 (if extrathyroidal) or +3 if distant metastases),  $+0.2 \times \text{tumor size in cm maximum diameter}$

PS range: 0–11.65, median 2.6

Risk categories: 0–3.99/4–4.99/5–5.99/>6. Overall survival 99%/80%/33%/13%

*MACIS (metastasis, age, completeness of resection, invasion, size)*

PS = 3.1 (age <39 years) or  $0.08 \times \text{age}$  (if age >40 years),  $+0.3 \times \text{tumor size in cm}$ , +1 (if incompletely resected), +1 (if locally invasive), +3 (if distant metastases)

PS risk categories: 0–5.99/6–6.99/7–7.99/>8. Overall survival 99%/89%/56%/24%

PS, prognostic score

size. All of these systems utilize the unique characteristic of age of the patient being a very predominant variable in terms of the overall prognosis for well differentiated thyroid cancer (Table 29.4). This is a somewhat unique situation among tumor staging in all of cancer. The other unique feature is that particularly in a young age range of patients, lymph node status has no impact on stage. Whether lymph node positive or lymph node negative,

all of patients under age 45 are considered stage I. Other key variables in addition to age include tumor size and extrathyroidal extension.

## TREATMENT OF WELL DIFFERENTIATED THYROID CANCER

The primary treatment of well differentiated thyroid cancer is surgical resection. The key questions for each tumor type identified by fine needle aspiration biopsy are 'What is the extent of surgery?' and 'What is the management of the cervical lymph nodes?' The postsurgical question is 'Who should receive radioactive iodine?' and at 'What dose level?' The extent of surgery has been widely debated over the years among endocrine surgeons<sup>20–22</sup>. Because of the overall excellent prognosis and long-term survival for this indolent cancer, there have been no randomized data to compare thyroid lobectomy with total thyroidectomy. For papillary thyroid cancer, most practitioners recommend a total thyroidectomy for any lesion over 1 cm in size. Since lesions smaller than 1 cm size should not be subjected to biopsy, this would translate into saying all patients with this diagnosis should undergo total thyroidectomy. There are some practitioners who feel that for a low risk age group total thyroidectomy is too extreme and advocate a thyroid lobectomy for papillary thyroid cancers smaller than 1.5 cm and others for thyroid cancers smaller than 2.0 cm<sup>20,21</sup>. Again, because the outcome is so universally good with few events of recurrent disease and even fewer patient deaths likely due to disease, a randomized trial which has been discussed among surgeons performing thyroid surgery will never be performed.

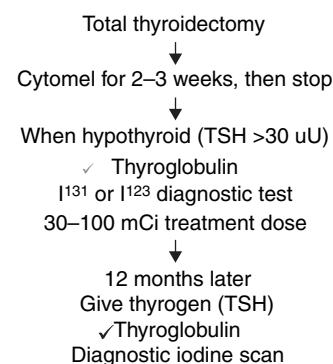
Proponents of total thyroidectomy feel that this is a very safe operation and the two most serious complications which are recurrent laryngeal nerve injury causing voice change and long-term hypoparathyroidism should have a very low level of incidence in experienced hands with a total thyroidectomy<sup>23</sup>. Patients undergoing lobectomy for small papillary thyroid cancers, will almost always have thyroid suppression to keep TSH levels low, and therefore the need to take thyroid hormone is not a strong argument for lesser surgery.

Management of lymph node disease in papillary thyroid cancer has evolved over the past decade due to several new technologies or tests. First, the routine use of measurement of serum thyroglobulin after total thyroidectomy as a tumor marker can identify patients with recurrent disease that is almost certainly in the nodes but may not be clinically apparent or apparent on radioactive iodine scans<sup>24,25</sup>. Second, high resolution ultrasound can now identify abnormal lymph nodes with

microcalcifications, increased blood flow, and architectural distortion in as small as 5 mm as well as perform accurate biopsy of these nodes<sup>26,27</sup>. Third, the increased use of PET scans is now identifying focal areas of malignant disease that are negative on previously utilized iodine scans<sup>28</sup>.

Traditional teaching would argue that during total thyroidectomy for papillary thyroid cancer, one could assess central neck lymph nodes in level VI between the trachea and carotid sheath structures by palpation as well as in low level internal jugular lymph nodes (level IV) as well as mid-internal jugular lymph nodes (level III)<sup>29,30</sup> (Figure 29.5). Due to the high incidence of nodal metastases, it has been argued by some that routine central neck lymph node dissection on the side of the papillary thyroid cancer should be performed in all patients. A surprising number of patients with normal appearing lymph nodes do have positive microscopic nodal disease. Whether this benefits patients in terms of survival is not clear, but it may prevent dangerous re-explorations at a later date in the area of the recurrent laryngeal nerve<sup>30</sup>.

For patients with bulky disease particularly at presentation, a modified central neck dissection or modified radical neck dissection should be performed. Although the majority of lymph node metastases for papillary thyroid cancer are in level VI in the central neck as well as the lower mid-jugular chain, there can be level II nodes in the high jugular chain as well as level V nodes in the posterior triangle. The added morbidity of dissecting these high jugular and posterior nodes is fairly minimal and again for patients with bulky disease a complete nodal resection in a functional approach should be considered. Occasional patients have substernal lymph nodes that cannot be readily dissected with transcervical approach and the so-called level VII lymph nodes may need a partial median sternotomy for full dissection in rare patients<sup>29</sup>. All patients who have gross disease identified in lymph nodes should have surgical excision as



**Figure 29.5** Flow algorithm for adjuvant therapy of well differentiated thyroid cancer with radioactive iodine.

opposed to treatment of radioactive iodine or external beam radiation therapy.

The surgical treatment of follicular neoplasms is hampered by the inability to make a clear distinction between follicular adenoma and follicular carcinoma on fine needle aspiration biopsies<sup>14</sup>. Furthermore, the ability to distinguish carcinoma on the basis of capsular or vascular invasion on intraoperative frozen section is also very difficult<sup>31,32</sup>. Patients also often have false negative results due to sampling error as the areas of invasion tend to be quite focal and one or two sections chosen for frozen section may not be the ones that identify capsular or vascular invasion. More worrisome is that the process of freezing may lead to artifacts that look like invasion and can lead to false positive identification. Investigators both at Johns Hopkins<sup>31</sup> and at the University of Pennsylvania<sup>14</sup> have stated that almost as much false information as true information is received from frozen sections for follicular neoplasms and this is generally not performed. For patients with significant cancer after a lobectomy to remove a follicular neoplasm on final pathology, a completion total thyroidectomy done to prepare them for radioactive iodine is almost always recommended<sup>33</sup>. Patients particularly in the low risk age range that have minimal capsular invasion and no angioinvasion with relatively small nodules are felt to be at very low risk of disease and often can be managed with thyroid lobectomy without completion total thyroidectomy and use of radioactive iodine<sup>10</sup>. When patients are prepared for thyroid lobectomy for follicular neoplasms, they should be told that there is approximately a 20% chance of having a second procedure to remove the contralateral lobe if cancer is identified and could be offered total thyroidectomy at the initial approach<sup>9</sup>. Again, the major difference between thyroid lobectomy and total thyroidectomy in terms of risk is a small risk of hypoparathyroidism and the mandatory need to take thyroid hormone replacement life-long. If a patient is already taking thyroid replacement as well as patients who are high anesthesia risk, a total thyroidectomy should be the recommended procedure. Also, for patients with larger nodules over 4 cm, the incidence of malignancy may increase to 30–35% and this may be a relative indication to recommend total thyroidectomy.

Follicular neoplasms rarely metastasize to central neck lymph nodes and, although nodes should be routinely palpated, there is no need to do any node resection for normal lymph nodes in this diagnosis. One distinction between Hurthle cell carcinoma and follicular carcinoma is that Hurthle cell neoplasms tend to have a higher incidence of nodal metastases although again no prophylactic node dissection is indicated in this patient group.

## ADJUVANT THERAPY

The only meaningful adjuvant therapy for postoperative treatment of patients with well differentiated thyroid cancer is radioiodine treatment<sup>34,35</sup>. The benefits of radioactive iodine are derived from case-control studies in large series in which there appears to be an overall survival benefit over the patients who do not receive this adjuvant treatment. Due to the very good outcomes and long survival in well differentiated thyroid cancer, randomized studies are not likely to be performed.

Adjuvant radioactive iodine therapy appears to lead to benefit in two ways. First, the primary goal of this treatment is to ablate any residual micrometastatic disease<sup>34</sup>. This would include micrometastatic disease in the cervical lymph nodes in the case of papillary thyroid cancer and micrometastatic hematogenous disease in the lungs, bone, and elsewhere in angioinvasive follicular and Hurthle cell carcinomas as well as the small subset of aggressive papillary thyroid cancers. Although virtually all well differentiated thyroid cancers are cold on preoperative nuclear studies, this does not mean that they do not take up and concentrate iodine. This means that these malignancies take up iodine to a lesser degree than normal thyroid tissue but the majority of these malignancies do concentrate iodine particularly in the presence of high TSH levels. The second benefit of radioactive iodine is that it allows the use of serum thyroglobulin as a circulating tumor marker<sup>36</sup> after ablation of any residual normal thyroid tissue left after thyroidectomy<sup>37</sup>. The location of this tissue typically is at the insertion of the recurrent laryngeal nerve into the larynx under the cricoid cartilage and depending on the patients individual anatomy this may be difficult to remove without causing nerve damage.

Since most well differentiated thyroid cancers concentrate iodine best under conditions of high TSH levels, the standard protocol (Figure 29.6) for iodine treatment involves withdrawal of thyroid replacement hormone to make the patients hypothyroid only for the purpose of leading to elevated endogenous TSH from the pituitary gland<sup>38</sup>. For this reason, patients after thyroidectomy are placed on Cytomel<sup>®</sup> which has a half-life of approximately 1 day as opposed to a thyroid preparation such as Synthroid<sup>®</sup> which has a half-life of 7–10 days. As the patient's native thyroid hormone produced by the thyroid gland prior to surgical removal is metabolized over 4–6 weeks, patients can be maintained in a euthyroid state with Cytomel. Then, at the appropriate time when the Cytomel is stopped and when the native thyroid hormone has essentially been eliminated by natural metabolism, the Cytomel leaves the system quite rapidly and the time period in which patients feel hypothyroid is limited<sup>38</sup>.

The normal range for TSH in most laboratories is between 0.5 and 4.0 uIU/ml. Treatment protocols typically would desire TSH levels of more than 25–30 uIU/ml prior to giving radioactive iodine therapy. Patients typically receive a low dose radioiodine initially as a scanning and calibration dose, and then based on those results receive a treatment dose calculated by dosimetry. It is noted in some cases when patients are withdrawn from their thyroid replacement after total thyroidectomy that their TSH levels do not rise. Appropriate management then would be to do either an ultrasound or radioactive scan to identify the residual normal thyroid tissue which again is often in the area of the upper pole but can be in the pyramidal lobe. Typically if this tissue is greater than 1 cm and does not allow patients to become hypothyroidal, referral to an experienced surgeon for re-operation and resection is appropriate.

The dose of radioactive iodine utilized is 30 mCi given as an outpatient for low risk stage I and II patients. Higher ablative doses between 100 mCi and 150 mCi should be used for older high risk patients particularly with locally invasive primary or known metastases. The goal of dosimetry is to deliver a dose of  $I^{131}$  that will deliver no more than 200 cGy to the blood which will decrease the risk of bone marrow damage and radiation fibrosis<sup>32</sup>. The most common toxicity of radioactive iodine therapy is due to destruction of the salivary glands and xerostomia. This side-effect can be quite troublesome for some patients as it may be a life-long effect and should limit the use of radioactive iodine treatment only to patients who would truly benefit.

One advance in the past decade has been the use of recombinant TSH or Thyrogen® as a replacement for hormone withdrawal and endogenous TSH from a patient's pituitary gland<sup>24</sup>. Again, the reason for hormone withdrawal is not because iodine uptake is inherently better when patients are hypothyroid, but rather it is the secondary effect of elevated circulatory TSH levels that is beneficial. By getting recombinant TSH, patients can be spared the fatigue and other side-effects from hypothyroidism prior to their therapy. Studies indicate that the degree of iodine uptake with recombinant Thyrogen is equivalent to that achieved with native TSH due to hormone withdrawal.

Subsequent follow-up after initial ablation includes follow-up physical examination, monitoring of circulating thyroglobulin levels, and follow-up iodine scans. Again, if all native thyroid tissue is either excised or ablated with the initial treatment dose, the level of thyroglobulin should be essentially zero. One key aspect of following thyroglobulin levels for recurrent thyroid cancer is that they are most sensitive in the setting of high TSH levels<sup>40</sup>. This is why a thyroglobulin is measured when patients are

withdrawn from their hormone at the time of initial treatment. In subsequent follow-ups, patients are typically given Thyrogen, and simultaneous TSH and thyroglobulin levels should be measured trying to ascertain that the thyroglobulin is undetectable in the setting of high TSH<sup>41</sup>. In patients who have circulating antithyroglobulin antibodies which is 15–20% of the general population, the use of circulating thyroglobulin is severely limited.

The ability of thyroglobulin to detect microscopic disease, which is often radioiodine resistant or at least is so small that it cannot be identified on iodine scan, has led to the identification of a population of patients that are thyroglobulin positive, radioiodine negative and have no disease by physical examination. The majority of these patients have cervical lymph node metastases and although a variety of imaging techniques have been utilized to evaluate these patients, the most sensitive appears to be cervical ultrasound by a skilled radiologist<sup>27</sup>. Metastases as small as 3–5 mm in normal-size lymph nodes, due to the destruction of nodal architecture, can be identified and even sampled with fine needle aspiration. In general, if disease is identified in a patient who is otherwise healthy and can tolerate neck re-exploration, surgery to remove that identified disease as well as surrounding lymph nodes is recommended. Whether this aggressive resection of lymph nodes that are otherwise undetectable leads to any benefit in terms of survival is unknown. The risks of neck re-exploration in particularly injury to the recurrent laryngeal nerve causing voice change are real and these re-explorations should be done by experienced surgeons.

Iodine is by far the most effective adjuvant therapy for well differentiated thyroid cancer. For patients who are completely iodine resistant, the best single standard therapeutic agent is Adriamycin® with partial response rates between 30 and 45%. However, there are almost no complete responses and the partial responses are short duration. In patients with localized disease, a combination of Adriamycin and external beam radiation therapy has been utilized but again rarely leads to complete responses. For patients whose only disease is cervical nodal disease, it is strongly recommended that surgical excision be utilized rather than external beam radiation therapy in iodine-resistant patients.

## MEDULLARY THYROID CANCER

Medullary thyroid cancer (MTC) was described in 1959 by Hazard as a solid neoplasm without follicular histology but with a high degree of lymph node metastases. In this initial report, MTC accounted for 3.5% of the thyroid

cancers in a large series from the Cleveland Clinic<sup>42</sup>. This description led to the identification of the parafollicular C cells as well as of calcitonin as a hormone that reduces serum calcium. In most series, MTC is between 5 and 7% of the total number of thyroid cancer cases, although it can be as low as 3% or as high as 12% depending upon institutional referral. As opposed to the more common well-differentiated thyroid cancer, MTC has a very clear genetic etiology as well as a large proportion of familial cases. Furthermore, since it does not derive from the follicular cells, there is no benefit of radioiodine treatment and there is no increased risk of MTC with radiation exposure. There are three distinct familial syndromes that comprise anywhere between 40 and 60% of MTC cases: multiple endocrine neoplasia (MEN)-2a, MEN-2b and non-MEN familial MTC<sup>43–45</sup>. Table 29.5 shows the associated findings as well as the prevalence of these findings in familial syndromes. For MEN-2, MTC has a prevalence of almost 100% which is the most common as well as the most lethal manifestation of this disease compared with pheochromocytoma and hyperparathyroidism in MEN-2a. The molecular genetics of MTC, because of these familial syndromes, identified the RET proto-oncogene as well as specific mutations that are associated with each of these familial syndromes. In virtually all types of MTC, there is an equal male or female proportion that would be expected for the genetic syndrome. The most aggressive forms are MTC associated with MEN-2b as well as

sporadic cases of MTC. The natural history of MTC includes a very high predominance of lymphatic invasion and extensive lymph node metastases to the cervical nodes. There also is an increased incidence of trophism to the liver leading some investigators to recommend screening laparoscopy for all patients operated on for this disease.

The AJCC TNM staging system for MTC is more typical of other solid neoplasms compared with that for a well differentiated thyroid cancer (Table 29.6). As opposed to well differentiated thyroid cancer, patient age does not play a role and lymph node status plays a prominent role. Stage I is defined as tumors <2 cm diameter without extrathyroidal extension. Stage II is larger tumors with evidence of extrathyroidal disease. Stage III is any tumor greater than 4 cm and lymph node metastasis in level VI. Stage IV is any distant metastases or lymph node metastases outside of level VI as well as gross tumor invasion of surrounding structures. Other staging systems have been proposed including ones from the National Thyroid Cancer Treatment Cooperative Study Group which defines stage I as premalignant C cell hyperplasia found only by familial screening (discussed below).

The primary treatment for MTC is surgical with total thyroidectomy and at minimum a central neck lymph node dissection performed in all cases except for prophylactic operations based on genetic testing<sup>47</sup>. It had been

**Table 29.5** Characteristics of sporadic and various familial forms of medullary thyroid cancer (MTC)

	<i>Sporadic</i>	<i>Familial</i>		
		<i>Non-MEN</i>	<i>MEN-2a</i>	<i>MEN-2b</i>
Age at diagnosis (years)	42–45	43–45	24–27	15–20
Gender	M = F	M = F	M = F	M = F
Associated diseases	None	None	Pheochromocytoma, hyperparathyroidism	Pheochromocytoma, Marfanoid body habitus, oral and eye mucosal neuromas, gastrointestinal ganglioneuromas
Lymph nodes at diagnosis (%)	40–50	10–20	10–20	40–45
Distant metastases at diagnosis (%)	10–15	0	0–3	20
Cured of MTC (%)	14–30	70–80	56–100	0
Mutations in RET on chromosome 10	Met 918→Thr (33%) Glu 768→Asp	Mutations in cysteines in extracellular domain (609, 611, 618, 620, 634, 768, 790, 791, 804, 891)	Mutations in cysteines in extracellular domain (609, 611, 618, 620, 630, 634, 740, 791, 804)	Met 918→Thr

**Table 29.6** Staging systems for medullary thyroid cancer

	<i>AJCC</i>	<i>NTCCTSG</i>	<i>DeGroot</i>
Stage I	Size <1 cm negative LN	C-cell hyperplasia	Any size tumor, negative LN
Stage II	Size <1 cm or extrathyroidal extension, negative LN	Size <1 cm, negative LN	Any size tumor, positive LN
Stage III	Tumor any size, positive LN	size >1 cm on any tumor, positive LN	Extrathyroidal or extranodal extension
Stage IV	Any distant metastases	Metastases outside the neck or extrathyroidal extension	Metastases

AJCC, American Joint Commission on Cancer; NTCCTSG, National Thyroid Cancer Cooperative Treatment Study Group; LN, lymph node

previously debated particularly in sporadic cases whether total thyroidectomy versus thyroid lobectomy needed to be performed. There is no reason to remove the contralateral lobe to prepare patients for radioactive iodine as this is ineffective as an adjuvant in this disease. However, it is felt that in a variety of cases there still can be bilateral disease and the safety of total thyroidectomy is such that this is the recommended procedure for all patients identified with MTC. The extent of a lymph node dissection depends on the size of the primary lesion and the presence of grossly positive lymph nodes. For MTC smaller than 1 cm there is still a reported incidence of 11% nodal spread. For lesions larger than 2 cm, there is a 60% incidence of spread to regional lymph nodes. Most surgeons would perform bilateral central neck dissection from carotid sheath to carotid sheath and across the anterior trachea for all patients with this disease<sup>44</sup>. Patients with gross evidence of positive lymph nodes in their central neck independent of the size of the primary tumor should have a lateral modified radical neck dissection on the side of the positive lymph node. Some have argued in patients who have primary tumors larger than 2 cm because of the prevalence of positive nodes that a modified radical neck dissection removing levels II, III, IV, and VI be performed on the side of the disease with a central level VI lymph node dissection on the contralateral side.

MTC has one of the best tumor markers available in all of oncology. Calcitonin is made only by follicular cell and medullary thyroid cancer, and virtually all of these tumors secrete this hormone in excess<sup>43</sup>. Furthermore, one can stimulate calcitonin production with the

injection of pentagastrin which will cause release only in the setting of tumor. Carcinoembryonic antigen (CEA) is a circulating tumor marker produced by over 50% of MTC and can be utilized to follow these patients as well. It should be noted that patients who have an elevated CEA and have no evidence of disease in terms of primary colon or other gastrointestinal malignancy should be considered to have potentially MTC and should have a screening calcitonin assessed.

Patients who have evidence of recurrent nodal disease after surgical treatment should be treated with very aggressive and complete surgical resection of this disease as MTC is relatively radiation resistant, has no beneficial effects from radioactive iodine, and has minimal benefit from standard chemotherapy. External beam radiation therapy causes considerable toxicity and for gross nodal disease from MTC often has very high persistent or recurrent disease rates. Utilizing external beam radiation can lead to surgical exploration through radiated fields which has significantly increased morbidity for the patients. Radiation therapy should be reserved only for patients with disease that is locally invasive deemed to be not surgically resectable.

Because of the prominent role in the RET proto-oncogene, patients who have MTC should be sent for genetic counseling to screen for these mutations and to allow potentially, if identified, first-degree relatives to undergo appropriate screening as well. The patients from known MEN-2 kindreds who have the inherited autosomal dominant mutation can be managed with prophylactic surgery at a young age prior to any risk of MTC developing<sup>48</sup>. Since the penetrance of MTC is 100% in MEN-2a and MEN-2b, all identified family members should undergo surgery either as a child or adolescent. It is notable that most of these patients have C cell hyperplasia detected in their pathology specimens. Patients who are identified as index cases should be screened by assessing the calcium levels, PTH levels and serum metanephrine as a way of screening for associated endocrine disorders in MEN-2.

The overall survival for MTC depends on the category of disease whether it is familial or sporadic and which type of familial disease. Specifically, patients with sporadic disease as well as MEN-2b have an incidence of lymph node metastases between 40 and 50% at the time of diagnosis and of distant metastases between 10 and 20% at the time of diagnosis. The overall survival rate in this group varies between 15 and 30%<sup>44</sup>. On the other hand, patients with MEN-2a or non-MEN familial MTC rarely have distant metastases from the time of diagnosis and have an incidence of lymph node metastases of only between 10 and 20%. Consequently, the overall survival in this patient population is quite good in most series varying

between 70 and 90%. These different natural histories and outcomes correlate with mutations in *cystines* in the extracellular domain in the good risk MTC groups in patients with sporadic MEN-2b having MTC with mutation in methionine-918 mutated to threonine. The poor outcome in MEN-2b can be avoided with appropriate genetic screening and prophylactic surgery.

## ANAPLASTIC THYROID CANCER

The third major category of thyroid cancer is anaplastic thyroid cancer. This is one of the most aggressive human malignancies defined by the median survival of only 4–5 months from the time of diagnosis<sup>49</sup>. The incidence of anaplastic thyroid cancer has declined over time. Historically, series from the mid-20th century stated that 5–10% of thyroid cancers were anaplastic and this has decreased to approximately 1–2% in recent series. Coincident with this decrease in incidence of anaplastic thyroid cancer has been an increase of thyroid lymphoma (see below) and it is likely that there has been a reclassification with appropriate tumor markers on lymphoid malignancies and that prior lymphomas were thought to be anaplastic. Anaplastic well differentiated thyroid cancer is thought to arise from the follicular cells. However, this is a disease that strikes older individuals, has an equal gender distribution as opposed to favoring women, and has a very aggressive course rather than indolent course.

Patients who present with very rapidly enlarging masses in the neck should be considered to have anaplastic thyroid cancer or lymphoma as well differentiated thyroid cancer or medullary thyroid tumors are much more indolent. These tumors tend to have very significant local invasion of the trachea, esophagus and surrounding musculature. Patients can have a surgical resection and should be aggressively resected with en bloc removal of

associated invaded structures. The majority of patients have local recurrence and approximately 50% of these patients die from local invasion particularly airway obstruction as opposed to metastatic disease as with other solid malignancies.

The overall prognosis with anaplastic thyroid cancer is very poor with the median survival in most series being less than 5 months from the time of diagnosis. Approximately 20% of patients have long-term disease-free survival and these are patients who can be resected with negative margins at the initial operation. Adriamycin is the most commonly utilized chemotherapeutic but there is no clear survival benefit in this rare disease regarding routine adjuvant use of this agent<sup>50</sup>.

## LYMPHOMA OF THE THYROID

Thyroid lymphoma is relatively rare comprising 2% of all extranodal non-Hodgkin's lymphoma. Again, the incidence of thyroid lymphoma over the past three decades has increased coincident with the decrease in incidence of anaplastic thyroid cancer. The majority of these lymphomas are intermittent to high grade and have rapid growth patterns. As with lymphoma elsewhere in the body, chemotherapy is the mainstay of treatment and complete extirpation by surgical removal is not necessary for cure<sup>45</sup>. In patients who have lymphoma suspected based on growth pattern, one could possibly make the diagnosis by fine needle aspiration but certainly by core biopsy for large lesions or incisional wedge biopsy. These lesions tend not to invade outside the thyroid-like anaplastic thyroid cancer and can be removed by total thyroidectomy but may only be identified only on final pathology<sup>51</sup>. Since these patients even after resection will be recommended to receive combination chemotherapy, if the diagnosis can be made without complete excision, this is not needed.

## REFERENCES

1. Jemal A, Siegel R, Ward E et al. Cancer Statistics, 2007. *CA Cancer J Clin* 2007; 57: 43–66.
2. Davies L, Welch HG. Increasing incidence of thyroid cancer in the United States, 1973–2002. *JAMA* 2005; 295: 2164–7.
3. Frates MC, Benson CB, Charboneau JW et al. Management of thyroid nodules detected at US: Society of Radiologists in Ultrasound consensus conference statement. *Radiology* 2005; 237: 794–800.
4. Ito Y, Kobayashi K, Tomoda C et al. Ill-defined edge on ultrasonographic examination can be a marker of aggressive characteristic of papillary thyroid microcarcinoma. *World J Surg* 2005; 29: 1007–11.
5. Phan TT, van Tol KM, Links TP et al. Diagnostic I-131 scintigraphy in patients with differentiated thyroid cancer: no additional value of higher scan dose. *Ann Nucl Med* 2004; 18: 641–6.
6. Hamburger JI. Diagnosis of thyroid nodules by fine needle biopsy: use and abuse. *J Clin Endocrinol Metab* 1994; 70: 335–9.
7. Hammings JF, Goslings BM, Van Steenis GJ et al. The value of fine needle aspiration biopsy in patients with nodular thyroid

- disease divided into groups of suspicion of malignant neoplasms on clinical grounds. *Arch Int Med* 1990; 150: 113.
8. Tyler DS, Winchester DJ, Caraway NP et al. Indeterminate fine-needle aspiration biopsy of the thyroid: identification of subgroups at high risk for invasive carcinoma. *Surgery* 1994; 116: 1054–60.
  9. Lo CY, Chan WF, Lam KY, Wan KY. Follicular thyroid carcinoma: the role of histology and staging systems in predicting survival. *Ann Surg* 2005; 242: 708–15.
  10. van Heerden JA, Hay ID, Goellner RJ et al. Follicular thyroid carcinoma with capsular invasion alone: a nonthreatening malignancy. *Surgery* 1992; 112: 1130–8.
  11. Burch HB. Evaluation and management of the solitary thyroid nodule. *Endocrinol Metab Clin North Am* 1995; 24: 663–81.
  12. Castro MR, Caraballo PJ, Morris JC. Effectiveness of thyroid hormone suppressive therapy in benign solitary thyroid nodules: a meta-analysis. *J Clin Endocrinol Metab* 2002; 87: 4154.
  13. Lopez-Penabad L, Chiu AC, Hoff AO et al. Prognostic factors in patients with Hurthle cell neoplasms of the thyroid. *Cancer* 2003; 97: 1186–94.
  14. LiVolsi VA, Asa SL. The demise of follicular carcinoma of the thyroid gland. *Thyroid* 1994; 4: 233–6.
  15. Ruter A, Nishiyama R, Lennquist S. Tall-cell variant of papillary thyroid cancer: disregarded entity? *W J Surg* 1997; 21: 15–20.
  16. Hay I, Bergstrahl E, Goellner J et al. Predicting outcome in papillary thyroid carcinoma: development of a reliable prognostic scoring system in a cohort of 1779 patients surgically treated at one institution during 1940 through 1989. *Surgery* 1993; 114: 1050–8.
  17. Hav ID, Grant CS, Bergstrahl EJ et al. Unilateral total lobectomy: is it sufficient treatment for patients with AMES low-risk papillary thyroid carcinoma? *Surgery* 1998; 124: 958–64.
  18. Lo CY, Chan WF, Lam KY, Wan KY. Optimizing the treatment of AMES high-risk papillary thyroid carcinoma. *World J Surg* 2004; 28: 1103–9.
  19. Jukkola A, Bloigu R, Ebeling T et al. Prognostic factors in differentiated thyroid carcinomas and their implications for current staging classifications. *Endocr Relat Cancer* 2004; 11: 571–9.
  20. Hay ID, Grant CS, Taylor WF, McConahey WM. Ipsilateral lobectomy versus bilateral lobar resection in papillary thyroid carcinoma: a retrospective analysis of surgical outcome using a novel prognostic scoring system. *Surgery* 1987; 102: 1087–94.
  21. Wanebo H, Coburn M, Teates D, Cole B. Total thyroidectomy does not enhance disease control or survival even in high-risk patients with differentiated thyroid cancer. *Ann Surg* 1998; 227: 912.
  22. Cheema Y, Olson S, Elson D, Chen H. What is the biology and optimal treatment for papillary microcarcinoma of the thyroid? *J Surg Res* 2006; 134: 160–2.
  23. Dralle H, Sekulla C, Haerting J et al. Risk factors of paralysis and functional outcome after recurrent laryngeal nerve monitoring in reoperative thyroid and parathyroid surgery. *Surgery* 2004; 136: 1310–22.
  24. Robbins RJ, Srivastava S, Shaha A et al. Factors influencing the basal and recombinant human thyrotropin-stimulated serum thyroglobulin in patients with metastatic thyroid carcinoma. *J Clin Endocrinol Metab* 2004; 89: 6010–6.
  25. Schlumberger M. Can iodine-131 whole body scan be replaced by thyroglobulin measurement in the postsurgical follow-up of differentiated thyroid carcinoma? *J Nucl Med* 1992; 33: 172.
  26. Ito Y, Tomoda C, Urano T et al. Preoperative ultrasonographic examination for lymph node metastasis: usefulness when designing lymph node dissection for papillary microcarcinoma of the thyroid. *World J Surg* 2004; 28: 498–501.
  27. Toriontano M, Attard M, Crocetti U et al. Follow-up of low risk patients with papillary thyroid cancer: role of neck ultrasonography in detecting lymph node metastases. *J Clin Endocrinol Metab* 2004; 89: 3402–7.
  28. Nahas Z, Goldenberg D, Fakhry C et al. The role of positron emission tomography/computed tomography in the management of recurrent papillary thyroid carcinoma. *Laryngoscope* 2005; 115: 237–43.
  29. Goropoulos A, Karamoshos K, Christodoulou A et al. Value of the cervical compartments in the surgical treatment of papillary thyroid carcinoma. *World J Surg* 2004; 28: 1275–81.
  30. Leboulleux S, Rubino C, Baudin E et al. Prognostic factors for persistent or recurrent disease of papillary thyroid carcinoma with neck lymph node metastases and/or tumor extension beyond the thyroid capsule at initial diagnosis. *J Clin Endocrinol Metab* 2005; 90: 5723–9.
  31. Udelsman R, Westra WH, Donovan PI et al. Randomized prospective evaluation of frozen-section analysis for follicular neoplasms of the thyroid. *Ann Surg* 2001; 233: 716.
  32. Callcut RA, Selvaggi SM, Mack E et al. The utility of frozen section evaluation for follicular thyroid lesions. *Ann Surg Oncol* 2004; 11: 94–8.
  33. DeJong SA, Demeter JG, Lawrence AM, Paloyan E. Necessity and safety of completion thyroidectomy for differentiated thyroid carcinoma. *Surgery* 1992; 112: 734–9.
  34. Roario PW, Maia FF, Cardoso LD et al. Correlation between cervical uptake and results of postsurgical radioiodine ablation in patients with thyroid carcinoma. *Clin Nucl Med* 2004; 29: 358–61.
  35. Zidan J, Hefer E, Iosilevski G et al. Efficacy of I<sup>131</sup> ablation therapy using different doses as determined by postoperative thyroid scan uptake in patients with differentiated thyroid cancer. *Int J Radiat Oncol Biol Phys* 2004; 59: 1330–6.
  36. Mazzaferri EL, Robbins RJ, Spencer CA et al. A consensus report of the role of serum thyroglobulin as a monitoring method for low-risk patients with papillary thyroid carcinoma. *J Clin Endocrinol Metab* 2003; 88: 1433.
  37. Bai CS, Kumar A, Pant GS. Radioiodine dose for remnant ablation in differentiated thyroid carcinoma: a randomized clinical trial in 509 patients. *J Clin Endocrinol Metab* 2004; 89: 2666–73.
  38. Davids T, Witterick IJ, Eski S et al. Three-week thyroxine withdrawal: a thyroid-specific quality of life study. *Laryngoscope* 2006; 116: 250–3.
  39. Sweeney DC, Johnson GS. Radioiodine therapy for thyroid cancer. *Endocrinol Metab Clin North Am* 1995; 24: 803–39.
  40. Kim TY, Kim WB, Kim ES et al. Serum thyroglobulin levels at the time of I<sup>131</sup> remnant ablation just after thyroidectomy are useful for early prediction of clinical recurrence in low-risk patients with differentiated thyroid carcinoma. *J Clin Endocrinol Metab* 2006; 90: 1440–5.
  41. Kioos RT, Mazzaferri EL. A single recombinant human thyrotropin-stimulated serum thyroglobulin measurement predicts differentiated thyroid carcinoma metastases three to five years later. *J Clin Endocrinol Metab* 2005; 90: 5047–57.
  42. Hazard JB, Hawk WA, Crile G. Medullary (solid) carcinoma of the thyroid - a clinicopathologic entity. *J Clin Endocrinol Metab* 1959; 19: 152–61.
  43. Chi DD, Moley JF. Medullary thyroid carcinoma: genetic advances, treatment recommendations, and the approach to the patient with persistent hypercalcitoninemia. *Surg Oncol Clin North Am* 1998; 7: 681–706.
  44. Pelizzo MR, Bernante P, Piotto A et al. The extent of surgery for thyroid medullary cancer. *Tumori* 1994; 80: 427–32.



45. Cha C, Chen H, Westra WH, Udelsman R. Primary thyroid lymphoma: can the diagnosis be made solely by fine-needle aspiration? *Ann Surg Oncol* 2002; 9: 298.
46. McHenry CR, Oppenheim DS, Murphy T et al. Familial nonmultiple endocrine neoplasia medullary thyroid carcinoma: An evolving clinical entity. *Surgery* 1992; 112: 729–33.
47. O'Riordain DS, O'Brien T, Weaver AL et al. Medullary thyroid carcinoma in multiple endocrine neoplasia types 2A and 2B. *Surgery* 1994; 116: 1017–23.
48. Gimm O, Ukkat J, Niederle BE et al. Timing and extent of surgery in patients with familial medullary thyroid carcinoma/multiple endocrine neoplasia 2A-related RET mutations not affecting codon 634. *World J Surg* 2004; 28: 1312–6.
49. Tan RK, Finley RK, Driscoll D et al. Anaplastic carcinoma of the thyroid: a 24-year experience. *Head and Neck* 1995; 17: 41–8.
50. DeCrevoisier R, Baudin E, Bachelor A et al. Combined treatment of anaplastic thyroid carcinoma with surgery, chemotherapy, and hyperfractionated accelerated external radiotherapy. *Int J Rad Oncol Biol Phys* 2004; 60: 1137–43.
51. Sippel RS, Gauger PG, Angelos P et al. Palliative thyroidectomy for malignant lymphoma of the thyroid. *Ann Surg Oncol* 2002; 9: 907–11.

Alison Waghorn

---

## INTRODUCTION

The parathyroid gland was discovered by Sir Richard Owen in 1851 in a rhinoceros. At the time it was unknown what the gland did and parathyroid hormone (PTH) was only identified in 1954. The introduction of the multichannel biochemical autoanalyzer in the 1960s resulted in primary hyperparathyroidism becoming one of the commonest endocrine disorders. The incidence of primary hyperparathyroidism is approximately 1 in 1000 in the adult population<sup>1</sup>.

Parathyroid glands are APUD glands originating from the third and fourth branchial pouches. The inferior parathyroid (third pouch) can lie anywhere from behind the submandibular gland to the lowest part of the anterior mediastinum, depending on its descent with or without the thymus. The superior gland (fourth pouch) is usually found lateral to the descended thyroid. As a result parathyroid carcinoma can be found from as high as the submandibular glands to deep within the mediastinum. The normal adult parathyroid gland consists of two main types of parenchymal cell, the chief or principal cell and the oxyphil cell. The chief cell and its proliferation is associated with hyperplasia and adenomas of the parathyroid gland. Malignant tumors of the parathyroid gland tend to arise from these chief cells.

Parathyroid carcinoma is a very rare malignancy. It was probably first reported by De Quervain in 1904<sup>2</sup>. These tumors are often slow growing, but have a propensity to recur locally and to be difficult to eradicate. Long-term survival rates may be improving with the use of adjuvant radiotherapy and calcimimetics to help hypercalcemic control.

## INCIDENCE

The actual incidence parathyroid carcinoma is not well documented. In 1999, an American National Cancer Data Base report published 286 cases of parathyroid carcinoma that had occurred over 10 years<sup>3</sup>. Parathyroid carcinoma has an equal incidence in men and women,

in contrast to benign hyperparathyroidism, which occurs more commonly in women 3 : 1. Over 700 cases have been reported in the literature, all mainly in individual case reports or retrospective studies, the youngest at 8 years old<sup>4</sup>.

Less than 1% of all patients with hyperparathyroidism are operated on as a result of malignancy in US and UK<sup>5,6</sup>. However, in some other series the incidence has been reported to be as high as 5%<sup>7</sup>. This variation may be due to genetic or environmental influences but may just represent local surgical practice for primary hyperparathyroidism.

Many cases of primary hyperparathyroidism are asymptomatic and go undetected in countries where regular screening health checks of the population are not undertaken. However, 80% of cases of hypercalcemia in asymptomatic patients are due to hyperparathyroidism. In the symptomatic and/or hospitalized patient this is considerably less at 13–33%<sup>8</sup>.

The etiology of parathyroid carcinoma remains unclear in most cases. Many risk factors have been implicated but none confirmed including radiation, dietary factors and inadequate sunlight exposure. There is a rare autosomal dominant disorder of familial hyperparathyroidism (*HRPT2* gene) in which an increased risk of parathyroid carcinoma has been demonstrated<sup>9</sup>. Hyper parathyroid jaw tumor syndrome (HPT-JT) is an autosomal dominant disease characterized by the occurrence of parathyroid and fibro-osseous tumors of the jaw bones which has an increased risk of parathyroid carcinoma (10% of affected individuals)<sup>10</sup>. It has also been recorded in multiple endocrine neoplasia (MEN) type 1 and 2A syndromes but only the occasional case<sup>11</sup>. Patients on long-term hemodialysis may also have an increased incidence<sup>12</sup>.

Familial isolated hyperparathyroidism has been suggested to be associated with an increased incidence of parathyroid carcinoma but it is more often associated with non-endocrine neoplasms including breast, colon, endometrial, and melanoma malignancies<sup>13</sup>. There are no reports of parathyroid carcinoma in familial hypercalcemic hypocalcemia or neonatal severe hyperparathyroidism (which manifests within first 6 months of life).

## PRESENTATION

Parathyroid carcinoma/malignancy presents most commonly in the fifth and sixth decades at an age which is on average 10 years younger than that for benign hyperparathyroidism.

Typically the patients present with a markedly elevated calcium ( $>3.0$  mmol/l) and parathyroid hormone levels greater than five times normal<sup>14,15</sup> (Table 30.1). Therefore parathyroid carcinoma patient usually present with symptoms comparable with those of hyperparathyroidism/hypercalcemia: tiredness, aches and pains in the bones (64%), bone disease (~90%), renal impairment (~75%<sup>14</sup>), peptic ulcer disease (18%<sup>16</sup>), gastritis, pancreatitis, constipation, mental illness, and rarely coma. It can therefore be difficult to distinguish it from benign causes of hyperparathyroidism. However, the high calcium levels of hyperparathyroidism/hypercalcemia mean that they are usually symptomatic and are more likely to present with the more extreme symptoms. Parathyroid carcinoma can present with a mass in the neck (22–52%)<sup>17,18</sup>. It is extremely rare for a benign parathyroid adenoma to be palpable. Lymph node metastases are often present at the time of diagnosis (17–32%); however, this has not been shown to effect overall survival<sup>3,19</sup>.

If a patient has a PTH that is less than four times normal and the mass of the tumour is less than 1.9 g the likelihood of them having a parathyroid carcinoma is negligible<sup>20</sup>. This can be reassuring for primary hyperparathyroidism patients waiting for surgery or histology.

### Non-functioning parathyroid carcinoma

Rarely a parathyroid carcinoma is non-secreting (5% of all parathyroid carcinomas<sup>21</sup>). Patients do not present with raised PTH and calcium levels, and so it is typically detected late, because of symptoms of palpable neck mass, dysphagia, or hoarseness. Lack of a specific blood marker makes recurrence detection difficult and overall the outcome is poor. Few patients survive longer than 2 years<sup>22</sup>.

**Table 30.1** Indications suggesting that parathyroid carcinoma should be suspected.

Parathyroid hormone levels $>5$ times normal
Calcium $>3.5$ mmol/l
Calcium is difficult to control with bisphosphonates
Tumor size $>1.9$ g
White tumor at operation

## Screening

Screening for this tumor in the normal population is not indicated because of its rarity but a difficult to control hypercalcemia with high PTH levels leads to a suspicion of malignancy. The only subpopulation where screening may well have some benefit is in the families with the *HRPT2* gene<sup>23</sup> and the HPT-JW gene.

All patients with any of the symptoms mentioned above should have calcium and phosphate levels performed. Many patients with hypercalcemia have been to a medical professional two to three times before a calcium profile is performed and even with admission to hospital for some of the conditions linked with hypercalcemia (see above) a calcium profile is not performed. Others are now going for regular health screens and a biochemical profile including bone markers is usually included.

Postoperative screening for recurrence is relatively easy in the secreting parathyroid carcinomas, calcium and PTH levels done 3 monthly are the best way to pick up recurrence. Non-secreting tumor recurrences are more difficult to find. Clinical examination and symptoms associated with invasion of local structures, or systemic symptoms linked with extensive tumor load (cachexia, etc.) must give rise to suspicion of recurrence. These tumors tend to have a poor prognosis.

## DIAGNOSTIC STRATEGIES

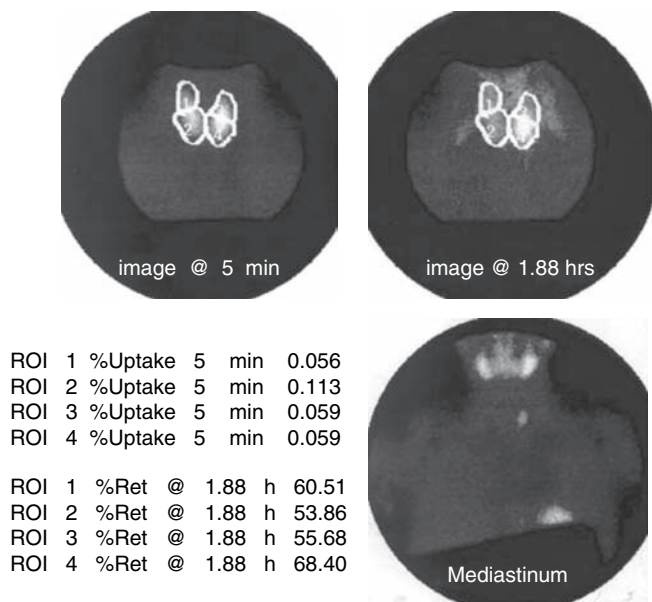
If the tumor is secreting, then the investigations are as for primary hyperparathyroidism: serum calcium, intact PTH, phosphate, albumin, and 24-hour urinary calcium (to exclude FHH). Because of the increasing desire to perform minimally invasive parathyroidectomy, most patients with hyperparathyroidism will undergo a single photo emission CT imaging (SPECT) Sesta MIBI scan with or without ultrasonography prior to an operation.

### Parathyroid imaging

#### History

It was originally noticed that the thyroid and heart took up technetium-99m pertechnetate and the larger parathyroid tumor was also later shown to take up this isotope. It was then discovered that the parathyroid gland did not take up thallium-201 which was taken up readily by the thyroid gland. A technetium/thallium subtraction scan was devised to isolate the enlarged parathyroid gland. This scan was later overtaken by a SestaMIBI scan.

Technetium-labeled Sesta MIBI was then shown to be retained by the parathyroid gland due to its mitochondrial activity and this added to SPECT more recently has enabled



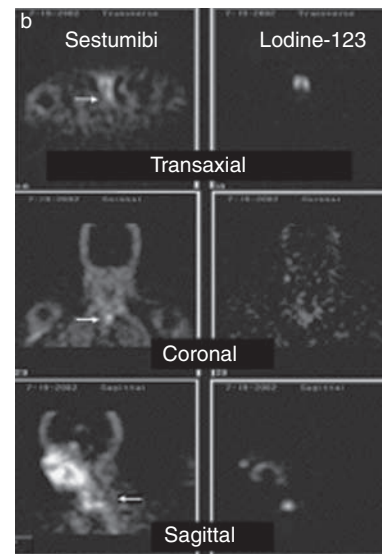
**Figure 30.1** SestaMIBI scanning of a left lower parathyroid adenoma. ROI, region of interest.

accurate identification and localization of parathyroid tumors over 200 mg<sup>24</sup>.

Sesta MIBI uptake and retention depends on the transmembrane potential of the cell and mitochondria. Parathyroid cells are rich in mitochondria, sometimes thyroid adenoma are more likely than normal thyroid parenchyma to be rich in oxyphil cells (rich in mitochondria). The sensitivity is 90% and specificity is 90% for tumors that are greater than 300 mg<sup>25</sup>. Smaller tumors are still more difficult to identify but this is not particularly relevant in parathyroid carcinoma as the tumors are usually much larger than the adenomas (Figure 30.1). There are no identifying characteristics of SestaMIBI uptake allowing there to be differentiation of parathyroid carcinoma from benign disease. Some centers are using iodine-123-labeled Sesta MIBI and SPECT (dual isotope imaging) and claim slightly better results<sup>26</sup> (Figure 30.2).

## Ultrasound

This imaging modality is most useful after the identification of an abnormality on the SPECT Sesta MIBI scan to confirm the presence of an abnormal parathyroid gland. It will help define the presence of a mass (Figure 30.3). In the non-secreting tumors or assessment of lymph node metastases fine needle aspiration under ultrasound control may be useful prior to surgery. Fine needle aspiration cytology is not advised in secreting tumors if possible, as in most endocrine tumors, there is concern about seeding of the tumors along the needle track and local dispersal leading to implantation.



**Figure 30.2** Imaging with iodine-123 and SPECT SestaMIBI scanning.

## Magnetic resonance imaging

If the carcinoma is palpable, then MRI imaging is the best method of imaging the tumor and metastatic disease. But carcinomas can be found incidentally at operation for primary hyperparathyroidism. MRI with gadolinium and fat suppression is the method of choice when difficulty is encountered localizing of parathyroid tumors and recurrences<sup>27</sup>.

## Positron emission tomography scan

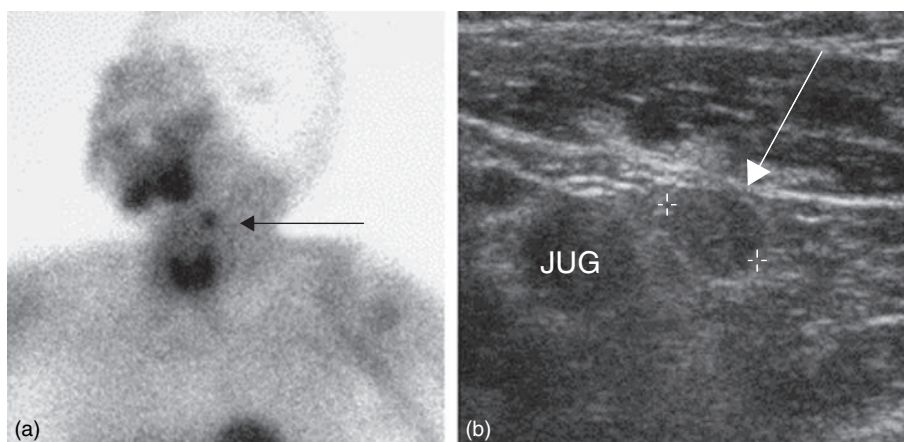
PET has been used to successfully detect recurrent and metastatic parathyroid carcinoma<sup>28</sup>. It is not as accurate as MRI, but may help in assessing disease that is initially difficult to localize on MRI scanning.

## Selective venous sampling

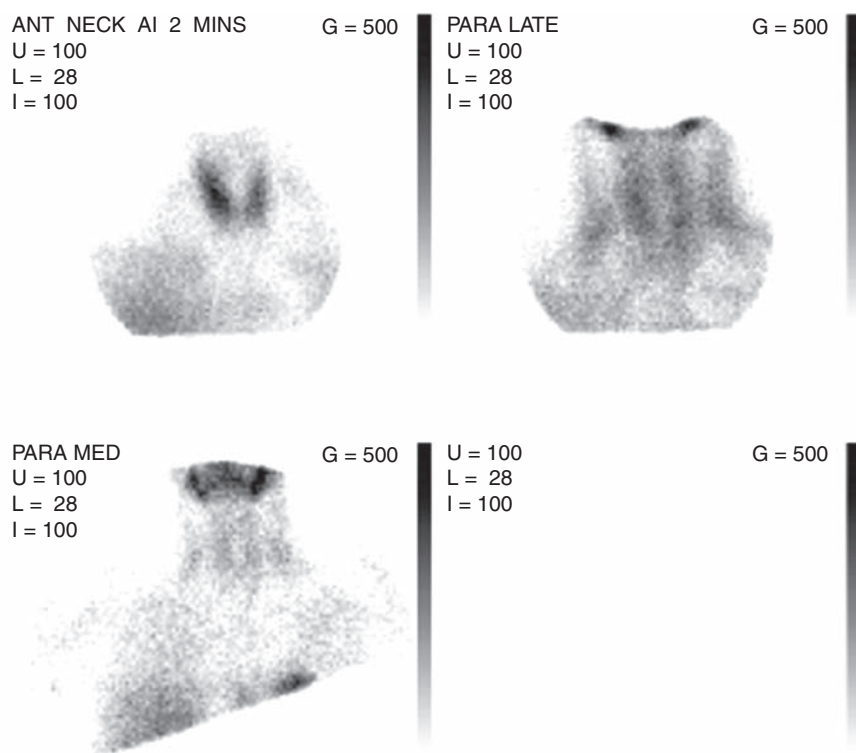
Selective venous sampling can sometimes be useful if non-invasive imaging fails to identify the lesion or the results are equivocal<sup>29</sup>. This may identify an area with a small amount of disease that is undetectable on MRI or PET scanning, so that surgical clearance of a specific area can be undertaken to help clear recurrent disease. It can also be useful to confirm a suspicious recurrence on other types of imaging.

## STAGING AND PATHOLOGY

Staging usually occurs after or during surgery. Often the diagnosis is made clinically at operation when the presence of an adherent, firm whitish-gray parathyroid gland is noted, sometimes invasion of adjacent neck structures is noted at operation. One series reported invasion of



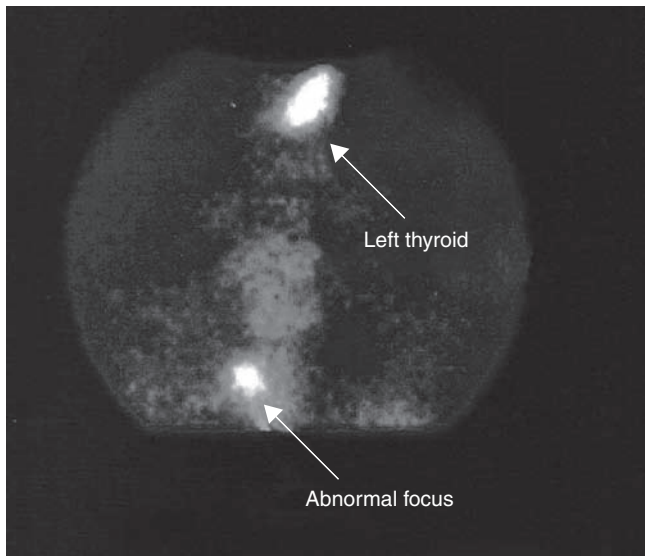
**Figure 30.3** The use of dual modality to identify parathyroid gland. (a) Planar Sestamibi of left lateral neck. (b) Transverse ultrasound of left neck. JUG, jugular vein; arrow.



**Figure 30.4** Parathyroid carcinoma on conventional Sesta MIBI imaging. Right upper thyroid area.

ipsilateral thyroid gland (89%), strap muscles (71%), ipsilateral recurrent laryngeal nerve (26%), esophagus (18%), and trachea (17%)<sup>30</sup>. A minimum of an en bloc resection with a hemithyroidectomy should be performed if the gland is suspicious. Parathyroid carcinomas typically weigh between 2 and 10 g (mean 7 g) and have a median size of 3.3 cm<sup>31</sup>. This is much larger than most adenomas that typically weigh between 80 mg and 2 g. Despite these defining characteristics, often inadequate surgery is performed because the diagnosis is not recognized at surgery. Initial incomplete

excision and a subsequent high recurrence rate is a common problem with these tumors. If after surgery the PTH and calcium remains high, then MRI scanning is the most helpful in assessing disease. SPECT Sesta MIBI, PET and venous sampling can be adjuncts to define metastases. Repeat surgery for benign hyperparathyroidism requires two correlating modalities from the five modalities mentioned above to justify a further surgical procedure. This needs to be borne in mind if considering operating on possible metastatic disease.



**Figure 30.5** Ectopic parathyroid gland in anterior mediastinum. Note the parathyroid pathology can be found anywhere from submandibular gland to the mediastinum.

## Pathology

Ultimately formal histology provides the diagnosis. Frozen section assessment of the affected parathyroid glands is difficult and the pathologist usually prefers to have a fixed specimen for more accurate histology. Frozen section of lymph nodes can be helpful in defining the extent of the lymph node dissection required by the tumor.

Establishing the histological diagnosis can be difficult as the immunocytochemical markers such as Ki-67, cyclin D1, MIB-1, and p27 have been used to aid diagnosis but benign and malignant tumors of the parathyroid gland can be positive for these markers<sup>32</sup>. In 1973 Schantz and Castleman<sup>33</sup> described a 'classical' histological finding (trabecular growth pattern, presence of capsular or vascular invasion, and numerous mitotic figures) but in reality these are all present in only a minority of cases. The most consistent findings include loss of typical lobular architecture, areas of fibrosis with hyaline bands splitting up the parenchyma in a nodular fashion and presence of nuclear atypia and prominent nucleoli. When a diagnosis cannot be made definitively, then a diagnosis of atypical parathyroid adenoma or parathyroid adenoma with suspicious features will be made<sup>34</sup>. This subset of patients lacks unequivocal evidence of invasive growth. Some have shown these patients to later develop recurrent or metastatic disease, confirming the original presence of malignancy; however, there is still not an absolute consensus on definition and some series have shown no recurrence rates when necrosis within the tumor is excluded from the definition. They usually act more like benign adenomas.

Parathyroid carcinoma is usually a single gland tumor, but multigland involvement has been documented<sup>35</sup>.

Investigation of hereditary (HPT-JT) syndrome has led to the discovery that it is associated with a germ-line mutation of the suppressor gene *HRPT2* which encodes the parafibromin protein product. Somatic gene mutations of *HRPT2* are present in 60–100% of sporadic parathyroid carcinomas. In most cases, mutations of *HRPT2* are associated with loss of heterozygosity and absence of parafibromin expression<sup>36</sup>. Several other studies have identified loss of heterozygosity in the long arm of chromosome 13 in parathyroid carcinoma. This gene is linked with the retinoblastoma gene and breast cancer susceptibility (*BRAC2*) gene. Loss of alleles for segments of chromosomes 1, 7, 10, and 13 have been found to be significantly higher in parathyroid carcinomas than in adenomas or parathyroid hyperplasia<sup>37</sup>.

## SURGERY FOR CURE

Often the malignant tumors are difficult to dissect off the thyroid, appear whitish gray rather than 'salmon pink', or are greater than 1000 mg and therefore arouse suspicion in the surgeon's mind. At surgery, if there is suspicion that the lesion is a carcinoma, then a hemithyroidectomy should be performed. This en bloc dissection gives the best chance of decreasing recurrence. En bloc resection involves the careful preservation of the parathyroid gland capsule, removal of contiguous lymph nodes and soft tissue from the ipsilateral central neck compartment. This procedure does not always require a formal central compartment lymphadenectomy, but it should involve removal/frozen section of any suspicious lymph nodes or any lymph nodes adjacent to the affected parathyroid gland. Any adherent structures should be resected with the specimen. The recurrent laryngeal nerves should only be removed if directly involved with the tumor (Table 30.2). Of those patients who only undergo routine parathyroidectomy because cancer is not suspected, 50% will develop local recurrence<sup>30</sup>.

## Lymph node dissection

Therapeutic modified radical neck dissection is indicated if cervical nodes are involved at the time of the initial operation<sup>15</sup>. Frozen section of the lymph nodes can be used to help decide on extent of operation. Prophylactic or radical neck dissection does not improve survival and is associated with increased risk of operative complications<sup>38</sup>. Thyroid lobectomy is usually used to obtain clear margins rather than to remove tumor in the thyroid lobe<sup>39</sup>. It is widely accepted that those patients who have en bloc resection have a longer disease-free and overall survival than those who have a lesser procedure<sup>38</sup>.



Table 30.2

*At the first operation, if any of the indications in Table 30.1 is found before/at operation one should CONSIDER performing*

En bloc resection including abnormal parathyroid gland and hemithyroidectomy

Frozen section of level VI (central neck) lymph nodes  $\pm$  level VI dissection

*Principles of surgery if more extensive disease is found*

All macroscopic disease should be removed with appropriate local structures and draining lymph nodes

If the tumor is found to invade any structure then a **minimum** of en bloc level VI, hemithyroidectomy, parathyroidectomy should be performed

If positive lymph nodes are found at level VI: an ipsilateral modified/radical neck dissection should be performed. Contralateral thyroidectomy and contralateral level VI dissection may also be required and should be considered

Intraoperative PTH levels can guide the extent of the operation if macroscopic disease is not present

*When the diagnosis of parathyroid carcinoma is made on histology after first operation unexpectedly*

Further surgery should be performed so that a **minimum** of complete resection of original site of parathyroid carcinoma and hemithyroidectomy is performed. Ipsilateral level VI dissection (central neck dissection) and ipsilateral hemithyroidectomy is the best way to ensure definitive en bloc resection of original site of parathyroid lesion

Intraoperative PTH levels and frozen sections can help guide extent of the operation if other areas need to be excised

PTH, parathyroid hormone.

More controversial is the management of parathyroid carcinoma that is diagnosed after the operation by histology. Further surgery should always be considered because of the very high incidence of local recurrence after parathyroidectomy alone (see above). Ipsilateral hemithyroidectomy should be performed with or without central node neck dissection (level VI) whenever possible.

Further surgery may not be necessary in those tumors with biologically low malignant potential and minimal invasion and some advocate follow-up at 3-monthly intervals for these patients<sup>40</sup>.

In those patients who have hypercalcemia and raised PTH levels postoperatively, the first operation was definitely inadequate and, after MRI assessment, a more extensive procedure should be performed: ipsilateral hemithyroidectomy with ipsilateral central compartment (level 6) dissection with or without ipsilateral modified neck dissection. Contralateral hemithyroidectomy with or without contralateral level 6 dissection may also be required. In these cases multiple intraoperative rapid intact PTH assays and an MRI scan can aid decisions on the extent of the operative procedure. The aim is to bring the PTH level to below 0.5 ng/ml at the end of the operation.

### Postoperative care

If the levels of PTH and calcium have been very high then often in the postoperative period the patient will develop hungry bone syndrome where it is difficult to maintain calcium levels over 1.9 mmol/l with oral supplementation

of vitamin D and calcium, and there is a need for a continuous calcium infusion. These patients can take up to 6 weeks to be able to maintain adequate calcium levels on vitamin D/calcium oral supplementation alone. A typical daily calcium infusion would be 40–60 ml of 10% calcium gluconate in 500–1000 ml of normal saline (0.9%) over 24 hours with supplementation of 1–2 g alfacalcidol and calcichew three tablets three times a day. Magnesium levels should also be monitored during this time and intravenous/magnesium given appropriately.

Over a period of days/weeks the need for intravenous infusion decreases and the supplementation will be sufficient. In patients without any of their parathyroid glands a good diet with 500–1000 ng of alfacalcidol should be sufficient. If their diet is inadequate then oral calcium supplementation will be required long term.

Once the patient is stabilized then serum calcium and PTH levels should be monitored 3 monthly for the first year and then 6 monthly thereafter.

### PALLIATIVE SURGERY

In spite of a 'curative' resection the recurrence rate of parathyroid carcinoma is approximately 50%<sup>15</sup>. Most recurrences occur 2–3 years after the initial operation but there can be decades before identifiable recurrence occurs<sup>41</sup>. A short disease-free interval is associated with a poor prognosis.

Parathyroid carcinoma metastasizes through both lymphatic and hematological routes. Of patients 30%

**Table 30.3** Adjuvant therapy and follow-up*Postoperative follow-up*

Secreting parathyroid carcinomas

PTH serum levels (3 monthly)

calcium serum levels (3 monthly once stable)

Non-secreting parathyroid carcinomas

clinical examination

6-monthly MRI scan for 2 years

PET Scanning can be useful when suspicious of recurrence

*Adjuvant treatment*

Radiotherapy

should be discussed with an endocrine tumor oncologist in all cases

Radiotherapy treatment is indicated if

tumor is invading other structures

lymph node involvement is present

any other aggressive features

Chemotherapy

should only be considered if recurrent or distant metastatic disease; very little in literature to support any chemotherapy

PTH, parathyroid hormone; MRI, magnetic resonance imaging; PET, position emission tomography.

**Table 30.4** Adjuvant treatment useful with uncontrolled hypercalcaemia and recurrence*Bisphosphonates*

Pamidronate

Zolendronate – stronger (effect lasts longer) but more side-effects

*Calcimimetics*

Cinacalcet (30–60 mg daily) – can become ineffective over a period of time

will present with regional lymph node involvement, these are palpable in 45% of patients. Distant metastases commonly involve the lungs and bone, but can involve liver and other organs.

Imaging for recurrence involves MRI scanning, Sesta MIBI Scan<sup>42</sup>, occasional PET scan<sup>28</sup>, and venous sampling if specific areas of recurrence need to be identified. A technetium-99m methylene diphosphonate (MDP) bone scan can be helpful in assessing possible metastatic disease, however, the coexistence of osteitis fibrosa cystica can lead to diagnostic pitfalls<sup>43</sup>.

Surgery is the treatment for recurrence to reduce tumor load, for locoregional recurrence. Cervical and mediastinal exploration wide resection with thymectomy is advised. Multiple operations for palliation have been shown to be helpful<sup>15,41</sup>.

**Adjuvant radiotherapy**

There are no prospective or randomized controlled studies regarding adjuvant radiotherapy of parathyroid carcinomas and these are unlikely to exist because of the rarity and the diversity of the tumor. Radiotherapy was thought not to be helpful, however, an increasing number of studies have demonstrated that there may be an increased disease-free survival if radiotherapy is given after surgery<sup>44</sup>, with some studies even suggesting that this is independent of the type of tumor and the disease stage<sup>45</sup>. There is a growing consensus of support for adjuvant radiotherapy for these tumors. Preoperative external beam radiotherapy as primary treatment or to shrink bulky disease has been unsuccessful.

**Adjuvant chemotherapy**

Chemotherapy is not used as an adjuvant therapy and would only be possibly considered for recurrence that is deemed inoperable. Chemotherapeutic agents have been unsuccessful in many cases. There are a few case reports of chemotherapy success. Combination of cyclophosphamide with or without 5-fluorouracil and dacarbazine has been shown to give a modest response but often only for short periods<sup>46</sup>. Other drugs including doxorubicin and vincristine, have yielded little or no response. Another case report<sup>47</sup> reported a good response for chemoradiotherapy.

**Palliative care**

The main problems in palliative care are of uncontrolled hypercalcaemia and its side-effects. It is rare to die from tumor burden itself, usually it is from uncontrolled hypercalcaemia<sup>48</sup>.

In an acute hypercalcemic crisis, urgent restoration of fluid volume is needed with 0.9% saline intravenous solution (200–300 ml/h). This can be followed by the use of a loop diuretic, e.g. frusemide (increases renal excretion of calcium). Dehydration can be a problem with the use of loop diuretics and therefore the calcium levels need to be measured regularly. My personal experience is that adding loop diuretics is of little help. Bisphosphonates are most often prescribed, e.g. pamidronate (60–90 mg given intravenously over 2–4 hours). These drugs interfere with osteoclast-mediated bone resorption and take



2–4 days to decrease calcium levels. More recently, zoledronate has been reported as being more effective at lowering serum calcium levels and can be administered more rapidly than other bisphosphonates. However, this is associated with more gastrointestinal, bone (avascular necrosis of the jaw), cardiac and renal side-effects. Long-term control of hypercalcemia can be achieved with bisphosphates but the effectiveness of the drugs decreases with time.

In 2004, cinacalcet was approved for the treatment of hypercalcemia associated with parathyroid carcinoma and tertiary hyperparathyroidism<sup>49</sup>. It is a calcimimetic, these drugs bind to the calcium sensing receptor on the surface of the parathyroid cells, increasing the receptor sensitivity to extracellular calcium and decreasing the secretion of PTH. Cinacalcet at a dose of 30–60 mg orally is well tolerated and has been shown to improve long-term control of serum calcium level in patient with primary hyperparathyroidism, including parathyroid carcinoma<sup>50,51</sup>.

Calcitonin reduces serum calcium, and although its effects are short lived, it can be helpful while waiting for the bisphosphonates to work.

Gallium nitrate has been used and is an effective hypocalcemic agent but its use is limited by its nephrotoxicity, WR-2721 (amifostine) is a chemoprotective agent that acts by inhibiting PTH secretion. It is very effective but has severe toxicity problems<sup>52</sup>. In practice these two drugs are rarely if ever used.

Dendritic cell immunotherapy<sup>53</sup> and immunization with human and bovine PTH peptides<sup>54</sup> are new therapies that may be used in the future.

## OUTCOMES

In spite of the best surgical efforts the recurrence rates for parathyroid carcinoma range from 33 to 78%<sup>38</sup>. The mean time to recurrence is usually between 3 and 5 years. The 10-year survival rates may be improving with the use of radiotherapy and hypercalcemic control. In 2004 Clayman *et al.* reported 5- and 10-year survival rates, of 85% and 77%, respectively<sup>45</sup>, compared with Hundahl *et al.* in 1999<sup>3</sup> who reported 5- and 10-year survival rates, of 85% and 49%, respectively. Neither lymph node status nor size of tumor seems to affect overall survival directly<sup>3</sup>.

Parathyroid carcinoma is a slow growing tumor of low malignant potential that infiltrates surrounding tissues and spreads by both lymphatic and hematogenous spread. Death is usually due to the metabolic consequences (renal failure, cardiac arrhythmias and pancreatitis) of hypercalcemia rather than to the tumor load itself.

Surgical resection has always been the mainstay of treatment and there is a growing body of clinicians that are using adjuvant radiotherapy. Calcimimetic agents and immunotherapy may enable us to prolong life because of better hypercalcemic control.

## REFERENCES

- Gallagher SF, Denham DW, Murr MM. The impact of minimally invasive surgery on the way endocrinologists treat primary hyperparathyroidism. *Surgery* 2003; 134: 910–7.
- De Quervain F. Parathyroid carcinoma. *Dtsch Z Chir* 100: 334–52.
- Hundahl SA, Fleming ID, Fremgen AM, Menck HR. Two hundred and eighty-six cases of parathyroid carcinoma treated in the US between 1985–1995; a National Cancer Data Base Report. The American College of Surgeons Commission on Cancer and the American Cancer Society. *Cancer* 1999; 86: 538–44.
- Hamill J, Maoate K, Beasley SW *et al.* Familial parathyroid carcinoma in a child. *J Paediatr Child Health* 2002; 38: 314–7.
- Cohn K, Silverman M, Corrado J, Sedgewick C. Parathyroid carcinoma: the Lahey Clinic experience. *Surgery* 1985; 98: 1095–100.
- Hakaim AG, Esselstyn CB Jr. Parathyroid carcinoma: 50 year experience at the Cleveland Clinic Foundation. *Cleve Clin J Med* 1993; 60: 331–5.
- Obara T, Fujimoto Y. Diagnosis and treatment of patients with parathyroid carcinoma: an update and review. *World J Surg* 1991; 15: 738–44.
- Heath H, Purnell DC. Asymptomatic hypercalcaemia and primary Hyperparathyroidism in Calcium Disorders. London: Butterworth Scientific, 1982: 189–216.
- Wassif WS, Minoz CF, Friedman E *et al.* Familial isolated hyperparathyroidism: a distinct genetic entity with an increased risk of parathyroid cancer. *J Clin Endocrinol Metab* 1993; 77: 1485–9.
- Chen JD, Morrison C, Zhang C *et al.* Hyperparathyroidism-jaw tumor syndrome. *J Intern Med* 2003; 253: 634–42.
- Schnatz A, Castleman B. Parathyroid carcinoma: a study of 70 cases. *Cancer* 1973; 31: 600–5.
- Bossola M, Tazza L, Ferrante A *et al.* Parathyroid carcinoma in a chronic hemodialysis patient: case report and review of the literature. *Tumori* 2005; 91: 558–62.
- Simonda WF, James-Newton O, Agarwal SK *et al.* Familial isolated hyperthyroidism. Clinical and genetic characterisations of 36 kindreds. *Medicine* 2002; 81: 1–26.
- Shane E. Clinical review 122 cases. Parathyroid carcinoma. *J Clin Endocrinol Metab* 2001; 86: 485–93.
- Kebebew E. Parathyroid carcinoma. *Curr Treat Options Oncol* 2001; 2: 347–54.
- Wang CA, Gaz RD. Natural history of parathyroid carcinoma. Diagnosis, treatment and results. *Am J Surg* 1985; 149: 522–7.
- Holmes EC, Morton D, Ketcham AS. Parathyroid carcinoma: a collective review. *Ann Surg* 1969; 169: 631–40.
- Kleinpeter KP, Lovato JF, Clark PB *et al.* Is parathyroid carcinoma indeed a lethal disease? *Ann Surg Oncol* 2005; 12: 260–6.

19. Shaha AR, Shah JP. Parathyroid carcinoma: a diagnostic and therapeutic challenge. *Cancer* 1999; 86: 378–80.
20. Robert JH, Trombetti A, Garcia A et al. Primary hyperparathyroidism: can parathyroid carcinoma be anticipated on clinical and biochemical grounds? Report of nine cases and review of literature. *Ann Surg Oncol* 2005; 12: 526–32.
21. Murphy MN, Glennon PG, Diocee MS et al. Nonsecretory parathyroid carcinoma of the mediastinum: light microscopic, immunohistological and ultrastructural features of a case and review of the literature. *Cancer* 1986; 55: 2468.
22. Giessler GA, Beech DJ. Nonfunctional parathyroid carcinoma. *J Natl Med Assoc* 2001; 93: 251–5.
23. Guarnieri V, Scillitani A, Muscarella LA et al. Diagnosis of parathyroid tumours in the familial isolated parathyroidism with HRPT2 mutation: implications for cancer surveillance. *J Clin Endocrinol Metab* 2006; 91: 2827–32.
24. Palestro CJ, Tomas MB, Tronco GG. Radionuclide imaging of the parathyroid glands. *Semin Nucl Med* 2005; 35: 266–76.
25. O'Doherty MJ, Kettle AG, Wells P et al. Parathyroid imaging with technetium-99m-sestamibi: preoperative localization and tissue uptake studies. *J Nucl Med* 1992; 33: 313–8, 1091–8, 1801–7.
26. Hindie E, Mellièrè D, Jeanguillane et al. Parathyroid imaging using simultaneous double window recording of technetium 99m sestamibi and iodine 123. *J Nucl Med* 1998; 39: 1100–5.
27. Weber AL, Randolph G, Askoy FG. The thyroid and parathyroid glands. CT and MR imaging and correlation with pathology and clinical findings. *Radiol Clin North Am* 2000; 38: 1105–29.
28. Arslan N, Rydzewski B. Detection of a recurrent parathyroid carcinoma with FDG positron emission tomography. *Clin Nucl Med* 2002; 27: 221–2.
29. Kebebew E, Arici C, Duh QY, Clark OH. Localisation and reoperation results for persistent and recurrent parathyroid carcinoma. *Arch Surg* 2001; 136: 878–85.
30. Koea JB, Shaw JH. Parathyroid cancer: biology and management. *Surg Oncol* 1999; 8: 155–65.
31. Hahrch HR. The parathyroid in endocrine pathology: differential diagnosis and molecular advances. Totowa, NJ: Humana Press, 2004: 109–22.
32. Delellis Ronald A. Parathyroid Carcinoma: an overview. *Advances in Anatomic Pathology* 2005; 12: 53–61.
33. Schantz A, Castleman B. Parathyroid carcinoma: a study of 70 cases. *Cancer* 1973; 31: 600–5.
34. Guiter GE, Delessis RA. Risk of recurrence or metastases in atypical parathyroid adenoma. *Mod Pathol* 2002; 15: 115A. Abstract.
35. Brown JJ, Mohamed H, Smith L et al. Primary hyperparathyroidism secondary to simultaneous bilateral parathyroid carcinoma. *Ear Nose Throat J* 2002; 81: 395–401.
36. Gill AJ, Clarkson A, Gimm O et al. Loss of nuclear expression of parafibromin distinguishes parathyroid carcinomas and Hyperparathyroidism- Jaw Tumour( HPT-JT) Syndrome- related Adenomas from sporadic parathyroid adenomas and hyperplasia. *Am J Surg Pathol* 2006; 30: 1140–9.
37. Hunt JL, Carty SE, Yim JH et al. Allelic loss in parathyroid neoplasia can help characterise malignancy. *Am J Surg Pathol* 2005; 29: 1049–55.
38. Sandelin K, Auer G, Bondeson L et al. Prognostic factors in parathyroid cancer: A review of 95 cases. *World J Surg* 1992; 16: 724–31.
39. Hoeting T, Weber T, Werner J, Herfarth C. Surgical treatment of parathyroid carcinoma (review). *Oncol Rep* 2001; 8: 931–4.
40. Fujimoto Y, Obara T, Ito Y et al. Localisation and surgical resection of metastatic parathyroid carcinoma. *World J Surg* 1986; 10: 539–47.
41. Shane E. Clinical review 122: Parathyroid carcinoma. *J Clin Endocrinol Metab* 2001; 86: 485–93.
42. Al-Sobhi S, Ashari LH, Ingemansson S. Detection of metastatic parathyroid carcinoma with Tc-99m sestamibi imaging. *Clin Nucl Med* 1999; 24: 21–3.
43. Pianou N, Housianakou I, Papathanasoiu N et al. Brown tumors in the technetium-99m methylidiphosphanate bone scan mimicking metastases of the parathyroid carcinoma. *Hell J Nucl Med*. 2006; 9: 146–8. [in Greek].
44. Munson ND, Foote RL, Northcutt RC et al. Parathyroid carcinoma is there a role for adjuvant radiotherapy. *Cancer* 2003; 98: 2378–84.
45. Clayman GL, Gonzalez HE, El-Naggar A, Vassilopoulou-Sellin R. Parathyroid carcinoma: evaluation and interdisciplinary management. *Cancer* 2004; 100: 900–5.
46. Bukowski RM, Sheller L, Cunningham J, Esselstyn C. Successful combination chemotherapy for metastatic parathyroid carcinoma. *Arch Intern Med* 1984; 114: 399–400.
47. Eurelings M, Frijns CJM, Jeurissen FJF. Painful ophthalmoplegia from metastatic non-producing parathyroid carcinoma: case study and review of the literature. *Neuro-oncol* 2002; 4: 44–8.
48. Wynne AG, Van Heerden J, Carney JA, Fitzpatrick LA. Parathyroid carcinoma: clinical and pathological features in 43 patients. *Medicine* 1992; 71: 197–205.
49. Krebs LJ. Calcimimetics and hyperparathyroidism. *Curr Opin Investig Drugs* 2004; 5: 1080–5.
50. Collins MT, Skarulis MC, Bilezikian JP et al. Treatment of hypercalcaemia secondary to parathyroid carcinoma with a novel calcimimetic agent. *J Clin Endocrinol Metab* 1998; 83: 1083–8.
51. Peacock M, Bilezikian JP, Klassen PS et al. Cinacalcet hydrochloride maintains longterm normocalcaemia in patients with primary hyperparathyroidism. *J Clin Endocrinol Metab* 2005; 90: 135–41.
52. Glover DJ, Shaw L, Glick JH et al. Treatment of hypercalcaemia in parathyroid carcinoma with WR-2721, S-2-(3-aminopropyl-amino) ethyl-phosphorothioic acid. *Ann Intern Med* 1985; 103: 55–7.
53. Schott M, Feld Kamp J, Schattenburg D et al. Induction of cellular immunity in a parathyroid carcinoma treated with tumour lysate – pulsed dendritic cells. *Eur J Endocrinol* 2000; 142: 300–6.
54. Bradwell AR, Harvey TC. Control of hypercalcaemia of parathyroid carcinoma by immunisation. *Lancet* 1999; 353: 370–3.



# Neuroendocrine tumors of the gastrointestinal tract

31

Menno R Vriens and Inne HM Borel Rinkes

## INTRODUCTION

In this chapter we concentrate on the following neuroendocrine tumors: carcinoid tumors and pancreatic endocrine tumors.

Carcinoid tumors, related to the gastrointestinal tract, can be found in the stomach, jejunum, ileum, appendix, ascending colon, and colorectal. Carcinoid primary tumors occur in the appendix (38%), ileum (23%) and rectum (13%). Flushing is the most frequent symptom (94%), followed by diarrhea (78%) and abdominal pain or cramping (51%). Other symptoms include endocardial fibrosis, wheezing, myopathy, arthritis, arthralgias, and changes in mental state. Carcinoid syndrome occurs in fewer than 10% of patients with carcinoid tumors and has an incidence of about 3.2–5 cases per million of the population per year and results from excessive secretion of hormone products into the systemic circulation (e.g. adrenocorticotrophic hormone (ACTH), gastrin, pancreatic polypeptide, insulin, tachykinins, vasoactive intestinal polypeptide (VIP), serotonin, or 5-hydroxyindoleacetic acid (5-HIAA)).

Carcinoid syndrome does not usually develop until a tumor has metastasized, usually to the liver. The incidence of metastases in carcinoid tumors is less than 2% in tumors smaller than 1 cm and almost 100% in tumors greater than 2 cm. Surgical removal of the tumors is the primary therapeutic option; chemotherapy is less effective. Octreotide is the primary medical therapy for the management of certain symptoms associated with carcinoid syndrome.

Pancreatic endocrine tumors occur 1 per 100 000 of the population. In this chapter we discuss the incidence, diagnostics, treatment, and prognosis of gastrinomas, insulinomas, glucagonomas, VIP secreting tumors (VIPomas), somatostatinomas, pancreatic polypeptide secreting tumors (PPomas), and non-functioning islet cell tumors (Table 31.1).

Optimal imaging and staging of the disease are the most important factors in both medical and surgical treatment of neuroendocrine tumors. Localization of the primary tumor and exclusion of metastatic disease, before performing surgery, is best practice. When liver metastases

have been identified and considered for resection, resectability of both solitary and multifocal lesions should be determined<sup>1</sup>.

## IMAGING

At present, gastrointestinal carcinoid tumors are often difficult to diagnose because of their small size and multiplicity. Endoscopy and endoscopic ultrasonography provide sensitive tools for visualizing gastric and duodenal carcinoids. Proctoscopy and colonoscopy together with ultrasonography can visualize rectal and sigmoid carcinoids. However, primary midgut tumors are difficult to diagnose. On occasion, they can be detected on barium enema, but usually lymph node and liver metastases (when at least 0.5–1 cm in diameter) are detected by computed tomography (CT) and magnetic resonance imaging (MRI)<sup>2–4</sup>. The current most sensitive diagnostic procedure for optimal management of patients with neuroendocrine tumors is somatostatin receptor scintigraphy (SRS). The sensitivity of SRS for the detection of carcinoid tumors has been reported to lie between 80 and 100% in different studies. There is no significant difference between foregut, midgut and hindgut tumors. Scintigraphy also provides a more accurate staging of the disease by demonstrating tumor sites which are not shown by conventional imaging. It also indicates the number of somatostatin receptors which may indicate efficacy of treatment with octreotide<sup>2</sup>. In a recent study Dimitroulopoulos *et al.* evaluated the diagnostic sensitivity and accuracy, and the cost-effectiveness of SRS in the detection of gastroenteropancreatic carcinoid tumors and their metastases in comparison with conventional imaging methods. They concluded that SRS imaging is a very sensitive method for the detection of gastroenteropancreatic carcinoids but is less sensitive than ultrasound and CT in the detection of liver metastases. Between several imaging combinations, the combination of chest X-ray/upper abdominal CT/SRS shows the highest sensitivity (89%) with a cost of €1294.93<sup>5</sup>.

**Table 31.1** Pancreatic endocrine tumors

<i>Types</i>	<i>Incidence per million per year</i>	<i>Clinical features</i>
Gastrinomas	0.5–4	Peptic ulcers, diarrhea
Insulinomas	2–4	Hypoglycemia, neuroglycopenic
Glucagonomas erythema	1	Necrolytic migratory
VIPomas	1	Watery diarrhea syndrome
Somatostatinomas neurofibromatosis	0.025	Non-specific,
PPomas	< 1	Jaundice due to compression
Non-functioning tumors	< 1	Pain, jaundice

VIPomas, vasoactive intestinal polypeptide secreting tumors; PPomas, pancreatic polypeptide secreting tumors.

Next to SRS, positron emission tomography (PET) is a non-invasive technique for measurement of regional tracer accumulation and quantification. PET has already provided much improved sensitivity in the localization of both primary and metastatic neuroendocrine tumors<sup>6</sup>. In the future, improved cameras and new tracers might further improve the sensitivity and specificity of SRS and PET, but already tumors as small as 2 mm can be visualized with the current PET technique<sup>2</sup>.

Li and Behshti state that in case of metastatic disease no single imaging technique identifies all the metastatic sites of neuroendocrine tumors. The best results may be obtained with a combination of functional imaging such as PET or/and SRS and morphological imaging with CT and/or MRI. Many molecular imaging and therapy modalities for neuroendocrine tumors are under investigation or being developed. The usefulness of these modalities, however, has to be evaluated by well-designed and multicenter studies<sup>7</sup>.

## BIOCHEMICAL MARKERS

The biochemical diagnosis of endocrine digestive tumors is based on general and specific markers. The best general markers are chromogranin A and pancreatic polypeptide (PP). Specific markers for endocrine tumors include insulin, gastrin, glucagon, VIP, somatostatin, and the primary catabolic product of serotonin, 5-HIAA<sup>8</sup>. Chromogranin A is a glucoprotein which is widely expressed in

neuroendocrine cells and constitutes one of the most abundant components of secretory granules. Chromogranin A immunohistochemistry is the main step in the diagnosis of neuroendocrine tumors. Increased levels of chromogranin A have been reported in 50–80% of pancreatic endocrine tumors. Serum pancreatic polypeptide alone shows a sensitivity of between 40 and 55%. Determination of plasma insulin and proinsulin concentrations by radioimmunoassay has simplified the diagnosis for insulinomas. For gastrinomas the combination of serum gastrin concentration together with a basal acid output (BAO) and penta-gastrin-stimulated acid output (MAO) is the most sensitive. The diagnosis of a glucagonoma is made on the basis of a raised fasting plasma glucagon concentration. Somatostatinomas are associated with excessive somatostatin secretion. VIPomas (Verner-Morrison syndrome) are associated with secretion of VIP. Carcinoid is usually diagnosed by increased 24-hour urinary 5-HIAA levels.

## CARCINOIDS

In general, radical surgical resection is considered to be the treatment of choice. However, in many instances carcinoids are found incidentally and are often not diagnosed until after surgery, when ileus/obstruction, ischemia, or other abdominal disturbances occur. Whenever carcinoids are diagnosed preoperatively, e.g. following endoscopic biopsy, surgery has to be considered, along with perioperative measures to prevent a carcinoid crisis during surgery (e.g. administration of octreotide). Surgical treatment is dominated by the location of the primary tumor<sup>1</sup>.

### Gastric carcinoids

Gastric endocrine tumors usually grow from enterochromaffin-like cells (ECL). They are rare neoplasms occurring in 1–2 per million of the population per year. Three types of tumor may be distinguished on the basis of the background gastric pathology: type I, which develops in atrophic body gastritis (ABG), represents 70–80% of the cases; type II, which is associated with multiple endocrine neoplasia (MEN) and Zollinger-Ellison syndrome and represents 5% of gastric carcinoids; and the sporadic type III, which is not associated with any background pathology and represent the remaining 15–20% (Table 31.2). This classification plays a major role in determining the optimal approach to these diseases<sup>9</sup>.

Due to their indolent course, an appropriate treatment for type I gastric carcinoids, localized in the gastric fundus/body, would be surveillance endoscopic follow-up based on gastroscopy with multiple gastric biopsy<sup>10</sup>, and a conservative approach with endoscopic resection and eventually

**Table 31.2** Risk of developing a gastric carcinoid in patients with atrophic body gastritis (ABG), multiple endocrine neoplasia types 1 (MEN-1) associated, or sporadic Zollinger-Ellison syndrome (ZES)

<i>Background pathology</i>	<i>Risk of developing carcinoid (%)</i>	<i>Risk of developing metastases in case of carcinoid</i>
ABG (type I)	1	Exceptional
MEN-1/ZES (type II)	20–30	Up to 30%
Sporadic ZES (type III)	0–1	50–100%

From reference 9.

somatostatin analogues. Gastric carcinoids do not tend to metastasize. Type II carcinoids are often multiple and thus not suitable for complete endoscopic resection. They develop in the gastric fundus/body, and rarely in the antrum as well. Regional lymph node involvement has been described in 30% of patients. In these cases the somatostatin analog octreotide has been demonstrated to be effective at reducing tumor growth<sup>11</sup>. Surgery is the treatment of choice for type III gastric carcinoid, which grows from the gastric fundus/body. This carcinoid has an aggressive tumor behavior (liver and lymph node metastases are frequent) and a high risk of tumor-related death. There is no place for somatostatin analogs.

### Carcinoids of jejunum, ileum and ascending colon

Carcinoids arising in the distal jejunum and ileum have a worse prognosis, compared with duodenal, gastric and rectal carcinoids, since they frequently lead to metastases to the adjacent lymph nodes, to the liver and other sites. The 10-year survival rate is approximately 43%, and this is more favorable if the primary tumor has been removed and liver metastases are absent. Therefore, in patients with small carcinoids in the ileum that have been discovered incidentally during endoscopy, a generous resection of ileum and distal jejunum is recommended. Aggressive palliative cytoreductive surgical treatment of the primary tumor, lymph node metastases and even liver metastases can ameliorate symptoms and improve survival in patients with advanced disease<sup>12</sup>.

### Appendiceal carcinoid

Carcinoids of the appendix are rare and are usually detected incidentally after appendectomy. Tumors less than 1 cm hardly ever metastasize and are treated by appendectomy.

Tumors larger than 2 cm require a right-sided hemicolectomy because of a significant risk of metastatic spread, even when primary surgery (appendectomy) has been radical. Treatment for lesions 1–2 cm is controversial and needs further characterization of the tumor and careful patient risk evaluation<sup>13</sup>. Median survival is 5–8 years. For surgically resectable tumors 10-year survival rates of more than 60% have been reported.

### Colorectal carcinoid

Small colorectal carcinoids may be treated by either polypectomy or transanal local excision, but for tumors larger than 2 cm in diameter an oncological resection is mandatory<sup>1</sup>. Carcinoid tumors are about twice as likely to occur in the rectum than in the colon. They grow slowly and have about a 1/300 000 chance of metastasizing. However, if carcinoid tumors do spread (to lymph nodes or liver) the survival rates mimic those of colorectal cancer.

## ISLET CELL TUMORS

### Gastrinomas

Zollinger-Ellison syndrome (ZES) is characterized by peptic ulcers of the upper gastrointestinal tract failing to heal despite maximal medical therapy, diarrhea and marked gastric acid hypersecretion associated with a gastrin-secreting tumour (gastrinoma). ZES might be associated with multiple endocrine neoplasia type 1 (MEN-1). To identify the localization of gastrinoma several imaging techniques have been proposed. Compared with ultrasound, CT and MRI, SRS is capable of locating the tumor in 80% of cases and of identifying it even in anatomic sites other than pancreas and duodenum. A new technique called selective arterial secretagogue injection test (SASI test) is able to identify even small tumors with a high sensitivity and specificity (both >90%)<sup>14</sup>. The two main principal therapeutic strategies are to control both the gastric acid hypersecretion and the growth of the neoplasia. The best surgical treatment is excision of gastrinoma before metastatic spread has occurred. However, about 50% of patients have metastases at the time of operation. Somatostatin analog can reduce both gastric acid hypersecretion and serum gastrin levels. Moreover, they have an antiproliferative effect. Chemotherapy, interferon and/or embolization are indicated in rapidly evolving tumors or in cases in which the tumoral symptoms cannot be treated by other approaches<sup>15</sup>. In a prospective study involving 123 patients with sporadic gastrinoma who had a surgical resection of tumor, Norton *et al.* showed cure rates of 40% at 5 years and 34% at 10 years<sup>16</sup>. In general, the progression

of gastrinomas is relatively slow with a combined 5-year survival rate of 65% and 10-year survival rate of 51%. In patients with ZES/MEN-1 the most important predictor of survival is the development of liver metastases. Since patients with ZES/MEN-1 with tumors of 2 cm or more have an increased probability of developing liver metastases, surgical exploration is recommended in these patients. Duodenotomy has improved both the tumor detection rate and the cure rate and should be routinely performed. Whipple pancreaticoduodenectomy results in the highest probability of cure in both sporadic and MEN-1 gastrinoma patients as it removes the entire gastrinoma triangle. However, the excellent long-term survival of these patients with lesser operations and the increased operative mortality and long-term morbidity of Whipple make its current role in the management of these patients unclear until studies are done to clarify these issues<sup>17</sup>.

### Insulinomas

Insulinomas are the most frequent of all islet cell tumors, with an incidence of 2–4 cases per million of the population per year. Insulinomas are characterized by fasting hypoglycemia and neuroglycopenic symptoms. The episodic nature of the hypoglycemic attacks is due to the intermittent insulin secretion by the tumor. The majority of insulinomas are intrapancreatic, benign and solitary. They are equally distributed between head, body and tail of the pancreas. Approximately 85% of insulinomas occur singly, 6–13% are multiple, and 4–6% are associated with MEN-1. Overall 5-year survival has been reported to approach 97%<sup>18</sup>. Surgical resection is the treatment of choice. A multimodal approach to detect primary tumors, which may include CT, SRS and endoscopic ultrasonography, is recommended. Preoperative imaging combined with intraoperative ultrasonography should enable accurate tumor localization in more than 95% of patients, and blind pancreatic resection in the absence of tumor detection is not recommended<sup>19</sup>. Nesidioblastosis has to be considered, if invasive localization studies do not reveal a tumor in absence of MEN-1. This is a rare condition, which is treated by diazoxide or streptozotocin, or by surgery<sup>1</sup>. Laparoscopic surgery, especially for small insulinomas, located in the body and tail is feasible and safe<sup>20</sup>. Enucleation will suffice in most cases of solitary insulinoma, but the surgeon has to pay special attention to the location of the tumor in relation to the pancreatic duct. Splenic salvage with or without preservation of the splenic vessels is feasible. In case of splenectomy pneumococcal vaccination has to be given.

### Other islet cell tumors

The estimated incidence of glucagonomas is one per million of the population per year. The glucagonoma syndrome

reflects the catabolic action of excessively elevated glucagon levels. Necrolytic migratory erythema is a common presenting feature, found in 70% of all patients. Glucagonomas are occasionally part of MEN-1 and commonly occur in the tail of the pancreas. Extrapancreatic glucagonomas are extremely rare. Approximately 60–70% of glucagonomas are already metastatic at the time of diagnosis, these tumors tend to grow slowly and patients may survive for many years<sup>1,18</sup>. Glucagonomas are generally large at presentation (>5 cm diameter); visualization is usually easy. Diagnostic laparoscopy to determine the extent of spread of disease and definitive operation strategy is recommended. Cytoreductive surgery in slowly progressing tumors like glucagonomas should always be considered. Following cytoreductive surgery in the presence of (liver) metastases and palliative chemotherapy, a 5-year survival rate of 50% may be achieved<sup>21</sup>.

VIPomas are tumors which secrete VIP. The incidence is one per million of the population per year. Of these tumors 50% are already malignant at the time of diagnosis and associated with the watery diarrhea syndrome (Verner-Morrison syndrome). Due to severe symptoms, an aggressive surgical treatment is warranted. VIP-omas in the corpus or tail of the pancreas require distal pancreatectomy; pancreaticoduodenectomy should be considered for tumors in the pancreatic head<sup>1</sup>. As symptoms are often so severe, blind distal pancreatectomy may be performed in case a primary tumor cannot be found. Liver metastases should be resected if technically possible. Surgical treatment, as extensive as possible, in combination with somatostatin analogs or chemotherapy when necessary, may result in prolonged survival, even in patients with advanced disease. The 5-year survival rate is 60% for patients with metastases and 94% for patients without metastases<sup>18</sup>.

Somatostatinomas are rare tumors, large at presentation and often located in the head of the pancreas or duodenum, especially in patients with neurofibromatosis (von Recklinghausen's disease). Between 70 and 92% demonstrate metastatic spread at diagnosis. Pancreaticoduodenectomy should be performed in patients with a respectable lesion without liver metastases. The overall 5-year survival rate is 75%, or 60% when metastases are present<sup>18</sup>.

PPomas are, like somatostatinomas, large at presentation (>5 cm) and located in the head of the pancreas. The foremost clinical feature is jaundice by compression of the bile duct<sup>1</sup>. Pancreaticoduodenectomy is the surgical procedure of choice.

Non-functioning islet cell tumors are usually advanced when diagnosed and therefore large in diameter (6–10 cm). The initial clinical presentation is pain (in 36% of patients) and jaundice (in 28% of patients). The malignancy rate, based on the findings of metastatic growth outside the pancreas, perineural or vascular invasion, varies from 62 to 92%<sup>18</sup>.

SRS can be helpful in differentiating these tumors from exocrine pancreatic carcinomas. Aggressive resection is indicated, if distant metastases cannot be found. In 60% of cases, distant metastases are already encountered. Overall 5-year survival rates are estimated around 75%<sup>23,24</sup>.

## LIVER METASTASES OF NEUROENDOCRINE TUMORS

Neuroendocrine tumors behave in a protracted and predictable way, which allows for multiple therapeutic options. Even in the presence of hepatic metastases, the standard treatment is surgery, either with curative intent or for more tumor cytoreduction, i.e. resection of 90% or more of the tumor volume<sup>25</sup>. Moreover, surgical clearance of the largest lesions should be considered prior to radionuclide treatment to increase the latter's efficacy in cases of extensive metastases both intra- and extrahepatic.

Surgery for liver metastases is often impossible due to their diffuse spread, cure is only possible in 5–10%. In half of patients hepatic, resection is combined with resection

of the primary tumor and adjacent lymph nodes. Vascular interventions such as embolization, chemoembolization, or radioembolization, and other local ablative therapies like radiofrequency ablation, interstitial laser coagulation, alcohol injection, and regional hyperthermia can be used for the treatment of liver metastases. Surgical treatment appears to result in outstanding long-term survival and amelioration of symptoms. Non-surgical treatment options for liver metastases of neuroendocrine tumors include long-acting somatostatin receptor antagonists (LAR), interferon- $\alpha$ , chemotherapy, and hepatic artery embolization with and without chemotherapy<sup>26</sup>. When patients with progressive metastatic disease are unresponsive to these options for treatment, total hepatectomy can be a final solution. However, liver transplantation is only rarely feasible<sup>12</sup>. Liver transplantation for patients with symptomatic liver metastases is associated with an overall 5-year survival of 65% and a median survival of 8 years, and immediate relief from hormone-related symptoms. A promising treatment modality for patients with symptomatic liver metastases of neuroendocrine tumors is the peptide receptor radionuclide therapy with somatostatin analog<sup>1</sup>.

## REFERENCES

1. Van Lanschot J, Gouma D, Jansen P et al. Textbook of Integrated Medical and Surgical Gastroenterology. Bohn Stafleu Van Loghum 2004; 416–20.
2. Oberg K, Eriksson B. Nuclear medicine in the detection, staging and treatment of gastrointestinal carcinoid tumors. *Best Pract Res Clin Endocrinol Metab* 2005; 19: 265–7.
3. Oberg K. Neuroendocrine gastrointestinal tumors—a condensed overview of diagnosis and treatment. *Ann Oncol* 1999; 10 (Suppl 2): S3–8.
4. Chaplin M, Buscombe J, Hilson A. Carcinoid tumors. *Lancet* 1998; 352: 799–805.
5. Dimitroulopoulos D, Xynopoulos D, Tsamakidis K et al. Scintigraphic detection of carcinoid tumors with a cost effectiveness analysis. *World J Gastroenterol* 2004; 10: 3628–33.
6. Ganim R, Norton J. Recent advances in carcinoid pathogenesis, diagnosis and management. *Surg Oncol* 2000; 9: 173–9.
7. Li S, Beheshti M. The radionuclide molecular imaging and therapy of neuroendocrine tumors. *Curr Cancer Drug Targets* 2005; 5: 139–48.
8. Tomassetti P, Migliori M, Lalli S et al. Epidemiology, clinical features and diagnosis of gastroenteropancreatic endocrine tumors. *Ann Oncol* 2001; 12 (Suppl 2): S95–9.
9. Delle Fave G, Capurso G, Milione M et al. Endocrine tumors of the stomach. *Best Pract Res Clin Gastroenterol* 2005; 19: 659–73.
10. Annibale B, Azzoni C, Corleto V et al. Atrophic body gastritis with enterochromaffin-like cell dysplasia are at increased risk for the development of type I gastric carcinoid. *Eur J Gastroenterol Hepatol* 2001; 13: 1449–56.
11. Tomassetti P, Migliori M, Caletti G et al. Treatment of type II gastric carcinoid tumors with somatostatin analogues. *N Engl J Med* 2000; 343: 551–4.
12. Herder de W. Tumors of the midgut (jejunum, ileum and ascending colon, including carcinoid syndrome). *Best Pract Res Clin Gastroenterol* 2005; 19: 705–15.
13. Stinner B, Rothmund M. Neuroendocrine tumors (carcinoids) of the appendix. *Best Pract Res Clin Gastroenterol* 2005; 19: 729–38.
14. Imamura M, Komoto I, Ota S. Changing treatment strategy for gastrinoma in patients with Zollinger-Ellison syndrome. *World J Surg* 2006; 30: 1–11.
15. Pellicano R, De Angelis C, Resegotti A et al. Zollinger-Ellison syndrome in 2006: concepts from a clinical point of view. *Panminerva Med* 2006; 48: 33–40.
16. Norton J, Fraker D, Alexander H et al. Surgery to cure the Zollinger Ellison syndrome. *N Engl J Med* 1999; 341: 635–44.
17. Norton J. Surgical treatment and prognosis of gastrinoma. *Best Pract Res Clin Gastroenterol* 2005; 19: 799–805.
18. Oberg K, Eriksson B. Endocrine tumors of the pancreas. *Best Pract Res Clin Gastroenterol* 2005; 19: 753–81.
19. Tucker O, Crotty P, Conlon K. The management of insulinoma. A review. *Br J Surg* 2006; 93: 264–75.
20. Assalia A, Gagner M. Laparoscopic pancreatic surgery for islet cell tumors of the pancreas. *World J Surg* 2004; 28: 1239–47.
21. Chastain M. The glucagonoma syndrome; a review of its features and discussion of new perspectives. *Am J Med Sci* 2001; 321: 306–20.
22. Nikou GC, Toubanakis C, Nikolaou P et al. VIPomas: an update in diagnosis and management in a series of 11 patients. *Hepato-gastroenterology* 2005; 52: 1259–65.



23. Schwab M, Knoll MR, Jentschura D, Hagmuller E. Hormone inactive neuroendocrine tumors of the pancreas. *Chirurg* 1997; 68: 705–9.
24. Panzuto F, Nasoni S, Falconi M et al. Prognostic factors and survival in endocrine tumor patients: comparison between gastrointestinal and pancreatic localization. *Endocr Relat Cancer* 2005; 12: 1083–92.
25. Atwell T, Charboneau J, Que F et al. Treatment of neuroendocrine cancer metastatic to the liver: the role of ablative techniques. *Cardiovasc Intervent Radiol* 2005; 28: 409–21.
26. Norton J. Surgical treatment of neuroendocrine metastases. *Best Pract Res Clin Gastroenterol* 2005; 19: 577–83.

Andrew J Hayes and Isaac M Cranshaw

## INTRODUCTION

Soft tissue sarcomas are the most common subset of tumors that arise from the embryonic mesoderm. The term sarcoma is derived from the Greek *sarkoma* meaning 'fleshy growth' and sarcomas can occur anywhere in the body. Resectional surgery is the principal treatment modality for primary localized disease as adult soft tissue sarcomas are relatively chemo-insensitive, and radiotherapy is of value in a curative context as an adjunct to completely resected disease. The great variation in anatomical location of what is a particularly rare form of malignancy presents particular problems to the surgical oncologist managing these tumors.

## INCIDENCE/PREVALENCE/PREDISPOSING FACTORS

Soft tissue sarcomas are a rare form of cancer accounting for less than 1% of all cancers and just over 1% of cancer deaths<sup>1</sup>. There will be about 8500 new cases diagnosed each year in the USA and approximately 13 100 in the European Union. Almost half of these patients will eventually die of the disease<sup>1,2</sup>.

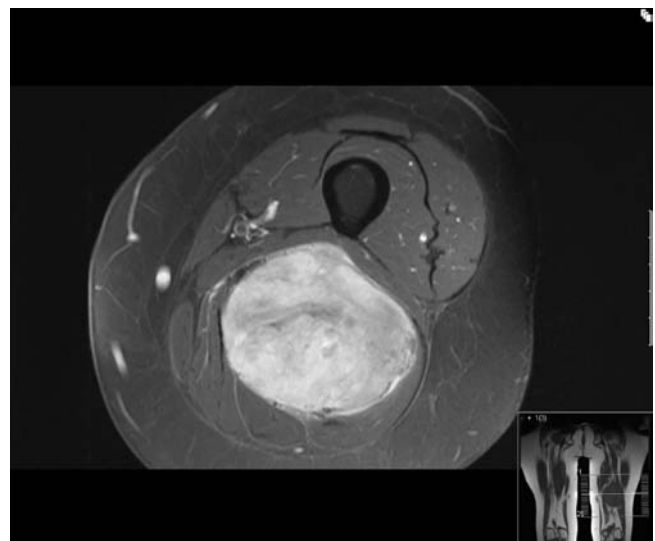
Although soft tissue sarcomas can occur anywhere in the body they most commonly originate in the limbs or limb girdle (Figure 32.1), with the trunk, retroperitoneum (Figure 32.2) and the head and neck the next most common sites<sup>1,3</sup> (Table 32.1). Soft tissue sarcomas do not arise from malignant change in benign soft tissue lesions, which are hundreds of times more common, other than in a few rare circumstances (e.g. sarcomatous change in a plexiform neurofibroma in patients with Neurofibromatosis Type 1).

Most soft tissue sarcomas are sporadic, arising in the absence of any identifiable cause but there are a few well described risk factors. Exposure to radiation, especially external beam radiotherapy, is a well recognized risk factor for soft tissue sarcoma. The incidence of soft tissue sarcoma increases up to 50 times in patients treated with

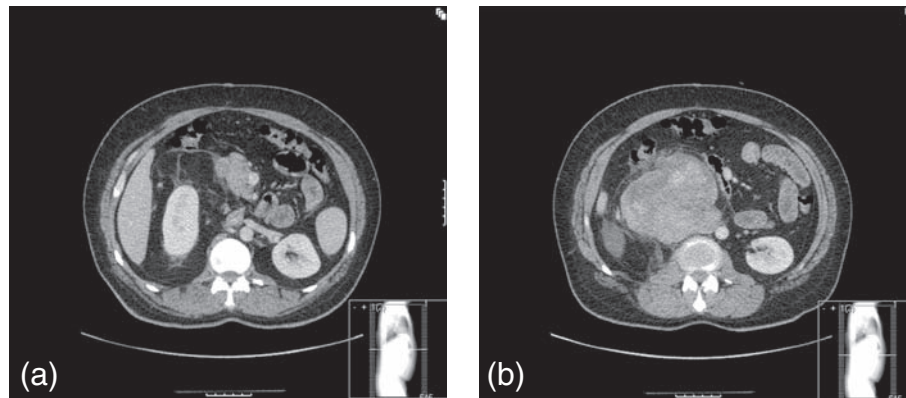
radiation therapy for other cancers<sup>4,5</sup>. Postirradiation-induced sarcomas occur after a latency period of between 3 and 15 years, and they are predominantly high grade tumors with a poor prognosis<sup>4</sup>.

Kaposi's sarcoma is 310 times more common in patients with AIDS and angiosarcoma is 17 times more common in this subpopulation<sup>6</sup>. In addition, AIDS patients who have concurrent Epstein-Barr virus (EBV) infection have an increased incidence of leiomyosarcoma<sup>7</sup>.

Other reported environmental risk factors include occupational exposure to certain industrial chemicals such as polyvinyl chloride, phenoxyacetic acid herbicides and chlorophenol wood preservatives<sup>8,9</sup>. Contamination of these various chemicals with dioxins, particularly 2, 3, 7, 8-tetrachlorodibenzo-*para*-dioxin, has been implicated in the development of soft tissue sarcoma. However the evidence for a strong causal relationship with dioxins is weak, in part because even in large prospective cohort studies of workers exposed to dioxins the number of



**Figure 32.1** Grade 2 myxofibrosarcoma arising from the right gluteus maximus.



**Figure 32.2** Two computed tomography scans of a retroperitoneal liposarcoma. (a) Abnormal fat surrounding the right kidney. (b) Dedifferentiated component compressing the inferior vena cava and with colon overlying it.

**Table 32.1** Anatomical distribution of soft tissue sarcomas

Site	Incidence (%)
Lower limb and girdle	40
Upper limb and girdle	20
Retroperitoneum	15
Trunk	10
Head and neck	10
Other	5

Adapted from references 1 and 3.

cases of soft tissue sarcoma, though increased is still small rendering statistical confirmation of a causal link difficult<sup>10</sup>.

Chronic lymphedema of the limb is a risk factor for developing lymphangiosarcoma in the affected limb, having originally been described following radical mastectomy for carcinoma of the breast (Stewart-Treves syndrome)<sup>11</sup>. Inherited susceptibility to development of soft tissue sarcomas occurs in patients with neurofibromatosis and patients with germline mutations of the retinoblastoma (Rb) gene and the p53 gene (Li Fraumeni syndrome). Patients with type 1 neurofibromatosis have a ten times increased rate of development of malignant peripheral nerve sheath tumors<sup>12</sup>. Mutations of the Rb gene are associated with development of both retinoblastoma and soft tissue sarcomas in these patients<sup>13</sup>. Patients with Li Fraumeni syndrome have increased rates of soft tissue sarcomas and have a greatly elevated sensitivity to the development of soft tissue sarcoma after radiation exposure<sup>14</sup>.

## PATHOLOGY

There is a huge variability in histopathological subtypes of soft tissue sarcoma. A detailed discussion of the histopathology of soft tissue sarcoma is beyond the scope of this chapter and is well described elsewhere<sup>15</sup>. However, a discussion of certain issues of histopathology relating to management is appropriate. Generally classification of soft tissue sarcoma is centered upon particular cellular lineages on the basis of morphology and immunohistochemical profiles. However, in a substantial number of cases no such cellular lineage is apparent and classification relies on morphological criteria (pleomorphic sarcoma)<sup>16,17</sup>. In the majority of cases knowledge of the histopathological subtype has less bearing on clinical management than knowledge of the grade of tumor or its anatomical relations. These two factors influence both the nature of surgery and the need for adjuvant radiotherapy. However, there are certain histological subtypes of soft tissue sarcoma that have distinct biological behaviors that influence management, the most important example being tumors displaying intrinsic chemosensitivity. Ewing's sarcoma and pediatric embryonal rhabdomyosarcoma are exquisitely chemosensitive, and synovial sarcoma which usually presents in young adults is relatively chemosensitive. For these subtypes induction chemotherapy prior to surgery is often indicated.

Grading of soft tissue sarcoma into low, intermediate and high grade tumors is most commonly according to the Trojani system (French Federation of Cancer Centers Sarcoma Group) taking into account mitotic rate, extent of necrosis and cellular differentiation<sup>18</sup>. Other more complex grading systems exist but offer little extra advantage in predicting survival and likely response to therapy<sup>19</sup>. Grade can usually be accurately determined preoperatively by core biopsy<sup>20</sup>.

## STAGING

The staging system in most common use is the American Joint Committee on Cancer (AJCC)/International Union Against Cancer (IUCC)<sup>21</sup> and is summarized in Table 32.2.

In contrast to TNM staging for other cancer subtypes this system includes grade as an important prognostic indicator. Tumor grade is based upon degree of differentiation, mitotic count and presence/extent of necrosis, and has been shown to be of similar prognostic importance to tumor size for soft tissue sarcoma<sup>22,23</sup>.

Five-year survival rates by stage are stage I 86%, stage II 72%, stage III 52%, and stage IV 10%. The utility of

the AJCC/UICC staging system is particularly accurate for limb, limb girdle and trunk sarcomas but is not particularly useful for retroperitoneal tumors or head and neck sarcomas. Specific anatomical considerations at these sites which prevent radical resection may be of greater importance than the biological characteristic of the tumor, and account for the considerably poorer overall prognosis for patients with sarcomas at these sites.

For retroperitoneal sarcoma grade and the ability to gain a complete resection of macroscopic disease is the most important determinants of survival with the size of the tumors appears to have much less prognostic relevance<sup>24,25</sup>. Completely resected retroperitoneal tumors have 5-year survival rates of 89% (low grade) and 40% (high grade) compared with only 26% for incompletely resected tumors<sup>27</sup>.

**Table 32.2** The grade, tumor, node, metastasis system of the American Joint Committee on Cancer for soft tissue sarcoma and the International Union Against Cancer

### *Tumor (T)*

T1	<5 cm largest dimension
T1a	Superficial to deep fascia
T1b	Deep to deep fascia*
T2	>5 cm largest dimension
T2a	Superficial to deep fascia
T2b	Deep to deep fascia*

### *Nodes (N)*

N1	Regional node metastases
----	--------------------------

### *Metastasis (M)*

M1	Distant metastases
----	--------------------

### *Grade (G)*

G1	Well differentiated
G2	Moderately differentiated
G3	Poorly differentiated
G4	Undifferentiated

### *Stage (S)*

I	G1 or G2	T1a, T1b or T2a	5-year survival 86%
II	G1 or G2	T2b	
	G3 or G4	T1a, T2b or T2a	5-year survival 72%
III	G3 or G4	T2b	5-year survival 52%
IV	Any G	Any T	
		N1 or M1	5-year survival 10%

\*Includes retroperitoneal and intrathoracic tumors.  
Data from reference 21.

## PRESENTATION

Soft tissue sarcomas usually present with a painless, enlarging mass. The size of the tumor at presentation is related to its site. Superficial sarcomas of the distal extremities are more likely to be noticed at a smaller size, whereas sarcomas in deep locations in the thigh or retroperitoneum may only present once they have become very large.

Soft tissue sarcomas are often asymptomatic but as they grow they can occasionally exert pressure effects on adjacent structures. Retroperitoneal tumors often grow to a very large size prior to diagnosis and these patients may present with associated weight loss, low grade intestinal or gastric outlet obstruction, and urinary symptoms. Low grade tumors can present asymptotically as an incidental finding as part of abdominal computed tomography (CT) scanning for another indication. Because of the relative rarity of soft tissue sarcoma it is not uncommon for there to be a delay between presentation and diagnosis. Significant delays in referral affect as many as 20% of cases seen in tertiary sarcoma units<sup>28</sup>. These patients often wait more than a year from initial presentation until the diagnosis is made.

The clinical and radiological differential diagnosis of a soft tissue sarcoma includes deep-seated benign lesions (e.g. intramuscular lipomas, myxomas and arteriovenous malformations, and a variety of fibroblastic conditions such as fibromatosis or nodular fasciitis). The other principal differential diagnoses are other malignant lesions, such as metastatic carcinoma, cutaneous lymphoma and melanoma. Treatment of these other conditions may be quite different to that of a sarcoma, emphasizing the importance of pre-operative histological diagnosis in guiding subsequent management.

## DIAGNOSTIC STRATEGIES

Diagnostic investigation for soft tissue sarcoma has three aims: first, to accurately define the pathology prior to treatment; second, to define the anatomical relations of the primary tumor for surgical (or radiotherapy) planning; and, third, to identify the presence or absence of metastatic disease. The presence of metastases usually renders primary surgical resection inappropriate.

The diagnosis of soft tissue sarcoma, other than in exceptional circumstances is dependent upon preoperative biopsy, usually in the form of needle core biopsy to provide an adequate sample for specialist histopathological review. While imaging by CT or magnetic resonance (MR) scanning is supportive of a diagnosis, on its own any imaging modality is usually insufficiently accurate for preoperative diagnosis and should not be used to define subsequent treatment.

### Diagnostic imaging for primary disease

Much of the literature citing the superiority of MRI over CT scanning in imaging soft tissue lesions is centered around the diagnostic superiority of MRI over CT scanning<sup>29–31</sup>. However, in terms of surgical/radiotherapy planning and in the identification of metastatic disease, modern CT scanning is equally as useful as MRI and has the advantage that imaging of the thorax for metastatic disease is easily performed at the same time. In fact, CT is the most commonly utilized technique. Contrast enhanced CT is the most useful technique for assessing retroperitoneal sarcoma as it is superior to other modalities in delineating the extent of tumor extension and relationships to adjacent intra-abdominal viscera and important vascular structures. CT can also be used successfully in the trunk, head and neck, and extremities where it is able to give accurate information regarding

tumor size, location and association to adjacent vital structures.

MRI has become the preferred modality for assessment of soft tissue sarcoma in the limbs, partly for the reasons cited above about diagnostic superiority (Figure 32.3). However, it also has certain advantages over CT in delineating muscle groups and separating tumor from adjacent vascular, muscular and bony structures<sup>29,30</sup>.

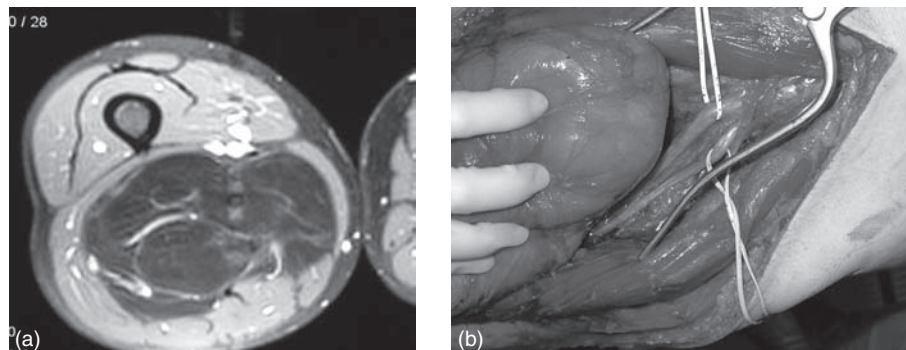
At primary presentation preoperative staging for distant disease is most commonly achieved by CT scanning of the thorax, as distant disease at other sites in the absence of pulmonary disease is very rare. There is no indication for positron emission tomography (PET) scanning in primary sarcoma.

### Preoperative biopsy

The principal reasons for securing a preoperative tissue diagnosis in suspected soft tissue sarcoma are to distinguish these tumors from benign soft tissue tumors or metastatic carcinoma, and also to identify chemosensitive tumors such as primitive neuroectodermal tumours/Ewing's sarcomas, or lymphoma.

Percutaneous core biopsy is the best technique for achieving a safe and accurate diagnosis and can be easily performed in the outpatient clinic under clinical guidance. In differentiating between benign and malignant soft tissue tumors, core biopsy had been shown to have a sensitivity and specificity of 99% and this result is comparable between biopsies taken at tertiary units and at referring units<sup>20</sup>. In addition, core biopsy identifies the correct grade in 85–88% and the correct subtype in 75–80% of cases<sup>20,32</sup>. Biopsy material should be reviewed by a pathologist specializing in soft tissue tumors<sup>33</sup>.

Biopsy should be performed at a tertiary center where it can be examined by a specialist pathologist. Additionally, the biopsy site can be chosen by the surgeon



**Figure 32.3** Magnetic resonance image of chondrosarcoma arising from rectus femoris. Note the close proximity to the superficial femoral vessels.

so that it can be excised along with the resection specimen. The accuracy and simplicity of core biopsy means that the formerly common procedure of incisional biopsy is rarely indicated. While incisional biopsy is as accurate as core biopsy in gaining a pathological diagnosis it requires an operation (especially for deep lesions). Concerns about scar placement and dissemination due to postincision biopsy hematoma have also been raised. Fine needle aspiration has virtually no role in providing a pathological diagnosis for primary soft tissue sarcoma. Core biopsy is greatly superior in terms of sensitivity and specificity and has the advantage of being able to identify the grade and histological subtype<sup>20</sup>. Fine needle aspiration is useful in for identifying metastatic spread in enlarged regional lymph nodes. In this situation identification of malignant spindle cells is adequate if the pathology of the primary lesion is already established.

## SURGERY FOR CURE

Surgical resection is by far the most effective treatment modality available for the vast majority of soft tissue sarcomas. Primary (as opposed to neoadjuvant) radiotherapy has limited response rates and is unlikely to result in long-term local control. The aim of surgery with curative intent is to widely excise the primary tumor ensuring negative histopathological margins. However, given the huge variety of anatomical locations of primary tumors, and the very different biological behaviors of sarcomas, putting that standard surgical dogma into clinical practice is much more complex than in other malignancies that present in a more uniform fashion.

Previous attempts to classify the types of resection for extremity sarcomas into radical, wide, marginal, and intracapsular are of only limited value but, as these terms are so commonly employed they merit discussion<sup>34</sup>. These different types of operation have traditionally been associated with widely differing rates of local recurrence rates, and certainly for high grade tumors this is the case. With intermediate and high grade tumors the macroscopic appearance of encapsulation is not reflected microscopically where this 'pseudocapsule' is invariably associated with microscopic infiltration of the surrounding tissues by malignant cells. Therefore, an excision of a high grade sarcoma on the surface of the tumor (marginal) or worse as an intracapsular enucleation (or shell out procedure) is a grave clinical error which can compromise local control or cure. The usual clinical scenario is that such operations are performed inadvertently on the assumption that the tumor is benign because no preoperative imaging or biopsy has been performed.

While for low grade tumors a preoperative biopsy and imaging is still vital, the distinction between radical excisions and marginal excisions is of less importance. Many low grade tumors (particularly well differentiated liposarcomas) can present as large masses where radical resections would either not be feasible or be associated with substantial morbidity. Because the biology of these tumors is dissimilar to high grade sarcomas it is often entirely appropriate for a planned marginal resection which can achieve long-term control because infiltration into surrounding tissues is less common (Figure 32.3). However, if it is possible to widely excise the tumor with acceptable morbidity then this should be the operation of choice for low grade tumors.

For high grade tumors radical resection with negative histopathological margins is paramount. Historically radical operations for extremity sarcomas involved either formal compartmentectomy or amputation at a level where the whole involved compartment was resected (e.g. forequarter amputation or hindquarter amputation). However, randomized studies comparing this approach with limb sparing/functional operations coupled with adjuvant radiotherapy demonstrated equivalence in survival and therefore primary amputation for sarcoma is a rare event in modern practice<sup>35–37</sup>. Isolated limb perfusion as induction chemotherapy prior to marginal resections of large tumors is also a valuable approach circumventing the need for amputation<sup>38</sup>.

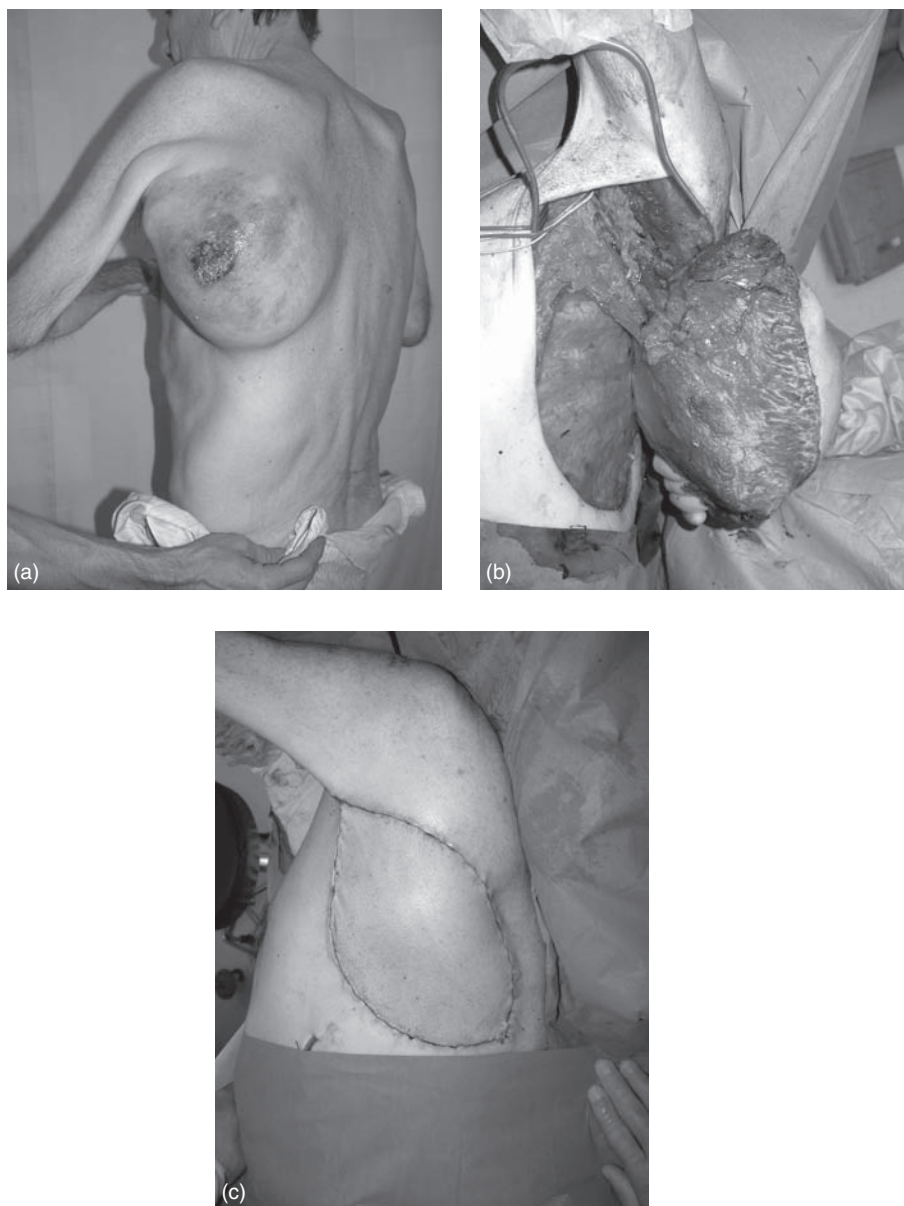
There is little oncological value in resecting uninvolved muscles within a compartment, and considerable functional benefit in preserving them along with their innervation. Furthermore, crucial neurovascular structures even when closely apposed to tumors can be preserved as part of a planned definitive resection and local recurrence rates appear to be acceptable<sup>39,40</sup>. In contrast, unplanned positive margins resulting from a partial resection of a muscle close to the tumor will inevitably result in local recurrence despite radiotherapy. Good quality preoperative imaging is crucial in this sort of planning, enabling a clear operative strategy defining those anatomical structures to be resected and those to be preserved. Surgical resections should be at the level of defined anatomical structures, such as a major neurovascular bundles, with all tissue up to that structure being resected en bloc with the tumor.

Reconstructive surgery has an important role to play in the management of soft tissue sarcoma, although data from our own institute suggest that reconstruction of any form is required in only 10–15% of all patients. This is usually because soft tissue sarcomas arise deep to the deep fascia and so primary skin closure can be achieved by raising skin flaps above the deep fascia, while still ensuring adequate oncological clearance. However, when plastic

surgical reconstruction is required, for particularly large or fungating tumors (Figure 32.4), the reconstructive considerations are complex and require the input of a reconstructive surgeon at the time of surgical planning. Simple skin grafting is usually inappropriate, because this method of reconstruction will not easily tolerate postoperative adjuvant radiotherapy, and is insufficient for large deficits with exposed deep neurovascular structures or bone. Consequently, pedicled or free myocutaneous tissue transfer is often required. Reconstruction of the abdominal wall and diaphragm can be achieved relatively simply using prolene mesh. Reconstruction of the chest wall may be more complex and require the input of a specialist thoracic surgeon.

### Surgery for retroperitoneal sarcoma

While the pathology of sarcomas in the retroperitoneum may be similar to those in the extremities, anatomical considerations are such that management will often differ to that of extremity sarcomas, and merits separate discussion. The indication for biopsy of tumors in the retroperitoneum is essentially similar to that in the limbs, that is the confirmation of malignancy, and in particular the identification of chemosensitive disease such that surgery may be deferred until after chemotherapy or avoided entirely. In the retroperitoneum the relevant differential diagnoses include male germ cell tumors, lymphoma and gastro intestinal stromal tumors. However, biopsy is not



**Figure 32.4** Reconstruction of a large defect in the chest wall with a latissimus dorsi myocutaneous flap.



mandatory for retroperitoneal sarcoma, particularly as retroperitoneal liposarcoma, the commonest retroperitoneal sarcoma may have appearances on CT that are pathognomonic (Figure 32.5).

Because retroperitoneal tumors are usually intimately related to irresectable structures (inferior vena cava or aorta), a resection can never be radical and is usually marginal. Consequently the nature of surgery is rarely altered by biopsy, once it has been defined that surgery is the primary treatment. However, it cannot be emphasized strongly enough that the aim of surgery in the retroperitoneum for any retroperitoneal sarcoma is complete resection of all macroscopic disease as major series have indicated that the ability to gain complete macroscopic clearance and grade of tumor are the two principle independent prognostic factors determining outcome<sup>24,25</sup>. Multiple visceral resections are commonly required in order to gain complete macroscopic clearance, although it is rarely the case that these viscera are involved by tumor<sup>25</sup>, rather that resection is necessary in order to remove all macroscopic disease. Even when complete macroscopic clearance is achieved, local recurrence within the abdomen is common and multiple palliative operations may be required<sup>24</sup>. For retroperitoneal sarcomas death usually results from intrabdominal recurrence rather than metastatic spread which is an infrequent event<sup>25</sup>. Because of the very large size of these tumors, radical postoperative radiotherapy is rarely feasible in the retroperitoneum, and radiotherapy is usually reserved for the palliation of irresectable local recurrence.

## ADJUVANT THERAPIES

### Adjuvant radiotherapy

Radiotherapy has an established role as an adjuvant therapy for soft tissue sarcomas of the limb, limb girdles

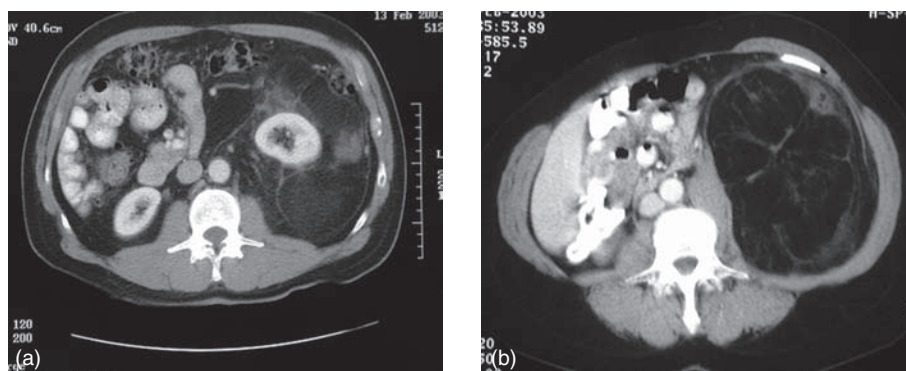
and trunk. The standard indication for radiotherapy is for completely excised intermediate or high grade tumors. Small tumors (<5 cm), regardless of grade and excised with a considerable surgical margin in all planes, may avoid radiotherapy with little effect on local recurrence<sup>22,23,35</sup>. In practice, however, the majority of soft tissue sarcomas present at a late stage, as large tumors and are therefore referred for adjuvant radiotherapy.

The usual strategy for microscopically involved margins is to attempt a further surgical resection for clearance. However, if it is the case that a definitive oncological resection has been performed up to a crucial anatomical structure and there is a positive margin at that point then further surgical resection is inappropriate and adjuvant radiotherapy can give adequate local control rates<sup>39-41</sup>.

For adjuvant radiotherapy for soft tissue tumors in other sites, such as head and neck and retroperitoneum, there is little evidence to support an effect on local control rates<sup>41</sup>. Radiotherapy is usually administered as external beam therapy due to the ease of delivery and high level of availability of the technique. Brachytherapy has also been used both alone and in combination with external beam therapy and offers some advantages in terms of dose delivery. There is no evidence of an advantage of either technique in terms of local control with results suggesting that the two techniques are equally efficacious<sup>41</sup>. The added benefit of radiotherapy in absolute terms is probably very small in cases of low grade soft tissue sarcoma where the risk of local recurrence is very small. However, in recurrent low grade tumors radiotherapy is a useful adjunct to wide resection in minimizing further episodes of recurrence. Adjuvant radiotherapy has no effect on rates of metastatic disease-free survival or overall survival in patients with soft tissue sarcoma<sup>41</sup>.

### Neoadjuvant radiotherapy

Classically radiotherapy has been administered postoperatively for soft tissue sarcomas but neoadjuvant



**Figure 32.5** Classical appearance of a large retroperitoneal liposarcoma surrounding the left kidney (which will have to be resected), and pushing all other intra-abdominal organs towards the right.



(preoperative) radiotherapy has also been shown to be effective<sup>42–45</sup>. Preoperative radiotherapy may induce tumor shrinkage, improving resectability, and the dose required may be less than that for the postoperative option. However, preoperative radiotherapy is associated with higher wound complication rates<sup>43,45</sup> and may hamper accurate histopathological assessment of the specimen due to tissue destruction. Rates of local control and progression-free survival are similar for both preoperative and postoperative radiation therapy<sup>45</sup>.

### Adjuvant chemotherapy

Assessing the benefit of adjuvant chemotherapy in soft tissue sarcomas has been hampered by the rarity of the condition. There have been many small studies which have failed to show an advantage and adjuvant treatment has generally been limited to the confines of clinical trials. A meta-analysis of 1568 patients treated with adjuvant doxorubicin-based chemotherapy failed to show a significant effect on overall survival<sup>46</sup>. The lack of a survival benefit combined with the significant toxicity of newer combination modalities mean that adjuvant chemotherapy for patients with soft tissue sarcoma still has little place outside clinical trials. Indeed the control arm for these trials remains ‘no therapy’<sup>47</sup>.

### Neoadjuvant chemotherapy

Preoperative chemotherapy holds some theoretical advantages for patients with large high grade tumors. Response to chemotherapy may improve resectability in some cases and eliminate microscopic disease earlier. Favorable local control rates have been achieved with neoadjuvant chemotherapy combined with radiotherapy<sup>48,49</sup>, however, complete pathological response rates only occur in 14%<sup>50</sup>. Improved resectability only occurs in one-tenth of patients and is offset by a similar proportion progressing during treatment and requiring more extensive surgery. There is no evidence that overall survival is improved but in those with a complete response both local control and survival are probably better<sup>50</sup>. In the subset of patients with large (>10 cm), high grade extremity sarcomas neoadjuvant chemotherapy has been shown to improve disease-specific survival in the short to medium term<sup>51</sup>.

### Isolated limb perfusion

Isolated limb perfusion is an operative technique for delivering high dose regional chemotherapy to a limb affected by malignancy. Isolation is achieved by cannulating the feeding artery and vein, applying a tourniquet,

and perfusing the limb on an extra-corporeal bypass circuit with high dose chemotherapy and then washing the limb out prior to decannulation. Continuous leakage monitoring ensures inadvertent leakage into the systemic circulation is prevented. Cytotoxic chemotherapy alone has relatively little efficacy in soft tissue sarcoma but when used in conjunction with the cytokine tumour necrosis factor- $\alpha$  response rates are increased<sup>52</sup>. Multicenter non-randomized series report limb salvage rates of 80% for soft tissue sarcoma deemed to be irresectable other than by amputation<sup>38</sup>. In these series the perfusion usually serves as induction chemotherapy prior to a marginal resection. Response rates for isolated limb perfusion alone without subsequent surgery are less encouraging<sup>53</sup>. No direct comparisons exist between isolated limb perfusion used as induction chemotherapy prior to surgical resection and more standard approaches of surgery and adjuvant pre- or postoperative radiotherapy.

### Pulmonary metastasectomy

Because the pattern of metastatic spread in sarcoma is usually limited to the lungs, resection of pulmonary metastases is viewed as a worthwhile treatment for both palliation of symptomatic pulmonary disease and improving long-term survival or even cure. While the absolute numbers of patients who gain survival benefit is probably small, major series have shown small numbers of long-term survivors in what is viewed as a fatal condition if untreated<sup>54</sup>. Randomized evidence for the benefit of pulmonary metastasectomy does not exist and given the perceived benefit of the procedure over palliative chemotherapy, it is unlikely that such trials will ever be undertaken. The accepted prognostic factors for benefit of metastasectomy are a long disease-free interval between treatment of the primary tumor and development of metastases and a small number of pulmonary metastases.

## PALLIATIVE THERAPIES

Soft tissue sarcoma often present as large high grade primary tumors and the development of incurable metastatic disease is common usually within the first 2 years after primary treatment. Surgery, radiotherapy and chemotherapy may all have roles to play in the palliative care setting but the early involvement of a palliative care physician is an important aspect of management of advanced disease, and current guidelines on improving outcomes for sarcoma advise that palliative care physicians are integral members of the core multidisciplinary team in any designated sarcoma treatment center<sup>55</sup>.

As there is little evidence that chemotherapy is useful as an adjuvant therapy<sup>46,47</sup>, in soft tissue sarcoma it has usually been confined to the palliative setting. Soft tissue sarcomas are not a particularly chemosensitive group of tumors and response rates for those with metastatic disease are well below 30% for most agents. There is good evidence for response rates in this range for both doxorubicin<sup>56</sup> and ifosfamide<sup>57</sup>, which are the most commonly used single agents<sup>58</sup>.

It is possible to combine doxorubicin and ifosfamide to achieve response rates above 40% depending on the regimen, but at the cost of severe toxicity<sup>58,59</sup>. Indeed the toxicity profiles of all these agents mean that patients have to be treated in an inpatient setting<sup>58</sup>. It is important to remember that palliative chemotherapy probably adds no more than 6–10 months to the overall survival of these patients.

## REFERENCES

- Cormier JN, Pollock RE. Soft tissue sarcomas. *CA Cancer J Clin* 2004; 54: 94–109.
- Weitz J, Antonescu CR, Brennan MF. Localized extremity soft tissue sarcoma: improved knowledge with unchanged survival over time. *J Clin Oncol* 2003; 21: 2719–25.
- Clark MA, Fisher C, Judson I et al. Soft-tissue sarcomas in adults. *N Engl J Med* 2005; 353: 701–11.
- Brady MS, Gaynor JJ, Brennan MF. Radiation-associated sarcoma of bone and soft tissue. *Arch Surg* 1992; 127: 1379–85.
- Zahm SH, Fraumeni JF Jr. The epidemiology of soft tissue sarcoma. *Semin Oncol* 1997; 24: 504–14.
- Goedert JJ, Cote TR, Virgo P et al. Spectrum of AIDS-associated malignant disorders. *Lancet* 1998; 351: 1833–9.
- McClain KL, Leach CT, Jenson HB et al. Association of Epstein-Barr virus with leiomyosarcomas in children with AIDS. *N Engl J Med* 1995; 332: 12–8.
- Keilhorn J, Melber C, Wahnschaffe U et al. Vinyl chloride: still a cause for concern. *Environ Health Perspect* 2000; 108: 579–88.
- Dich J, Zahm SH, Hanberg A et al. Pesticides and cancer. *Cancer Causes Control* 1997; 8: 420–43.
- Smith AH, Pearce NE, Fisher DO et al. Cancer mortality in workers exposed to phenoxy herbicides, chlorophenols, and dioxins. An expanded and updated international cohort study. *Am J Epidemiol* 1997; 145: 1061–75.
- Stewart FW, Treves N. Lymphangiosarcoma in postmastectomy lymphedema: a report of six cases in elephantiasis chirurgica. *Cancer* 1948; 1: 64–81.
- Theos A, Korf BR. Pathophysiology of neurofibromatosis type 1. *Ann Intern Med* 2006; 144: 842–9.
- Wong FL, Boice JD Jr, Abramson DH et al. Cancer incidence after retinoblastoma. Radiation dose and sarcoma risk. *JAMA* 1997; 278: 1262–7.
- Strong LC, Williams WR, Tainsky MA et al. The Li-Fraumeni syndrome: from clinical epidemiology to molecular genetics. *Am J Epidemiol* 1992; 135: 190–9.
- Weiss SW, Goldblum JR. *Enzinger and Weiss's Soft Tissue Tumours*, 4th edn. Mosby, St. Louis, Missouri USA, 2001.
- Fletcher CD. The evolving classification of soft tissue tumours: an update based on the new WHO classification. *Histopathology* 2006; 48: 3–12.
- Fisher C. Myofibroblastic malignancies. *Adv Anat Pathol* 2004; 11: 190–201.
- Coindre JM, Nguyen BB, Bonichon F et al. Histopathologic grading in spindle cell soft tissue sarcomas. *Cancer* 1988; 61: 2305–9.
- Guillou L, Coindre JM, Bonichon F et al. Comparative study of the National Cancer Institute and French Federation of Cancer Centers Sarcoma Group grading systems in a population of 410 adult patients with soft tissue sarcoma. *J Clin Oncol* 1997; 15: 350–62.
- Hoerber I, Spillane AJ, Fisher C et al. Accuracy of biopsy techniques for limb and limb girdle soft tissue tumors. *Ann Surg Oncol* 2001; 8: 80–7.
- Greene FL, Page DL, Fleming ID et al. *AJCC Cancer Staging Manual*, 6th edn. New York: Springer Verlag, 2002.
- Ramanathan RC, A'Hern R, Fisher C et al. Modified staging system for extremity soft tissue sarcomas. *Ann Surg Oncol* 1999; 6: 57–9.
- Pisters PW, Leung DH, Woodruff J et al. Analysis of prognostic factors in 1041 patients with localized soft tissue sarcoma of the extremities. *J Clin Oncol* 1996; 14: 1679–89.
- Lewis JJ, Leung D, Woodruff JM et al. Retroperitoneal soft-tissue sarcoma: analysis of 500 patients treated and followed at a single institution. *Ann Surg* 1998; 228: 355–65.
- Neuhaus SJ, Barry P, Clark MA. Surgical management of primary and recurrent retroperitoneal liposarcoma. *Br J Surg* 2005; 92: 246–52.
- Singer S, Antonescu CR, Reidel E. Histologic subtype and margin of resection predict pattern of recurrence and survival for retroperitoneal liposarcoma. *Ann Surg* 2003; 238: 358–70.
- Van Dalen T, Hennipman P, Van Coevorden F et al. Evaluation of a clinically applicable post-surgical classification system for primary retroperitoneal soft-tissue sarcoma. *Ann Surg Oncol* 2004; 11: 483–90.
- Clark MA, Thomas JM. Delay in referral to a specialist soft-tissue sarcoma unit. *Eur J Surg Oncol* 2005; 31: 443–8.
- Hanna SL, Fletcher BD. MR imaging of malignant soft-tissue tumors. *Magn Reson Imaging Clin N Am* 1995; 3: 629–50.
- Demas BE, Heelan RT, Lane J et al. Soft-tissue sarcomas of the extremities: comparison of MR and CT in determining the extent of disease. *AJR Am J Roentgenol* 1988; 150: 615–20.
- Fenstermacher MJ. Imaging evaluation of patients with soft tissue sarcoma. *Surg Oncol Clin N Am* 2003; 12: 305–32.
- Heslin MJ, Lewis JJ, Woodruff JM et al. Core needle biopsy for diagnosis of extremity soft tissue sarcoma. *Ann Surg Oncol* 1997; 4: 425–31.
- Alvegard TA, Berg NO. Histopathology peer review of high-grade soft tissue sarcoma: the Scandinavian Sarcoma Group experience. *J Clin Oncol* 1989; 7: 1845–51.

34. Enneking WF, Spanier SS, Goodman MA. A system for the surgical staging of musculoskeletal sarcoma. *Clin Orthop Relat Res* 2003; 415: 4–18.
35. Coindre JM, Terrier P, Bui NB. Prognostic factors in adult patients with locally controlled soft tissue sarcoma. A study of 546 patients from the French Federation of Cancer Centers Sarcoma Group. *J Clin Oncol* 1996; 14: 869–77.
36. Rosenberg SA, Tepper J, Glatstein E et al. The treatment of soft-tissue sarcomas of the extremities: prospective randomized evaluations of (1) limb-sparing surgery plus radiation therapy compared with amputation and (2) the role of adjuvant chemotherapy. *Ann Surg* 1982; 196: 305–15.
37. Pisters PW, Harrison LB, Leung DH et al. Long-term results of a prospective randomized trial of adjuvant brachytherapy in soft tissue sarcoma. *J Clin Oncol* 1996; 14: 859–68.
38. Eggermont AM, Schraffordt Koops H, Klausner JM et al. Isolated limb perfusion with tumor necrosis factor and melphalan for limb salvage in 186 patients with locally advanced soft tissue extremity sarcomas. The cumulative multicenter European experience. *Ann Surg* 1996; 224: 756–64.
39. Gerand CH, Wunder JS, Kandel RA et al. Classification of positive margins after resection of soft-tissue sarcoma of the limb predicts the risk of local recurrence. *J Bone Joint Surg Br* 2001; 83: 1149–55.
40. Stojadinovic A, Leung DH, Hoos A et al. Analysis of the prognostic significance of microscopic margins in 2,084 localized primary adult soft tissue sarcomas. *Ann Surg* 2002; 235: 424–34.
41. Strander H, Turesson I, Cavallin Stahl E et al. A systematic overview of radiation therapy effects in soft tissue sarcomas. *Acta Oncol* 2003; 42: 516–31.
42. Suit HD, Mankin HJ, Wood WC et al. Preoperative, intraoperative and postoperative radiation in the treatment of primary soft tissue sarcoma. *Cancer* 1985; 55: 2659–67.
43. Cheng EY, Dusenbery KE, Winters MR. Soft tissue sarcomas. Preoperative versus postoperative radiotherapy. *J Surg Oncol* 1996; 61: 90–9.
44. Robinson MH, Keus RB, Shasha D et al. Is pre-operative radiotherapy superior to postoperative radiotherapy in the treatment of soft tissue sarcoma? *Eur J Cancer* 1998; 34: 1309–16.
45. O'Sullivan B, Davis AM, Turcotte R et al. Preoperative versus postoperative radiotherapy in soft-tissue sarcoma of the limbs: a randomized trial. *Lancet* 2002; 359: 2235–41.
46. Tierney JF. Adjuvant chemotherapy for localized resectable soft-tissue sarcoma of adults: meta-analysis of individual data. *Sarcoma Meta-analysis Collaboration. Lancet* 1999; 350: 1647–54.
47. Bramwell VH. Adjuvant chemotherapy for adult soft tissue sarcoma: Is there a standard of care? *J Clin Oncol* 2001; 19: 1235–7.
48. Pisters PW, Ballo MT, Patel SR. Preoperative chemoradiation treatment strategies for localized sarcoma. *Ann Surg Oncol* 2002; 9: 535–42.
49. Frustaci S, Gherlizoni F, De Paoli A et al. Adjuvant chemotherapy for adult soft tissue sarcomas of the extremities and girdles: results of the Italian randomized cooperative trial. *J Clin Oncol* 2001; 19: 1238–47.
50. Meric F, Hess KR, Varma DG et al. Radiographic response to neoadjuvant chemotherapy is a predictor of local control and survival in soft tissue sarcomas. *Cancer* 2002; 95: 1120–6.
51. Grobmyer SR, Maki RG, Demetri DG et al. Neo-adjuvant chemotherapy for primary high-grade extremity soft tissue sarcoma. *Ann Oncol* 2004; 15: 1667–72.
52. Eggermont AM, de Wilt JH, ten Hagen TL et al. Current uses of isolated limb perfusion in the clinic and a model system for new strategies. *Lancet Oncol* 2003; 4: 429–37.
53. Hayes AJ, Neuhaus SJ, Clark MA et al. Isolated limb perfusion with melphalan and tumour necrosis factor alpha for advanced melanoma and soft tissue sarcoma. *Ann Surg Oncol* 2007; 14: 230–8.
54. Gadd MA, Caspers MS, Woodruff AM et al. Development and treatment of pulmonary metastases in adult patients with extremity soft tissue sarcoma. *Ann Surg* 1993; 218: 705–12.
55. National Collaborating Centre for Cancer. NICE guidelines for improving outcomes for people with sarcoma. National Institute for Health and Clinical Excellence. [www.nice.org.uk/page.aspx?o=csgsarcomaguidance](http://www.nice.org.uk/page.aspx?o=csgsarcomaguidance), accessed Oct 2006.
56. O'Bryan RM, Luce JK, Talley RW et al. Phase II evaluation of adriamycin in human neoplasia. *Cancer* 1973; 32: 1–8.
57. Bramwell VH, Mouridsen HT, Santoro A. Cyclophosphamide versus ifosfamide: a randomized phase II trial in adult soft-tissue sarcomas. *EORTC Soft tissue and bone sarcoma group. Cancer* 1984; 53: 1825–32.
58. Spira AI, Ettinger DS. The Use of Chemotherapy in Soft-tissue Sarcomas. *Oncologist* 2002; 7: 348–59.
59. Santoro A. Advanced soft tissue sarcoma: how many more trials with anthracyclines and ifosfamide? *Ann Oncol* 1999; 10: 151–4.

Ginger E Holt and Herbert S Schwartz

---

## INTRODUCTION

Metastatic carcinoma to bone occurs far more commonly than a skeletal sarcoma which arises in bone. Skeletal sarcomas originate in the bone and are termed primary cancers of the bone, while metastatic carcinomas to bone are defined as secondary malignancies of bone. Secondary cancers of bone are at least 100-fold more common than primary tumors of bone especially when the individual is over 40 years of age. Consideration of the incidences of prostate, breast, lung, and colorectal carcinomas, metastatic cancer to bone should be the primary consideration when evaluating a potential bone tumor irrespective of age<sup>1</sup>.

Diagnosing and managing malignancies of the skeleton can be quite complex because of the multiple variables that affect this dynamic organ. The age of individuals can be between 1 and 100 years: Metastatic deposits occur more often in the axial skeleton than the appendicular. This is especially true for carcinoma metastases. However, skeletal sarcomas can also occur in the axial skeleton. Metabolic bone disease, endocrinopathies, drugs, infection, benign neoplasia, and trauma often present with symptoms and radiographic features that overlap those of bone malignancies.

Evaluation of a patient with a bone lesion requires a thorough history and physical examination, imaging studies and sometimes associated laboratory tests to formulate a differential diagnosis and provide appropriate treatment. The differential diagnosis will then determine the need for further investigation, i.e. biopsy. Once a diagnosis is firmly established the appropriate treatment can be chosen. In the case of metastatic bone disease this can be medical or surgical management depending on the biology of the tumor and its location in the skeleton. The treatment of primary bone tumors is quite different from that for metastatic lesions. Treatment also differs greatly when a pathological fracture is present. Overall, cancer surgery for the musculoskeletal system has many unique caveats when compared with surgery for other systems.

Patients with a bone tumor commonly present with pain due to a pathological fracture. The definition of a pathological fracture varies. Traditionally, a pathological fracture occurs when a disease process breaks through at least one cortex of a bone. There does not have to be displacement or fracture hematoma. There usually is pain, especially when bearing weight. Many tumors present as a pathological fracture. Pain with weightbearing is often the first presenting sign of a micropathological fracture from a tumor growing in bone. Therefore for the purpose of this discussion, a pathological fracture is defined as a symptomatic break in a bone's cortex by a tumor.

There are four and only four types of cancer surgical procedures. This is especially true for surgical treatment of cancer of bone cancers. Resections can be intralesional, marginal, wide, or radical. Intralesional surgery cuts through the tumor, such as a curettage, and often leaves gross tumor behind. Marginal surgery involves a surgical dissection plane at the pseudocapsule of the tumor. This often leaves microscopic tumor behind. Wide surgical resection theoretically removes all tumor, but is at risk for leaving small microscopic satellite malignant cells. The surgical dissection plane is still within the anatomic compartment that the tumor began in and surrounds the tumor with a cuff of normal tissue. Radical resections remove the entire anatomic compartment that the tumor began in and surrounds the tumor with a wall of compact, connective compartmental tissue. For example, a radical resection of a femoral sarcoma removes the entire femur from hip joint to knee joint. The local recurrence rate is inversely proportional to the surgical margin; the wider the margin the lower the local recurrence rate. Limb salvage surgery is predicated on achieving a tumor-free resection margin in three dimensions, often with a wide dissection plane. Theoretically, it is possible to achieve a wider margin with limb salvage than with amputation<sup>2</sup>. Limb salvage surgery is more complicated than just achieving tumor-free surgical margins. The function of the skeleton must be restored. Therefore, every limb salvage surgical case has a resection and reconstruction component. Function and functional

outcome are key variables in determining whether limb salvage or an ablative surgical procedure is best for any one individual.

Reconstruction of skeletal defects can occur through the use of autografts, allografts, metallic prostheses, or combinations of these. Large structural allografts are unique transplantable organs. They are avascular, aneural and function as biomechanical and cellular scaffolds. They pose large infection risks. They also pose biomechanical risks, both in the first year and later as they become slowly and partially revascularized over decades<sup>3,4</sup>. Biomechanics and the biology of bone resorption and bone formation are key elements in deciding which limb salvage option is best. This is especially true because metallic implants have a finite lifespan. Reconstruction of an articular surface is best accomplished with an arthroplasty rather than allograft articular cartilage. Pediatric limb salvage adds the complex task of bone and soft tissue enlargement to equalize limb lengths as the child grows.

## STAGING OF BONE TUMORS

Staging a bone tumor requires local and systemic evaluation. The local evaluation of a tumor includes imaging and biopsy. The systemic staging of a tumor necessitates complete imaging modalities. Other laboratory analyses may be helpful in diagnosing a bone lesion, but are not necessary in staging. Once local and systemic evaluation is complete, a biopsy may be necessary to establish a tissue diagnosis or to assist in tumor staging by providing the tumor grade. Biopsy of skeletal lesions is a complex cognitive skill and may prove more harmful than helpful if inappropriately performed.

### Imaging

#### *Local*

Plain radiographs remain the most specific non-invasive means of establishing a differential diagnosis for primary and secondary bone tumors. Plain radiographs in two perpendicular planes should first be obtained to evaluate a lesion. Typically the benign or malignant nature of a tumor can be determined on plain radiographic evaluation. In formulating a differential diagnosis, Enneking's four questions should be asked regarding any bone tumor<sup>5</sup>.

- (1) Where is the location?
- (2) What is the tumor doing to the bone?
- (3) What is the bone doing to the tumor?
- (4) What is the underlying tumor matrix?

Location of the tumor includes diaphyseal, metaphyseal, epiphyseal, and intramedullary locations, or an extramedullary surface tumor.

If the diagnosis is unclear after plain radiographic evaluation, a more specific evaluation can be ordered. The next test to be obtained is based on what question one is asking. Computerized tomography (CT) is the test of choice to evaluate cortical bone. It allows for evaluation of endosteal scalloping or erosion and whether or not there is mineralization within the lesion<sup>6</sup>. Magnetic resonance imaging (MRI) provides information on anatomy including intramedullary or extramedullary tumor location. It also provides information as to the bone, whether there is a surrounding soft tissue mass, and provides definitive tumor margins<sup>7</sup>. An MRI scan can give specific information about the matrix of the tumor. The treating physician should then determine, based on these imaging studies, whether a diagnosis can confidently be made on the imaging studies or whether a biopsy is warranted.

#### *Systemic*

Systemic staging includes evaluation for multifocal disease, metastatic disease from a primary bone tumor, or to locate the source of metastatic disease causing a secondary bone tumor.

A whole body technetium-99 labeled methylene diphosphonate (<sup>99m</sup>Tc-MDP) bone scan is useful in evaluating multifocal skeletal disease<sup>8</sup>. Although such imaging may assist in determining an alternative biopsy site if the underlying diagnosis is unknown, it aids in narrowing the differential diagnosis. A CT scan of the chest, abdomen and pelvis will determine the origin of metastatic disease in approximately 85% of cases<sup>9</sup>. These scans serve as systemic staging for primary malignant bone tumors as well. Although this is an excellent test for skeletal metastatic disease, an exception is in the evaluation of myeloma. In this disease bone turnover occurs so rapidly that the radiotracer is not taken up by bone and is, therefore, not detected. Systemic skeletal evaluation for myeloma is best achieved with a skeletal survey.

(<sup>18</sup>F) 2-fluoro-2-dioxy-D-glucose positron emission tomography (FDG-PET) uses the glucose metabolism of tumors to detect tumor activity<sup>10</sup>. This method of systemic staging is most useful for melanoma, adenocarcinoma and lymphoma.

#### *Laboratory evaluation*

Serum and urine tests are non-specific and should be ordered selectively. An elevated white blood cell count, erythrocyte sedimentation rate (ESR) and C-reactive

protein suggest infection, although the ESR may be elevated in many malignant tumors. Prostate specific antigen (PSA) should be tested in males with lytic bone lesions to evaluate for prostate cancer. Serum protein electrophoresis and urine protein electrophoresis are useful in evaluating multiple myeloma. Alkaline phosphatase may be elevated in primary bone tumors (osteosarcoma) and Paget's disease. Serum calcium and parathyroid hormone levels are increased in the brown tumors of hyperparathyroidism. Serum lactate dehydrogenated alkaline phosphatase have been shown to be of prognostic significance in as much as patients with elevated levels have shorter survival times than do those with normal values<sup>11</sup>. Calcium levels should be checked in patients with a bone tumor, especially those undergoing surgery as these patients often have hypercalcemia. Urine tests include N telopeptide and urine hydroxy proline. These tests may be helpful in evaluating bone turnover in Paget's disease or osteoporosis.

Three primary concepts are needed to establish the diagnosis of a skeletal malignancy. These three components are essential and must occur before management is begun.

- (1) A biopsy is necessary to make a tissue diagnosis. There are several *methods* by which to obtain a biopsy and they are dependent upon the expertise and experience at the institution or facility. Closed needle biopsies should be performed to confirm a suspected diagnosis. The suspected diagnosis can be based on clinical or radiographic grounds. A good example is a needle biopsy used to confirm the presence of metastatic disease when the primary is known. A closed needle biopsy is most useful when the cytopathologist, or surgical pathologist in the case of a true cut needle, is experienced and confident. There is little place for a pathological diagnosis that is descriptive and devoid of a specific histopathological diagnosis. Open biopsies yield a higher percentage of correct tissue diagnoses. The larger tumor volume harvested lessens sampling error. However, costs are more expensive<sup>12</sup>. Most open biopsies are now performed in the outpatient setting. While a closed needle biopsy may potentially be useful in a hard to access location, such as the spine, such areas often require open biopsy. This is especially true if the bone cortex is hard and difficult to penetrate with a needle.
- (2) *Technique* of the biopsy is the second critical component. It involves understanding the concept that biopsy tracts harbor malignant cells. This has been proven true for essentially every malignancy<sup>13,14</sup>. Therefore, since malignant cells lie within the biopsy

tract, the biopsy tract must be removed when performing a definitive surgical resection, especially for limb salvage procedures. If the biopsy tract is not removed there is an increased incidence of local recurrence. The placement of the biopsy tract therefore becomes a critical component of successful limb salvage. Several studies have clearly demonstrated that an inappropriately placed biopsy complicates treatment and survival<sup>15</sup>. We recommend that biopsies, especially of sarcomas, be performed at tertiary referral centers where there is an experienced group of professionals familiar with these practices. Complication rates are typically three to four times greater when biopsies of sarcomas are performed by non-experienced personnel.

- (3) Establish a *tissue diagnosis*. Because such a variety of malignancies may present with bone pathology, it is imperative that a tissue diagnosis is made prior to the initiation of definitive management. Symptoms and radiological imagery overlap. The surgeon should not begin a resection without a confident tissue diagnosis.

After a complete history and physical evaluation, local and systemic evaluation and diagnosis of the tumor type and grade based on biopsy a tumor may be staged. Systems exist for both benign and malignant bone tumors. In general, staging allows for prediction of the risk for metastatic disease and therefore helps to determine the appropriate treatment. Malignant bone tumor staging consists of the Enneking System/SSS or the American Joint Commission on Cancer (AJCC) Staging System<sup>16</sup>.

In the Enneking System, malignant bone tumors are graded by histology and compartment status<sup>17</sup>. Histologically tumors are graded as low or high grade, whereas compartment status is evaluated by confinement of the tumor to a compartment (intracompartmental) or no such confinement (extracompartmental). Histologically stage I tumors are low grade lesions and stage II tumors are high grade lesions. Compartmental status is determined as stage A when the tumor remains within the bony compartment and stage B represents an extracompartmental tumor. Stage III defines metastases, whether they are low grade or high grade. The majority of malignant tumors are high grade and extracompartmental (stage II B) lesions. The Enneking System does not apply to Ewing's sarcoma or rhabdomyosarcoma.

The AJCC staging system uses the TNN classification scheme. It determines the prognosis based on tumor size (T1  $\leq$  8 cm; T2  $>$  8 cm), grade (G1, G2 low grade; G3, G4 high grade), lymph nodes (plus or minus), and metastases (plus or minus).

## METASTATIC BONE TUMORS

Over 1.2 million new cases of carcinoma are diagnosed each year in the USA and approximately 50% of these tumors can metastasize to the skeleton<sup>16</sup>. As medical management of these patients improves, more patients are expected to present with metastatic bone disease. The skeleton is the third most common site for metastasis that originate from primary carcinomas<sup>18</sup>. Metastatic disease to the liver and lung may remain asymptomatic while metastatic bone disease presents early. It is not unusual for this to be the primary presentation of a visceral primary carcinoma. Primary cancers that most commonly metastasize to the bone include those of the prostate, breast, lung, thyroid, and kidney. The most common sites of metastatic bone disease include spine, pelvis, ribs, skull, and proximal aspects of the long bones. Treatment of the patient with metastatic bone disease requires a global view. The biology of the tumor, a patient's functional status and the location of the tumor are all critical points to evaluate in ultimate management.

A thorough treatment plan for the patient with metastatic carcinoma to bone must take into account all variables about a particular lesion prior to developing a treatment strategy. A multitude of treatment variables can be schematically represented in the three points of an outcome triangle. A thorough and appropriately weighted evaluation of these three variables will more likely result in a favorable outcome for a patient with a metastatic lesion of bone prior than an algorithmic approach. The three variables within this outcome triangle include bone biology, the pathology of the underlying lesion and the functional status of the patient.

### Bone biology

Bone biology includes the cellular makeup of the fractured bone and its biomechanical environment. Each bone is different and each site within a bone is different. The healing potential of the bone is a function of multiple variables including patient age, location of the lesion in the bone and the remodeling potential. The location of the lesion certainly dictates its treatment, and the location of the tumor dictates its treatment and outcome. A tumor located in the non-weightbearing bones such as the upper extremity may be first treated with radiation therapy and can be followed by determining whether surgical stabilization is necessary. Lesions located within the lower extremities are more likely to require surgical fixation prior to radiation therapy.

### Pathology

The pathology component of the outcome triangle is based on an understanding of the disease and its biological behavior and natural history. A thorough understanding of the disease entity and its pathological behavior is critical in determining how best to treat it. Treatment of a pathological fracture is therefore dependent on the diagnosis which can only be established with certainty from a properly obtained and representative biopsy sample. An exception to this occurs in a patient who has known metastatic disease and has previously had tissue obtained from a metastatic site confirming metastatic pathology. It can reasonably be assumed that other lesions within the bone, if their appearance in accordance with metastatic disease, can be assumed metastatic. Knowledge of the underlying pathology is critical as it severely affects treatment and potentially outcome. The life expectancy of a patient with metastatic renal cell carcinoma may be different in a patient who develops a single metastatic lesion and can be treated with en bloc resection; as compared with intralesional resection and curettage for a patient with multifocal disease. Lesions such as lymphoma may respond to radiation therapy, reconstituting bone within a lesion, therefore these lesions may be treated non-surgically with radiation therapy, chemotherapy and protected weightbearing for non-critical skeletal locations. It should be clear that pathology alone does not dictate management.

### Function

It is important to understand the level of function of the patient and the pathology of the disease when deciding the ultimate treatment course for an impending or a completed pathological fracture. What are the needs of the patient? Is pain control paramount? Who is the caregiver? Can the patient transfer from bed to chair? What about personal hygiene? Is the patient capable of making decisions about their care? The answer to these questions often dictates the role of surgery, extent of procedure and durability of implant inserted.

### *Surgical versus non-surgical management*

The two most important considerations for treatment of a metastatic lesion to bone are the tumor pathology and tumor location. A lesion in a non-weightbearing bone (humerus) that is treatable by radiation may not require surgical stabilization. A lesion in the peritrochanteric femur has a high chance of progression to a complete fracture and should be treated with an intramedullary nail

with a head and neck locking device. A spinal lesion producing neurological compromise requires urgent direct decompression and stabilization<sup>82</sup>.

Non-surgical treatment measures include chemotherapy, external beam radiotherapy and bisphosphonates. Chemotherapy is a systemic anticancer therapy. The appropriate medical regimen should be chosen by a medical oncologist. Radiotherapy provides palliation and pain relief at single metastatic sites. Radiographic recalcification post-treatment may be seen 3–6 weeks after treatment with maximal recalcification 2–3 months after radiation. Bisphosphonates are effective in reducing skeletal morbidity by decreasing osteoclast resorption of bone. All patients with skeletal metastatic disease should receive bisphosphonate therapy. Typically these treatments are used in combination with each other and are often combined with surgical management. Surgical management of secondary bone lesions differs based on the location and extent of the disease. Surgery in these patients is rarely curative and more commonly palliative. The goal of surgery in this case is to provide an immediately stable, durable construct to last the lifetime of the patient. This may necessitate surgical techniques that vary from the norm, such as filling the bone tumor void with bone cement, or using a fixation plate where an intramedullary nail may be used in non-pathological bone. A large periarticular lesion might best be treated with resection of the entire bone and reconstruction with a megaprosthesis and hinged joint. It cannot be overemphasized that each patient is an individual and must be evaluated and treated with individual goals in mind.

## SKELETAL SARCOMAS

Primary neoplasms of the skeleton are rare amounting to only 0.2% of all human tumors<sup>19</sup>. Skeletal sarcomas occur at a rate of approximately one-tenth of their soft tissue counterparts (including gynecological sarcomas)<sup>20,21</sup>. The incidence of bone sarcomas is approximately one new case per 100 000 population per year. Osteosarcoma is the most common primary malignant tumor of bone representing approximately one-third of cases. This is followed by chondrosarcoma at 25% and Ewing's sarcoma at 16%. Chordoma comprises approximately 8% and malignant fibrous histiocytoma of bone comprises approximately 5% of skeletal sarcomas. The histopathological diagnosis of fibrosarcoma of bone overlaps with the newer classification of malignant fibrous histiocytoma (MFH). Several bone tumors occur in the setting of

inherited tumor syndromes<sup>22,23</sup>, but their histology differs little from their respective sporadic counterparts. Non-Hodgkin's lymphoma of bone (NHL) can also occur as the only site of presentation of this disease. Pre-existing benign bone tumors can undergo malignant transformation into skeletal sarcomas. There is also a rising incidence of postradiation sarcomas as the number of childhood cancer survivors and mammary lumpectomy survivors increases.

The age distribution of skeletal sarcomas is bimodal. The first peak occurs during the second decade of life while the second peak occurs in individuals older than 60 years of age. Skeletal sarcomas have a bimodal age distribution incidence pattern while soft tissue sarcomas in contrast, gradually increase with age.

## Clinical features

Pain is the first and foremost symptom in nearly all bone tumors whether of primary or secondary etiology. Activity related pain indicates biomechanical weakness. Persistent pain, especially at night, indicates a more rapidly growing tumor. Neurovascular compromise due to mass compression results in symptoms related to the structure compromised. An enlarging mass is another common presenting symptom. Often the mass can present as a painless swelling. The masses are often hard and deep. They are not mobile on the long bone as a soft tissue sarcoma would be. Tumors that present at extreme size may involve the dermis or ultimately the epidermis presenting with tumor fungation. This complicates biopsy and resection due to the need to resect more skin, leaving less skin for wound coverage. Limited joint mobility is another presenting symptom. The loss of motion either due to mass impedance to flexion or sympathetic effusions can also cause the patient to present to the physician. Constitutional symptoms, such as fever, usually are not the presenting symptoms of a sarcoma.

Imaging is an important component of the overall staging, evaluation and management of malignancy. Three-dimensional imaging is critical to determine local and regional tumor extent. This directly impacts the nature and type of the resection and reconstruction. It can often influence the biopsy technique. When evaluating a potential malignancy of bone, it is critical to obtain a plain X-ray of the entire bone, an MRI of the entire bone from joint to joint and a chest X-ray and/or CT scan of the chest. Bone scans are important only for the purpose for evaluating the entire skeleton for polyostotic disease. PET scans are currently being evaluated to assess their efficacy and utility.



## OSTEOSARCOMA

Osteogenic sarcoma or osteosarcoma is defined as a malignant bone tumor that produces neoplastic osteoid. Any amount of malignant osteoid production meets the criteria for osteosarcoma. Often there is histopathological overlap as cartilage and fibrous tumors in various stages of dedifferentiation can have a malignant osteoid component. Strictly, however, any malignant osteoid production is termed osteogenic sarcoma. Osteosarcoma is the most frequent bone tumor and is a heterogeneous skeletal sarcoma. Most arise in long bones without a precursor. Osteosarcoma is heterogeneous whether it is classified by clinical, pathological, radiographic or genetic mechanisms. There are low and high grade osteosarcomas.

### Epidemiology

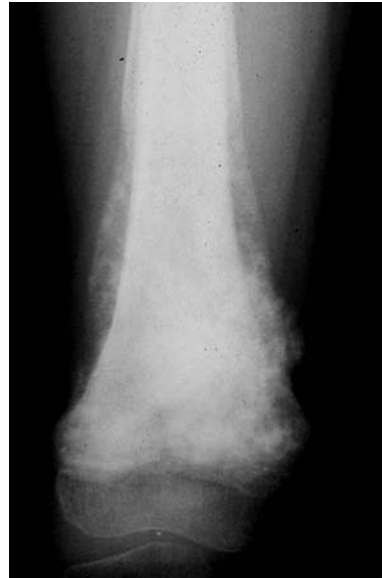Conventional osteosarcoma is the most common and is a high grade intramedullary malignancy often occurring in adolescents. Conventional osteosarcoma occurs most typically in the second decade of life around rapidly growing growth plates such as the knee and shoulder. There is a 3 : 2 male to female predominance. The appendicular skeleton is involved more than the axial. Frequently the bone metaphysis is involved.

### *Clinical and radiographic characteristics*

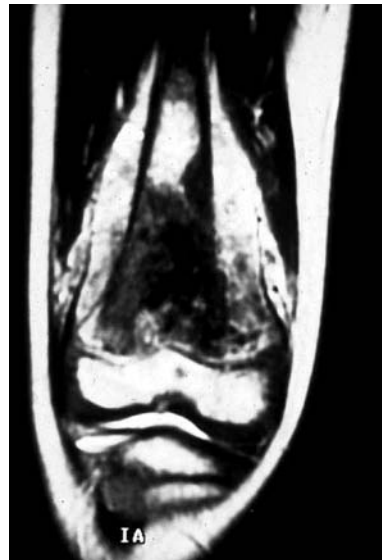Symptoms typically are a painless mass around the joint that causes pain as the mass gets larger. A pathological fracture can occur. The radiographic appearance on plain X-ray is one of a lytic lesion with poorly defined margins (Figure 33.1). Careful examination of the plain radiograph may identify ossification in the soft tissues. An MRI is critical to determine the proximal and distal intramedullary tumor extent and the relationship between the soft tissue component and critical neurovascular structures (Figure 33.2). Skip metastases may occur to the same bone, as intraosseous, non-contiguous tumor deposits which portend a poor prognosis<sup>24</sup>.

### *Histopathology*

Malignant osteoid is produced by pleomorphic cells in a disorganized fashion. Varying amounts of bone production can be identified and overlap with fibrous or cartilaginous matrix production by the malignant cells (Figure 33.3). Chemotherapy-induced tumor necrosis of more than 90% is the variable most predictive of survival<sup>25</sup>.



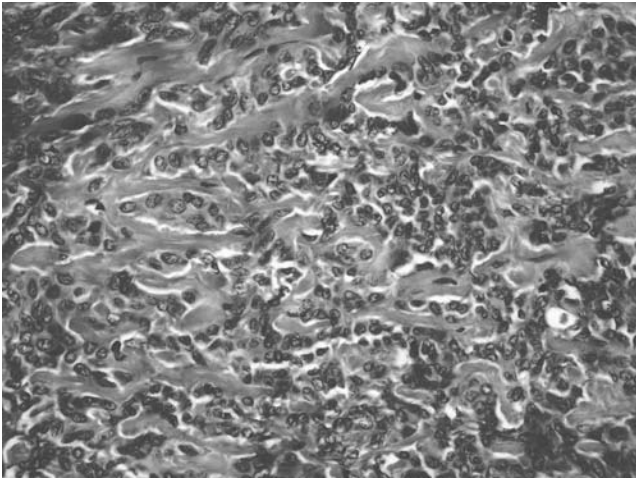
**Figure 33.1** Anteroposterior X-ray of right distal femur osteosarcoma with extraosseous extension.



**Figure 33.2** MRI axial T1 of osteosarcoma seen in Figure 33.1.

### *Genetics*

The karyotype of any osteosarcoma cell is variable and may contain a complex aberration of numerical and structural chromosome alterations. No specific translocation has been assigned to conventional osteosarcoma. Amplifications at 1q 21-23 and 17p are frequent findings in conventional osteosarcoma<sup>26</sup>. Similarly a variety of genes in the 12q 13-15 region are co-amplified. A variety of genes have been found to be overexpressed in osteosarcoma without a specific or diagnostic pattern. These include



**Figure 33.3** Osteosarcoma photomicrograph demonstrating abundant tumor osteoid (200 × H&E).

MET<sup>27,28</sup>, BMP6 and BMP receptor-2. They may be expressed in more than half of osteosarcomas<sup>29</sup>.

Hereditary retinoblastoma patients have a high risk of developing osteosarcoma later in life<sup>30</sup>. Such tumors are likely to show loss of heterozygosity at 13q and alterations in the RB1 tumor suppressor gene. The prognosis for patients with RB1 alterations seems to be poorer than for patients without RB1 alteration<sup>31</sup>. Li-Fraumeni syndrome patients have a p53 germ line mutation and are at an increased risk for developing osteosarcoma. In sporadic osteosarcoma, 17p alterations and p53 mutations are seen in approximately 35% of tumors<sup>32</sup>.

### *Prognostic factors*

The universal fate of untreated osteosarcoma is death. Even if treated with ablation alone, it is fatal in 80% of individuals. Pulmonary metastases are the primary mechanism of mortality. This reinforces the concept of micrometastases at presentation. Micro metastases are frequently present even when non-visualized on plain chest X-ray or CT of the lungs. Contemporary advances in limb salvage reconstructive metallic endoprosthesis and the concept of micrometastases on presentation heralded the introduction of neoadjuvant chemotherapy in the treatment of osteosarcoma<sup>33,34</sup>. This philosophy has been mimicked for treatment of other aggressive solid tumors. Intensive neoadjuvant chemotherapy provides modest tumor shrinkage, while a reconstructive prosthesis or plan is developed. Individuals who are candidates for limb salvage and who are more apt to respond to chemotherapy are identified. Chemotherapy protocols typically involve high dose methotrexate, doxorubicin and etoposide<sup>35,36</sup>. After approximately 3 months of treatment, the candidate

is restaged for the possibility of limb salvage and surgery is then performed. Chemotherapy is reinstituted within 2–3 weeks after surgery and continued for 1 year. Liberal use of flaps and extensile exposures has facilitated restarting of chemotherapy early in the postoperative period. The postoperative switch of chemotherapeutic agents (that failed to produce the expected antitumor effects) to alternatives has been popularized, but studies have yet to prove it universally advantageous for prolonged survival<sup>35,37</sup>.

The neoadjuvant therapy approach for limb salvage, has yielded local recurrence rates typically less than 10%, and limb salvage has not affected overall survival in experienced hands. Long-term continuously free of disease survival rates of 61% at 10 years have been demonstrated<sup>35</sup>. The most important prognostic variable predicting survival in conventional osteosarcoma is the percentage of chemotherapy-induced necrosis. Necrosis values greater than 90% are associated with improved survival<sup>38,39</sup>, unfortunately this important variable cannot be determined on clinical presentation; therefore, the high risk patients are not identified until after surgical resection. This emphasizes the need for identification for early prognostic biomarkers. Those patients who experience a good response to chemotherapy (greater than 90% necrotic tumor) generally have a long-term survival rate of 80–90%<sup>40,41</sup>.

Histological variants of osteosarcoma can be broadly divided into high and low grade components. High grade osteosarcoma variants include telangiectatic osteosarcoma, small cell osteosarcoma and high grade surface osteosarcoma. There are no specific immunophenotypes, genetic or cytogenetic markers or prognostic features to individually identify these variants. Radiographically, telangiectatic osteosarcoma can mimic the presentation of aneurysmal bone cyst. Low grade variants of osteosarcoma include low grade central osteosarcoma, parosteal osteosarcoma and periosteal osteosarcoma. These typically present in older patients, have a less aggressive clinical course and a more innocuous radiographic appearance. The histological appearance is characterized by increased matrix production of fibrous or cartilaginous tissue.

The chromosomal alterations in parosteal osteosarcoma are different from those of conventional osteosarcoma. They often have more supernumerary ring chromosomes as the sole abnormality. Survival is excellent in parosteal osteosarcoma representing 90% survival in 5 years following successful surgical resection<sup>42</sup>. Treatment is often with limb salvage surgery and no chemotherapy. Periosteal osteosarcoma has a prognosis intermediate between parosteal and conventional osteosarcoma. It occurs in the shafts of long bones and has a prevalent cartilaginous feature. Medullary involvement portends a poor prognosis

and often is treated as a conventional osteosarcoma. Typically periosteal osteosarcoma is not treated with chemotherapy.

## EWING'S SARCOMA

Ewing's sarcoma and primitive neuroectodermal tumor (PNET) are small, blue cell malignancies of bone which cytogenetically are the same entity (Figure 33.4). They were originally described by Ewing as a diffuse endothelioma. In common with other blue cell malignancies, they are exquisitely sensitive to radiation and chemotherapy. They produce little matrix and are distinctly different from osteosarcoma. These small, round blue cells have little cytoplasm and frequently contain glycogen (periodic acid-Schiff (PAS) positive). In some cases, rosettes are evident indicative of their primitive neuroectodermal origin. CD99 is the immunophenotype expressed in almost all cases on the membrane for Ewing's sarcoma.

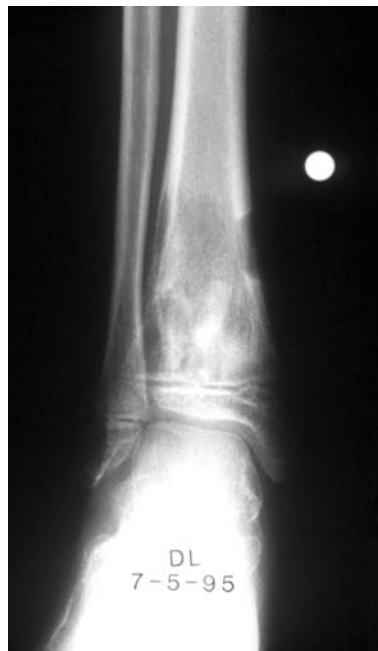### Epidemiology

Ewing's sarcoma accounts for about 16% of primary malignant bone tumors. It has a predilection for males with a ratio of 1.4 : 1 and is seldom seen in blacks. Almost 80% of patients are younger than 20 years of age and it is uncommon to see Ewing's sarcoma in individuals older than 30.

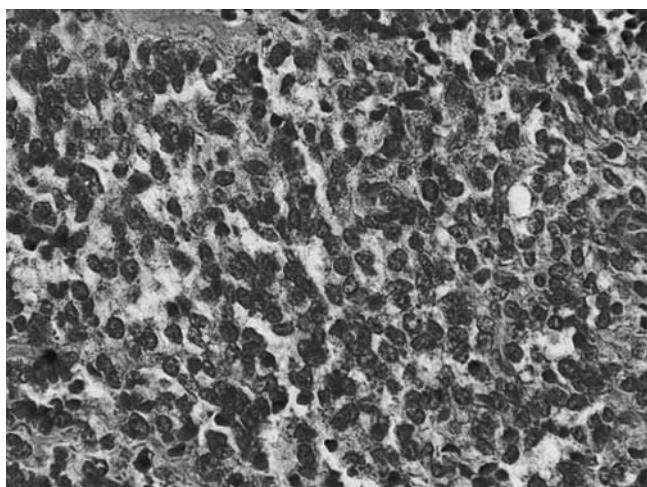
### Clinical features

Ewing's sarcoma tends to arise in the diaphysis of long bones (Figure 33.5). It may also occur in the flat bones of the pelvis or ribs. The plain radiographic appearance

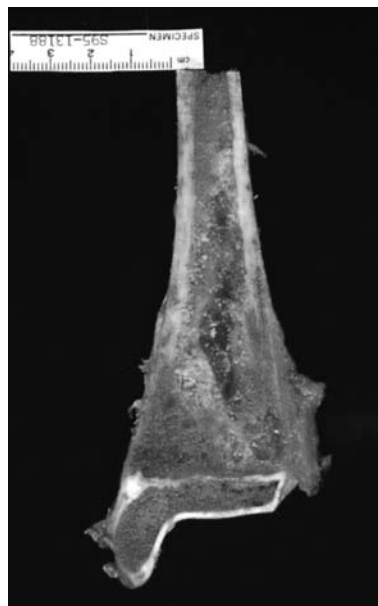
depicts a rapidly growing, poorly defined moth-eaten bone destruction pattern which overlaps with an aggressive infection. Circumferential soft tissue masses emanating from the bone are common as well. Macroscopically, the tumor looks like pus (Figure 33.6). This emphasizes the need to accurately verify the tissue diagnosis. The adage of 'biopsy what you culture and culture what you biopsy' is sound advice.



**Figure 33.5** Distal tibia Ewing's sarcoma with significant periosteal reaction on plain X-ray.



**Figure 33.4** Photomicrograph of Ewing's sarcoma (400×H&E).



**Figure 33.6** Macroscopic specimen from Figure 33.5.

## Genetics

The Ewing's family of tumors is characterized by t(11;22) (q24;q12) chromosomal translocation detectable in about 85% of cases<sup>43</sup>. Molecular cloning of the t(11;22) translocation breakpoints reveals a fusion between the 5' end of the EWS gene from the 22q12 chromosome with the 3' end of the 11q24 FLI1 gene<sup>44</sup>. The remaining 10–15% of cases have a variant translocation t(21;22) (q22;q12) fusing EWS to a closely related gene called ERG from chromosome band 21q22<sup>45–47</sup>. FLI1 and ERG are members of the ETS family of transcription factors. Virtually all Ewing's tumors express some form of the EWS/ETS family gene fusion<sup>48</sup>. EWS/FLI1 have potent oncogenic activities<sup>49</sup> suggesting the resultant protein functions as an aberrant transcription factor which binds and regulates expression of target genes<sup>50,51</sup>.

## Prognostic and treatment factors

The overall management of Ewing's sarcoma is similar to that of other aggressive skeletal sarcomas. Most patients receive 1 year of systemic cytotoxic chemotherapy. Two to three cycles of neoadjuvant chemotherapy are given prior to surgical intervention which usually occurs after the 3 month of chemotherapy. Unlike osteosarcoma, the soft tissue mass of Ewing's sarcoma is markedly reduced by the cytoreductive effects of neoadjuvant chemotherapy. This greatly facilitates limb salvage surgery. There is controversy as to what constitutes a true, final negative microscopic surgical margin when one considers the virgin tumor volume compared with the contracted tumor volume after exposure to cytotoxic agents. Careful scrutiny of the prechemotherapy and post-chemotherapy images best identifies the areas of bone and surrounding soft tissue necessary for margin-free resection. The modern era of Ewing's sarcoma treatment has increased 5-year survival rates to approximately 65%. This is higher for the more peripheral tumors of the appendicular skeleton and lower for the larger axial tumors of the pelvis and spine<sup>52</sup>. While chemotherapy and surgery remain the mainstay of treatment, radiation is reserved for refractory Ewing's sarcomas or those in which microscopic positive margins remain following resection. It is preferable not to radiate, especially for young individuals, as this complicates skeletal growth and augments the possibility of secondary malignancies later in life. A molecular marker such as telomerase has been demonstrated to be a significant unfavorable prognostic variable<sup>54</sup>.

## CHONDROSARCOMA

Chondrosarcomas are malignant skeletal neoplasms producing hyaline cartilage. These tumors comprise a

heterogeneous and diverse group of lesions with diverse morphology, imaging and clinical behavior. Surgery is the mainstay of treatment. Grade remains the single most important prognostic variable. While there are many different types of chondrosarcomas, the main differentiating classification is primary versus secondary chondrosarcomas. Primary chondrosarcomas arise in normal bone. In contrast, secondary chondrosarcomas arise from a pre-existing benign bone neoplasm. Primary chondrosarcoma accounts for about 25% of malignant bone tumors<sup>55</sup>. Approximately 90% of chondrosarcomas are primary.

## Clinical characteristics

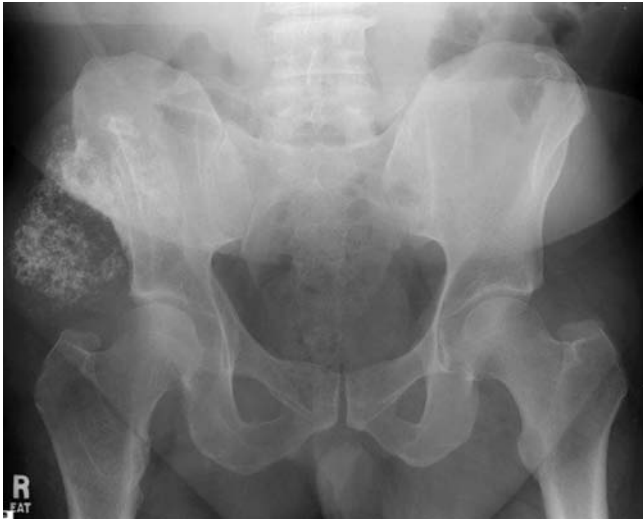Chondrosarcoma is a disease of adulthood with most patients being older than 50 years. The most common sites affected are in the axial skeleton and limb girdles. Symptoms are characteristically of long duration. Radiographic characteristics consistently demonstrate expansion with central, lobular cartilage formation containing punctate calcifications. As the grade of the chondrosarcoma increases, the dedifferentiation results in loss of lobular formation and a more aggressive and destructive radiographic pattern to the bone.

## Prognostic features

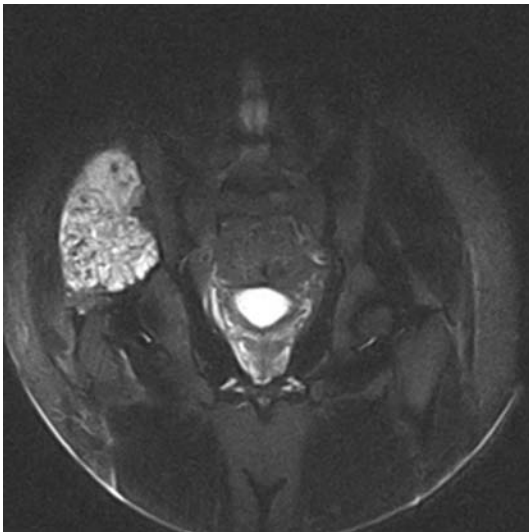
Grading is important in chondrosarcoma. Many studies have confirmed its usefulness<sup>56</sup>. Grading chondrosarcomas involves more than just microscopic examination. Identical histopathological pictures can be seen from a benign enchondroma in the phalanx of a child compared with pelvic cartilage sarcoma in an adult. The phalanx tumor has no metastatic potential, while the pelvic lesion has a high local recurrence rate and metastatic potential. Therefore, clinical information is paramount for the pathologist to make an accurate and clinically relevant diagnosis. Five-year survival rates approach 90% for patients with grade I tumors, while grade III tumors have 5-year survival rates of 40–50%<sup>56</sup>. Margin-free surgical resection remains the mainstay of treatment. The first operation offers the best chance to achieve recurrence-free results, especially in the pelvis<sup>57</sup>.

## Secondary chondrosarcoma

Secondary chondrosarcomas arise from a pre-existing precursor lesion such as an osteochondroma or enchondroma as demonstrated in Figures 33.7 and 33.8. The risk of developing a chondrosarcoma from one of its benign precursors is probably very rare and much less than 1%. An accurate calculation is impossible because the denominator is unknown. Patients with Ollier disease or Maffucci



**Figure 33.7** Anteroposterior X-ray of pelvis of large chondrosarcoma arising from outer table osteochondroma of pelvis.



**Figure 33.8** Coronal T2 MRI of Figure 33.7, note the sessile osteochondroma of origin.

syndrome have a 25–30% risk of developing chondrosarcoma<sup>58,59</sup>. The chance of tumor-specific death is much higher when the chondrosarcoma develops in the axial skeleton rather than the appendicular skeleton. Maffucci syndrome patients often die from occult carcinomas<sup>59</sup>.

The histopathological appearance of secondary chondrosarcomas is not significantly different from that of primary chondrosarcomas. Sometimes the malignant cartilage will be juxtaposed to its benign counterpart. Radiographic diagnosis of a secondary chondrosarcoma arising from a pre-existing osteochondroma is said to occur when the cartilaginous cap exceeds 1–2 cm<sup>60</sup>.

### *Chondrosarcoma variants*

Variants of chondrosarcoma include periosteal chondrosarcoma. This is a surface neoplasm of bone. Its synonym is juxtacortical chondrosarcoma. Aside from the differing radiographic appearance, the morphological features, treatment and prognosis are not significantly different from conventional primary chondrosarcoma. Dedifferentiated chondrosarcoma is a distinct variety of chondrosarcoma, defined as having juxtaposed histological areas of well-differentiated cartilage and a high-grade, non-cartilaginous sarcoma. They make up approximately 20% of chondrosarcomas and occur in the older age group of the 7th and 8th decades of life. The large long bones are commonly involved. The radiographic picture often suggests the presence of a pre-existing enchondroma with a high grade aggressive appearing lesion emanating from one side of it. Of patients 90% are dead from distant disease within 2 years and chemotherapy has not been proven to be effective<sup>61</sup>.

Mesenchymal chondrosarcoma is an even more rare variant of chondrosarcoma representing 3–5% which occurs in the 3rd and 4th decades of life<sup>62,63</sup>. These high grade chondrosarcomas are biphasic. In a fashion similar to dedifferentiated chondrosarcoma, they show islands of hyaline cartilage juxtaposed to a high grade undifferentiated component which has small round cells simulating Ewing's sarcoma or hemangiopericytoma. This variant of chondrosarcoma is often pre treated with neoadjuvant chemotherapy similar to Ewing's sarcoma.

Clear cell chondrosarcoma is a rare variant of chondrosarcoma which uniformly occurs in the epiphyseal remnants of long bones. This suggests a relationship to a malignant counterpart of chondroblastoma. This is a lower grade chondrosarcoma with a survival rate of 85% with surgery alone<sup>64</sup>.

### **Chondrosarcoma genetics**

Total or partial, gains or losses predominate in the genetic imbalances of chondrosarcoma. Loss of material from 13q has been found to be an independent predictor of metastases regardless of tumor grade<sup>65</sup>. Significant advances in the molecular genetics of chondrogenesis and chondrosarcoma oncogenesis have focused on the *EXT1* and *EXT2* genes as well as the *PTHRI* gene which encodes a receptor for PTH and PTHrP<sup>66</sup>. The mutation in the receptor results in a constitutive increase in cAMP signaling analogous to Jansen's disease of metaphyseal chondrodysplasia. The underlying hypothesis is that a mutant PTHrP receptor delays the differentiation of proliferating chondrocytes by constitutively activating hedgehog signaling<sup>67</sup>. This has been substantiated by

work in transgenic mice carrying the *PTHRI* mutation<sup>66</sup>. Normal chondrocyte proliferation to the hypertrophic chondrocyte occurs via a PTHrP and hedgehog loop (PTHrP causes proliferation and hedgehog encourages maturation and hypertrophy). A mutant PTHrP receptor delays differentiation augmenting hedgehog signaling, producing an abnormal proliferation of chondrocytes and the production of excess cartilage (enchondroma or synovial chondromatosis). Normally hedgehog regulates PTHrP in a loop. The PTHrP receptor is located only in the physis and not articular cartilage<sup>66,68</sup>.

Osteochondromatosis is genetically characterized by two genes, *EXT1* and *EXT2*, located at 8q24 and 11p11-12, respectively<sup>69,70</sup>. Both *EXT* genes are involved in a gene deletion syndrome. The patients carrying the deletion of 8q24 demonstrate Langer-Giedion syndrome (characterized by craniofacial dysmorphism, mental retardation and osteochondromas). Langer-Giedion syndrome is due to a loss of both functional copies of the *TRPS1* gene encoding a zinc finger protein and the *EXT1* gene at 8q24<sup>71,72</sup>. Patient's carrying a deletion of 11p11.2-p12 demonstrate Potocki-Shaffer syndrome (demonstrating osteochondromas and craniofacial dysostosis along with retardation). This syndrome is caused by deletion of *EXT2* and *ALX4*. The gene products of *EXT1* and *EXT2* form a complex that catalyzes heparin sulfate polymerization<sup>73,74</sup>. These form components of heparin sulfate proteoglycans that are large macromolecules composing the glycosaminoglycan chains linked to a protein core. It is hypothesized that *EXT* mutations affect Indian hedgehog signaling within the normal growth plate. Thus *EXT1* and *EXT2* are involved in heparin sulfate biosynthesis and elongation.

## CHORDOMA

Chordomas account for 8% of primary malignant bone tumors. They often present in the 6th decade of life. Sixty per cent occur in the sacrum, 25% occur in the base of the skull with the remainder occurring scattered within the mobile segments of the spine. Chordomas occur as notochord remnants.

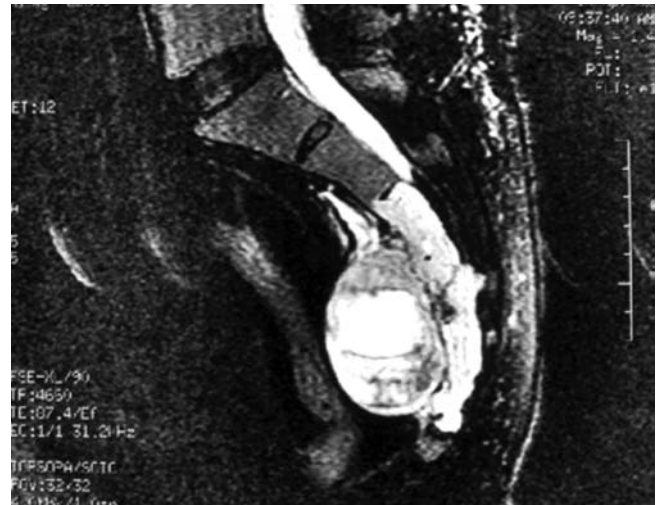


Figure 33.9 Sagittal MRI T2 of chordoma.

## Clinical features

Chordomas are typically solitary and central, and occur in vertebral bodies<sup>75,76</sup>. These tumors are slow-growing and present with a large extraosseous soft tissue mass that displaces surrounding structures as seen in Figure 33.9.

Chordomas are lobular tumors represented by sheets of cells floating in a myxoid matrix. These cells have abundant amounts of cytoplasm and are termed physaliferous cells<sup>77,78</sup>. Rarely chordomas have a cellular component that is high grade.

The prognosis for chordoma is directly related to margin-free resection. This is difficult in the sacrum and near-impossible to achieve at the base of the skull. In these instances, intralesional resection followed by radiotherapy can be effective<sup>79,80</sup>. Reconstruction following sacrectomy often is unnecessary if at least one sacral level remains.

## Cytogenetics

Chordoma has clonal chromosome aberrations with losses on chromosomes 3p and 1p most common<sup>81</sup>.

## REFERENCES

- Jemal A, Murray T, Ward E et al. Cancer Statistics, 2005. *CA Cancer J Clin* 2005; 55: 10–30.
- Simon MA, Aschliman MA, Thomas N et al. Limb-salvage treatment versus amputation for osteosarcoma of the distal end of the femur. *J Bone Joint Surg Am* 1986; 68: 1331–7.
- Mankin HJ, Hornicek FJ, Raskin KA. Infection in massive bone allografts. *Clin Orthop Relat Res* 2005; 432: 210–6.
- Enneking WF, Campanacci DA. Retrieved human allografts: a clinicopathological study. *J Bone Joint Surg Am* 2001; 83A: 971–86.
- Enneking WF. *Musculoskeletal Tumor Surgery*. New York: Churchill Livingstone, 1983: 3–60.
- Gitelis S, Williams R, Conrad EU III. Benign Bone Tumors. *J Bone Joint Surg Am* 1995; 77: 1756–82.
- Wetzel LH, Levine E, Murphey MD. A comparison of MR imaging and CT in the evaluation of musculoskeletal masses. *Radiographics* 1987; 7: 851–74.
- Peabody TD, Gibbs CP Jr, Simon MA. Evaluation and staging of musculoskeletal neoplasms. *J Bone Joint Surg Am* 1998; 80: 1204–18.
- Schulert M, Brecht-Krauss D, Werrer M et al. Evaluation of neoadjuvant therapy response of osteogenic sarcoma using FDG PET. *J Nucl Med* 1999; 40: 1637–43.
- Rougraff BT, Kneisl JS, Simon MA. Skeletal metastasis of unknown origin: a prospective study of a diagnosis strategy. *J Bone Joint Surg Am* 1993; 75: 1276–81.
- Greene FL, Page DL, Fleming ID et al. *American Joint Commission on Cancer Staging Manual*, 6th edn. New York: Springer-Verlag, 2002.
- Skrzynski MC, Biermann JS, Montag A et al. Diagnostic accuracy and charge savings of outpatient core needle biopsy combined with open biopsy of musculoskeletal tumors. *J Bone Joint Surg* 1996; 78A: 644–49.
- Mankin HJ, Mankin CJ, Simon MA. The methods of biopsy revisited. *J Bone Joint Surg Am* 1996; 78A: 656–63.
- Randall RL, Bruckner JD, Papenhausen MD et al. Errors in diagnosis and margin determination of soft tissue sarcoma initially treated at non-tertiary centers. *Orthopaedics*. 2004; 27: 209–212.
- Trovik CK. Scandinavian Sarcoma Group Project. *Acta Orthop Scand Suppl* 2001; 300: 1–31.
- Jemal A, Thomas A, Murray T. Cancer Statistics, 2002. *CA Cancer J Clin* 2002; 52: 23–47.
- Enneking WF, Spanier SS, Goodman MA. A system for the surgical staging of musculoskeletal sarcoma. *Clin Orthop Rel Res* 1980; 153: 106–20.
- Frassica FJ, Gitelis S, Sim FH. Metastatic bone disease: general principles, pathophysiology, evaluation and biopsy. *Instr Course Lect* 1992; 41: 293–300.
- Ries LAG, Kosary CL, Hankey BF et al. *SEER Cancer Statistics Review 1973–1996*. Bethesda, MD: National Cancer Institute, 1999.
- Dorffman HD, Czerniak B. Bone cancers. *Cancer* 1995; 75: 203–10.
- Dahlin DC, Unni KK. *Bone Tumors*. Springfield, IL: Charles C. Thomas, 1986.
- Malkin D, Li FP, Strong LC et al. Germ line p53 mutations in a familial syndrome of breast cancer, sarcomas and other neoplasms. *Science* 1990; 250: 1233–38.
- Li FP, Fraumeni JF, Mulvihill JJ et al. A cancer family syndrome in 24 kindreds. *Cancer Res* 1988; 48: 5358–62.
- Enneking WF, Kagan A. “Skip” metastases in osteosarcoma. *Cancer* 1975; 36: 2192–205.
- Picci P, Bacci G, Campanacci M et al. Histologic evaluation of necrosis in osteosarcoma induced by chemotherapy. Regional Mapping of viable and nonviable tumor. *Cancer* 1985; 56: 1515–21.
- Bridge JA, Nelson M, McComb E et al. Cytogenetic findings in 73 osteosarcoma specimens and a review of the literature. *Cancer Genet Cytogenet* 1997; 95: 74–87.
- Ferracini R, DiRenzo MF, Scotlandi K et al. The Met/HGF receptor is over-expressed in human osteosarcomas and is activated by either a paracrine or an autocrine circuit. *Oncogene* 1995; 10: 739–49.
- Wu JX, Carpenter PM, Gresens C et al. The proto-oncogene c-fos is over-expressed in the majority of human osteosarcomas. *Oncogene* 1990; 5: 989–1000.
- Guo W, Gorlick R, Ladanyi M et al. Expression of bone morphogenetic proteins and receptors in sarcomas. *Clin Orthop* 1999; 175–83.
- Draper GJ, Sanders BM, Kingston JE. Second primary neoplasms in patients with retinoblastoma. *Br J Cancer* 1986; 53: 661–71.
- Wadayama B, Toguchida J, Shimizu T et al. Mutation spectrum of the retinoblastoma gene in osteosarcomas. *Cancer Res* 1994; 54: 3042–408.
- McIntyre JF, Smith-Sorenson B, Farend SH et al. Germ line mutations of the p53 tumor suppressor gene in children with osteosarcoma. *J Clin Oncol* 1994; 12: 925–30.
- Rosen G, Marcove RC, Caparros B et al. Primary osteogenic sarcoma: the rationale for preoperative chemotherapy and delayed surgery. *Cancer* 1979; 42: 2163–177.
- Link MP, Goorin AM, Miser AW et al. The effect of adjuvant chemotherapy on relapse-free survival in patients with osteosarcoma of the extremity. *N Engl J Med* 1986; 314: 1600–6.
- Bacci G, Ferrari S, Bertoni F et al. Long term outcome of patients with nonmetastatic osteosarcoma of extremity. *J Clin Oncol* 2000; 18: 4016–27.
- Goorin AM, Schwartzentruber DJ, Devidas M et al. Pediatric oncology group. Presurgical chemotherapy combined with immediate surgery and adjuvant chemotherapy for nonmetastatic osteosarcoma. POG 8651. *J Clin Oncol* 2003; 21: 1574–80.
- Provisor AJ, Ettinger LJ, Nachman JB et al. Treatment of nonmetastatic osteosarcoma of the extremity with preoperative and postoperative chemotherapy. *J Clin Oncol* 1997; 15: 76–84.
- Souhami RL, Craft AW, VanderEijken JW. Randomised trial of two regimens of chemotherapy in operable osteosarcoma. *Lancet* 1997; 350: 911–17.
- Meyers PA, Heller G, Healey J et al. Chemotherapy for nonmetastatic osteogenic sarcoma. *J Clin Oncol* 1992; 10: 5–15.
- Bacci G, Picci P, Ferrari S et al. Primary chemotherapy and delayed surgery for nonmetastatic osteosarcoma of the extremities. *Cancer* 1993; 72: 3227–38.
- Glasser DB, Lane JM, Huvos AG et al. Survival, prognosis and therapeutic response in osteogenic sarcoma. *Cancer* 1992; 69: 698–708.
- Okada K, Frassica FJ, Sim FH et al. Parosteal osteosarcoma. A clinicopathological study. *J Bone Joint Surg Am* 1994; 76: 366–78.
- Aurias A, Rimbaut C, Buffe D et al. Chromosomal translocations in Ewing's sarcoma. *N Engl J Med* 1983; 309: 496–97.

44. deAlava E, Gerald WL. Molecular biology of the Ewing's sarcoma/primitive neuroectodermal tumor family. *J Clin Oncol* 2000; 18: 204–13.
45. Giovannini M, Biegel JA, Serra M et al. EWS-erg and EWS-Flt1 fusion transcripts in Ewing's sarcoma and primitive neuroectodermal tumors with variant translocations. *J Clin Invest* 1994; 94: 489–96.
46. Sorensen PH, Lessnick SL, Lopez-Terrada D et al. A second Ewing's sarcoma translocation, t(21;22), fuses the EWS gene to another ETS-family transcription factor, ERG. *Nat Genet* 1994; 6: 146–51.
47. Zucman J, Melot T, Desmaze C et al. Combinatorial generation of variable fusion proteins in the Ewing family of tumors. *EMBO J* 1993; 12: 4481–7.
48. Delattre O, Zucman J, Melot T et al. The Ewing family of tumors – a subgroup of small-round-cell tumors defined by specific chimeric transcripts. *N Engl J Med* 1994; 331: 294–9.
49. May WA, Gishizky ML, Lessnick SL et al. Ewing sarcoma 11;22 translocation produces a chimeric transcription factor that requires the DNA-binding domain encoded by FLI1 for transformation. *Proc Natl Acad Sci USA* 1993; 90: 5752–6.
50. Bailey RA, Bosselut R, Zucman J et al. DNA-binding and transcriptional activation properties of the EWS-FLI-1 fusion protein resulting from the t(11;22) translocation in Ewing sarcoma. *Mol Cell Biol* 1994; 14: 3230–41.
51. May WA, Lessnick SL, Braum BS et al. The Ewing's sarcoma EWS/FLI-1 fusion gene encodes a more potent transcriptional activator and is a more powerful transforming gene than FLI-1. *Mol Cell Biol* 1993; 13: 7393–8.
52. Krasin MJ, Davidoff AM, Rodrigues-Galindo C et al. Definitive surgery and multiagent systemic therapy for patients with localized Ewing's sarcoma family of tumors. *Cancer* 2005; 104: 367–73.
53. Bacci G, Forni C, Longhi A et al. Long term outcome for patients with non-metastatic Ewing's sarcoma treated with adjuvant and neoadjuvant chemotherapies. *European J Cancer* 2004; 40: 73–83.
54. Ohali A, Avigar S, Cohen IJ et al. Association between telomerase activity and outcome in patients with nonmetastatic Ewing's family of tumors. *J Clin Oncol* 2003; 21: 3836–43.
55. Unni KK. *Dahlin's Bone Tumors General Aspects and Data on 11,087 Cases*, 5th edn. Philadelphia: Lippincott-Raen, 1996.
56. Bjornsson J, McLeod RA, Unni KK et al. Primary chondrosarcoma of long bones and limb girdles. *Cancer* 1998; 83: 2105–19.
57. Sheth DS, Yasko AW, Johnson ME et al. Chondrosarcoma of the pelvis. Prognostic factors for 67 patients treated with definitive surgery. *Cancer* 1996; 78: 745–50.
58. Liu J, Hudkins PG, Sweet RG, Unni KK. Bone sarcomas associated with Ollier's disease. *Cancer* 1987; 59: 1376–85.
59. Schwartz HS, Zimmerman NB, Simon MA et al. The malignant potential of enchondromatosis. *J Bone Joint Surg Am* 1987; 69: 269–74.
60. Brien EW, Mirra JM, Kerr R. Benign and malignant cartilage tumors of bone and joint: their anatomic and theoretical basis with an emphasis on radiology, pathology and clinical biology. 1. The intramedullary cartilage tumors. *Skeletal Radiol* 1997; 26: 325–53.
61. Dickey ID, Rose PS, Fuchs B et al. Dedill CS: the role of chemotherapy. *J Bone Joint Surg* 2004; 86A: 2412–8.
62. Dabska M, Huvois AG. Mesenchymal chondrosarcoma in the young. *Virchows Arch A Pathol Anat Histopathol* 1983; 399: 89–104.
63. Nakashima Y, Unni KK, Shives TC et al. Mesenchymal chondrosarcoma of bone and soft tissue. A review of 111 cases. *Cancer* 1986; 57: 2444–53.
64. Collins MS, Koyama T, Sweet RG, Inwards CY. Clear cell chondrosarcoma: radiographic, CT ;#x00026; MRI findings in 34 patients with pathologic correlation. *Skeletal Radiol* 2003; 32: 687–94.
65. Mandahl N, Gustafson P, Mertens F et al. Cytogenetic aberrations and their prognostic impact in chondrosarcoma. *Genes Chromosomes Cancer* 2002; 33: 188–200.
66. Hopyan S, Gokgoz N, Poon R et al. A mutant PTH/PTHrP type 1 receptor in enchondromatosis. *Nat Genet* 2002; 30: 306–10.
67. Schipani E, Kruse K, Juppner H. A constitutively active mutant PTH-PTHrP receptor in Jansen-type metaphyseal chondrodysplasia. *Science* 1995; 268: 98–100.
68. Hopyan S, Nadesan P, Yu C et al. Dysregulation of hedgehog signaling predisposes to synovial chondromatosis. *J Pathol* 2005; 206: 143–50.
69. Ahn J, Ludecke HJ, Lindow S et al. Cloning of the putative tumor suppressor gene for hereditary multiple exostoses (EXT1). *Nat Genet* 1995; 11: 137–43.
70. Stickens D, Clines G, Burbee D et al. The EXT2 multiple exostoses gene defines a family of putative tumour suppressor genes. *Nat Genet* 1996; 14: 25–32.
71. Hou J, Parrish J, Ludecke HJ et al. A 4-megabase YAC contig that spans the Langer-Giedion syndrome region on human chromosome 8q24.1: use in refining the location of the trichorhinophalangeal syndrome and multiple exostoses genes (TRPS1 and EXT1). *Genomics* 1995; 29: 87–97.
72. Ludecke JH, Wagner MJ, Nardmann J et al. Molecular dissection of a contiguous gene syndrome: localization of the genes involved in the Langer-Giedion syndrome. *Hum Mol Genet* 1995; 4: 31–6.
73. Lind T, Tufaro F, McCormick C et al. The putative tumor suppressors EXT1 and EXT2 are glycosyltransferases required for the biosynthesis of heparin sulfate. *J Biol Chem* 1998; 273: 26265–8.
74. McCormick C, Duncan G, Goutsos KT et al. The putative tumor suppressors EXT1 and EXT2 form a stable complex that accumulates in the Golgi apparatus and catalyzes the synthesis of heparin sulfate. *Proc Natl Acad Sci USA* 2000; 97: 668–73.
75. Sundaresan N, Galicich JH, Chu FC et al. Spinal chordomas. *J Neurosurg* 1979; 50: 312–9.
76. Stephens GC, Schwartz HS. Lumbosacral chordoma resection. *J Surg Oncol* 1993; 54: 226–32.
77. Heffelfinger MJ, Dahlin DC, MacCarty CS et al. Chordomas and cartilaginous tumors at the skull base. *Cancer* 1973; 32: 410–20.
78. Kaiser TE, Pritchard DJ, Unni KK. Clinicopathologic study of sacrococcygeal chordoma. *Cancer* 1984; 53: 2574–8.
79. Stener B, Gunterberg B. High amputation of the sacrum for extirpation of tumors. Principles and technique. *Spine* 1978; 32: 926–39.
80. Bjornsson J, Wold LE, Ebersold MJ et al. Chordoma of the mobile spine. A clinicopathologic analysis of 40 patients. *Cancer* 1993; 71: 735–40.
81. Scheil A, Bruderlein S, Liehr T et al. Genome wide analysis of 16 chordomas by comparative genomic hybridization and cytogenetics of the first human chordoma cell line, U-CH1. *Genes Chromosomes and Cancer* 2001; 32: 203–11.
82. Patchell RA, Tibbs PA, Regine WF et al. Direct decompressive surgical resection in the treatment of spinal cord compression caused by metastatic cancer: a randomised trial. *Lancet* 2005; 366: 643–48.





# Neurosurgical oncology: neoplasms of the brain and meninges

34

Charles B Stevenson and Reid C Thompson

---

The past two decades have witnessed remarkable technological advances in imaging, surgical technique and adjuvant therapy for central nervous system (CNS) tumors. In a general sense, these innovative technologies, including the advent of magnetic resonance imaging (MRI), image-guided surgery and stereotactic radiosurgery, have all had a far-reaching impact on the overall approach to the management of intracranial tumors. For specific neurosurgical patient populations, such as those patients diagnosed with low grade gliomas or metastatic brain cancer, these advances have translated into significantly improved clinical outcomes. This chapter focuses on the classification, presentation and specific treatment options for the most common intracranial neoplasms, including both *intrinsic* tumors, or those arising from brain parenchyma (gliomas), as well as *extrinsic* neoplasms arising from non-neural tissue (e.g. meningiomas, pituitary adenomas). In addition, contemporary management strategies for patients with metastatic tumors to the brain are also discussed.

## GLIOMA

The term 'glioma' encompasses a diverse group of glial neoplasms arising from the brain's native astrocytes, oligodendrocytes and ependymal cells. Gliomas are the most common primary tumors of the brain, accounting for more than 70% of all newly diagnosed primary brain neoplasms<sup>1</sup>. Of these, tumors of astrocytic (astrocytomas) and oligodendroglial (oligodendrogliomas) origin together comprise the majority of gliomas and are the focus of this discussion. Because of their tendency to widely infiltrate adjacent brain tissue, astrocytomas and oligodendrogliomas are often referred to as *diffuse* glial neoplasms. The World Health Organization (WHO) has created a four-tiered neuropathological grading scheme used for classifying diffuse glial tumors according to specific histological criteria (Table 34.1)<sup>2</sup>. The WHO system grades features such as nuclear atypia, mitotic index, extent of microvascular proliferation, and presence or absence of necrosis within a tumor and serves to

outline a spectrum of histological progression for gliomas, ranging from least aggressive (grade I) to most aggressive (grade IV)<sup>3</sup>. In practice, this classification system is used by clinicians to distinguish between two very different groups of tumors in terms of clinical behavior and treatment considerations: low grade (grades I/II) and high grade (grades III/IV) gliomas.

## Low grade gliomas

### *Classification and incidence*

Low grade gliomas (LGG) comprise a heterogeneous group of tumors found most commonly in children and young adults. As their name suggests, LGG exhibit more benign histological features and in general portend a more favorable outcome than their high grade counterparts. However, the designation of LGG encompasses two different classes of tumors, each with its own unique biological behavior, prognosis and treatment. Pilocytic astrocytomas (WHO grade I) represent approximately 5–6% of primary brain tumors, with an incidence rate of approximately 0.4 cases per 100 000 of the population per year<sup>4</sup>. These tumors have relatively distinct margins, making them generally amenable to gross total resection. They exhibit essentially benign behavior, and once resected, seldom recur. Pilocytic astrocytomas have only rarely been reported to progress to a more malignant phenotype.

Conversely, WHO grade II astrocytomas and oligodendrogliomas are diffuse, infiltrative lesions that, because of their invasive nature, invariably recur, often as a higher grade of malignancy, and so carry a worse prognosis than pilocytic astrocytomas. Combined, these tumors comprise roughly 11.5% of primary brain tumors reported, with approximately 0.6 new cases of per 100 000 of the population per year when adjusted to the European Standard Population<sup>1</sup>. Grade II tumors form a continuum of disease with the more malignant grade III and grade IV tumors, frequently progressing to a higher grade years after the original diagnosis. The median survival of patients with

**Tabel 34.1** World Health Organization (WHO) grading system for diffuse astrocytic and oligodendroglial tumors

*Grade I*

Pilocytic astrocytoma

biphasic histological pattern consisting of microcystic regions of loosely knit stellate astrocytes, and dense sheets of compact, elongated cells often containing Rosenthal fibers

nuclear atypia and microvascular proliferation may be present, but are not necessarily adverse prognostic indicators

*Grade II*

Astrocytoma

composed of well differentiated fibrillary (most common), protoplasmic, giant cell, or gemistocytic astrocytes

little cellularity

minimal pleomorphic changes

mitotic figures absent

*Oligodendroglioma*

consist of well differentiated oligodendrocytes

no endothelial proliferation or necrosis

minimal atypia

mitoses rare or absent

*Grade III*

Anaplastic astrocytoma

increased cellularity and pleomorphic features

mitotic figures present

no necrosis

Anaplastic oligodendroglioma

hypercellular

nuclear atypia present

mitotic figures and microvascular proliferation common

*Grade IV*

Glioblastoma multiforme

highly cellular with marked pleomorphism

abundant microvascular proliferation

frequent mitoses

areas of 'pseudopalisading' necrosis are a hallmark finding but not required for diagnosis

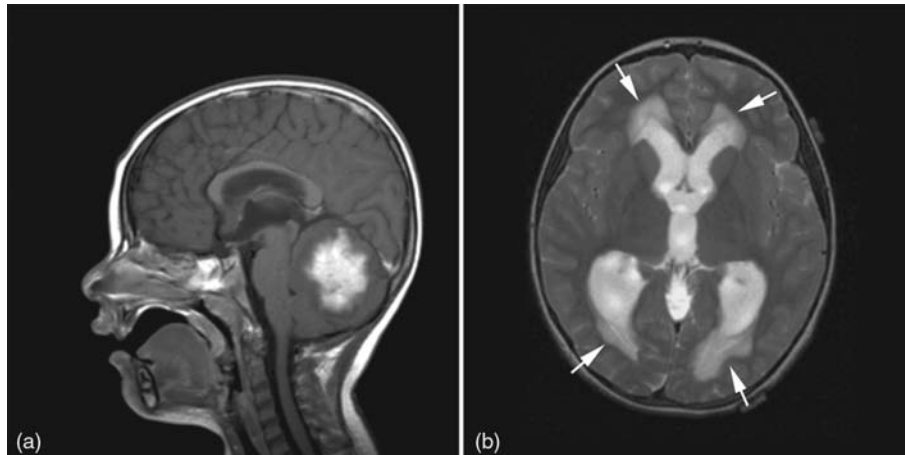
Adapted from reference 2.

grade II astrocytomas ranges from 6 to 8 years, while patients with grade II oligodendrogliomas survive an average of 10 years following diagnosis.

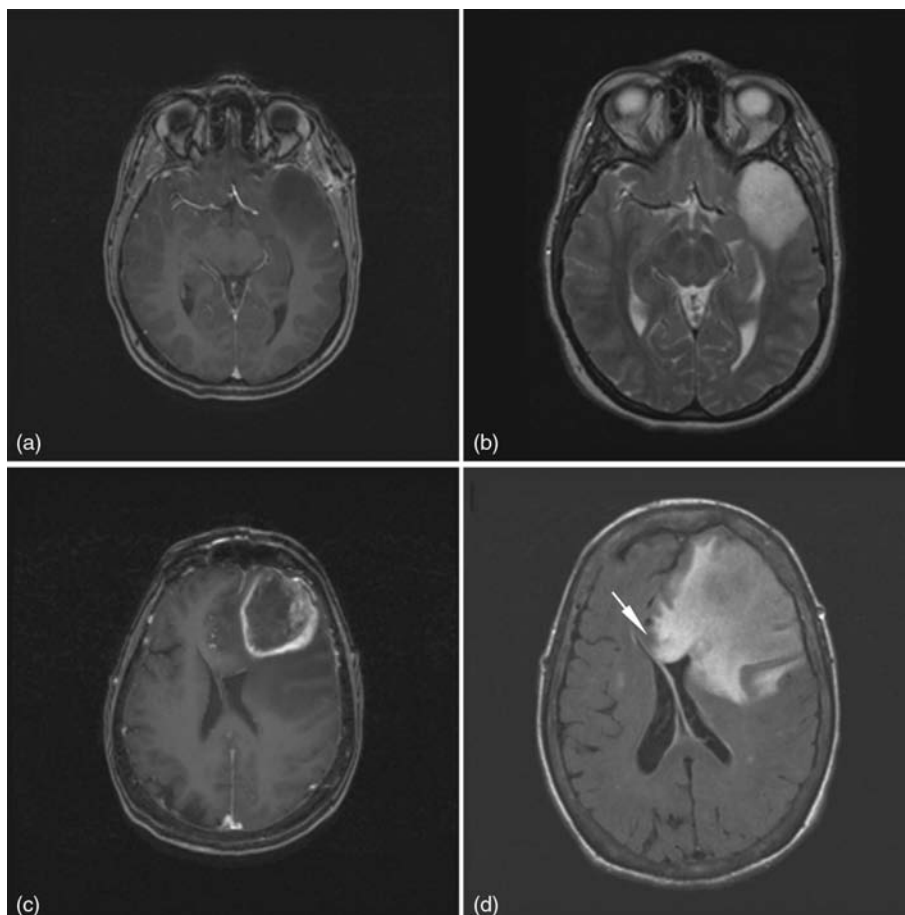
*Clinical presentation and neuroimaging*

Pilocytic astrocytomas tend to occur in children and adolescents, with a peak incidence between 10 and 20 years of age<sup>5</sup>. They may arise throughout the neuraxis, such as the optic apparatus and hypothalamic region, brainstem, or in the cerebral hemispheres, but they most commonly occur in the cerebellum (40%)<sup>4</sup>, where they present with signs and symptoms of increased intracranial pressure (ICP) due to hydrocephalus resulting from obstruction of flow of cerebrospinal fluid (CSF) through the cerebral aqueduct and fourth ventricle. A constellation of headache, nausea, vomiting, gait ataxia, diplopia, and papilledema in a child mandates immediate neuroimaging to evaluate for hydrocephalus and a potential posterior fossa tumor. Due to the non-epileptogenic nature of the cerebellum, these patients rarely present with seizures. On computed tomography (CT) or MRI, pilocytic astrocytomas located in the cerebellum or cerebral hemispheres typically appear as well-circumscribed, contrast-enhancing lesions comprised of a compact mural nodule and tumor-associated cyst (Figure 34.1). Pilocytic astrocytomas located elsewhere also appear as discrete, enhancing lesions, but generally lack the associated cyst present in the 'classic' radiographic appearance of the cerebellar form. These lesions most often have little or no surrounding cerebral edema.

WHO grade II astrocytomas and oligodendrogliomas are generally tumors of young adulthood, with a peak incidence in the 3rd – 4th decade of life<sup>6,7</sup>. These tumors characteristically present with new-onset seizures. Less commonly, patients may present with focal neurological deficits such as hemiparesis, behavioral and personality changes, visual loss, or speech disturbance, due to mass effect or invasion of surrounding brain parenchyma<sup>8</sup>. Grade II gliomas have a predilection for the temporal, posterior frontal, and anterior parietal lobes<sup>5</sup> and generally have less straightforward imaging features than their more benign pilocytic counterparts. On CT these lesions appear as hypodense or isodense masses with minimal or no enhancement and very little local mass effect. Oligodendroglial tumors may sometimes contain a significant calcified component appearing as a diffuse hyperdensity on CT. Grade II LGG typically appear as low-intensity, non-enhancing masses on T1-weighted MR imaging, with high-intensity signal changes and indistinct borders on T2-weighted imaging (Figure 34.2a and b). As such, these tumors are often referred to as 'T2 lesions' based on the observation that they are best appreciated on T2-weighted images or fluid-attenuated inversion recovery (FLAIR) sequences.



**Figure 34.1** (a) Sagittal gadolinium-enhanced magnetic resonance (MR) image of a cerebellar pilocytic astrocytoma in a child. Note that the tumor is comprised of a large enhancing nodule as well as a surrounding cyst. (b) Axial T2-weighted MR image demonstrating obstructive hydrocephalus in the lateral and third ventricles with transependymal resorption of cerebrospinal fluid (arrows) resulting from compression of the cerebral aqueduct by the large cerebellar tumor.



**Figure 34.2** Axial gadolinium-enhanced (a) and T2-weighted (b) magnetic resonance (MR) images of a left temporal lobe WHO grade II astrocytoma demonstrating the characteristic imaging features of these low grade lesions. The tumor does not exhibit any appreciable enhancement following gadolinium administration, nor does it have any significant cerebral edema or mass effect associated with it on T2 images. (c) Typical postcontrast axial T1-weighted view of a left frontal lobe glioblastoma (WHO grade IV) illustrating the classic 'ring-enhancing' pattern of these tumors. Glioblastomas are often associated with a significant amount of cerebral edema and mass effect as demonstrated by the compression and distortion of the lateral ventricles in the corresponding FLAIR image (d). Note that the tumor tracks along the corpus callosum (arrow in (d)) and infiltrates the contralateral hemisphere.

## Management

Advances in microneurosurgery, use of intraoperative image-guided navigation systems, and the relatively benign biological behavior of pilocytic astrocytomas often allow for a gross total surgical resection, which is the treatment of choice for these lesions. Long-term survival data for patients with surgically resected pilocytic astrocytomas are generally excellent: 100% survival at 5 years and more than 95% at 10 years representing average outcomes<sup>4</sup>. Interestingly, recent studies have failed to demonstrate a role for routine postoperative radiotherapy of pilocytic astrocytomas<sup>4</sup>. Instead, reoperation following initial partial resection or for tumor recurrence has been shown to yield long-term survival and cure rates comparable with those observed with gross total resection at the time of first surgery. Due to the lack of any demonstrable survival benefit of routine radiotherapy following surgery for pilocytic tumors, it is now considered a reasonable strategy to observe these patients, particularly children, following surgery, even if a subtotal resection has been performed<sup>9,10</sup>.

Because most patients diagnosed with diffuse grade II astrocytomas and oligodendrogliomas are relatively young and neurologically normal, determining an optimal treatment course can be quite challenging. Indeed, their management is controversial. As discussed earlier, a minority of patients will present with hemiparesis, impaired cognitive function, or other significant neurological deficit, generally due to a large tumor with considerable mass effect. These patients are immediately treated with maximal surgical resection followed by radiotherapy to the involved region. However, for those patients presenting with an isolated seizure and no symptoms from mass effect, the role of surgery in the treatment of these tumors is less clear. Arguments against aggressive surgical resection include the potential morbidity associated with surgery, particularly when the tumor is located in a critical area involving motor or language function. Moreover, the knowledge that the indolent growth rate of these tumors allows many patients to live symptom free for a considerable amount of time, sometimes several years while deferring treatment, lends support to a conservative approach to managing these lesions. Thus, many have proposed that until there is clear evidence of progressive neurological symptoms or documented tumor progression on serial imaging studies, no treatment may be just as beneficial as early treatment<sup>6,11</sup>. Nevertheless, it is also a reasonable approach to perform early surgery on those low grade tumors located in safely accessible regions of the brain with the intent of achieving an 'image-complete resection'. The timing and extent of surgical resection for these tumors remain controversial, however, largely due to the lack of randomized clinical trials that address these issues.

Unfortunately, the ability to accurately diagnose grade II gliomas on the basis of CT or MRI appearance alone is limited<sup>12</sup>. Thus, an important concept in the management of diffuse low grade tumors is safely establishing a tissue diagnosis with a biopsy<sup>13</sup>. This is particularly important in cases in which a suspected grade II glioma has abnormal imaging characteristics, such as an area of enhancement, that might be suggestive of a higher grade tumor. Generally, a stereotactic-guided biopsy can be performed with minimal risk and can provide valuable diagnostic information to guide therapy.

Radiation therapy is currently the most effective non-surgical treatment for grade II gliomas. Several multicenter trials have demonstrated improved survival and superior quality of life in patients receiving external beam radiation at a dose between 45.0 and 50.4 Gy<sup>14</sup>. However, the timing of radiotherapy for grade II gliomas, either immediate or deferred until clinical progression, has been the subject of intense investigation. Studies have now shown that while early radiotherapy, administered immediately following surgery or biopsy, significantly delays the time to progression of tumor when compared with deferred radiotherapy, it does not affect overall survival time<sup>15</sup>. Thus, many neuro-oncologists now favor following patients with newly diagnosed LGG while deferring radiation therapy until there is clear evidence of radiographic or clinical progression.

Early trials utilizing chemotherapy for the treatment of grade II gliomas failed to show a significant benefit to therapy, and until recently there was no indication for the routine use of chemotherapy in the treatment of these tumors. However, recognition in the 1990s that oligodendroglial tumors with loss of heterozygosity (LOH) at chromosomes 1p and 19q are sensitive to regimens of procarbazine and vincristine quickly brought chemotherapy to the forefront of therapy for these tumors<sup>16</sup>. LOH for 1p and 19q has been demonstrated in up to 40% of patients with newly diagnosed low grade oligodendrogliomas, and presence of this phenotype has been found to delineate a favorable prognostic subset of patients regardless of therapy type, with 5-year survival rates of up to 95% observed for patients with tumors harboring those deletions versus 65% for those without<sup>17</sup>. While chemotherapy is not curative in these patients, it does produce sustained remissions with survival times equivalent to treatment with radiotherapy. Similarly, grade II astrocytomas, traditionally regarded as chemoresistant, are now being shown to respond to newer chemotherapeutic agents. Recent evidence has suggested that treatment with temozolomide, an oral alkylating agent, may be efficacious for low grade gliomas, both astrocytomas as well as oligodendrogliomas<sup>18</sup>. As such, temozolomide is being increasingly employed in the management of grade II gliomas.

## High grade gliomas

### *Epidemiology*

Malignant, or high grade, gliomas (HGG) are by far the most common primary brain tumors, occurring in 6–7 per 100 000 of the population per year in the US<sup>19</sup>. As a group, HGG are comprised of anaplastic astrocytoma (AA), anaplastic oligodendroglioma (AO) and glioblastoma multiforme (GBM). GBM, the most malignant primary brain tumor, accounts for over 80% of all HGG. The male to female ratio among affected patients is about 3 : 2, and most HGG are sporadic, although they are occasionally associated with genetic syndromes such as neurofibromatosis (type 1 and 2) and Li-Fraumeni syndrome. The peak age of onset for anaplastic tumors (AA and AO) is during the 4th or 5th decade, while GBM generally presents in the 6th or 7th decade. Prior exposure to ionizing radiation is the only unequivocal risk factor that has been identified for malignant gliomas, but this accounts for only a small percentage of patients. The effects of cellular telephone use and exposure to high-tension power lines have received considerable attention in the media for their purported association with brain tumor formation; however, numerous studies have failed to establish any definitive links.

### *Molecular pathogenesis*

Although a comprehensive review of the molecular pathogenesis of malignant gliomas is beyond the scope of this chapter, a brief discussion will serve to demonstrate how study of the cellular pathways of this disease has led to the development of new treatment strategies and how genetic differences have helped define distinct subsets of malignant glioma not evident by routine histopathology. GBMs can arise *de novo* (primary GBM) or may progress from lower grade precursors (secondary GBM). It is generally believed that the two types of GBM arise through different molecular pathways. Primary GBMs are associated with a high rate of overexpression and mutation of the epidermal growth factor receptor (EGFR), *p16* deletions and mutations in the gene for phosphate and tensin homologues (*PTEN*). EGFR overexpression is perhaps the most common molecular aberration seen in GBM, with approximately 40–60% of primary GBMs exhibiting some degree of amplification or overexpression of wildtype EGFR or EGFRvIII, a truncated EGFR isoform that is constitutively active in these tumors. Interestingly, EGFR overexpression is very rare in secondary GBMs. Conversely, secondary GBMs commonly have genetic alterations of the *p53* tumor suppressor gene, while primary GBMs rarely display *p53* mutations. These two pathways indicate that the glioblastoma phenotype can arise by at least two distinct mechanisms and

demonstrate how alterations in different genetic pathways can lead to common histological endpoints.

In addition to these well characterized pathways, proteomic and genomic analysis of HGG have identified mutations in several other genes, including the cyclin-dependent kinases, fibroblast growth factor and platelet-derived growth factor and its receptor. Abnormalities in angiogenic factors, such as vascular endothelial growth factor, and in factors promoting glioma invasion, including various matrix metalloproteinases and chemokine receptors, have also been characterized. The ultimate goal of such work is to create a molecular classification system for HGG that discriminates between distinct genetic abnormalities in different tumors, giving a far more detailed and comprehensive picture of a tumor's biology than histology alone. Profiling tumor heterogeneity through gene expression and proteomic analysis has already been shown to identify specific subsets of HGG with similar molecular signatures, and these signatures have been used to accurately predict patient survival<sup>20,21</sup>. Molecular profiling will also inevitably lead to significant breakthroughs in targeted therapies for HGG, allowing physicians to accurately tailor therapy based on a tumor's genetic or pathway-specific abnormalities. Clinical trials evaluating EGFR inhibitors have demonstrated some benefit for subsets of GBM patients<sup>22</sup>, paving the way for future development of molecular-specific therapies for HGG.

### *Clinical presentation and imaging*

Patients presenting with malignant gliomas generally have predictable but often non-specific signs and symptoms. In contrast to patients harboring LGG, patients with HGG frequently experience symptoms of increased intracranial pressure secondary to the considerable mass effect of these aggressive tumors. Nausea and vomiting, visual disturbance, and even diminished level of consciousness are all common. Many patients complain of headache which is classically described as being worse upon awakening in the morning and ameliorated with sitting upright or with the administration of corticosteroids. Approximately 20% of patients with HGG experience global, poorly localized neurological deficits such as behavior change or cognitive decline which is generally first noticed by family members. In addition, approximately one-third of patients with HGG present with new-onset seizures.

Malignant gliomas often have a characteristic MRI appearance that is virtually diagnostic. Following gadolinium administration, GBM frequently demonstrates ring enhancement around a central T1 hypointense region representing necrosis (Figure 34.2c). T2 and FLAIR sequences reveal extensive signal changes extending beyond the borders suggested on contrasted images, indicating the presence

of both cerebral edema as well as infiltrative disease disseminated from the main tumor mass (Figure 34.2d). As a result of large tumor size and significant surrounding edema, these tumors, unlike LGG, demonstrate a considerable degree of mass effect, distorting local anatomy and shifting structures across the midline. In addition, careful inspection of T2- and FLAIR-weighted images will often reveal the presence of tumor migrating across white matter tracts into the contralateral hemisphere, a poor prognostic sign (Figure 34.2d). In recent years, magnetic resonance spectroscopy (MRS) has been used increasingly to obtain metabolic information about brain tumors beyond what is provided by anatomic images. MRS involves measuring the relative quantities of a variety of metabolites in a tumor compared with adjacent normal brain parenchyma. MRS spectral patterns of such metabolites, including *N*-acetylaspartate, choline, creatine, and lactate, have been shown to be distinct for different tumor types and grades. MRS can be particularly useful for HGGs, which typically show generously elevated levels of choline, a marker for increased rate of cell turnover, as well as reduced levels of *N*-acetylaspartate, a normal neuronal marker. In areas of necrosis, often found centrally within HGG, all metabolites may be reduced.

### Treatment

Currently, the treatments for anaplastic astrocytoma and GBM are identical. Surgical resection is often the initial intervention, with gross total removal of the tumor being the goal. Although it seems intuitive that maximal tumor resection at the time of surgery would be beneficial to patients, there remains some debate as to whether aggressive surgical resection of HGG is associated with prolonged survival, largely due to a lack of prospective, randomized trials examining total versus partial resection. However, there is enough evidence suggesting longer survival with gross total excision so that maximal safe tumor resection generally remains the goal of neurosurgeons and neuro-oncologists alike<sup>23,24</sup>. Furthermore, prolonged survival is not the sole benefit nor is it the only therapeutic goal for HGG resection. Patients with HGG often have rapidly declining neurological function as a result of the significant mass effect of their tumor. Thus, reducing mass effect is an important objective of surgery, with approximately 50% of patients demonstrating improved neurological function following surgery for HGG<sup>25</sup>. Finally, craniotomy for tumor resection offers the opportunity for implantation of local chemotherapeutic agents. Lining the resection cavity with biodegradable bis-chloroethyl-nitroso-urea (BCNU)-impregnated wafers has been shown to confer a survival benefit for patients with recurrent malignant gliomas<sup>26</sup>.

Following surgery, all patients with HGG should receive external beam radiotherapy to the affected area up to a total dose of 60 Gy. In addition, in 2005 the results of a landmark clinical trial indicated a significant survival benefit for patients receiving concomitant postoperative radiotherapy and chemotherapy with temozolomide, an oral alkylating agent<sup>27</sup>. In this randomized trial, patients with newly diagnosed GBM were assigned to receive postoperative radiotherapy alone or radiotherapy plus continuous daily temozolomide over a period of 6 weeks. Patients in the latter group also received six cycles of adjuvant temozolomide following radiotherapy. The 2-year survival rate was 26.5% with radiotherapy plus temozolomide and 10.4% with radiotherapy alone, with minimal additional toxicity found in the combined therapy group. Concurrent administration of radiotherapy plus temozolomide has now become standard of care for all patients diagnosed with anaplastic astrocytoma and GBM.

Like malignant astrocytic tumors, anaplastic oligodendrogliomas are initially treated with extensive resection if feasible. Initiation of treatment with a regimen of procarbazine, lomustine and vincristine, or with oral temozolomide usually follows, as AO have rate of response (>70% of newly diagnosed AO patients) to chemotherapy, regardless of 1p and 19q gene deletion status. Radiotherapy is also employed, although many physicians choose to use it only after progression of the tumor on chemotherapy, thereby saving it as salvage therapy for recurrent tumor.

Despite aggressive treatment, the prognosis for patients with HGG remains poor. Patients with AO have a median survival of 3–5 years, while patients diagnosed with AA have a median survival of about 3 years. For patients with GBM, median survival remains abysmal at approximately 12–15 months following diagnosis, a figure that has not changed significantly in 25 years. In general, longer-term survivors are young, in good health and able to undergo gross total resection of their tumor as well as tolerate radiotherapy and multiple courses of chemotherapy.

### Summary and future directions

For pilocytic astrocytomas, surgical therapy may be curative. Higher grade tumors are infiltrative in nature and difficult to treat. The major cause of morbidity with grade II diffuse gliomas, particularly astrocytomas, is dedifferentiation, or malignant transformation, to a higher grade tumor. Patients with malignant gliomas (grades III and IV) continue to have a poor prognosis despite aggressive treatment. Further molecular characterization of these tumors should lead to the development of more efficacious treatment strategies, such as molecular-specific chemotherapeutic agents, immunotherapy and stem cell therapies. New treatment strategies on the horizon include development

of targeted immunotherapeutic approaches with vaccine development. While drug delivery to the central nervous system continues to present a challenge, important recent advances aim to effectively bypass the blood–brain barrier. One of these technologies, convection-enhanced delivery, utilizes an array of microcatheters implanted within the brain at surgery to deliver therapeutic agents directly into the brain at or near the tumor resection bed. This strategy is currently being employed in many early phase clinical trials and will facilitate testing of novel agents that do not readily cross the blood–brain barrier.

## METASTATIC BRAIN CANCER

The past two decades have been marked by significant advances in the management of cerebral metastases, allowing patients to enjoy longer survival and overall better quality of life. Despite these improvements, however, survival for patients with brain metastases remains limited: approximately 1 month median survival for untreated patients, 3–6 months for those receiving whole brain radiation therapy (WBRT) alone, and approximately 14–16 months for those undergoing local treatment (surgical resection or radiotherapy) plus WBRT, with the majority of patients ultimately dying from progression of their systemic disease<sup>28–32</sup>.

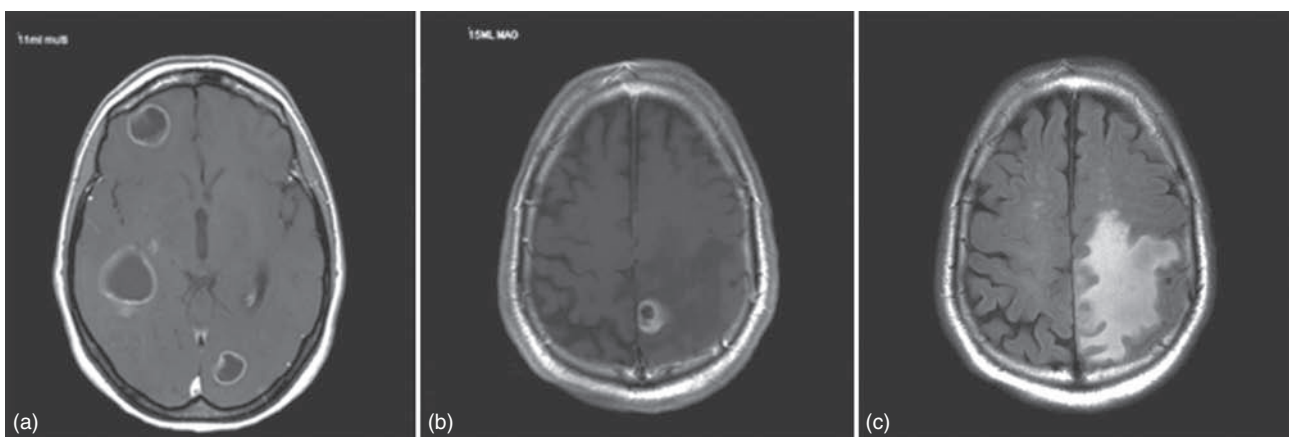
### Incidence, distribution and dissemination of brain metastases

Metastases to the brain are the most common brain tumors encountered clinically<sup>5</sup>. It is estimated that between 170 000 and 300 000 new cases of cerebral metastases are diagnosed each year in the US<sup>32</sup>, with epidemiologic data suggesting a trend towards increasing incidence. This rise may represent an overall increase in cancer incidence in an

aging population, as well as reflect recent improvements in the treatment of systemic cancer, prolonging survival and thereby allowing brain metastases to become clinically apparent in patients who previously would have succumbed to progression of their extracranial disease<sup>5,34,35</sup>. Indeed, it is estimated that 20–40% of cancer patients will develop metastatic disease in the CNS at some point during their course. Most metastatic brain tumors arise from hematogenous dissemination of cancerous cells that enter the CNS in areas where narrowing of cerebral vasculature and slowed blood flow are more conducive to seeding of tumor microemboli<sup>36</sup>. For this reason, brain metastases are frequently located at the gray–white matter junction and vascular border zones, with approximately 80% of lesions found in the cerebral hemispheres (Figure 34.3), 15% in the cerebellum and 5% in the brainstem<sup>37,38</sup>. The distribution of specific tumor types among metastatic lesions corresponds with that of systemic neoplasms in the general population, such that lung cancer and breast cancer (the two most common sites of primary tumors), when combined with melanoma, account for nearly two-thirds of all brain metastases<sup>39</sup>.

### Role of surgery in the treatment of brain metastases

The benefit of surgery in the treatment of brain metastases was first validated by Patchell *et al.*<sup>30</sup> in 1990 in a trial that randomized patients with a single metastasis to either surgery plus WBRT or needle biopsy plus WBRT. This study showed that the addition of surgery greatly improved not only median survival time (40 weeks versus 15 weeks;  $p < 0.01$ ), but also yielded longer functional independence in those patients undergoing surgery compared with those receiving WBRT alone (38 weeks versus 8 weeks;  $p < 0.005$ ). Thus, surgical resection has become the treatment of



**Figure 34.3** (a) Axial gadolinium-enhanced magnetic resonance (MR) image of multiple cystic ring-enhancing metastases in a patient with small cell lung cancer. (b) Contrast-enhanced and (c) FLAIR views of a small convexity metastasis. Even relatively small metastatic tumors are often associated with a tremendous degree of cerebral edema, a hallmark of these lesions.



choice for most patients with cerebral metastases, particularly those who are relatively young, exhibit satisfactory functional status as assessed by the Karnofsky performance scale (KPS) score, and have a single and surgically accessible tumor with either stable or absent extracranial disease. These factors have all been shown to successfully predict those patients likely to benefit from surgery<sup>40</sup>. Conversely, patients with multiple metastases, poor functional status, tumors in or adjacent to eloquent cortex, or uncontrolled extracranial disease have historically been considered poor candidates for aggressive surgical treatment, as it was thought they would likely die before obtaining any potential benefit from surgery<sup>40,41</sup>.

However, improvements in the management of systemic disease, in addition to advances in neurosurgical technique, are changing the way neurosurgeons approach metastatic disease, resulting in treatment protocols that are more aggressive. Image-guided surgery, functional neuronavigation, cortical mapping, and the ability to perform awake craniotomies for functional localization are now standard technologies available at most medical centers. Together these surgical adjuncts have allowed surgeons to resect multiple tumors, larger tumors and tumors adjacent to deep or eloquent sites, all with a higher margin of safety and better patient outcomes<sup>40,41</sup>. Several studies, for example, have reported similar survival in patients in whom multiple brain metastases were resected and a matched control group of patients undergoing resection of a single metastasis. Although a randomized trial remains to be performed, these data suggest that the presence of multiple metastatic lesions should no longer be considered an automatic contraindication to craniotomy<sup>40,42</sup>. As the technology of neurosurgery continues to progress, so too will the ability of neurosurgeons to optimize surgical approaches and achieve gross total resection of multiple, complex lesions with minimal morbidity.

There are additional factors in the clinical presentation that should be identified when considering patients who might benefit from resection but who do not meet the traditional 'standard criteria' outlined above. Surgical resection continues to be the preferred treatment in cases where tumors result in significant mass effect and when tumor resection is necessary to provide immediate relief from symptoms of raised intracranial pressure<sup>40</sup>. Surgical resection confers an added benefit in the reduction of edema that is commonly associated with metastatic lesions in the brain. Often, surgery alone can significantly improve a patient's quality of life, restoring some measure of their functional independence and permitting them to be managed without prolonged courses of high-dose corticosteroids. Similarly, patients with tumors causing medically refractory seizures might benefit from surgery as opposed to WBRT or radiosurgery. Surgery is also indicated for

patients with an unknown primary tumor or a suspected primary tumor that may be difficult to biopsy. In these cases surgery can provide accurate histological diagnosis which can, in turn, be critical to staging and optimal systemic work-up and treatment planning. Finally, resection has an increasingly important role in the treatment of recurrent metastases. Surgery not only improves both survival and quality of life in patients with recurrent disease<sup>43,44</sup>, it also provides an opportunity to utilize emerging localized therapies such as brachytherapy and implantable chemotherapy.

### Whole brain radiation therapy and stereotactic radiosurgery for brain metastases

WBRT has been the mainstay of therapy for patients with brain metastases for more than 50 years, providing symptomatic relief, improving neurological function and extending median survival in most patients<sup>45,46</sup>. While it remains the standard palliative treatment for patients with cerebral metastases that are too numerous or too disseminated for effective surgery or radiosurgery<sup>47</sup>, WBRT also has a proven role in preventing recurrence of intracranial disease in patients who have had prior surgery to resect a metastatic lesion. In 1998 Patchell *et al.*<sup>29</sup> conducted a randomized phase III study to determine the benefit of post operative WBRT in patients with a single brain metastasis. Following resection of their metastatic tumor, patients either received WBRT or no further treatment (observation) for their intracranial disease. The trial was not adequately powered to detect a survival difference in the two treatment groups; however, the rate of neurological death, local recurrence and recurrence of tumor anywhere in the brain were all nearly four-fold less frequent in the WBRT cohort than in the observation group, establishing surgical resection followed by WBRT as a more effective treatment for control of local and regional metastatic brain disease compared with surgery alone<sup>46</sup>.

Despite this, there are a number of arguments against the use of WBRT as part of routine treatment protocols. Like all therapeutic modalities, WBRT is not without risk. Late complications (defined as occurring more than 90 days after treatment) can be quite debilitating and include radiation necrosis of cerebral white matter, personality and memory changes, and neurocognitive deficits<sup>28,46</sup>. Unfortunately, there are few data from prospective, controlled trials available to guide treatment decision-making. DeAngelis *et al.*<sup>48</sup> reported an 11% rate of dementia following administration of WBRT in a small study, but several patients experiencing these side-effects had received total radiation doses greater than the current standard of 30 Gy over 10 fractions. More recently, Penitzka *et al.*<sup>49</sup> reported that they were unable to demonstrate a significant decline in cognitive function following WBRT and concluded

that such deficits were likely present before WBRT, a result of previous treatments, or of tumor burden itself. When balanced against the potential adverse cognitive effects seen with uncontrolled metastatic disease, the risk of permanent neurological complications from WBRT is generally considered low, particularly when current dose parameters and fractionation schemes are employed<sup>46</sup>.

Because of the great concern regarding side-effects of cranial irradiation, the past two decades have seen significant development and refinement of techniques for delivering precise, focal radiation therapy to brain tumors<sup>46</sup>. Stereotactic radiosurgery (SRS) generally refers to the use of either high-energy X-rays from a linear accelerator (LINAC) or multiple convergent gamma rays from a commercial cobalt-60 containing device, known as a Gamma Knife (Leksell Gamma Knife®, Elekta Instrument AB, Inc., Stockholm, Sweden), to provide a high dose of radiation to a small area of the brain in a single treatment while minimizing exposure to surrounding normal brain tissue. In addition to sparing non-neoplastic tissue, SRS also has the advantage of providing higher focal doses to target lesions than conventional radiotherapy and has proven a valuable tool against tumors traditionally considered to be 'radioresistant', including melanoma, renal cell carcinoma and sarcoma<sup>50,51</sup>. However, SRS is limited to treatment of tumors less than 3 cm in diameter, and the incidence of adverse neurological effects after SRS ranges from 5 to 15%, with an increased incidence of transient or permanent neurological deficit when the target lesion is adjacent to eloquent tissue<sup>28,52</sup>.

Although there are no class I data comparing the efficacy of SRS to WBRT, prospective, randomized trials by Kondziolka *et al.*<sup>53</sup> and the Radiation Therapy Oncology Group (RTOG)<sup>28</sup> examined the use of SRS as a boost to WBRT in patients with fewer than four metastases. In both studies the addition of SRS to WBRT was more effective than WBRT alone, significantly improving local brain tumor control and improving performance for all patients. Moreover, SRS following WBRT was not associated with increased risk for complications in either study. These compelling data suggest that optimal radiation treatment of patients with one to three brain metastases may consist of a multimodal approach involving a combination of WBRT plus SRS boost<sup>46,54</sup>. Furthermore, SRS has recently been suggested as an alternative to surgery in patients with good KPS score, limited extracranial disease and a manageable number of intracranial tumors that can be delineated with certainty<sup>46</sup>. Retrospective studies have demonstrated that SRS is comparable with surgery for patients with solitary metastatic tumors in terms of median survival, local failure rate and duration of functional independence<sup>55,56</sup>. An ongoing phase III randomized, prospective trial conducted by the European Organization for Research and Treatment

of Cancer (EORTC 22952) is currently comparing surgery and SRS, with or without the use of adjuvant WBRT, to examine the role for replacing surgery with SRS in selected patients with metastatic brain cancer<sup>57</sup>.

## Summary and future directions

As improved control of systemic disease allows patients to live longer, new and recurrent brain metastases will become more common. Surgery, WBRT and radiosurgery continue to represent the first-line therapies for most patients; however, with ongoing technological improvements and refinements, the optimal role of each of these modalities in the treatment of patients with metastatic brain cancer remains to be elucidated. Currently, surgical resection followed by WBRT and/or SRS to the tumor bed is the treatment of choice for most patients presenting with a solitary, surgically accessible metastasis or symptomatic metastasis with mass effect (Figure 34.4)<sup>54</sup>. However, advances in image-guided navigation, functional mapping and intra-operative physiological monitoring have increased the number of patients who may benefit from craniotomy, leading to an ever-growing role for surgery in patients with two to three brain metastases<sup>42</sup>. In addition, more advanced brachytherapy systems, in which a radioactive source is placed in the resection cavity at the time of initial tumor resection, may provide a vehicle to efficiently deliver therapeutic doses of radiation locally, allowing patients to suspend WBRT or forego it altogether. Unfortunately, treatment for patients with four or more metastases remains limited. Generally, palliative treatment with WBRT alone is considered standard therapy for these patients, approximately half of whom will die because of CNS disease progression. Radiosensitizers and radioenhancers, compounds designed to increase the toxicity of radiotherapy in cancerous tissue with minimal or no damage to adjacent normal tissue, have shown some promise in recent clinical trials and may one day represent a useful adjunct for patients undergoing WBRT<sup>58</sup>. Likewise, systemic chemotherapy, which has to date never demonstrated a survival benefit in patients with brain metastases<sup>31</sup>, may soon play a role in the treatment of metastatic brain cancer with the advent of newer chemotherapeutic agents such as temozolomide, which has been shown to have a synergistic effect with WBRT and improve response rates in patients with cerebral metastases compared with WBRT alone<sup>59</sup>.

## EXTRINSIC TUMORS OF THE BRAIN

### Meningioma

Meningiomas hold a special place in the history of neurosurgery. It has been nearly a century since Harvey Cushing

<b>Clinical and radiographic variables</b> <ul style="list-style-type: none"> <li>• Age</li> <li>• Functional status</li> <li>• Extent of systemic disease</li> <li>• Number, size and location of intracranial tumors</li> <li>• Degree of mass effect/cerebral edema resulting from tumor(s)</li> </ul>			
Clinical scenarios	I	II	III
	<ul style="list-style-type: none"> <li>• Good or marginal functional status</li> <li>• Extensive or controlled systemic disease</li> <li>• Single, surgically accessible tumor</li> <li>• <math>\pm</math> Mass effect</li> </ul>	<ul style="list-style-type: none"> <li>• Good or poor functional status (attributable to cerebral edema and mass effect)</li> <li>• Extensive or controlled systemic disease</li> <li>• Two or three surgically accessible tumors</li> </ul>	<ul style="list-style-type: none"> <li>• Poor functional status</li> <li>• Extensive systemic disease</li> <li>• Four or more brain metastases</li> </ul>
Treatment options			
WBRT/ corticosteroids only (supportive care)	–	+	+
Surgery $\pm$ WBRT	+	+	–
SRS $\pm$ WBRT	Option (for tumors <3 cm)	–	–

Figure 34.4 Sample algorithm for treatment of brain metastases. WBRT, whole brain radiation therapy; SRS, stereotactic radiosurgery.

published his seminal monograph<sup>60</sup> detailing the clinical and pathological behavior of meningiomas, and surgery remains the definitive therapy for these tumors today as it did then. Emphasizing the role for surgery in the treatment of meningiomas, Cushing wrote: ‘There is today nothing in the whole realm of surgery more gratifying than the successful removal of a meningioma with subsequent perfect functional recovery, especially should a correct pathological diagnosis have been previously made’<sup>61</sup>. Today, advances in skull base surgery as well as conformal radiotherapy

and stereotactic radiosurgery allow for effective and safe treatment of even the most challenging meningiomas.

### *Epidemiology and biology*

Meningiomas arise from the arachnoid cap cells of meningeothelial origin that contribute to the external membranous coverings, or meninges, of the brain and spinal cord. Meningiomas are the most common extra-axial, or extrinsic, intracranial tumors and constitute approximately 20% of

all intracranial neoplasms, with an overall incidence of about 7.8 per 100 000. They have a peak incidence between 40 and 50 years of age and occur more frequently in women, with some series reporting a female to male ratio of 3 : 2 or even 2 : 1<sup>2</sup>. Several environmental risk factors have been reported to play a role in meningioma tumorigenesis, including ionizing radiation, head trauma and viral infection. Of these, only ionizing radiation has been conclusively shown to contribute to the development of meningiomas in large cohort studies. Ron *et al.* reviewed the medical records of nearly 11 000 Israeli children receiving radiation therapy for tinea capitis between 1948 and 1960 and found a four-fold increase in the incidence of meningiomas in irradiated children than in age-matched controls<sup>62</sup>. Other reports have suggested that the amount of cumulative radiation received in annual dental radiographs may pose a risk.

The vast majority of meningiomas are histologically benign, with only approximately 2% demonstrating malignant behavior. An additional 5% are described as 'atypical', meaning that they possess some aggressive histological features but do not appear frankly malignant. Radiation-induced meningiomas are commonly more biologically aggressive than sporadic meningiomas: they are more likely to be multiple, to recur after surgery, and to manifest atypical histology. Meningiomas have been shown to possess characteristic genetic alterations, the most important of which is a deletion of chromosome 22q that occurs in 50–60% of these tumors<sup>63</sup>. Interestingly, mutation and/or deletion of the *NF2* gene on 22q, which is present in most sporadic meningiomas, is also a molecular characteristic of neurofibromatosis type 2 (NF-2), of which multiple meningiomas are a hallmark feature. There is also a compelling epidemiological link between steroid hormones and meningioma growth suggested clinically by their increased frequency in women, increased growth rates during pregnancy and association with breast cancer. Approximately 50–80% of meningiomas express the progesterone receptor and 30% express the estrogen receptor in an active form. To date it has been difficult to clearly elucidate the role these receptors may play in meningioma growth *in vivo*; however, there are no compelling data to support the efficacy of hormone suppression therapy in treating patients with meningioma.

### *Clinical presentation and imaging*

Meningiomas occur most commonly along the falx cerebri, over the convexities of the cerebral hemispheres, and at the base of the skull along the sphenoid wing, olfactory groove, or parasellar region adjacent to the pituitary gland and cavernous sinus. They can, however, occur anywhere arachnoid cells are found, including inside the ventricles

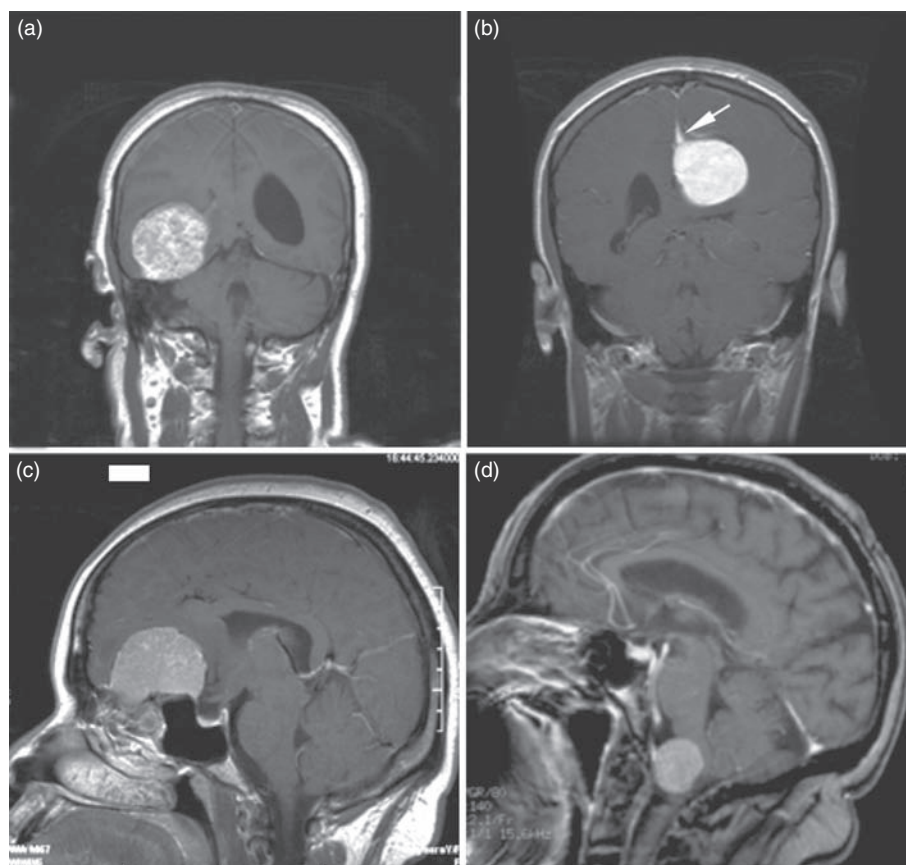
and within the orbit. Meningiomas do not generally invade brain parenchyma, but they may, depending on their size and location, produce focal neurological deficits by the gradual compression of adjacent neural structures. For example, patients with tumors over the convexity of the frontal lobe may present with progressive hemiparesis due to compression of the motor and premotor cortex, whereas patients with skull-based lesions typically present with cranial neuropathy secondary to involvement of the cranial nerves as they exit the skull or traverse the cavernous sinus. The signs and symptoms accompanying meningiomas thus often directly reflect the location of the tumor.

The diagnosis of meningioma can generally be established by neuroimaging alone, with MRI being the study of choice. Meningiomas demonstrate a striking homogeneous enhancement pattern following gadolinium administration (Figure 34.5). They commonly display a broad base along a bony structure or free dural margin and classically demonstrate an enhancing 'dural tail' which anchors the tumor to its meningeal origin. MRI is also useful in evaluating relative tumor vascularity, relationship to major cerebral arteries and veins, as well as in revealing any associated cerebral edema adjacent to the tumor.

### *Management*

In an era when access to high quality CT and MR imaging is quite prevalent, the decision *not* to treat newly diagnosed meningiomas has become increasingly important. Many meningiomas are in fact asymptomatic and detected incidentally after an imaging study has been obtained for unrelated reasons, such as work-up of migraine headaches or following trauma. Particularly in older patients, small asymptomatic meningiomas may simply be followed with serial imaging studies. In many cases, these tumors remain static for the duration of the patient's lifetime and never cause neurological symptoms. When meningiomas do show evidence of radiographic or clinical progression, the decision to treat can be re-evaluated.

When treatment of meningioma is necessary, surgery is the mainstay of therapy. Gross total resection provides the advantage of immediate symptom relief and offers the patient a chance for cure. However, even among tumors that are completely resected, up to 20% may recur within 10 years, and more than 80% progress following partial resection. To this end, radiation therapy has become an important part of treatment for meningioma. Several studies have demonstrated lower overall recurrence rates and longer disease-free intervals in patients receiving post-operative conformal radiotherapy following incomplete resection of benign meningioma<sup>64,65</sup>. In those patients presenting with a recurrent meningioma, a second resection should be performed, with consideration given to



**Figure 34.5** Contrasted magnetic resonance (MR) images demonstrating characteristic locations of intracranial meningiomas. (a) Coronal view of a meningioma arising from the tentorium cerebelli. (b) Coronal view of a large falcine meningioma illustrating its 'dural tail' (arrow). (c) Sagittal view of an olfactory groove meningioma. (d) Sagittal image of a meningioma taking its origin from the anterior aspect of the foramen magnum. Note the significant degree of brainstem compression in (d).

postoperative radiation therapy to the tumor bed, as existing data suggest better local control as well as a significant survival benefit in patients receiving reoperation and radiotherapy than in those undergoing reoperation alone<sup>66</sup>. Stereotactic radiosurgery may be an efficacious and safe alternative to conformal fractionated radiation therapy in meningiomas measuring less than 3 cm in diameter<sup>67</sup>. For patients diagnosed with atypical or anaplastic/malignant meningioma, postoperative radiotherapy should be considered due to the aggressive behavior of these tumors and their tendency to recur<sup>68</sup>.

The role of chemotherapy in the treatment of meningiomas is not yet established. Studies evaluating the efficacy of hydroxyurea- and doxorubicin-based regimens in the treatment of recurrent and malignant meningiomas have been thus far disappointing<sup>69,70</sup>. In addition, antiestrogen and antiprogesterone therapies, as well as interferon therapy, have all been ineffective.

### Pituitary adenomas

Given the role of the pituitary in regulating hormonal homeostasis and maintaining fluid and electrolyte balance

in the body, tumors of the pituitary gland comprise a unique class of neoplasms encompassing the disciplines of neurosurgery, endocrinology and oncology. In addition, the location of the pituitary gland relative to the optic apparatus often necessitates involvement of a neuro-ophthalmologist when caring for patients with pituitary neoplasms. While surgery and pharmacological therapy remain the preferred therapeutic options for most pituitary tumors, recent advances in radiosurgery have shown promise in the treatment of tumors unable to be completely resected.

### *Epidemiology and biology*

Pituitary tumors represent approximately 10–15% of all primary intracranial neoplasms, placing them third in order of frequency behind gliomas and meningiomas. Studies on pituitary adenomas report an incidence of between 0.4 and 18.7 cases per 100 000 population per year. Most pituitary tumors present in the 3rd and 4th decades of life, and data suggest that men and women are equally affected. Patients with multiple endocrine neoplasia syndrome type 1 (MEN-1) are known to have a genetic predisposition to pituitary tumors. MEN-1 is an uncommon

autosomal dominant syndrome associated with pituitary, pancreatic and parathyroid neoplasms. The disorder is variably penetrant, with approximately 25% of patients with MEN-1 eventually developing pituitary adenomas.

Specific genetic mutations have been linked to pituitary tumorigenesis, in particular inactivation of the MEN-1 tumor suppressor gene located on chromosome 11q13. Individuals with MEN-1 carry a germline mutation of the MEN-1 gene, and thus subsequent spontaneous mutation or deletion in the normal copy of the gene leads to tumor formation in these patients. In addition, recent evidence suggests that MEN-1 gene mutations are responsible for approximately 20% of sporadic pituitary tumors<sup>71</sup>, and that loss of heterozygosity at 11q13 (near the MEN-1 locus) may increase invasiveness in pituitary tumors. Another tumor suppressor gene implicated in the development of pituitary neoplasms is the cyclin-dependent kinase inhibitor p16. Levels of p16 transcript were undetectable in all pituitary adenoma samples analyzed in one study, while expression levels were normal in surrounding normal gland of patients with tumor as well as in control samples<sup>72</sup>.

### *Clinical presentation and imaging*

Pituitary tumors are often classified on the basis of their size: tumors less than 1 cm in diameter are termed microadenomas, whereas larger tumors are considered macroadenomas. They may be further divided into functional and non-functional groups based upon their secretory products. Functional adenomas secrete biologically active hormones such as prolactin or growth hormone, while non-functioning pituitary tumors either have no secretory product or elaborate a hormone such as gonadotropin that does not readily cause endocrinological symptoms. This distinction becomes important when evaluating a patient presenting with a pituitary adenoma. Patients with functional adenomas often present early with endocrinological symptoms caused by the physiological effects of the excess hormones that they secrete. As such, these tumors are often small and still confined to the sella turcica upon initial diagnosis. For example, thyrotropic adenomas often produce excessive amounts of thyroid stimulating hormone, with patients presenting with clinical secondary hyperthyroidism. In contrast, non-functioning adenomas do not usually become symptomatic until they have grown to sufficient size to cause neurological deficits. These tumors may be quite large and are often found to have extended outside the sella upon initial presentation. A common presenting sign is the development of a bitemporal hemianopsia from optic chiasm compression. Invasion into the adjacent cavernous sinus may lead to additional cranial neuropathies, with patients complaining of double vision or facial numbness.

Diagnosis of pituitary adenomas is generally made by concurrent analysis of serum hormone levels as well as by MRI. Serial hormone assays not only facilitate diagnosis of functional pituitary adenomas, but also serve as markers of treatment response and can detect early tumor recurrence following treatment. Coronal and sagittal MR images through the sella turcica (Figure 34.6) can easily confirm the presence of a functional microadenoma or diagnose a large non-functioning tumor. On gadolinium-enhanced sequences, microadenomas characteristically appear hypointense relative to the normal gland. Macroadenomas typically demonstrate robust and homogeneous uptake of contrast and may be seen to invade the cavernous sinus or compress the optic nerves or chiasm.

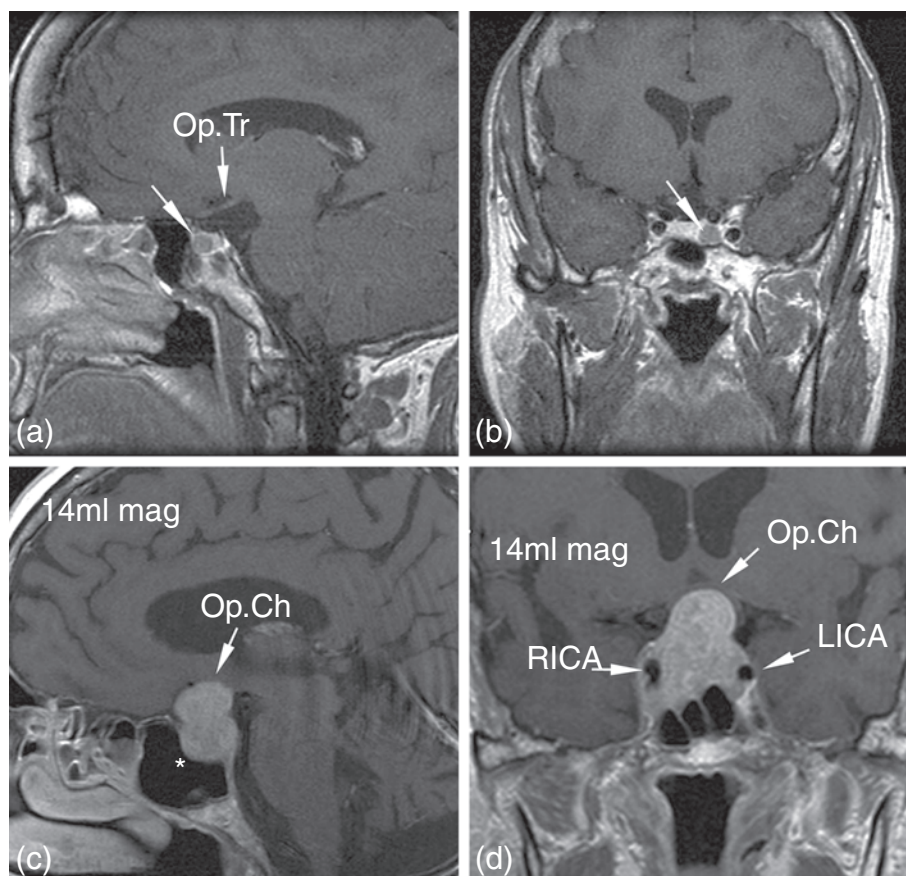
### *Management*

Despite significant improvements in medical therapy, surgery remains the preferred primary therapy for most pituitary tumors, functional and non-functioning alike. An exception to this is prolactinoma, for which pharmacological therapy with a dopamine agonist is the initial treatment of choice. In the overwhelming majority of cases, surgery for pituitary tumors is performed through a transsphenoidal approach to the sella. Although originally described over 100 years ago, the transsphenoidal approach remains remarkably similar in concept today. However, recent developments such as frameless stereotaxy and video-assisted endoscopic pituitary surgery have made performing surgery through the sphenoid sinus safer, less invasive and more accurate. Macroadenomas with a considerable amount of tumor extending rostrally out of the sella and into the suprasellar cistern may still be approached via a transcranial approach alone or in conjunction with a transsphenoidal approach.

Prolactinomas are the most common pituitary adenomas, comprising approximately 25–30% of all pituitary tumors. Prolactinomas generally present with amenorrhea/galactorrhea and infertility in women of childbearing age. Regardless of size, prolactinomas should be treated initially with a dopamine agonist, most commonly bromocriptine or cabergoline. These medications result in normalization of prolactin levels and decrease in tumor size in 80–90% of patients<sup>73</sup>. In patients with large prolactinomas compressing the optic chiasm, dopamine agonist therapy has been shown to be efficacious in resolving visual field deficits, obviating the need for surgical decompression. Surgical treatment is warranted for prolactinomas that do not respond to medical therapy.

Non-functioning, or null cell, pituitary tumors are responsible for about 25% of pituitary adenomas. These tumors typically present with signs and symptoms of mass effect on surrounding cranial nerves: bitemporal hemianopsia,





**Figure 34.6** Sagittal (a) and coronal (b) enhanced magnetic resonance (MR) views of a pituitary microadenoma (arrows). Microadenomas typically appear hypointense on T1-weighted images following gadolinium administration. Note that the tumor is contained within the sella and does not impinge on the optic apparatus (Op. Tr). Sagittal (c) and coronal (d) gadolinium-enhanced images of a pituitary macroadenoma. Macroadenomas are generally homogeneously enhancing masses that extend out of the sella to compress the optic nerves or chiasm (Op. Ch). Note the sphenoid sinus (\*), which defines the surgical approach for most pituitary tumors, as well as the left internal carotid artery (LICA) and right internal carotid arteries (RICA), which are encased by the macroadenoma.

loss of visual acuity and diplopia occur frequently. These tumors may also present with varying degrees of hypopituitarism as a result of compression on the normal gland. Surgery is the mainstay of therapy for null cell adenomas, with the primary goal being decompression of the optic apparatus to preserve vision. The most important determinants of clinical outcome are the size and invasiveness of the tumor, with recurrence being directly proportional to both of these variables. Larger tumors may invade the cavernous sinus, where they are often not amenable to safe surgical resection. Postoperative radiation has been shown to be beneficial in reducing recurrence in cases with significant residual tumor or cavernous sinus extension<sup>74</sup>.

Somatotrophic, or growth hormone, adenomas account for approximately 15–20% of pituitary adenomas. These tumors present clinically with acromegaly or gigantism. Acromegaly is characterized by extensive soft tissue swelling as well as skeletal hyperostosis and is associated with hypertension, cardiomyopathy and abnormal serum glucose regulation, all of which pose significant health risks if

growth hormone hypersecretion is not corrected. Long-acting somatostatin analogs (octreotide) and growth hormone receptor antagonists (pegvisomant) have shown significant promise in the long-term medical management of acromegaly resulting from growth hormone adenomas; however, surgery remains the initial treatment of choice for these tumors.

Corticotrophic adenomas are responsible for approximately 10% of pituitary adenomas and occur nearly five times more frequently in females. Clinically, corticotrophic adenomas are responsible for Cushing disease, which is characterized by pituitary-dependent hypercortisolism. Patients with Cushing disease typically have centripetal obesity with wasting of the extremities, abdominal striae, acne, hirsutism, hypertension, and diabetes mellitus. Tumor size generally has no correlation with severity of hypercortisolism. As a result, these tumors are often quite small and not able to be easily visualized on imaging studies. When the diagnosis of corticotrophic adenoma is suggested by laboratory studies but the tumor itself is not seen

on MRI, inferior petrosal sinus sampling before and after corticotropin-releasing hormone administration can be used to confirm the diagnosis and to provide a rough estimate of tumor lateralization to guide surgical planning. Tumor recurrence following transsphenoidal surgery for Cushing disease may be treated with radiotherapy or radiosurgery. Pharmacologically, ketoconazole is useful in lowering serum cortisol levels pending definitive treatment.

## SUMMARY

There is an incredible array of diverse neoplasms that arise within the central nervous system. Benign neoplasms such as meningiomas may be strategically located in areas that are exceptionally challenging to treat; however, recent advances in surgical and radiation therapy now make the treatment of these lesions quite safe. Primary malignant neoplasms are insidious in their capacity to invade the brain

and, unfortunately, remain uniformly fatal despite recent advances in surgery, radiation and delivery of chemotherapeutic agents to the brain. However, the next decade promises to bear witness to an unlocking of the molecular code that defines these neoplasms. Protein and genetic profiling will delineate subsets of patients who are likely to respond to targeted, pathway-specific therapies. These new molecular insights are beginning to now transform the specialty of neurosurgical oncology. Moreover, the field of stem cell biology holds significant promise in revealing new insights into the potential cell of origin for primary brain cancers<sup>75</sup>. Metastatic brain cancer remains the most common tumor of the central nervous system, with an incidence that is on the rise. Yet with more advanced intraoperative stereotaxy as well as more effective postoperative radiation therapy regimens, the diagnosis of a metastatic tumor in the brain is no longer fatal, as patients, appropriately treated, can experience longer disease-free survival with restoration of neurological function.

## REFERENCES

- Ohgaki H, Kleihues P. Population-based studies on incidence, survival rates, and genetic alterations in astrocytic and oligodendroglial gliomas. *J Neuropathol Exp Neurol* 2005; 64: 479–89.
- Kleihues P, Cavanee WK, eds. *World Health Organisation Classification of Tumors: Pathology and Genetics of Tumors of the Nervous System*, 3rd edn. Lyon: IARC Press, 2000.
- Kleihues P, Louis DN, Scheithauer BW et al. The WHO classification of tumors of the nervous system. *J Neuropathol Exp Neurol* 2002; 61: 215–225.
- Burkhard C, Di Patre PL, Schuler D et al. A population-based study of the incidence and survival rates in patients with pilocytic astrocytoma. *J Neurosurg* 2003; 98: 1170–4.
- Greenberg M. *Handbook of Neurosurgery*, 5th edn. New York: Thieme Medical Publishers, 2001.
- DeAngelis LM. Brain tumors. *N Engl J Med* 2001; 344: 114–23.
- Ohgaki H, Kleihues P. Epidemiology and etiology of gliomas. *Acta Neuropathol (Berl)* 2005; 109: 93–108.
- Bauman G, Shaw EG. Low-grade supratentorial glioma. In: Black P, Loeffler JS, eds. *Cancer of the Nervous System*, 2nd edn. Philadelphia: Lippincott Williams & Wilkins, 2005: 465–89.
- Fisher BJ, Leighton CC, Vujovic O et al. Results of a policy of surveillance alone after surgical management of pediatric low grade gliomas. *Int J Radiat Oncol Biol Phys* 2001; 51: 704–10.
- Sutton LN, Cnaan A, Klatt L et al. Postoperative surveillance imaging in children with cerebellar astrocytomas. *J Neurosurg* 1996; 84: 721–5.
- Cairncross JG, Laperriere NJ. Low-grade glioma. To treat or not to treat? *Arch Neurol* 1989; 46: 1238–9.
- Kondziolka D, Lunsford LD, Martinez AJ. Unreliability of contemporary neurodiagnostic imaging in evaluating suspected adult supratentorial (low-grade) astrocytoma. *J Neurosurg* 1993; 79: 533–6.
- Berger M. Role of surgery in diagnosis and management. In: Apuzzo M, eds. *Benign Cerebral Glioma*. Park Ridge: American Association of Neurological Surgeons, 1995; 2: 293–307.
- Karim AB, Maat B, Hatlevoll R et al. A randomized trial on dose-response in radiation therapy of low-grade cerebral glioma: European Organization for Research and Treatment of Cancer (EORTC) Study 22844. *Int J Radiat Oncol Biol Phys* 1996; 36: 549–56.
- van den Bent MJ, Afra D, de Witte O et al. Long-term efficacy of early versus delayed radiotherapy for low-grade astrocytoma and oligodendroglioma in adults: the EORTC 22845 randomised trial. *Lancet* 2005; 366: 985–90.
- Mason WP, Krol GS, DeAngelis LM. Low-grade oligodendroglioma responds to chemotherapy. *Neurology* 1996; 46: 203–7.
- Jaecle KA, Ballman KV, Rao RD et al. Current strategies in treatment of oligodendroglioma: evolution of molecular signatures of response. *J Clin Oncol* 2006; 24: 1246–52.
- Brada M, Viviers L, Abson C et al. Phase II study of primary temozolomide chemotherapy in patients with WHO grade II gliomas. *Ann Oncol* 2003; 14: 1715–21.
- Wrensch M, Minn Y, Chew T et al. Epidemiology of primary brain tumors: current concepts and review of the literature. *Neuro-oncol* 2002; 4: 278–99.
- Freije WA, Castro-Vargas FE, Fang Z et al. Gene expression profiling of gliomas strongly predicts survival. *Cancer Res* 2004; 64: 6503–10.
- Schwartz SA, Weil RJ, Thompson RC et al. Proteomic-based prognosis of brain tumor patients using direct-tissue matrix-assisted laser desorption ionization mass spectrometry. *Cancer Res* 2005; 65: 7674–81.
- Rich JN, Reardon DA, Peery T et al. Phase II trial of gefitinib in recurrent glioblastoma. *J Clin Oncol* 2004; 22: 133–42.
- Lacroix M, Abi-Said D, Fournay DR et al. A multivariate analysis of 416 patients with glioblastoma multiforme: prognosis, extent of resection, and survival. *J Neurosurg* 2001; 95: 190–8.
- Simpson JR, Horton J, Scott C et al. Influence of location and extent of surgical resection on survival of patients with glioblastoma multiforme: results of three consecutive Radiation Therapy



- Oncology Group (RTOG) clinical trials. *Int J Radiat Oncol Biol Phys* 1993; 26: 239–44.
25. Chang SM, Parney IF, McDermott M et al. Perioperative complications and neurological outcomes of first and second craniotomies among patients enrolled in the Glioma Outcome Project. *J Neurosurg* 2003; 98: 1175–81.
  26. Brem H, Piantadosi S, Burger PC et al. Placebo-controlled trial of safety and efficacy of intraoperative controlled delivery by biodegradable polymers of chemotherapy for recurrent gliomas. The Polymer-brain Tumor Treatment Group. *Lancet* 1995; 345: 1008–12.
  27. Stupp R, Mason WP, van den Bent MJ et al. Radiotherapy plus concomitant and adjuvant temozolomide for glioblastoma. *N Engl J Med* 2005; 352: 987–96.
  28. Andrews DW, Scott CB, Sperduto PW et al. Whole brain radiation therapy with or without stereotactic radiosurgery boost for patients with one to three brain metastases: phase III results of the RTOG 9508 randomised trial. *Lancet* 2004; 363: 1665–72.
  29. Patchell RA, Tibbs PA, Regine WF et al. Postoperative radiotherapy in the treatment of single metastases to the brain: a randomized trial. *JAMA* 1998; 280: 1485–9.
  30. Patchell RA, Tibbs PA, Walsh JW et al. A randomized trial of surgery in the treatment of single metastases to the brain. *N Engl J Med* 1990; 322: 494–500.
  31. Peereboom DM. Chemotherapy in brain metastases. *Neurosurgery* 2005; 57: S54–65.
  32. Pollock BE, Brown PD, Foote RL et al. Properly selected patients with multiple brain metastases may benefit from aggressive treatment of their intracranial disease. *J Neurooncol* 2003; 61: 73–80.
  33. Johnson JD, Young B. Demographics of brain metastasis. *Neurosurg Clin N Am* 1996; 7: 337–44.
  34. Mehta MP, Patel RR. Radiotherapy and radiosurgery for brain metastases. In: Black PM, Loeffler JS eds. *Cancer of the Nervous System*, 2nd edn. Philadelphia: Lippincott Williams & Wilkins, 2005; 657–72.
  35. Nugent JL, Bunn PA Jr, Matthews MJ et al. CNS metastases in small cell bronchogenic carcinoma: increasing frequency and changing pattern with lengthening survival. *Cancer* 1979; 44: 1885–93.
  36. Nathoo N, Chahlavi A, Barnett GH et al. Pathobiology of brain metastases. *J Clin Pathol* 2005; 58: 237–42.
  37. Delattre JY, Krol G, Thaler HT et al. Distribution of brain metastases. *Arch Neurol* 1988; 45: 741–4.
  38. Hwang TL, Close TP, Grego JM et al. Predilection of brain metastasis in gray and white matter junction and vascular border zones. *Cancer* 1996; 77: 1551–5.
  39. Nussbaum ES, Djalilian HR, Cho KH et al. Brain metastases. Histology, multiplicity, surgery, and survival. *Cancer* 1996; 78: 1781–8.
  40. Sills AK. Current treatment approaches to surgery for brain metastases. *Neurosurgery* 2005; 57: S24–32.
  41. Weinberg JS, Lang FF, Sawaya R. Surgical management of brain metastases. *Curr Oncol Rep* 1988; 3: 476–83.
  42. Bindal RK, Sawaya R, Leavens ME et al. Surgical treatment of multiple brain metastases. *J Neurosurg* 1993; 79: 210–6.
  43. Arbit E, Wronski M, Burt M et al. The treatment of patients with recurrent brain metastases. A retrospective analysis of 109 patients with nonsmall cell lung cancer. *Cancer* 1995; 76: 765–73.
  44. Bindal RK, Sawaya R, Leavens ME et al. Reoperation for recurrent metastatic brain tumors. *J Neurosurg* 1995; 83: 600–4.
  45. Borgelt B, Gelber R, Kramer S et al. The palliation of brain metastases: final results of the first two studies by the Radiation Therapy Oncology Group. *Int J Radiat Oncol Biol Phys* 1980; 6: 1–9.
  46. Mehta MP, Khuntia D. Current strategies in whole-brain radiation therapy for brain metastases. *Neurosurgery* 2005; 57: S33–44.
  47. Coia LR. The role of radiation therapy in the treatment of brain metastases. *Int J Radiat Oncol Biol Phys* 1992; 23: 229–38.
  48. DeAngelis LM, Delattre JY, Posner JB. Radiation-induced dementia in patients cured of brain metastases. *Neurology* 1989; 39: 789–96.
  49. Penitzka S, Steinworth S, Schlleier S et al. Assessment of cognitive function after preventive and therapeutic whole brain irradiation using neuropsychological testing. *Strahlenther Onkol* 2002; 178: 252–8. [in German]
  50. Alexander E 3rd, Moriarty TM, Davis RB et al. Stereotactic radiosurgery for the definitive, noninvasive treatment of brain metastases. *J Natl Cancer Inst* 1995; 87: 34–40.
  51. Brown PD, Brown CA, Pollock BE et al. Stereotactic radiosurgery for patients with "radioresistant" brain metastases. *Neurosurgery* 2002; 51: 656–665.
  52. Sneed PK, Suh JH, Goetsch SJ et al. A multi-institutional review of radiosurgery alone vs. radiosurgery with whole brain radiotherapy as the initial management of brain metastases. *Int J Radiat Oncol Biol Phys* 2002; 53: 519–26.
  53. Kondziolka D, Patel A, Lunsford LD et al. Stereotactic radiosurgery plus whole brain radiotherapy versus radiotherapy alone for patients with multiple brain metastases. *Int J Radiat Oncol Biol Phys* 1999; 45: 427–34.
  54. McDermott MW, Sneed PK. Radiosurgery in metastatic brain cancer. *Neurosurgery* 2005; 57: S45–53.
  55. Auchter RM, Lamond JP, Alexander E et al. A multiinstitutional outcome and prognostic factor analysis of radiosurgery for resectable single brain metastasis. *Int J Radiat Oncol Biol Phys* 1996; 35: 27–35.
  56. Muacevic A, Kreth FW, Horstmann GA et al. Surgery and radiotherapy compared with gamma knife radiosurgery in the treatment of solitary cerebral metastases of small diameter. *J Neurosurg* 1999; 91: 35–43.
  57. EORTC. EORTC 22952/26001: A randomized phase III study of no radiotherapy versus whole brain radiotherapy for 1-3 brain metastases from solid tumour after surgical resection or radiosurgery., in [http://groups.eortc.be/radio/Protocols/22952\\_26001.htm](http://groups.eortc.be/radio/Protocols/22952_26001.htm), 2006.
  58. Mehta MP, Rodrigus P, Terhaard CH et al. Survival and neurologic outcomes in a randomized trial of motexafin gadolinium and whole-brain radiation therapy in brain metastases. *J Clin Oncol* 2003; 21: 2529–36.
  59. Antonadou D, Paraskevaidis M, Sarris G et al. Phase II randomized trial of temozolomide and concurrent radiotherapy in patients with brain metastases. *J Clin Oncol* 2002; 20: 3644–50.
  60. Cushing H. *Meningiomas: their Classification, Regional Behavior, Life History, and Surgical End Results*. Springfield, IL: Charles C Thomas, 1938.
  61. Cushing H. The meningiomas (dural endotheliomas): their source, and favoured seats of origin. *Brain* 1922; 45: 282–316.
  62. Ron E, Modan B, Boice JD Jr et al. Tumors of the brain and nervous system after radiotherapy in childhood. *N Engl J Med* 1988; 319: 1033–9.
  63. Dumanski JP, Rouleau GA, Nordenskjold M et al. Molecular genetic analysis of chromosome 22 in 81 cases of meningioma. *Cancer Res* 1990; 50: 5863–7.
  64. Barbaro NM, Gutin PH, Wilson CB et al. Radiation therapy in the treatment of partially resected meningiomas. *Neurosurgery* 1987; 20: 525–8.
  65. Goldsmith BJ, Wara WM, Wilson CB et al. Postoperative irradiation for subtotally resected meningiomas. A retrospective

- analysis of 140 patients treated from 1967 to 1990. *J Neurosurg* 1994; 80: 195–201.
66. Maire JP, Caudry M, Guerin J et al. Fractionated radiation therapy in the treatment of intracranial meningiomas: local control, functional efficacy, and tolerance in 91 patients. *Int J Radiat Oncol Biol Phys* 1995; 33: 315–21.
67. Kondziolka D, Levy EI, Niranjan A et al. Long-term outcomes after meningioma radiosurgery: physician and patient perspectives. *J Neurosurg* 1999; 91: 44–50.
68. Dziuk TW, Woo S, Butler EB et al. Malignant meningioma: an indication for initial aggressive surgery and adjuvant radiotherapy. *J Neurooncol* 1998; 37: 177–88.
69. Chamberlain MC. Adjuvant combined modality therapy for malignant meningiomas. *J Neurosurg* 1996; 84: 733–6.
70. Schrell UM, Rittig MG, Anders M et al. Hydroxyurea for treatment of unresectable and recurrent meningiomas. II. Decrease in the size of meningiomas in patients treated with hydroxyurea. *J Neurosurg* 1997; 86: 840–4.
71. Bystrom C, Larsson C, Blomberg C et al. Localization of the MEN1 gene to a small region within chromosome 11q13 by deletion mapping in tumors. *Proc Natl Acad Sci USA* 1990; 87: 1968–72.
72. Woloschak M, Yu A, Xiao J et al. Frequent loss of the P16INK4a gene product in human pituitary tumors. *Cancer Res* 1996; 56: 2493–6.
73. Molitch ME. Medical treatment of prolactinomas. *Endocrinol Metab Clin North Am* 1999; 28: 143–69.
74. Ebersold MJ, Quast LM, Laws ER Jr et al. Long-term results in transsphenoidal removal of nonfunctioning pituitary adenomas. *J Neurosurg* 1986; 64: 713–9.
75. Sanai N, Alvarez-Buylla A, Berger MS. Neural stem cells and the origin of gliomas. *N Engl J Med* 2005; 353: 811–22.



# Index

---

Note: Page references in *italic* refer to tables or figures in the text

- abarelix 279
- abdominal wall flaps 142–3
- ablative therapies
  - hepatocellular carcinoma 212
  - liver metastases 244–5
  - renal masses 253–4
- Academic Medical Center, Amsterdam 191, 192
- ‘accelerated repopulation’ 12
- acquired cystic kidney disease 250
- acrolein 260
- acromegaly 406
- actinic keratosis 303, 306
- adenocarcinoma, small bowel 157
- adenomatous polyposis coli (APC) gene 165
- adhesion molecules 161
- Adjuvant Online 108
- adrenalectomy 331–2, 333
  - adrenocortical cancer 333–4
  - laparoscopic 332–3, 333
  - open 332, 333–4, 333, 334
- adrenal gland
  - anatomy and physiology 327, 328
  - androgens 279
  - congenital hyperplasia 329
  - surgical approaches 332, 333
- adrenal tumors
  - adrenocortical cancer 333–5, 334, 335
  - diagnosis 330–1, 330, 331
  - diagnostic/treatment algorithm 332
  - epidemiology 327
  - incidental 327, 328
  - metastases 81, 90, 336
  - pheochromocytoma 335–6
  - presentation 327–8
  - screening 330
  - surgery 331–3, 333
  - types 327, 328
- adriamycin 235, 263, 347
- Aetius of Amida 1
- Africa, prostate cancer 272
- African-Americans 93, 94, 249, 311
- age
  - prostate cancer 271
  - and pulmonary resection 84
- AGES staging, thyroid cancer 343–4, 344
- AIDS patient 369
- airway obstruction 89
- alanine aminotransferase (ALT) 207
- albumin levels 207
- alcohol use 65, 94
- aldosterone 328, 330
- alfacalcidol 358
- alkaline phosphatase 251, 381
- alkylating agents 22, 300
- $\alpha$ -fetoprotein (AFP)
  - cholangiocarcinoma 227
  - hepatocellular carcinoma 205–6
  - testicular tumors 287, 290
- ALX4 gene 389
- American Association for the Study of Liver Diseases 205
- American black races 249, 311
  - prostate cancer 271
- American Cancer Society 166, 311
- American College of Surgeons Oncology Group
  - Z0030 study 87
  - Z1031 trial 133
- American National Cancer Database 353
- American Society of Anesthesiologists (ASA), grade, gastric cancer 148, 152
- American Society of Clinical Oncology (ASCO) 169, 177, 180, 239
- American Urological Association 261
- AMES staging, thyroid cancer 343, 344
- amifortine 360
- ampullary carcinoma
  - epidemiology 189
  - etiology 189
  - outcomes 199, 200
  - see also* pancreatic cancer
- anal canal
  - anatomy 167–8, 169, 181
  - cancer 183
- anal cancer 180–4
  - diagnosis and staging 181–2, 182–3

- anal cancer (*Continued*)  
 epidemiology 180–1  
 etiology 181  
 metastatic 184  
 pathology 181  
 persistent/recurrent disease 184
- analgesics  
 abuse 260  
 classification 42–3, 43  
 WHO ladder 42
- anal verge 167–8, 169
- anastomosis, coloanal 175
- androgens, prostate cancer 278–9, 280
- anemia, gastric cancer 151
- anorectal melanoma 319
- anorexia 45, 151
- anthracycline based chemotherapy 118, 133
- antiandrogens 279, 279
- antibiotics, prior to colorectal resection 170
- antiemetic treatments 43–4
- anxiety 51
- appendiceal tumors 160–2, 160, 161, 162  
 carcinoid 161, 162, 365
- Aristolochia fangchi* 260
- aromatase inhibitors 118
- arsenic exposure 260
- arterial blood gas analysis 87
- arylamines 260
- asbestos exposure 249
- ascites 207
- Asia  
 intrahepatic cholangiocarcinoma 226  
*see also named Asian countries*
- aspartate aminotransferase (AST) 207
- astrocytoma 394  
 anaplastic 394, 397  
 management 17, 396  
 pilocytic 393, 394, 396, 398  
 presentation 394
- Australia, cholangiocarcinoma 217
- axillary lymph nodes  
 breast cancer 123  
 excision in melanoma 320  
 ultrasound evaluation 106
- Azzopardi scar 288
- Bacillus Calmette–Guerin (BCG) 27, 259, 263
- bacteribilia 219
- bad news, communicating 44
- Balkan nephropathy 260
- Ball, Sir Charles 3
- barium enema 363
- barium swallow 95, 96
- Barret's metaplasia 94
- basal cell carcinoma (skin) 303, 309
- Beatson, George 2
- Benelli, L 136
- benign tumors 3
- benzodiazepines 44
- betel nut use 66
- bevacizumab 24–5, 26, 89, 177
- biclutamide 279
- bile duct resection, gallbladder cancer 233
- bile reflux, post-gastrectomy 153
- biliary cystic disease, congenital 217
- biliary drainage  
 pancreatic cancer 192–3, 195–6  
 percutaneous 225, 235
- biliary-enteric bypass, intrahepatic 225
- biliary obstruction  
 cholangiocarcinoma 225, 229  
 gallbladder cancer 235  
 palliation 230
- biliary tree adenocarcinoma, *see* cholangiocarcinoma
- bilirubin, serum 207  
 cholangiocarcinoma 219–20, 229
- Billroth 1
- biological therapies 24–5, 26, 118  
 renal cell carcinoma 254
- biology of cancer 2–3
- biopsy  
 adrenal tumors 331  
 bone tumors 381  
 melanoma 312–13  
 prostate bland 276  
 renal 251  
 soft tissue sarcoma 372–3  
*see also* sentinel lymph node biopsy
- Birt–Hogg–Dube (BHD) syndrome 250
- bis-chloroethyl-nitro-urea (BCNU) 398
- Bismuth–Corlette classification 222
- bisphosphonates 280, 359–60, 359, 383
- Blackfoot disease 260
- black races 249, 311  
 prostate cancer 271, 272
- bladder cancer 259  
 chemotherapy and radiotherapy 17, 21, 27, 265–6  
 diagnosis 261  
 histopathology 259  
 incidence and prevalence 259  
 multidisciplinary approach 267, 268  
 muscle-invasive 263, 265–6  
 non-invasive 263  
 outcomes 266–8, 266, 267  
 palliative care 265, 266  
 predisposing/risk factors 259–60  
 presentation 260  
 screening 260–1  
 staging 261–3, 262  
 surgery for cure 263–4
- Blalock, Alfred 232
- bleeding  
 colonic tumors 176  
 liver resection 242  
 nephrectomy 253  
 pancreaticoduodenectomy 194, 195  
 postmenopausal (PMB) 296
- bleomycin 23, 292, 299  
 side effects 290
- bleomycin, etoposide, cisplatin (BEP) 289
- blood–brain barrier 25–6, 399
- blood gas analysis 87
- blue cell malignancies 386–7
- body mass index 230, 271
- bone biology 382
- bone invasion, oropharyngeal tumors 71

- bone morphogenetic proteins (BMPs) 385
- bone scans, prostate cancer 275
- bone tumors
  - biopsy 381
  - laboratory evaluation 380–1
  - metastatic 379, 382–3
    - common sites 382
    - management 382–3
    - pathology 382
    - prostate cancer 275, 280
  - primary 379
    - chondrosarcoma 387–9
    - chordoma 383, 389
    - Ewing's sarcoma 386–7
    - osteosarcoma 384–6
  - reconstruction of defects 380
  - staging 380–1
- bortezomib 25
- bowel preparation, preoperative 170
- Bowen's disease 306
- brachytherapy
  - brain metastases 401
  - prostate cancer 277
  - soft tissue sarcoma 375
- brain metastases 399–401, 407
  - distribution 399
  - incidence 399
  - lung cancer 90
  - management algorithm 402
  - stereotactic radiosurgery 401
  - surgical treatment 399–400
  - systemic chemotherapy 401
  - whole brain radiation therapy 400–1
- brain tumors
  - extrinsic 401–4
  - glioma 393–9
    - grading 393, 394
    - high grade 397–9
    - low grade 393–6
  - metastatic, *see* brain metastases
- breast
  - clinical examination 113
  - Paget's disease 121–2
  - volume, estimation 131
- breast cancer
  - axillary node recurrence 123
  - axillary node assessment 106
  - biological therapy 24
  - chemotherapy 22, 118, 121
    - neoadjuvant 133
  - ductal carcinoma *in situ* (DCIS) 105, 107, 108, 114
  - epidemiology 105, 113
  - grading 114–15
  - HER-2 expression 133
  - hormonal therapy 117–18, 133
  - hormone-receptor status 120, 133
  - inflammatory 114, 114, 119, 120, 120
  - invasive ductal 114
  - liver metastases 246
  - lobular carcinoma *in situ* 114
  - locally advanced 119–21, 119, 120
  - locoregional recurrence 122–3, 123, 128
  - metastatic 121
    - nipple discharge 118–19
    - radiotherapy 17, 117
    - screen-detected 105
      - adjuvant treatment 108
      - diagnostic strategy 105–6, 107
      - prognosis and outcome 108, 109
      - staging 108
      - surgery 106–7
    - sentinel lymph node biopsy 108, 115, 117, 121, 123
    - staging 108, 116–17, 119
      - and prognosis 123
- breast cyst 114
- breast flaps, composite 135
- breast mass, evaluation 113–15
- breast-ovarian cancer families 296
- breast reconstruction 57, 106–7
  - see also* breast surgery, oncoplastic
- breast surgery 115, 117
  - breast conservation 115, 127, 128
  - chest wall resection 121
  - historical 1–2
  - modified radical mastectomy 121, 122
  - oncoplastic
    - cosmetic challenges of partial mastectomy 128–9, 129
    - goals 127–8
    - implants 143–4
    - margin assessment 134–5, 134, 139–40
    - partial mastectomy defect repair 135–7, 136
    - patient selection 129–32
    - preoperative planning 132–3
    - reduction mammoplasty 137–40, 137–9
    - re-excision of margins 132
    - regional and distant flaps 140–3, 141
    - timing 131
  - and outcomes of cancer 127, 128
  - prophylactic 55
  - and quality of life 127
  - radical mastectomy 12, 115, 119
  - screen-detected cancer 106–7
  - total mastectomy 121
- Breslow tumor thickness 314, 318
- bromocriptine 405
- bronchial sleeve resection 88
- CA 19-9 159, 161, 189–90
- CA125 296
- cabergoline 405
- Cabrol, Barthelemy 1
- cachexia 45
- cadmium 272
- calcitonin 341, 348, 349
  - therapy 360
- calcium levels 251, 381
  - lowering 359–60
  - malabsorption 153
  - management after parathyroidectomy 358
  - parathyroid carcinoma 353, 354, 354
  - supplementation 358
- Cancer and Leukemia Group B (CALGB) 101
- capecitabine 161, 226
- carboplatin 23
- carcinoembryonic antigen (CEA) 159, 161, 169, 189–90, 239, 240
- carcinoid syndrome 160, 363

- carcinoid tumors 157–8, 363
  - appendiceal 161, 162, 365
  - gastric 364–5
  - imaging 363–4
  - jejunum, ileum, colon 365
  - metastases 363
  - outcomes 160, 162
  - symptoms 363
- cardiovascular syndromes 328
- carers 58, 59
- Carney's complex 328, 329
- Caroli's disease 217
- castration 279
  - side-effects 279, 280
- catecholamines 328, 330
  - hypersecretion 328
- catheter, indwelling 58
- CD20 antibodies 24
- celiac disease 157
- celiac plexus blockade 196–7
- cellular telephone use 397
- centralization of cancer surgery 161, 194–5
- cerebral edema 395, 398
- cerebral metastases, *see* brain metastases
- cervical cancer
  - adjuvant chemotherapy 299
  - diagnostic strategy 296–7
  - incidence and prevalence 295
  - outcomes 300, 301
  - palliative care 300
  - palliative radiotherapy 300
  - presentation 296
  - screening 296
  - staging 297
  - surgery for cure 298
- cervical lymph nodes 64, 64
  - dissection 69
  - metastases, oropharyngeal tumors 64, 68
  - resection, parathyroid carcinoma 357
- cervical mediastinoscopy (CME) 81
- cetuximab 25, 26, 246
- Chamberlain's procedure 81
- chemotherapy
  - adjuvant 21–2
  - cell cycle-specific drugs 22
  - commonly used drugs 22–3, 23–4
  - commonly used regimens 22
  - delivery 25–7
  - goals of 21–2
  - hepatic artery infusion (HAI) 27, 226, 229, 243
  - intraperitoneal 25, 161
  - intrathecal 25–6
  - intravesical 27, 263
  - isolated limb perfusion/infusion 26–7, 320–1, 373, 376
  - liver metastases 245–6
  - palliative 22
  - transcatheter arterial chemoembolization (TACE) 27, 212–13
- chest wall resection, breast cancer 121
- Child–Pugh classification 207, 207
- children, pilocytic astrocytoma 395, 396
- Chinese herb nephropathy 260
- Chinese men 271
- chlorambucil 300
- chlorophenol wood preservatives 369
- cholangiocarcinoma
  - classification 217
  - distal 218
  - epidemiology 217
  - etiology/risk factors 217–18
  - hilar 218
    - adjuvant therapy 224
    - assessment of resectability 221–2, 221
    - management algorithm 223
    - outcomes 224
    - palliation 224–6
    - presentation and diagnosis 219–20
    - radiological investigation 220–1
    - staging 222–3
    - surgery 223–4, 224
    - treatment alternatives 224
- histopathology 218, 218, 219
- intrahepatic 218
  - adjuvant therapy 228–9
  - distal 229–30
  - presentation and diagnosis 226–7
  - resectability assessment 227
  - staging 227
  - surgery and outcomes 228
- cholangiography 221, 232, 232
  - percutaneous transhepatic (PTC) 190, 220, 221
- cholangiopancreatography
  - endoscopic retrograde (ERCP) 190
  - magnetic resonance (MRCP) 190, 218, 220–1
- cholangitis 189
  - primary sclerosing (PSC) 217
  - recurrent bacterial 218
- cholecystectomy
  - gallbladder cancer diagnosed at 232, 233, 234
  - treatment of gallbladder cancer 233
- cholecystojejunostomy 196
- choledochal cysts 217
- choledochoduodenostomy 196
- choledochojejunostomy 196
- choledocholithiasis 219–20, 229
- cholelithiasis 230
- chondrosarcoma 372, 383, 387–9
  - secondary 387–8
- chordoma 383, 389
- Christie Hospital, Manchester, UK 161
- chromosomal aberrations, adrenal tumors 329
- chromosome 22q 403
- chromosome aberrations, skeletal sarcoma 388, 389
- chronic myelogenous leukemia 25, 26
- cigarette smoking 83, 94, 181, 189, 218
  - oropharyngeal tumors 65
  - renal cell carcinoma 249
  - urothelial carcinoma 260
- cinacalcet 359, 360
- cirrhosis 205, 210–11, 227
  - surveillance 205–6
- cisplatin 213, 226, 265, 299, 335
  - 5-FU/radiotherapy 183
  - approved indications 23
  - mechanism of action 23
- cisplatin-containing regimens, gastric cancer 151
- c-kit* 25, 26, 93

- Clark's level of invasion 314  
clear cell chondrosarcoma 388  
Cleveland Clinic 348  
Clinical Outcomes of Surgical Therapy (CST) trial 171  
clinical trials, *see* randomized clinical trials *and* named trials  
*Clonorchis sinensis* 218  
Cloquet's node 320  
close needle biopsy 381  
*Clostridium difficile* colitis 153  
*c-myc* oncogene 272  
cognitive decline, following whole brain radiation 400–1  
colic 44  
coloanal anastomosis 174–5  
colon, surgical anatomy 171, 172  
colonoscopy 166, 167  
    surveillance 180  
    virtual 167  
Color Doppler sonography 274  
colorectal cancer  
    adjuvant and neoadjuvant therapy 176–80  
    appendiceal tumors 160  
    associated inherited disorders 165–6  
    chemotherapy 22, 176–8, 245–6  
    diagnosis and staging 166–7, 168  
    early detection/screening 166, 167  
    epidemiology 165, 239  
    liver metastases 168, 239  
        ablation 244–5  
        chemotherapy 27, 245–6  
        incidence 239  
        increasing resectability 245  
        management algorithm 244  
        outcomes of resection 243  
        patient selection for resection 239–40, 240  
        preoperative staging 240–1  
        resection 241–3, 242  
        screening 239  
    molecular factors 177–8  
    palliative therapy 176  
    pathogenesis 165, 166  
    post-treatment surveillance 180  
    surgical resection 170–1, 171, 172  
        guidelines 173  
    tumor markers 169  
colorectal polyps 166  
colostomy 7  
colposcopy 296–7  
colrectal cancer, chemotherapy 22  
colrectal carcinoid tumors 365  
combined modality therapy (CMT), anal cancer 183, 184  
communication 8, 44, 49  
    historical perspective 49–50  
    postoperative 54  
    preoperative 52–4, 53  
    skills for health-care professionals 50  
computed tomography (CT) scanning  
    bone tumor staging 380  
    cholangiocarcinoma 218, 220, 221, 226–7, 226  
    colorectal cancer 168–9, 180  
    esophageal cancer 96, 97  
    gastric cancer 147–8  
    glioma 394  
    liver metastases 240–1  
    lung cancer 80–1, 85  
    multi-slice 158  
    multislice 240–1  
    oropharyngeal tumors 67  
    pancreatic mass 190, 191, 193  
    small bowel tumors 158  
    soft tissue sarcoma 372  
    urothelial cancer diagnosis 263  
congenital adrenal hyperplasia 329  
congenital biliary cystic disease 217  
Conn's syndrome 327, 330, 333  
consent 49, 50  
constipation 44  
continent cutaneous reservoir 264  
convection-enhanced delivery 399  
core biopsy, soft tissue sarcoma 372–3  
corticosteroids, and non-melanoma skin cancer 305  
cortisol secretion 328  
cough, esophageal tumors 95, 95  
coughing 95  
cranial neuropathy 405  
creatinine, serum 251  
C-reactive protein 380–1  
Crohn's disease 158, 181  
cryotherapy  
    prostate cancer 277  
    skin cancers 307  
Cushing disease 406–7  
Cushing, Harvey 401–2  
Cushing's syndrome 327, 328  
    diagnosis 330  
    surgical treatment 331–3, 333  
cyclin-dependent kinase inhibitor P16 405  
cyclizine 43, 44  
cyclophosphamide 23, 300  
    indications 23  
    mechanism of action 23  
    and urothelial carcinoma 260  
cyproterone acetate 279  
cystectomy 265  
    open radical 263  
    radical 267–8  
cystoscopy 261  
cytoreductive surgery 25  
    ovarian cancer 298  
    pseudomyxoma peritonei 161  
    renal cell carcinoma 254  
dacarbazine 323  
death 45  
decision making 50–1  
deglutination 64, 65  
delayed gastric emptying 194, 195  
Delhi, India 230  
deltopectoral myocutaneous flap 73  
dementia, following whole brain irradiation 400  
Denonvillier's fascia 175, 175  
dental radiographs 403  
dentures, poorly fitting 66  
Department of Veterans Affairs Laryngeal Study Group 71  
depression 45, 51  
De Quervain, F 353  
diabetes mellitus, adult-onset 189



- diagnosis of cancer
  - communication 44
  - psychological needs of patient 55–6
- dialysis patient 250
- dietary factors, prostate cancer 271–3
  - see also* nutrition
- diffusing capacity for carbon monoxide (DLCO) 84, 85, 86
- digital rectal examination (DRE) 167–8, 273, 274
- dioxins 369–70
- diuretics, loop 359
- DNA damage, skin cancers 304
- docetaxel 280
  - indications 23
  - mechanism of action 23
- doctor–patient relations 8, 54
- dopamine agonists 405
- Doppler ultrasound 232
- doxorubicin 151, 213, 300, 335, 376, 377, 385
  - approved indications 23
  - mechanism of action 23
- ductal carcinoma *in situ* (DCIS) 105, 107, 108
- ductography 119
- dumping 153
- Dutch Cancer Registry 306
- dysarthria 64–5
- dysphagia 64–5, 95, 95, 100, 147
- dysplastic nevus syndrome 313
- dyspnea
  - lung cancer 89
  - management 44
- Early Breast Cancer Trialists Collaborative Group
  - database 108
- Edinburgh Depression Scale 45
- ejaculation, retrograde 289, 292
- electroplating industry 272
- electrosurgery 309
- embolization
  - portal vein 245
  - renal 253
- encephalopathy, hepatic 207
- end-of-life care 45, 45
- endometrial cancer
  - diagnostic strategy 297
  - incidence and prevalence 295
  - outcomes 301
  - palliative care 300
  - presentation 296
  - radiotherapy 17, 299
  - risk factors 295
  - staging 297
  - surgery for cure 298
- endometrium, thickness 297
- endorectal ultrasound (ERUS) 169–70
- endoscopic retrograde cholangiopancreatography (ERCP) 190, 221, 229
- endoscopic ultrasound
  - esophageal cancer 95, 96, 97
  - gastric cancer 147, 148
  - pancreatic cancer 190, 191
- endoscopy
  - oropharyngeal tumors 67
  - ‘triple’ 67
- end-stage renal disease 250
- Enneking System 381
- enteric fistula 152
- environmental exposures
  - renal cell carcinoma 249
  - urothelial carcinoma 260
- epidermal growth factor receptor (EGFR) 199, 397
  - monoclonal antibody 25
- epidermodysplasia verruciformis 304
- epididymal cyst 287
- epididymo-orchitis 288
- epirubicin 151, 263
  - approved indications 23
  - mechanism of action 23
- epirubicin, cisplatin, infused fluorouracil (ECF) 151, 152
- Epstein–Barr virus (EBV) 369
- Erichsen, Sir John 2
- erlotinib 26, 199
- errors, professional 6–7
- erythrocyte sedimentation rate (ESR) 380–1
- erythroplakia 62
- esophageal cancer
  - adjuvant therapies 21, 100–2
  - characteristics and prognosis 94–5, 95
  - diagnosis 95
  - incidence 93–4
  - palliative treatment 101
  - preoperative management 98
  - reconstructive surgery 99–100, 100
  - risk factors 94
  - staging 95–7, 96, 97
  - surgery for cure 97–9
- esophageal stricture 95
- esophageal tumors, benign 93, 94
- esophagectomy
  - en bloc 99
  - palliative 101
  - reconstruction 99–100, 100
  - thoroscopic 99
  - transhiatal 98, 99
- esophagogastroduodenoscopy (EGD) 147
- esophagoscopy 95
- esophagus, swallowing mechanism 65
- ESPAC-1 study 199
- estrogen receptors
  - breast cancer 120, 133
  - meningioma 403
- estrogen replacement therapy 295
- estrogen therapy, prostate cancer 279, 279
- ethanol injection
  - celiac plexus blockade 197
  - hepatocellular carcinoma 211
- ethical issues 49
- etomidate 335
- etoposide 213, 225, 289, 290, 335, 385
  - mechanism of action 23
  - side effects 190
- ETS transcription factors 387
- European Liver Transplant Registry 228
- European Organization for Research and Treatment of Cancer (EORTC) 180, 183, 401
- Ewing’s sarcoma 21, 22, 370, 383, 386–7
- EWS gene 387

- exenterative surgery 263, 298  
 exercise testing 84  
 expert patient 50  
*EXT1/EXT2* genes 388, 389
- familial adenomatous polyposis (FAP) 157, 158, 165, 189  
   variants 165  
 familial hyperparathyroidism 353  
 familial syndromes  
   adrenal lesions 328, 329  
   atypical multiple melanoma syndrome (FAMMM) 189  
   colorectal cancer 165–6  
   medullary thyroid cancer 348, 348  
 family history  
   breast cancer 55  
   prostate cancer 271, 272  
 family members 44, 58, 59  
 FAMTX (cisplatin-fluorouracil, doxorubicin, high dose  
   methotrexate) 151  
 farmers 272  
 fat, dietary 271  
 fear 51  
 fecal occult blood test 166, 167  
 femur, osteosarcoma 379, 384  
 fertility, testicular tumors 290–1  
 fibrosis, liver 211, 211  
 field cancerization 61–2, 66, 87  
 fine needle aspiration (FNA)  
   breast lesion 106, 114  
   liver mass 206  
   soft tissue sarcoma 373  
   thyroid nodule 341–2  
 FIRM-ACT trial 335  
 fistula  
   enteric 152  
   gynecological cancers 298–9  
   pancreatic 194, 195  
   pharyngocutaneous 69  
   transesophageal 100  
 flank mass 260  
 flaps  
   breast reconstruction 135, 140–3, 141  
   latissimus dorsi 130, 140–1, 141, 374  
   oropharyngeal reconstruction 72–3  
   soft tissue sarcoma management 373–4  
   thoracodorsal artery perforator (TAP) 73, 141–2  
   transverse rectus abdominis myocutaneous (TRAM) 130, 130,  
     142–3  
 FLI1 gene 387  
 floxuridine 229  
 fluorodeoxyglucose (FDG) PET scanning 67, 148, 241  
 5-fluorouracil (5-FU) 70, 243, 299  
   approved indications 23  
   colorectal cancer 177–8, 179–80  
   gastric cancer 151–2  
   and leucovorin (LV) 177, 179–80, 225, 235, 245–6  
   and levamisole (LEV) 177  
   mechanism of action 23  
   and mitomycin 234  
   and mitomycin C/radiotherapy 183, 184  
   and oxaliplatin/leucovorin (FOLFOX) 22, 177  
   and semustine/vincristine (MOF) 177  
 flutamide 279
- FOLFOX (5-fluorouracil (5-FU)/oxaliplatin/leucovorin) 22, 177  
 folinic acid 243  
 forced expiratory volume in 1 second (FEV-1) 84, 86  
 fracture, pathological 379  
 free tissue transfer, oropharyngeal defects 73  
 future liver remnant volume (FLR) estimation 207–8, 213
- galactography 119  
 gallbladder, polyps 230  
 gallbladder carcinoma  
   adjuvant therapy 234  
   epidemiology 230  
   outcomes 233–4  
   palliation 234–5  
   pathology and staging 230–2, 231  
   presentation and diagnosis 232, 232  
   risk factors 230  
   surgical therapy 232–3  
 gallium nitrate 360  
 gallstone disease 230  
   intrahepatic 217  
 Gamma Knife 401  
 ganglioside vaccines 321  
 Gardner's syndrome 165  
 gastrectomy 149–51  
   first performed 1  
   laparoscopic 151  
   operative mortality 152  
   palliative 151  
   postoperative complications 152–3  
   proximal with jejunal interposition 149–50  
   radical 'D2' 150, 152–3  
   subtotal 149  
   total 149–50  
 gastric cancer  
   chemotherapy/radiotherapy 21, 152  
   diagnostic strategies 147  
   incidence and prevalence 147  
   liver metastases 246  
   lymph node dissection 150, 150  
   lymph node involvement 147  
   outcomes 152–3  
   palliative surgery 151  
   presentation 147  
   risk factors 147  
   screening 147  
   staging 147–9, 148  
   surgery 149–51  
     decision algorithm 149  
 gastric emptying, delayed 194, 195  
 gastric outlet obstruction, pancreatic cancer 196  
 gastrinoma 364, 365–6  
 gastroesophageal junction, adenocarcinoma 94, 95  
 gastroesophageal reflux disease (GERD) 94  
 gastrointestinal polyposis syndromes 157, 158, 189  
 gastrointestinal stromal tumor (GIST) 25, 26  
   leiomyoma 93  
 gastrojejunostomy 196  
 gastrostomy, drainage 159  
 gefitinib 25  
 gemcitabine 198–9, 226, 265  
   approved indications 23  
   mechanism of action 23

- gender  
  gallbladder cancer 230  
  melanoma 313–14
- genetic factors  
  colorectal cancer 165, 166  
  meningiomas 403  
  pancreatic and ampullary cancer 189  
  pituitary tumors 405  
  prostate cancer 271, 272  
  small bowel and appendiceal tumors 157–8, 158
- genetics  
  chondrosarcoma 388–9  
  osteosarcoma 384–5, 387
- genitourinary tract tumors  
  liver metastases 246  
  *see also* urothelial carcinomas
- German Rectal Cancer Study 179
- germ cell tumors  
  non-seminomatous (teratomas) 287, 289, 290, 291  
  types 287, 289
- Gerota's fascia 251, 252, 253
- gigantism 406
- Gleason score 273, 274, 275
- glioblastoma multiforme 394, 397, 397–8
- glioma  
  etiological factors 397  
  high grade 397–9  
  epidemiology 397  
  imaging 397–8  
  management 398  
  molecular pathogenesis 397  
  presentation 397  
  prognosis 398  
  low grade 393–6  
  classification and incidence 393–4, 394  
  imaging 394, 395  
  management 396–7  
  presentation 394  
  WHO grading system 393, 394
- glossectomy, neo-total 65
- glucagonomas 364, 364, 366
- Goldman cardiac index 148
- Gompertzian growth 21
- goserelin 279
- gossypol 335
- Graham, Everts 2
- Grant, General Ulysses S 61
- growth hormone receptor antagonists 406
- growth retardation, radiation 15
- haloperidol 43, 44
- Handley, Sampson 2
- head and neck surgery  
  psychological needs of patient 57  
  *see also* esophageal tumors; oropharyngeal tumors
- Heald, Professor Moriya 37
- hedgehog signaling 388–9
- hematuria  
  intractable 265  
  investigation 261  
  screening tests 260
- hemianopia, bitemporal 405
- hemorrhage, gastric cancer 151
- heparin sulfate biosynthesis 389
- hepatectomy, *see* liver resection
- hepatic artery  
  embolization/chemoembolization 27, 212–13, 367  
  infusion (HAI) 27, 226, 229, 243
- hepaticojejunostomy 194, 194, 218
- hepatitis B virus (HPB) 205
- hepatitis C virus (HPC) 205, 218
- hepatocellular carcinoma  
  ablative therapies 212  
  chemotherapy 213  
  clinical presentation 205  
  differentiation from cholangiocarcinoma 227  
  etiology 205  
  liver function assessment 207, 207, 213  
  liver transplantation 211–12, 213  
  multinodular 210  
  radiotherapy 213  
  screening and diagnosis 205–6  
  staging and prognosis 208–11, 209, 210, 211, 212  
  surgical resection 206–8  
  transcatheter/transarterial embolization 212–13
- heptatitis, chronic 210–11
- hereditary cancer syndromes 250  
  *see also* familial syndromes
- hereditary non-polyposis colonic cancer (HNPCC) 157, 158, 165–6, 296
- histiocytoma, malignant fibrous (MFH) 383
- HIV infection 181
- hoarseness 95
- holistic care 41
- homosexual males 181
- hormonal therapies  
  breast cancer 117–18, 133  
  endometrial cancer 300  
  melanoma 324  
  prostate cancer 276–7, 278–9, 279
- Horner's syndrome 88
- Horton, Richard 33
- hospice movement 41, 50
- HPT-JW* gene 354
- HRPT2* gene 354, 357
- Huggins, Charles 2
- $\beta$ -human chorionic gonadotropin ( $\beta$ -hCG) 287, 290
- human epidermal growth factor receptor (HER-2) 133
- human papilloma virus (HPV) 181, 295, 304, 306  
  type 16 (HPV-16) 66
- hungry bone syndrome 358
- Hurthle cell carcinoma 342, 343, 346
- hydration, advanced disease 45
- hydrocele 287
- hydronephrosis 260
- hydroxy prolene, urine 381
- 5-hydroxytryptamine (5HT) 160, 161
- hyoscine butylbromide 43, 44
- hypercalcemia 251, 381  
  parathyroid carcinoma 353, 354, 359–60
- hypercortisolism 328, 330, 406–7
- hyperparathyroidism  
  familial isolated 353  
  primary 353
- hyper parathyroid jaw tumor syndrome (HPT-JT) 353, 357
- hypertension 249

- hyperthyroidism, secondary 405
- hypocalcemia 358
- hypoxia inducible factors 252
- hysterectomy
  - total abdominal 298
  - vaginal 298
- hysteroscopy 297
- ibritumomab tiuxetan 24
- ifosfamide 24, 377
- ileal conduit 158, 264, 265
- iliac lymphadenectomy 320
- iliac lymph nodes, common 264
- imatinib mesylate 25, 26
- imiquimod 309
- immunodeficiency syndromes 158
- immunosuppression, non-melanoma skin cancer 304
- immunotherapy 309
  - melanoma 321–2
  - small bowel tumors 159
  - urothelial carcinoma 259, 263
  - vascular endothelial growth factor 159
- incidentalomas 327, 328
- India 230
- indocyanine green (ICG) clearance 207
- industrial exposures 259, 260, 272, 369–70
- inferior vena cava, tumor invasion 334, 334
- inflammatory bowel disease 158, 167, 217
- information
  - cancer patient 50, 52–4, 53
- informed consent 50
- inguinal lymph nodes 182, 183–4
- insulinoma 364, 366
- intensity modulated radiation therapy (IMRT) 70, 101
- intercostal artery perforator (ICAP) flap 142
- interferon 213, 226, 321
- interleukin-2 (IL-2) 254
- International Cooperative Study Group for HCC 208
- International Society of Urological Pathologists 261
- International Study Group on Pancreatic Fistula
  - Definition 194
- International Union Against Cancer 148
- intestinal obstruction
  - colorectal cancer 176
  - gallbladder cancer 235
  - gynecological cancers 299
  - management 43, 44
- irinotecan 24, 24, 25, 152, 245, 246
- ‘Irish’ nodes 147
- islet cell tumors 363, 364
  - gastrinoma 365–6
  - insulinoma 364, 366
  - non-functioning 366–7
- isolated limb infusion 321
- isolated limb perfusion 26–7
  - melanoma 320–1
  - soft tissue sarcoma 373, 376
- Japan 217, 218, 271, 272
- jaundice, obstructive
  - cholangiocarcinoma 219
  - gallbladder cancer 232, 234
  - pancreatic cancer 189, 190, 192–3, 195–6
- Kaposi’s sarcoma 369
- Karnofsky performance scale 400, 401
- Kausch–Whipple procedure 193
- ketoconazole 335, 407
- kidney
  - metastatic disease 251
  - surgical approaches 253
  - see also* renal cell carcinoma
- Kocher 2
- Kraissl’s lines 133
- Kraske procedure 174
- Kroll, Stephen 135
- lactate dehydrogenase (LDH) 287, 290, 315
- Lahey Clinic group, thyroid cancer staging 343
- Langer–Giedion syndrome 389
- Langerhans cells 304
- Langer’s lines 133
- laparoscopy
  - adrenalectomy 332–3, 333
  - cholecystectomy 232, 233, 234
  - colon cancer resection 170–1
  - distal gastrectomy 151
  - gastric cancer staging 148
  - hilar cholangiocarcinoma 222, 223
  - nephrectomy 253
  - nephroureterectomy 264
- laryngopharyngectomy 99–100
- latissimus dorsi myocutaneous flap 73, 374
  - breast reconstruction 130, 140–1, 141
- laxatives 44
- leiomyoma, esophagus 93, 94
- leiomyosarcoma 369
- lentigo maligna melanoma 312, 322
- leucovorin (LV) 22, 151–2, 177, 179–80, 225, 235, 245–6
- leukemia
  - chronic myelogenous (CML) 25, 26
  - secondary to chemotherapy 290
- leukoplakia 62
- leuprolerin 279
- levamisole (LEV) 177
- Leydig cells 279
- Leydig cell tumors 287
- LHRH agonists 279
- LHRH antagonists 279
- lichen sclerosis (LS) 295, 296
- Li–Fraumeni syndrome 329, 370, 385, 397
- limbs
  - chronic lymphedema 322, 370
  - soft tissue sarcoma 373
- limb salvage, skeletal sarcoma 379–80, 385
- linitis plastica 151
- lipiodol 212
- lipiodol-iodine-131-labeled microspheres 213
- liposarcoma, retroperitoneal 370
- liver atrophy, lobar, cholangiocarcinoma 220, 221
- Liver Cancer Study Group of Japan 227
- liver function, Child–Pugh classification 207, 207
- liver function tests 168, 226
- liver metastases
  - anal cancer 184
  - colorectal cancer 168, 239
  - chemotherapy 27, 243, 243–4

- liver metastases (*Continued*)
  - increasing resectability 245
  - management algorithm 244
  - outcomes of resection 243
  - patient selection for resection 239–40, 240
  - preoperative staging 240–1
  - resection 241–3, 242
  - screening 239
- gastric cancer 149
- neuroendocrine tumors 367
- non-neuroendocrine primary tumors 246–7
- pancreatic cancer 191
- liver resection
  - adrenal tumors 333, 334
  - anatomic 208, 241, 241
  - cholangiocarcinoma 221, 223–4, 224, 228
  - first performed 2
  - gallbladder carcinoma 233
  - hepatocellular carcinoma 208, 211, 213
  - metastases 241–3, 242
  - outcomes 242, 243
  - repeat 211
  - safety 213
- liver transplantation
  - cholangiocarcinoma 224, 228
  - hepatocellular carcinoma 211–12, 213
  - metastases of neuroendocrine tumors 367
- liver volume, estimation 207–8
- long-acting somatostatin receptor antagonists (LAR) 367
- loss of heterozygosity (LOH)
  - colorectal cancer 166
  - oligodendroglial tumors 396
  - parathyroid carcinoma 357
  - pituitary adenoma 405
  - skeletal sarcoma 385
- lung cancer
  - epidemiology 77
  - non-small cell (NSCLC) 77
    - adrenal metastases 81, 90
    - brain metastases 90
    - molecular fingerprinting 90
    - patient evaluation 77–8
    - physiological evaluation 82–7
    - second primary tumor 87, 90
    - stage-specific therapy 77, 78
    - staging 78, 79, 80–2, 80, 81
    - survival by stage 78, 79
  - radiotherapy 17
  - small cell carcinoma (SCLC) 77
- lung metastases 184, 240, 385
  - resection 376
  - soft tissue sarcoma 376
- lymphadenectomy
  - melanoma 320
  - ovarian cancer 298
  - pelvic 263–4
  - prostate cancer 275
- lymphangiosarcoma 370
- lymphedema, chronic limb 322, 370
- lymph node dissection
  - gastric cancer 150
  - medullary thyroid cancer 348–9
  - oropharyngeal cancers 69
  - parathyroid carcinoma 357–8
  - thyroid cancer 345–6, 348–9
- lymphoepithelioma, oropharyngeal 62
- lymphoma
  - non-Hodgkin's 24, 62, 350, 383
  - small bowel 157
  - thyroid 339, 340, 350
- Lynch I/Lynch II syndromes 165
- McCune–Albright syndrome 328, 329
- McDowell, Ephraim 1
- Macfarlane staging, adrenocortical cancer 333, 334
- Maffucci syndrome 387–8
- MAGIC trial 151
- magnetic resonance cholangiopancreatography (MRCP) 190, 218, 220–1
- magnetic resonance imaging (MRI)
  - bone tumors 380
  - breast 106
  - cholangiocarcinoma 218, 220, 220
  - esophageal cancer 96, 97
  - fluid-attenuated inversion recovery (FLAIR) 394, 395
  - glioma 394, 395, 397–8
  - liver metastases 241
  - meningioma 403, 404
  - oropharyngeal tumors 67
  - parathyroid gland 355
  - pituitary adenoma 405, 406
  - prostate cancer 275
  - renal cell carcinoma 251
  - soft tissue sarcoma 372, 372
- magnetic resonance spectroscopy (MRS) 398
- malignant fibrous histiocytoma (MFH) 383
- malnutrition, after gastrectomy 153
- mammography
  - nipple discharge 119
  - pick-up rate 105
  - see also* breast cancer, screen-detected
- mammoplasty, reduction 137–40, 137–9
- mandibular bone, reconstruction 71, 73
- Marjolin ulcer 305–6
- mastectomy
  - evolution of surgical techniques 115
  - local cancer recurrence 122–3, 123
  - modified radical (MRM) 121, 122
  - and outcomes of breast cancer 127, 128
  - Paget's disease of breast 122
  - partial
    - breast implants 143–4
    - closure of cavity 135
    - cosmetic challenges 128–9, 129
    - defect repair 135–7, 136
    - margin assessment 134–5, 134, 139–40
    - margin re-excision 132
    - and outcome of cancer 127, 128
    - recurrence of cancer 143
    - reduction mammoplasty 137–40, 137–9
    - skin incision 133–4, 133
  - prophylactic 55
  - radical 12, 115, 119
- mastopexy
  - batwing 135, 136
  - donut 136–7

- Mayo Clinic thyroid cancer staging 343–4, 344  
M D Anderson Cancer Center 120, 206  
mediastinal lymph nodes, lung cancer 81, 83, 87  
medical errors 6–7  
Medical Outcomes Study (MOS) 200  
Medical Research Council (MRC) 33, 279, 300  
megestrol acetate 45  
melanoma  
    acral lentiginous 312, 314  
    adjuvant radiotherapy 322–3  
    adjuvant systemic therapy 321–2  
    biopsy of primary lesions 312–13  
    borderline lesions 316  
    desmoplastic 322  
    historical surgery 2  
    incidence and prevalence 311  
    *in situ* lesions 316  
    invasive 316  
    lentigo maligna 312, 314, 322  
    metastatic, chemotherapy 323  
    mucosal 319  
    nodular 314  
    ocular 246, 319  
    presentation 311–13, 312  
    prognostic factors 313–14, 314  
    risk factors 311  
    sentinel lymph node biopsy 316–18  
    staging 315, 315–16  
    subungual 313, 313, 319  
    superficial spreading 312, 314  
    surgery 315–21  
        lymphadenectomy 319–21  
        metastatic disease 323  
        and tumor thickness 317, 318–19, 320  
melphalan 27, 321  
Memorial Hospital, New York 49  
Memorial Sloan–Kettering Cancer Center 222, 226, 227, 228, 229, 231, 234, 261  
MEN-1 tumor suppressor gene 405  
meningioma 401–4  
    epidemiology 402–3  
    imaging 403, 404  
    management 403–4  
    presentation 403  
mesenteric vessels, resection 193  
metaiodobenzylguanidine (MIBG) scanning 331, 331  
metastases  
    adrenal gland 81, 336  
    bone 379, 382–3  
    brain 399–401  
    kidney 251  
    lung 184, 240, 376, 385  
MET gene 384–5  
methotrexate 151, 385  
metyrapone 335  
microcalcifications, thyroid 340, 340  
micro-metastases 385  
microsatellite instability 165, 166  
microspheres 213  
microwave ablation 254  
Milan criteria 211  
Miles, Ernest 2  
minimally invasive surgery  
    esophageal cancer 97  
    gastric cancer 151  
    renal cell carcinoma 253  
    *see also* laparoscopy  
mitomycin 161, 183, 234, 235, 299  
mitotane 334, 335  
mitoxantrone 280  
Moh's micrographic surgery 307, 309  
monoclonal antibodies 24–5, 26, 118  
    VEGF 24, 246  
    *see also* named antibodies  
mood disorders 45  
Moore, Charles Hewitt 2  
morphine 43, 44  
mortality–volume relationships 194–5  
MOSAIC trial 177  
mucosal melanoma 319  
Multicenter Selective Lymphadenectomy Trial II 318  
multidisciplinary approach 56  
    palliative care 300  
    urothelial cancer 267, 268  
multiple endocrine neoplasia (MEN)  
    type 1 329, 353, 365, 365, 366, 404–5  
    type 2 329, 348, 348, 349  
    type 2A 353  
MVAC (methotrexate, vinblastine, doxorubicin, cisplatin) 265  
  
nail, subungual melanoma 313, 313, 319  
Nannoni 2  
nanoparticles 275  
nasopharyngoscopy 68  
National Cancer Database 266  
National Cancer Institute (US) 115, 166, 178  
    NCI-Intergroup phase III trial 183  
National Comprehensive Cancer Network 177, 180  
National Institute for Clinical Excellence (NICE) 161, 300  
National Institutes of Health (NIH) 177, 178  
National Surgical Adjuvant Breast and Bowel Project (NSABP) 115, 121, 177  
nausea, management 43–4  
neck dissection  
    esophageal cancer 99  
    lateral modified radical 349  
    oropharyngeal tumors 69  
    thyroid cancer 345, 348–9  
necrosis, chemotherapy-induced 385  
neobladder, orthotopic 264  
nephrectomy  
    cytoreductive 254  
    laparoscopic 253  
    partial 253  
    radical 252–3, 254  
nephritis, chronic radiation 15  
nephrostomy, prostate cancer 280–1  
nephroureterectomy 264  
    laparoscopic 264  
nerve blockade, celiac plexus 196–7  
Netherlands  
    Cancer Registry 306  
    non-melanoma skin cancers 303, 304, 306  
    pancreatic resection 195  
    total mesorectal excision trial 36, 37–8

- neurofibromatosis 157
  - type 1 329, 397
  - type 2 397, 403
- neurological deficits, glioma 397
- neutropenic sepsis 70
- NF2* gene 403
- nilutamide 279
- nipple discharge 113, 118–19
- nitrosoureas 235
- nodular lymphoid hyperplasia 158
- non-Hodgkin's lymphoma (NHL) 24, 62, 350, 383
- non-seminomatous germ cell tumors (teratoma) 287, 289, 290, 291
- non-steroidal anti-inflammatory drugs (NSAIDs) 43
- normal tissue complication probability (NTCP) 13
- North American Lung Intergroup
  - 0139 phase III study 89
  - 0160 trial 88
- North Hampshire Hospital, Basingstoke 161
- Norway 230
- Nottingham combined histological grade 114–15
- N telopeptide 381
- nurse specialists 300
- nutrition
  - after gastrectomy 153
  - esophageal cancer 98
  - prostate cancer risk 271, 272–3
  - terminal illness 45
- obesity 249
  - breast reconstruction 130
  - gallbladder cancer 230
  - gynecological cancers 295
- occupational exposure
  - prostate cancer 272
  - renal cell carcinoma 249
  - urothelial cancers 260
- octreotide 44, 363, 406
- octreotide scanning 158, 161
- ocular melanoma 246, 319
- oligodendroglioma 393, 394
  - imaging 394, 395
  - management 396
  - presentation 394
- oligodendroma, anaplastic 397, 398
- Ollier disease 387–8
- omenectomy 298
- oophorectomy
  - colorectal cancer 173
  - ovarian cancer 298
- operative mortality, gastric cancer 152
- opioids 42–3, 42, 43, 44
- Opisthorchis viverrini* 218
- oral contraceptive pill, combined 295
- oral hygiene 65
- orchidectomy 288
  - bilateral 279, 280
- organizational quality 7–8
- oronasal fistula 72
- oropharyngeal tumors
  - cervical lymph node metastases 64, 65, 68
  - diagnosis 66–7
  - etiology 61–2
  - histopathology 62
  - incidence and prevalence 65
  - lymphoepithelioma 62
  - mortality rates 61
  - outcomes 73
  - palliative care 73
  - predisposing risk factors 65–6
  - presentation 66
  - recurrence 71
  - screening 66
  - squamous cell carcinoma 62
  - staging 67–8, 67, 68
  - treatment
    - chemoradiotherapy 70, 73
    - considerations 68
    - early (historical) surgery 61
    - radiotherapy 17, 69–70
    - surgery for cure 69
    - surgical salvage 71
  - verrucous carcinoma 62
- oropharynx 61
  - anatomy 62–4, 63
  - examination 62, 66–7
  - functions 64–5
  - precancerous lesions 62
  - reconstruction 71–3, 72
- osteochondroma 387, 388
- osteochondromatosis 389
- osteoid, malignant 384, 385
- osteosarcoma 22, 383
  - epidemiology 384
  - parosteal 385
  - periosteal 385–6
  - telangiectatic 385
- outcome indicators 5–6
- ovarian cancer 1
  - adjuvant chemo/radiotherapy 25, 299–300
  - histological types 295
  - incidence and prevalence 295
  - outcomes 300–1
  - palliative chemotherapy 300
  - palliative surgery 299
  - presentation 296
  - screening 296
  - staging 297
  - surgery for cure 298
- Owen, Sir Richard 353
- oxaliplatin 24, 177, 199, 226, 245, 246
- p53 gene 165, 304, 370, 385, 397
- paclitaxel 24
- Paget's disease 381
  - breast 121–2
- pain
  - concept of total 42, 42
  - esophageal tumors 95, 95
  - gastric cancer 151
  - skeletal sarcoma 383
- pain control 42–3, 42, 43
  - pancreatic cancer 196–7
  - urothelial cancer 266
- palatal defects, through-and-through 72
- palatal island flap 72

- palatal obturator 65
- palliative care
  - anorexia and cachexia 45
  - bowel obstruction 44
  - communication 44
  - defined 41
  - development of 41–2
  - dyspnea 44
  - end-of-life 45, 45
  - gynecological cancers 300
  - nausea and vomiting 43–4, 43
  - oropharyngeal tumors 73
  - pain control 42–3, 42, 43
  - renal cell carcinoma 254
  - urothelial cancers 266
- palliative surgery 57–8
  - aims of 58
  - gastric cancer 151
  - gynecological cancers 298–9
  - pancreatic cancer 195–7
  - psychological needs of patient 57–8
  - urothelial cancers 265
- palliative therapy
  - chemotherapy 22
  - cholangiocarcinoma 225
  - colorectal cancer 176
  - esophageal cancer 101
  - radiotherapy 11
  - soft tissue sarcoma 376–7
- pamidronate 359, 359
- Pancoast syndrome 88
- pancreatectomy, total 193
- pancreatic cancer
  - adjuvant and neoadjuvant therapy 197, 198
  - diagnosis and staging 190–1, 192
  - differentiation from cholangiocarcinoma 229
  - epidemiology 189
  - future liver remnant volume estimation 207–8
  - gastric outlet obstruction 196
  - genetic factors 189
  - metastases 191
  - molecular factors 199
  - outcomes 199, 200
  - pain management 196–7
  - palliative chemo/radiotherapy 198–9
  - surgery 192–5
    - palliative 195–6
    - perioperative somatostatin 193–4
    - preoperative biliary drainage 192–3
    - volume-mortality relationship 194–5
- pancreatic endocrine tumors 363, 364, 365–7
  - biochemical markers 364
  - imaging 363–4
  - liver metastases 367
- pancreatic fistula 194, 195
- pancreatic intraepithelial neoplasia (PanIN) 189
- pancreaticoduodenectomy 229
  - partial 193–4, 194, 195
- pancreatic polypeptide secreting tumors (PPomas) 366
- pancreatitis, chronic 190, 191
- pancreatospelenectomy, radical antegrade 193
- panitumumab 25, 26
- paracetamol 43
- paraganglioma syndromes 329
- paraneoplastic syndromes, renal cell carcinoma 250
- parapharyngeal space, tumor invasion 63
- parasites, biliary tract 218
- paratesticular tumors 287
- parathyroid adenoma 354, 356
- parathyroid carcinoma
  - adjuvant therapies 359, 359
  - diagnostic strategies 354–5, 355, 356
  - etiology 353
  - incidence 353
  - non-functioning 354
  - palliative surgery 358–9
  - pathology 357
  - presentation 354
  - staging 355–6
  - surgery for cure 357–8, 358
- parathyroid glands
  - anatomy/physiology 353
  - excision 357–8, 358
  - imaging 354–5, 355, 356
- parathyroid hormone (PTH) 353, 358, 381
  - in parathyroid malignancy 354
- paratracheal lymph nodes 81, 82
- Paré, Ambroise 33
- Partin's tables 274–5, 278
- patient–doctor relations 8, 54
- patient information 50, 52–4, 53
- Pean 1
- peau d'orange 119, 120
- pectoralis major myocutaneous flap 73
- pegvisomant 406
- pelvic lymphadenectomy 263–4
- pelvis, chondrosarcoma 387, 388
- perchloroethylene 249
- percutaneous transhepatic cholangiography (PTC) 190, 220, 221
- performance indicators 5–6
- peritoneal metastases 240
- peritoneal mucinous carcinomatosis (PMCA) 161, 162
- peritoneal washings
  - cholangiocarcinoma 222
  - gastric cancer 148
- pesticide use 272
- Petit, Jean-Louis 2
- Peutz–Jeghers syndrome 166, 189
- phaeochromocytoma
  - diagnosis 330, 331, 331
  - malignant 335–6
  - surgery 331–3, 333
- pharyngeal wall, posterior 63–4
- pharyngocutaneous fistula 69
- pharyngotomy 69
- phenoxyacetic acid herbicides 369
- pheochromocytoma 328, 329
- photodynamic therapy 225, 309
- phyllodes tumor 114
- PIAF (cisplatin, interferon -2b, doxorubicin, fluorouracil) 213
- pituitary adenoma 404
  - biology 404–5
  - corticotrophic 406–7
  - epidemiology 404
  - imaging 405, 406
  - management 405–7



- null cell 405–6
  - somatotrophic 406
- platelet-derived growth factor 25, 252
- platinum-based chemotherapy agents 70
  - ovarian cancer 299–300
- pleural effusion
  - hepatic surgery 242
  - malignant 89
- polyps
  - colorectal 166
  - esophageal 93
  - gallbladder 230
- polyvinyl chloride 369
- portal hypertension 207
- portal vein
  - embolization 208, 245
  - involvement in cholangiocarcinoma 220, 221
  - resection 193
- positron emission tomography (PET) scanning
  - bone tumors 380
  - colorectal cancer 169
  - esophageal cancer 97
  - 5-fluorodeoxyglucose (FDG) 67, 81, 85, 97, 148, 241, 380
  - gastric cancer 148
  - liver metastases 241
  - neuroendocrine tumors 364
  - non-small cell lung cancer 81, 85
  - oropharyngeal tumors 67
  - parathyroid tumors 355
  - thyroid gland 340
- POSSUM score 148, 152
- postembolization syndrome 213
- postoperative complications
  - gastrectomy 152–3
  - pancreatoduodenectomy 194, 195
  - prostatectomy 277, 277
- Potocki–Shaffer syndrome 389
- power lines, high-tension 397
- prealbumin, serum 67
- prednisolone 280
- pregnancy, pheochromocytoma 328
- preoperative care and communication 52–4, 53
- primary sclerosing cholangitis (PSC) 217
- primitive neuroectodermal tumor (PNET) 386
- Pringle maneuver 242
- proctosigmoidoscopy 180
- professional standards 6–7
- progesterone receptor expression 403
- progestogens 300
- prolactinoma 405
- prophylactic surgery 55
- prostate
  - cryotherapy 277
  - transurethral resection (TURP) 276, 278
- prostate cancer
  - advanced disease 278–9
  - chemotherapy 280
  - complications 275, 280–1
  - diagnostic biopsy 276
  - grading and staging 273–5, 274, 275
  - hormone refractory 279–80
  - localized disease 276
  - locally advanced disease 278
  - presentation 273
  - risk factors 271–3
  - screening 275
  - treatment 276–80
    - hormonal therapies 278–9, 279
    - radiotherapy 277
    - surgery 276–7, 277
- prostatectomy
  - complications 277, 277
  - radical 276–7, 277
  - urothelial cancer 263
- Prostate, Lung, Colorectal and Ovarian Cancer Screening Trial (PLCO) 275
- prostate specific antigen (PSA) 273, 276, 277, 277, 381
- PROTEC study 275
- protein-calorie malnutrition 153
- prothrombin time 207
- proto-oncogenes 304
- pseudomyxoma peritonei (PMP) 160, 162
- psoralene UVA radiation (PUVA) therapy 305, 305
- psoriasis 305, 305
- psychological adaptation 52
- psychological distress
  - carers 58
  - patient 51
- psychological needs of patient 51–2, 55
  - after surgery 54
  - definitive surgery 56
  - diagnosis of cancer 55–6
  - postoperative 54
  - prophylactic surgery 55
  - recognition of 49–50
  - reconstructive surgery 56–7
- psychosocial problems 45
- PTEN* gene 397
- PTHRI* gene 388–9
- pulmonary fibrosis, bleomycin therapy 290
- pulmonary function testing 84, 85–6, 87
- PUVA therapy 305, 305
- pyloric obstruction 151
- quality control
  - clinical trials 35, 37–8
  - cyclic monitoring 5–6, 6
  - organizational factors 7–8
  - professional quality 6–7
  - relational factors 8
- quality cycle 5, 6
- quality of life
  - and breast surgery 127
  - end of life 45, 45
  - oropharyngeal tumors 65, 73
  - pancreatic cancer 199, 200
  - rectal cancer surgery 173–4
- racial differences
  - esophageal cancer 93, 94
  - melanoma 311
  - prostate cancer 271, 272
- radial forearm free tissue transfer 73
- radiation, ionizing
  - exposure to 369, 397, 403
  - see also* ultraviolet (UV) radiation
- Radiation Therapy Oncology Group (RTOG) 100

- radioactive occult lesion localization (ROLL) 106
- radioenhancers 401
- radiofrequency ablation
  - hepatocellular carcinoma 212
  - liver metastases 244–5
- radioiodine treatment 346
- radionuclide bone scans, prostate cancer 275
- radiosurgery, stereotactic 401, 404
- radiotherapy
  - adjuvant 11, 14
    - applications 17, 17
    - dose considerations 15–16
    - patient selection 15
    - time factors 16–17
  - biological basis 12–14, 13
  - bone metastases 383
  - brain tumors 398
    - low grade glioma 396
  - history 11–12
  - indications 11
  - intensity-modulated (IMRT) 70, 101
  - interstitial (brachytherapy) 277
  - malignant melanoma 322–3
  - oropharyngeal tumors 61, 69–70
  - palliative 11
  - preoperative versus postoperative 16, 16
  - sensitizing agents 12, 70, 401
  - side-effects 14–15, 14, 15
  - tumor growth rates 12
- randomized clinical trials 33
  - data management 36
  - design 34
  - difficulties in conduction 33–4
  - Dutch total mesorectal excision 36, 37–8
  - logistics 35–6
  - patient participation 35
  - quality assurance 35, 37–8
  - study protocols 34–5
- reconstructive surgery
  - after esophagectomy 99
  - after pancreatoduodenectomy 194, 194
  - breast 57, 106–7
  - lower urinary tract 264
  - oropharynx 71–3, 72
  - psychological needs of patient 56–7
  - skeletal defects 380
  - soft tissue sarcoma 373–4, 374
    - see also* breast surgery, oncoplastic
- rectal cancer
  - adjuvant and neoadjuvant therapies 17, 21, 178–80
  - clinical staging evaluation 167–70, 168
  - diagnosis 167–8
  - palliative therapies 176
  - post-treatment surveillance 180
  - quality assurance 6, 7
  - staging 167, 168
  - surgery 172–6, 173
    - abdominal perineal resection 173–4
    - guidelines 173
    - sphincter-sparing 174–5
    - total mesorectal excision 34, 37–8, 175–6, 175, 176, 179
- rectal examination, digital (DRE) 167–8, 273, 274
- rectovaginal fistula 298–9
- rectus femoris, chondrosarcoma 372
- recurrent laryngeal nerves 357
- relational quality 8
- renal biopsy 251
- renal cell carcinoma
  - ablative therapy 253–4
  - diagnosis 250–1
  - histological types 252
  - incidence and prevalence 249
  - metastatic disease 254
  - palliative care 254
  - predisposing/risk factors 249–50
  - presentation 250
  - prognosis 254
  - screening 250
  - staging 251–2, 251
  - surgery for cure 252–3
- renal embolization 253
- renal masses, small
  - management 253–4
  - natural history 252
- renal medullary carcinoma 250
- renal transplant recipients 304
- retinoblastoma, hereditary 385
- retinoblastoma (Rb) gene 370, 385
- retinol (vitamin A) 272–3
- RET proto-oncogene 349
- retroperitoneum, soft tissue sarcoma 370, 371, 374–5
- retropharyngeal space 64, 69
- rhabdomyosarcoma 22
  - pediatric embryonal 370
- rituximab 24
- Robson classification 251, 252
- root cause analysis 7
- Rydgier 1
- St Christopher's Hospice, England 41
- salivary gland tumors 62
- salpingo-oophorectomy, bilateral 298
- sarcomas
  - liver metastases 246
  - radiotherapy 17
  - small bowel 157
  - upper urinary tract 259
    - see also* skeletal sarcoma; soft tissue sarcoma
- schistosomiasis 260
- screening
  - adrenal tumors 330
  - colorectal cancer 166, 167
  - gastric cancer 147
  - gynecological cancers 296
  - liver metastases 239
  - oropharyngeal tumors 66
  - prostate cancer 275
  - renal cell carcinoma 250
  - urothelial carcinomas 260–1
    - see also* mammography
- selective venous sampling 355
- SELECT study 273
- selenium 273
- seminoma 287, 289
  - prognosis 290
  - treatment 291

- sentinel lymph node, mapping techniques 317, 317
- sentinel lymph node biopsy
- breast cancer 108, 115, 117, 121, 123
  - colorectal cancer 170
  - melanoma 316–18
  - squamous cell carcinoma 307
- serine threonine kinase STK-11 166
- Sertoli cell tumors 287
- sesta MIBI scanning 354–5, 355, 356
- sex cord tumors 287
- sex steroids 328
- sexually-transmitted diseases 181
- sickle cell trait 250
- ‘Sister Mary Joseph’ nodules 147
- skeletal pathology, prostate cancer 275, 280
- skeletal sarcomas 383–9
- chondrosarcoma 372, 383, 387–9
  - chordoma 383, 389
  - clinical presentation 383
  - Ewing’s sarcoma 370, 383, 386–7
  - imaging 383
  - osteosarcoma 384–6
  - postradiation 383
- skin cancer, *see* basal cell carcinoma (skin); melanoma; squamous cell carcinoma (skin)
- skip metastases 384
- small bowel tumors
- adjuvant treatment 159–60
  - benign 157
  - epidemiology 157, 158
  - investigation and diagnosis 158–9
  - presentation 158
  - risk factors 157–8
  - surgical treatment 159
- small cell carcinoma
- lung 77
  - upper urinary tract 259
- soft palate tumors 63, 65, 72
- cervical lymph node metastases 65
  - reconstructive surgery 72
- soft tissue sarcoma
- adjuvant therapies 26–7, 375–6
  - anatomical distribution 369, 370
  - diagnostic strategies 372–3
  - differential diagnosis 371
  - histopathology 370
  - incidence 369
  - palliative therapies 376–7
  - predisposing /risk factors 369–70
  - presentation 371
  - retroperitoneal 371, 374–5
  - staging 371, 371
  - surgery for cure 373–5, 374
- somatostatinomas 364, 364, 366
- somatostatin, pancreatic surgery 193–4
- somatostatin analogs 365
- somatostatin receptor scintigraphy (SRS) 363
- sorafenib 25, 26, 254
- Southwest Oncology Group (SWOG) 88, 89, 263
- specialist treatment centres
- appendiceal tumors 161
  - pancreatic surgery 194–5
- speech 64–5, 73
- sphincteroplasty, transduodenal 218
- spinal cord compression, prostate cancer 281
- spirometry 84, 86
- splanchnicectomy, chemical 197
- splenectomy 152
- squamous cell carcinoma
- anus 180–4
  - bladder 259
  - esophagus 93–4
  - oropharynx 62
- squamous cell carcinoma (skin)
- diagnosis 307
  - follow up 308
  - incidence/prevalence 303
  - in situ* 306
  - precursor lesions 303, 306
  - predisposing/risk factors 304–5, 305
  - prognosis 306–7, 306
  - synonyms 303
  - TNM classification 308–9, 308
  - treatment 307–8, 308
- stair climbing assessment 84
- Staphylococcus aureus*, methicillin-resistant (MRSA) 153
- Stauffer’s syndrome 250
- stent
- biliary 195–6
  - colonic obstruction 176
  - duodenal artery 195
  - small bowel obstruction 159
- stereotactic radiosurgery (SRS) 401, 404
- sternocleidomastoid muscle 64
- steroid hormones, role in disease 403
- Stewart–Treves syndrome 370
- streptozocin 335
- subcarinal lymph nodes 81, 82
- Sugarbaker, Professor PH 161
- sun exposure
- melanoma risk 311
  - non-melanoma skin cancers 304
- sunitinib 25, 26
- supportive care, principles 49
- supportive surgery 58
- suramin 335
- surgery
- history of oncological 1–2
  - integration with other therapies 3
- surveillance
- colorectal cancer 180
  - liver cirrhosis 205–6
- Surveillance, Epidemiology, and End Results (SEER) database 108, 157, 249
- swallowing
- mechanism of 65
  - restoration after oropharyngeal surgery 71–2
  - see also* dysphagia
- Swedish family cancer database 157–8
- Swedish Rectal Cancer Trial 34, 35, 179
- sweeteners, artificial 260
- ‘Swiss cheese’ model 7
- symptoms, assessing/alleviating 54
- systematic reviews 33

- Taiwan 217, 260
- tamoxifen 118, 295, 323
- targeted therapies 25, 26
  - pancreatic cancer 199
  - renal cell carcinoma 254
  - see also* immunotherapy
- taxanes 118, 121, 300
  - approved indications 23–4
  - gastric cancer 152
  - mechanism of action 23–4
  - prostate cancer 280
- technetium-99 labeled methylene diphosphonate bone scan 380
- technetium-99m pertechnetate 354
- technetium-labeled Sesta MIBI 354–5, 355, 356
- temozolomide 396, 398, 401
- tentorium cerebelli, meningioma 404
- teratoma 287, 289, 290, 291
- terminal disease
  - nutrition 45
  - psychological needs of patient 54
  - see also* palliative care
- testicular implant, silicone 288
- testicular intraepithelial neoplasia (TIN) 292
- testicular torsion 288
- testicular tumors
  - chemotherapy 289–91
  - etiological factors 287
  - fertility 290–1
  - histopathology 287, 288–9
  - metastatic spread 288
  - post-chemotherapy management 291–2
  - post-treatment follow-up 292
  - presentation 287–8
  - prognostic classification 289, 290
  - relapse of disease 292–3
  - serum markers 287, 290
  - staging 289, 290
  - surgical management 288
- testosterone, prostate cancer 272, 279
- Thailand, cholangiocarcinoma 217, 218
- thalidomide 45
- thiotepa 263
- thoracodorsal artery perforator (TAP) flap 73, 141–2
- thoracoscopy, video-assisted (VATS) 93, 96, 97
- thyroglobulin 347
- thyroid cancer 7
  - anaplastic 339, 340, 341, 350
  - distribution of cell types 339, 340
  - epidemiology 339, 339
  - etiology 339
  - follicular 339, 340, 343
  - Hurthle cell 342, 343, 346
  - lymphoma 339, 340, 350
  - medullary 339, 340, 341, 347–50
  - outcomes 349–50
  - papillary 339, 340, 341, 342, 343
  - staging and prognosis 343–5, 344
  - treatment
    - adjuvant therapy 346–7
    - medullary cell 348–9
    - well differentiated cancer 345–6
- thyroidectomy
  - partial 346
    - in parathyroid carcinoma 358, 358
  - total 345, 348–9
- thyroid function tests 340
- thyroiditis, autoimmune 342
- thyroid nodules 339–43
  - classification 343
  - evaluation 340–2, 340, 341
  - incidence 342–3
- thyroid replacement hormone 346
- thyroid stimulating hormone (TSH) 346–7
  - recombinant (Thyrogen) 347
- tibia, Ewing's sarcoma 386
- tinea capitis, radiotherapy for 403
- TNM staging
  - adrenocortical cancer 333, 334
  - anal cancers 182
  - bone tumors 381
  - breast cancer 116–17, 119
    - and prognosis 123
  - colorectal cancer 167, 168
  - esophageal cancer 95–6, 96
  - gallbladder cancer 230–1, 231
  - hepatocellular carcinoma 208–9, 209, 210
  - malignant melanoma 315, 315–16
  - non-small cell lung cancer 78, 79–81
  - oropharynx 67–8, 67, 68
  - prostate cancer 273, 275, 275
  - renal cell carcinoma 251–2, 251
  - soft tissue sarcoma 371
  - squamous cell carcinoma of skin 308–9, 308
  - thyroid cancer 343, 344, 348, 348
  - urothelial carcinoma 261, 262, 266
- tobacco use, *see* cigarette smoking
- To Err is Human* 6–7
- Tokyo, National Cancer Center Hospital 152
- tongue base
  - anatomy 63
  - reconstructive surgery 72
  - tumors 62, 65, 68
- tonsillar tumors 62, 63, 66, 66
  - cervical lymph node metastases 65
- tonsils, anatomy 63
- topotecan 23, 300
- tositumomab 24
- total mesorectal excision (TME) 34, 175–6, 175, 176, 179
  - Dutch trial 36, 37–8
- TP-53* 62
- tracheotomy 73
- transanal endoscopic microsurgery (TEM) 174
- transarterial chemoembolization (TACE) 27, 212–13
- transcatheter arterial embolization (TAE) 212–13
- transesophageal fistula 100
- transforming growth factors (TGF- $\alpha$  /TGF- $\beta$ ) 252
- transitional cell carcinoma, *see* urothelial carcinoma
- transplant recipients 158, 304
- transurethral resection of prostate (TURP) 276, 278
- transurethral resection (TUR) 261
- transverse rectus abdominis myocutaneous (TRAM) flap 130, 130, 142–3
  - free 143
  - pedicled 142

- trapezius myocutaneous flap 73
- trastuzumab 24, 26, 118, 133
- treatment delays 7–8
- trichlorethylene 249
- tritorelin 279
- Trogan system 370
- TRPS1 gene 389
- tuberous sclerosis 250
- tumor banks 36
- tumor behavior, variability 90
- tumor biology 2–3
- tumor control probability (TCP) curves 13, 13
- tumor growth kinetics 21
- tumor markers
  - CA 19.9 159, 161, 189–90
  - CA125 296
  - carcinoembryonic antigen (CEA) 159, 161, 189–90, 239, 240, 349
  - colorectal cancer 169
  - gynecological cancers 296
  - hepatocellular carcinoma 205–6
  - medullary thyroid cancer 349
  - pancreatic cancer 189–90
  - testicular tumors 287, 290
- tumor necrosis factor- $\alpha$  (TNF- $\alpha$ ) 27, 321, 376
- tumor seeding, gallbladder cancer 233
- tumor suppressor genes 304
  - p53 165, 304, 370, 385, 397
  - VHL 250, 252
- Turcot's syndrome 165
- tyrosine kinase inhibitors 25, 26, 254
- ulcerative colitis 217
- ultrasound
  - axillary lymph nodes 106
  - breast 106, 114, 119
  - cholangiocarcinoma 220, 220
  - endorectal 169–70
  - endoscopic 95, 96, 97, 147, 148, 190, 191
  - gallbladder cancer 232, 232
  - high intensity focused (HIFU) 278
  - liver 206, 239
  - ovaries 297
  - parathyroid tumors 355, 356
  - thyroid 340, 340
  - transrectal 274
  - transvaginal 297
- ultraviolet (UV) radiation
  - skin cancers 304, 311
  - prostate cancer 272
- umbrella cells 259
- University of Southern California 267–8
- ureteropyeloscopy 261
- ureteroscopy 261
- urethrectomy 263
- urinary tract diversion 264, 265
- urinary tract obstruction
  - gynecological cancers 300
  - prostate cancer 280–1
- urine analysis, bone tumors 381
- urine cytology 260–1
- uroepithelium 259
- urothelial carcinoma 259
  - chemotherapy 265–6
  - diagnostic strategy 261
  - etiology 259
  - grading and staging 261, 261, 262, 263
  - incidence and prevalence 259
  - multidisciplinary approach 267, 268
  - outcomes 266–8, 266, 267
  - palliative care 266
  - palliative surgery 265
  - predisposing/risk factors 259–60
  - presentation 260
  - radiotherapy 265–6
  - screening 260–1
  - surgery for cure 263–4
  - upper tract 259
  - see also* bladder cancer
- US Multi-Society Task Force on Colorectal Cancer 166
- uterine cancer
  - variants 295
  - see also* endometrial cancer
- vaccine development
  - human papilloma virus (HPV) 181
  - melanoma 321–2
- Vancouver Cancer Registry 108
- vascular endothelial growth factor (VEGF) 252
  - monoclonal antibodies 24, 246
  - overexpression 250
- velopharyngeal closure 63
- venous sampling, selective 355
- ventilation perfusion scanning 84, 86, 87
- verrucous carcinoma, oropharynx 62
- vesicovaginal fistula 298–9
- Veterans Administration Cooperative Urological Research Group 279
- Veterans Affairs Hospitals, US 229
- video-assisted thoracoscopic surgery (VATS) 80, 81, 87, 93, 96, 97, 99
- vinblastine 24, 213, 265
- vinca alkaloids 22, 24
- VIP-secreting tumors 364, 364, 366
- Virchow's node 147
- vitamin A (retinol) 272–3
- vitamin D 272, 358
- vitamin E 273
- vomiting
  - gastric cancer 151
  - management 43–4
- von Hippel–Lindau gene (VHL) 250, 252, 329
- von Hippel–Lindau (VHL) syndrome 250, 329
- von Langenbuch, Carl 2
- vulval cancer 17
  - adjuvant therapy 299–300
  - diagnostic strategy 296
  - incidence and prevalence 295
  - outcomes 300, 301
  - palliative care 300
  - palliative surgery 298–9
  - predisposing factors 295
  - presentation 295–6
  - screening 296

- 
- staging 297
  - surgery for cure 297–8
  - vulval intra-epithelial neoplasia (VIN) 295, 296
  
  - waiting lists 7
  - Waldeyer's fascia 175
  - Waldeyer's ring tumors 62, 63, 68
  - weight loss 95, 95, 226
  - well woman screening 296
  - Westernization of disease 2
  - Whipple procedure 193, 366
  - whole brain radiation therapy (WBRT) 399, 400–1
  - Wolcott, E B 2
  - World Health Organization (WHO)
    - analgesic ladder 42
    - glial tumor grading 393, 394
    - non-melanoma skin cancer 303
  
  - pain management 196–7
  - palliative care definition 41, 195
  - urothelial cancer grading 261, 261
  - WR-2721 (amifostine) 360
  
  - xeroderma pigmentosum 304
  - xerostomia 15
  - X-ray
    - bone tumors 380
    - esophageal cancer 95
    - lung cancer 80–1, 85
  
  - York–Mason procedure 174
  - Young, Hugh 2
  - yttrium-90-labeled microspheres 213
  
  - zoledronic acid (zoledronate) 280, 359, 360
  - Zollinger–Ellison syndrome (ZES) 365, 366



# Textbook of Surgical Oncology

Edited by

Graeme J Poston

R Daniel Beauchamp

Theo JM Ruers

Surgery alone cures more than 60% of those patients whose cancer are amenable to curative treatment. Surgical oncology is not universally accepted as a unified discipline worldwide. There are many reasons for this situation, including the drive to anatomic site specialisation, but also the need to provide comprehensive 'general' surgical provision to more isolated and rural communities.

*Textbook of Surgical Oncology*, written by a highly acclaimed list of international authors, comprehensively covers the role of the surgical oncologist in the management of patients with solid tumours. This book provides a state of the art review of cancer surgery for senior residents approaching certification at the completion of their training as well as providing an up to date reference work for established clinicians in their day to day practice, including those in general surgery, surgical oncology, urologists, gynaecologists, thoracic, neurosurgical, radiation oncologist and medical oncologists.

#### Sections include

General Principles • Head and Neck • Thoracic • Breast • Gastroenterology • Urology  
• Gynaecology • Skin • Endocrine • Sarcoma • Brain

#### About the editors

**Graeme J Poston, MB BS, MS, FRCS(Eng), FRCS(Ed)**, Director of the Division of Surgery, University Hospital Aintree, Liverpool, UK

**Theo J M Ruers, MD, PhD**, Head of the Division Surgical Oncology, The Netherlands Cancer Institute, Amsterdam, The Netherlands

**R. Daniel Beauchamp, M.D., F.A.C.S.** is J.C. Foshee Distinguished Professor and Chair and Surgeon-in-Chief, Professor of Cancer Biology, Vanderbilt University Medical Center, Nashville, Tennessee, USA.

**informa**  
healthcare

[www.informahealthcare.com](http://www.informahealthcare.com)



9 781841 845074

