



Sorting the Sheep from the Goats: Morphological Distinctions between the Mandibles and Mandibular Teeth of Adult *Ovis* and *Capra*

P. Halstead and P. Collins

Department of Archaeology and Prehistory, University of Sheffield, Northgate House, West Street, Sheffield S1 4ET, U.K.

V. Isaakidou

Institute of Archaeology, University College London, 31–34 Gordon Square, London WC1H 0PY, U.K.

(Received 24 May 2001, revised manuscript accepted 16 November 2001)

Diagnostic criteria are described for the taxonomic discrimination of adult mandibles of sheep (*Ovis aries*) and goat (*Capra hircus*). These criteria, based on morphological distinctions in the mandible, permanent premolars (P3–P4) and molars (M1–M3), have been successfully tested on a large and diverse body of modern reference material. In conjunction with published work on deciduous premolars, the new criteria enable complete and fragmentary mandibles of young, adult and elderly individuals to be identified to sheep or goat with acceptable levels of accuracy.

© 2002 Elsevier Science Ltd. All rights reserved.

Keywords: ARCHAEOZOOLOGY, MANDIBLE, TEETH, SHEEP, *OVIS*, GOAT, *CAPRA*, IDENTIFICATION.

Introduction

Although sheep and goat may be herded together and raised for the same goals, these two species exhibit significant differences in environmental tolerances, feeding preferences, ease of control, reproductive characteristics, carcass quality, and range of secondary products (e.g., Payne, 1973; Redding, 1981, 1984). Archaeozoological analyses of mortality patterns for the combined category “sheep/goat” thus risk masking important contrasts in management between these species or, worse still, creating an illusory composite picture which is valid for neither species. These problems are particularly acute in areas, such as the Mediterranean and Near East, where both sheep and goat have long been major constituents of livestock populations. Young ovicaprid mandibles, containing deciduous premolars (dp3, dp4) and/or very lightly worn first or second molars (M1, M2) and representing animals up to c. 2 years of age, can be speciated following Payne (1985). The analysis of adult mortality patterns, however, has largely been dependent on the problematic evidence of postcranial epiphyseal fusion; in addition to the usual limitations of fusion data (e.g., Payne, 1972; Watson, 1978), the identification of postcranial material to sheep or goat tends to be much

more difficult for juvenile than for adult specimens (Boessneck, Müller & Teichert, 1964). Recently, Helmer (2000) has published diagnostic criteria for the permanent premolars, P3 and P4, of sheep and goat, which greatly aid separation of adult mandibles of these two species. The present paper describes tested diagnostic criteria for the separation of adult mandibles (with deciduous premolars replaced by permanent) of sheep and goat. These criteria partly overlap with those of Helmer, but also cover the molars (M1–M3) and parts of the mandible and can thus be applied to a broader range of fragmentary material. They can also be used to separate younger mandibles in which application of Payne’s published criteria is precluded by loss of dp3 and dp4 and degree of wear of M1 and M2 (in our experience, beyond wear stage 7a of Payne, 1987: 610 Figure 1).

Materials and Methods

Diagnostic criteria were initially sought, tested, revised and refined on adult mandibles of 43 sheep and 41 goats held in the modern reference collection of the Department of Archaeology and Prehistory, University of Sheffield. In addition, also from the

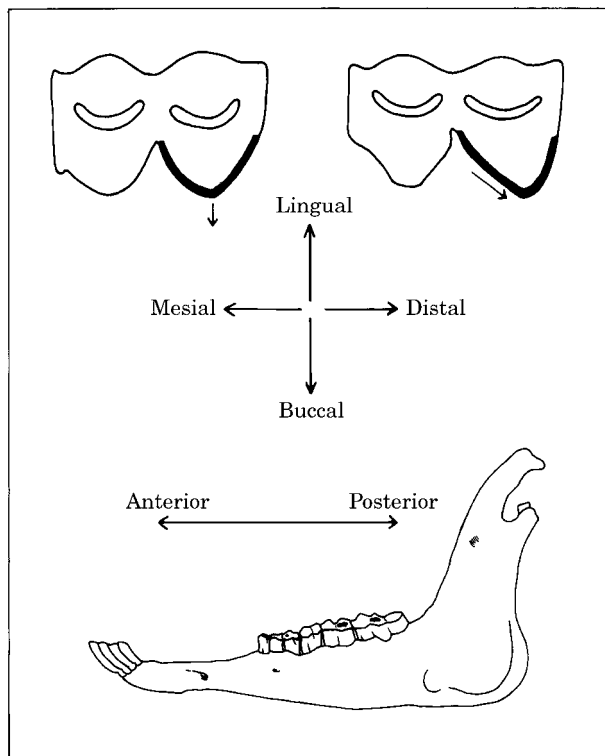


Figure 1. The terms “mesial”, “distal”, “buccal” and “lingual” are used to denote different parts of the tooth; the terms “anterior” and “posterior” are used to denote the orientation of particular features relative to the mandible as a whole. Thus, the buccal edge of the bucco-distal cusp (shown by a thickened line) points in a posterior direction in the tooth on the right but not in that on the left.

Sheffield collection, young mandibles (but with M1 erupting or erupted) were examined of 20 sheep and 28 goats, in order to explore further the speciation of M1 and M2 in early wear. Because the ultimate aim of this project was the archaeozoological analysis of mortality patterns rather than taxonomic differentiation *per se*, the search for diagnostic criteria was restricted to the mandibular cheek tooth row (P2–M3) and to the adjacent parts of the mandible. Useful diagnostic criteria were found on P3, P4, M1, M2 and M3 and on the parts of the mandible immediately adjacent to P2–P4 and posterior of M3.

The revised and refined criteria were then tested in two stages, with the aim of evaluating their diagnostic value and reliability both individually and in combination. First, the Sheffield mandibles on which the diagnostic criteria were originally developed, were examined “blind” (mandible by mandible, rather than tooth by tooth or criterion by criterion). Plainly, a blind test on an independent set of mandibles would have been preferable, but this re-examination was conducted some months after the material was last handled and the collection is sufficiently large to minimize the risk that the analyst can “cheat” by recognizing the colour, size or wear state of individual specimens. For each modern mandible, the following information was recorded:

- (1) accession number;
- (2) species attribution and, if known, provenance, age, sex, and breed;
- (3) the state of eruption and wear of P3–M3;
- (4) the scoring of each of 22 diagnostic criteria as “sheep”, “goat”, “possible sheep”, “possible goat”, “indeterminate” (i.e., intermediate, ambiguous or resembling neither) or “unsuitable for diagnosis” (i.e., broken, missing, insufficiently erupted, too worn);
- (5) the overall attribution of the mandible to “sheep”, “goat”, “possible sheep”, “possible goat” or “indeterminate”, taking account not only of the scores for each criterion but also of the reliability and asymmetry of each criterion (see below).

Secondly, a similar examination was conducted, and similar records were made, of 31 adult and 40 young sheep and 107 adult and 24 young goats held by the British Museum of Natural History in London, the National Museum of Wales in Cardiff (Noddle collection), the Museum d’histoire naturelle in Paris, and Dr Ingrid Mainland of Bradford University. The London, Cardiff, Paris and Mainland collections have the advantage of being independent of the material on which the criteria were developed, but could not practicably be used for blind testing because the material is stored by taxon.

The provenance information for these modern specimens is of varying quality (particularly for earlier accessions), but the material examined for both species includes individuals drawn from wild or feral populations and several domestic breeds, with a broad geographical range (Table 1), and ranging in age from juveniles (with deciduous premolars), through young adults (with permanent premolars erupting or unworn), to elderly individuals (with all premolars and molars heavily worn or lost). Thus intra-specific variability, though doubtless not exhausted, has been explored fairly thoroughly.

Description of Diagnostic Criteria

Most dental criteria are described in occlusal view and for teeth in medium wear; criteria may be unclear or misleading in unworn/lightly worn and heavily worn teeth. It is useful to view also the buccal or lingual face of the tooth for criteria P3.1–2, P4.1, M1.1–3, M2.1–3 and M3.1–4, especially if the occlusal surface has not yet been worn flat. It is *essential* to view the buccal face for criteria M1.4 and M3.5. Note that the terms “buccal”, “lingual”, “mesial” and “distal” are used to describe the location of diagnostic features within individual teeth, while “anterior” and “posterior” refer to the orientation of these features or to the location of features within the mandible (Figure 1).

Most of the criteria described below are “symmetrical”, in the sense that alternative forms provide means

Table 1. Sources of modern comparative material consulted
a. Nos of individuals studied, by species and age group, in each collection

Collection	Sheep		Goat		Total
	Young ¹	Adult ²	Young ¹	Adult ²	
Sheffield	20	43	28	41	132
BMNH, London	0	2	9	40	51
NMW, Cardiff	0	0	15	42	57
MNHN, Paris	0	12	0	25	37
Mainland	40	17	0	0	57
Total	60	74	52	148	334

¹With deciduous premolars in place.

²With permanent premolars erupting/erupted.

Table b. Country of origin and species/breed/population (where known)³

Domestic sheep	Greenland (Northern Short-Tail), Iceland, Scotland (incl. Scottish Blackface), England (incl. Herdwick, Portland, White-Faced Woodland), France, Dahomey, Greece (local and improved breeds), Albania, Spain
Wild/feral sheep	England (farmed Soay, mouflon [<i>Ovis musimon</i>])
Domestic goats	England (incl. Bagot, Golden Guernsey), Sardinia, Greece (incl. local and improved breeds), Spain, Egypt, Sudan (incl. Dwarf Nilotic), Nigeria, Tanzania, Comores, Madagascar, Nepal, India, Tahiti
Wild/feral goats	Scotland (Rhum feral, Arran feral), Greece (Cretan feral), Azores (?feral), Iran (<i>C. aegagrus</i>), Oman (<i>C. aegagrus</i>)

³Attributions to wild, feral or domestic populations, based on museum records, may be inaccurate in the case of some early accessions.

of identifying both sheep and goat, with more or less even reliability. It is important to note, however, that some criteria are “asymmetrical” in that, while one form may positively identify goats, the alternative form is compatible with both sheep and goats.

P3 (Figure 2a)

P3.1. A vertical ridge in the middle of the lingual face is more strongly developed in sheep. As a result, the lingual edge of the occlusal face is usually clearly “stepped” in sheep and usually forms a more or less straight line, inclining buccally in a posterior–anterior direction, in goat.

P3.2. The vertical ridge on the disto-buccal corner tends to be more pronounced in sheep. As a result, the distal part of the buccal edge forms a relatively distinct and deep hollow in sheep, but a more or less shallow and indistinct hollow in goat.

P3.3. The mesial part of the buccal face slopes inwards (lingually) in a posterior–anterior direction more strongly in goat than sheep; the mesial face often slopes anteriorly in a bucco-lingual direction in goat, but is typically perpendicular to the axis of the mandible in sheep. As a result, the mesio-buccal quarter of the tooth tends towards a right angle in sheep, but towards a more open angle (in extreme cases, almost approach-

ing a straight line) in goat. N.B. the mesio-buccal “corner” may be rounded or angled in both species.

P3.4. Overall, the tooth tends to be longer and slenderer in goat, shorter and broader in sheep, but these dimensions may be altered by tooth wear and masked by tooth crowding.

P4 (Figure 2b)

P4.1. The mesio-lingual corner is typically marked by a vertical rib, projecting lingually, in sheep; this feature is typically weak or absent in goat. (There is a similar, but less consistent, difference between sheep and goat on the disto-lingual corner.)

P4.2. The mesio-buccal quarter of the tooth forms an open angle (clearly more than 90 degrees) in goat, but is closer to a right angle (sometimes rounded, sometimes with the “corner” emphasized by a vertical rib) in sheep.

P4.3. Overall, the tooth tends to be longer and slenderer in goat, usually shorter and broader in sheep, but these dimensions may be altered by tooth wear and masked by tooth crowding.

M1 and M2

M1.1 and M2.1 (Figure 2c). The mesial part of the buccal edge (ignoring the buccally projecting flange on

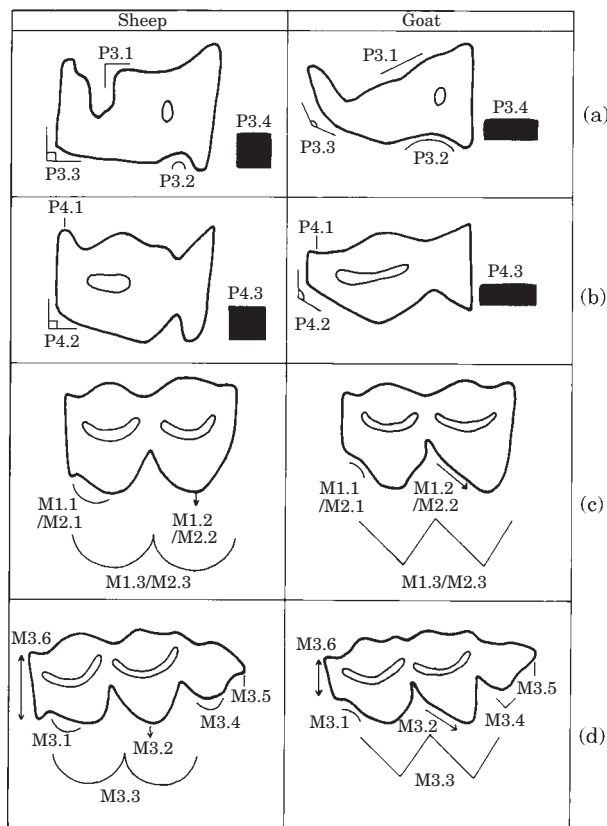


Figure 2. Morphological criteria for distinction between mandibular teeth of sheep and goat, in occlusal view. Orientation: mesial(/anterior) left, distal(/posterior) right, lingual above, buccal below. The numbering of each criterion (P3.1, P3.2, etc.) follows the description in the text. (a)—P3, (b)—P4, (c)—M1 and M2, (d)—M3.

the mesial corner) is typically convex in sheep, but often concave in goat. Note that the mesial part of the buccal edge may be somewhat hollow (or goat-like) in unworn M1 and M2 and also in heavily worn M1 and M2 (especially those beyond the “mature” wear stage 9A [Payne, 1987: 610 Figure 1]), even in sheep; criteria M1.3 and M2.3 (below) may aid correct identification in such cases.

M1.2 and M2.2 (Figure 2c). The buccal edge of the disto-buccal cusp of M1 and M2 often points strongly in a posterior direction in goat, while typically it is relatively symmetrical in sheep. Thus, a strong posterior orientation is indicative of goat, but a slight or no posterior orientation, although more typical of sheep, is compatible with either sheep or goat. Note that the distal margin of *unworn and lightly worn* M1 and M2 (up to wear stages 6A/7A [Payne, 1987: 610 Figure 1]) flares in a posterior direction so that, in such cases, the buccal edge of the disto-buccal cusp may be symmetrical (or sheep-like) even in goats.

M1.3 and M2.3 (Figure 2c). The buccal edge of M1 and M2 overall tends to a pointed “triangular” appearance

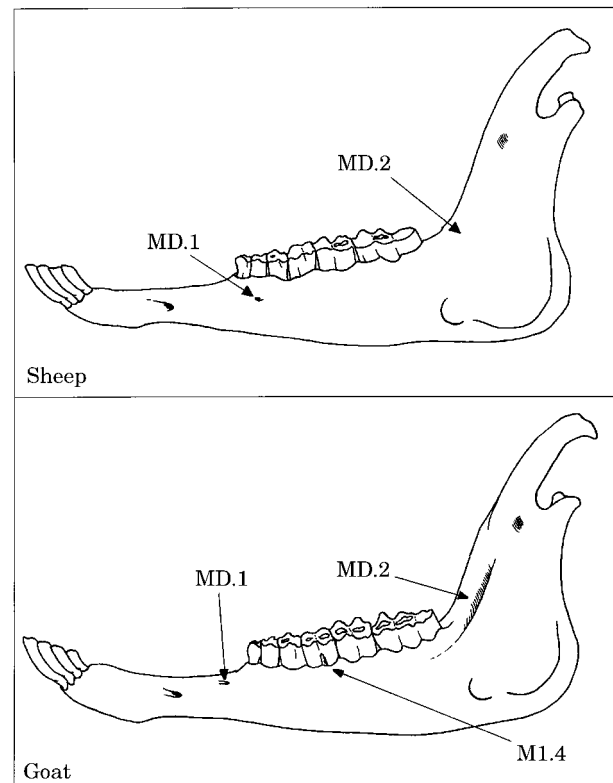


Figure 3. Morphological criteria for distinction between mandibles of sheep and goat, in lateral view. The numbering of each criterion (MD.1, MD.2) follows the description in the text. Note that, in goat, MD.1 may be anterior of P2 (as shown) or absent altogether. The dental criterion M1.4 is also shown.

in goat and to a rounded “arcaded” appearance in sheep. This criterion in part subsumes criteria M1.1–2 and M2.1–2.

M1.4 (Figure 3). A “caprine pillar” occurs fairly frequently on the buccal face of goat M1 and very rarely in sheep (Payne, 1985: 143). The presence of a pillar is thus strongly suggestive of goat, but the absence of a pillar has no diagnostic value. A similar pillar was observed in M2 and M3 of goat, but so rarely as to be of very limited routine diagnostic value.

M3 (Figure 2d)

M3.1. The mesial part of the buccal edge of the mesio-buccal cusp of M3 (ignoring the buccally projecting flange on the mesio-buccal corner) is typically convex in sheep, but often concave or flat in goat. Note that the mesial part of the buccal edge may be somewhat concave (or goat-like) in heavily worn M3 (beyond wear stage 11G [Payne, 1987: 610 Figure 1]), even in sheep; criterion M3.3 (below) may aid correct identification in such cases.

M3.2. The buccal edge of the centro-buccal cusp of M3 often points strongly in a posterior direction in goat,

while it is relatively symmetrical in sheep. Thus, a strong posterior orientation is indicative of goat, but a slight or no posterior orientation is compatible with sheep or goat. Note that the distal margin of the centro-buccal cusp of *unworn and lightly worn* M3 (up to wear stages 6A/7A [Payne, 1987: 610 Figure 1]) flares in a posterior direction so that, in such cases, the buccal edge of this cusp may be symmetrical (or sheep-like) even in goats.

M3.3. The buccal edge of the mesial and central parts of M3 overall tends to a pointed “triangular” appearance in goat and to a rounded “arcaded” appearance in sheep. This criterion in part subsumes criteria M3.1–2. Thus, a flat and pointed profile is indicative of goat; conversely, a rounded profile is more typical of sheep than goat, but is of less diagnostic value than the corresponding criteria in M1 and M2 (i.e., M1.3 and M2.3).

M3.4. The buccal edge of the distal cusp of M3 is often more or less pointed in goat and typically rounded in sheep. Thus, a pointed edge is suggestive of goat, but a rounded edge is compatible with sheep or goat.

M3.5. The distal margin of the distal cusp of M3 often has a buccally defined “flute” in sheep, rarely so in goat. Thus, the presence of a flute is strongly suggestive of sheep, while its absence is suggestive of goat. Note that a flute defined only lingually is of no diagnostic value and that a buccally defined flute may be clearer in buccal than in occlusal view. (The diagnostic value of a distal flute was suggested to the authors independently by Profs H.-P. Uerpmann and A. J. Legge).

M3.6. The flange on the mesial face of M3 tends to be broad in sheep and narrow in goat, but this feature is heavily influenced by, and must be judged relative to, the degree of occlusal wear. Thus, a broad flange is suggestive of sheep in a lightly worn M3 (up to, say, wear stage 10G/10H [Payne, 1987: 610 Figure 1]) and less securely so in an M3 of medium wear (at the long-lasting stage 11G), but may be compatible with either species in a heavily worn M3 (from, say, wear stage 12G/12H onwards). Conversely, a narrow flange is strongly suggestive of goat in an M3 of medium or heavy wear (from, say, stage 11G onwards) and less securely so in a lightly worn M3.

The mandible (Figure 3)

MD.1. On the lateral face of the mandible, a foramen is frequently found below P2–4 in sheep, but is typically absent or, less commonly, present but anterior of P2 in goat.

MD.2. Immediately posterior of M3, the lateral face of the mandible usually has a more or less pronounced hollow in goat, which is typically slight or absent in

sheep. In sheep, a single obvious sinus is common, whereas in goat there tends to be no sinus or two or more indistinct sinus. This criterion cannot be evaluated until M3 is fully erupted and the mandible has more or less achieved full size.

The Reliability of Individual Criteria

Taking together all the modern collections examined, 334 mandibles of known species were studied. For individual criteria (Table 2), the number of specimens potentially attributable to species (i.e., excluding those “unsuitable for diagnosis” because of breakage, loss, insufficient eruption or excessive wear) ranged from a minimum of 183 (55%) for M3.5 (requiring full eruption of the distal cusp of M3 for reliable attribution) to a maximum of 331 (99%) for MD.1 (usually available for inspection even when teeth were unerupted, broken or shed). Of these potentially attributable cases, the number classified as “indeterminate” (i.e., intermediate, ambiguous or atypical) on a particular criterion ranged between 1 and 39 (0–15%).

The accuracy of identifications to species varied between criteria. Moreover, while some criteria (e.g., all those for P3 and P4) were equally able to identify sheep and goats, other “asymmetrical” criteria (see descriptions for M1.2, M2.2, M3.2, M3.3, M3.4, M3.6 and especially M1.4) could only positively identify goats. On individual criteria, 84–100% of attributions to goat were correct; the corresponding figures for sheep are only 43–95%, but are much higher, at 83–95%, if the “asymmetrical” criteria (Table 2) are excluded. As all the criteria used are qualitative rather than quantitative, and as the distinction between “possible sheep” or “possible goat”, on the one hand, and “indeterminate” or “unsuitable for diagnosis”, on the other hand, is somewhat subjective, the percentage figures for correct attribution should not be taken as precise measures of reliability. They do, however, suggest that, with due allowance for any “asymmetry”, each criterion, even in isolation, has considerable diagnostic value.

Helmer’s study of mandibular P3 and P4 of sheep and goats (Helmer, 2000) draws attention to criteria essentially comparable with our P3.1, P3.3 and P4.2, although defined in slightly different terms. He studied 40 modern mandibles not examined for the present study and his results were only seen, in draft form, after completion of the present study. The compatibility of the results of these two, entirely independent, studies must be regarded as very encouraging.

The Reliability of the Criteria in Combination

When the diagnostic criteria were used in combination, the ease of identification of modern mandibles of known species was still variable. In some mandibles, teeth were of intermediate appearance or different

Table 2. Number and percentage of correct attributions to species for individual diagnostic criteria in modern mandibles (all collections combined)

	Attributions to sheep ¹			Attributions to goat ²			Indet.	Total ³
	Sheep	Goat	% correct	Sheep	Goat	% correct		
P3.1	82	14	85	139	9	94	10	254
P3.2	40	2	95	133	8	94	11	194
P3.3	47	4	92	132	5	96	6	194
P3.4	38	8	83	112	7	94	28	193
P4.1	89	13	87	145	5	97	5	257
P4.2	58	3	95	137	3	98	5	206
P4.3	45	7	87	115	6	95	31	204
M1.1	77	6	93	133	8	92	38	262
M1.2 G	100	66	60	111	10	92	12	299
M1.3	103	15	87	152	7	96	26	303
M1.4 G	113	149	43	28	2	93	1	293
M2.1	99	8	93	145	7	95	15	274
M2.2 G	98	64	60	89	10	90	17	278
M2.3	101	9	92	120	6	95	39	275
M3.1	67	15	82	114	4	97	12	212
M3.2 G	66	31	68	89	6	94	10	202
M3.3 (G)	69	22	76	81	0	100	31	203
M3.4 G	55	52	51	67	7	91	10	191
M3.5	49	10	83	105	15	88	4	183
M3.6 G	59	33	64	90	13	87	15	210
MD.1	93	5	95	186	36	84	11	331
MD.2	67	11	86	107	0	100	12	197

¹Including specimens scored as either “sheep” or “possible sheep”.

²Including specimens scored as either “goat” or “possible goat”.

³Attributions to sheep+attributions to goat+“indeterminate” (i.e., excluding “unsuitable for diagnosis”). G “Assymetrical” criterion suitable for positive identification of goat only.

criteria for the same tooth were contradictory. In others, some teeth were typical of sheep and others of goat; indeed rare examples of each tooth (P3–M3) in mandibles of both sheep and goat closely resembled the wrong species. In many cases, however, most or all criteria and most or all teeth were consistently typical of either sheep or goat (Figure 4). In general, identification was easiest for mandibles with all teeth in moderate wear, because the greatest number of criteria could be assessed. It was harder to identify mandibles with erupting or heavily worn teeth and hardest for senile mandibles with missing teeth, because fewer criteria could be assessed (Figure 4c,f). In identifying each mandible, therefore, an overall judgement was made of the strength of evidence in favour of each species, taking account of the state of preservation (and hence assessability) of relevant cusps, the degree of similarity to the “typical” forms, defined here, and the “asymmetry” of certain criteria; identification was not based on a simple tally of the number of criteria scored to each species and indeed, some mandibles were (correctly, as it transpired) assigned to the species represented by fewer criteria. The attribution of mandibles, using a combination of observable criteria in this way, was remarkably successful.

When the Sheffield adult mandibles, on which the criteria were originally developed, were re-examined “blind”, all 84 mandibles were correctly identified to

species; young mandibles were excluded from this exercise to avoid the risk of a successful identification being based on Payne’s established criteria for dp3–dp4 or lightly worn M1–M2. The London, Cardiff, Paris and Mainland collections were not examined “blind”, but identification based on the new diagnostic criteria was “incorrect” in only three out of 138 adult mandibles. Moreover, in two of these cases (one each in London and Paris), the contentious mandible could be securely matched with a cranium which demonstrated clearly that our mandibular identification was correct and the museum accession records incorrect. In the third case (BMNH no. 3048), the accuracy of the accession records is at least open to doubt: labelled as a goat collected in 1962 on the Scottish island of Rhum, this accession in fact comprises at least two individuals, including one mandible attributed by ourselves to goat and a pair of mandibles attributed to sheep. In sum, the diagnostic criteria presented here have been tested with remarkable (probably 100%) success against a large and varied body of modern control specimens.

While examining these modern mandibles, the opportunity was taken also to test the validity of Payne’s criteria for identification of dp3–dp4 and of unworn/ lightly worn M1–M2 (Payne, 1985). Mandibles of 60 young sheep and 52 young goats were examined in the Sheffield, London, Cardiff, Paris and Mainland

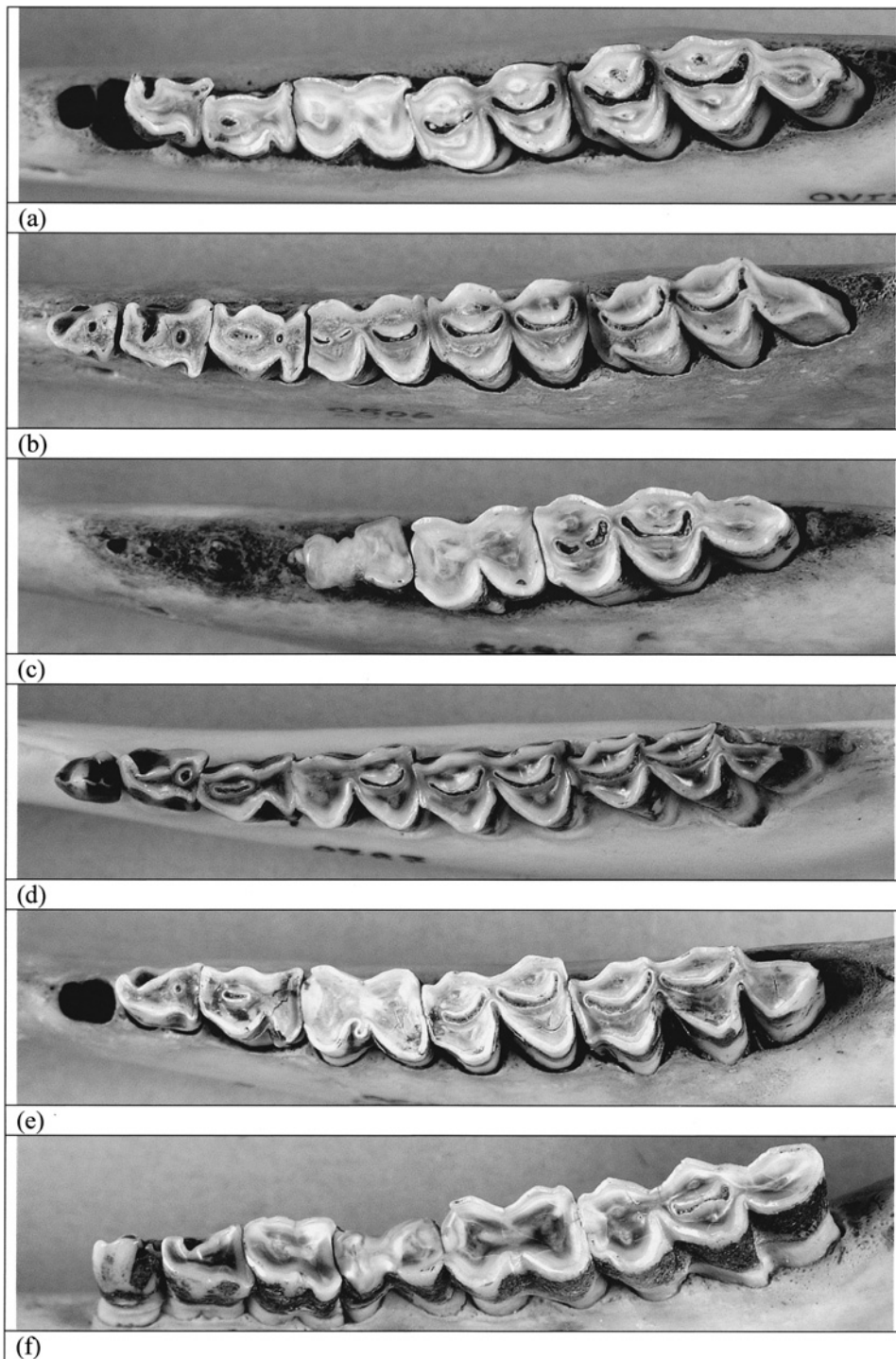


Figure 4. Mandibles of modern adult sheep and goats in occlusal view, illustrating more or less “typical” examples of various criteria. Orientation as in Figure 1. (a) Sheep (Sheff. 0711; from Derbyshire, U.K.): all dental criteria are classified as “sheep”, except M3.6 (“possible sheep”) and P3.3 (“indeterminate”); both mandibular criteria (not shown) are classified as “sheep”. (b) Sheep (Sheff. 0506; from C. Macedonia, Greece): all dental criteria are classified as “sheep”, except M3.4 (“possible goat”) and M1.1 (“unsuitable for diagnosis”); both mandibular criteria (not shown) are classified as “sheep”. (c) Female sheep (Sheff. 0482; from C. Macedonia, Greece): P3 and P4 are missing and M1 is too heavily worn for diagnosis; dental criteria for M2 and M3 are classified as “sheep” (the “flute” of M3.5 is clearer in buccal view); both mandibular criteria (not shown) are classified as “sheep”. (d) Male goat (Sheff. 0787; from C. Macedonia, Greece): all dental criteria are classified as “goat”, except M1.2, M1.4 and M2.2 (all “sheep”); both mandibular criteria (not shown) are classified as “goat”. (e) Female goat (Sheff. 0513; from C. Macedonia, Greece): all dental criteria are classified as “goat”, except P4.2 and P4.3 (“indeterminate”), M1.1 (“unsuitable for diagnosis”) and M3.6 (“possible sheep”); both mandibular criteria (not shown) are classified as “goat”. (f) Female goat (Sheff. 0585f; from C. Macedonia, Greece): M1 is too worn for diagnosis; dental criteria for P3, P4, M2 and M3 are classified as “goat”, except P4.2 and P4.3 (both “possible goat”) and P4.1 and M3.6 (both “unsuitable for diagnosis”); both mandibular criteria (not shown) are classified as “goat”.

collections. Although representing a considerably larger and more heterogeneous control sample than that originally used by Payne, his published diagnostic criteria were thoroughly vindicated, with difficulties encountered only in the case of teeth insufficiently erupted for thorough inspection.

Application of the Criteria to Archaeological Mandibles of Unknown Species

To date, the new criteria have been applied by the authors to archaeological mandibles from a range of prehistoric sites in Greece (Late Neolithic Makrigialos and Late Bronze Age Toumba Thessalonikis in Central Macedonia, Final Neolithic Doliana in Epirus, Late Neolithic–Early Bronze Age cave of Zas in the Cyclades, Early Neolithic and Early Bronze Age Knossos and Early Bronze Age Poros on Crete, Late Bronze Age Pylos in Messenia), Ireland (Mediaeval Dublin) and Scotland (Mediaeval Dun Vulcan in the Outer Hebrides). As with the modern material, the archaeological assemblages include mandibles in which all criteria are consistently suggestive of either sheep or goat, others in which some criteria suggest sheep and some suggest goats, and others in which some or all criteria are ambiguous. Identification is further hindered by the fragmentation of the archaeological assemblages, although identification of loose teeth on these criteria did speed up the strewing and mending of fragmented mandibles. These adult mandibular criteria “work” well in the sense that most of the material examined could be identified with some confidence, with the greatest difficulties being posed by incomplete or heavily worn specimens. The proportion of indeterminate specimens is probably higher than that encountered by the present authors in applying Payne’s criteria for dp3–dp4 to young mandibles, but far lower than that normally encountered in postcranial material (following Boessneck, Müller & Teichert, 1964; Prummel & Frisch, 1986) because of the difficulty of identifying immature postcranial specimens and the vulnerability of postcranial specimens to postdepositional attrition. These archaeological applications are, of course, strictly untested, although not untestable (cf. Loreille *et al.*, 1997), but it is encouraging that loose teeth and mandible fragments, independently identified to the same species using these criteria, were frequently found to belong to the same mandible during mending.

Conclusions

The criteria presented here, in combination with those published by Payne (1985), enable sheep/goat mandibles of all ages to be identified to species. Speciation is most difficult in very young mandibles, with unerupted teeth, and in very old mandibles, with heavily worn or shed teeth. Overall, however, teeth tend to be better preserved than postcranial material and so these cri-

teria are widely applicable. All of the criteria exhibit intra-specific variability, but no more so than the widely used postcranial criteria. As with the postcranial criteria, these mandibular criteria are more reliable in suites than individually and are best interpreted with the aid of modern reference specimens. The importance has been stressed of distinguishing between “symmetrical” criteria, equally able to identify both sheep and goats, and “asymmetrical” criteria which only allow positive identification of one species (in this case goat); similar caution is needed with some of the standard postcranial criteria for speciating sheep and goats.

Acknowledgements

The initial impetus for this study was a drawing on a beer-mat at Troy by Hans-Peter Uerpmann of a criterion (our M3.5) which was subsequently and independently suggested also by Tony Legge. In building up the Sheffield collection of modern mandibles, we are particularly grateful to Francis Pryor and Maisie Taylor, for Soay sheep and mouflon carcasses from Flag Fen Visitor Centre, in England, and to Stelios Moukhalis of Assiros, in Greek Macedonia, for heads of local sheep and goats; Yannis Tzelepis and Panagiotis Miaouras kindly provided burial space in Assiros and Makrigialos, respectively, for our Greek specimens, while Rocky Hyacinth and Glynis Jones helped with burial and cleaning. The collection and initial analysis of modern reference material in Greece was undertaken in tandem with archaeozoological study of material from Makrigialos, funded by the British Academy and the Institute for Aegean Prehistory; our diagnostic criteria were refined with the help of AHRB funding for faunal analysis at Makrigialos.

For access to collections at the BMNH in London, Natural History Museum in Cardiff and Museum d’histoire naturelle in Paris, we are grateful to Paula Jenkins and Richard Sabin, to Peter Howlett, and to Jean-Denis Vigne, respectively. Louise Martin and Ingrid Mainland have provided a variety of valuable comments on the project and the latter also made accessible a large assemblage of sheep mandibles from Scotland and Greenland. We are indebted to Jenny Marchant and Colin Merrony respectively for original drawing and final composition of Figures 1–3, to Rob Craigie for production of Figure 4, and to Glynis Jones, Ingrid Mainland, Louise Martin and Jean-Denis Vigne for comments on the clarity of the text. Finally, we thank Jean-Denis Vigne for bringing to our attention the parallel study by Daniel Helmer.

References

- Boessneck, J., Müller, H.-H. & Teichert, M. (1964). Osteologische Unterscheidungsmerkmale zwischen Schaf (*Ovis aries* Linné) and Ziege (*Capra hircus* Linné). *Kühn-Archiv* **78**, 1–29.

- Helmer, D. (2000). Discrimination des genres *Ovis* et *Capra* à l' aide des prémolaires inférieures 3 et 4 et interpretation des ages d' abattage; l' exemple de Dikili Tash (Grèce). *Anthropozoologica* **31/Ibex: Journal of Mountain Ecology** **5**, 29–38.
- Loreille, O., Vigne, J.-D., Hardy, C., Callou, C., Treinen-Claustre, F., Dennebouy, N. & Monnerot, M. (1997). First distinction of sheep and goat archaeological bones by the means of their fossil mtDNA. *Journal of Archaeological Science* **24**, 33–37.
- Payne, S. (1972). On the interpretation of bone samples from archaeological sites. In (E. Higgs, Ed.) *Papers in Economic Prehistory*. London: Cambridge University Press, pp. 68–71.
- Payne, S. (1973). Kill-off patterns in sheep and goats: the mandibles from Asvan Kalé. *Anatolian Studies* **23**, 281–303.
- Payne, S. (1985). Morphological distinctions between the mandibular teeth of young sheep, *Ovis*, and goats, *Capra*. *Journal of Archaeological Science* **12**, 139–147.
- Payne, S. (1987). Reference codes for wear states in the mandibular cheek teeth of sheep and goats. *Journal of Archaeological Science* **14**, 609–614.
- Prummel, W. & Frisch, H.-J. (1986). A guide for the distinction of species, sex and body side in bones of sheep and goat. *Journal of Archaeological Science* **13**, 567–577.
- Redding, R. (1981). *Decision Making in Subsistence Herding of Sheep and Goats in the Middle East*. PhD thesis, University of Michigan.
- Redding, R. (1984). A herder's decisions: the sheep/goat ratio. In (J. Clutton-Brock & C. Grigson, Eds) *Animals and Archaeology* **3**. (BAR Int. Series **202**). Oxford: British Archaeological Reports, pp. 223–241.
- Watson, J. P. N. (1978). The interpretation of epiphyseal fusion data. In (D. R. Brothwell, K. D. Thomas & J. Clutton-Brock, Eds) *Research Problems in Zooarchaeology*. London: Institute of Archaeology, pp. 97–101.